

Practical clinical considerations in endodontic re-treatment

Authors_Dr Richard E. Mounce, USA & Dr Gary D. Glassman, Canada

Non-surgical endodontic re-treatment (NSER) of failed root canals is almost exclusively a specialist procedure, owing to the complexity of diagnosis, treatment planning and advanced techniques required for re-treatment procedures. As implants have become more predictable, the level of clinical success required with NSER in an attempt to retain the natural dentition has taken on new significance. This article reviews and discusses several key conceptual strategies for the re-treatment of failed root canals that optimise the outcome of the procedure.

It is assumed here that the clinician appreciates the value of the surgical operating microscope (SOM; Global Surgical) and ultrasonics in re-treatment procedures. While it is beyond the scope of this article to elaborate at length on the use of the SOM, its use is associated with improved outcomes of NSER and endodontic surgery.

Conceptually, NSER can be broken down into several key steps:

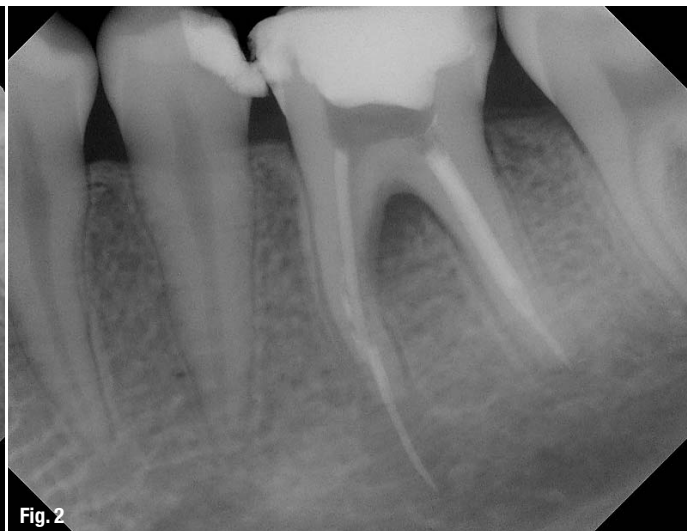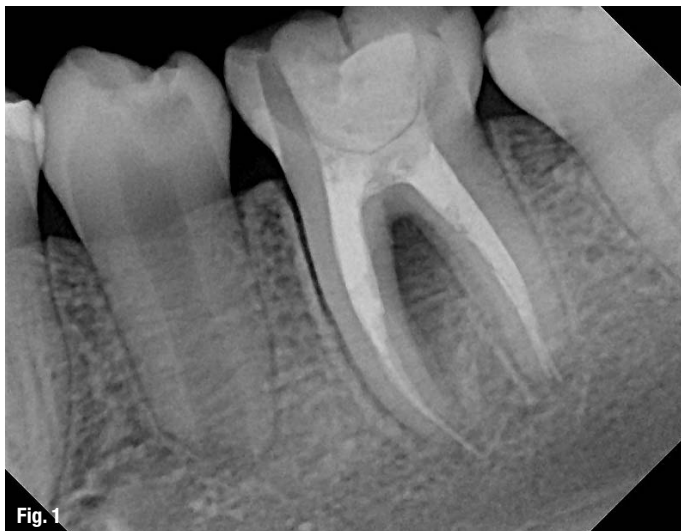1) Determination of restorability

The determination of restorability is a key component of NSER success. Treatment on teeth that are non-restorable is obviously contra-indicated. If these teeth were extracted from the pool of candidates for either endodontic therapy or NSER, success rates for both treatments can only go up. Figures 1 to 3 show three different cases that were poorly treated using inappropriate concepts and for which removal was indicated. Had the initial endodontic therapy been correctly conducted, the probabilities of clinical success would obviously have been far greater and the option of implant therapy irrelevant.

In the context of NSER, rather than compounding the existing failure, the clinician should carefully examine the case at hand and evaluate whether the tooth can be re-treated, and if so what the likely success will be. The initial treatment of the teeth pictured in Figures 4 to 6 was conducted to a high standard and for

Figs. 1-3_Endodontic treatment with significant resulting iatrogenic events and other clinical defects.

Figs. 4-6_Endodontic treatment conducted within the standard of care.



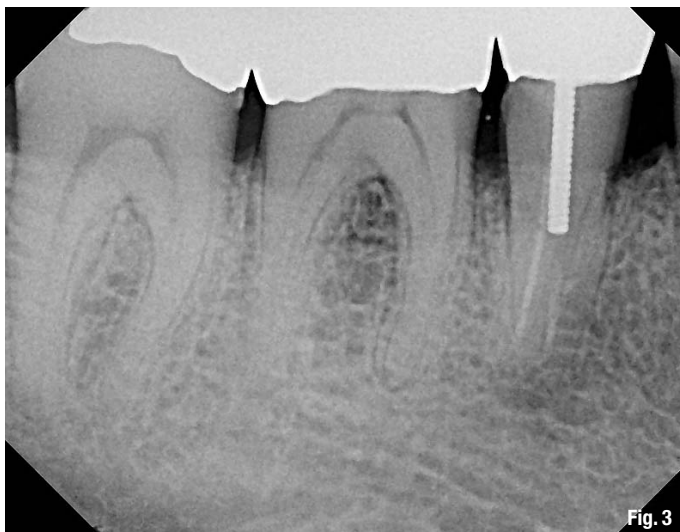


Fig. 3

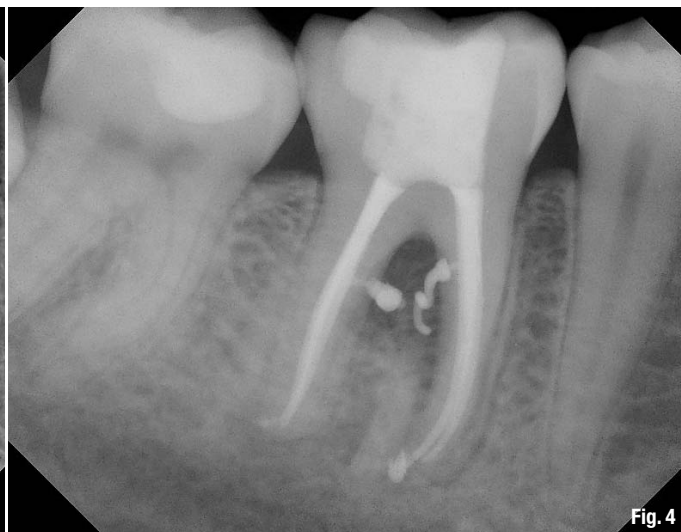

Fig. 4

this reason treatment will have a much better chance of long-term success. The difference between the two sets of outcomes is in large measure related to the different levels of pre-operative risk assessment.

2) *Preoperative diagnosis and assessment of risk factors*

One aspect of the determination of restorability is whether the tooth is vertically fractured and/or whether treatment will make vertical fracture likely. In addition, if the tooth has not had an overt iatrogenic event, the clinician should determine whether the contemplated treatment will lead to one. Near strip perforations through overzealous shaping can lead to overt strip perforations, should the removal of existing obturation material not be performed passively and with the correct methods (heat removal first, mechanical second, solvents and patency files third). The placement of highly

tapered rotary nickel titanium (RNT) files into large canals at high speed is predictive of mid-root strip perforation. Minimising this risk is addressed in detail below.

3) *Access*

If at all possible, the crown should be removed. Leaving crowns in place and creating access risks leaving portals for coronal micro-leakage, unset restoratives, caries and fractures. It also minimises access for evacuation of the obturation material and removal of objects of all types that may be lodged in the canal system (such as posts and RNT file fragments). A compromised access will limit both the tactile and visual control of the clinician and as a result some teeth that could otherwise be re-treated successfully are compromised.

It is noteworthy that the vast majority of failed root canals show evidence of overt coro-

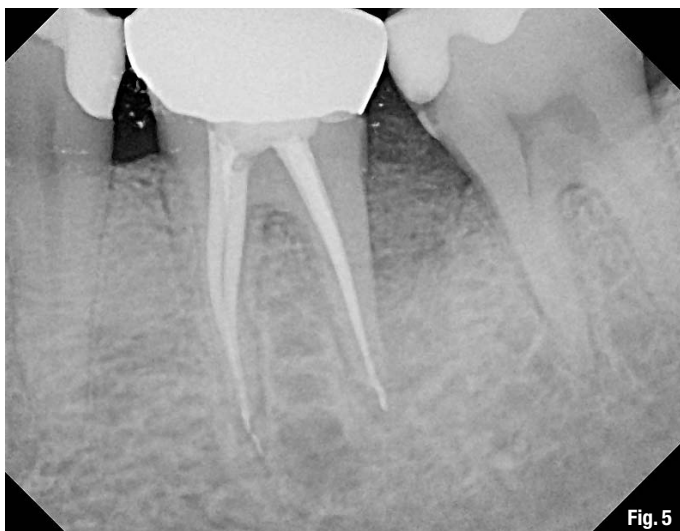

Fig. 5

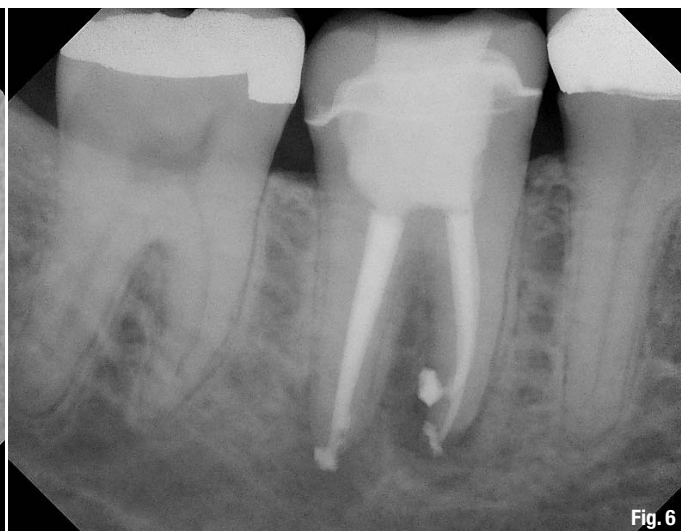
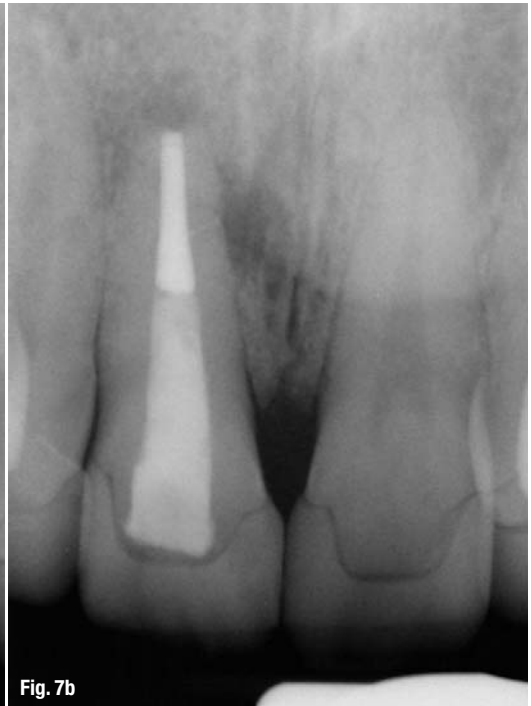
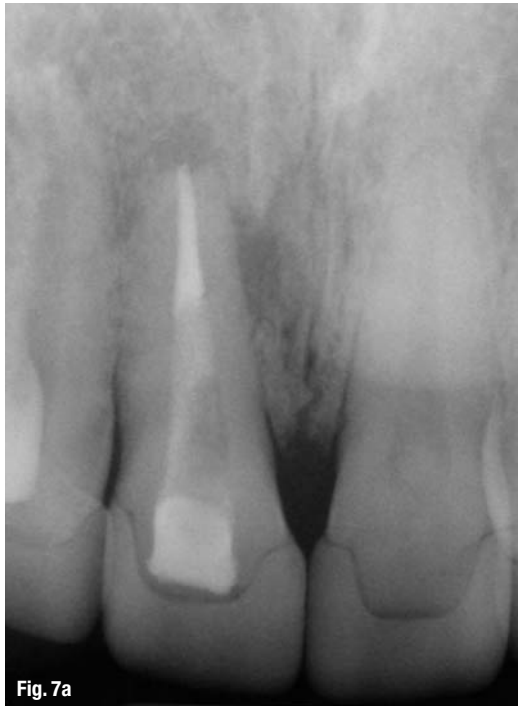

Fig. 6

Figs. 7a–9b Clinical cases re-treated using the concepts above with the Twisted File and RealSeal bonded obturation.



nal micro-leakage once their crowns are accessed. This micro-leakage appears in the form of odour, moisture, unset restoratives and voids, amongst other visual clues. Assuring that the post-endodontic result will be sealed correctly is best accomplished through removal of the crown, re-treatment procedures and the placement of a new coronal build-up. Owing to its ease of use and durability, Dr Mounce uses Maxcem (Kerr) for build-ups, a self-etching, self-adhesive composite cement.

4) Removal of posts and coronal obstructions of all types including the build-up

While a comprehensive discussion of post and obstruction removal is beyond the scope of this paper, it should be mentioned that the overriding principle in removal of all obstructions is to remove as little dentine as possible in order to minimise both perforation and the risk of vertical root fracture. As a result, the greater the extent to which procedures can be performed that both cools the tooth to prevent overheating during ultrasonic vibration and conserves tooth structure, the greater the probability of clinical success. The Ruddle Post Removal System is invaluable in this regard if used correctly. Post removal involves selecting the correct ultrasonic tips. The coronal access must be ideal before either the orifice is managed or the clinician progresses beyond the orifice. Attempting to remove obturation material or shape the orifice without attaining straight-line access is contraindicated.

5) Removal of canal contents

The coronal access must be ideal before either the orifice is managed or the clinician progresses beyond the orifice. Attempting to remove obturation material or shape the orifice without attaining straight-line access is contraindicated.

The removal of canal contents is passive, gentle and done in three waves (heat, mechanical and solvents). The Elements Obturation Unit (EOU) is an excellent source of heat for removing gutta-percha. The heat plugger of the EOU is used in the same motion as the System B down-pack. Approximately half of the gutta-percha can be removed with one to two down-pack motions per canal. Removal of gutta-percha with the heat tips also creates a space into which the RNT instruments can be placed to remove shreds of gutta-percha that remain along the walls. Both the removal of gutta-percha with heat and with RNT instruments is done dry.

These two successive steps allow the vast majority of gutta-percha to be removed and if performed correctly minimise the amount of solvent to be placed in the presence of hand files and time required to achieve patency. It is essential that the RNT files that are used to remove gutta-percha entered passively and gently, and used with an upward brush-stroke away from the furcation. Placing them apically with force into the mass of gutta-percha can easily lead to strip perforation, particularly if the existing dentinal wall next to the furcation is relatively thin from the start, owing to previous overzealous shaping.

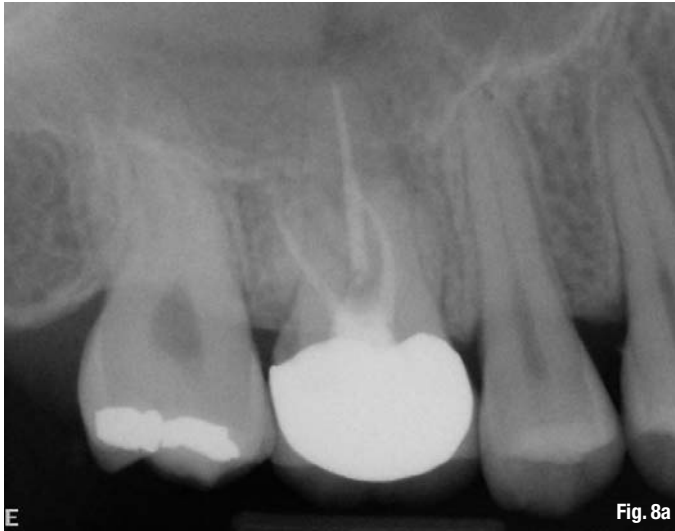

Fig. 8a

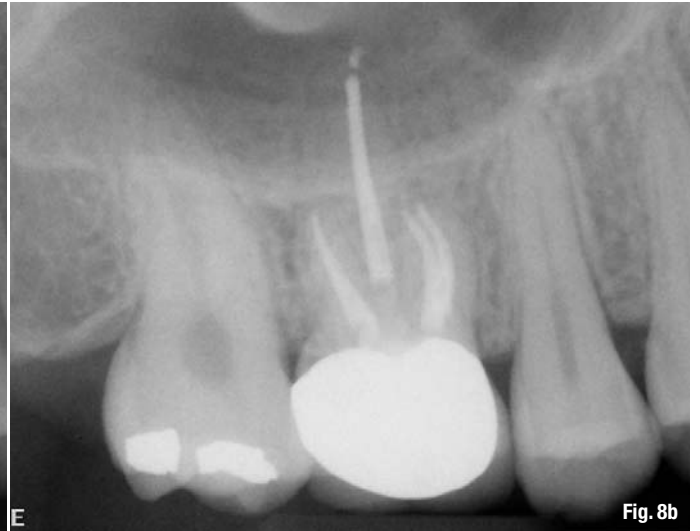

Fig. 8b

6) *Assessment and repair of iatrogenic events if possible*

The two most common iatrogenic events encountered are canal transportations and separated instruments, commonly RNT files. The deeper the instrument fragments, the lesser the chance that they can be retrieved. This said, ideal access, crown removal, use of the SOM and creation of the ideal orifice size can all contribute towards fragment visualisation, even if the fragment is at or slightly beyond a curvature in the apical third of a root. In addition, it is optimal to use the thinnest ultrasonic tips possible that allow the clinician an optimal view of the fragment used in an anticlockwise motion to remove the dentine that binds the fragment. RNT fragments should not be directly vibrated (touched) by ultrasonic tips. Doing so will cause them to shatter. In addition to ultrasonics, there are many systems available that engage the fragment with either frictional retention or possible tube and glue options.

Instrument fragments that are entirely beyond the apical curvature and that cannot be bypassed are generally left in place and obturation is placed up to them. In the event of clinical failure with RNT fragments lodged, it may be required to follow NSER with root resection and retrofill.

7) *Achievement and maintenance of apical patency*

Once the canal is evacuated of gutta-percha, the clinician will need to spend as much time as it takes to either achieve apical patency or determine that apical patency is unattainable. Fortunately, in many clinical failures, the apical third of a large number of roots has not been touched owing to an inaccurate determination of working length, as well as an inadequate cleaning and shaping. In any event, in the apical 3 to 4 mm of a root with #6, 8 and 10 hand K-files, the clinician should place one

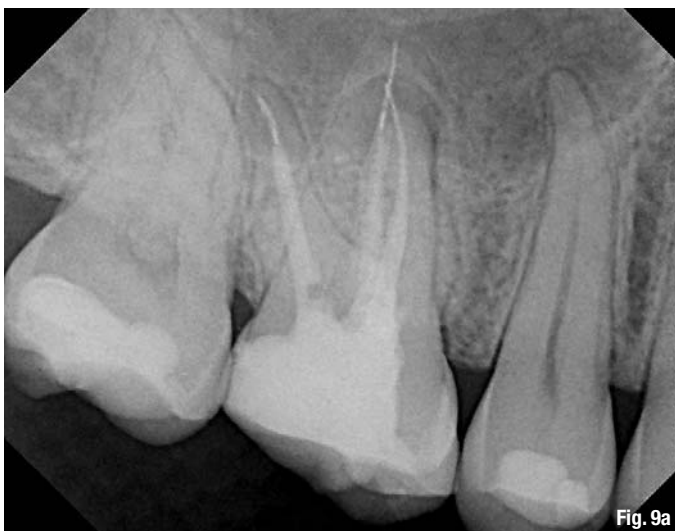

Fig. 9a

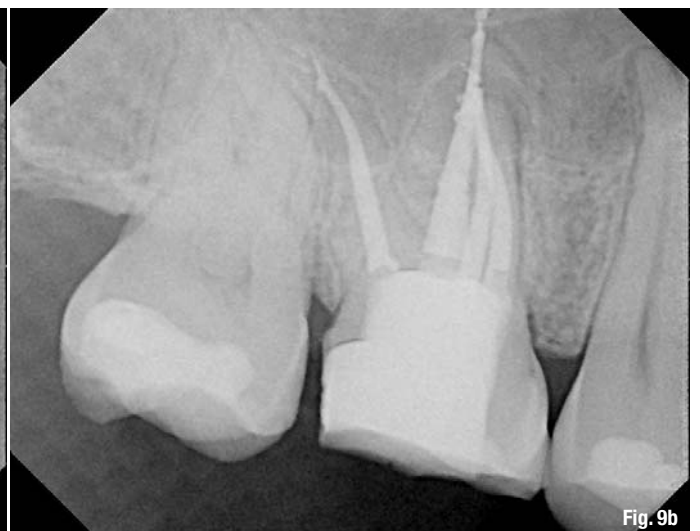

Fig. 9b

drop of chloroform into the canal at a time until the hand K-files just reach the MC. Once the estimated working length has been reached, the electronic apex locator can be used and the first determination of true working length can be obtained.

When and where to stop attempts at achieving patency are common clinical concerns. In essence, when is it time to fill to the depth gained in the canal in the absence of patency? If repeated attempts to gain patency have failed using pre-curved hand K-files of the appropriate length and diameter, particularly if the clinician is sure that he or she has removed all of the previous obturation materials, the canal should be cleaned and shaped to an optimal diameter despite the blockage and then obturated. This recommendation notwithstanding, an experienced clinician can often gain patency in cases in which an inexperienced one cannot. This difference in skill level is usually related to the amount of pressure used, the correct curvature of the hand K-file, the correct diameter of the hand K-file, adequate irrigation and clinical experience.

8) *Achievement of the optimal master apical diameter*

In the endodontic literature, the achievement of the correct apical diameter is correlated with

enhanced cleanliness. Such larger apical diameters provide greater irrigant flows and the removal of necrotic dentine up to the MC. It is a common finding in failed endodontic cases that both the apical diameter and master apical taper are too small. One way to determine the ideal master apical diameter is through gauging; alternatively, the clinician can simply instrument the canal to the desired master apical diameter, keeping in mind that non-vital teeth have higher failure rates because they are harder to cleanse relative to vital teeth (for which the emphasis is on asepsis rather than disinfection of an already infected canal).

9) *Obturation*

One benefit of creating larger apical diameters is the ease of cone fit and obturation, be it obturation with a master cone or obturator. Given that one of the most significant causes of clinical endodontic failure is the loss or lack of coronal seal, it makes intuitive sense to bond the obturation. In both *in vitro* and *in vivo* studies, RealSeal in the master cone and form of RealSeal 1 Bonded Obturator has been shown to resist the movement of bacteria in canals to a statistically significant degree relative to gutta-percha. In addition to placing a coronal seal in step 10 below, this provides an invaluable step in addressing one of the weaknesses of gutta-percha: it is a material that bonds neither to dentine nor to sealers, thus it is entirely dependent on the placement of a coronal seal for it to function clinically. Bonding obturation is simple; the clinician clears the smear layer with a liquid EDTA such as SmearClear and subsequently rinses with distilled water. After drying the canal, the RealSeal self-etching sealer is placed in the canal and obturation is achieved with either the aforementioned RealSeal master cones or RealSeal One Bonded Obturator.

10) *Placement of a coronal seal*


A number of clinical principles and steps have been addressed that can streamline endodontic re-treatment procedures conceptually and clinically. Emphasis has been placed on optimal visual and tactile control, removal of crowns before re-treatment, passive removal of previous obturation materials and obstructions, repair and revision of previous treatment, achievement and maintenance of apical patency, and optimisation of master apical diameter.

We welcome your feedback.

_about the authors		roots
	<p>Dr Richard E. Mounce lectures globally and is widely published. He has a private practice specialising in endodontics in Vancouver in Washington. Dr Mounce offers intensive customised endodontic single-day training programmes in his office for one or two doctors. For information, contact Dennis at +1 360 891 9111 or E-mail RichardMounce@MounceEndo.com.</p> <p>Dr Mounce is also the author of the non-fiction book <i>Dead Stuck</i>, "one man's stories of adventure, parenting, and marriage told without heaping platitudes of political correctness", by Pacific Sky Publishing (www.deadstuck.com).</p>	
	<p>Dr Gary D. Glassman has authored numerous publications and is on the staff in the Faculty of Dentistry in the graduate Department of Endodontics at the University of Toronto. A renowned international lecturer on endodontics, Dr Glassman has presented at major dental conferences around the world. He is an endodontic editor for Oral Health and maintains a private practice in Toronto, Ontario. He can be reached through his website: www.rootcanals.ca.</p>	

EndoInnovations III

SybronEndo offers you advanced technology for safer, more efficient procedures.

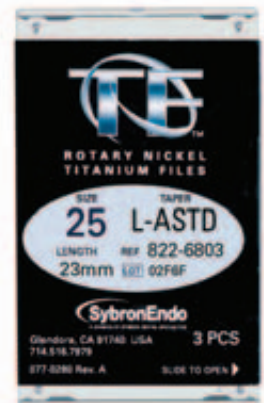


REALSEAL 1 Warm-Bonded Obturator

All the components of RealSeal 1™ – sealer, filler and core – are resin-based materials that chemically bond with each other to form a *superior seal*. As an added benefit, this system's core is engineered to be easily seen on a radiograph.

TF – Faster, Safer, Stronger

TF™ is twisted, not ground – unlike other nickel titanium files – making it more durable. Endodontic files are made by grinding the flutes, weakening the metal's molecular structure which can lead to separation. Our unique manufacturing process produces a file with optimal sharpness, strength and flexibility. TF allows you to work in difficult situations faster, safer and with a stronger file.



SybronEndoEurope | *Safe files, superior fills.*

A DIVISION OF SYBRON DENTAL SPECIALTIES

SybronEndo Europe, Basicweg 20, 3821 BR Amersfoort, The Netherlands
tel: +31 33 4536 159 fax: +31 33 4536 153 email: Endo@SybronDental.com

SybronEndo, 1717 West Collins Avenue, Orange, CA 92867
800.346.ENDO 714.516.7979 Fax 714.516.7911 SybronEndo.com