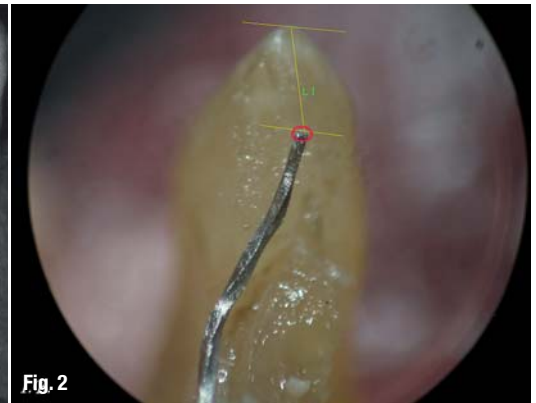
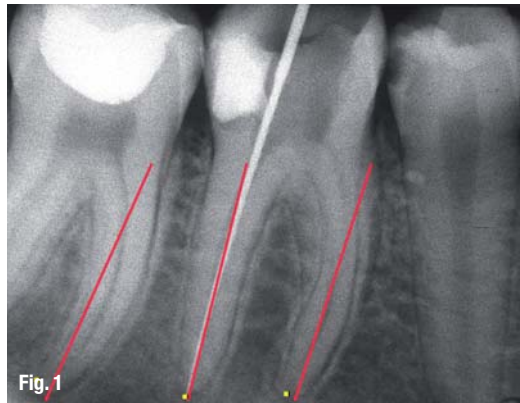


Determining working length, or how to locate the apical terminus (Part I)

Authors_Prof Vladimir Ivanovic & Dr Katarina Beljic-Ivanovic, Serbia

Fig. 1_The apical foramen almost never coincides with the principal axis of the root.

Fig. 2_The anatomical foramen is not always located at the anatomical apex.

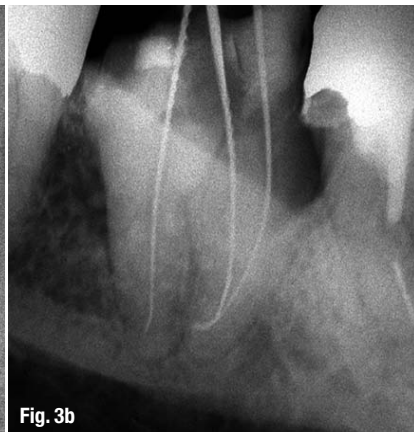
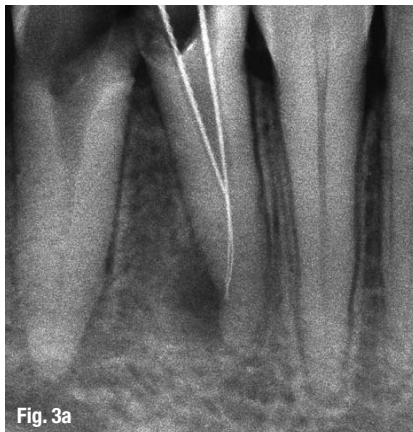

Introduction

Determining working length (WL) is one of the crucial aspects in successful endodontic treatment. However, major controversy exists regarding where to locate the apical end point of the root canal preparation and obturation. The ongoing debate centres on different concepts of shaping and cleaning the apical portion of the root canal, and whether to complete manipulation within the dentinal walls to the physiologic foramen or to extend into the cemental cone close to the anatomical foramen.

Figs. 3a & b_The anatomical foramen is not located at the radiographic apex, and canal instruments exit through the foramen in various angulations.

Several colleagues contributed their research results to this article. They are Prof Mirjana Vujaskovic, Dr Katarina Beljic-Ivanovic, Dr Jugoslav Ilic and Dr



Ivana Bosnjak from the Faculty of Dental Medicine at the University of Belgrade; Prof Joshua Moshonov from the Hebrew University of Jerusalem, who incorporated parts of his own research and provided laboratory testing; Dr Julian Webber, who supplied materials and gave useful advice; and Prof Paul Dummer from Cardiff University, who contributed valuable suggestions and instructions for our *in vivo* study.

This article is based on my recent lecture at the European Society of Endodontology (ESE) congress in Edinburgh for which I consulted numerous papers and books. I wish to point out a few that have directly influenced my own standpoints and work over the years and finally directed much of this article through their philosophy and conception:

- _Ricucci D, Langeland K: Apical Limit of Root Canal Instrumentation and Obturation, Part 1: Literature Review. *International Endodontic Journal* 1998; 31(6):384-393.
- _Ricucci D, Langeland K: Apical Limit of Root Canal Instrumentation and Obturation, Part 2: A histological study. *International Endodontic Journal* 1998; 31(6):384-409.
- _Wu M, Wesselink P, Walton R: Apical Terminus Location of Root Canal Treatment Procedures. *Oral Surgery, Oral Medicine, Oral Pathology, Oral Radiology and Endodontics* 2000; 89(1):99-103.
- _Fava LRG, Siqueira JF: Considerations in Working Length Determination. *Endodontic Practice* 2000; 3(5):22-33.

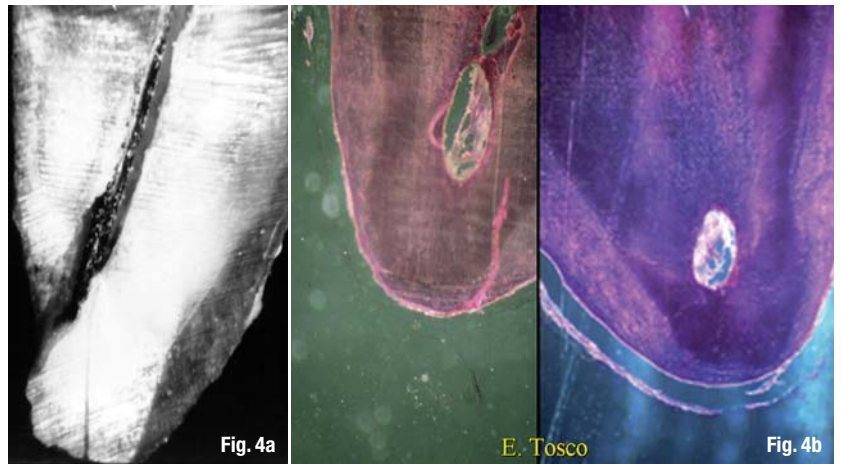
Nekoofar MH, Ghandi MM, Hayes SJ, Dummer PM: The Fundamental Operating Principles of Electronic Root Canal Length Measurement Devices. *International Endodontic Journal* 2006; 39(8):595–609.
 Mounce R: Determination of True Working Length. *Endodontic Practice* 2007; 10(1):18–22.

Decision-making factors

Each time we need to determine WL we are faced with various challenges and factors influencing our decision of *where, when, why* and *how* to locate the apical terminus. For one, there are factors dictated by nature that lie beyond our influence: the anatomy of the root canal system, the morphology of the apical region and its variations, and the pathological state of the pulp and periodontal tissues. Additionally, there are factors that we can and should control, namely our knowledge, skills and equipment. Our daily practice brings us experience and moulds our preferences, however, after years of practising, certain prejudices can develop that in some cases can lead to errors.

Looking at root canal anatomy, the first fact is that root canals always deviate from the long axis of their roots and the apical foramen almost never coincides with the principal axis of the root (Fig. 1). Anatomical details and variations of the apical region are central to determining WL. The anatomical foramen is seldom (in less than 50 % of cases) located at the anatomical apex. In other words, the anatomical foramen is not always located at the anatomical apex (Fig. 2), which has been proven in numerous studies that have presented figures of 50, 80, 92 and up to 98 % of cases with the anatomical foramen 0.2 to 3.8 mm short of the anatomical apex.

Therefore, it is a fact that the anatomical foramen is neither at the anatomical nor at the radiographic apex. Consequently, the instrument placed into the root canal exits through the apical foramen at various angulations from 10° up to 90° (Figs. 3a & b). In other words, root canals deviate and exit mesially and



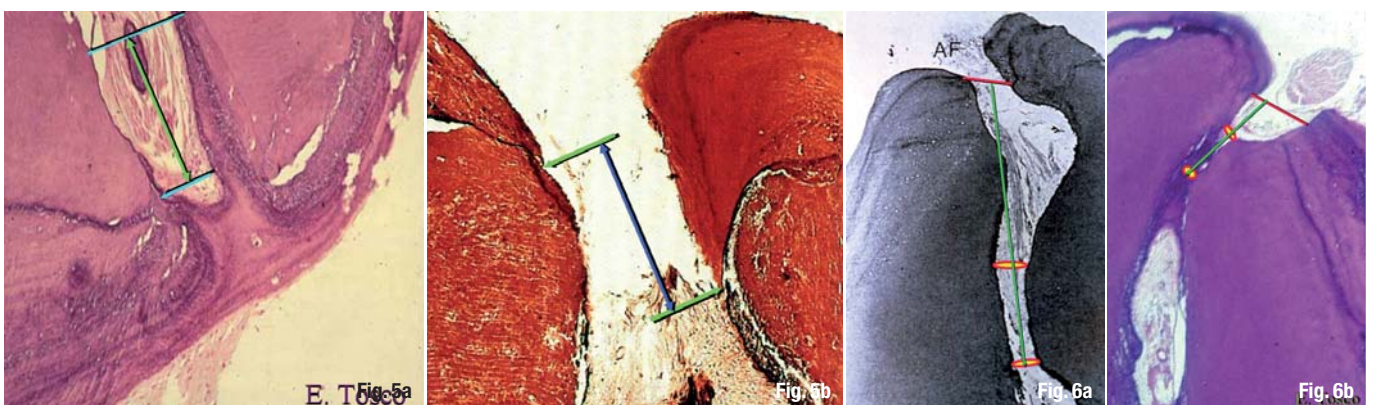
distally, something that can easily be revealed on a clinical radiograph. Unfortunately, canals also deviate buccally and lingually. According to the literature, this is the case in 20 to 55 % of teeth, depending on their morphological type (Figs. 4a & b). Additionally, a majority of root apices have multiple foramina, causing apical delta and difficulty in locating the endodontic terminus.

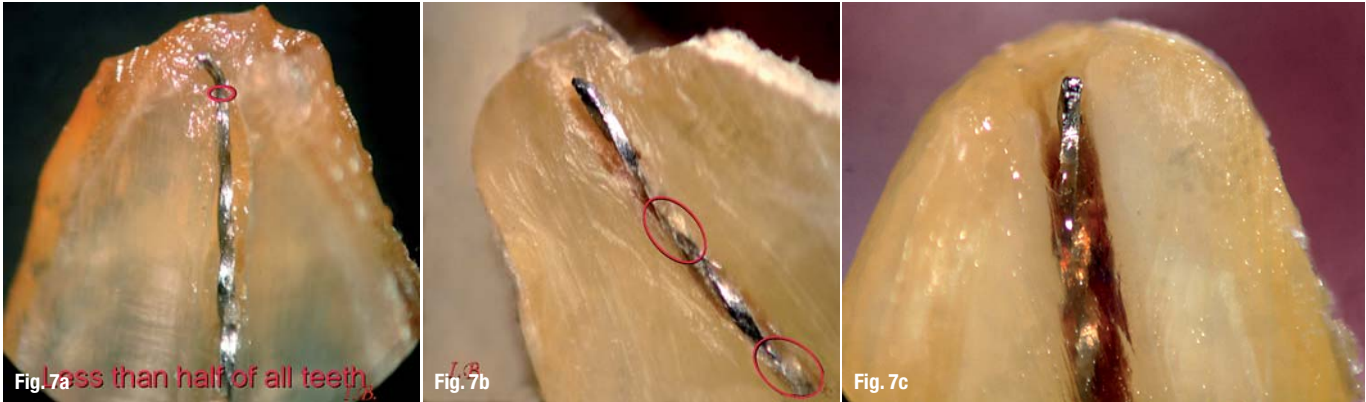
Figs. 4a & b Root canals deviate buccally and lingually in 20–55 % of all cases.

The histology of the apical cementum and cemento-dentinal junction (CDJ) and their variations is morphologically intriguing. In only 5 % of teeth, cementum extends at the same level of two opposite walls of the same canal. The extent of those layers of cementum on different walls could vary from 0.5 to 3.0 mm into the root canal, and variations of the CDJ in each individual tooth range from 200 to 800 μm (Figs. 5a & b). The CDJ is seldom well defined and sometimes it is very difficult to differentiate dentine from cementum. Therefore, most of the eminent authors consider the CDJ an inconsistent feature, even histologically.

Throughout the entire life and function of a tooth, the apex is constantly remodelled by cementum deposition and resorption. This remodelling process leads to illusory dislocation of the apical foramen but actually increases the length of a root. Thus, even the CDJ is

Figs. 5a & b The depth of the layers of cementum on different walls of the root canal varies from 0.5 to 3 mm.
Figs. 6a & b The apical constriction is always located coronally to the CDJ.





Figs. 7a-c Less than half of teeth have single constriction (a) and the remainder have either multiple (b) or no constriction at all (c).

considered and recommended to be the ideal physiological apical limit of the WL. However, since it is impossible to determine it clinically, many refer to this as a myth.

The next anatomical challenge for the practitioner is the apical constriction. It has been proven that the CDJ and the apical constriction are two separate points and almost never coincide. The apical constriction is always located coronally to the CDJ (Figs. 6a & b). While the apical foramen is easily visualised in root canals microscopically, no well-defined apical constriction has been clearly confirmed. Less than 50 % of teeth display the points that could be regarded as the apical constriction.

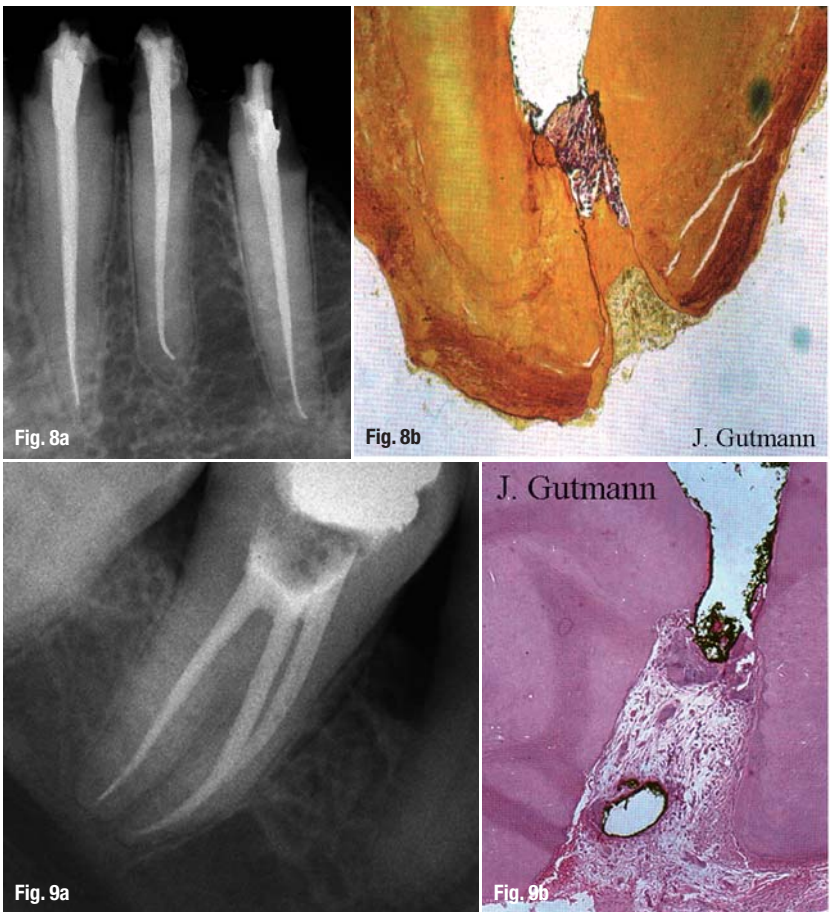
Several authors have pointed out and classified variations in the topography and position of the apical constriction. Unfortunately, this knowledge cannot be consistently applied as less than half of the teeth have single constriction; the remainder have either multiple or no constriction at all (Figs. 7a-c). The distance from the apical constriction to the apical foramen ranges from 0.07 to 1.76 mm. Consequently, the distance from the apical constriction to the radiographic apex ranges from 0.75 to 4 mm.

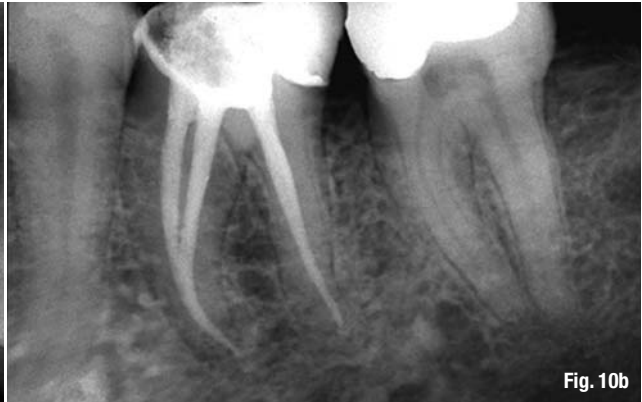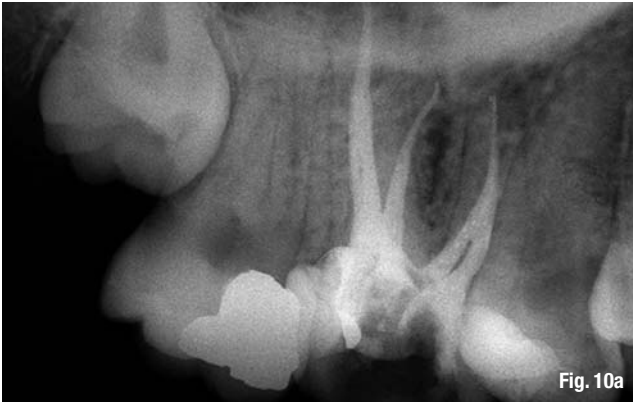Figs. 8a & b The less tissue to heal, the better the cure: X-ray control after 12 months (a); healing with cemental bridge (b).

Figs. 9a & b The apical terminus at the physiological foramen: X-ray after 12 months (a); optimal healing (b).¹⁶

The following statements properly summarise this section on anatomy. Determining the apical foramen as the reference point gives more consistency than the apical constriction or radiographic apex.⁷ The use of the major foramen is more reproducible for accuracy studies.⁸ We can therefore conclude that owing to numerous inconsistencies, variations and 'ifs' with regard to the apical constriction and CDJ and their interrelationship, the apical foramen may be a more useful and reliable apical reference point in determining WL.

The pathological and microbiological status of the dental pulp and peri-apical tissues is an extremely important decision-making factor for where, when, why and how to locate the apical terminus. In cases of vital and healthy or irreversibly inflamed pulp, free of bacteria or bacteria limited to the pulp chamber, there are two standpoints. One firmly suggests that pulpectomy is the treatment of choice in cases in which the apical terminus is located at the physiological foramen (Figs. 8a & b). We utilise this method, which is widely accepted amongst a majority of dental schools and practitioners in Europe, in almost each case, in following the basic biological and medical principle for any wound: the less tissue to heal, the better the cure.¹ For the same pulp conditions, the second standpoint advocates partial pulpectomy in cases in which the apical terminus is located short of the constriction at a variable distance that can range from 1.5 to 10.0 mm short of the apex, leaving a pulp stump. Dressed and sealed appropriately with bio-compatible material, its vitality is preserved, enabling the pulp to continue with what it does the best: forming mineralised dentine tissue.



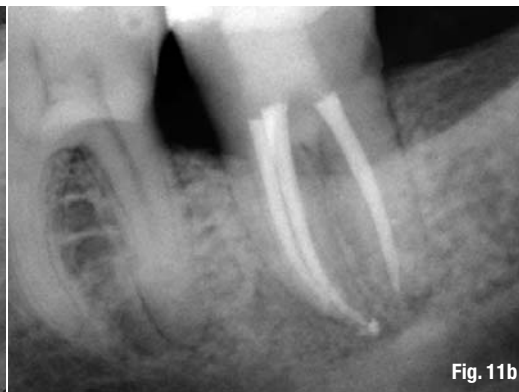
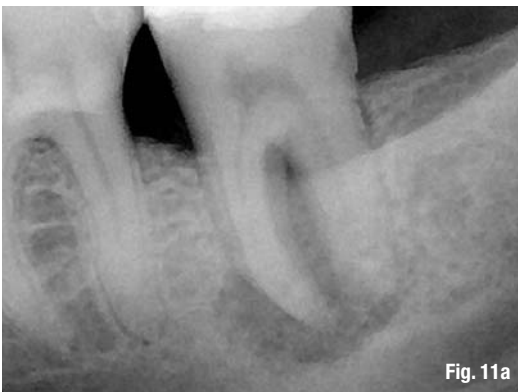
Cases with necrotic and/or infected pulp are much more complicated, even when there is no peri-apical lesion. Some colleagues advocate that the apical terminus be located at the physiological foramen. This location preserves integrity of the apical morphology, and neither violates the apical foramen nor challenges the periodontal ligament, thus enabling optimal healing (Figs. 9a & b). Other colleagues suggest that the apical terminus be located at the anatomical foramen, sometimes identified as the apex, or even at the radiographic apex.⁹ This approach adopts the concept of apical patency or the apical clearing technique (Figs. 10a & b).

In cases with apical periodontitis there is even more controversy about the location of the apical terminus. A conservative approach insists that all manipulations end at the physiological foramen, since any over-instrumentation or overfilling of this end point leads to either clinical or histological failure. Another approach, supported by a group of prominent academics and experienced practitioners, advocates that preparation and obturation in such cases always be terminated at the anatomical or radiological foramen, the radiographic apex of the tooth. Figures 11a and b demonstrate the extent of success in treatment when the end points of all intra-canal manipulations are located at the anatomical foramen, irrespective of the

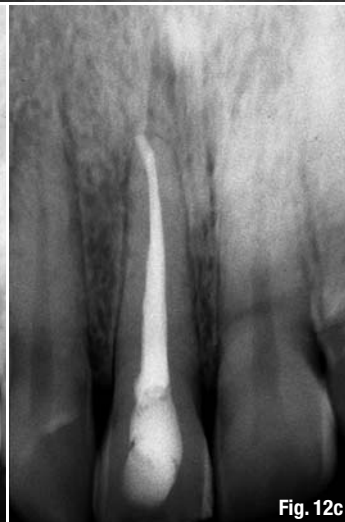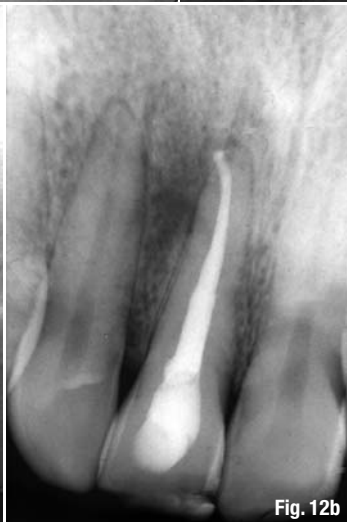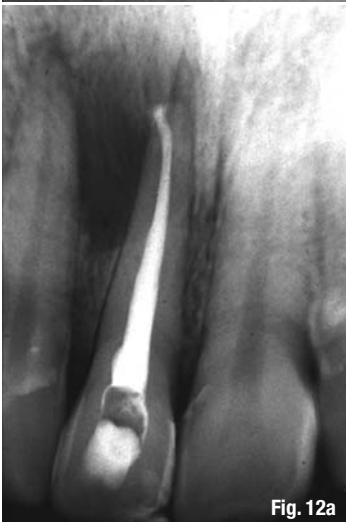Fig. 10a_The apical terminus at the anatomical-radiographic apex with excellent outcome: X-ray control after 2 years.

Fig. 10b_The canals were successfully obturated to the anatomical apex.

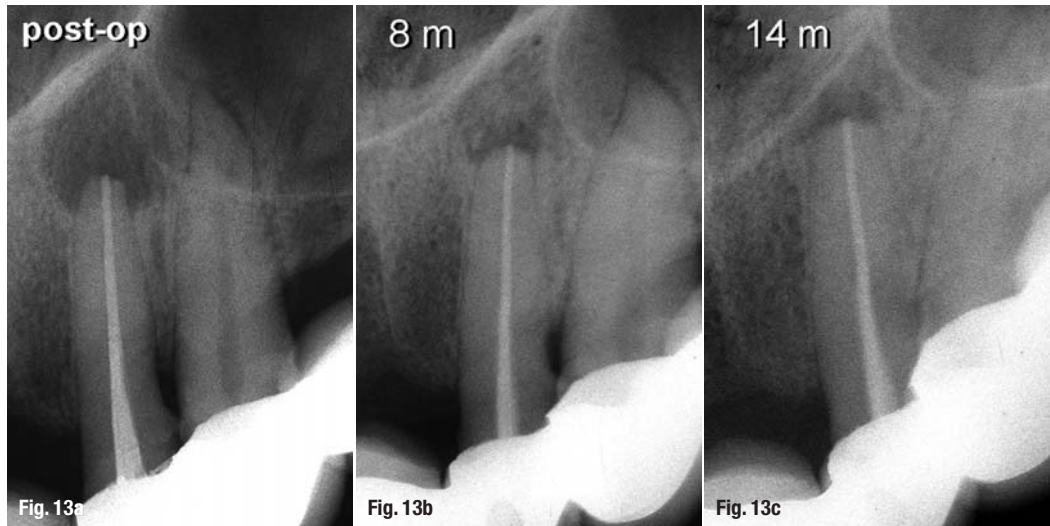


Figs. 11a & b_In cases of apical periodontitis, the endodontic terminus should preferably be at the end of the root canal, near to the anatomical foramen: Post-op image (a; courtesy Dr Julian Webber); control after 2 years (b).

Figs. 12a-c_Case with the end-point at the anatomical foramen/radiographic apex: Post-op image (a); after 6 months (b); after 2 years (c).



Figs. 13 a–c_Pathological inflammatory root resorption: Post-op image (a); after 8 months (b); after 14 months (c).



type of apical periodontitis. If possible, the goal of orthograde treatment is to avoid peri-radicular surgery (Figs. 12a–c).

In cases of peri-apical pathosis associated with pathological inflammatory apical root resorption it is particularly difficult to decide where to locate and how to determine the endodontic terminus. Controversial opinions from the literature suggest that it should be either 0.5 mm short or 1.0 mm long of the apex. As there is no accurate technique for such cases, the situation becomes even more frustrating for the practitioner (Figs. 13a–c).

In summary, the root canal should be prepared and obturated to a point as close to the apical foramen as possible yet still within sound tooth structure.¹⁰ The objective of determining the WL is to enable the root canal to be prepared as close to the apical constriction as possible.¹¹

Methods for determining working length

The following methods can be used to determine WL:

1. predetermined 'normal' tooth length (this method is not detailed here, owing to its inaccuracy);

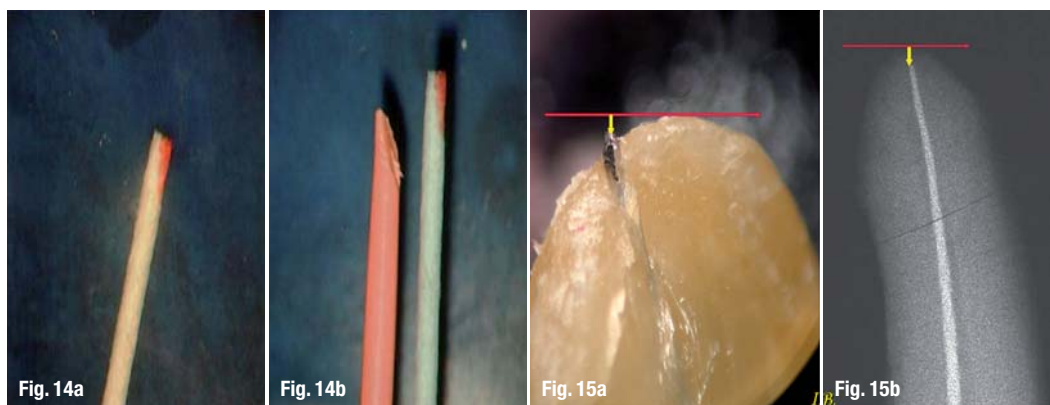
2. patient pain response;
3. tactile sensation of a therapist;
4. paper point technique;
5. radiographic method; and
6. electronic locators.

A patient's response to pain is probably the oldest method used. However, owing to several interfering factors, it is very unreliable. For one, remnants of vital pulp tissue within the apical portion can cause pain, leading to shorter WL. Pressure of the instrument tip transmitted via tissue debris to the viable periodontal ligament can also lead to shorter WL. Also, destruction of peri-apical tissues causes no sensation at all if an instrument is protruded beyond the foramen even for several millimetres, resulting in longer WL. This technique is also extremely subjective owing to the individual pain threshold of each patient. Moreover, it is impossible to apply this method when local anaesthesia is performed. There is a lack of evidence in the literature regarding whether this method is still in use; is this method dental history?

Tactile sensation is a very subjective technique too. Its limitations are due to morphological irregularities, tooth type and age (generally leading to shorter length values), and pathological apical resorption or wide

Fig. 14a&b_Customising master gutta-percha cone.

Figs. 15a & b_The radiograph shows that the instrument is short of the radiographic apex (a), but in reality the instrument tip is far beyond the anatomical foramen (b).



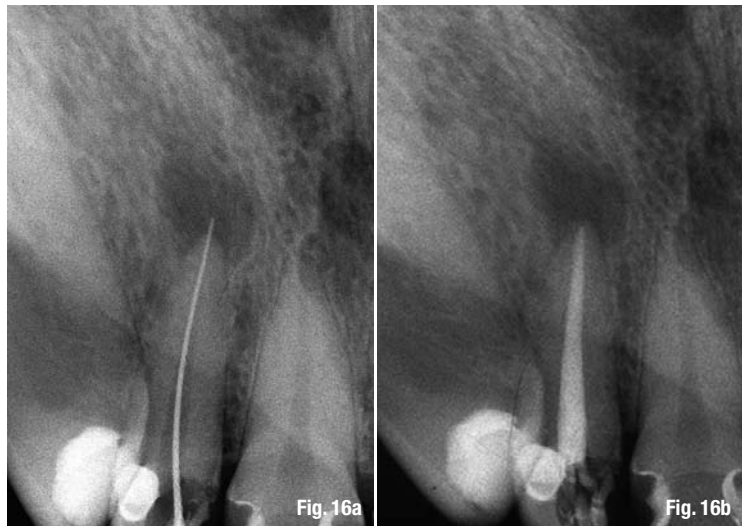foramen in immature teeth, which leads to longer WL. The literature offers little information on this method; nevertheless, the tactile sensation technique is still advocated as very useful in the determination of apical constriction.

In 1986, Dr Mirjana Vujaskovic and her mentor Prof Miroslav Pajic conducted extensive clinical research on the accuracy of the tactile sensation method controlled radiographically in relation to two reference points: 0.5 mm from the radiographic apex in patients younger than 25 and 1.0 mm in patients older than 25. The method was accurate in only 19 % of the cases, but accuracy increased to 42 % when tolerance was extended to ± 0.5 mm. Furthermore, the researchers found significant under- and overestimations—up to 4.5 mm before and after reference points. The literature presents accuracy in a variable range of 30 to 44 % and 30 to 60 %, with wide and random distribution of measured values. An important finding for our daily practice was that pre-flaring helps in locating the apical constriction, increasing accuracy from 32 to 75 %.

The paper point technique (PPT) is claimed to be the most accurate method by which to determine both WL to the very end of the canal and minimal apical foramen diameter in three dimensions. It allows the practitioner to see the cavo-surface of the apical foramen with precision in 1/4 mm. Logically, the apical patency technique is mandatory for this method. Additionally, this technique enables customisation of master gutta-percha cone three-dimensionally based on the information gained from the paper point (Fig. 14).

Even though it is claimed to be the most accurate method in determining WL, neither scientific nor clinical evidence is available in the literature. In spite of being advocated by many endodontic experts, PPT lacks the ability to determine morphological details and pathological states within the root canal and in the peri-apical tissues. However, it is a fairly simple method and can be helpful in establishing and confirming final WL since it is non-aggressive and therefore does not injure periodontal tissues or endanger apical wound healing.

The radiographic method (RM) is probably still the most widely used method for determining WL. It reveals many important details and is useful in every endodontic procedure. However, it also has limitations and often provides an illusory image. There are three matters to be noted when determining WL with RM. First, it is mandatory to produce preoperative, diagnostically accurate radiographs. Second, the radiographic apex and the anatomical apex do not (always) coincide, but in most textbooks and articles these terms are used interchangeably. Third, the apical foramen cannot (always) be visualised on a radiograph, which is a significant handicap.



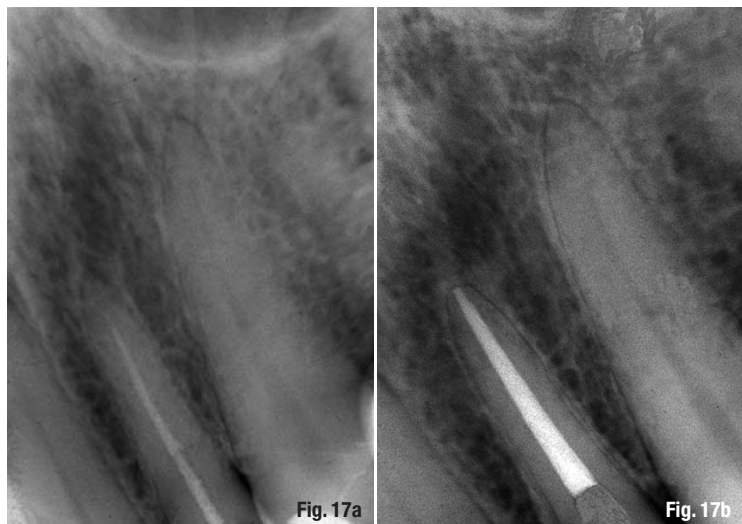
In 1986, Dr Vujaskovic, Prof Pajic and I conducted a long-term clinical study on the accuracy of RM in determining WL. The same methodology was applied as described for the tactile sensation method. The RM was accurate in 51 % of cases, strictly respecting reference points on a radiograph (0.5 mm from the radiographic apex in patients younger than 25 and 1.0 mm in patients older than 25).

When the range of tolerance was extended to a clinically acceptable ± 0.5 mm from the reference points, accuracy increased to 68 %. It further increased to 88 % when tolerance was extended to ± 1.0 mm. Under- and overestimations were not over 2 mm, compared to 4.5 mm with the tactile sensation method. Similar findings were confirmed in other studies.

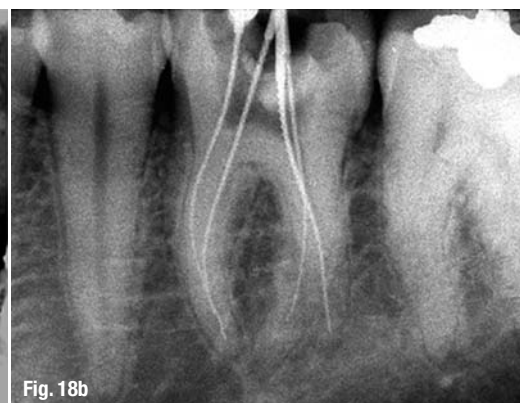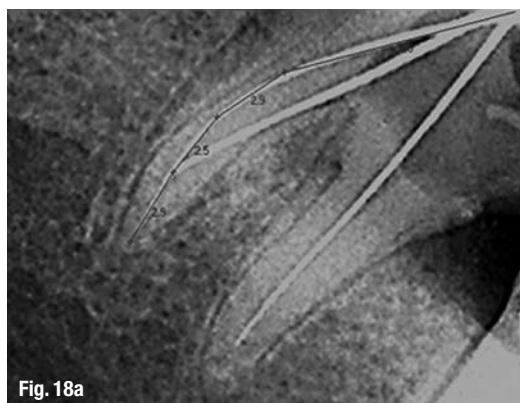
Figures 15a and b show that the measuring file is longer than it appears radiographically. When the instrument is short of the radiographic apex, it is beyond the apical foramen in 43 % of all cases. If the apical constriction is 0.5 mm before the apex, then 66 % of all

Figs. 16a & b Clinical situation with instrument beyond the apex (a), which was later corrected by obturating the canal approximately 0.8 mm short of the radiographic apex (b).

Figs. 17a & b Correction of a treatment mistake in determining WL (a) and the more or less successful end result (b).



Figs. 18a & b_RVG image of the lower molar (a) and conventional radiograph (b).



measurements are beyond this.¹² When the file is short of the radiographic apex, it is actually closer to the apical foramen than it appears radiographically.¹³ Radiographic WL ending 0 to 2 mm short of the radiographic apex provides a basis for unintentional over-instrumentation, more often than expected.¹⁴ Figures 16a to 17b demonstrate the way mistakes in determining WL can be corrected to finalise the case successfully.

The RM depends on a few different factors, namely the surrounding structures, the angulations of the cone-beam, the visibility of the measuring file influenced by its size, and the film exposing and developing speed. In summary, radiographs are indispensable for calculating but not for determining WL and the endodontic terminus.¹⁵

The most prominent advantage of digital radiography (DR) is the ability to quantify distances with exact figures. Thanks to software programmes, images can


be varied in size and contrast. But there are limitations if small size canal instruments with fine file tips, for example #8 or 10, are used. They display low contrast in their structures and affect visualisation and precision of the measuring process and hence the results. Therefore, sizes #15 and bigger are preferable.

Even though there are many advantages and benefits in the use of DR, many reports emphasise that complete image quality is better with conventional radiographs (Figs. 18a & b). When conventional and DR radiographs were used for WL determination and compared to electronic locators, it was demonstrated that electronic foramen locators are superior because the RM generally gives long measurements with over-instrumentation.

Editorial note: Part II of this article will be published in roots 1/2010. A complete list of references is available from the publisher.

_about the author

roots




Prof Vladimir Ivanovic graduated from the Faculty of Dentistry at the University of Belgrade in 1976. He obtained a M.Dent.Sc and Ph.D. with specialisation in Oral and Dental Pathology and Endodontology. He was appointed Professor in Restorative Odontology and Endodontics in 1998 at the Faculty of Dental Medicine and served as a Vice-Dean for postgraduate and undergraduate studies. He has also chaired the School Board for Dental Pathology.

Prof Ivanovic conducts research at the University of Belgrade and Edinburgh Dental Institute. His main interests are maintaining vital pulp, resin-based composites and adhesive systems, and endodontology. He has attended numerous international endodontic seminars and courses to further his knowledge and skills. He has delivered over 100 lectures both nationally and internationally, published over sixty articles in national and international journals, and chapters in four dental textbooks.

He is founder and President of the Serbian Endodontic Society and has been a member of the ESE since 1989. He is also country representative for the ESE General Assembly, member of the International Association for Dental Research/Continental European Division and school representative for the Association for Dental Education in Europe. He has organised over a dozen endodontic meetings in Belgrade with internationally recognised speakers. Prof Ivanovic can be contacted at vladaivanovic@hotmail.com.

FDI Annual World Dental Congress 2-5 September 2010 Salvador da Bahia, Brazil



congress@fdiworldental.org
www.fdiworldental.org

