

# roots

international magazine of endodontology

4<sup>2009</sup>

| **clinical report**

The X-Files: four case reports

| **research**

Determining working length

| **industry report**

The DownPak Device

# Hygiene Made Simple.

VDW'S STERILE  
ENDODONTIC INSTRUMENTS  
ARE IN STRICT CONFORMITY WITH  
DIN EN ISO 11137 - STERILISATION  
OF HEALTH CARE PRODUCTS



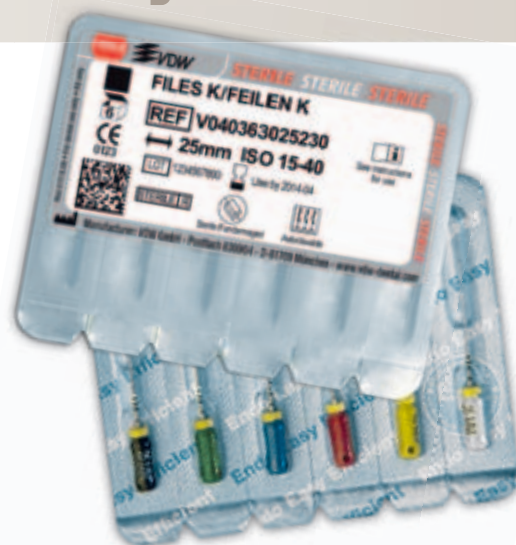## Sterile Endo Instruments by VDW.

### Enhanced safety for you and your patients

- No sterilisation prior to first use
- Ready to use instruments, individually packed
- Sterile product range: stainless steel instruments, NiTi files (Mtwo®, FlexMaster®), paper points
- TÜV-certified quality management

Please contact us for more information:

**VDW GmbH**  
P.O. Box 830954 • 81709 München • Germany  
Tel. +49 89 62734-0 • Fax +49 89 62734-304  
[www.vdw-dental.com](http://www.vdw-dental.com) • [info@vdw-dental.com](mailto:info@vdw-dental.com)



**Look for the red dot.**

VDW. Over 30 years' experience in sterile products.



**Endo Easy Efficient®**

# Dear Reader,

I am very pleased to be able to address colleagues from nearly all fields of dentistry in the editorial for this issue of **roots**, which will be distributed at the 2009 Greater New York Dental Meeting.

Endodontic therapy is often the last opportunity to preserve a natural tooth. If a tooth has a sufficient restorative and periodontal prognosis and the necessary endodontic treatment is done properly, the longevity of patients' teeth can be extended to decades. There is ongoing debate comparing endodontics and implants as therapy alternatives. Yet, there seems to be a tendency towards the replacement of natural teeth with implants, sometimes even in cases in which the tooth could have been preserved.

Research figures show that there is a significant difference between the high success rates of endodontic treatment in controlled studies and the incidence of apical periodontitis after endodontic treatment, as demonstrated in cross-sectional studies. This may be an indication of the difference of what is possible with treatment following a controlled protocol and what is achieved in reality, thereby explaining the endodontic treatment results we often see in our patients.

Controlled studies in implantology have mostly presented data indicating implant survival and not implant success, as demanded by Dale, Albrektsson and others. Even early implant loss, within the first weeks of placement, is often not included in many statistical calculations. In the last two years, reports have indicated instances of peri-implantitis at a rate of 10 per cent and in some implant types of up to 29 per cent. Some studies have shown higher incidences of peri-implantitis in patients that have lost teeth because of periodontitis before and therefore suggest a possible predisposition. Additionally, we are only beginning to understand the treatment of peri-implantitis.

In my opinion, implants are a very valuable instrument if the natural tooth has already been lost or has an insufficient prognosis. But if a tooth has a sufficient restorative, periodontal and endodontic prognosis, it should be preserved in most cases. Thus, I consider that the situation is not one of endodontics versus implants but one of two disciplines working alongside in the goal of best serving our patients.

So, I hope that you will enjoy this issue of **roots**, which demonstrates the possibilities of endodontic treatment through cases treated by excellent clinicians.

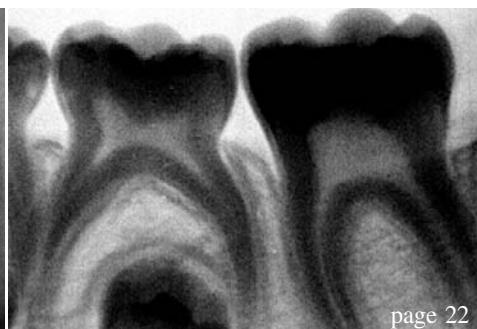
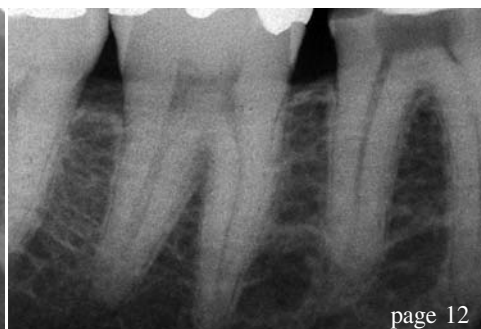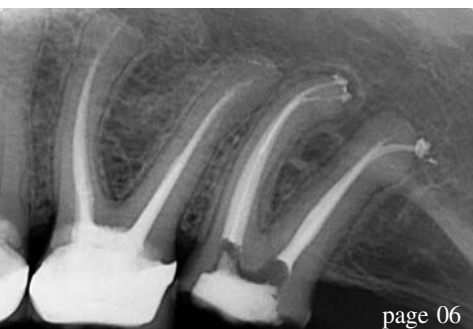Sincerely yours,



Dr Carsten Appel  
Guest Editor  
President of the German Society of Endodontology  
Niederkassel, Germany



Dr Carsten Appel  
Guest Editor



## | editorial

- 03 **Dear Reader**  
| Dr Carsten Appel, Guest Editor

## | clinical report

- 06 **The X-Files: four case reports**  
| Dr L. Stephen Buchanan
- 12 **Endodontically speaking, the proof is in the pudding**  
| Dr Barry Musikant
- 18 **Apical microsurgery—Part III**  
| Dr John J. Stropko
- 22 **The future of endodontics: pulp revascularisation**  
| Dr Philippe Sleiman

## | trends

- 24 **Practical clinical considerations in endodontic re-treatment**  
| Dr Richard E. Mounce & Dr Gary D. Glassman

## | research

- 30 **Determining working length, or how to locate the apical terminus**  
| Prof Vladimir Ivanovic & Dr Katarina Beljic-Ivanovic

## | industry report

- 38 **The DownPak Device: obturation with heat and vibration**  
| Dr Stephen Cohen et al.

## | lifestyle

- 42 **Enjoy your trip and indulge in the journey!**  
| Annemarie Fischer


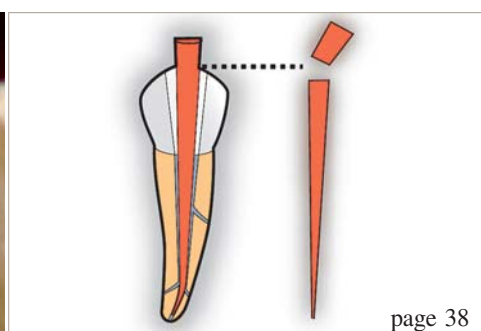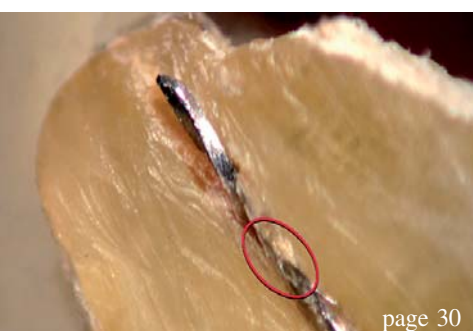
## | meetings

- 46 **ESE holds another record meeting in Scotland**  
| Daniel Zimmermann
- 48 **Endo events**

## | about the publisher

- 49 | submissions
- 50 | imprint

Cover image courtesy of alphaspirt.






# TOOLS TO KEEP SMILING

No less than ...  
...4 launches !

## D-RaCe

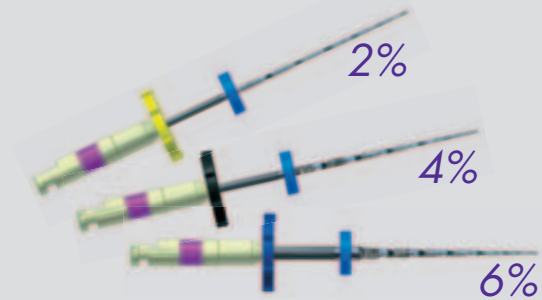*Desobturation made easy*



[www.d-race.ch](http://www.d-race.ch)

## FKG RaCe ISO 10

*Mechanical Glide Path*



## Spreader 4%

*NiTi & Electro-chemical polishing*



## SMG handle

*Indicator of uses*



*For K/H files and reamers*

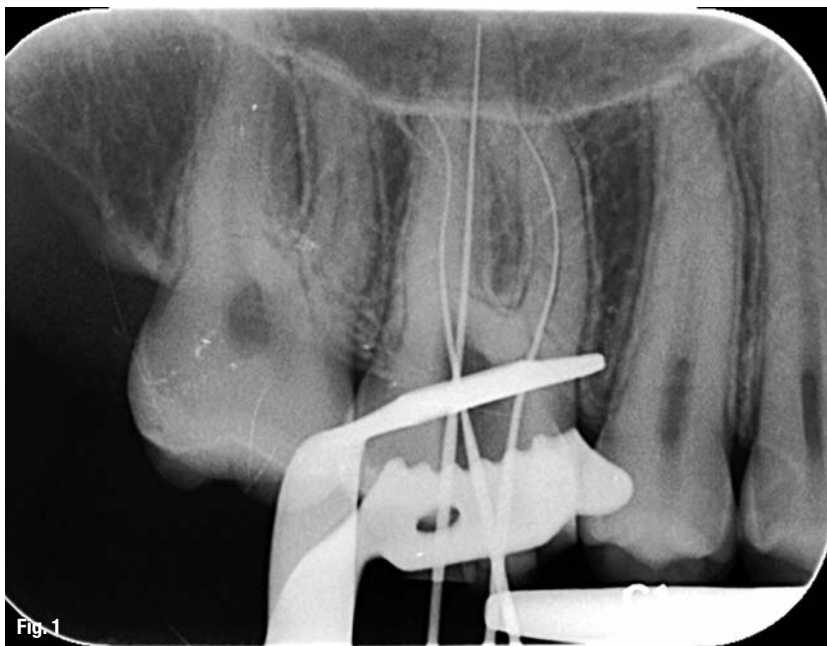
[www.fkg.ch](http://www.fkg.ch)

**FKG**  
FKG DENTAIRE  
Swiss Dental Products



# The X-Files: four case reports

Author\_Dr L. Stephen Buchanan, USA



**Fig. 1** Maxillary molar with files in each root to lengths determined by Root ZX (J. Morita); note the curvatures in the MB and DB canals, as well as the lengths in the palatal and DB canals that are short of the radiographic root apices but at the termini of those canals.

In his book *Innovation and Entrepreneurship*, business guru Peter Drucker stated that a new technology is not widely taken up by users unless it provides a 10x improvement over their current methods of work. This is certainly true in dentistry. Incorporating a new concept, technique, or instrument into a fully scheduled day is a huge stressor. It also entails significant training costs for the dentist and staff, as well as high costs for the new inventory needed. Because of this, the most financially successful dentists watch carefully for the point in time at which the benefits of the new technology outstrip the costs of taking it on. Only early adopters, who are driven by wanting to be on the cutting edge of technology, will jump in sooner.

When the 10x factor of improved results becomes a reality, clinicians who recognise these advantages can accomplish the treatment in less time, with fewer steps and greater confidence in

the outcome. The new GTX Rotary File with M-Wire metallurgy satisfies these requirements. This new file has the attributes of much greater resistance to cyclic fatigue failure—the major cause of instrument separation. In addition, fewer files and procedural steps are needed to create ideal shapes in root canals. As an improvement to the GT File series, the GTX Files have landed cutting blades for prevention of transportation, although the radial lands have been optimised. This has been accomplished by varying the land widths along the file length to increase cutting efficiency without losing their resistance to straightening curved canal paths. Furthermore, the blade angles have been opened up (fewer twists), which not only increases cutting speeds, but also increases their flexibilities and the size of their chip spaces between the flutes.

All of these changes in efficiency were accomplished without forsaking one of the unique features of the GT File series: the 1 mm maximum flute diameter (MFD) limitation, which prevents over-enlargement of the coronal region of the root canal. This is a key factor in reducing the loss of structural integrity of the tooth after endodontic treatment. So, with the pre-existing safety features of landed cutting blades and limited MFDs, and the newly enhanced safety of R-Phase NiTi metallurgy, the only thing that could be better would be to reduce the number of files and procedural steps needed to accomplish shaping procedures in canals.

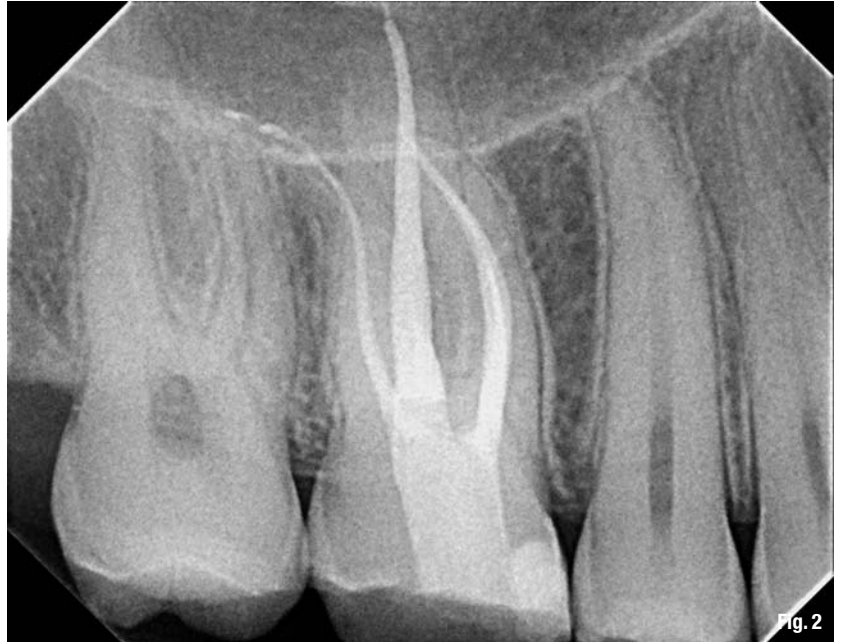
This article is intended to describe how these files are able to cut the shapes that are needed in most root canals, using one or two instruments with four to five procedural steps. I will detail the shaping procedures used in molars with moderate-to-severe canal curvatures by me and two of my esteemed endodontic colleagues.

## Case 1: Maxillary molar treatment

This case was treated as a live demonstration at the California Dental Association meeting in Anaheim in USA on 3 May 2008. Figure 1 is a radiograph showing the final negotiating files in each canal. I do not consider this a means of length determination because they are not as accurate as my J. Morita apex locator for this purpose. This image was taken to demonstrate for my audience the curvatures of the different canals in this tooth. The mesio-buccal (MB) and disto-buccal (DB) canals have obvious, significant curvatures. The palatal canal appears to be straight in this X-ray angle but could be curved in the buccal or lingual planes, a possibility that will be discovered during the shaping of the canal. This image shows the negotiating prerequisite to shaping with GTX Files: a #15 K-file (or larger) to the terminus of all canals.

The shaping objective for GTX File use has been changed (streamlined) from that suggested for GT File shaping. Notably, the small-canal shaping objective is now limited to a .06 shape and the shaping objective for medium-large canals is typically limited to a .08 shape. This is with the understanding that some medium and large canals may occasionally need a .10 or even a .12 shape, if their apical canal form is large. So, the MB and DB canals will be shaped to a .06 taper and the palatal canal to a .08 taper, with the final apical diameters to be determined by apical gauging procedures followed after the initial shape has been cut.

This tooth had two MB canals that were apically confluent. GTX File shaping is achieved in the presence of 6 % NaOCl, and the shaping routine in small canals is always begun with the 20/.06 GTX File used at 300 rpm with a torque limit of around 250 gm/cm. The 20/.06 GTX File is spun up and introduced into the canal with a light but steady apical movement. This is where the biggest difference between GT File and GTX File function becomes apparent. The GT Files (with their smaller chip space) typically cut for about four to six seconds before stalling in their apical progress, owing to the cut debris filling the chip spaces; whereas the GTX Files (having twice the chip space) will cut for ten to twelve seconds before stalling. I usually let the file continue its apical progress without any interruption. However, many of my colleagues cut with the file for three to four seconds, withdraw by 0.5 mm, and then continue further apical progress until the file stalls.



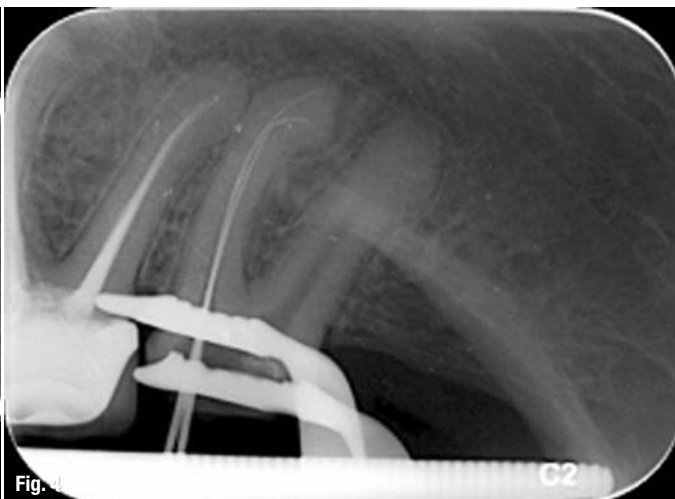
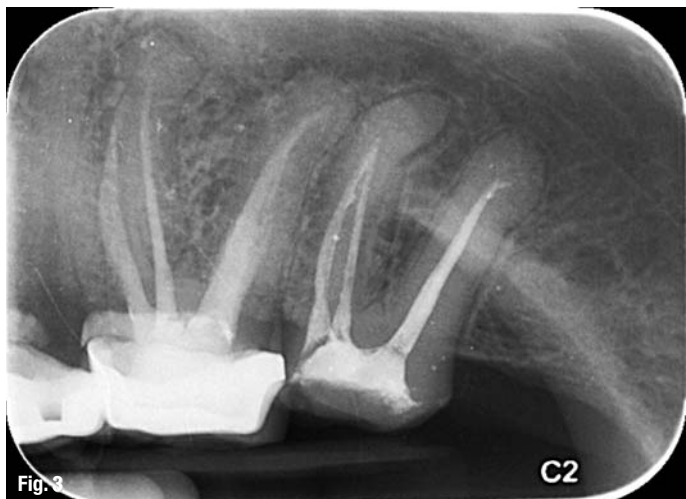**Fig. 2** Post-op radiograph showing conservative coronal shapes, apically accurate fills, and an ideally cut access cavity with the mesial and distal access walls parallel to the mesial surface of the tooth.

The main issue is that landed blade files do not cut effectively when used with an in-and-out pecking motion; they require the blades to be set against the canal walls for cutting to occur. While this is sometimes perceived as a less effective cutting event than the bite of non-landed blades, the time to completion of shape belies that perception. Obviously, when the GTX File finally stalls, it is retrieved, the blades are cleaned with alcohol gauze, and then the file is re-introduced for further cutting. When the same GTX File starts to stall again, it is time to drop down in size to a 20/.04 GTX File so that initial shaping in small canals can continue safely. In this case, the 20/.06 GTX File cut all the way to length in the MB1 and MB2 canals in two or three cutting cycles, but in the DB canal a 20/.04 GTX File was needed to achieve length. This is typical in maxillary molars.

One of the new technique strategies taught for GTX File use is visual gauging at the end of initial shaping, looking at the first 20 Series GTX File that cuts to length to determine whether there is dentine debris in the tip flutes. When the first GTX File to length has debris packing the last flute space, there is a good chance that the terminus is no larger than the tip diameter of that file. When that file is devoid of chips at its tip, it is most likely that the terminal diameter of the canal is larger.

This is a time saver, as it eliminates the need to introduce NiTi K-files (tactile gauging) to determine whether a larger apical size will be needed to create apical continuity of taper—confirmation that the taper in the preparation extends all the way to the apical terminus.





**Fig. 3\_** Mandibular molar with failing endodontic therapy due to apically inadequate treatment in all canals.

**Fig. 4\_** Negotiation files in mesial canals after removal of filling material and advancement through apical blockage; note the severe curvatures.

**Fig. 5\_** Post-op radiograph showing apical confluence of mesial canal shapes and the second apical portal of exit branching off the point of confluence; note the apical ledge at the curvature in the distal canal, bypassed with bent stainless-steel K-files and finished with a pre-bent GTX Rotary File.

Apical continuity of the taper is what gives us the greatest chance of having apical accuracy when we fill the canal, so this is a critical element of the GT and GTX File technique. Visual gauging allows a quick decision to be made on the likely final shape, and in this clinical case the 20/.06 GTX File had no tip debris after reaching the terminus of the MB1 and MB2 canals, indicating that a 30/.06 GTX File should then be used. In the DB canal, the first file to length (the 20/.04 size) showed tip flutes packed with debris, indicating that a 20 Series GTX File would probably suffice to complete the shape in that canal. And in fact, when the 20/.06 file was cut to length and tactile gauging was achieved, this proved to be the case.

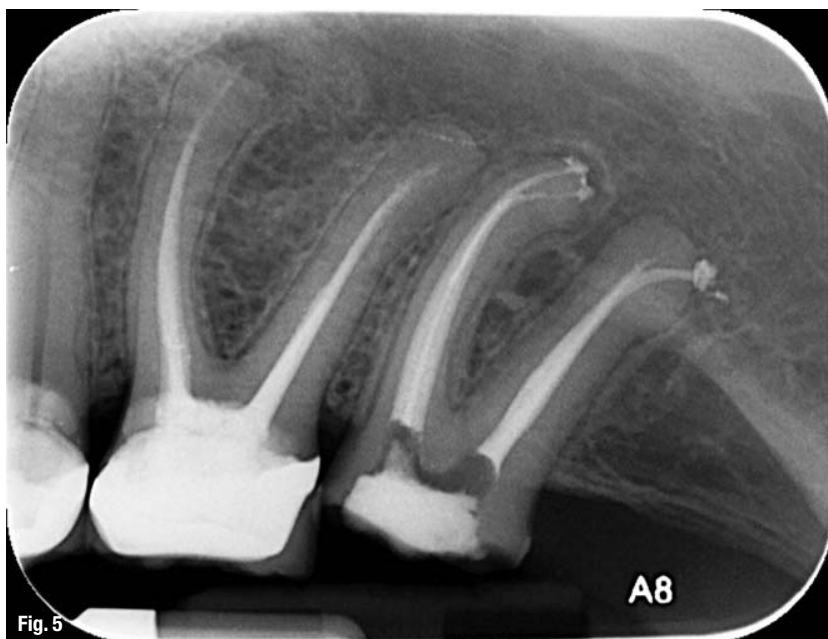
This technique shows the clinician which tip size of a .02 tapered K-file binds at length, indirectly revealing the apical diameter of the

canal. Tactile gauging is achieved with NiTi K-files to increase the accuracy of the test because the more rigid stainless-steel K-files can cause misreadings of apical diameters. Tactile gauging is achieved in the presence of 17 % aqueous EDTA, so that the smear layer is removed at the same time that shaping is completed (in visual gauging dentists will still place EDTA in the canal for a minute to remove the smear layer before reintroducing NaOCl), and it is absolutely critical that the NiTi gauging files are used with a straight-in, straight-out motion—not even a wiggle can occur or the apical constricture will be cut open and further shaping will be required to recreate apical continuity of taper.

Shaping of the palatal canal (a medium-size canal) was begun with a 30/.08 GTX File and it easily cut to length, showing no chips at the tip of the file. A 40/.08 GTX File was then cut to length with visual gauging, indicating that shape might then be complete—a fact that was confirmed by tactile gauging. Each canal was shaped with just two GTX Files, and the post-operative radiograph shows very conservative coronal shapes and excellent apical accuracy in the obturation (Fig. 2).

### **\_Case 2: Mandibular molar re-treatment**

Figure 3 shows a previously treated tooth that was sensitive to percussion and biting pressure. It had an overt apical lesion on the mesial root apex due to the inadequacy of apical treatment. After removal of the gutta-percha, lubricant and small K-files were used to bypass the apical blockage in the mesial canals (Fig. 4) and the ledge in the distal canal. The mesial canals had separate apical openings that were each negotiated. However, they were also confluent





and my shaping files working through those canals cut into a common terminal opening. The second apical portal of exit in the root was kept patent with a #15 K-file, the gutta-percha points were fitted into the confluence, and the second opening was filled during the Continuous Wave of Condensation Downpack. The canals were initially shaped with a single 20/.06 in three cutting cycles, followed by a 30/.06 GTX File to finish as the 20/.06 had no tip flute debris upon reaching length.

The distal canal was more difficult because it had a sharply bent canal with a ledge at the apex of the curve (created by the previous dentist who treated the patient). Pre-bent, stainless-steel K-files were used to bypass the ledge impediment and a series of files (sizes 15 to 30) were used in a light serial step-back technique to rough out the apical shape. I had used this technique to cut tapered-preparation shapes in root canals for about ten years, and although it was the only method we had prior to variably tapered NiTi shaping instruments, it was slow and tedious, and created less-than-perfect tapers in canals. So in this case, although it was necessary to cut an initial shape with this method, I wanted an apical taper that would improve the apical accuracy of obturation in the canal.

The technique taught to me by Dr David Rosenberg, (a dear friend) who tragically passed away earlier this year and will always be an inspiration, in these situations is to pre-bend the NiTi shaping files with Endo-Bender pliers. While NiTi (even with its shape memory) is commonly thought to be impervious to bending, it actually requires greater flexure—about a 180 degree bend—to achieve a residual bend of approximately 30 to 45 degrees. This can be done to GT Hand Files or to GTX Rotary Files (I prefer using

handpiece-driven files for this procedure). After a 30/.08 GTX File was bent and the directional indicator on the stop was aligned with the bend, I tapped the foot pedal until the bend on the file in the handpiece was in a distal direction, dropped it past the ledge impediment, and depressed the foot pedal. The file quickly cut to length and the canal was tactilely gauged at a 30 K-file size.

However, the ledge was so large that it was virtually impossible to fit a gutta-percha cone beyond it, so this canal was filled with a GTX Obturator. These filling devices always move the sealer and gutta-percha ahead of the carrier. So, in this case I filled beyond the impediment by inserting the obturator to the ledge point in four seconds, thereby accelerating the apical movement of filling material ahead of the carrier by 3 to 4 mm. This was instead of the usual six- to eight-second insertion time, described in my typical GTX Obturator technique, necessary to limit the filling material to only end up 1 mm ahead of the carrier—which is obviously the goal when the carrier can be placed to a length 1 mm short of the terminus.

This case was shaped with just two GTX Files in the reasonable curvature of the mesial canals. However, as is typical with difficult canals, the distal canal required four K-files and a single GTX File (Fig. 5).

#### **\_Cases 3 and 4**

The two cases shown in Figures 6 and 7 were treated by my good friend Dr Giuseppe Cantatore. As is typical of his GTX technique for virtually all canals, he negotiated each canal up to a K-file size 20, cut a 20/.06 GTX File to length, then cut a 30/.04 GTX File to length, and finished with a 30/.06 GTX File. Dr Cantatore is known for

**Figs. 6 & 7** \_Maxillary molars with S-shaped curves in the DB canals; note the MB root structure in Figure 6 with its narrow width and remarkable curvature. No anti-curvature brushing motion was needed because of the GTX File lands and their limited MFDs. These cases were filled with carrier-based obturation. (Courtesy of Dr Giuseppe Cantatore)

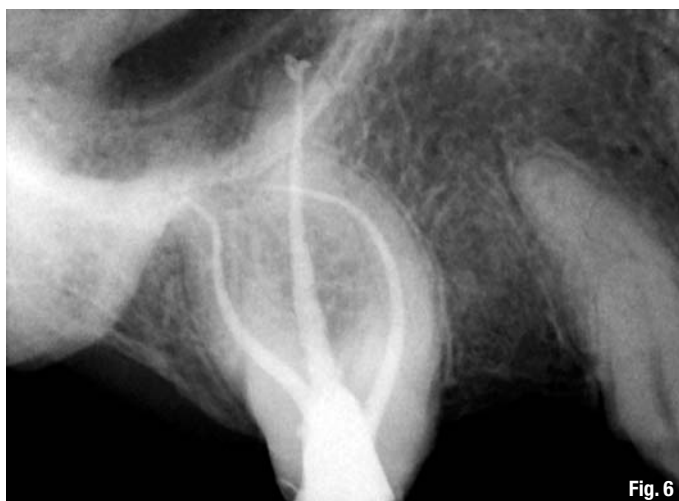

Fig. 6

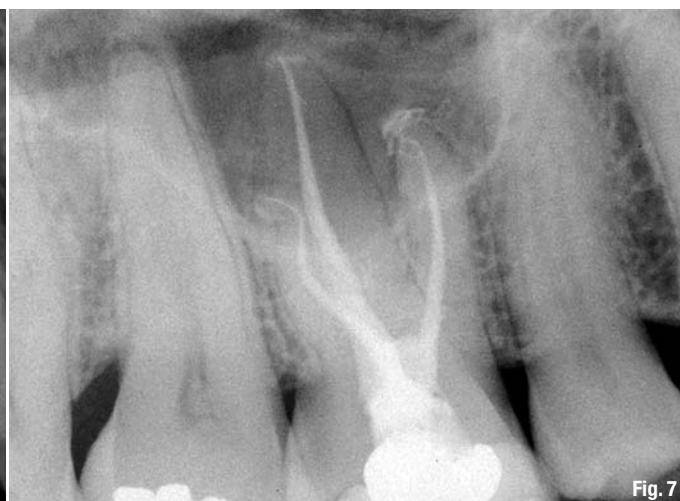
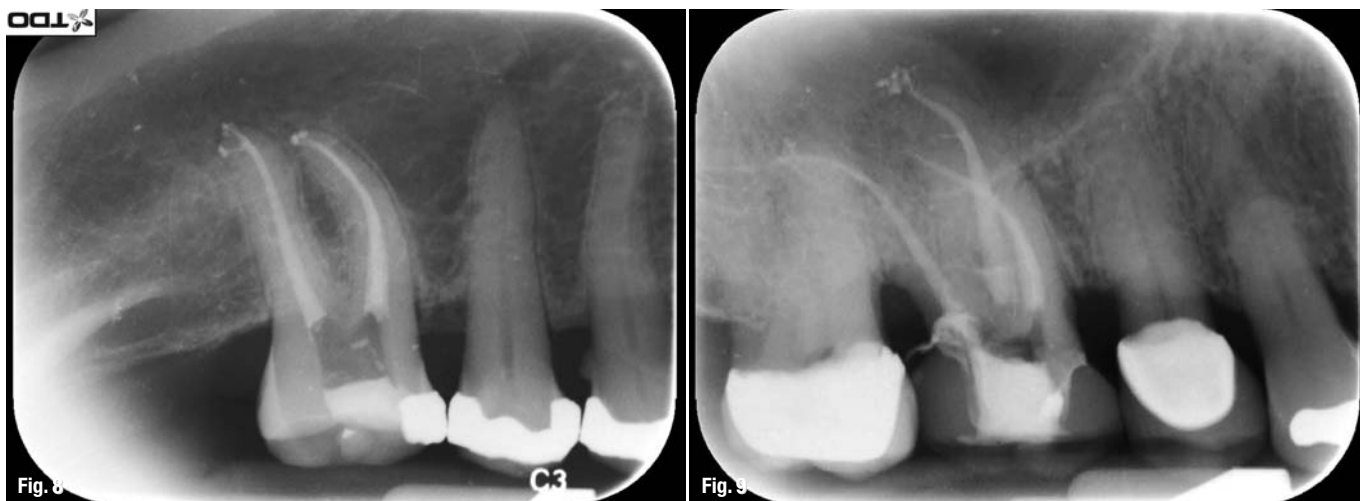
Fig. 7



**Fig. 8**\_A mandibular molar shaped with two GTX Files in the mesial canals and a single 30/.08 GTX File in the distal canal; note the excellent 3-D cleaning and filling of lateral canals.

(Courtesy of Dr David Rosenberg)

**Fig. 9**\_Maxillary molar with severe curvature in all four canals; note the conservative coronal shapes, the excellent apical control, and the multiple lateral canals cleaned and filled. This is an excellent clinical result requiring only two GTX Files per canal.

(Courtesy of Dr David Rosenberg)

his very conservative coronal shapes through which he uses carrier-based obturation to fill with excellent apical results.

The final two cases (Figs. 8 & 9) were treated by Dr Rosenberg. In his case notes, he stressed that he spent much time creating ideal access cavity preparations prior to instrumentation, with special emphasis on creating straight-line glide paths for files, so that they do not accumulate cyclic fatigue stresses in the coronal third. He assured me that he no longer uses Gates–Glidden Burs for his approach and instead uses ultrasonic tips and an LAX diamond bur (SybronEndo), where it fits without over-enlargement of orifices.

Dr Rosenberg also instruments to a #20 K-file size in small canals before cutting GTX Files to length (more handwork than I do), but as a result he usually gets the 20/.06 GTX File to length without using a 20/.04 GTX File. If he has difficulty working a #20 K-file to length in a tightly curved canal, he cuts to shape in the coronal third with a 20/.06 GTX File and then with the

#20 cuts to length with less effort. Occasionally, he will use a 20/.04 GTX File when a 20/.06 GTX File resists placement. In medium or large canals, he works progressively larger K-files to length until the first one binds at length (usually a #30 or #40), and then cuts to shape with a 30/.08 or 40/.08, respectively.

Like me, both of these clinicians use rotary files only in a single tooth before they are discarded. We know that the cost of tracking previous file use, or worse a file separation, is never worth the cost of a new file being brought into the case.

### Conclusion

What is seen in all of these cases instrumented using just one to three GTX Files per canal is ideal apical management, both in terms of fidelity to the original canal path and in terms of apical accuracy and three-dimensionality of obturation. We see shapes that are confluent with the original curvature of the canals with teeth with their structural integrity intact after endodontic therapy for the best chance of an excellent long-term prognosis.

In my opinion, the shaping results with GTX Files shown here are a 10x improvement over shaping file systems requiring four to six instruments, twice the number of procedural steps, laborious anti-curvature brushing motions to make up for large MFD sizing, and less than predictable avoidance of transportation. The state-of-the-art endodontic shaping is now a two-file reality, allowing more time for things like negotiating all canals to their termini and effective irrigation.

*This article is dedicated to the memory of Dr David Rosenberg, a friend, colleague, devoted husband and loving father.*

### about the author

roots



**Dr L. Stephen Buchanan** is a Diplomate of the American Board of Endodontics and a Fellow of both the International College of Dentists and American College of Dentists. Clinicians interested in his DVD series, *The Art of Endodontics*, and his hands-on laboratory workshops in Santa Barbara, USA, can call +1 800 528 1590.

For more information related to this article and for GTX updates and answers to frequently asked questions, please visit [www.endobuchanan.com](http://www.endobuchanan.com). Free CE online courses are also available on the GTX System and other topics.

Diagnostic  
Information  
Treatment  
Care  
Healing



## Design meets precision

There is hardly another dental equipment manufacturer who demonstrates such a passion for perfection as the Japanese family-owned company Morita. Our work reflects the highest standards in terms of quality, reliability, precision and customer satisfaction.

One example: the high-performance Apex Locator Root ZX mini. Root ZX mini uses the ratio technique of the Root ZX, the winner of many awards, to provide the highest measurement accuracy. Its function and precision are not affected by temperature fluctuations or moisture in the canal. Hardly larger than a smartphone, the Root ZX mini is compact and light, ideally suited for the hand or patient's chest if you like. There is space for this elegant high quality device wherever your treatment requires it. The coloured display is easy to read, the automatic calibration and the automatic zero balance make its use both comfortable and safe.

Talk to your dental equipment specialist retailer about the Root ZX mini, or call us directly: +49 (60 74) 8 36-0!

[www.jmoritaeurope.com](http://www.jmoritaeurope.com)



**MORITA**

Thinking ahead. Focused on life.

# Endodontically speaking, the proof is in the pudding

Author\_Dr Barry Musikant, USA

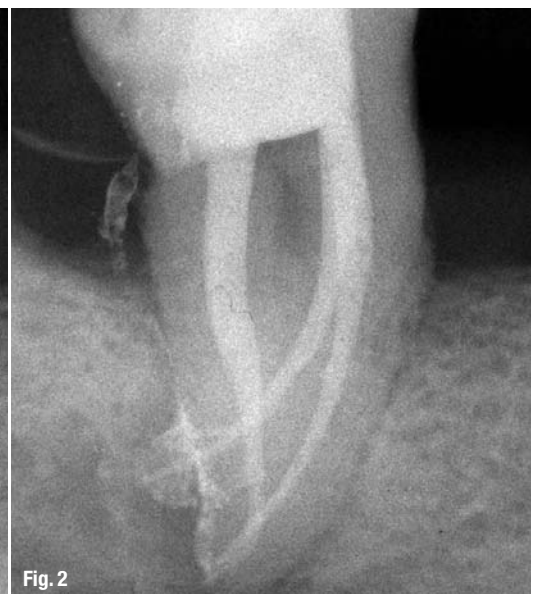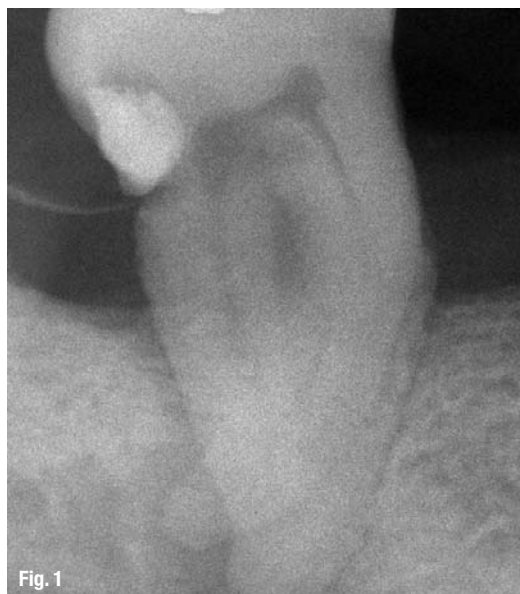**\_Having lived through the traditional** (hand instrumentation) and rotary NiTi periods of endodontics, the main drawback of both periods, in my estimation, has been in not applying what our clinical experience and our wealth of research has told us. Today, we essentially use K-files as if they were reamers. By this, I mean that we use them predominantly in a watch-winding motion, a reaming action by another name.

Does it matter if a K-file is used in a reaming motion? What are the differences between a K-file and a K-reamer that call for differences in their usage? A K-file has twice as many flutes along the 16 mm working length that a K-file and K-reamer have in common. Twice as many flutes means twice as much engagement along length and at least twice the resistance encountered during

apical negotiation. Increased resistance to gaining apical length does not sound like a desirable trait.

Are there any other differences? The flutes on a reamer are twice more vertically oriented than those on a file. Does this have implications for using the recommended watch-winding motion?

The more the cutting edges of the flutes approach a right angle to the plane of motion (which is mainly horizontal), the greater the cutting efficiency of the flutes. An easy way to visualise this concept is to consider the use of a file in carpentry. The carpenter is able to cut wood with a file because he/she is applying a vertical motion to an instrument that has horizontal flutes. If the flutes were vertical, in the same plane





as the plane of motion, then the carpenter would be scratching the wood, not cutting it. The same applies to planing an internal root surface.

In addition to engaging the walls of the canal less and cutting dentine more efficiently, the K-reamer is more flexible than the K-file because the fewer number of flutes produces a less work

1. even greater flexibility because of its thinner cross-sectional diameter;
2. less engagement along length;
3. the inclusion of two vertical columns of chisels that cut effectively in both clockwise and counterclockwise motion;
4. the inclusion of a cutting tip; and
5. a space for dentinal debris.

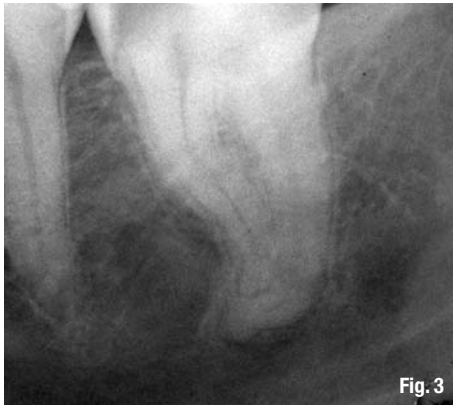

Fig. 3

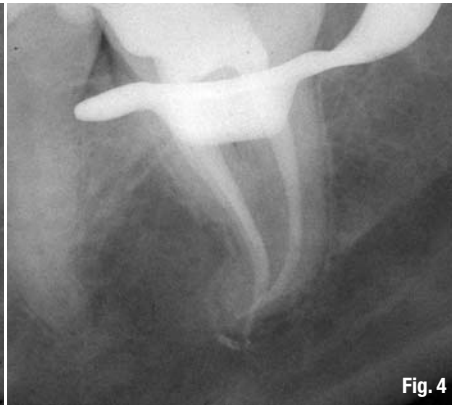

Fig. 4

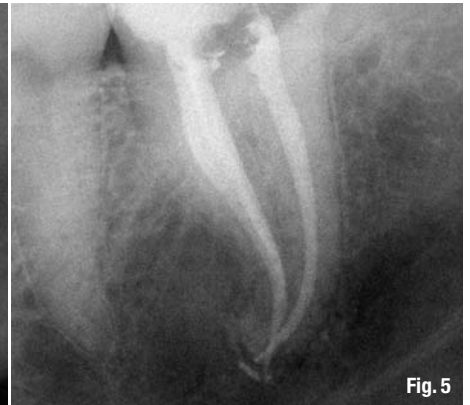

Fig. 5

hardened instrument. Greater flexibility, less engagement and more efficient planing of the canal walls give the dentist an improved tactile perception, providing the ability to distinguish between a tight canal and the encountering of a solid wall.

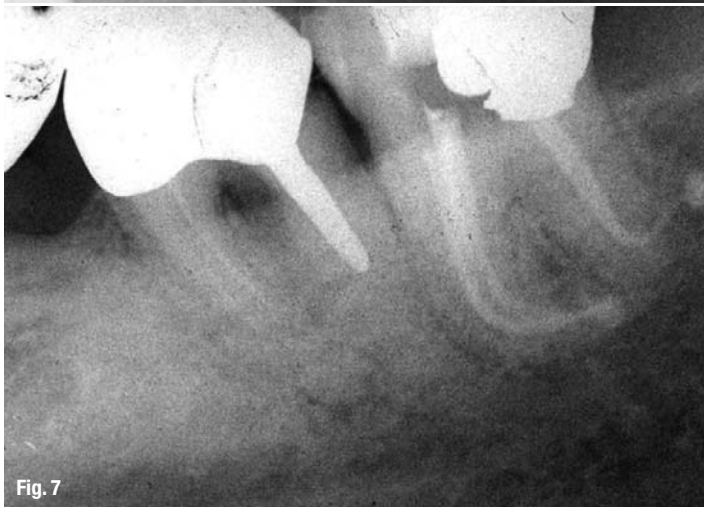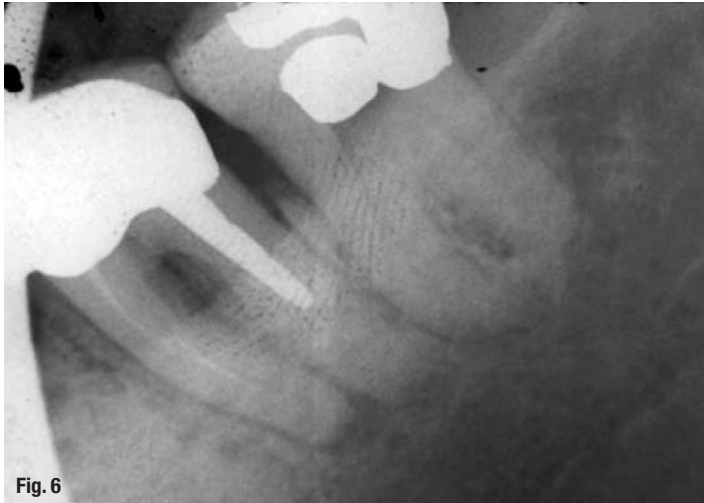This is all very well, but the problem is that the vast majority of dentists are still being taught to use K-files if not for the entire preparation of the canal at least for the glide path so that rotary NiTi can be used with greater safety. The K-file, an instrument not well designed for its function makes glide-path creation a challenge. It also motivates dentists to use these instruments for as short a period as possible so the more efficient rotary NiTi instruments can be used. There is a bit of a conundrum here. Inefficient K-files are being used so that the more efficient rotary NiTi can be safely employed. If instruments far more efficient than K-files could be employed, the need to switch to rotary NiTi would be reduced. Furthermore, rotary NiTi has its own problems, including unpredictable separation, the need for single usage and great expense.

The way to solve this conundrum is through relieved reamers used either with a tight watch-winding motion or in a 30° reciprocating handpiece. This brings a vast improvement and nullifies the need for rotary NiTi. While K-reamers are vastly superior to K-files in the shaping of canals, relieved K-reamers, otherwise known as SafeSiders, are measurably superior to non-relieved K-reamers. The reasons for this superiority include the following:

These factors produce an even better tactile perception, giving the dentists precise knowledge regarding not only when a solid wall is being encountered, but also whether the canal is round or oval.

Why is the dentist better off using an instrument that clearly tells him when he/she is encountering a wall? The more precisely the instrument tells the dentist what the tip of the instrument is encountering, the easier it is for the dentist to know when to bend the instrument at the tip to negotiate around any blockage that he/she comes upon. If a dentist doesn't know a wall has been encountered, he/she is more likely to keep applying increasing vertical force as the instrument is twisted. The result is often an artificially made canal with the original canal with tissue in it untouched or at best inadequately cleaned. Once the dentist has negotiated around the blockage manually, he/she may reattach the relieved K-reamer to the reciprocating handpiece for quick and effective apical negotiation. It usually takes no more than a few seconds to achieve apical length when the canal is patent.

The relieved reamers have two requirements to achieve rapid non-distorted shaping. First patency must be maintained. The way to do this is by extending the instrumentation 0.5 mm beyond the constriction through a #25. As long as this is done, patency will be maintained and distortion will not occur. The other requirement is either the use of a tight watch-winding motion or use in a 30° reciprocating handpiece. This particular



requirement becomes increasingly essential with increasing curvature of the canal. The short arc of motion keeps the K-reamers well centred within the confines of the canal. Distortion will only occur in curved canals if the arc of motion is significantly increased. This cannot happen when a reciprocating handpiece is used and is unlikely to happen with manual use simply because canals of increasing curvature produce dramatically more resistance to rotation, making the short arc of motion far more achievable. In fact, customising a short arc of motion, where the greatest resistance is encountered, is entirely compatible with distortion-free shaping.

These two insights eliminate the need for rotary NiTi entirely and in doing so, eliminate the concerns for separation either through torsional stress or cyclic fatigue. While this sounds good, are there drawbacks? Does this system require many more instruments and can they be used efficiently?

If one considers the reality that most glide paths are first created with difficulty using K-files

through a #20 before rotary NiTi is used, we can dispense with instrumentation through a #20 for both approaches because the number of instruments is common to both. In reality, the glide path through a #20 with both non-relieved and relieved K-reamers will be dramatically easier and more rapid than K-files, but it is the use of the same relieved reamers in larger dimensions that negate the need for rotary NiTi. After the #20 relieved reamer is used, the coronal curve is straightened with a tapered peeso called a Pleezer. It is used only until resistance is met and never closer than 6 mm from the apex, even if possible. The use of a Pleezer would be similar to the use of a rotary NiTi instrument employed in a crown-down fashion, except the Pleezer is made of stainless steel with a far greater capacity to remove tooth structure from the outer wall of the canal, thus providing straight-line access for the subsequent instruments.

Once straight-line access has been attained with the Pleezer, the #25 relieved reamer is taken 0.5 mm beyond the constriction, followed by the #30 to the constriction. At this point, if the canal was tight to begin with and highly curved, the final instrument would be a 25/.06 reamer 0.5 mm beyond the constriction, followed by obturation of the canal. In order to gain a canal preparation of a #30 at the apex, the minimum preparation stated in the literature to ensure adequate irrigation and a 25/.06 overlaid taper requires four instruments beyond the #20. This preparation compares favourably with rotary NiTi that often will not shape a curved canal to more than a 20/.04 or at most a 25/.06 to the apex, dimensions that do not fulfil the minimum preparation for effective irrigation as suggested by research.

If the canals are larger, shaping may be continued with the #35 after the #30 to the apex with the #40 1 mm short and the 25/.06 used at this point. Even these larger preparations require no more than six instruments and are rarely ever needed in recapitulation, the way rotary NiTi instruments must be used.

The system sounds too good to be true. The claims are that the system is able to shape highly curved canals without distortion, that canals can be shaped to a minimum diameter of #35 in most cases and that the instruments will not break, that they can be used six to seven times and overhead will diminish by approximately 90 % when switching from a rotary NiTi system to one using relieved reamers both manually and in the reciprocating handpiece. Where is the proof for these claims?

Well, for one we have the presentation of cases. Secondly, we offer free two- to three-hour workshops for anyone interested in trying our system, so they can decide for themselves on the validity of these assertions.

Below are some examples of fairly challenging cases that were treated recently in our office using the SafeSiders. Please understand that the instruments are not simply placed into the reciprocating handpiece and then the canals are shaped. Rather, the reamers—both relieved and non-relieved—give excellent tactile feedback so we know when we are in the canal and when we are encountering a wall. With this knowledge, we know when to bend an instrument to negotiate manually around any blockage. Once patency has been achieved, the instruments used either manually or in the handpiece give us the ability to widen most often apically to a #35 without distortion and then obturate most often with a single medium point in a canal flooded with epoxy resin cement.

The case pictured in Figures 1 and 2, treated by Dr Young Bui, displays several important features of the system. Dr Bui was able to shape the canals to a #35 to the apex, ensuring enough irrigation to open up whatever lateral canals were present so they too could be obturated with the epoxy cement. While shaping to these dimensions, distortion is avoided because the instruments are fed apically using either a tight manual watch-winding motion or the reciprocating handpiece. If a wall had been encountered, the instruments would have been pre-bent, fed manually around the blockage and then reattached to the reciprocating handpiece. Please note the density of the fills. These radiographs were originally generated from film, not a digital source, which tends to exaggerate the density of gutta-percha and cement. The original negotiation of the canal was fairly straightforward because, despite the curves negotiated, the reamers (both relieved and non-relieved) produce far less resistance along length than K-files. After the #20, the coronal curves of the canals were straightened with a Pleezer, which has a tip size of 0.75 mm and a 0.03 mm taper.

Figures 3 to 5 demonstrate the maintenance of canal anatomy while shaping canals to a minimum of #35 and an overlaid taper of 25/.06, producing conditions that allow for adequate irrigation and the placement of a 3-D fill in a predictable manner. Again, the canals were initially negotiated with instruments that are inherently less engaging along the walls of the canal, provid-

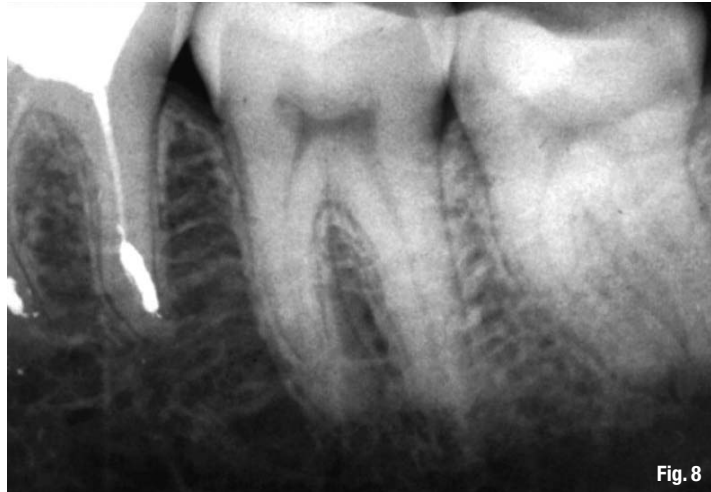

Fig. 8

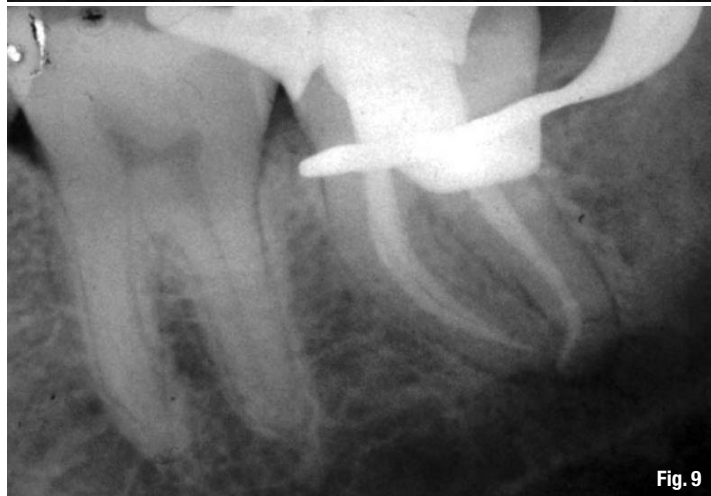

Fig. 9

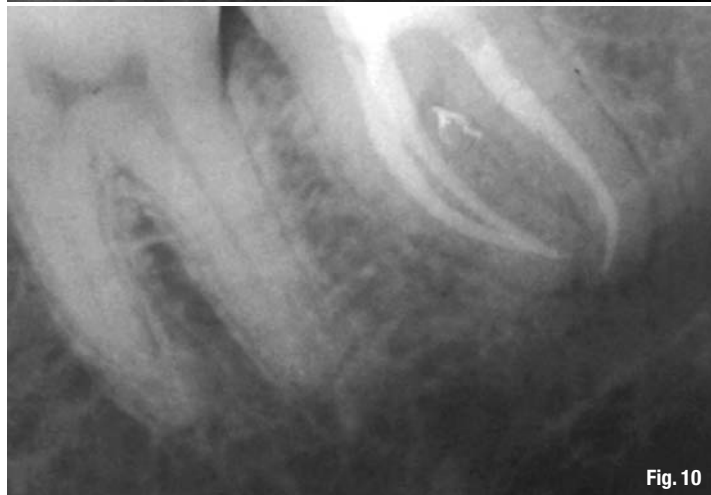

Fig. 10

ing for less resistance as they negotiate apically. All apical negotiation is achieved with the same manual watch-winding motion or the 30° arc produced by the reciprocating handpiece. Either way, maintaining patency assures a non-distorted canal preparation.

Figures 6 and 7 present an extreme case of canal curvature, treated by my partner Dr Doug Kase. The curve on the distal root could not be



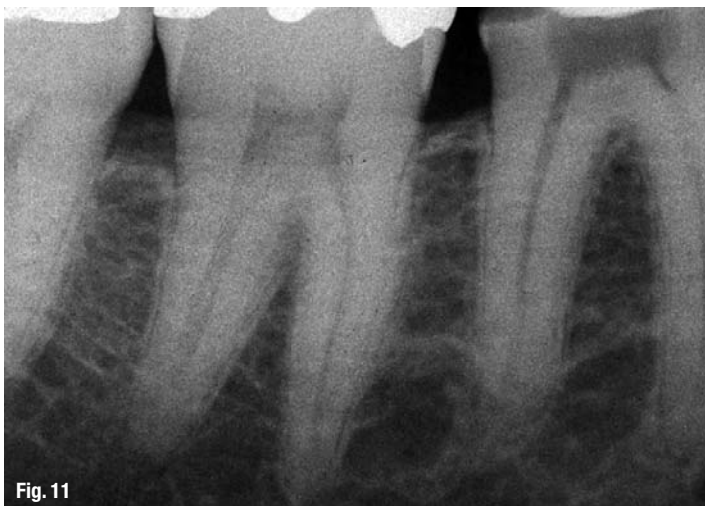

Fig. 11

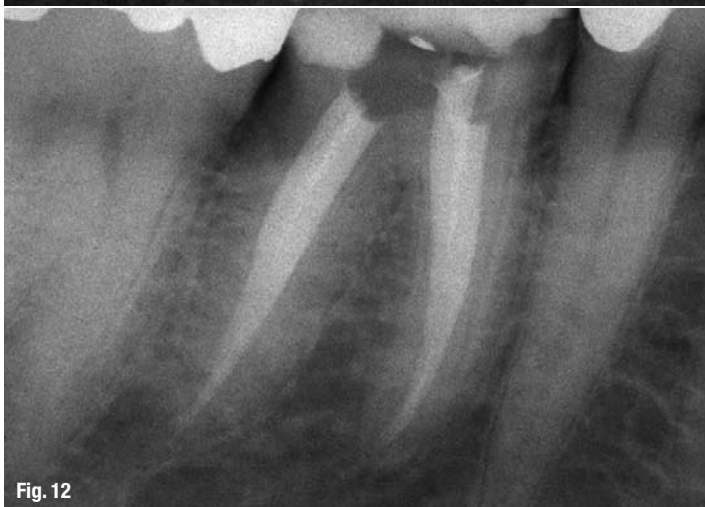

Fig. 12

taken to a #30 to the apex. In this situation, Dr Kase shaped to the apex to a #20, 1 mm back to a #25, another 1 mm back to a #30 and then shaped as far as he could go with the 25/06 without applying excessive apical pressure. Some of the lessons from this case include reading the original X-ray accurately to be aware that roots sometimes make strange bends. This is easy to say in hindsight. Just when you think you have a set of rules to follow, a condition comes up that doesn't allow for such consistency. In these cases, it is good to know that the shaping and obturation system you are using has the adaptability to handle whatever arises.

Figures 8 to 12 give two more cases that demonstrate the use of our system. The first case (Figs. 8–10) again shows the subtle curve that we successfully maintain, and the second case (Figs. 11 & 12) demonstrates the shaping of thicker canals because, as we know, not all canals are round. Some are thin and wide, particularly in the bucco-lingual dimension, and we must be prepared to shape these in such a way as to remove as much debris as possible.

Maintaining the curves is relatively indigenous to the instruments, as long as they are used with the two following criteria: maintaining patency and used within a short arc of motion—something that the system is designed to deliver.

As seen in Figure 12, canals call for wider preparations, be they in the mesio-distal or bucco-lingual plane. The relieved reamers in combination with the Pleezer are able to adapt to these situations as they arise.

We have presented a discussion of the advantages that come from a system that doesn't rely on either rotation or NiTi to deliver stress-free shaping of significantly curved canals. Being capable of successfully treating the cases above, makes our system well designed to handle less radical cases. By stress-free, we mean the impact of the canal anatomy on the integrity of the instruments and the benign impact on the health of the dentist of using a system that is virtually free of breakage. Without question, the incorporation of this shaping system along with our method of obturation has made the practice of endodontics far more enjoyable than I once thought it was destined to be.

For those wishing to attend the free 2 to 3 hour workshops, please call us at +1 212 582 8161 to set up a mutually agreeable time. For those who might like to join us on our message board, a site of true collegial respect and collaboration, please go to [www.endomailmessageboard.com](http://www.endomailmessageboard.com), create a user name and password and become a member. It is loaded with valuable information.

_about the author	roots
	<p><b>Dr Barry Lee Musikant</b> is co-director of dental research at and co-founder of Essential Dental Systems, a dental products manufacturing company located in South Hackensack, USA. The company's roots stem from the desire for product improvements. Dr Musikant's lecture schedule has taken him to over 400 international locations. He co-authored over 250 articles in dentistry in various major international and US dental journals. Dr Musikant can be contacted at <a href="mailto:info@edsdental.com">info@edsdental.com</a>.</p>





# 2010

# GREATER NEW YORK DENTAL MEETING

## FREE REGISTRATION\*

MEETING DATES:  
NOVEMBER 26 -  
DECEMBER 1

EXHIBIT DATES:  
NOVEMBER 28 -  
DECEMBER 1

86<sup>th</sup>  
Annual Session

The  
Largest  
Dental  
Convention/  
Exhibition/  
Congress  
in the  
United  
States



*\*Free registration  
before November 26*

Please send me more information about...

- Attending the Greater New York Dental Meeting
- Participating as a guest host and receiving free CE
- I speak \_\_\_\_\_ and am willing to assist international guests  
enter language



Name \_\_\_\_\_

Address \_\_\_\_\_

City, State, Zip/Country Code \_\_\_\_\_

Telephone \_\_\_\_\_ E-mail \_\_\_\_\_

Fax or mail this to:  
Greater New York Dental Meeting or  
visit our website: [www.gnydm.com](http://www.gnydm.com) for more information.

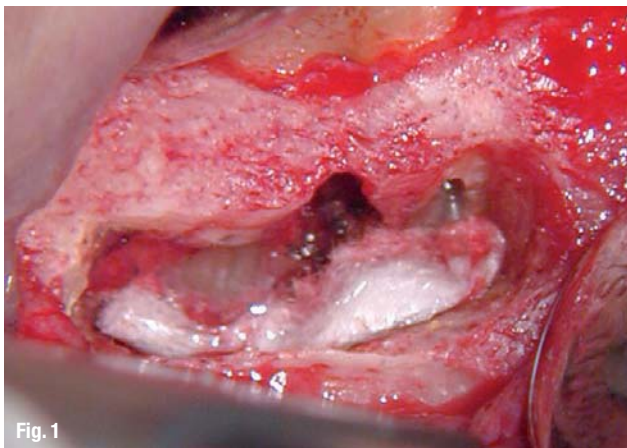


For More Information:  
Greater New York Dental Meeting™  
570 Seventh Avenue - Suite 800  
New York, NY 10018 USA  
Tel: +1 (212) 398-6922  
Fax: +1 (212) 398-6934  
E-mail: [info@gnydm.com](mailto:info@gnydm.com)  
Website: [www.gnydm.com](http://www.gnydm.com)

# Apical microsurgery— Part III: Access and crypt management

Author\_ Dr John J. Stropko, USA

In Parts I and II of this series, we discussed the preparation of the patient, the incision, and atraumatic flap elevation. These are the first three steps necessary to perform predictable apical microsurgery. As was mentioned, it is of utmost importance that each step is completed before proceeding to the next step. If a step is omitted or not completed, the next step will be difficult, if not impossible, to complete properly. The operation will develop into a stressful experience for the patient, the staff, and the doctor, with a less desirable or predictable end result. If all of the steps are completed as outlined, all procedures can be performed without stress and a favourable post-operative result is predictable. I have completed hundreds of apical microsurgical operations and the desirable results were mainly the same with just a few exceptions. The technique is very gentle and predictable—if all of the steps are followed without compromise!



**Fig. 1** \_An adequate amount of crestal bone should remain between the osseous crest and the coronal extent of the crypt.

\_After the properly designed flap has been atraumatically reflected and retracted, the access preparation is ready. Some important considerations are:

1) How much bone exists on the buccal aspect of the root being surgerised? If there is total dehiscence, guided tissue regeneration has to be considered. Ideally, there should be at least 3 to 4 mm of healthy, intact crestal buccal bone remaining after the access preparation has been completed (Fig. 1).

2) How much of the apex can be bevelled, or resected? Usually, there is an adequate amount of root length to work with. The shorter the root, the more conservative the operator will have to be when beveling, and the closer the bevel should be to 0°, so less removal of the root end is possible. If an exceptionally long post is present, that is closer to the apical terminus than desired, not as much of the root end can be resected. Or, if the periodontal bone level is less than desired, a more conservative amount of apical root structure should be removed to preserve as much of the crown/root ratio as possible.

Fortunately, the Operating Microscope (OM), and/or the Endoscope, allows the operator the luxury of being ultra-conservative when necessary.

The access to the root end is achieved most effectively with a high-speed handpiece that has no air exiting the working end (Fig. 2a). The usual air-driven handpiece does have air at the working end and using it may result in an air embolism. It is important to use as much water coolant as vision will permit to maintain the moisture in the tissues. Using a fine stream of water from the Stropko Irrigator fitted with a 27-gauge needle, the scope



Fig. 2

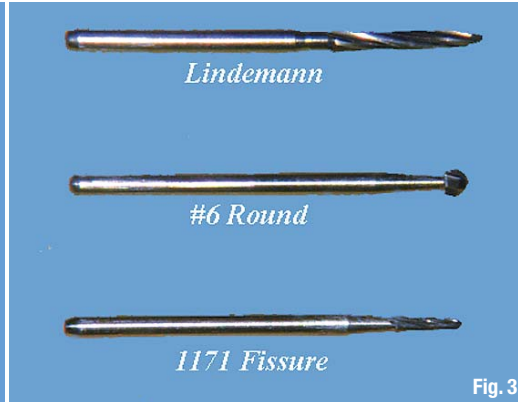


Fig. 3

**Fig. 2a** The surgical handpiece, such as Impact Air, should be used to prevent the possibility of an air embolism.

**Fig. 2b** Only three surgical burs are normally necessary for the access and REB.

assistant can keep the area moist and evacuate excess fluids at the same time. The initial access and root end apisection (RER) can be accomplished with just three surgical-length burs: the Lindemann bone bur, a #6 round bur, and an 1,171 fissure bur (Fig. 2b).

There are two different ways to begin the access:

- 1) Estimate the amount of the apex to be resected and with a Lindemann bone-cutting bur, remove the apex and prepare the access opening in one step. If there is any portion of the apex remaining in the crypt, it is curetted out and the access is more or less complete.
- 2) A more accurate procedure is to estimate the location of the apex. Then, using a #6 surgical length, round bur, slowly and gently remove the bone overlying the buccal surface of the root. Once the buccal surface of the apex has been uncovered, bone is removed until the coronal limit of the crypt is established and the general outline of the apex is readily observed and can be resected at this time. Often, especially with larger peri-apical involvement, the lesion can be curetted and the entire apex exposed. If the lesion is more palatal, or lingual, the root apex may prevent the necessary access for curettage and will have to be partially bevelled, or resected as part of the access process. A thorough curettage is important because it is an important first stage of achieving haemostasis from within the crypt. In general, if all of the granulation tissue is removed, the amount of haemorrhage will be greatly reduced, the management of the crypt will be easier to accomplish, and good visibility will be restored. This technique takes more time but results in improved visibility and the ability to be more precise with the initial RER. The finished bevel will be discussed in more detail later in the article.

In general, a biopsy should be performed on all tissue removed from the body. Granted, we are

usually quite confident of the pathological diagnosis of the LEO, but my feeling is that even if the odds are 1 in 100,000 that we are correct, no chances should be taken and a biopsy should be taken on a routine basis.

The final dimension of the access opening varies and is dependent on several factors:

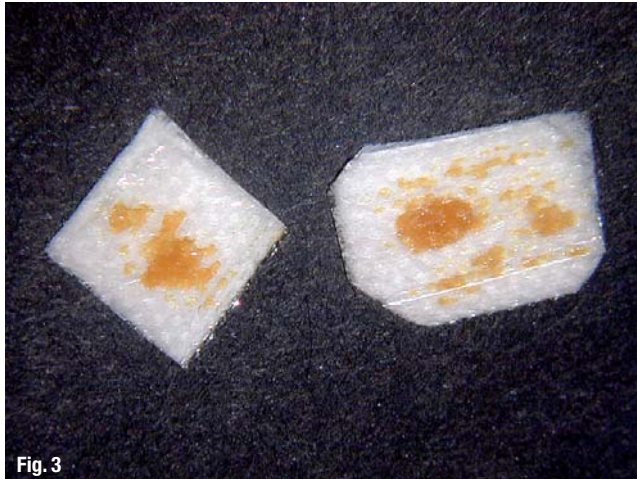- 1) The size and position of the lesion is important. If the lesion is larger, the access will, of necessity, be larger in order to perform a complete curettage.
- 2) The position of the apex determines the size of the access. The more lingual the apex, the more overlying bone has to be removed and the larger the access has to be for good visibility.
- 3) The access has to be sufficiently large to allow the instruments room to prepare the apical canal system without inhibiting their freedom of movement. The larger the instruments used, the larger the access must be.
- 4) The thickness of overlying bone is also important. If the buccal plate is thick, a wider access is necessary to eliminate a 'tunnel effect', so vision is not compromised.
- 5) The experience and ability of the operator, and equipment available is a great determinant of the size the access will need to be. I use both an Endoscope and the OM when performing apical microsurgery. In some cases, the Endoscope (JedMed) permits a better view of the surgical site owing to increased lighting and magnification. It also increases the ability to view previously difficult, and sometimes impossible, areas to be seen with the OM. The extent of a defect or existing anatomical variations that are lingual to the involved root end are typical examples of the value of also having an Endoscope during microsurgical procedures.

The management of the crypt is one of the most important steps and the operator should take as

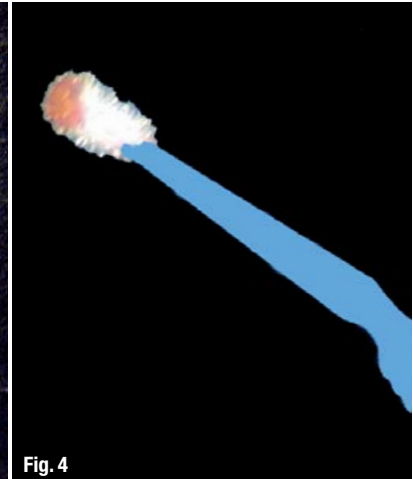


**Fig. 3** An appropriately sized piece of Telfa Pad can be lightly streaked with ferric sulfate for crypt management.

**Fig. 4** Only a small amount of ferric sulfate is used on the Micro Applicator.



**Fig. 3**



**Fig. 4**

much time as necessary to achieve the desired result. The clean and well-managed crypt is essential for good visibility and proper use of the retrofill materials. Ferric sulfate (Monsel's Solution, Cutrol), calcium sulphate (Capset, SurgiPlaster), Telfa Pads, and epinephrine-soaked pellets (Epidry, Pascal) are the most commonly used and effective agents for this purpose. I don't use CollaCote because the majority of the other materials mentioned are easier to use and provide a more efficient haemostasis.

After all granulation tissue and other debris have been thoroughly removed from the crypt, haemostasis is often achieved as a result of proper haemostasis-staging injections, discussed in Part II of this series. If that is the case, only an appropriately sized piece of Telfa Pad, lining the floor of the crypt is necessary to enhance lighting. However, this is not always the case and even slight bleeding must be addressed in order to preserve optimum visibility.

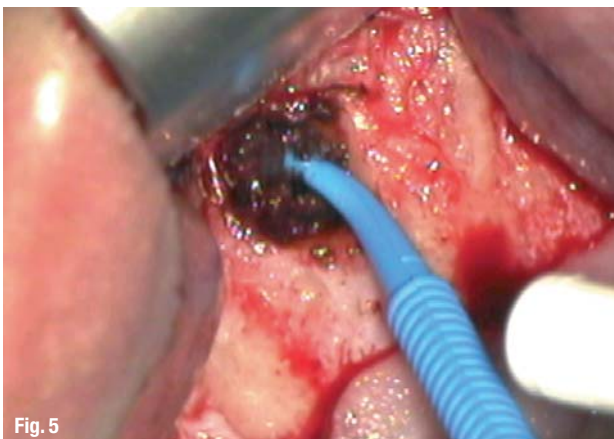
crypt for a short period of time until the haemorrhaging is completely controlled (Fig. 3).

If there is a moderate haemorrhaging, the Monsel's Solution is carefully applied with a Micro Applicator (Ultradent) directly to the problem area in the floor of the crypt. Keep in mind that only a small amount is necessary (Fig. 4). When ferric sulfate is used to achieve haemostasis, a thick brownish-black coagulum will usually result (Fig. 5). The resultant coagulum can be easily removed from the crypt with a clean Micro Applicator, gently flushed with water using a larger tip on a Stropko Irrigator as the scope assistant is evacuating any debris during irrigation of the crypt. The process is repeated until the bleeding is controlled. As soon as there is complete control of all bleeding in the crypt, the Telfa Pad should be removed and replaced with a fresh piece so there is as much 'white surface' as possible to facilitate light reflection and enhance vision.

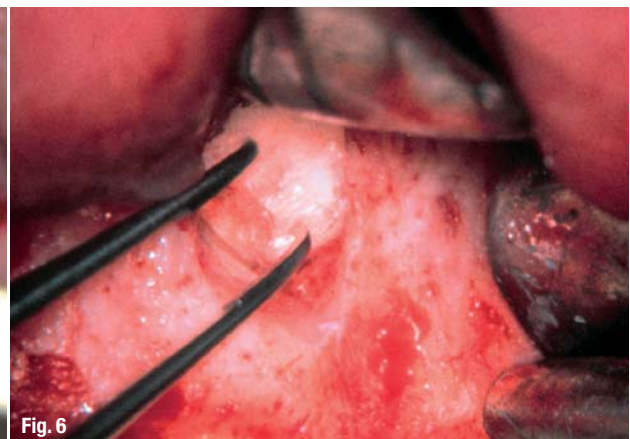
On condition that the coagulum resulting from the use of Monsel's Solution has been cleaned out of the crypt after the completion of the surgery, its use has not been shown to affect the healing process.<sup>1</sup> CAUTION: All forms of ferric sulfate must

**Fig. 5** When ferric sulfate is used for crypt management, a dark brown coagulum will result.

**Fig. 6** The Telfa Pad should be replaced as necessary to maintain good light reflection in the crypt.



**Fig. 5**



**Fig. 6**



be kept well within the confines of the crypt. It has an extremely low pH and will instantly chemically cauterise anything it touches! The buccal plate of bone, the periosteum, soft tissue, and the Snyderian membrane should always be avoided! It is important to keep in mind: If a little bit is good, a lot is not better! Use only small amounts on the end of an applicator because a small amount goes a long way (Fig. 4). NOTE: There are two popular forms of ferric sulfate: Monsel's Solution has a concentration of 72 % and Cutrol has one of 53 %. I like Monsel's Solution because it is very effective, readily available and less costly to use.

On a few occasions, severe haemorrhaging occurs. This can be a result of inflammation, a severed interdental artery or a compromised clotting mechanism. At any rate, when the blood flows faster than the evacuator can remove it, there is good reason for a little excitement and fast action! Immediately, pressure must be applied over the crypt with a finger. This will stop the haemorrhaging long enough to prepare the next few steps calmly. First, in a low and controlled voice, instruct the scope assistant to insert a bigger tip into the evacuator and hold it close to the crypt. If after removing your finger the haemorrhaging has not subsided, quickly replace your finger over the crypt as before. It is a good idea to take a radiograph and clinically re-evaluate the surgical area at this time to ensure no unforeseen anatomical structures (mandibular canal, palatine artery, etc.) have been infringed upon. Now it is safe to have your surgical assistant make a 'cotton plug' with a piece of sterile cotton roll large enough to completely fill the crypt, lightly streaking the tissue surface with Monsel's Solution and insert into the crypt, holding it firmly in place with your finger for a minute or so. After a few minutes, the cotton plug can be safely removed and

you can proceed without undue concern. A gentle irrigation with the Stropko Irrigator will remove most of the dark-coloured coagulum.

The above technique has worked all three times I found myself in this situation. In two of the cases, an interdental artery was the cause and the other was highly inflamed granulation tissue remaining in the crypt.

If haemorrhaging occurs on the surface of the exposed buccal plate, a Touch 'n Heat (SybronEndo) can be used. The scope assistant can evacuate the bleeder with a small surgical tip, so its exact source can be determined, and the Touch 'n Heat can be used to effectively cauterise it. After the haemorrhaging has been completely controlled and the crypt relatively cleansed of the coagulum, a fresh piece of Telfa Pad should be placed over the internal surface of the crypt (Fig. 6). Keep in mind when using the OM that light and dryness are the most important factors for good visibility. NOTE: Never proceed to the next step until total crypt management has been accomplished.

Once the crypt management is completed, the doctor can proceed to refinement of the bevel and preparing the retropreps with confidence and good visibility. At the end of this step, all haemorrhaging should be controlled, the grossly resected apical end of the root should be easily seen and the floor of the crypt should be covered with a clean, white piece of Telfa Pad; an apical microsurgeon's dream!\_

#### \_Reference

1. Lemon R, Steel P, Jeanson B. Ferric Sulfate Hemostasis: Effect on Osseous Wound Healing: Left in situ for Maximum Exposure. *J Endod* 1993: 170-173.

#### \_about the author

roots

**Dr John J. Stropko** received his DDS from Indiana University in 1964 and for 24 years practised restorative dentistry. In 1989, he received a certificate for endodontics from Boston University. He recently retired from the private practice of endodontics in Scottsdale in Arizona. Dr Stropko is an internationally recognised authority on micro-endodontics. He has been a visiting clinical instructor at the Pacific Endodontic Research Foundation (PERF), an Adjunct Assistant Professor at Boston University and an Assistant Professor of graduate Clinical Endodontics at Loma Linda University. His research on in vivo root canal morphology has been published in the *Journal of Endodontics*. He is the inventor of the Stropko Irrigator, has published in several journals and textbooks, and is an internationally known speaker. Dr Stropko has performed numerous live micro-endodontic and microsurgical demonstrations. He is the co-founder of *Clinical Endodontic Seminars*. He can be contacted at [topendo@aol.com](mailto:topendo@aol.com).



# The future of endodontics: pulp revascularisation

Author\_Dr Philippe Sleiman, Lebanon

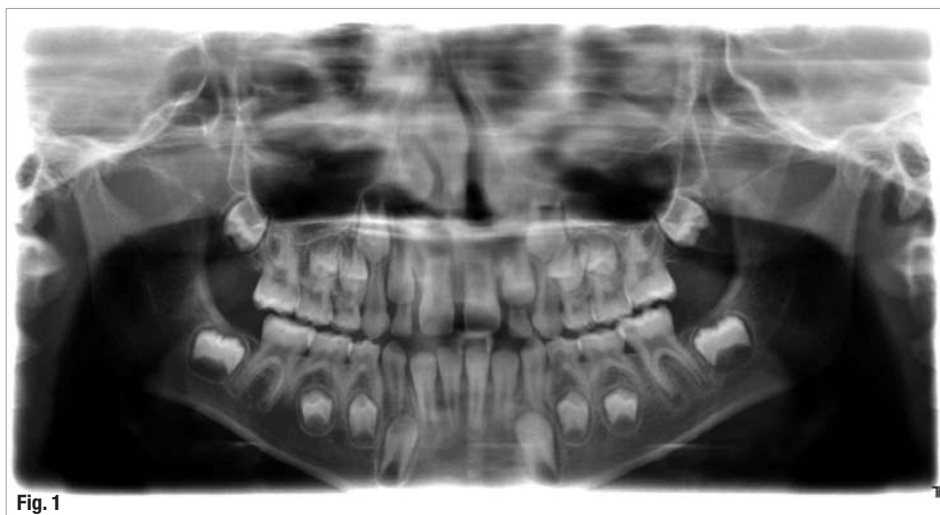

Fig. 1

new method for treatment of teeth with irritated, inflamed or necrotic pulp. Its main advantage lies in the possibility of further root development and reinforcement of dentinal walls by deposition of hard tissue, strengthening the root against fracture.<sup>6</sup>

This method depends mainly on pulp re-growing over the remaining pulp tissue. It is based on the presence of undifferentiated mesenchymal cells in the pulp and in the dentine that will give rise to stem cells, which upon injury differentiate into odontoblastoid cells that are later responsible for the formation of dentine bridges.

The conventional way to treat immature teeth with peri-radicular abscesses is to resort to the apexification method in which calcium hydroxide is used as intra-canal medication after instrumentation of the thin canal walls.<sup>1,2</sup> Calcium hydroxide has proven to be an effective intra-canal medication, as it creates an environment conducive to the formation of a hard-tissue bridge at the apex.<sup>3,4</sup> However, it has one main disadvantage owing to its high pH: it will digest tissues within immediate contact with it and thereby destroy tissues with the potential to differentiate into new pulp, which altogether results in teeth with thin and weak roots that are susceptible to fracture.<sup>5</sup>

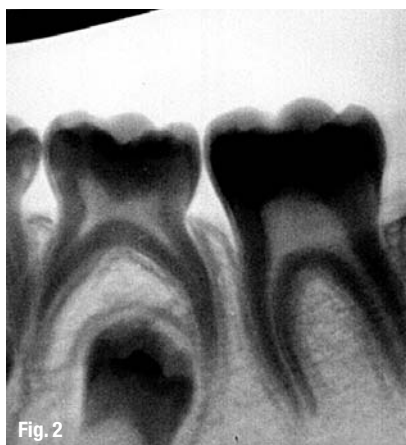


Fig. 2

The novelty of the clinical case presented here is that it is one of the few published thus far that demonstrates the use of a dual antibiotic paste and tissue engineering for apexification.

## Clinical case

A young female patient was referred to the office, suffering from pain in her lower molar. The X-ray revealed a lesion on both roots, with the mesial canals not yet in full formation regarding length and diameter (Fig. 1).

After discussing the case with the patient's parents and explaining the new technique, I opened the molar in very clean conditions. The distal root showed signs of light bleeding, so the pulp was relatively vital. The mesial roots did not show signs of bleeding, but the remaining pulp was clearly visible under the microscope. After copious irrigation using chlorhexidine in both the mesial and distal roots, SmearClear solution (SybronEndo) was placed and a passive activation with a #10 K-file

was performed in the mesial canals, with only some bleeding. Distilled water was used to flush out all the chemicals and a dual antibiotic paste was placed. Thereafter, glass ionomer was placed as an intermediate and composite was placed over this (Fig. 2). The patient did not report any pain, only mild discomfort.

I contacted the patient's parents on several occasions to invite them for a check-up but, unfortunately, they did not respond. After 18 months, I received a call from them, saying that the patient was feeling some discomfort. I immediately scheduled them and was surprised to see from the X-ray a complete formation of the mesial roots and the closure of the distal root (Fig. 3). The reason for the discomfort was a coronal crack with part of the composite lost, so coronal leakage was the main problem. A conventional root canal treatment was performed as the roots were then completely mature, using the TF (twisted files) for crown-down and apical enlargement up to size 45 in the mesial and size 50 in the distal using K3 files with .04 taper, and the root canals were sealed using RealSeal (SybronEndo; Fig. 4). The patient was sent to her dentist for molar restoration.

## Discussion

Attempts to regenerate pulp tissue under conditions of inflammation or pulp necrosis have proven to be unsuccessful.<sup>7</sup> In the presence of an infection, the pulp stem cells seem to be incapable of mineralisation and deposition of tertiary dentine bridge. It is therefore necessary to disinfect the root canal system in a fashion that does not impede the healing and integration of tissue-engineered pulp with the root canal walls.<sup>8</sup>

Disinfection of the root canal system is realised by abundant irrigation, followed by application of a mixture of antibiotics for several weeks. The antibiotic paste is to be renewed only when clinical signs show, such as pain and discomfort, which generally happens in the few weeks after the treatment. In order to preserve the pulp connective tissue that appears to act as a scaffold for further development of the stem cells, chlorhexidine gluconate is used for intra-canal irrigation instead of NaOCl because the latter is well known for its dissolution of the soft tissues.<sup>9,10</sup> Removal of the smear layer is essential for intimate contact between the stem cells and the nutrients coming from the scaffold.

The placement of the antibiotics is necessary following a particular procedure and in this case a mixture of two antibiotics (Curam, amoxicillin associated with clavulanic acid, and metronidazole)

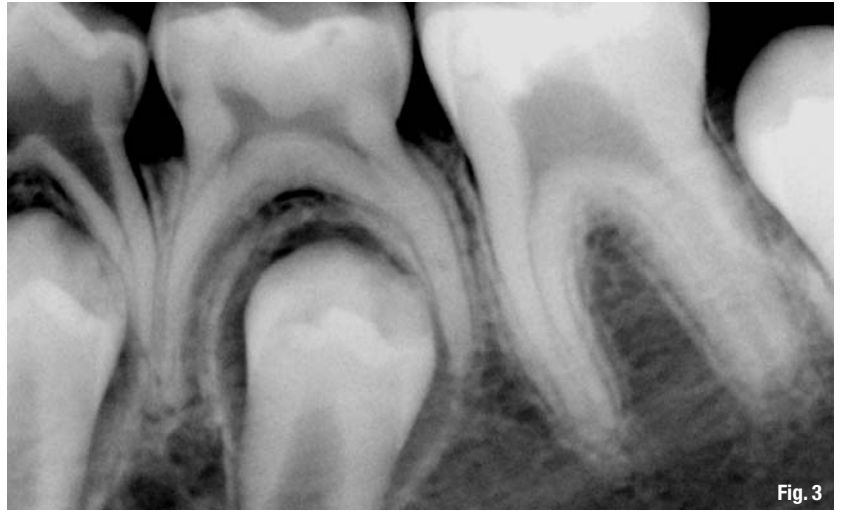

Fig. 3

was used. Amoxicillin is a broad-spectrum antibiotic that has bactericidal activity and is capable of inhibiting the synthesis of the bacterial cellular membrane during its growth phase owing to the competitive inhibition of transpeptidase. The clavulanic acid has low antibacterial activity but it irreversibly incorporates to the beta-lactamase, inhibiting the decomposition of amoxicillin. The tooth is sealed hermetically with a composite restoration with a glass ionomer as intermediate.

The author would like to thank Phd Yulia Vorobyeva, interpreter and translator, for her help with this article.

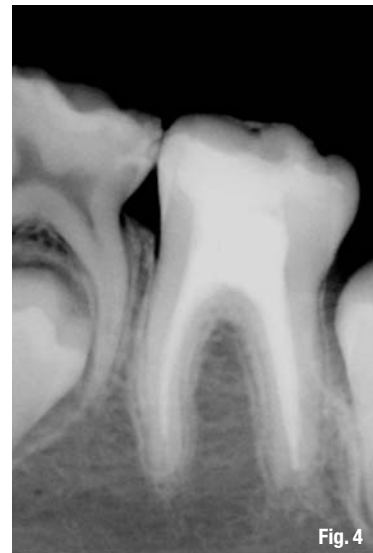

Fig. 4

*Editorial note: A complete list of references is available from the publisher.*

## \_about the author

## roots



### Dr Philippe Sleiman

is an endodontist and instructor at the Lebanese University Dental School. He lectures and conducts hands-on endodontics courses worldwide and has contributed to several endodontic

publications. His line of endodontic instruments is distributed by Hu-Friedy. Dr Sleiman can be contacted at phil@cyberia.net.lb.

# Practical clinical considerations in endodontic re-treatment

**Authors**\_Dr Richard E. Mounce, USA & Dr Gary D. Glassman, Canada

**\_Non-surgical endodontic re-treatment (NSER)** of failed root canals is almost exclusively a specialist procedure, owing to the complexity of diagnosis, treatment planning and advance techniques required for re-treatment procedures. As implants have become more predictable, the level of clinical success required with NSER in an attempt to retain the natural dentition has taken on new significance. This article reviews and discusses several key conceptual strategies for the re-treatment of failed root canals that optimise the outcome of the procedure.

It is assumed here that the clinician appreciates the value of the surgical operating microscope (SOM; Global Surgical) and ultrasonics in re-treatment procedures. While it is beyond the scope of this article to elaborate at length on the use of the SOM, its use is associated with improved outcomes of NSER and endodontic surgery.

Conceptually, NSER can be broken down into several key steps:

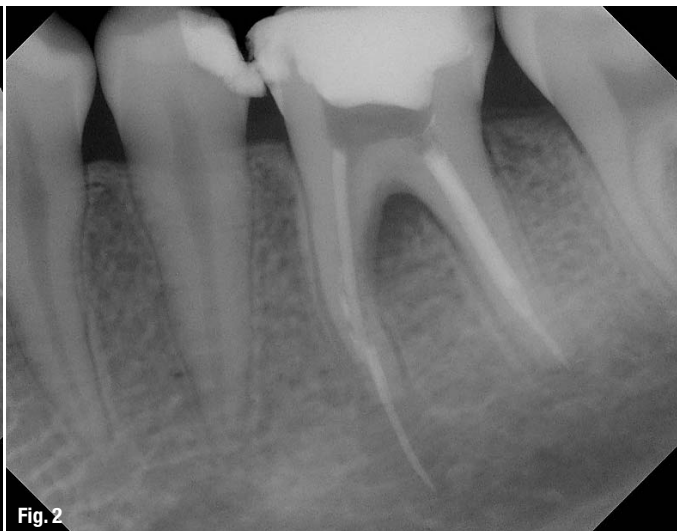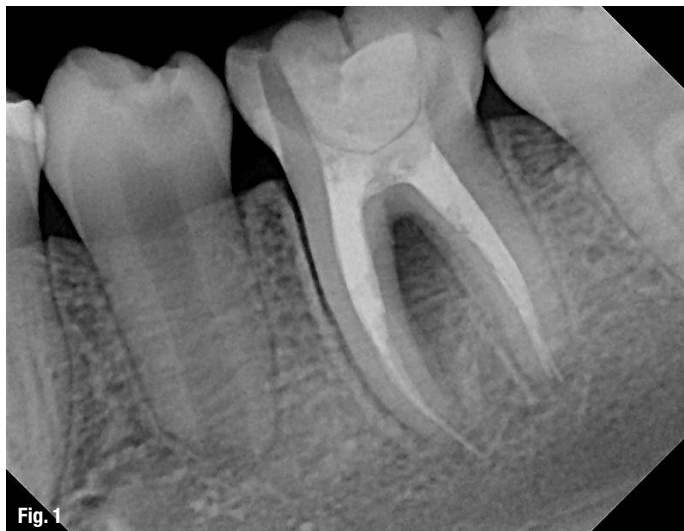## 1) *Determination of restorability*

The determination of restorability is a key component of NSER success. Treatment on teeth that are non-restorable is obviously contra-indicated. If these teeth were extracted from the pool of candidates for either endodontic therapy or NSER, success rates for both treatments can only go up. Figures 1 to 3 show three different cases that were poorly treated using inappropriate concepts and for which removal was indicated. Had the initial endodontic therapy been correctly conducted, the probabilities of clinical success would obviously have been far greater and the option of implant therapy irrelevant.

In the context of NSER, rather than compounding the existing failure, the clinician should carefully examine the case at hand and evaluate whether the tooth can be re-treated, and if so what the likely success will be. The initial treatment of the teeth pictured in Figures 4 to 6 was conducted to a high standard and for

**Figs. 1-3**\_Endodontic treatment with significant resulting iatrogenic events and other clinical defects.

**Figs. 4-6**\_Endodontic treatment conducted within the standard of care.





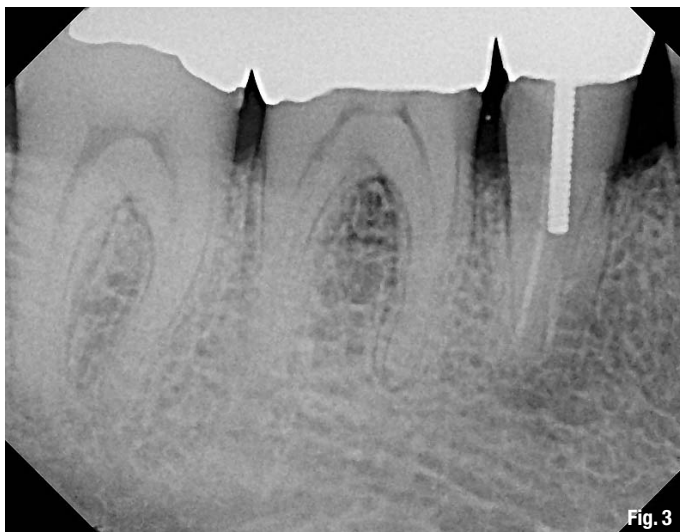


Fig. 3

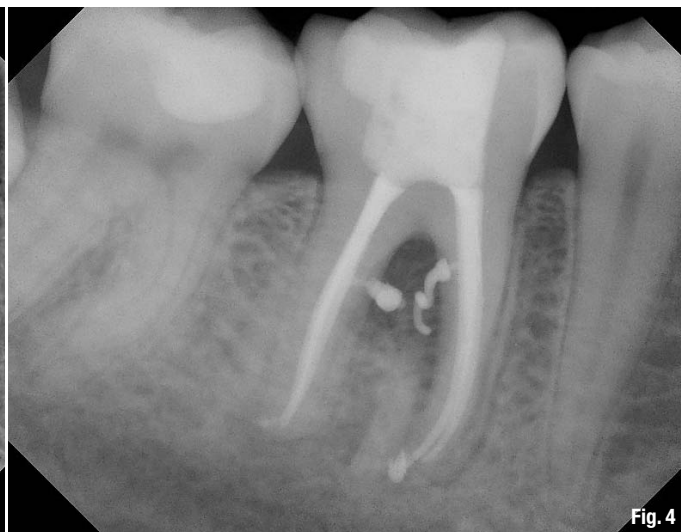

Fig. 4

this reason treatment will have a much better chance of long-term success. The difference between the two sets of outcomes is in large measure related to the different levels of pre-operative risk assessment.

2) *Preoperative diagnosis and assessment of risk factors*

One aspect of the determination of restorability is whether the tooth is vertically fractured and/or whether treatment will make vertical fracture likely. In addition, if the tooth has not had an overt iatrogenic event, the clinician should determine whether the contemplated treatment will lead to one. Near strip perforations through overzealous shaping can lead to overt strip perforations, should the removal of existing obturation material not be performed passively and with the correct methods (heat removal first, mechanical second, solvents and patency files third). The placement of highly

tapered rotary nickel titanium (RNT) files into large canals at high speed is predictive of mid-root strip perforation. Minimising this risk is addressed in detail below.

3) *Access*

If at all possible, the crown should be removed. Leaving crowns in place and creating access risks leaving portals for coronal micro-leakage, unset restoratives, caries and fractures. It also minimises access for evacuation of the obturation material and removal of objects of all types that may be lodged in the canal system (such as posts and RNT file fragments). A compromised access will limit both the tactile and visual control of the clinician and as a result some teeth that could otherwise be re-treated successfully are compromised.

It is noteworthy that the vast majority of failed root canals show evidence of overt coro-

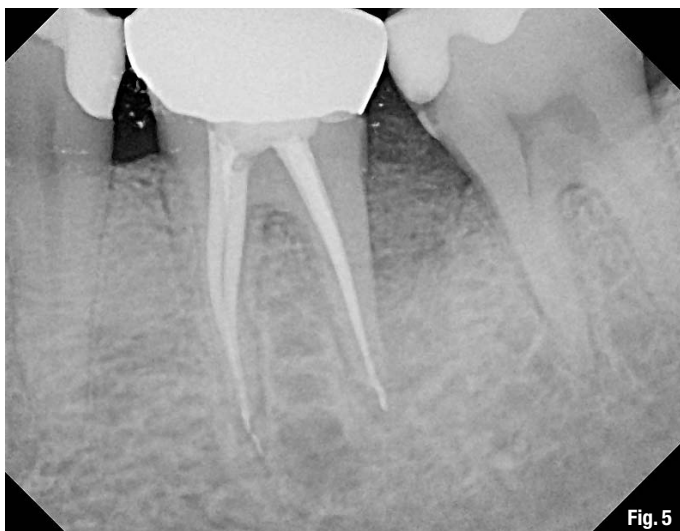

Fig. 5

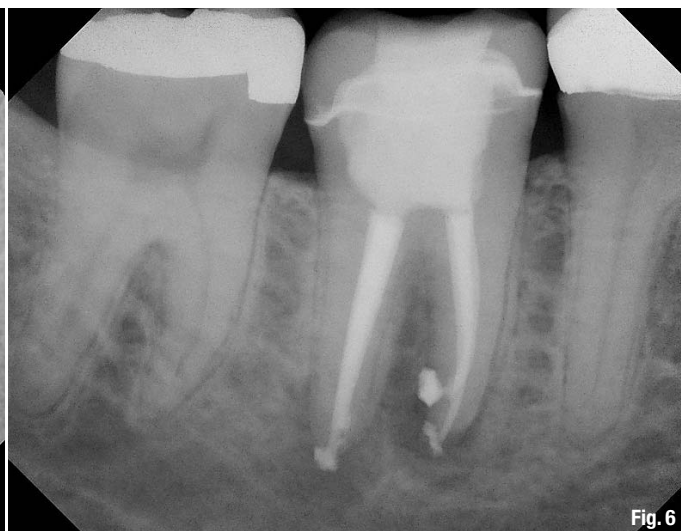
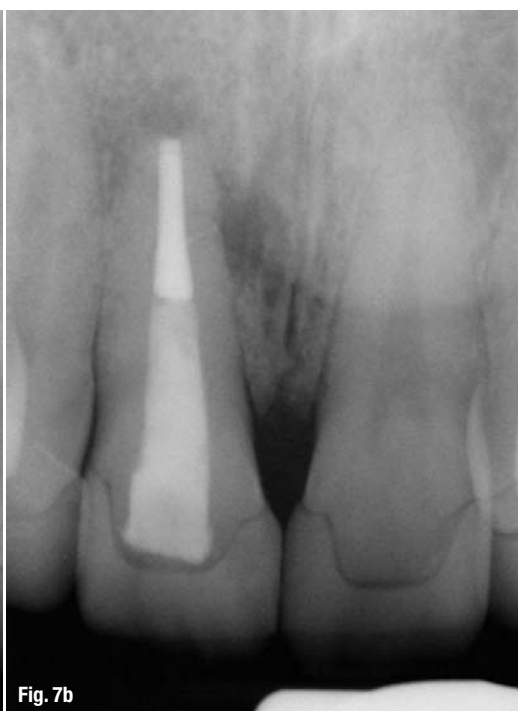
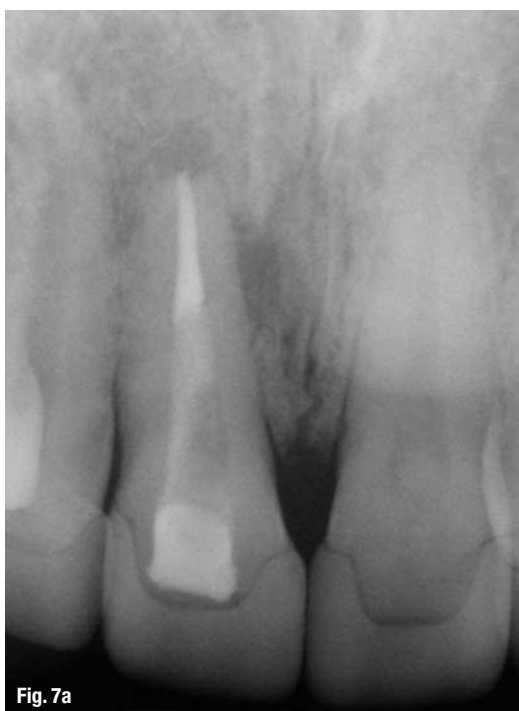

Fig. 6

**Figs. 7a–9b**\_Clinical cases re-treated using the concepts above with the Twisted File and RealSeal bonded obturation.



nal micro-leakage once their crowns are accessed. This micro-leakage appears in the form of odour, moisture, unset restoratives and voids, amongst other visual clues. Assuring that the post-endodontic result will be sealed correctly is best accomplished through removal of the crown, re-treatment procedures and the placement of a new coronal build-up. Owing to its ease of use and durability, Dr Mounce uses Maxcem (Kerr) for build-ups, a self-etching, self-adhesive composite cement.

#### *4) Removal of posts and coronal obstructions of all types including the build-up*

While a comprehensive discussion of post and obstruction removal is beyond the scope of this paper, it should be mentioned that the overriding principle in removal of all obstructions is to remove as little dentine as possible in order to minimise both perforation and the risk of vertical root fracture. As a result, the greater the extent to which procedures can be performed that both cools the tooth to prevent overheating during ultrasonic vibration and conserves tooth structure, the greater the probability of clinical success. The Ruddle Post Removal System is invaluable in this regard if used correctly. Post removal involves selecting the correct ultrasonic tips. The coronal access must be ideal before either the orifice is managed or the clinician progresses beyond the orifice. Attempting to remove obturation material or shape the orifice without attaining straight-line access is contraindicated.

#### *5) Removal of canal contents*

The coronal access must be ideal before either the orifice is managed or the clinician progresses beyond the orifice. Attempting to remove obturation material or shape the orifice without attaining straight-line access is contraindicated.

The removal of canal contents is passive, gentle and done in three waves (heat, mechanical and solvents). The Elements Obturation Unit (EOU) is an excellent source of heat for removing gutta-percha. The heat plugger of the EOU is used in the same motion as the System B down-pack. Approximately half of the gutta-percha can be removed with one to two down-pack motions per canal. Removal of gutta-percha with the heat tips also creates a space into which the RNT instruments can be placed to remove shreds of gutta-percha that remain along the walls. Both the removal of gutta-percha with heat and with RNT instruments is done dry.

These two successive steps allow the vast majority of gutta-percha to be removed and if performed correctly minimise the amount of solvent to be placed in the presence of hand files and time required to achieve patency. It is essential that the RNT files that are used to remove gutta-percha entered passively and gently, and used with an upward brush-stroke away from the furcation. Placing them apically with force into the mass of gutta-percha can easily lead to strip perforation, particularly if the existing dentinal wall next to the furcation is relatively thin from the start, owing to previous overzealous shaping.

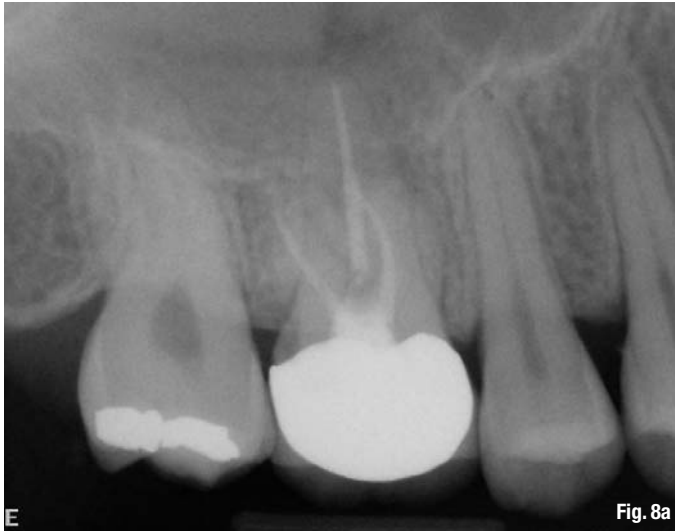

Fig. 8a

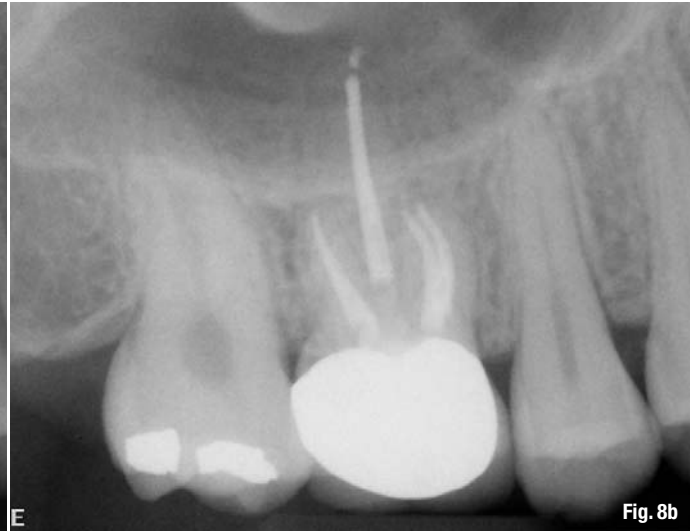

Fig. 8b

#### 6) *Assessment and repair of iatrogenic events if possible*

The two most common iatrogenic events encountered are canal transportations and separated instruments, commonly RNT files. The deeper the instrument fragments, the lesser the chance that they can be retrieved. This said, ideal access, crown removal, use of the SOM and creation of the ideal orifice size can all contribute towards fragment visualisation, even if the fragment is at or slightly beyond a curvature in the apical third of a root. In addition, it is optimal to use the thinnest ultrasonic tips possible that allow the clinician an optimal view of the fragment used in an anticlockwise motion to remove the dentine that binds the fragment. RNT fragments should not be directly vibrated (touched) by ultrasonic tips. Doing so will cause them to shatter. In addition to ultrasonics, there are many systems available that engage the fragment with either frictional retention or possible tube and glue options.

Instrument fragments that are entirely beyond the apical curvature and that cannot be bypassed are generally left in place and obturation is placed up to them. In the event of clinical failure with RNT fragments lodged, it may be required to follow NSER with root resection and retrofill.

#### 7) *Achievement and maintenance of apical patency*

Once the canal is evacuated of gutta-percha, the clinician will need to spend as much time as it takes to either achieve apical patency or determine that apical patency is unattainable. Fortunately, in many clinical failures, the apical third of a large number of roots has not been touched owing to an inaccurate determination of working length, as well as an inadequate cleaning and shaping. In any event, in the apical 3 to 4 mm of a root with #6, 8 and 10 hand K-files, the clinician should place one

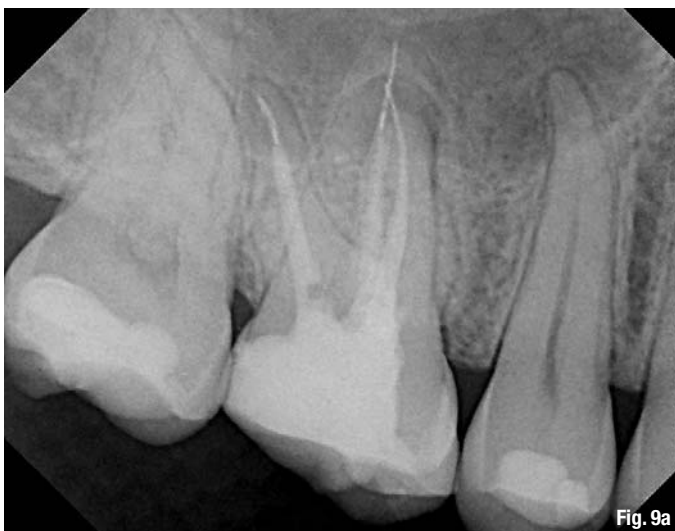

Fig. 9a

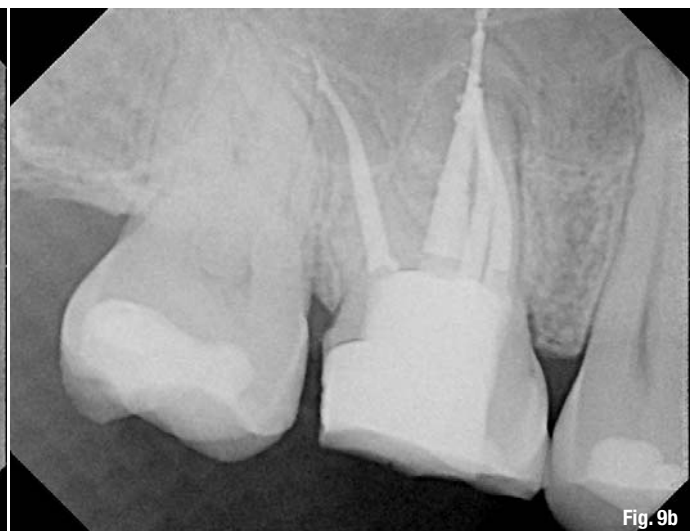


Fig. 9b



drop of chloroform into the canal at a time until the hand K-files just reach the MC. Once the estimated working length has been reached, the electronic apex locator can be used and the first determination of true working length can be obtained.

When and where to stop attempts at achieving patency are common clinical concerns. In essence, when is it time to fill to the depth gained in the canal in the absence of patency? If repeated attempts to gain patency have failed using pre-curved hand K-files of the appropriate length and diameter, particularly if the clinician is sure that he or she has removed all of the previous obturation materials, the canal should be cleaned and shaped to an optimal diameter despite the blockage and then obturated. This recommendation notwithstanding, an experienced clinician can often gain patency in cases in which an inexperienced one cannot. This difference in skill level is usually related to the amount of pressure used, the correct curvature of the hand K-file, the correct diameter of the hand K-file, adequate irrigation and clinical experience.

8) *Achievement of the optimal master apical diameter*

In the endodontic literature, the achievement of the correct apical diameter is correlated with

enhanced cleanliness. Such larger apical diameters provide greater irrigant flows and the removal of necrotic dentine up to the MC. It is a common finding in failed endodontic cases that both the apical diameter and master apical taper are too small. One way to determine the ideal master apical diameter is through gauging; alternatively, the clinician can simply instrument the canal to the desired master apical diameter, keeping in mind that non-vital teeth have higher failure rates because they are harder to cleanse relative to vital teeth (for which the emphasis is on asepsis rather than disinfection of an already infected canal).

9) *Obturation*

One benefit of creating larger apical diameters is the ease of cone fit and obturation, be it obturation with a master cone or obturator. Given that one of the most significant causes of clinical endodontic failure is the loss or lack of coronal seal, it makes intuitive sense to bond the obturation. In both *in vitro* and *in vivo* studies, RealSeal in the master cone and form of RealSeal 1 Bonded Obturator has been shown to resist the movement of bacteria in canals to a statistically significant degree relative to gutta-percha. In addition to placing a coronal seal in step 10 below, this provides an invaluable step in addressing one of the weaknesses of gutta-percha: it is a material that bonds neither to dentine nor to sealers, thus it is entirely dependent on the placement of a coronal seal for it to function clinically. Bonding obturation is simple; the clinician clears the smear layer with a liquid EDTA such as SmearClear and subsequently rinses with distilled water. After drying the canal, the RealSeal self-etching sealer is placed in the canal and obturation is achieved with either the aforementioned RealSeal master cones or RealSeal One Bonded Obturator.

10) *Placement of a coronal seal*

A number of clinical principles and steps have been addressed that can streamline endodontic re-treatment procedures conceptually and clinically. Emphasis has been placed on optimal visual and tactile control, removal of crowns before re-treatment, passive removal of previous obturation materials and obstructions, repair and revision of previous treatment, achievement and maintenance of apical patency, and optimisation of master apical diameter.

We welcome your feedback.           

<b>_about the authors</b>		<b>roots</b>
	<p><b>Dr Richard E. Mounce</b> lectures globally and is widely published. He has a private practice specialising in endodontics in Vancouver in Washington. Dr Mounce offers intensive customised endodontic single-day training programmes in his office for one or two doctors. For information, contact Dennis at +1 360 891 9111 or E-mail <a href="mailto:RichardMounce@MounceEndo.com">RichardMounce@MounceEndo.com</a>.</p> <p>Dr Mounce is also the author of the non-fiction book <i>Dead Stuck</i>, "one man's stories of adventure, parenting, and marriage told without heaping platitudes of political correctness", by Pacific Sky Publishing (<a href="http://www.deadstuck.com">www.deadstuck.com</a>).</p>	
	<p><b>Dr Gary D. Glassman</b> has authored numerous publications and is on the staff in the Faculty of Dentistry in the graduate Department of Endodontics at the University of Toronto. A renowned international lecturer on endodontics, Dr Glassman has presented at major dental conferences around the world. He is an endodontic editor for Oral Health and maintains a private practice in Toronto, Ontario. He can be reached through his website: <a href="http://www.rootcanals.ca">www.rootcanals.ca</a>.</p>	

# EndoInnovations III

SybronEndo offers you advanced technology for safer, more efficient procedures.

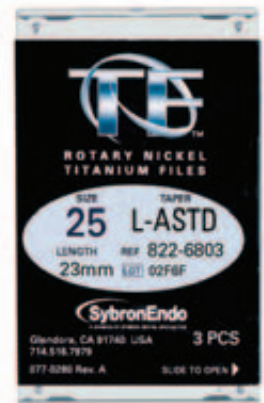

## REALSEAL 1 Warm-Bonded Obturator

All the components of RealSeal 1™ – sealer, filler and core – are resin-based materials that chemically bond with each other to form a *superior seal*. As an added benefit, this system's core is engineered to be easily seen on a radiograph.

## TF – Faster, Safer, Stronger

TF™ is twisted, not ground – unlike other nickel titanium files – making it more durable. Endodontic files are made by grinding the flutes, weakening the metal's molecular structure which can lead to separation. Our unique manufacturing process produces a file with optimal sharpness, strength and flexibility. TF allows you to work in difficult situations faster, safer and with a stronger file.



**SybronEndoEurope** | *Safe files, superior fills.*

A DIVISION OF SYBRON DENTAL SPECIALTIES

SybronEndo Europe, Basicweg 20, 3821 BR Amersfoort, The Netherlands  
tel: +31 33 4536 159 fax: +31 33 4536 153 email: Endo@SybronDental.com

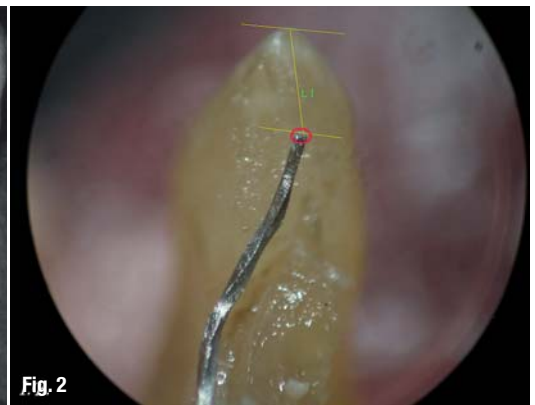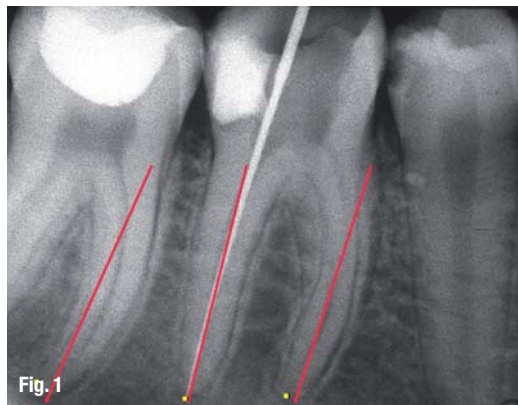
SybronEndo, 1717 West Collins Avenue, Orange, CA 92867  
800.346.ENDO 714.516.7979 Fax 714.516.7911 SybronEndo.com

# Determining working length, or how to locate the apical terminus (Part I)

**Authors**\_Prof Vladimir Ivanovic & Dr Katarina Beljic-Ivanovic, Serbia

**Fig. 1**\_The apical foramen almost never coincides with the principal axis of the root.

**Fig. 2**\_The anatomical foramen is not always located at the anatomical apex.

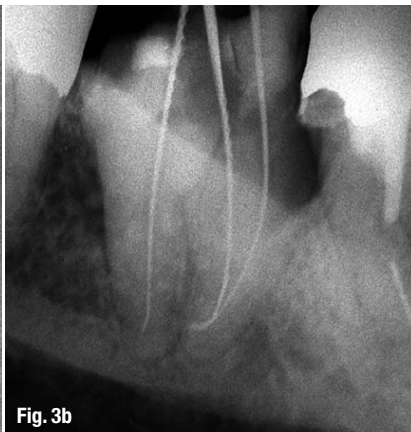
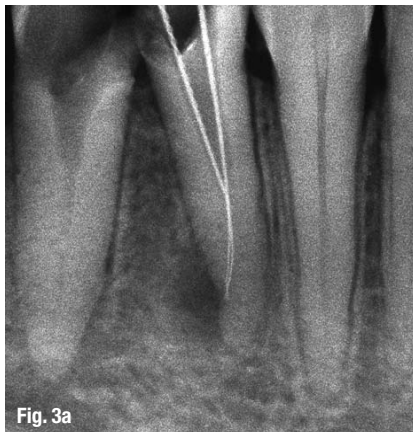

## Introduction

**Determining working length (WL)** is one of the crucial aspects in successful endodontic treatment. However, major controversy exists regarding where to locate the apical end point of the root canal preparation and obturation. The ongoing debate centres on different concepts of shaping and cleaning the apical portion of the root canal, and whether to complete manipulation within the dentinal walls to the physiologic foramen or to extend into the cemental cone close to the anatomical foramen.

**Figs. 3a & b**\_The anatomical foramen is not located at the radiographic apex, and canal instruments exit through the foramen in various angulations.

Several colleagues contributed their research results to this article. They are Prof Mirjana Vujaskovic, Dr Katarina Beljic-Ivanovic, Dr Jugoslav Ilic and Dr



Ivana Bosnjak from the Faculty of Dental Medicine at the University of Belgrade; Prof Joshua Moshonov from the Hebrew University of Jerusalem, who incorporated parts of his own research and provided laboratory testing; Dr Julian Webber, who supplied materials and gave useful advice; and Prof Paul Dummer from Cardiff University, who contributed valuable suggestions and instructions for our *in vivo* study.

This article is based on my recent lecture at the European Society of Endodontology (ESE) congress in Edinburgh for which I consulted numerous papers and books. I wish to point out a few that have directly influenced my own standpoints and work over the years and finally directed much of this article through their philosophy and conception:

- \_Ricucci D, Langeland K: Apical Limit of Root Canal Instrumentation and Obturation, Part 1: Literature Review. *International Endodontic Journal* 1998; 31(6):384-393.
- \_Ricucci D, Langeland K: Apical Limit of Root Canal Instrumentation and Obturation, Part 2: A histological study. *International Endodontic Journal* 1998; 31(6):384-409.
- \_Wu M, Wesselink P, Walton R: Apical Terminus Location of Root Canal Treatment Procedures. *Oral Surgery, Oral Medicine, Oral Pathology, Oral Radiology and Endodontics* 2000; 89(1):99-103.
- \_Fava LRG, Siqueira JF: Considerations in Working Length Determination. *Endodontic Practice* 2000; 3(5):22-33.



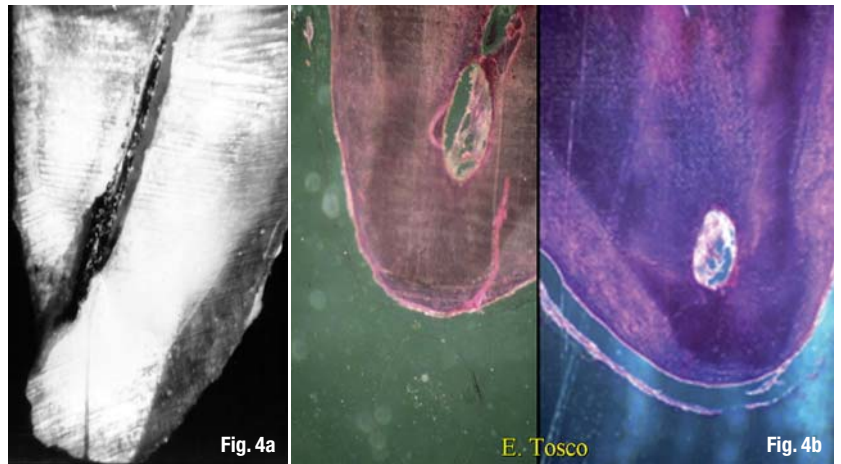
Nekoofar MH, Ghandi MM, Hayes SJ, Dummer PM: The Fundamental Operating Principles of Electronic Root Canal Length Measurement Devices. *International Endodontic Journal* 2006; 39(8):595–609.  
 Mounce R: Determination of True Working Length. *Endodontic Practice* 2007; 10(1):18–22.

**Decision-making factors**

Each time we need to determine WL we are faced with various challenges and factors influencing our decision of *where, when, why* and *how* to locate the apical terminus. For one, there are factors dictated by nature that lie beyond our influence: the anatomy of the root canal system, the morphology of the apical region and its variations, and the pathological state of the pulp and periodontal tissues. Additionally, there are factors that we can and should control, namely our knowledge, skills and equipment. Our daily practice brings us experience and moulds our preferences, however, after years of practising, certain prejudices can develop that in some cases can lead to errors.

Looking at root canal anatomy, the first fact is that root canals always deviate from the long axis of their roots and the apical foramen almost never coincides with the principal axis of the root (Fig. 1). Anatomical details and variations of the apical region are central to determining WL. The anatomical foramen is seldom (in less than 50 % of cases) located at the anatomical apex. In other words, the anatomical foramen is not always located at the anatomical apex (Fig. 2), which has been proven in numerous studies that have presented figures of 50, 80, 92 and up to 98 % of cases with the anatomical foramen 0.2 to 3.8 mm short of the anatomical apex.

Therefore, it is a fact that the anatomical foramen is neither at the anatomical nor at the radiographic apex. Consequently, the instrument placed into the root canal exits through the apical foramen at various angulations from 10° up to 90° (Figs. 3a & b). In other words, root canals deviate and exit mesially and



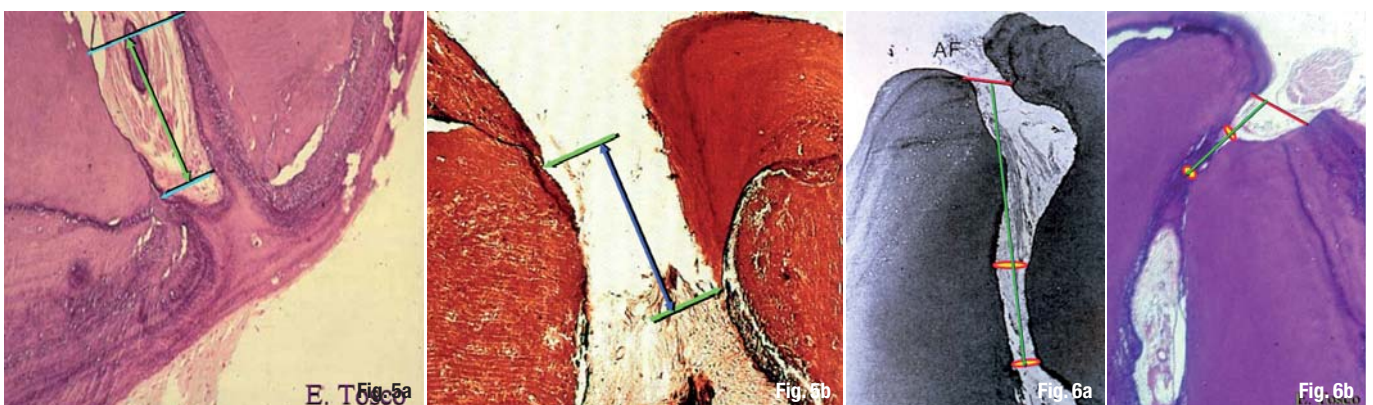
distally, something that can easily be revealed on a clinical radiograph. Unfortunately, canals also deviate buccally and lingually. According to the literature, this is the case in 20 to 55 % of teeth, depending on their morphological type (Figs. 4a & b). Additionally, a majority of root apices have multiple foramina, causing apical delta and difficulty in locating the endodontic terminus.

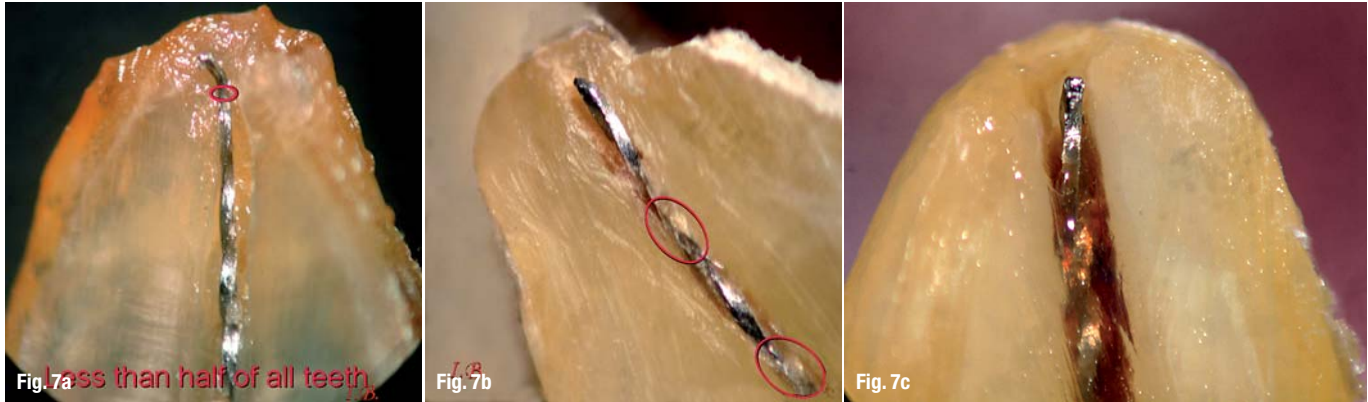
**Figs. 4a & b** Root canals deviate buccally and lingually in 20–55 % of all cases.

The histology of the apical cementum and cemento-dentinal junction (CDJ) and their variations is morphologically intriguing. In only 5 % of teeth, cementum extends at the same level of two opposite walls of the same canal. The extent of those layers of cementum on different walls could vary from 0.5 to 3.0 mm into the root canal, and variations of the CDJ in each individual tooth range from 200 to 800 µm (Figs. 5a & b). The CDJ is seldom well defined and sometimes it is very difficult to differentiate dentine from cementum. Therefore, most of the eminent authors consider the CDJ an inconsistent feature, even histologically.

Throughout the entire life and function of a tooth, the apex is constantly remodelled by cementum deposition and resorption. This remodelling process leads to illusory dislocation of the apical foramen but actually increases the length of a root. Thus, even the CDJ is

**Figs. 5a & b** The depth of the layers of cementum on different walls of the root canal varies from 0.5 to 3 mm.  
**Figs. 6a & b** The apical constriction is always located coronally to the CDJ.





**Figs. 7a-c** Less than half of teeth have single constriction (a) and the remainder have either multiple (b) or no constriction at all (c).

considered and recommended to be the ideal physiological apical limit of the WL. However, since it is impossible to determine it clinically, many refer to this as a myth.

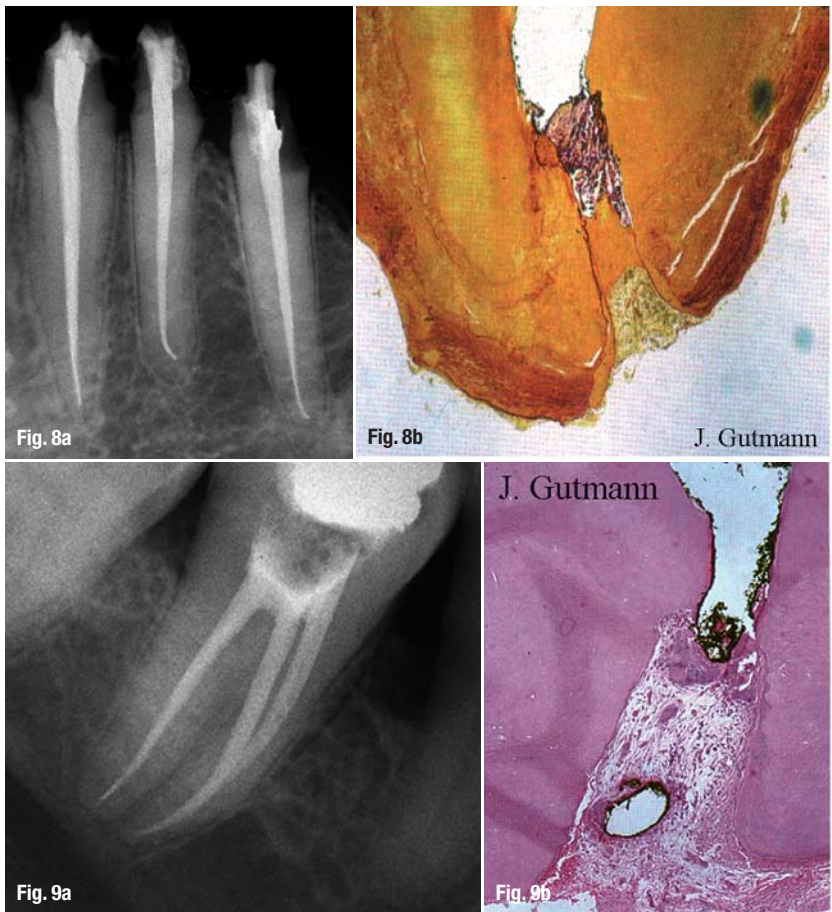
**Figs. 8a & b** The less tissue to heal, the better the cure: X-ray control after 12 months (a); healing with cemental bridge (b).

The next anatomical challenge for the practitioner is the apical constriction. It has been proven that the CDJ and the apical constriction are two separate points and almost never coincide. The apical constriction is always located coronally to the CDJ (Figs. 6a & b). While the apical foramen is easily visualised in root canals microscopically, no well-defined apical constriction has been clearly confirmed. Less than 50 % of teeth display the points that could be regarded as the apical constriction.

**Figs. 9a & b** The apical terminus at the physiological foramen: X-ray after 12 months (a); optimal healing (b).<sup>16</sup>

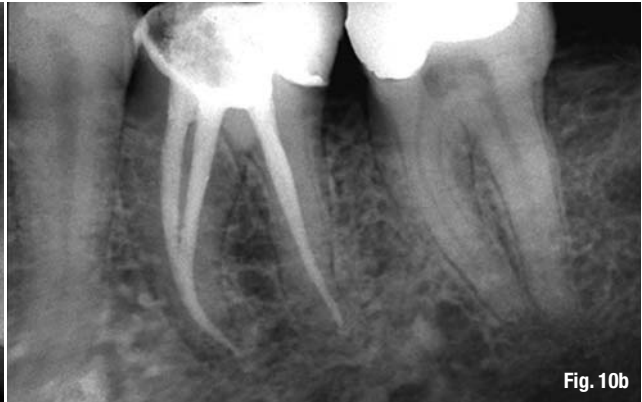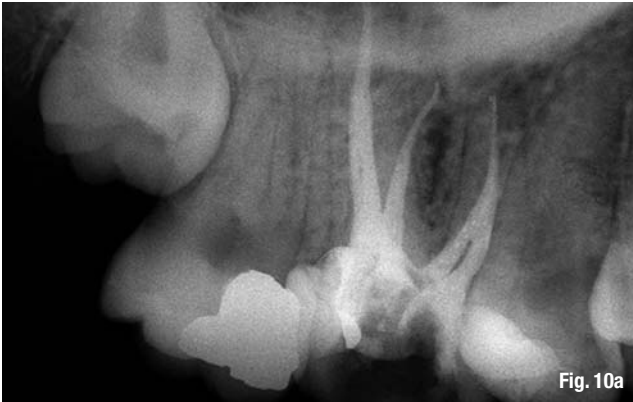Several authors have pointed out and classified variations in the topography and position of the apical constriction. Unfortunately, this knowledge cannot be consistently applied as less than half of the teeth have single constriction; the remainder have either multiple or no constriction at all (Figs. 7a-c). The distance from the apical constriction to the apical foramen ranges from 0.07 to 1.76 mm. Consequently, the distance from the apical constriction to the radiographic apex ranges from 0.75 to 4 mm.

The following statements properly summarise this section on anatomy. Determining the apical foramen as the reference point gives more consistency than the apical constriction or radiographic apex.<sup>7</sup> The use of the major foramen is more reproducible for accuracy studies.<sup>8</sup> We can therefore conclude that owing to numerous inconsistencies, variations and 'ifs' with regard to the apical constriction and CDJ and their interrelationship, the apical foramen may be a more useful and reliable apical reference point in determining WL.



The pathological and microbiological status of the dental pulp and peri-apical tissues is an extremely important decision-making factor for where, when, why and how to locate the apical terminus. In cases of vital and healthy or irreversibly inflamed pulp, free of bacteria or bacteria limited to the pulp chamber, there are two standpoints. One firmly suggests that pulpectomy is the treatment of choice in cases in which the apical terminus is located at the physiological foramen (Figs. 8a & b). We utilise this method, which is widely accepted amongst a majority of dental schools and practitioners in Europe, in almost each case, in following the basic biological and medical principle for any wound: the less tissue to heal, the better the cure.<sup>1</sup> For the same pulp conditions, the second standpoint advocates partial pulpectomy in cases in which the apical terminus is located short of the constriction at a variable distance that can range from 1.5 to 10.0 mm short of the apex, leaving a pulp stump. Dressed and sealed appropriately with bio-compatible material, its vitality is preserved, enabling the pulp to continue with what it does the best: forming mineralised dentine tissue.



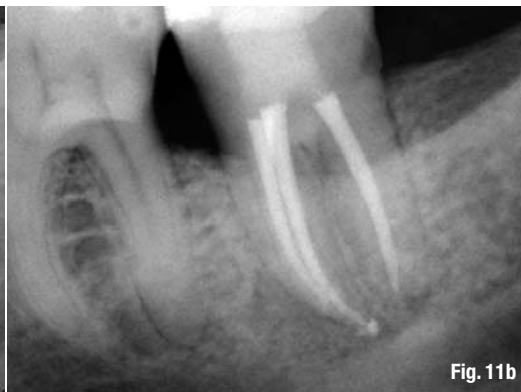
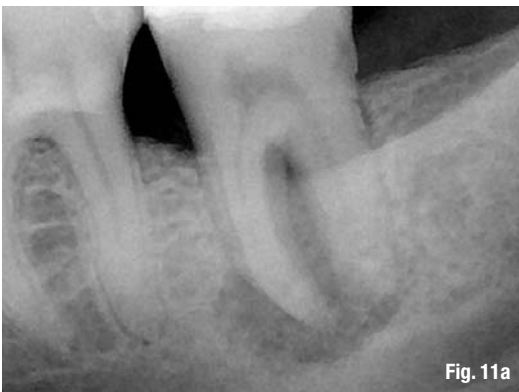
Cases with necrotic and/or infected pulp are much more complicated, even when there is no peri-apical lesion. Some colleagues advocate that the apical terminus be located at the physiological foramen. This location preserves integrity of the apical morphology, and neither violates the apical foramen nor challenges the periodontal ligament, thus enabling optimal healing (Figs. 9a & b). Other colleagues suggest that the apical terminus be located at the anatomical foramen, sometimes identified as the apex, or even at the radiographic apex.<sup>9</sup> This approach adopts the concept of apical patency or the apical clearing technique (Figs. 10a & b).

In cases with apical periodontitis there is even more controversy about the location of the apical terminus. A conservative approach insists that all manipulations end at the physiological foramen, since any over-instrumentation or overfilling of this end point leads to either clinical or histological failure. Another approach, supported by a group of prominent academics and experienced practitioners, advocates that preparation and obturation in such cases always be terminated at the anatomical or radiological foramen, the radiographic apex of the tooth. Figures 11a and b demonstrate the extent of success in treatment when the end points of all intra-canal manipulations are located at the anatomical foramen, irrespective of the

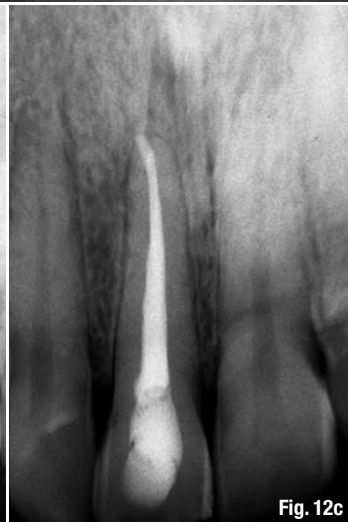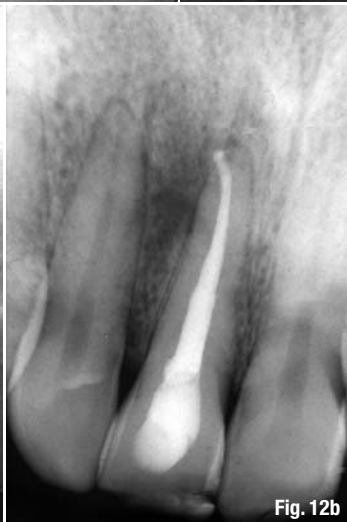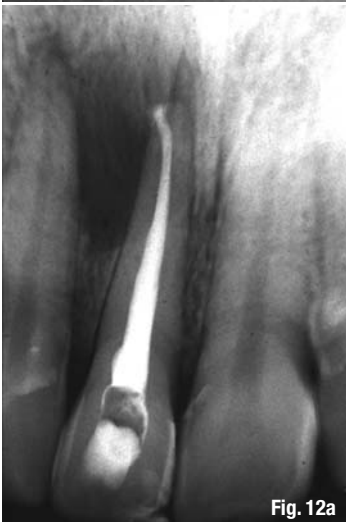**Fig. 10a**\_The apical terminus at the anatomical-radiographic apex with excellent outcome: X-ray control after 2 years.

**Fig. 10b**\_The canals were successfully obturated to the anatomical apex.



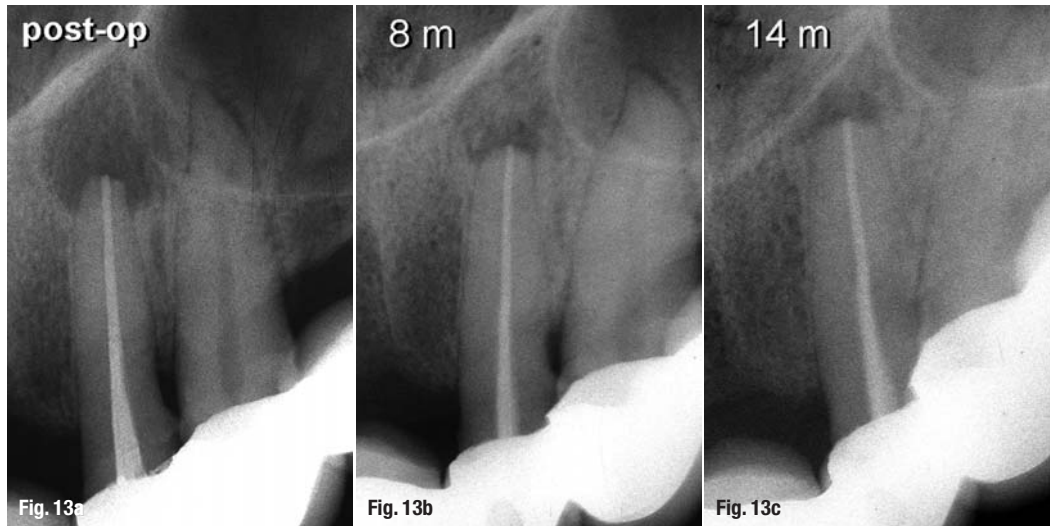
**Figs. 11a & b**\_In cases of apical periodontitis, the endodontic terminus should preferably be at the end of the root canal, near to the anatomical foramen: Post-op image (a; courtesy Dr Julian Webber); control after 2 years (b).

**Figs. 12a-c**\_Case with the end-point at the anatomical foramen/radiographic apex: Post-op image (a); after 6 months (b); after 2 years (c).





**Figs. 13 a–c**\_Pathological inflammatory root resorption: Post-op image (a); after 8 months (b); after 14 months (c).



type of apical periodontitis. If possible, the goal of orthograde treatment is to avoid peri-radicular surgery (Figs. 12a–c).

In cases of peri-apical pathosis associated with pathological inflammatory apical root resorption it is particularly difficult to decide where to locate and how to determine the endodontic terminus. Controversial opinions from the literature suggest that it should be either 0.5 mm short or 1.0 mm long of the apex. As there is no accurate technique for such cases, the situation becomes even more frustrating for the practitioner (Figs. 13a–c).

In summary, the root canal should be prepared and obturated to a point as close to the apical foramen as possible yet still within sound tooth structure.<sup>10</sup> The objective of determining the WL is to enable the root canal to be prepared as close to the apical constriction as possible.<sup>11</sup>

### Methods for determining working length

The following methods can be used to determine WL:

1. predetermined 'normal' tooth length (this method is not detailed here, owing to its inaccuracy);

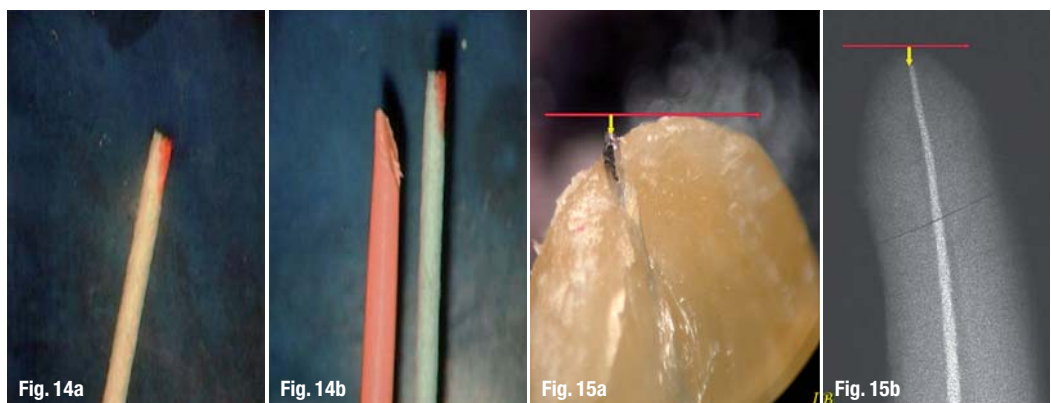
2. patient pain response;
3. tactile sensation of a therapist;
4. paper point technique;
5. radiographic method; and
6. electronic locators.

A patient's response to pain is probably the oldest method used. However, owing to several interfering factors, it is very unreliable. For one, remnants of vital pulp tissue within the apical portion can cause pain, leading to shorter WL. Pressure of the instrument tip transmitted via tissue debris to the viable periodontal ligament can also lead to shorter WL. Also, destruction of peri-apical tissues causes no sensation at all if an instrument is protruded beyond the foramen even for several millimetres, resulting in longer WL. This technique is also extremely subjective owing to the individual pain threshold of each patient. Moreover, it is impossible to apply this method when local anaesthesia is performed. There is a lack of evidence in the literature regarding whether this method is still in use; is this method dental history?

Tactile sensation is a very subjective technique too. Its limitations are due to morphological irregularities, tooth type and age (generally leading to shorter length values), and pathological apical resorption or wide

**Fig. 14a&b**\_Customising master gutta-percha cone.

**Figs. 15a & b**\_The radiograph shows that the instrument is short of the radiographic apex (a), but in reality the instrument tip is far beyond the anatomical foramen (b).



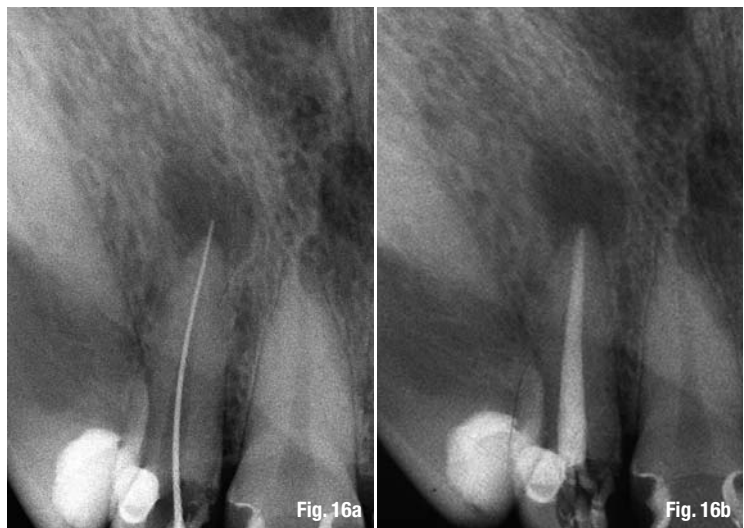foramen in immature teeth, which leads to longer WL. The literature offers little information on this method; nevertheless, the tactile sensation technique is still advocated as very useful in the determination of apical constriction.

In 1986, Dr Mirjana Vujaskovic and her mentor Prof Miroslav Pajic conducted extensive clinical research on the accuracy of the tactile sensation method controlled radiographically in relation to two reference points: 0.5 mm from the radiographic apex in patients younger than 25 and 1.0 mm in patients older than 25. The method was accurate in only 19 % of the cases, but accuracy increased to 42 % when tolerance was extended to  $\pm 0.5$  mm. Furthermore, the researchers found significant under- and overestimations—up to 4.5 mm before and after reference points. The literature presents accuracy in a variable range of 30 to 44 % and 30 to 60 %, with wide and random distribution of measured values. An important finding for our daily practice was that pre-flaring helps in locating the apical constriction, increasing accuracy from 32 to 75 %.

The paper point technique (PPT) is claimed to be the most accurate method by which to determine both WL to the very end of the canal and minimal apical foramen diameter in three dimensions. It allows the practitioner to see the cavo-surface of the apical foramen with precision in 1/4 mm. Logically, the apical patency technique is mandatory for this method. Additionally, this technique enables customisation of master gutta-percha cone three-dimensionally based on the information gained from the paper point (Fig. 14).

Even though it is claimed to be the most accurate method in determining WL, neither scientific nor clinical evidence is available in the literature. In spite of being advocated by many endodontic experts, PPT lacks to the ability to determine morphological details and pathological states within the root canal and in the peri-apical tissues. However, it is a fairly simple method and can be helpful in establishing and confirming final WL since it is non-aggressive and therefore does not injure periodontal tissues or endanger apical wound healing.

The radiographic method (RM) is probably still the most widely used method for determining WL. It reveals many important details and is useful in every endodontic procedure. However, it also has limitations and often provides an illusory image. There are three matters to be noted when determining WL with RM. First, it is mandatory to produce preoperative, diagnostically accurate radiographs. Second, the radiographic apex and the anatomical apex do not (always) coincide, but in most textbooks and articles these terms are used interchangeably. Third, the apical foramen cannot (always) be visualised on a radiograph, which is a significant handicap.



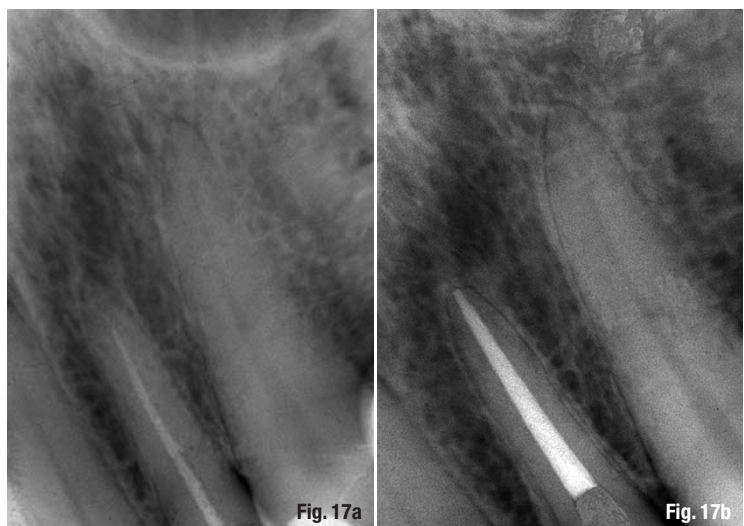In 1986, Dr Vujaskovic, Prof Pajic and I conducted a long-term clinical study on the accuracy of RM in determining WL. The same methodology was applied as described for the tactile sensation method. The RM was accurate in 51 % of cases, strictly respecting reference points on a radiograph (0.5 mm from the radiographic apex in patients younger than 25 and 1.0 mm in patients older than 25).

When the range of tolerance was extended to a clinically acceptable  $\pm 0.5$  mm from the reference points, accuracy increased to 68 %. It further increased to 88 % when tolerance was extended to  $\pm 1.0$  mm. Under- and overestimations were not over 2 mm, compared to 4.5 mm with the tactile sensation method. Similar findings were confirmed in other studies.

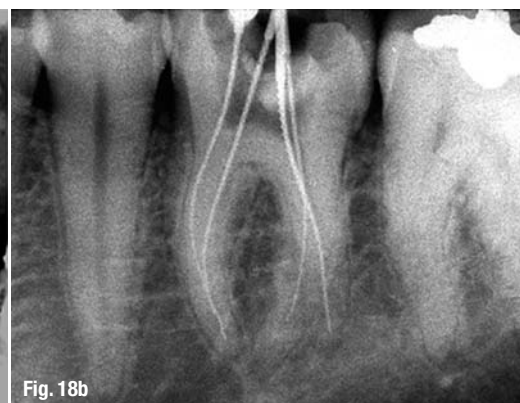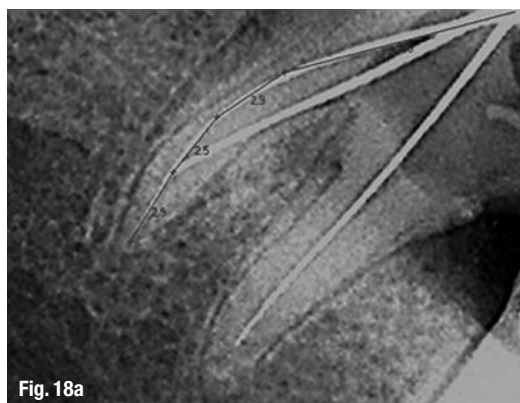
Figures 15a and b show that the measuring file is longer than it appears radiographically. When the instrument is short of the radiographic apex, it is beyond the apical foramen in 43 % of all cases. If the apical constriction is 0.5 mm before the apex, then 66 % of all

**Figs. 16a & b** Clinical situation with instrument beyond the apex (a), which was later corrected by obturating the canal approximately 0.8 mm short of the radiographic apex (b).

**Figs. 17a & b** Correction of a treatment mistake in determining WL (a) and the more or less successful end result (b).



**Figs. 18a & b**\_RVG image of the lower molar (a) and conventional radiograph (b).



measurements are beyond this.<sup>12</sup> When the file is short of the radiographic apex, it is actually closer to the apical foramen than it appears radiographically.<sup>13</sup> Radiographic WL ending 0 to 2 mm short of the radiographic apex provides a basis for unintentional over-instrumentation, more often than expected.<sup>14</sup> Figures 16a to 17b demonstrate the way mistakes in determining WL can be corrected to finalise the case successfully.

The RM depends on a few different factors, namely the surrounding structures, the angulations of the cone-beam, the visibility of the measuring file influenced by its size, and the film exposing and developing speed. In summary, radiographs are indispensable for calculating but not for determining WL and the endodontic terminus.<sup>15</sup>

The most prominent advantage of digital radiography (DR) is the ability to quantify distances with exact figures. Thanks to software programmes, images can


be varied in size and contrast. But there are limitations if small size canal instruments with fine file tips, for example #8 or 10, are used. They display low contrast in their structures and affect visualisation and precision of the measuring process and hence the results. Therefore, sizes #15 and bigger are preferable.

Even though there are many advantages and benefits in the use of DR, many reports emphasise that complete image quality is better with conventional radiographs (Figs. 18a & b). When conventional and DR radiographs were used for WL determination and compared to electronic locators, it was demonstrated that electronic foramen locators are superior because the RM generally gives long measurements with over-instrumentation.

*Editorial note: Part II of this article will be published in roots 1/2010. A complete list of references is available from the publisher.*

**\_about the author**

**roots**




**Prof Vladimir Ivanovic** graduated from the Faculty of Dentistry at the University of Belgrade in 1976. He obtained a M.Dent.Sc and Ph.D. with specialisation in Oral and Dental Pathology and Endodontology. He was appointed Professor in Restorative Odontology and Endodontics in 1998 at the Faculty of Dental Medicine and served as a Vice-Dean for postgraduate and undergraduate studies. He has also chaired the School Board for Dental Pathology.

Prof Ivanovic conducts research at the University of Belgrade and Edinburgh Dental Institute. His main interests are maintaining vital pulp, resin-based composites and adhesive systems, and endodontology. He has attended numerous international endodontic seminars and courses to further his knowledge and skills. He has delivered over 100 lectures both nationally and internationally, published over sixty articles in national and international journals, and chapters in four dental textbooks.

He is founder and President of the Serbian Endodontic Society and has been a member of the ESE since 1989. He is also country representative for the ESE General Assembly, member of the International Association for Dental Research/Continental European Division and school representative for the Association for Dental Education in Europe. He has organised over a dozen endodontic meetings in Belgrade with internationally recognised speakers. Prof Ivanovic can be contacted at [vladaivanovic@hotmail.com](mailto:vladaivanovic@hotmail.com).



# FDI Annual World Dental Congress 2-5 September 2010 Salvador da Bahia, Brazil



[congress@fdiworldental.org](mailto:congress@fdiworldental.org)  
[www.fdiworldental.org](http://www.fdiworldental.org)





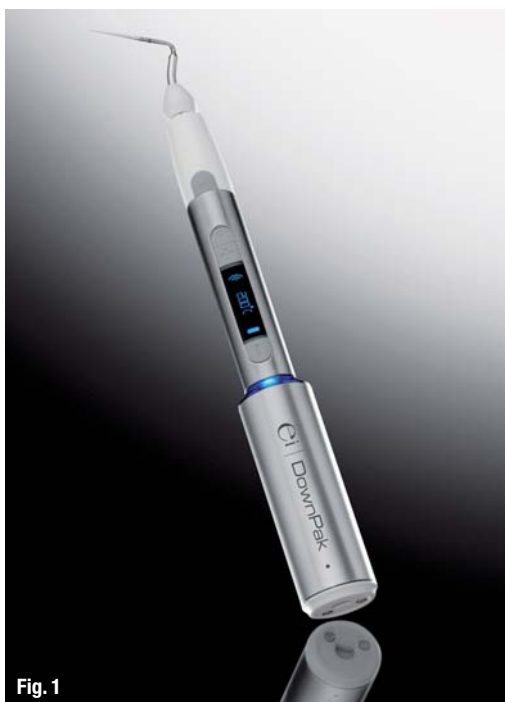# The DownPak Device: obturation with heat and vibration

**Authors**\_Dr Stephen Cohen, Dr Louis H. Berman & Dr Gabriela Martin, USA

**Successful endodontic treatment** depends on a proper diagnosis, a favourable prognosis assessment and proper cleaning, disinfection, shaping, and obturation of the canals and their associated radicular spaces. As countless studies have demonstrated that it may not be possible to disinfect and clean all canal ramifications thoroughly, obturation makes it possible to seal the roots internally to prevent leakage coronally or from peri-radicular tissues.<sup>1</sup> Presently, there is no ideal obturation material. Gutta-percha remains the primary obturation material in use today, although other obturation filling materials have gained some recent attention, including Resilon (Pentron Clinical Technologies) and ProRoot MTA (DENTSPLY Tulsa Dental). All of these materials have some limitation in their ability to seal the main and accessory canals three-dimensionally. Nevertheless, it is important to obtain an homogenous mass

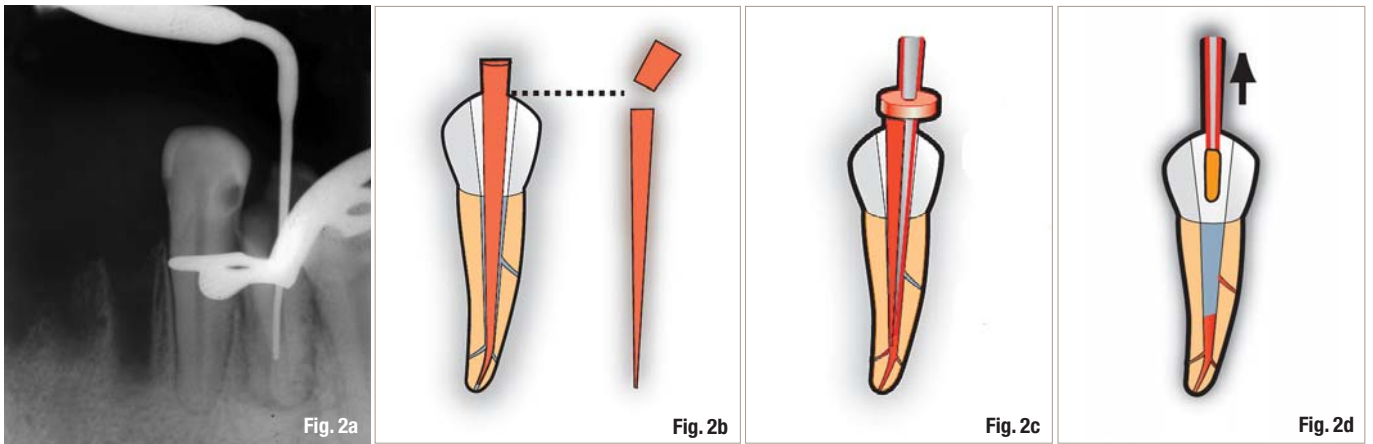
of obturation material that will conform well to the interior walls of the canals when plasticised. Gutta-percha and Resilon are the most suitable materials. Heated gutta-percha changes its crystalline form from a beta phase, which is relatively solid, to an alpha phase, in which it becomes a more plasticised and sticky material that adheres better to the canal walls.<sup>2</sup> In its alpha phase, gutta-percha can be compacted vertically and laterally, by mechanical or rotary instruments. Resilon, a polyester- and methacrylate-based resin obturation material, has good flow when warmed. One study concludes that Resilon bonds to etched canal walls when heated, which may provide a tighter seal of the canal system while also strengthening the root system.<sup>3</sup>

Several techniques have been used to facilitate the placement of gutta-percha, including cold and warm lateral compaction, warm vertical compaction, injectable systems, carrier-based obturation and thermomechanical compaction. All of these techniques require various degrees of clinical proficiency and, depending on the canal system that is to be obturated, certain techniques may be more appropriate than others. For example, when a tooth has a large internal resorption defect in the canal, cold lateral compaction may not adequately fill all of the canal space, whereas vertically compacting or injecting warm gutta-percha may provide a more 3-D obturation. Considering the multitude of canal ramifications in any given tooth, it may be impossible to fill these spaces three-dimensionally unless the gutta-percha is heated. *In vitro* studies have demonstrated that cold lateral compaction of gutta-percha is approximately 25 per cent less dense than warm lateral compaction; additionally, it has been shown that gutta-percha fills significantly more canal space when warm vertical compaction is used.<sup>4-6</sup> Even after heating and compacting gutta-percha or Resilon into a canal system, there still may be voids in the obturation. To min-



**Fig. 1**

**Fig. 1**\_The DownPak is a self-contained device that transfers heat and vibration to a spreader or plugger tip. All of the controls are easily accessible on the handle.



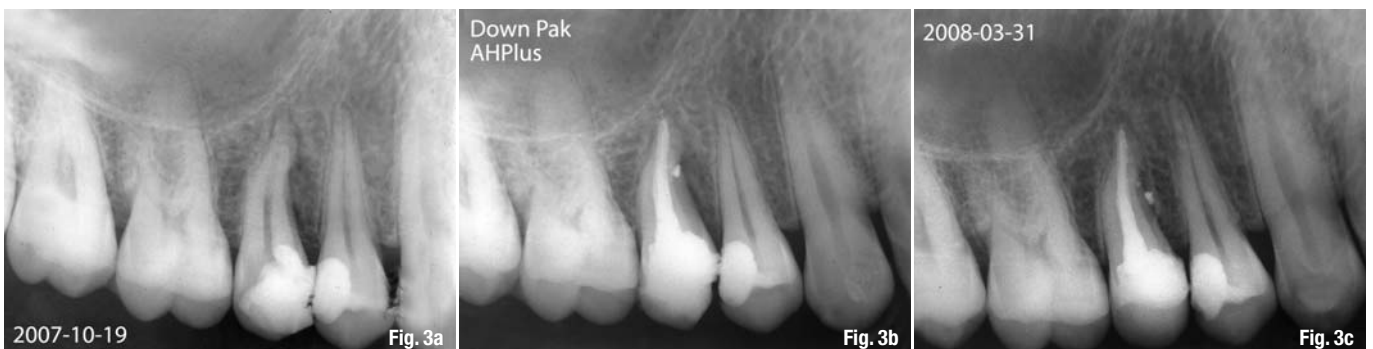
imise this problem, Dr Howard Martin developed a self-contained electronically heated spreader for warming and laterally compacting gutta-percha (Endotec, Medidenta International). This device significantly enhanced the compaction of gutta-percha.<sup>7</sup> A 1993 study found that the Endotec device increased the density of the obturation by approximately 15 per cent.<sup>8</sup> Although this obturation device is no longer commercially available, it demonstrated that electrically induced heat on a spreader or plugger tip is an efficient way of delivering heat to gutta-percha, producing a denser obturation as a result. Subsequently designed obturation heating systems, the Touch 'n Heat (SybronEndo) and the System B (SybronEndo), expanded on this concept and were found to be successful for creating a more homogenous obturation of gutta-percha.<sup>9</sup> The EndoTwin (MDCL) is another such device that has been used throughout Europe for many years. Like the Endotec, the EndoTwin is a hand-held, self-contained, heat-carrying instrument with spreader and plugger tips. Sonic vibration was also incorporated into this device to augment the compaction and obturation effectiveness of EndoTwin's heated tips. Several studies have reported that by simultaneously combining the efficacy of heating the obturating material with sonic vibration to help the plasticised gutta-percha flow, the average percentage of gutta-percha in the canal space could increase significantly, especially in the more narrowly tapered canals.<sup>10-12</sup> In early 2007, efforts to improve

and refine the EndoTwin led to the introduction of the DownPak (Hu-Friedy). The DownPak enables the clinician to employ variable temperature settings and to turn the vibration feature on or off as desired.<sup>13</sup> The variable temperature settings become useful when different obturation materials are used. For example, Resilon softens at a lower temperature than gutta-percha. The DownPak is cordless and lightweight, with an ergonomically balanced hand-held grasp; all of the switches and adjustments are easily accessible on the handle (Fig. 1).

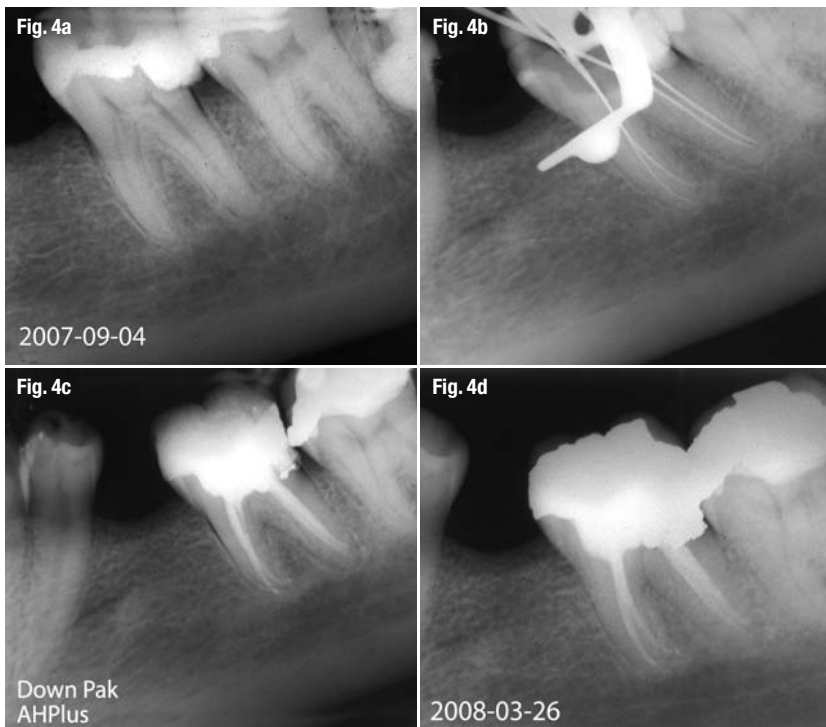
### Technique

The use of the DownPak is similar to a combined vertical and lateral compaction of gutta-percha, so the clinician familiar with these techniques should find the device very user-friendly. First, the appropriate DownPak tip is selected so that it reaches a depth in the canal that is 3 to 5 mm from the apical terminus. A silicone stop can be adjusted on the tip as a reference point for this measurement (Fig. 2a). Next, the canal walls are coated with sealer and a master gutta-percha (or Resilon) cone is placed in the canal to working length. Using the tip of the heated DownPak, excess coronal gutta-percha is removed to the level of the orifice (Fig. 2b). With a sustained push, the DownPak tip is introduced into the canal with the heat and vibration modes activated. The tip is then extended down the canal space to the predetermined binding point, 3 to 5 mm from

**Fig. 2a** The appropriate DownPak tip is selected to extend 3 to 5 mm from the apical terminus. A silicone stop on the tip is adjusted as a reference point.  
**Fig. 2b** Canal walls are coated with sealer and a master gutta-percha (or Resilon) cone is placed in the canal to working length. Using the tip of the heated DownPak, excess coronal gutta-percha is removed to the level of the orifice.  
**Fig. 2c** The DownPak tip is introduced into the canal to the predetermined binding point with the heat and vibration modes activated for two to four seconds. The tip is rotated rapidly 180 degrees clockwise/counterclockwise two or three times and heated for two seconds.  
**Fig. 2d** The tip is removed quickly along with any excess gutta-percha. Remaining voids are sealed coronally with additional accessory cones by applying vertical compaction as described above.  
**Fig. 3a** Pre-op radiograph of maxillary right second pre-molar: note apical dilacerations and peri-radicular bone loss.  
**Fig. 3b** Immediately after obturation: note the lack of voids and the lateral canal filled on the mesial.  
**Fig. 3c** Five months post-endodontic treatment: note the re-mineralisation in the area of the peri-radicular bone.










the apical terminus (Fig. 2c). The tip is rotated rapidly 180 degrees clockwise/counterclockwise two or three times and heated for two to four seconds; at this time, the tip is removed quickly along with any excess gutta-percha (Fig. 2d). Any remaining voids can be sealed coronally with additional accessory cones by applying vertical compaction as described above. Although radiographs are only 2-D, the clinical cases depicted in Figures 3 and 4 provide an indication of the clinical effectiveness of obturating canals using the DownPak.

### Summary

The literature and this article have documented the benefits to patients when clinicians employ plasticised gutta-percha and vertical compaction combined with vibration. The advent of cordless devices like the DownPak makes it easier for the clinician to provide a 3-D obturation more effectively.

*Editorial note: A complete list of references is available from the publisher.*

**Fig. 4a**\_Pre-op radiograph of mandibular left first molar.  
**Fig. 4b**\_Working length radiograph depicting four canals, each with a separate apical terminus.  
**Fig. 4c**\_Immediately after obturation.  
**Fig. 4d**\_Six months post-endodontic treatment: note favourable peri-radicular bone healing.

_about the authors		roots
	<p><b>Dr Stephen Cohen</b> is the senior editor of all nine editions of <i>Pathways of the Pulp</i>. He is a diplomate of the American Board of Endodontics and has held leadership positions in many of the major professional and academic organisations in endodontics. Dr Cohen is Adjunct Professor of Endodontics in the Arthur A. Dugoni School of Dentistry at the University of the Pacific in San Francisco and Professor of Endodontics in the Department of Preventive and Restorative Dental Sciences at the University of California, San Francisco. He also serves on the advisory board of Hu-Friedy Co. Dr Cohen can be contacted at <a href="mailto:scohen@unionsquareendo.com">scohen@unionsquareendo.com</a>.</p>	
	<p><b>Dr Louis H. Berman</b> is a former clinical instructor and guest lecturer at the Albert Einstein Medical Center and former Assistant Professor of Endodontics at the University of Maryland School of Dentistry. He is past president (1999–2000) of the Maryland State Association of Endodontists and a member of the <i>Journal of Endodontics</i> Scientific Advisory Panel. Dr Berman is the senior author for the chapter on diagnosis in the ninth edition of <i>Pathways of the Pulp</i>. He is also the senior editor and contributing author of the comprehensive textbook <i>A Clinical Guide to Dental Traumatology</i>, published by Mosby in 2006. A board-certified endodontist, he has been in full-time private practice in Annapolis in Maryland for the past 25 years. Dr Berman can be contacted at <a href="mailto:Berman@AnnapolisEndodontics.com">Berman@AnnapolisEndodontics.com</a>.</p>	
	<p><b>Dr Gabriela Martin</b> is Professor of Endodontics at the School of Dentistry at the National University of Cordoba in Argentina. She obtained her Certification in Endodontics in 2000 through the Argentine Society of Endodontics and is an active member of the Argentine Association of Dentistry. She is a voter member of the Association of Endodontics of Cordoba, Argentina and teaches hands-on courses at the Dentistry Association of Cordoba. Her dentistry work is focused on endodontics, and she has been in private practice in Cordoba since 1992. Dr Martin can be contacted at <a href="mailto:ggmartin@hotmail.com">ggmartin@hotmail.com</a>.</p>	



Under the patronage of  
**H. H. Sheikh Hamdan Bin Rashid Al Maktoum**  
Deputy Ruler of Dubai, Minister of Finance  
President of the Dubai Health Authority



# UAE International Dental Conference & Arab Dental Exhibition

**9 - 11 March, 2010**  
Dubai International Convention  
& Exhibition Centre

إيدك  
**AEDC®**  
Dubai 2010

Network with over  
**27,000** highly qualified  
professionals, oral  
healthcare providers and  
more than **700** exhibitors  
from **65** participating  
countries

[www.aedc.com](http://www.aedc.com)

Unique Opportunities  
not to be Missed!

- Great business to business opportunities
- Excellent exposure for your dental innovations and services
- Get involved in various educational dental activities
- Witness the latest advancement in dentistry
- Learn and gain knowledge from more than 80 lectures
- Meet and interact with more than 100 reputed international and regional experts

Organised by



In cooperation with



Strategic Partner



Supported by



Scientific Support



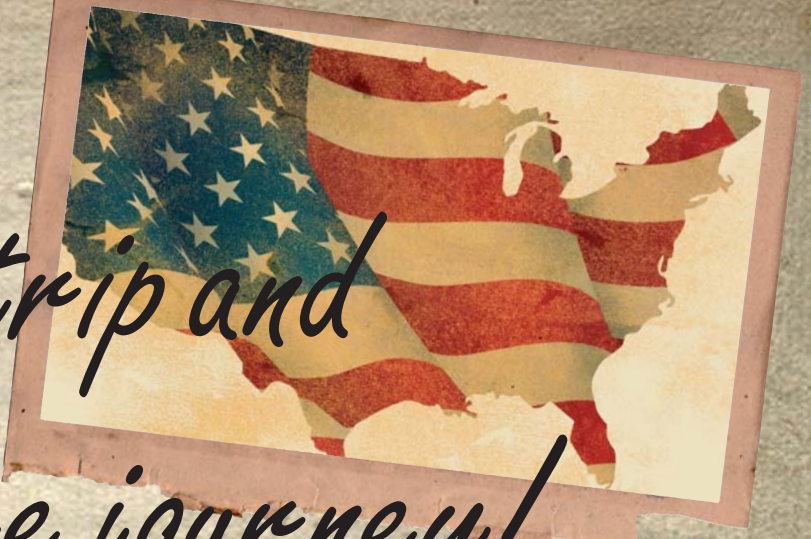**INDEX® Conferences & Exhibitions Organisation Est.**

P.O. Box: 13636 | Ibn Sina Bldg. Block B – Office 203 | Dubai Health Care City | Dubai – United Arab Emirates  
Tel.: +971 4 362 4717 | Fax: +971 4 362 4718 | E-mail: [aedc@index.ae](mailto:aedc@index.ae) | Website: [www.aedc.com](http://www.aedc.com)



# Enjoy your trip and indulge in the journey!

Author & Photographer \_ Annemarie Fischer, Germany



*"The American Road Trip isn't just a pastime; it's a birthright, a necessity, a rite of passage, it's a way of life."  
(Erin McHugh, The Little Road Trip Handbook)*

The road trip is a constant narrative in US-American pop culture and is synonymous with escape, freedom, and independence from borders and boundaries. In the land of the free and the home of the mobile, the *Asphalt Nation* of America, as observed by Jane Holtz Kay, is built around automobiles and cherishes the ideal of mobility. Some road-enthusiasts, referring to themselves as road trippers—

if you would like to go straight, left or right, and not planning ahead too much. It is about impromptu 'moseying' down the road rather than following a strict schedule.

have developed the science of a road trips, *roadology*, that explores the effects of roads on societies.

A true American road trip starts at the first crossroads, not knowing

This road trip combines two routes, the hiker-favourite Appalachian Trail, starting in Pennsylvania and exploring Southern Atlanta, and the NYC-Miami Atlantic Coast Route to Florida. The routes explore the historical birthplace of the United States in Philadelphia, the impressive nature of the Shenandoah, Great Smoky Mountains and Everglades National Parks, Ivy League university campuses of Cornell, Princeton and Pennsylvania University, the cradle of the African-American civil rights movement and global news in Atlanta, the Kennedy Space Center in Cape Canaveral, and the colourful Miami.





For outlanders, a well-kept rental car, sufficient insurance coverage, a working mobile phone and a good map, as well as credit cards and some dollar bills to secure cash-flow are enough. In local supermarkets, one can get a regular supply of water, fresh fruit and chopped veggies. In some states, one might be lucky to find on-the-road selling stations of local produce. With most rentals nowadays, you get access to hundreds of digital radio stations that complete the road track with the perfect sound track. Jamie Jenson, author of *Road Trip USA*, offers a road trip blog and podcast at [www.roadtripusa.com](http://www.roadtripusa.com).

Motels are available easily down the road; with the Days Inn as well as Jamestown being on the (more) pleasant side. However, their early nutrition consists mostly of a crime called Con-

### \_Going green

Nature parks in the States truly signify the gorgeousness of this country, and function as an oasis from civilization—no gigan-tomaniac malls and no fast food restaurants disturb the scenic nature. A small entrance fee is valid for a couple days up to a week. Hotels or camping facilities offer a place to stay for the night.

Being thrown into nature, one is to respect the speed limit in order not to hurt an animal. A 35-mile-speed limit in Skyline Drive explores Shenandoah National Park. Down the Appalachian Trail, the fog-covered mountains name the Great Smoky Mountains National Park and amaze visitors in the most popular park in the United States. Alligators, pythons and vultures come close in the Florida Everglades Park, and protection from mosquitoes is mandatory!



tinental Breakfast. The Waffle House, for example, offers a more decent way to start the day and is open-all-night to savour fresh waffles with maple syrup, eggs'n'bacon and grits in enormous portion sizes. For a decent dinner, one should always ask for the best local diner on the way, and fast food branches offer a quick snack to go.

The concept of Park and Ride is not compulsory in most cities. Most downtown areas are quite car-friendly, with most sights offering free parking or at rates for a couple of dollars per hour. Park and Ride is only mandatory in city molochs like New York.

### \_Going Ivy

American elite Ivy League Universities—Cornell, Pennsylvania University and Princeton—are always worth the trip, since their campuses blend in with the nature and offer an



impressive architecture. University bookstores are tea'n'coffee havens to indulge in the oeuvres of university lecturers, for instance novelists Vladimir Nabokov in Cornell, Philip Roth at PennU, and Jeffrey Eugenides at Princeton.






The campuses also own captivating museums: The University of Pennsylvania, that claims to be America's First University, possesses in Museum of Archaeology and Anthropology one of the finest ethnology collections in the world.

### \_Shopping in the USA

Since consumption of goods has been elevated to a true art form in the United States of America, a typical road tripper goes shopping. In times of crisis, outlet shopping centres function as a holy grail for an almost guilt-free indulgence. It is more fun to explore the less-crowded centres in the South, such as in *nomen est omen* Commerce.



impressive art collections. Film legend Rocky Balboa turned its stairs into an American pop culture icon—to climb and conquer the stairs and to cheer on top has become a verb, "to do the Rocky (Balboa)". Cruising South Philly is even more amazing—it unravels graffiti buildings, outdoor neighbourhoods and family businesses. Geno's and Pat's just face each other to win the culinary competition over the Best Philly Cheese Steak, a sandwich filled with steak and cheese sauce.



### \_Rocking Philly

Philly forms the perfect symbiosis between history and relaxation. The City of Brotherly Love is the historical birthplace of the United States and welcomes you with American historical sites in the Independence National Historical Park, home of the Liberty Bell, as well as the Betsy Ross House, where historians still debate if the first US-American flag had been indeed designed there. The Philadelphia Museum of Art offers one of the most



### \_Hotlanta

Temperatures and heartiness rise as one reaches the capital of the Peach State Georgia, Atlanta. Hotlanta is the home of Coca-Cola and CNN, and of Martin Luther King Jr, who was born and raised here. The King Center and his birthplace blend in unpretentiously with the neighbourhood. King's powerful rhetoric accompanies insightful information on his life path that reflects the struggles of the civil rights movement, and on current human rights movements around the world in this living memorial.

When Hotlanta makes hungry, The Varsity is considered as the best Drive-In hot dogs, greeting the customers with the legendary "What'll ya have?".





The CNN Headquarters satisfies an appetite for information, where the longest escalator of the world guides one to the CNN studios, where visitors can see directly into studio windows. News is today a highly-complex and digitalised production. CNN anchormen and -women work directly from news bureaus, endowed with highly-sensitive microphones that block surrounding noises, and are digitally beamed into futuresque studio settings.



calypso sound. The Spanish churros pastry, along with hot chocolate, drench the night.

### Going up

The Kennedy Space Center is financed uniquely with entrance fees, and is the most gigantic PR measure to promote aerospace. The space center is located in a gigantic



### Bienvenidos a Miami!

Miami truly cites its *Miami Vice* pop culture reference, shimmering in pleasant pastel colours, and glowing as the vibrant and voluptuous as the eighties era. Pastel-blue daytime skies change into dramatic evening shades. The Art Déco district can be explored with guided tours, and it is the sight of a tragedy: Gianni Versace was murdered at Ocean Drive 1116 in his Casa Casuarina.

The Magic City merges into a true melting point and is the largest and most vibrant out-of-Latin America community, visible in Little Havana. Two-thirds of Miami people cite Spanish as their mother tongue. Those Latin, Caribbean, Central and South American as well as European influences melted into the unique New World, or Nuevo Latino, cuisine. In the Las Vegas Restaurant, one can get a taste of the Cuban Fusion cuisine. After sun-bathing at South Beach, synonymous to "showing what you've got", most restaurants turn into nightclubs. Coconut Grove offers after-dinner cocktails in outside cafés and bars, where one cannot only indulge in tastes, but also sounds of Latin America and the Caribbean. Cubans brought the conga and rumba to Miami from their homelands, instantly popularising it into US-American culture. Dominicans carried bachata, and merengue into the bars, while Caribbeans brought reggae, soca,



nature reserve and is not only a high-tech playground, visitors can witness work in progress on the working facilities.

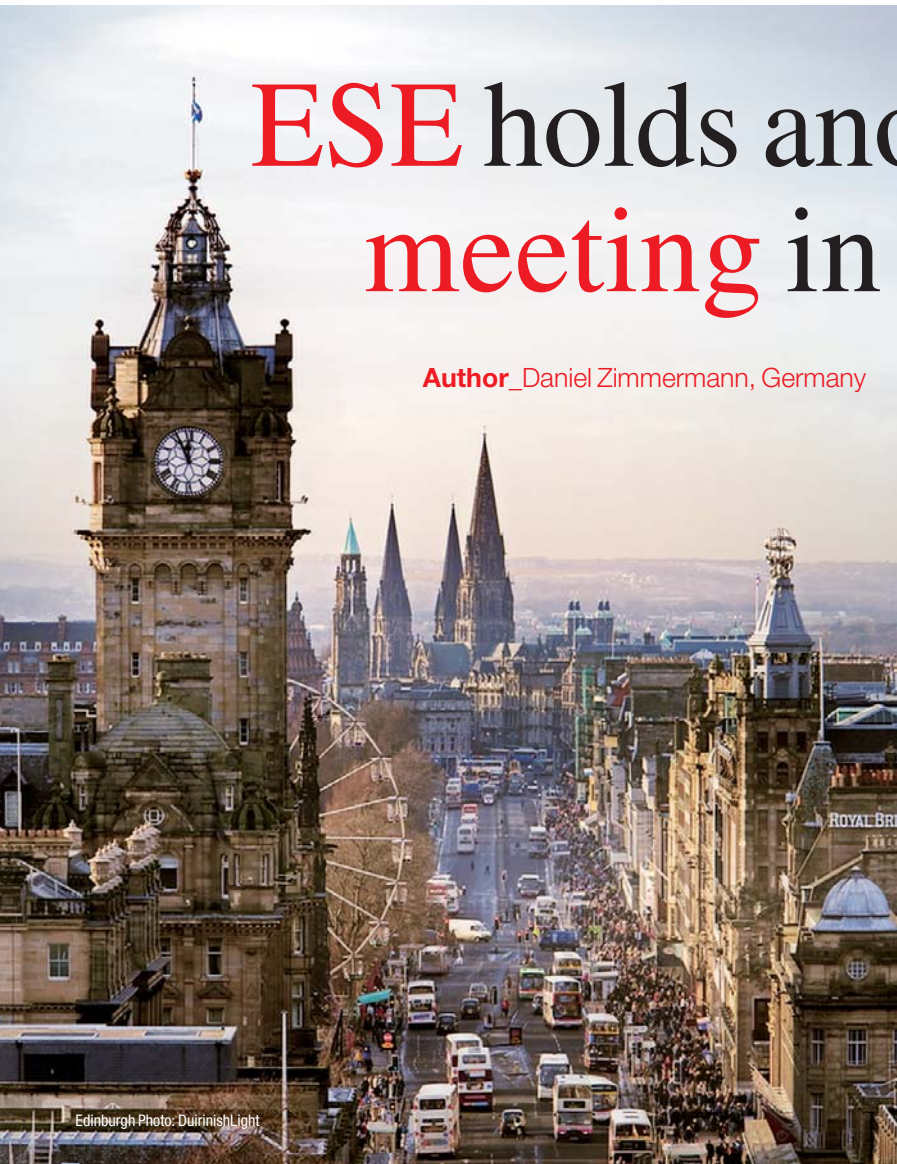For outlanders, an All-American road trip is the path to understand that the United States of America is a gathering of civilizations and cultures, flora and fauna, images and sounds, flavours and aromas, styles, and feelings; and "to get the feel of the road", notes Erin McHugh in *The Little Road Trip Handbook*, "remember that it's the journey, not the destination."





# ESE holds another record meeting in Scotland

Author\_Daniel Zimmermann, Germany



Edinburgh Photo: DuirinishLight

The auditorium filled with the sound of Scottish bagpipes, but not playing the familiar tunes of folk classics such as *Amazing Grace* or *Auld Lang Syne*; it was the famous guitar intro from AC/DC's 1990 track *Thunderstruck* as re-interpreted by the Red Hot Chilli Pipers. The performance by the Scottish ensemble, who won the BBC's *When Will I Be Famous* television show in 2007 and currently conquer stages in Scotland and worldwide with their energetic bagpipe rock, clearly was one of the highlights of this year's European Society of Endodontology (ESE) congress in Edinburgh.


The 14<sup>th</sup> biennial ESE meeting, which was the second held in the UK (the first was the London congress in 1993), saw a record attendance of over 1,400 endodontic specialists from 50 countries. They had been invited to join a comprehensive lecture programme discussing key issues like the rights and wrongs of different instrumentation, and perennials like the realities of microbial biofilms and the challenges of 3-D imaging. New this year was a significant offering



Meeting Photos: Daniel Zimmermann







of 20-minute presentations that illustrated the latest clinical findings from research groups throughout Europe and further afield.

At the accompanying trade show, the Austrian company W&H presented their new anaesthetic system Anesto that allows targeted local anaesthetisation of individual teeth and will be available to UK dentists in autumn. SybronEndo, a gold sponsor of the meeting, said that their successful TF rotary NiTi files are now available in apical sizes 30, 35 and 40. French Acteon had their EndoSuccess range of tips for apical surgery on display.

"This was a record-breaking blockbuster for the ESE and we were delighted to have been able to host an event of such quality and size in Edinburgh. Each of our invited speakers brought their own style and insights, producing a varied and balanced programme for a large and diverse audience. ESE has become a beacon meeting, an exceptional gathering for scholarship, fellowship and discovery," Prof John Whitworth from Newcastle University and President of the British Endodontic Society told **roots**.

Delegates at the General Assembly elected former ESE secretary Prof Claus Löst as their new president. Prof Löst is currently Clinical Director of the Center of Dentistry, Oral Medicine and Maxillofacial Surgery at the Tübingen University Hospital in Germany. He will succeed incumbent president Prof Gunnar Bergenholtz (right) from Sweden at the beginning of 2010. More staff changes are expected to be announced soon.

Amongst others, treasurer Prof Dag Ørstavik from Norway will step down at the end of this year.

The Executive Board also proposed the co-funding of a symposium in July 2010 with the Pulp Biology and Regeneration Group of the International Association for Dental Research, which will address the topics of inflammation and regeneration.

ESE, founded in April 1982, is a federal organisation representing national endodontic and dental societies in 27 European countries. Their next congresses will take place in Rome (Italy) in 2011 and in Lisbon (Portugal) in 2013.



# Endo events

## 2010

### 145<sup>th</sup> Midwinter Meeting Chicago Dental Society

Where: Chicago, IL, USA  
Date: 25–27 February 2010  
Tel.: +1 312 836 7300  
Web site: [www.cds.org.mwmm](http://www.cds.org.mwmm)

### AAE Annual Session

Where: San Diego, CA, USA  
Date: 14–17 April 2010  
Tel.: +1 800 872 3636  
E-mail: [info@aae.org](mailto:info@aae.org)  
Web site: [www.aae.org](http://www.aae.org)

### IADR 88<sup>th</sup> General Session & Exhibition

Where: Barcelona, Spain  
Date: 14–17 July 2010  
Tel.: +1 703 299 8095  
Web site: [www.iadr.org](http://www.iadr.org)

### FDI Annual World Dental Congress

Where: Salvador, Brazil  
Date: 2–5 September 2010  
Tel.: +33 450 4050 50  
E-mail: [congress@fdiworldental.org](mailto:congress@fdiworldental.org)  
Web site: [www.fdiworldental.org](http://www.fdiworldental.org)

### 8<sup>th</sup> IFEA World Congress

Where: Athens, Greece  
When: 6–9 October 2010  
E-mail: [IFEAsecretary@aol.com](mailto:IFEAsecretary@aol.com)  
Web site: [www.ifea2010-athens.com](http://www.ifea2010-athens.com)

### Trans-Tasman Endodontic Conference

Where: Christchurch, New Zealand  
Date: 4–6 November 2010  
Tel.: +61 2 9518 7722  
E-mail: [info@tteconference.com](mailto:info@tteconference.com)  
Web site: [www.tteconference.com](http://www.tteconference.com)

### Greater New York Dental Meeting

Where: New York, NY, USA  
Date: 26 November–1 December 2010  
Tel.: +1 212 398 6922  
Web site: [www.gnydm.org](http://www.gnydm.org)

## 2011

### 34<sup>th</sup> International Dental Show

Where: Cologne, Germany  
Date: 22–26 March 2011  
Tel.: +49 221 8210  
E-mail: [ids@koelnmesse.de](mailto:ids@koelnmesse.de)  
Web site: [www.ids-cologne.de](http://www.ids-cologne.de)

### FDI Annual World Dental Congress

Where: Mexico City, Mexico  
Date: 14–17 September 2011  
Tel.: +33 450 4050 50  
E-mail: [congress@fdiworldental.org](mailto:congress@fdiworldental.org)  
Web site: [www.fdiworldental.org](http://www.fdiworldental.org)

### 15<sup>th</sup> Biennial ESE Congress

Where: Rome, Italy  
Date: 28 September–1 October 2011  
Web site: [www.eserome2011.com](http://www.eserome2011.com)





# submissions:

## formatting requirements

**Please note** that all the textual elements of your submission:

- \_ the complete article,
- \_ all the figure captions,
- \_ the complete literature list, and
- \_ the contact info (bio, mailing address, E-mail address, etc.)

must be combined into one Word document. Please do not submit multiple files for each of these items.

In addition, images (tables, charts, photographs, etc.) must not be embedded into the Word document. All images must be submitted separately, and details about how to do this appear below.

### Text length

Article lengths can vary greatly—from a mere 1,500 to 5,500 words—depending on the subject matter. Our approach is that if you need more or less words to do the topic justice then please make the article as long or as short as necessary.

We can run an extra long article in multiple parts, but this is usually discussing a subject matter where each part can stand alone because it contains so much information. In addition, we do run multi-part series on various topics.

In short, we do not want to limit you in terms of article length, so please use the word count above as a general guideline and if you have specific questions, please do not hesitate to contact us.

### Text formatting

Please use single spacing and un-indented paragraphs for your text. Just place an extra blank line between paragraphs.

We also ask that you forego any special formatting beyond the use of italics and boldface, and make sure that all text is left justified.

If you would like to emphasize certain words within the text, please only use italics (do not use underlining or a larger font size). Boldface is reserved for article headers.

Please do not 'center' text on the page, add special tab stops, or use underlining as all of this must be removed before layout. If you require a special layout, please let the word processing programme you are using help you to do this formatting rather than doing it by hand on your own.

If you need to make a list, or add footnotes or endnotes, please let the Word processing programme do it for you automatically. There are menus in every programme that will help you to do this. The fact is that no matter how careful one might be, errors have a way of creeping in when you try to hand number footnotes and literature lists.

### Image requirements

Please number images consecutively throughout the article by using a new number for each image. If it is imperative that certain images are grouped together, then use lowercase letters to designate the images in a group (ie, 2a, 2b, 2c).

Please put figure references in your article wherever they are appropriate, whether that is in the middle or end of a sentence. If you are not directly mentioning the figure in the body of your article, when it appears at the end of the sentence the figure reference should be enclosed within parenthesis and be inside the sentence, meaning before the period.

In addition, please note:

- \_ We require images in TIF or JPEG format.
- \_ These images must be no smaller than 6 x 6 cm in size at 300 DPI.
- \_ Images cannot be any smaller than 80 KB in size (or they will print the size of a postage stamp!).

Larger images are always better, and something on the order of 1 MB is best. Thus, if you have an image in a large size, do not bother sizing it down to meet our requirements but send us the largest file sizes available. (The larger the starting image is in terms of bytes, the more leeway the designer has in terms of resizing the image to fill up more space should there be room available).

Also, please remember that you should not embed the images into the body of the text document you submit. Images must be submitted separately from the textual submission.

You may submit images through a zipped file via E-mail, unzipped individual files via E-mail, or post a CD containing your images directly to us (please contact us for the mailing address as this will depend upon where in the world you will be mailing them from).

Please do not forget to send us a head shot photo of yourself that also fits the parameters above so that it can be printed along with your article.

### Abstracts

An abstract of your article is not required. However, if you choose to provide us with one, we will print it in a separate box.

### Contact info

At the end of every article is a Contact Info box with contact information along with a head shot of the author. Please note at the end of your article the exact information you would like to appear in this box and format it according to the previously mentioned standards. A short bio may precede the contact info if you provide us with the necessary information (60 words or less).

### Questions?

Please contact us for our Author Kit, or if you have other questions:

### Managing Editor

Claudia Salwiczek  
c.salwiczek@dental-tribune.com

**roots**

the international magazine of endodontics

**dti** Dental  
Tribune  
International

**Publisher**

Torsten R. Oemus  
[t.oemus@dental-tribune.com](mailto:t.oemus@dental-tribune.com)

**Managing Editor**

Claudia Salwiczek  
[c.salwiczek@dental-tribune.com](mailto:c.salwiczek@dental-tribune.com)

**Product Manager**

Bernhard Moldenhauer  
[b.moldenhauer@dental-tribune.com](mailto:b.moldenhauer@dental-tribune.com)

**Executive Producer**

Gernot Meyer  
[g.meyer@dental-tribune.com](mailto:g.meyer@dental-tribune.com)

**Designer**

Franziska Dachsel  
[f.dachsel@dental-tribune.com](mailto:f.dachsel@dental-tribune.com)

**Copy Editor**

Sabrina Raaff  
Hans Motschmann

**International Administration**

**President/CEO**

Peter Witteczek  
[p.witteczek@dental-tribune.com](mailto:p.witteczek@dental-tribune.com)

**Executive Vice President**

**Finance**

Dan Wunderlich  
[d.wunderlich@dental-tribune.com](mailto:d.wunderlich@dental-tribune.com)

**International Media Sales**

*Europe*  
Antje Kahnt  
[a.kahnt@dental-tribune.com](mailto:a.kahnt@dental-tribune.com)

*Asia Pacific*  
Peter Witteczek  
[p.witteczek@dental-tribune.com](mailto:p.witteczek@dental-tribune.com)

*North America*  
Humberto Estrada  
[h.estrada@dtamerica.com](mailto:h.estrada@dtamerica.com)

**International Offices**

*Europe*  
Dental Tribune International GmbH  
Contact: Nadine Parczyk  
Holbeinstr. 29  
04229 Leipzig, Germany  
Tel.: +49 341 484 74 302  
Fax: +49 341 484 74 173  
[www.dti-publishing.com](http://www.dti-publishing.com)

*Asia Pacific*  
Dental Tribune Asia Pacific Ltd.  
Contact: Tony Lo  
Room A, 26/F, 389 King's Road  
North Point, Hong Kong  
Tel.: +852 3113 6177  
Fax: +852 3113 6199  
[www.dti-publishing.com](http://www.dti-publishing.com)

*The Americas*  
Dental Tribune America, LLC  
Contact: Anna Wlodarczyk  
213 West 35<sup>th</sup> Street, Suite # 801  
New York, NY 10001, USA  
Tel.: +1 212 244 7181  
Fax: +1 212 244 7185  
[www.dti-publishing.com](http://www.dti-publishing.com)

**Editorial Board**

Fernando Goldberg, Argentina  
Markus Haapasalo, Canada  
Ken Serota, Canada  
Clemens Bargholz, Germany  
Michael Baumann, Germany  
Benjamin Briseno, Germany  
Asgeir Sigurdsson, Iceland  
Adam Stabholz, Israel  
Heike Steffen, Germany  
Gary Cheung, Hong Kong  
Unni Endal, Norway  
Roman Borczyk, Poland  
Bartosz Cerkaski, Poland  
Esteban Brau, Spain  
José Pumarola, Spain  
Kishor Gulabivala, United Kingdom  
William P. Saunders, United Kingdom  
Fred Barnett, USA  
L. Stephan Buchanan, USA  
Jo Dovgan, USA  
Vladimir Gorokhovskiy, USA  
James Gutmann, USA  
Ben Johnson, USA  
Kenneth Koch, USA  
Sergio Kuttler, USA  
John Nusstein, USA  
Ove Peters, USA  
Jorge Vera, Mexico

**roots** Copyright Regulations

*\_roots\_ the international magazine of endodontics* is published by Dental Tribune Asia Pacific Ltd. and will appear in 2009 with one issue every quarter. The magazine and all articles and illustrations therein are protected by copyright. Any utilisation without the prior consent of editor and publisher is inadmissible and liable to prosecution. This applies in particular to duplicate copies, translations, microfilms, and storage and processing in electronic systems.

Reproductions, including extracts, may only be made with the permission of the publisher. Given no statement to the contrary, any submissions to the editorial department are understood to be in agreement with a full or partial publishing of said submission. The editorial department reserves the right to check all submitted articles for formal errors and factual authority, and to make amendments if necessary. No responsibility shall be taken for unsolicited books and manuscripts. Articles bearing symbols other than that of the editorial department, or which are distinguished by the name of the author, represent the opinion of the afore-mentioned, and do not have to comply with the views of Dental Tribune Asia Pacific Ltd. Responsibility for such articles shall be borne by the author. Responsibility for advertisements and other specially labeled items shall not be borne by the editorial department. Likewise, no responsibility shall be assumed for information published about associations, companies and commercial markets. All cases of consequential liability arising from inaccurate or faulty representation are excluded. General terms and conditions apply, legal venue is North Point, Hong Kong.



**AT THE GNYDM NOVEMBER 29 - DECEMBER 2, 2009**

The DTSC Symposia at the Greater New York Dental Meeting offer an inspiring schedule of continuing education lectures in various dental disciplines. Each scientific lecture will provide an invaluable opportunity to learn diverse aspects of dentistry and how to integrate a variety of treatment options into your practice.

We have developed a course schedule that is both diverse and engaging, and which also offers you the opportunity to earn C.E. credits. The symposia sessions are FREE for all Greater N. Y. Dental Meeting visitors, but pre-registration is recommended to ensure preferred seating.

SUNDAY NOVEMBER 29	MONDAY NOVEMBER 30	TUESDAY DECEMBER 1	WEDNESDAY DECEMBER 2
<p>10:00 - 11:00 am  <b>ONE-STEP ADHESION,            ONE-STEP CEMENTATION</b>            Dr. George Freedman DDS</p> <p>11:30 - 12:30 pm  <b>HIGH RESOLUTION CONE            BEAM WITH PREXION 3D</b>            Dr. Dan McEowen DDS</p> <p>1:30 - 2:30 pm  <b>SIMPLIFY ESTHETIC DENTISTRY</b>            Dr. Steven Weinberg DDS</p> <p>3:00 - 4:00 pm  <b>THE BEAUTY OF +BONDING</b>            Dr. Howard Glazer DDS</p> <p>4:15 - 5:15 pm  <b>NEW DISCUSSION: RISK OF            CORONARY HEART DISEASE IN            ASSOCIATION WITH            PERIODONTITIS AND            PERIMPLANTITIS</b>            Dr. Hans Dieter John, Dr. Richard            Meissen and D.R. Gieselmann</p>	<p>10:00 - 11:00 am  <b>E4D SKY: DENTISTRY'S            DESTINATION</b>            Dr. Gary Severance DDS and Lee Culp            CDT</p> <p>11:30 - 12:30 pm  <b>KNOW YOUR PRODUCTS &amp; TOOLS            FOR TODAY'S HEALING DENTISTRY</b>            Dr. Fay Goldstep DDS</p> <p>1:30 - 2:30 pm  <b>ORAVERSE™ - IN PRACTICE</b>            Dr. Steven Glassman DDS</p> <p>3:00 - 4:00 pm  <b>THE ADVANTAGE OF SMALL FOV            HIGH RESOLUTION CBCT IMAGING</b>            Dr. Dan McEowen DDS</p> <p>4:15 - 5:15 pm  <b>NEW DISCUSSION: RISK OF            CORONARY HEART DISEASE IN            ASSOCIATION WITH PERIODONTITIS            AND PERIMPLANTITIS</b>            Dr. Hans Dieter John, Dr. Richard            Meissen and D.R. Gieselmann</p>	<p>10:00 - 11:00 am  <b>TECHNOLOGICAL            RESOURCES AND            BIOLOGICAL CONCEPTS IN            MINIMALLY INVASIVE            ENDODONTICS</b>            Dr. Renato Leonardo DDS</p> <p>11:30 - 12:30 pm  <b>THE AFFORDABLE SOFT            TISSUE DIODE LASERS</b>            Dr. George Freedman DDS</p> <p>1:30 - 2:30 pm  <b>ESTHETICS USING COSMETIC            PERIODONTAL SURGERY</b>            Dr. David Hoexter DMD</p> <p>3:00 - 4:00 pm  <b>YOU'VE TAKEN IMPLANT            TRAINING ...WHAT DO YOU            DO NEXT?</b>            Lynn Mortilla, RDH</p>	<p>10:00 - 11:00 am  <b>ICON - INNOVATIVE            CARIES TREATMENT            WITHOUT DRILLING</b>            Dr. George Freedman DDS</p> <p>11:30 - 12:30 pm  <b>IMMEDIATE TOOTH            REPLACEMENT IN THE            ESTHETIC ZONE</b>            Dr. Barry Levin DDS</p> <p>1:30 - 2:30 pm  <b>MORE THAN JUST TEETH            AND GUMS</b>            Dr. Ron Schefdore DDS</p> <p>3:00 - 4:00 pm  <b>MY FIRST ESTHETIC            IMPLANT CASE - WHY,            HOW, &amp; WHEN?</b>            Dr. Marius Steigmann DDS</p>

**FREE FOR REGISTERED GNYDM ATTENDEES, BUT PRE-REGISTRATION IS RECOMMENDED.**  
 Register now for the GNYDM under [www.gnydm.com](http://www.gnydm.com) and find full program  
 details under [www.DTStudyClub.com](http://www.DTStudyClub.com).



Dental Tribune America is an ADA CERP recognized provider

For more information, please contact **Julia E. Wehkamp**, C.E. Director, Dental Tribune Study Club  
 Phone: (416) 907-9836, Fax: (212) 244-7185, E-mail: [j.wehkamp@DTStudyClub.com](mailto:j.wehkamp@DTStudyClub.com)

This program is made available through educational grants provided by:  
 PreXion, VOCO, Ultradent, Clinical House Europe GmbH, SHOFU, Novalar, Straumann, DMG, D4D, Chase and AMD Lasers





# With an extra small head



Endea contra-angle handpieces. The new standard in mechanical endodontics. With their new and extra small heads Endea NiTi contra-angle handpieces provide even better access to the treatment area. For the best results in the shortest amount of time.