

Er,Cr:YSGG laser and Internal Root Resorptions

Case report of an **endodontic treatment**
using **radial firing tips**

Authors: Dr Miguel Rodrigues Martins, Prof. Dr Manuel Fontes Carvalho, Prof. Dr Irene Pina-Vaz,
Prof. Dr Miguel André Martins & Prof. Dr Norbert Gutknecht, Portugal/Germany

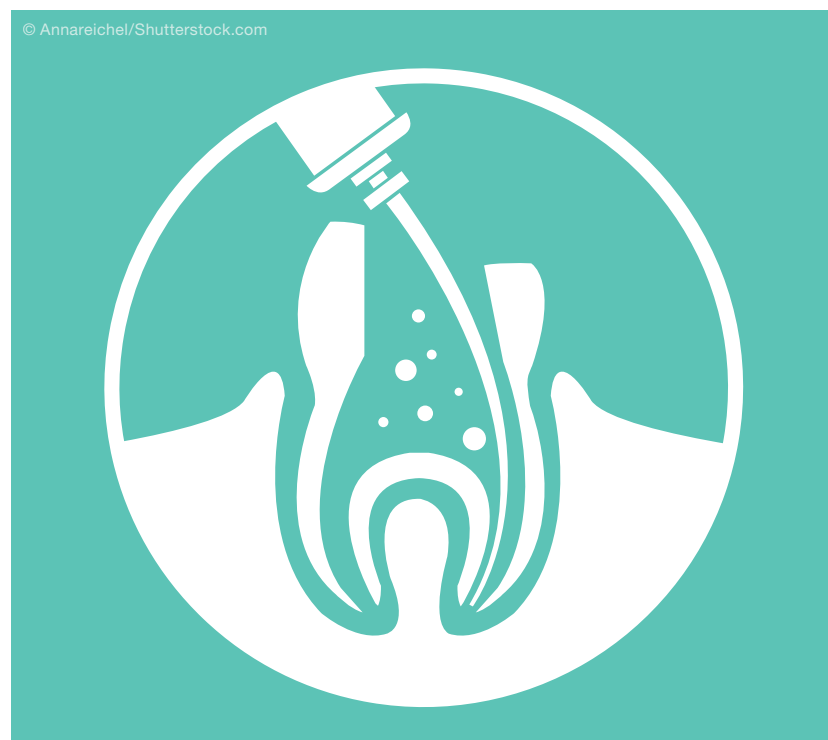
Introduction

Endodontic therapy is the treatment of choice for teeth with apical periodontitis and Internal Root Resorptions (IRR) as it aims to eliminate bacterial contamination, granulation tissue and blood supply of the clastic cells that are commonly reported to be involved with the process.^{1,2}

Sodium hypochlorite (NaOCl) is arguably chosen as primary endodontic disinfection solution. Nevertheless, the ideal concentration, temperature, contact period and extent of clinical effectiveness of NaOCl remains under discussion.³⁻⁶ Moreover, several clinical factors (e.g. root perforations, absence of apical constriction etc.) may accidentally induce NaOCl extrusion into periapical tissues with potentially severe and hazardous consequences.⁷⁻⁹

In spite of this, several clinical strategies were reported with regards to the management of root resorptions,¹⁰ their scientific evidence is limited to case reports and few present alternative disinfection techniques.¹¹⁻¹⁴ Lasers have long been presented as promising alternatives to conventional endodontic procedures.¹⁵ Each laser wavelength has a specific absorption coefficient for every tissue¹⁶ and erbium lasers demonstrate a high absorption coefficient for both water/aqueous solutions and hydroxyapatite.^{17,18} Thus, the rationale for using erbium lasers in endodontics may be briefly described as: (1) the ability of infrared light to interact with aqueous solutions and produce cavitation effects capable to remove smear layer, dentinal debris and filling materials from the root canal walls¹⁹⁻²¹ and (2) the ability of infrared light to propagate into the dentinal tubules, achieving significant bactericidal effects deeper than conventional chemical solutions.^{22,23}

Accordingly, the 2,780 nm Er,Cr:YSGG laser has been reported as an effective method for smear layer



© Annareichel/Shutterstock.com

and debris removal in comparison with EDTA irrigation, hand activation or even ultrasonic activated irrigation,^{19,24,24–27} resulting in a significant clearance of canals/isthmuses prior obturation²⁸ and less microleakage of root canal filling materials.²⁹ Moreover, it has also been shown to be suitable for deep root canal system disinfection and to allow irrigation solutions to travel apically.^{22,30–32} In addition, Er,Cr:YSGG laser irradiation has been shown to produce clinically safe temperature increments along the root canal walls,^{32–35} together with absence of molecular dentine changes, signs of melting or carbonisation.^{18,34,36}

Previously, laser-assisted endodontic protocols consisted of using plain fibres (with a straightforward emission beam profile). Generally, these fibres were placed in the main canal and withdrawn from apical to coronal in a rotating motion. However, such technique is known to be sensitive and to produce inconsistent results.^{18,35,37}

Designed to overcome such limitations, radial firing tips (RFT) present a beam expansion pattern—promoted by the tip geometry—that favours a homogeneous energy distribution along the root canal

wall. In contrast with plain fibres, RFT have been shown to produce consistently relevant *in vitro* results. They are known to spread their energy in the direction of the dentinal tubules,²² to produce lower temperature increments,²⁷ to increase cavitation effects towards the root canal walls without harming periapical tissues,³⁸ to be highly efficient in bacterial and biofilm reduction^{39,40} and to allow irrigating solutions to travel apically by overcoming the airlock effect.⁴¹

Although some clinical studies have demonstrated the potential benefits and long-term outcomes after laser-assisted treatments,^{42,43} there is no mention of any IRR case treated with a laser-assisted technique. The report of distinct clinical cases with long-term follow-ups may be an additional support for an evidence-based proof of concept.

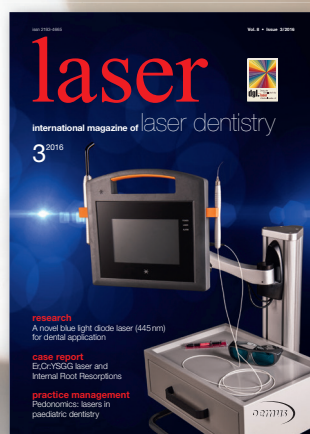
Case report

A 31-year-old female patient presented for consultation, complaining of recurrent swelling and painful episodes related to tooth 11, which had been treated with antibiotic prescriptions over the past few years. The patient's medical history was not con-

AD

Publish your expertise!

Become an author for **laser**—international magazine of laser dentistry



Please contact: Georg Isbaner · Editorial manager
g.isbaner@oemus-media.de

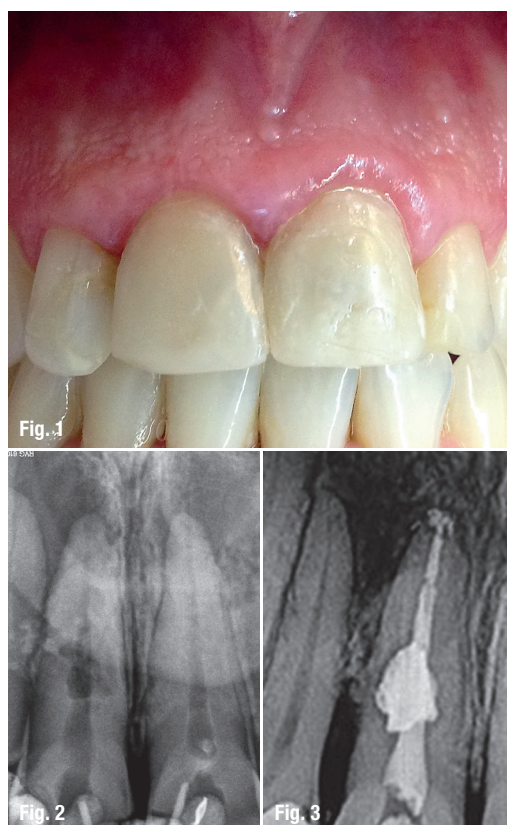
© Peshkova/Shutterstock.com



Fig. 1: Clinical picture demonstrating aesthetic initial appearance of tooth 11.

Fig. 2: Initial radiographic appearance of tooth 11 demonstrating an extensive apical radiolucency and internal root resorption.

Fig. 3: Immediate post-operative radiograph of tooth 11.



tributary. The patient reported trauma to her upper teeth when she was 20 years old. After performing clinical and radiographic examinations, tooth 11 was diagnosed with pulp necrosis with internal root resorption and apical periodontitis. The tooth was slightly tender to percussion, periodontal probing depths were considered normal (< 3 mm), and there was no discoloration (Figs. 1 & 2).

Approval for the study protocol (N_682/068) was obtained. Treatment options were discussed and the required consent obtained (Helsinki Declaration, revised in Edinburgh 2000). No financial incentive was offered (i.e., patient was responsible for the usual root canal treatment fee).

Under local anaesthesia (2% lidocaine with 1:100,000 epinephrine, Scandonest, Saint Maur des Fossés, France) and rubber-dam isolation (Hygenic Non-Latex Rubber Dam, Coltène/Whaledent, Germany), an access cavity was prepared with a high-speed carbide bur (SS White, Lakewood, NJ) and Zekrya Endo burs (DENTSPLY Maillefer, Ballaigues, Switzerland). The working length (WL) was electronically established (Root Zx mini, Morita, USA) as 1 mm short of the biological apex of the root and confirmed by radiography. No bleeding was noted from the root canal. Patency was confirmed with an ISO #20 K-file and root canal preparation was performed with the Protaper system (DENTSPLY Maillefer, Ballaigues Switzerland) up to an F5 (#50.05)

instrument. Root canal irrigation was performed between each file with 3 ml of sterile saline solution (Monoject 27G, Kendall-Covidien, USA). No chemical irrigants or inter-appointment dressings were used.

For smear layer removal and root canal disinfection, a previously reported laser-assisted protocol was adopted.^{42,43} Following root canal preparation, the main canal was filled with distilled water and laser irradiation was performed with the 2,780 nm Er,Cr:YSGG laser (Waterlase MD; Biolase Technology, San Clement, CA) and radial firing Tip (RFT2 Endolase, Biolase Technology; calibration factor of 0.55) which was 270 µm in diameter, with panel settings of 0.75 W, 20 Hz (37.5 mJ), 140 µs pulse, 0% water and 0% air. The tip was placed at the working length and irradiation was performed, approximately, at the speed of 2 mm/s until it reached the most coronal part of the canal. The irradiation procedure was repeated four times: 2x with the canal filled with distilled water (for smear layer and granulation/pulp tissue removal) followed by 2x in dry conditions (to achieve deep dentine penetration and disinfection), with approximately 15 seconds between each irradiation. Afterward, a sterile cotton pellet was placed in the pulp chamber, and the access cavity was sealed with a reinforced zinc-oxide eugenol intermediate restorative material (IRM, DENTSPLY).

At the second appointment after seven days, the patient reported pain, tenderness to percussion and swelling upon questioning. Under local anaesthesia and rubber dam isolation, the canal was re-accessed. The main canal was filled with distilled water and laser irradiation was performed using a 320 µm radial firing tip (RFT3 Endolase, Biolase Technology; calibration factor of 0.85), with panel settings of 1.25 W, 20 Hz (62.5 mJ), 140 µs pulse, 0% water and 0% air. The irradiation protocol was identical to the first appointment. After irradiation, a final rinsing of sterile saline solution (3 ml) was performed, and the canal was dried with sterile paper points, checking for the absence of any suppuration or exudate. Filling was performed with a #50.05 auto-fit gutta-percha cone (DENTSPLY Maillefer, Ballaigues Switzerland) using a down pack-backfill technique (Calamus, DENTSPLY Maillefer) and a resin-based endodontic sealer (Topseal, DENTSPLY Maillefer). Both down pack motion and gutta-percha injection were performed with low pressure and extreme caution due to the root weakness. Radiographic images were taken immediately (Fig. 3) and after one (Fig. 4), two (Fig. 5) and three years (Figs. 6 & 7). Over this follow-up period, the tooth remained completely asymptomatic and periapical healing was noticed.

Discussion

Due to its insidious pathology, the following clinical findings enabled the establishment of the diagnosis of IRR: 44 initial absence of bleeding from the root canal confirming a necrotic pulp, normal probing depth (< 3 mm) and the complete resolution of apical radiolucency after endodontic treatment, followed by the cessation of the progression of resorption.

Given that there is insufficient clinical data supporting the superiority of any chemical irrigation regimen and no guidelines for the management of low-occurrence pathologies such as IRR, case reports may be of special relevance while adequately reporting new disinfection techniques and their clinical outcomes.^{3,45}

The present protocol adopted the use of an Er,Cr:YSGG laser and innocuous irrigants (e.g. saline solution as irrigation and distilled water for laser activation). The decision was primordial based on the assumption that IRR lesions may perforate external root surfaces without being detectable on conventional radiographic images,⁴⁶ and that anatomic variations are known to significantly contribute to the occurrence of sodium hypochlorite accidents.⁴⁷

While trying to achieve significant bacterial reductions, our protocol contrast with that recently reported by Christo et al. which used low concentrations of NaOCl and a Er,Cr:YSGG laser-activation technique. In fact, this protocol has been shown not to improve the antibacterial effects of NaOCl⁴⁸ and, therefore, the activation of NaOCl may seem inadequate for the management of such conditions. In accordance, it was shown that the use of Er,Cr:YSGG laser with relatively high output powers to activate irrigants such as NaOCl or EDTA may result in a high magnitude of pressure changes capable to induce irrigants extrusion during laser-activated irrigation.⁴⁹

In order to obtain adequate microbial control calcium hydroxide (CH) is often recommended for the management of IRR lesions.^{50–52} However, the use of CH as an intra-canal medication consistently fails to present improved clinical outcomes.^{53–55} In the present report we may support that CH medication should not be considered crucial as antimicrobial agent and neither as essential to stop the IRR progression.

In fact, the decision process for not using CH as intra-canal medication during the endodontic treatment of IRR was also supported by the following criteria: (1) no irrigation technique is completely able to remove CH from simulated internal root resorption cavities¹⁴ and (2) the long-term exposure to CH can cause a significant reduction in the mechanical properties of radicular dentine.⁵⁶

Due to their biophysical properties, lasers have long been seen as a promising disinfection tool in endodontics. However, each wavelength demonstrates different biophysical interactions with the main radicular dentine components.¹⁵ The high absorption coefficients in both water and hydroxyapatite may justify the selection of the Er,Cr:YSGG laser ($\lambda=2,780$ nm) for both smear layer removal and disinfection purposes.¹⁸ Conflicting evidence while using other wavelengths can be found consistently.^{57,58}

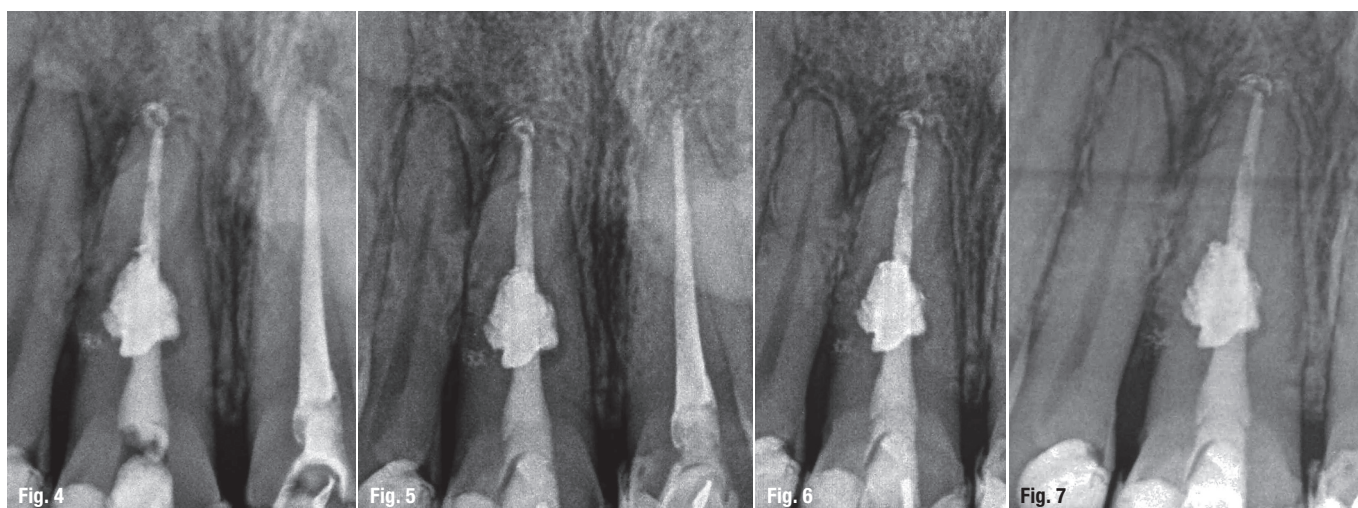
In the present report, the laser protocol consisted in two irradiations with distilled water in the main canal followed by two irradiations in dry conditions, respectively for smear layer removal and disinfection purposes.⁴² The rationale was that in wet conditions the Er,Cr:YSGG laser can promote beneficial cavitation effects inside the main canal without increasing the extrusion of irrigants.³⁸ Moreover, water-mediated cavitation has been shown to be highly effective for the removal of dentin debris in comparison with conventional or passive ultrasonic irriga-

Fig. 4: Twelve-month follow-up.

Fig. 5: Two-year follow-up.

Fig. 6: Three-year follow-up from the mesial direction.

Fig. 7: Three-year follow-up from the distal direction.



tion.^{19,38} Then, to achieve its maximum bactericidal properties, the Er,Cr:YSGG laser should work on a dry canal, allowing the energy to be transmitted deep into the dentinal tubules²² and to instantaneously interact with the water molecules trapped into the bacterial membrane and within endodontic biofilms.³⁹

RFT have been shown to overcome several limitations attributed to bare fibres, distributing the emitted laser energy in a uniform ring-shaped pattern.^{33,59} In similarity with any other innovative root canal treatment strategies, there are few reports demonstrating the prospective, long-term clinical outcomes associated with the use of Er,Cr:YSGG laser, namely with RFT. However, Martins et al. have shown that RFT can be considered predictable as the concomitant use of 3% NaOCl and CH for the endodontic treatment of single-rooted teeth with apical periodontitis.^{42,43} Our findings may provide further evidence that RFT can be considered safe in cases of teeth with wide apical foramina while being adequate to effectively reach all the contours of the resorption lesion.

The prognosis for the conservative treatment of IRR should increase due to the report of alternative endodontic techniques along with the use of new technologies (Al-Momani & Nixon 2013, Khojastepour et al. 2015, Nilsson et al. 2013).^{2,44,46} Therefore, clinicians may consider this laser-assisted technique

while selecting an appropriate endodontic disinfection strategy for the management of IRR.

Conclusion

Despite their intrinsic methodological limitations, the adequate report of single clinical cases may either help the understanding of unusual presentations of common diseases or assist in guiding new treatment concepts into clinical practice.⁴⁵ This case report presents potential benefits towards the use of Er,Cr:YSGG laser and radial firing tips in endodontics. Further randomised clinical trials should be conducted to clearly demonstrate its effectiveness.

Editorial note: A list of references is available from the publisher.

contact

Dr Miguel Rodrigues Martins, DDS, MSc, PhD

Endodontic Department, Faculty of Dental Medicine,
Universidade do Porto, Portugal
Rua Dr. Manuel Pereira da Silva,
4200-393 Porto, Portugal
Tel.: +351 914610046
miguel.ar.martins@gmail.com

Kurz & bündig

Im Gegensatz zur konventionellen, lasergestützten Wurzelkanalbehandlung mithilfe einfacher Laserfasern mit einem geraden Emissionsprofil stellt die RFT-Therapie mithilfe radial abstrahlender Faserspitzen eine vorhersagbare und sichere Alternative dar. Die spezielle Geometrie der Faserspitze ermöglicht eine homogene Energieverteilung entlang der Wurzelkanalwand in Richtung der Dentintubuli. Der entstehende Temperaturanstieg fällt geringer aus und die Kavitationseffekte entlang der Wurzelkanalwand werden verstärkt, ohne dass periapikale Gewebe beschädigt werden. Dabei zeigt sich die RFT-Therapie hocheffizient hinsichtlich der Reduktion von Bakterien und Biofilm und ermöglicht es, dass Spüllösungen sich apikal verteilen können.

Diese Eigenschaften der RFT-Therapie belegen die Autoren ausführlich anhand der aktuellen Literatur und stellen zudem selbst einen Patientenfall vor, bei dem diese für die Therapie einer internen Wurzelresorption angewendet wurden. Dies wurde in der vorliegenden Literatur bisher nicht dokumentiert.

Beschrieben wird diese Behandlung bei einer 31-jährigen Patientin ohne auffällige Vorgeschichte. Nach einem Zahntrauma elf Jahre zuvor litt sie unter wiederkehrenden Schwellungen und Schmerzen im Bereich von Zahn 11, bei welchem wir nach klinischer Untersuchung und Röntgenbefund eine Pulpanekrose mit interner Wurzelresorption und apikaler Parodontitis feststellten. Der Zahn war leicht empfindlich gegenüber Perkussion und die parodontalen Sondierungstiefen waren normal (< 3 mm). Verfärbungen wurden nicht festgestellt. Direkt nach der Behandlung sowie nach einem, zwei und drei Jahren wurden Röntgenaufnahmen angefertigt. Innerhalb dieses Zeitraums blieb der Zahn symptomfrei und eine periapikale Heilung setzte ein. Obwohl der vorliegende Fallbericht damit die potenziellen Vorteile der Anwendung des Er,Cr:YSGG-Lasers und radial abstrahlender Faserspitzen in der Endodontie bestätigt, empfehlen die Autoren weitere randomisierte klinische Studien, um diese eindeutig zu belegen.

Fascination of Laser in Munich

- 25th INTERNATIONAL CONGRESS OF THE DGL
- LASER START UP 2016

30 September — 1 October 2016
Munich | The Westin Grand Munich



ORGANIZER/SCIENTIFIC CHAIR

Deutsche Gesellschaft für Laserzahnheilkunde e.V.
Klinik für Zahnerhaltung, Parodontologie und
Präventive Zahnheilkunde
Universitätsklinikum der RWTH Aachen
Pauwelsstraße 30 | 52074 Aachen | Germany
Tel.: +49 241 8088-164 | Fax: +49 241 803388-164
sekreteria@dgl-online.de | www.dgl-online.de

ORGANIZATION

OEMUS MEDIA AG
Holbeinstraße 29 | 04229 Leipzig | Germany
Tel.: +49 341 48474-308 | Fax: +49 341 48474-290
www.oemus.com | event@oemus-media.de

REGISTRATION

www.dgl-jahrestagung.de | www.startup-laser.de



Fax Reply +49 341 48474-290

I would like to receive further information on the:

☐ 25th International Congress of the DGL

☐ LASER START UP 2016

Title, Name, Prenom

E-mail adress (for digital programme)

Stamp