

Survival of allogenic corticocancellous bone blocks

Horizontal alveolar process augmentation for implant placement

Author: Dr Dadi Hrafnkelsson, M.Sc., Denmark

Introduction

Loss of mastication or aesthetics that is to be restored by dental implants requires sufficient volume and quality of alveolar bone.¹⁻³ It is important for the primary stability and the long term success of any dental implant treatment. The famous golden standard remains to be the autologous bone block^{4,5} as it is not involved in any immunological concerns, and contains vital cells. However, the vitality of the graft is highly dependent on the perioperative storage of

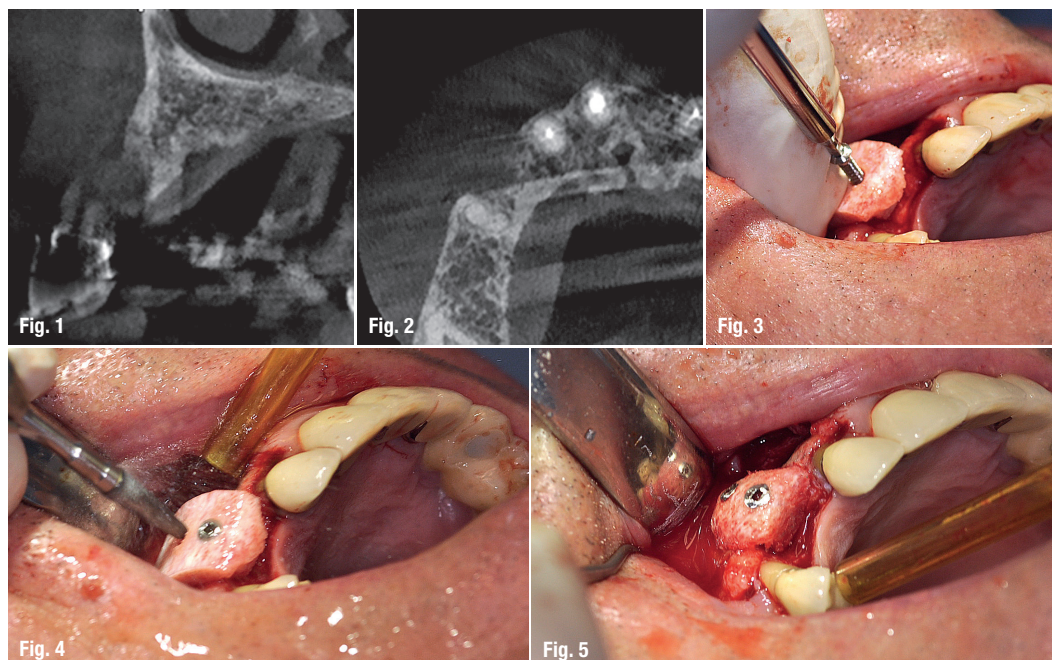
the graft.⁶ It is generally accepted that class IV and V, according to the Cawood and Howell classification,⁷ need block augmentation before implant placement. The use of osseous allograft blocks for alveolar process augmentation is not very well documented in the literature.

Antonio Barone et al.⁸ published his study in 2009 and showed a good success with the osseous allogenic block, 24 blocks were used to augment the maxilla in 13 patients. Five blocks were used for ver-

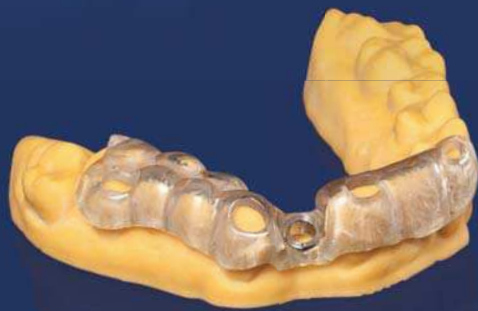Figs. 1 & 2: Case 1: Horizontal atrophy of the alveolar process in the maxilla.

Figs. 3 & 4: Allogenic bone block is fixed with two osteosynthesis screws.

Fig. 5: All sharp edges are removed intraorally.



The complete implant workflow - easiness with **one** software



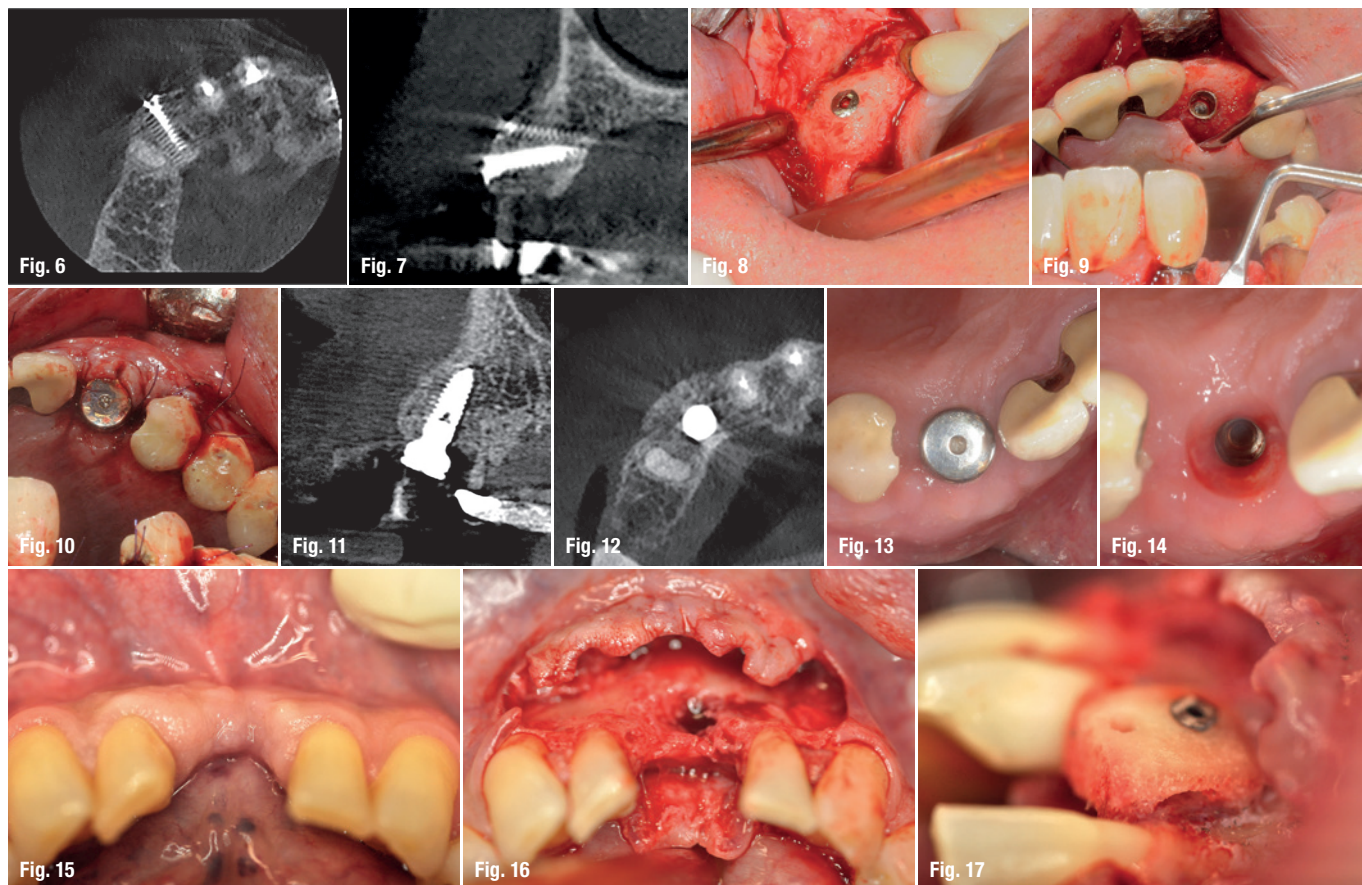
Taking an implant plan to actual surgery is now easier than ever! From imaging to implant planning and guide designing, all workflow steps can be controlled and completed in the **Planmeca Romexis**® software. Lastly, the guide can be easily and accurately created with **Planmeca Creo**™ 3D printer.

www.planmeca.com



PLANMECA





Figs. 6–8: Six months after bone augmentation.
Figs. 9 & 10: Implant placement.
Figs. 11–14: Healing six weeks after implant placement.
Figs. 15 & 16: Case 2: Preoperative situation.
Fig. 17: Allogenic bone block stabilised with a single osteosynthesis screw. Lateral view, much of the spongious part was removed so there was a gap between residual bone and graft.

tical augmentation. Out of these 24 blocks, two were a failure due to soft tissue exposure and thus completely removed. The remaining blocks were loaded with 38 implants at later stages and all implants achieved good primary stability. Contar et al.⁹ also published their paper in 2009. A total of 34 osseous allogenic blocks were used in 15 patients, one block had an early exposure. A number of 51 implants were placed into the grafted area with sufficient primary stability. None of the implants were lost within an observation period between 24 to 35 months. Carinci et al.¹⁰ published a paper in 2010 where implants placed in the resorbed maxilla, which had been grafted with osseous allogenic blocks and reported a survival rate of 98.3% over a mean follow-up of 26 months. This study showed results comparable to same areas augmented with autologous iliac crest bone.¹¹ In 2015, Krasny et al.¹² published an article in which 21 patients were treated with 26 grafts. In two grafts, there were complications with soft tissue, and one augmentation had to be redone because of iatrogenic causes. After three to six months of healing, 33 implants were placed. Within an average observation time of 36 months (28–50), no implant had been lost. Araujo et al.¹³ published a systematic review on the same matter in 2013, in which a total of 253 osseous allogenic blocks were placed in 194 patients with a mean follow-up of twelve months (3–66). All studies showed good success from 95% to 100%.

Materials and methods

A total of 15 Patients were treated by the same surgeon in Godt Smil Odense from November 2013 to March 2015. Nine Patients were male, six were female. The youngest patient is 26 and oldest patient is 78-years-old. These 15 patients received 19 allogenic bone blocks to horizontally augment the atrophic alveolar process both in the mandible and in the maxilla prior to implant placement. All patients were in good general health, one was a smoker. All patients underwent periodontal therapy, if needed, before surgical intervention.

Surgical procedure

Premedication is 2,000 mg Imdrax (Amoxicillin), 1,000 mg Pinex (Paracetamol) and 400 mg Ibuprofen (Ibuprofen) 60 minutes before treatment. All Patients were instructed to rinse their mouth with 0.05% Chlorhexidine solution twice for one minute. The same strength of chlorhexidine solution was used for the perioral skin using a chlorhexidine-impregnated gauze. Local anaesthesia was administered as infiltration buccally and palatally/lingually (Xyloplyin® dental adrenalin 20 mg/ml + 12.5 microgram/ml lidocain hydrochlorid + adrenalin, DENTSPLY). Venous blood was sampled with a so-called butterfly (Vacuette® Greiner bio-one). The blood was collected in 10 ml

in a place that has no borders,
creativity goes unbound...



VCONCEPT[®] By
mis[®]
SET THE VOLUME

Albert Einstein once said "look deep into nature and then you will understand everything better". We are proud to introduce you to our VCONCEPT, based on natural design. Ingenuity that leaves more bone volume, more soft tissue volume, more room for nature. Because in a place that has no borders, creativity goes unbound... To learn more about VCONCEPT visit: www.vconcept.com

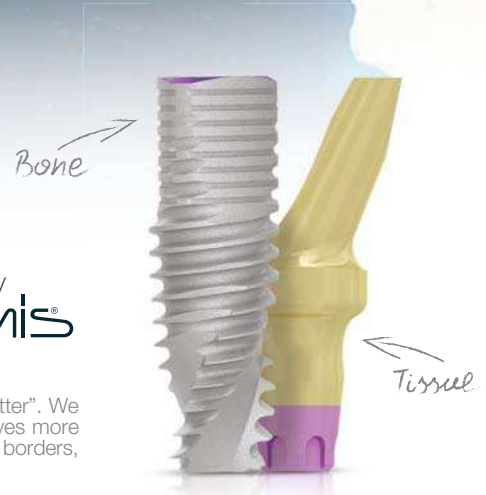
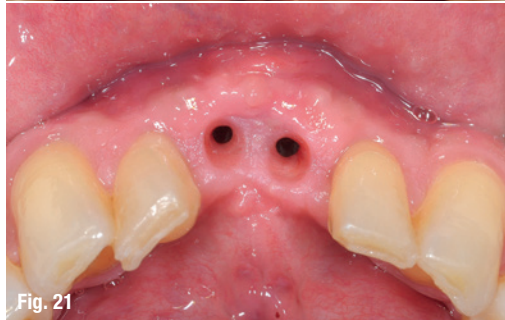
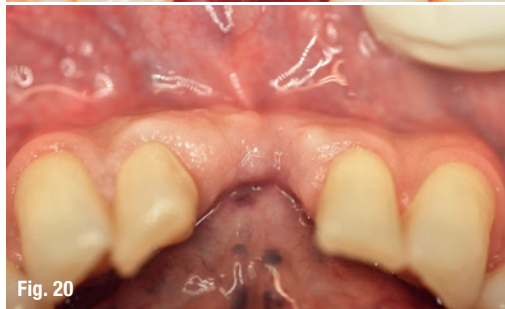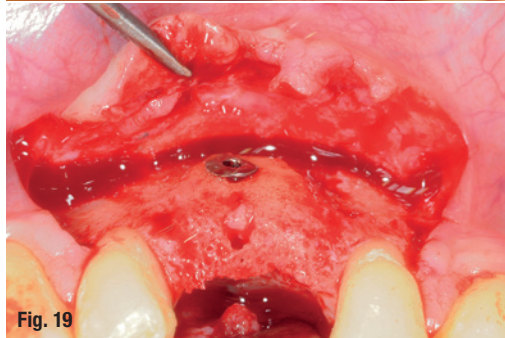
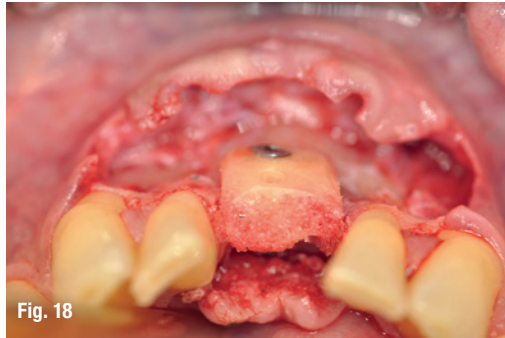


Fig. 18: Allogenic bone block, occlusal view.

Fig. 19: Allogenic bone block, integrated after six months of healing.

Figs. 20 & 21: Before and after surgical intervention.



tubes (A-PRF[®]+) and centrifuged according to Choukroun's protocol.

A mucoperiosteal trapezoid flap was raised exposing the defect area. Neighbouring teeth were cleaned of any debris. Allogenic bone blocks weather, J bone or Iliac crest, were customised chairside and fixed to the recipient site with osteosynthesis screws. The block was further adjusted after fixation has taken place, making sure there were no sharp edges and keeping the graft at least 1 mm away from any tooth surface. A PRF was placed over the block and healing was done by primary intention. Sutures were Resilon (Glycolon 5-0). Postoperative medication was Imadrax (Amoxicillin), 1,000 mg twice a day for three days, Ibumetin (Ibuprofen, 400 mg) in combina-

tion with 1,000 mg Pinex (Paracetamol) as needed. Six months later, when the implants were installed, survival of the graft was measured only by the integration of the graft from a clinical perspective, including no apparent pathology, bleeding from the graft during osteotomy and the possibility to place dental implants with or without minimal GBR.

Results

None of the patients reported any problems during healing. All 19 bone blocks were integrated to the recipient site and bleeding at osteotomy after six months of healing gave a 100% result. There was great variation in resorption that was measured from the head of the screw: nine cases showed no resorption from the head of the screw, the remaining cases showed resorption ranging from 0.5 to 1.5 mm from the head of the osteosynthesis screw. Peripheral areas of the blocks, however, can exhibit a higher degree of resorption, but they were not measured in any way in this study.

Discussion

It must be noted that none of the grafts were used for vertical augmentation. This sample is a part of a bigger sample that involves more complex bone augmentation with use of more types of biomaterials such as spongy allogenic bone, prefabricated or not. In the bigger sample, there were failures that were not present when the augmentation was strictly horizontal and done by corticospongyous blocks alone, indicating that this is a very predictable procedure when done like described in this case series.

The surgeon's opinion is that resorption is related to width of the augmentation, thickness of the cortex on the corticospongyous allogenic bone block after modification in the mouth, and area of the mouth, whereas the mandible showed more resorption. However, the surgeon's opinion is per se of low evidence, and these topics should be investigated more in well-planned studies.

contact

Dr Dadi Hrafnkelsson
Cand. Odont., M.Sc.
 Overtandlæge
 Godt Smil Odense/Horsholm
 Mogensensvej 24 c
 5000 Odense, Denmark
 Tel.: +45 28874904



Your confidence is our inspiration

World Summit Tour 2017—the scientific congress on implant dentistry


Join us for the World Summit Tour in 2017 and experience a state-of-the-art scientific program, workshops and product demonstrations, all designed to inspire and broaden your knowledge.

Through the presentation of clinical evidence and strategies for treatment success, as well as peer-to-peer discussions, you will gain renewed confidence knowing you are providing your patients with the best treatment solutions available.

To bring this common theme of inspiration and confidence to you, the World Summit Tour will visit Tokyo, San Diego, Nice, and Shanghai. Each destination offers a journey of innovation and discovery led by a scientific committee and renowned international and regional speakers. Personalize your experience to best fit your interests and needs by combining general sessions, hands-on workshops, and your choice of various parallel sessions.

Don't miss your chance to experience the dynamic and powerful synergy of people, science and clinical practice.

Because inspiration and confidence matters.



**WORLD
SUMMIT
TOUR 2017**

TOKYO *San Diego*
NICE *SHANGHAI*

International Scientific Committee



Tomas Albrektsson
Sweden



Christoph Hämmerle
Switzerland



Ye Lin
China



Jan Lindhe
Sweden



Clark Stanford
USA



Meike Stiesch
Germany



Tetsu Takahashi
Japan



#WorldSummitTour
www.worldsummittour.com

**Dentsply
Sirona**
Implants