A variety of photo-coagulation techniques

Haemostasis in oral soft tissue and extraction socket

Authors: Chaivasan Malakam, Nuttakarn Rungrojwittaya, Nattaya Sanposh & Sajee Sattayut, Thailand

Introduction

There is a variety of surgical procedures, such as soft tissue biopsy and surgical extraction, which usually results in difficulties for haemostasis. One of the major concerns in oral surgery is to minimise bleeding and postoperative complications. Currently, a number of laser wavelengths have been used in oral surgery and dentistry, including CO_2 laser, Nd:YAG laser, argon laser, diode lasers in various wavelengths, Er:YAG laser and potassium titanyl phosphate (KTP) laser. Their applications were soft tissue procedures, such as gingivectomy and gingivoplasty, excision of tumors and lesion, incisional and excisional biopsies, frenectomy, control of bleeding in vascular lesions, arthroscopic temporomandibular joint surgery, caries diagnosis and removal.[1,2]

The photothermal reaction, which depended on the tissue absorption of the laser energy, played an important part in the laser-surgery procedure with hemostasis.[3] This reaction was mainly applied in soft tissue surgery comprising 1) photoablation, 2) photovaporisation, and 3) photocoagulation. Each reaction or a combination of reactions occurred with varied laser parameters and procedures.

Regarding the procedure with pure photocoagulation, there have been various techniques of laser application[4,5] or light-emitting diodes in dental prac-

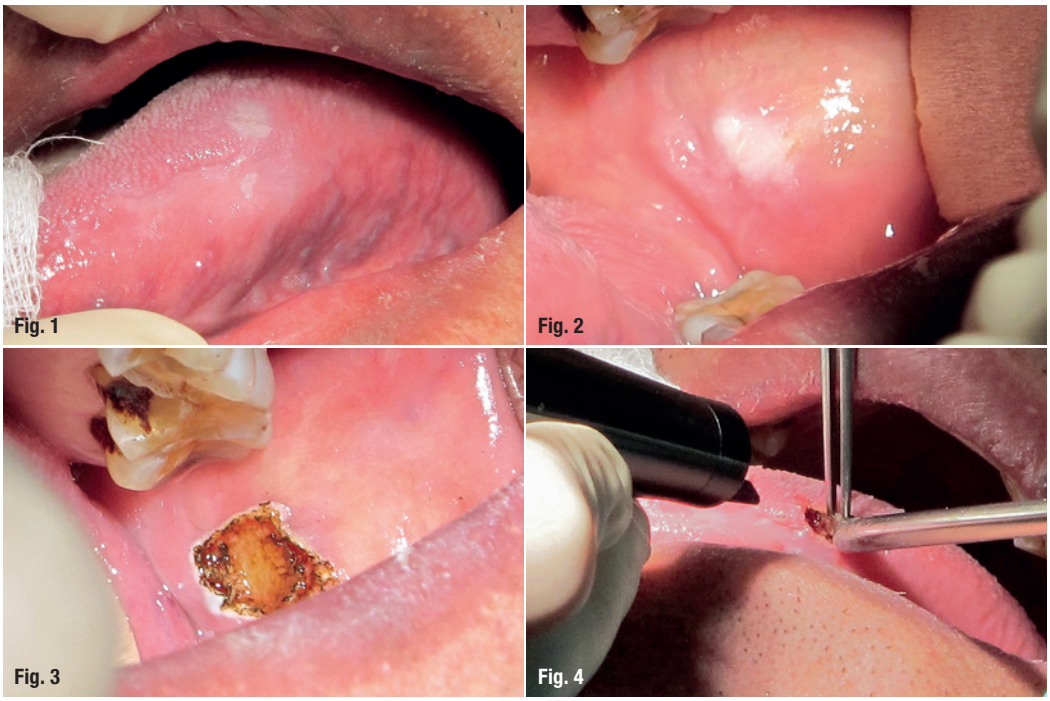

Fig. 1: Left lateral border of the tongue with 6 mm and 2 mm in diameter of leukoplakia in the tongue.
Fig. 2: Buccal mucosa with a 7-mm diameter and whitish moderate-thickening lesion.
Fig. 3: Post-CO_2 excision of the lesion was completed with no active bleeding.
Fig. 4: Intra-operation of CO_2 excisional biopsy (photoablation).

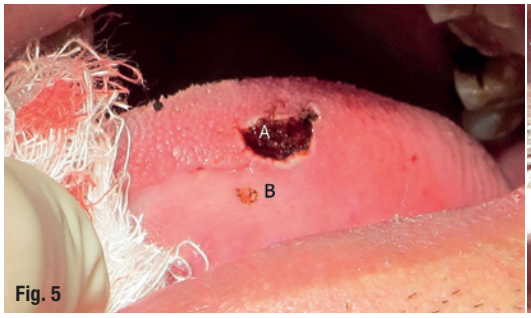

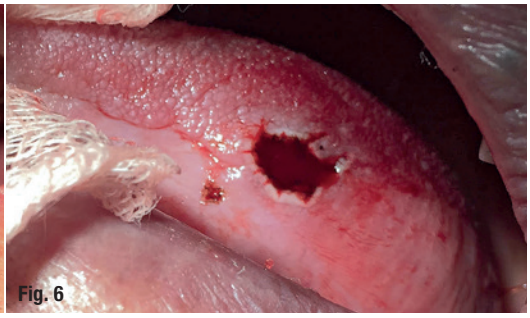

Fig. 5: Immediate postoperative view; **A)** oozing in the surgical area after CO_2 laser photoablation; **B)** coagulative surgical area after CO_2 laser vapourisation.
Fig. 6: Immediate post-photocoagulation using LED showed an initial blood clot formation without oozing.

tice[6], which were well absorbed by haemoglobin for achieving haemostasis after oral surgery. In the following case reports, we present a variety of photocoagulation techniques in cases of soft tissue biopsy, simple extraction socket and surgical removal of the wisdom tooth involving hard tissue surgery. The clinical outcomes of haemostasis and patient satisfaction are also reported.

Case 1: Photocoagulation for soft tissue haemostasis in excisional biopsy by LED light unit

A 65-year-old male patient presented at the Department of Oral and Maxillofacial surgery, Faculty of Dentistry Khon Kaen University, with a whitish lesion at the left lateral border of the tongue. In the past three months, the patient was treated with low intensity laser therapy and topical steroid for the chronic ulceration at the left lateral border of the tongue. The ulcer was healed with a coverage of the whitish patches. There was also a whitish lesion at the buccal mucosa of the left cheek with intermittent pain on palpation.

The clinical examinations showed three non-scrapable whitish lesions as follows: 1) a moderate thickening whitish patch at the left lateral border of the tongue, measuring approximately 6 mm in diameter; 2) a mild thickening whitish lesion at the left ven-

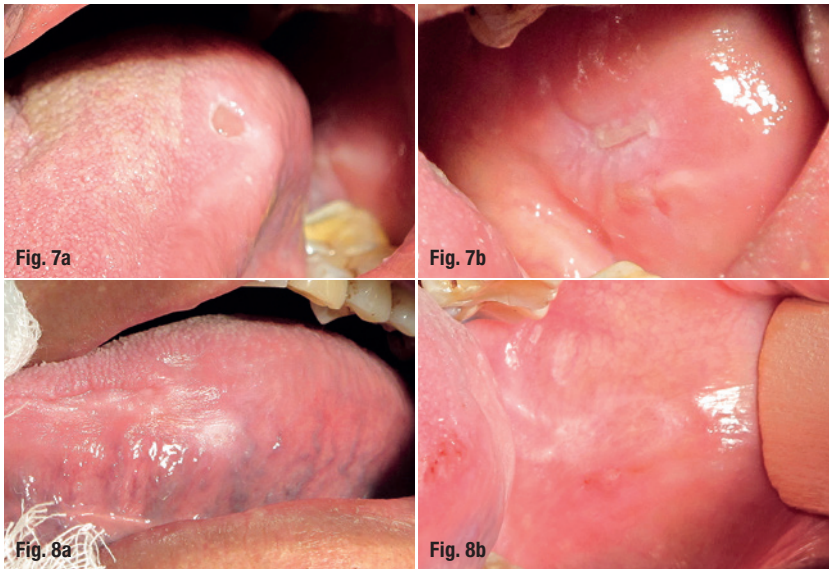

Figs. 7a & b: Two-week post photoablation biopsy and the healing with coagulum coverage.
Figs. 8a & b: Five-week follow-up after photoablation biopsy, complete coverage with mild whitish mucosa.

tral side of the tongue, measuring approximately 2 mm in diameter (Fig. 1); and 3) a moderate thickening whitish patch at the buccal mucosa of the left cheek, measuring approximately 7 mm in diameter (Fig. 2).

The surgical procedure involved local anaesthesia (2 % lidocaine with epinephrine 1:100,000) and excisional biopsy of the lesions at the buccal mucosa by using 10,600 nm CO_2 laser at 5 W and continuous wave. Then tissue coagulation for haemostasis was undertaken using a defocused CO_2 laser at 3 W and continuous wave. The ablation with haemostasis was easily achieved (Fig. 3).

At the left lateral border of the tongue, the photoablation was undertaken using a 10,600 nm CO_2 laser at 5 W and continuous wave (Fig. 4). After excisional biopsy, there was an active bleeding over the lesion because of a highly vascularised tissue (Fig. 5-A). A blue light-emitting diode (LED) for dental practice (WOODPECKERTM LED light unit; a single blue light source non-heat producing, energy density 1,000-1,200mW/cm^2) was irradiated for 5 seconds to the oozing area. This was repeated for four episodes to gain an initiating blood clot (Fig. 6). For the smaller lesion at the ventral side of the tongue, the vapourisation technique was applied using 10,600 nm CO_2 laser at 3 W and continuous wave. There was no active bleeding at the surgical site (Fig. 5).

Fig. 9: Oozing at the sockets of bleeding after tooth extraction.
Fig. 10: Immediate post-photocoagulation using LED showed an initial blood clot formation.

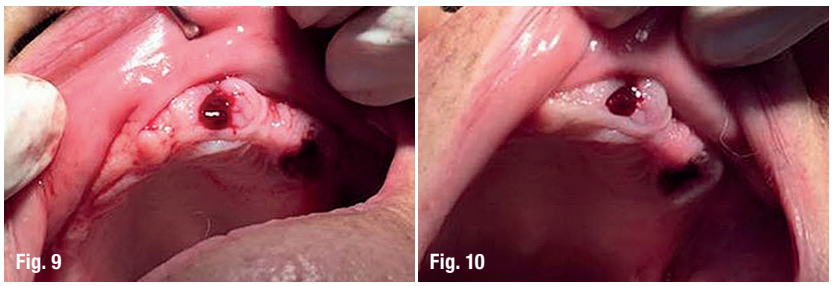

Clinical results

The outcome after using laser for surgical removal of the soft tissue lesion showed ablation with haemostasis except the lesion at lateral border of the tongue, a site with high vascularity. In this case, the irradiation of LED at the active bleeding area promoted blood clot formation without producing any clinical soft tissue destruction. Furthermore, soft tissue biopsy using laser had many advantages, for example, providing a dry clean surgical field enhancing visibility for the operator and reducing operation time. At the two-week follow-up, there was soft tissue healing with some coagulum coverage and no clinical signs of inflammation or infection (Figs. 7a & b). The histopathology investigation was obtainable. In this case, epithelial keratosis was diagnosed. The five-month follow-up after excisional biopsy showed complete healing of the mucosal coverage with some thin whitish areas and without tethering of the scar (Figs. 8a & b). Based on the histopathological finding, these should be in a condition for observation.

Patient satisfaction

Without any efforts to stop bleeding such as biting on gauze pads, he felt more confident with regard to the operation being necessary and agreed with routine follow-up. There was still no pain and bleeding interfering routine activities after laser surgery.

Case 2: Photocoagulation for hard tissue haemostasis after routine tooth extraction by LED light curing unit

The second case study was a 66 year-old woman who had a history of diabetes mellitus and hypertension. The upper left canine and second premolar were diagnosed "chronic periodontitis". The tooth extraction was requested as a treatment. Routine tooth extraction was performed under local anaesthesia; 2 % mepivacaine with 1:100,000 epinephrine. The LED at an energy density of 1,000-1,200 mW/cm^2 was irradiated at the extraction socket for 5 sec per cycle for a total of four episodes.

Clinical results

There was an oozing of bleeding after extraction (Fig. 9). An initial clot occurred in the bony socket immediately after LED photocoagulation procedure (Fig. 10).

Patient satisfaction

The patient seemed to be anxious about the operation at the beginning. After using LED light photocoagulation to accelerate blood clot formation into the sockets, she seemed more comfortable and satisfied with the procedure with no need to be worried about pressure compression by biting a gauze.

Case 3: Photocoagulation for surgical site after surgical removal of impacted tooth by 790 diode laser

A 19 year-old woman with no systemic disease presented with a lower right third molar partial bony impaction. This needed to be removed by surgical extraction. The standard procedure including flap operation, osteotomy and tooth section was conducted under local anaesthesia; 2% mepivacaine with 1:100,000 epinephrine. After the tooth was delivered, there was bleeding in the bony socket (Fig. 11). A 790 nm diode laser at 0.3 W was used to irradiate the socket and wounded area for 30 sec per cycle, for a total of two episodes. An initial blood clot was found (Fig. 12).

Clinical results

There was no active bleeding, but an immediate haemostasis in the surgical removal area, which was different compared to our experiences of using standard technique. Also the healing in a week was favourable (Figs. 13a & b).

Patient satisfaction

The patient seem to be satisfied with immediate haemostasis after the operation.

Case 4: Photocoagulation for bony socket and soft tissue haemostasis after surgical removal of soft tissue impaction by 808 nm diode laser

A 26 year-old woman with no systemic disease had a chief compliant of a lower right third molar soft tissue impaction. The surgical removal was required for treatment. The standard procedure including flap operation ostectomy and tooth section was conducted under local anesthesia; 2% mepivacaine with 1:100,000 epinephrine. After the tooth was delivered, there was bleeding in the bony socket (Fig. 14). An 808 nm diode laser at 0.5 W was used to irradiate the socket and wounded area for 5 sec per cycle and a total of four episodes. The initial blood clot with some carbonisation was found (Fig. 15).

Clinical results

There was no active bleeding and an immediate haemostasis in the surgical removal area, which was different from our experiences of using standard technique.

Patient satisfaction

The patient seem to be satisfied that there was no bleeding after the operation.

Discussion

Although the CO_2 laser was commonly used in the surgical removal of intraoral lesions due to the limitation of lateral damage, which made specimen available for histopathological investigation together with the ability of sealing of vessels up to 500 micron in diameter,[7-9] we experienced insufficient tissue coagulation at the lateral border of the tongue in case 1. In this case, we used the LED photocoagulation in order to avoid photoablation and carbonisation effect.

The benefits of using lasers in oral surgical procedures were clinically significant to both the dental surgeons and the patients. All techniques and wave-

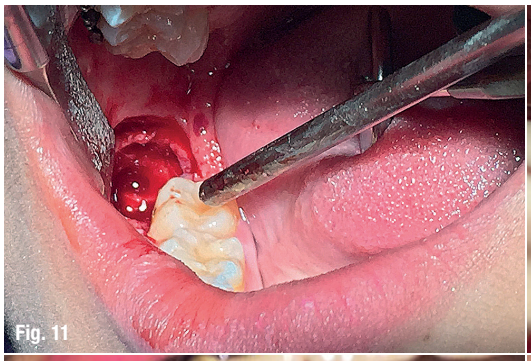

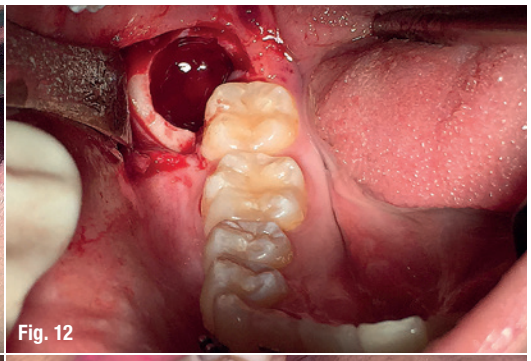

Fig. 11: After surgical removal of the lower right third molar impaction, it was oozing via the bony socket.
Fig. 12: Initial blood clot formation without oozing was found immediately after post-photocoagulation using a 790 nm diode laser.
Figs. 13a & b: One week after operation, there was no complication. Surgical wound healing was observed.

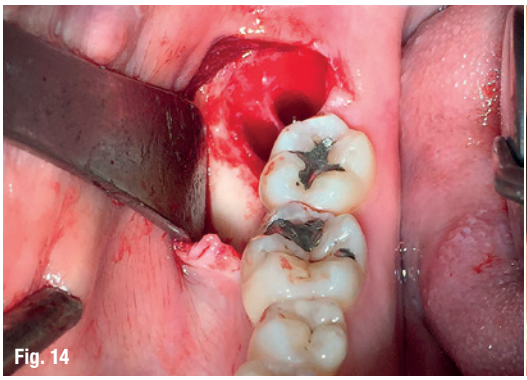

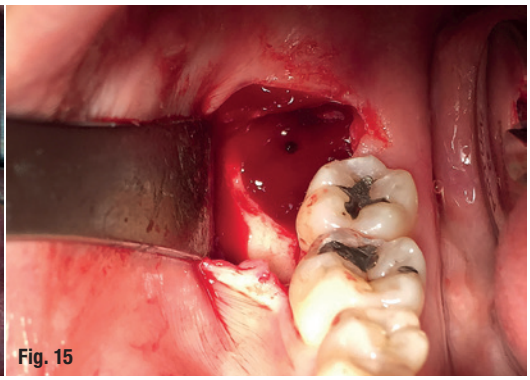

Fig. 14: After surgical removal of the lower right third molar impaction, it was oozing via the bony socket.
Fig. 15: Initial blood clot formation without oozing was found immediately after post-photocoagulation using 808 nm diode laser.

lengths used in these case reports were able to create immediate haemostatic effect on soft tissue and bone socket without any complication. It was noticed that, using 808 nm diode laser, at least the parameter used in case 4 was able to produce some carbonisation, while LED and 790 nm did not show such an effect. Therefore, using 800 nm diode laser for photocoagulation may make reducing irradiation time or power necessary to avoid a photovapourisation effect.

With regard to wound healing, the results from soft tissue laser biopsy were favourable. These were supported by in vivo studies showing laser wounds found a significantly lower number of myofibroblast and inflammatory cells, resulting clinically in less wound contracture and less post-operative complication for inflammation.[10,11] In our reports, these clinical benefits were also found in the cases limited to photocoagulation such as case 3.

Conclusion

Both LED (single blue light source, non-heat producing) and diode laser of 790 nm at 0.3 W and 808 nm at 0.5 W were able to produce localised coagulation and enhance haemostasis in soft tissue after excisional biopsy and bone-socket due to tooth extraction and surgical removal. The results showed successful management in terms of clinical outcome of haemostasis and healing together with patient's satisfaction.

Acknowledgement

We absolutely thank Dr. Rattiya Hathaidechadusadee, postgraduate student in oral and maxillofacial surgery, Faculty of Dentistry, Khon Kaen University, for being an operator in the surgical removal of impaction and all members of staff in LDRG-KKU and Faculty of Dentistry, Khon Kaen University. We are also very thankful for every patient who trusted us and permitted data to be reported._

contact

Assoc. Prof. Sajee Sattayut DDS, PhD
Lasers in Dentistry Research Group,
Khon Kaen University
Department of Oral and Maxillofacial Surgery,
Faculty of Dentistry, Khon Kaen University
123 Mittraphap Rd. Amphur Muang
Khon Kaen, KhonKaen,
Thailand 40002
Tel.: +66 0935466178
Fax: +66 43202862
sajee@kku.ac.th

Author details

Kurz & bündig

Im Rahmen von Laseranwendungen mit Hämostase spielen photothermale Rekationen in Abhängigkeit vom Absorptionsvermögen des Gewebes für Laserenergie eine entscheidende Rolle. Diese Wechselwirkungen finden vor allem in der Weichgewebschirurgie mit Photoablation, Photovaporisation und Photokoagulation Anwendung. Jede Gewebsreaktion oder eine Kombination dieser tritt dabei bei unterschiedlichen Laserparametern und -anwendungen auf. In den hier vorgestellten Fallberichten erläutern die Autoren eine Vielzahl von Techniken der Photokoagulation bei Weichgewebsbiopsie, an der Extraktionsalveole oder im Rahmen der chirurgischen Entfernung eines Weisheitszahns im Zusammenhang mit der Hartgewebschirurgie. Zusätzlich berichten die Autoren auch über Hämostase und Patientenzufriedenheit bei verschiedenen Laseranwendungen und -wellenlängen. Dabei konnten sowohl LED (einfache blaue Lichtquelle ohne Wärmeentwicklung) als auch Diodenlaser mit 790 nm und 0,3 W sowie 808 nm und 0,5 W eine lokalisierte Koagulation erzielen und die Hämostase verbessern. Die Ergebnisse zeigen ein erfolgreiches Management der klinischen Ergebnisse in Bezug auf Hämostase, Heilungsverlauf und Patientenzufriedenheit.

Literature

Dear authors, thank you for your contributions in 2016. Looking forward to working with you in 2017!



1/16

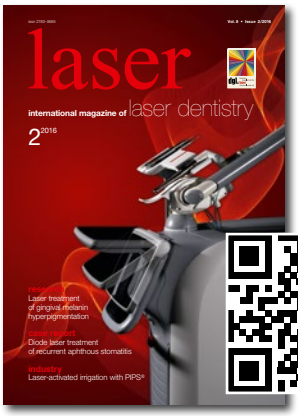

2/16

3/16

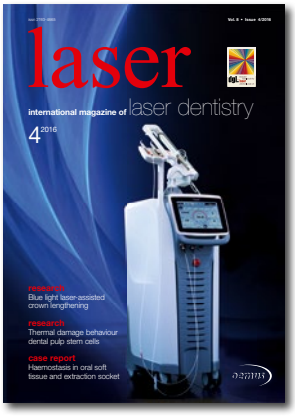

Happy New Year

© ciccino77/Shutterstock.com

Please contact:

Georg Isbaner · Editorial manager
g.isbaner@oemus-media.de