

# Dynamic navigation for precise implantation in cases of critical anatomy

**Author:** Dr David Burgess, United Kingdom

## Introduction

Using the CBCT image as a map, dynamic navigation guides surgeons just like a GPS guides drivers. The clinician virtually plans where implants should be placed. During surgery, the navigation system dynamically tracks the drill and the patient's jaw, providing guidance and visual feedback to ensure the implants are placed according to plan.

There are several advantages with dynamic navigation. The technology allows clinicians to place implants more accurately than free-hand. This results in improved safety and aesthetics, as it helps the clinician to anticipate and to avoid potential complications.

Other advantages are the ability to have more minimal invasive treatments, which means less chair time, less patient discomfort and less recovery time. This treatment option has generally been seen as a 'blind' procedure in the past, but the ability to avoid delicate anatomical structures due to the real-time surgical feedback makes so-called flapless surgery a valuable option.

In the following case report, Dr David Burgess describes how using computer-guided dynamic navigation helped him overcome clinical challenges for dental implant placement in the lower posterior region.

## Case report

A 75-year-old male patient had endured a gap for five years, following removal of his lower left second molar, due to an acute apical infection. He was finding mastication increasingly difficult and sought advice about the treatment options available.

## Planning for optimum implant positioning

As there was no tooth distal to the space, conventional fixed bridgework was not possible. The treatment options were either a unilateral single saddle



© Tom Pitkin Photography

## info

Dr Burgess is holding four hands-on courses in 2017 for experienced implant dentists who want to incorporate dynamic navigation into their digital workflow.

Courses are available on 28 April, 16 June, 11 August and 22 September.

For further information, course reservations or other related requests, email: [dns@claronav.com](mailto:dns@claronav.com)



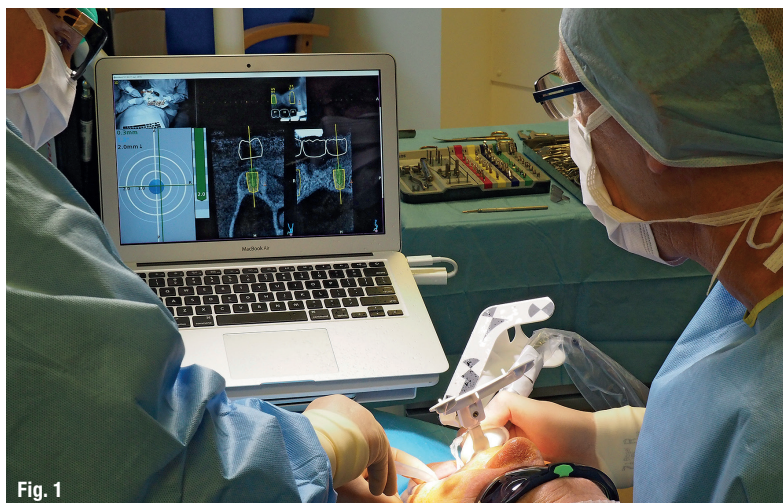


Fig. 1

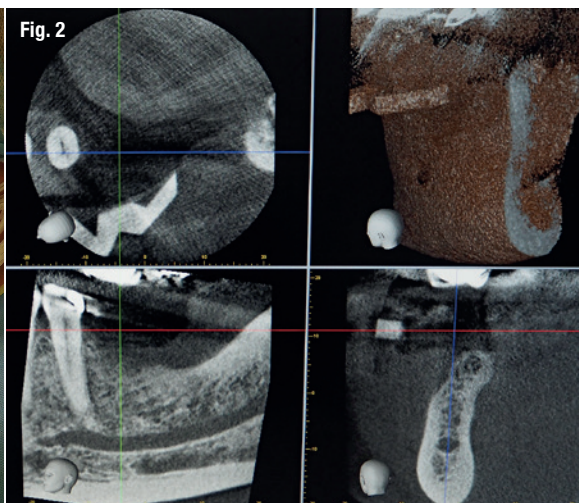


Fig. 2

**Fig. 1:** An illustrative image of Dr Burgess using Navident. – **Fig. 2:** A CBCT scan was taken two weeks prior to surgery. – **Fig. 3:** The treatment plan was created immediately after the scan. – **Fig. 4:** The patient was able to see the proposed treatment displayed by the Navident software.

lower partial denture or restoration of the space with two dental implants. The patient chose to have dental implant treatment as he did not wish to have any form of removable prosthesis.

What makes Navident dynamic navigation stand out is it precisely guides the surgeon to prepare and place the implant in a pre-determined position (Fig. 1). This allows me to achieve greater accuracy and certainty than I have previously been able to, using conventional protocols. Whilst there is no physical guide, a simple scanning template (NaviStent) is used to hold the fiducial in place whilst taking the CT scan, and secure the jaw reference (JawTag) for the navigated osteotomy.

In this case, the NaviStent was fabricated, the fiducial marker attached and a CBCT scan taken two weeks prior to surgery (Fig. 2). The treatment plan was created immediately after the scan (Fig. 3), with the patient present. He was able to see the proposed treatment displayed by the Navident software and appreciated that great care was being taken to achieve the optimum implant positioning, with minimal risk of potential complications (Fig. 4). The patient was impressed with, and reassured by, the state-of-the-art technology.

### Confidence from continuous feedback

Treatment was carried out under local anaesthesia. Prior to preparation of the implant sites, the simple Navident protocol for calibration and verification of the drill axis and drill tip was carried out. A crestal incision was made, with a minimal flap reflected. The software shows the drill position on

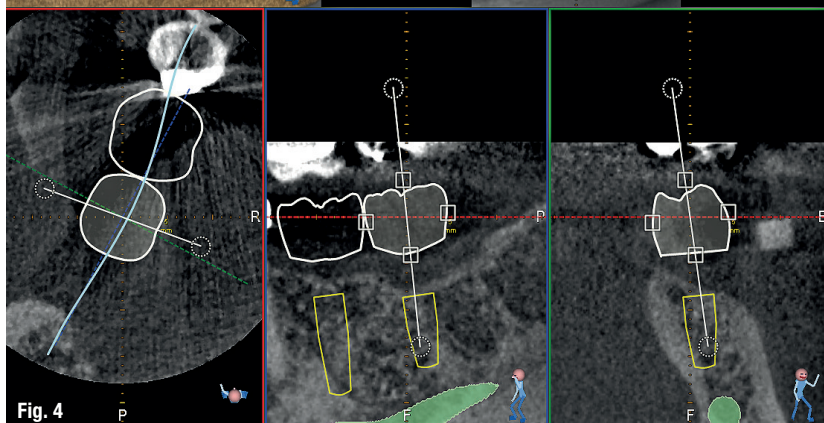
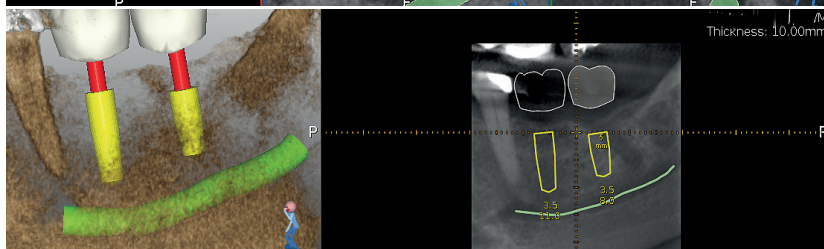
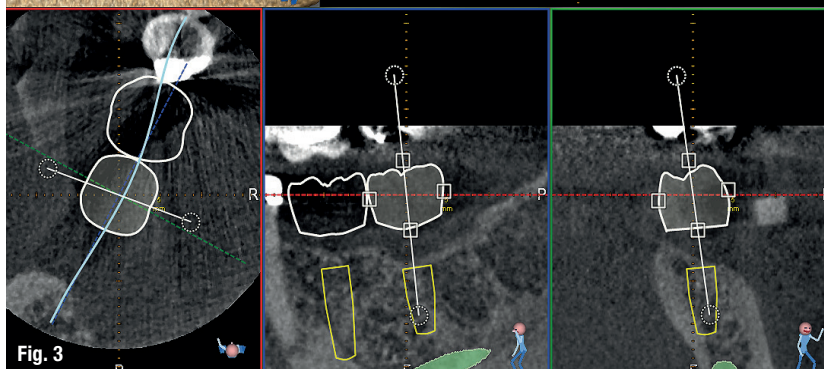
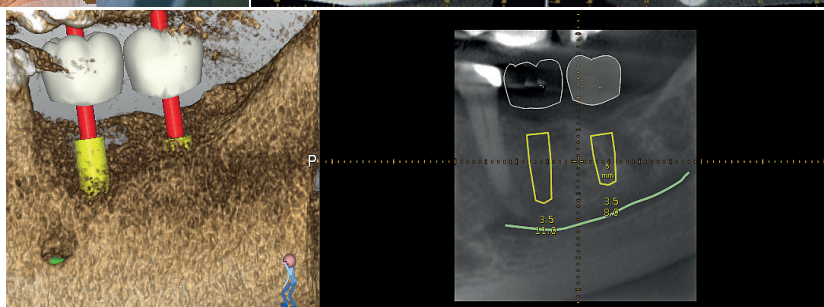
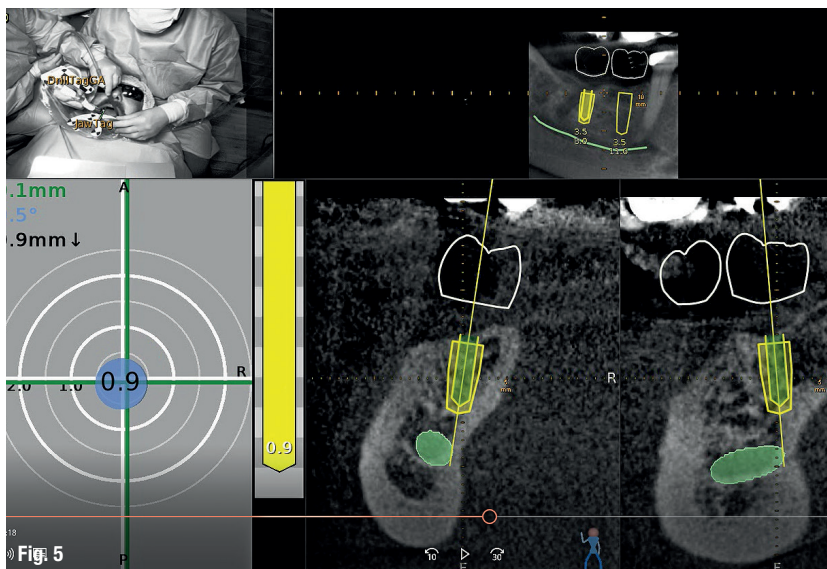


Fig. 4



**Fig. 5:** I was able to achieve the best buccal and lingual position of the implants, and their relation to each other and to adjacent teeth.

the scan in real time, as it enters the jaw. This allows adjustments to be made, if necessary, whilst the site is being drilled. Two Dentsply Ankylos® CX 3.5 mm diameter dental implants were placed sub-crestally in the lower left first and second molar sites, with implant lengths of 11 mm and 9.5 mm respectively.

Avoiding damage to the inferior alveolar nerve was a crucial factor in the treatment planning of this case. Access was difficult, due to the limited opening of the patient's mouth. The issue was compounded by the plan to place an implant as distal as the second molar. These challenges were overcome using Navident's continuous internal visual feedback, which gave the author the confidence to use the optimum length of implant, whilst staying within a safe distance from the inferior alveolar nerve and avoiding post-surgical complications, such as paraesthesia.

Navident provided guidance for accurate implant location, even with restricted visibility and the drill being impeded by opposing teeth. Tactile feedback can often be reduced when using a physical drill guide. Dynamic navigation removes this obstacle. The author was able to achieve the best-possible buccal and lingual position of the implants, and their relation to each other and to adjacent teeth (Fig. 5). This would allow for optimal shape, position and occlusal function of the final restorations.

Ankylos® Balance posterior sulcus formers were fitted and the incision was closed with simple interrupted sutures. There was no need for bone augmentation. Two to three months after surgery, the implants will be restored with Atlantis® custom-made CAD/CAM titanium abutments and screw-retained linked zirconia crowns.

## Conclusion

The clinical outcome was excellent. The planned placement was restoratively driven and the implants were well positioned, with good primary stability. Having used the Navident dynamic navigation system for more than a year, the author would not want to go back to preparing and placing dental implants without its 3-D visual guidance. The patient was comfortable and reassured, with no postoperative pain, swelling, bruising or paraesthesia. He was delighted and, if he needed any implant treatment in the future, would insist on dynamic navigation.

## About Dr David Burgess BDS DPDS MScConSed

David Burgess has been principal of Carbis Bay Dental Care in Cornwall since 1988 and has placed over 2,000 implants. Throughout his career, David has striven to combine clinical perfection with the ultimate in patient care. He has been a willing pioneer of new technology, particularly in the field of digital dentistry. David was the first UK clinician to introduce the Navident dynamic navigation system into his implant treatment workflow, with the objective of achieving a higher degree of precision and greater patient comfort.

David Burgess is also a member of the Dynamic Navigation Society as a Master Clinical Trainer, providing courses for implantologists who wish to experience how dynamic navigation can help to simplify their digital workflow. More information can be found on <http://dns.claronav.com>.

## contact

### Dr David Burgess

Carbis Bay Dental Care  
6-7 Boskerris Terrace  
St Ives Road, Carbis Bay, St Ives  
Cornwall TR26 2SF, United Kingdom  
Tel.: +44 1736 793090  
carbisbaydental@btconnect.com  
www.carbisbaydental.co.uk

Author details





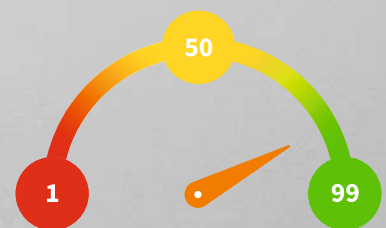


# Penguin<sup>RFA</sup>

MONITOR OSSEOINTEGRATION



- ▶ Autoclavable  
20 times
- ▶ ISQ Standard  
Calibrated™
- ▶ Optimal platform fit
- ▶ Laser marked with  
type number



The ISQ-scale is from 1–99 and tells you how stable your implants are.