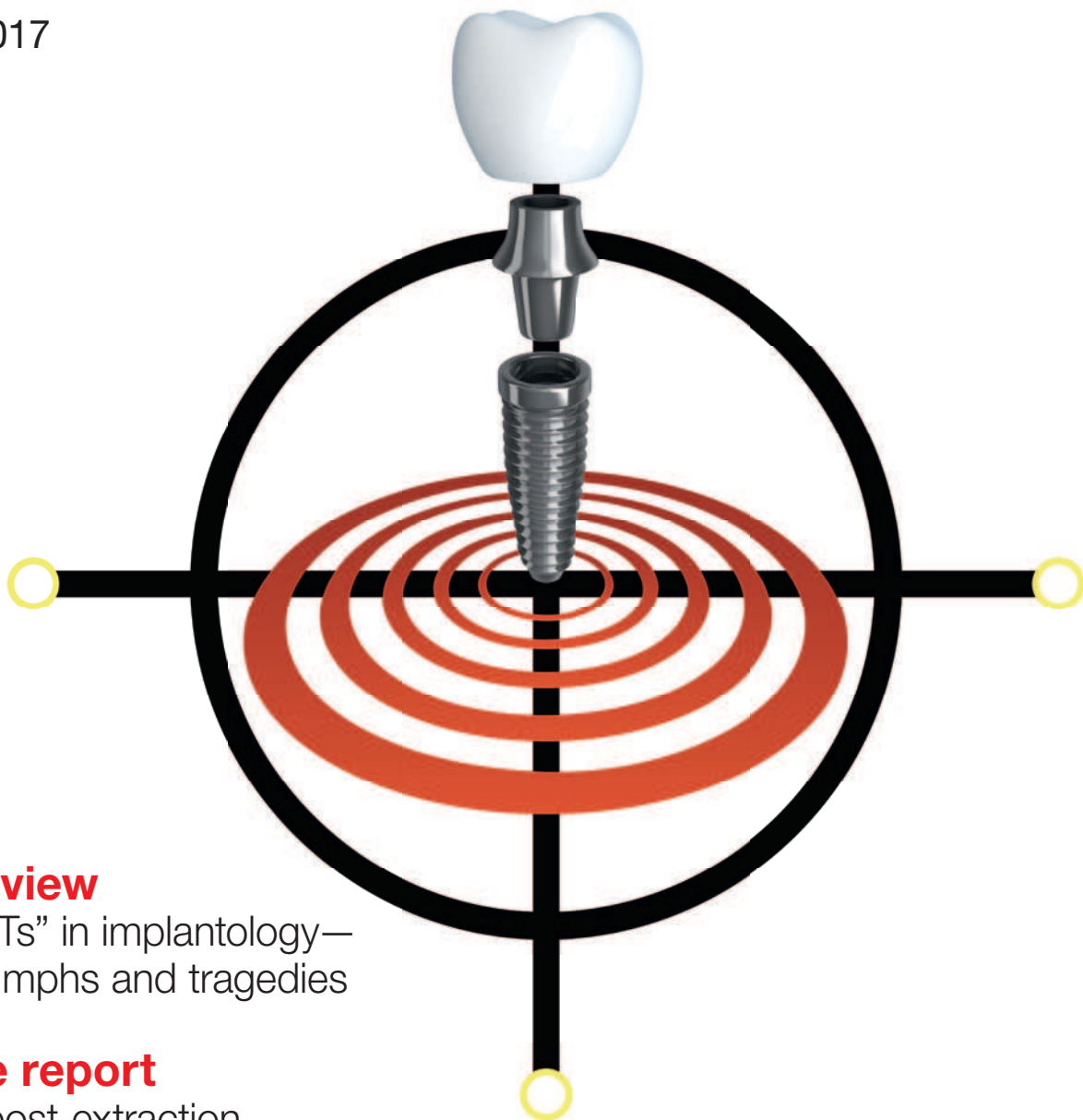


# implants

international magazine of oral implantology

1 2017



## overview

The “Ts” in implantology—  
of triumphs and tragedies

## case report

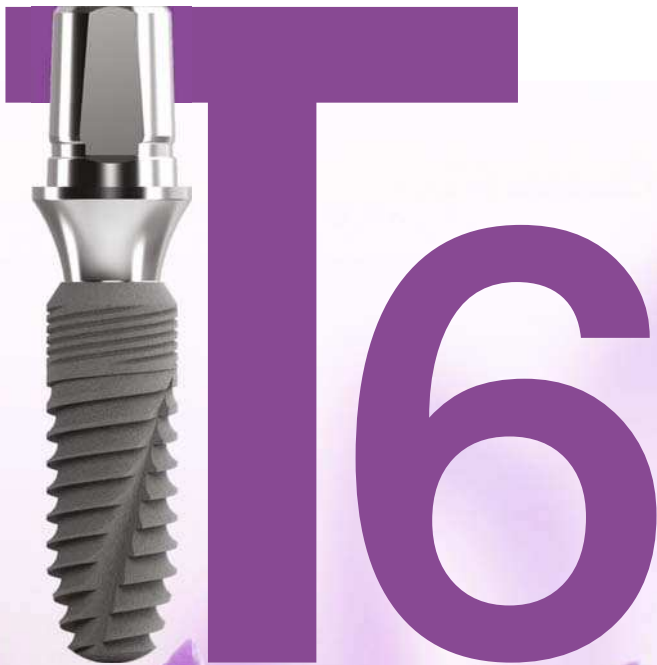The post-extraction  
immediate implant

## industry

Dynamic navigation for  
precise implant placement



much **more**  
implant



*Smart Designs  
Brave Smiles...*

# Full speed ahead— Implantology in 2017



Dr Rolf Vollmer

Dear colleagues,

2017 seems to have plenty to offer with regard to implantology: The DGZI has already started invitations for its scientific awards presented at the 47<sup>th</sup> International Annual DGZI Congress on 29 and 30 September in Berlin, Germany. This includes the DGZI Implant Dentistry Award 2017 (5,000 EUR) as well as the DGZI Thesis Award 2017 (2,000 EUR). The final deadline for both of the two awards is 31 May 2017.

And of course, the 37<sup>th</sup> International Dental Show in Cologne, Germany, already is promising to become another record-breaking dental trade show, once more featuring innovations in implantology as the driving force behind dentistry. Numerous new partnerships will enhance integrative workflow solutions, both digital and analogous. At each new IDS, we observe new market participants contributing their entrepreneurial spirit and determination to the greater good of a progressing health industry.

In this regard, I would especially like to point out the latest developments in zirconium dioxide-based implant systems. In this branch, we can find several companies offering their new and innovative systems to the still growing niche sector of ceramic implant technology. However, conventional titanium-based implant systems and their progresses are presented at or will have their debut at the IDS. This gives both specialists in implantology and oral surgery the demanding task to wisely choose among the many innovations presented at this year's International Dental Show.

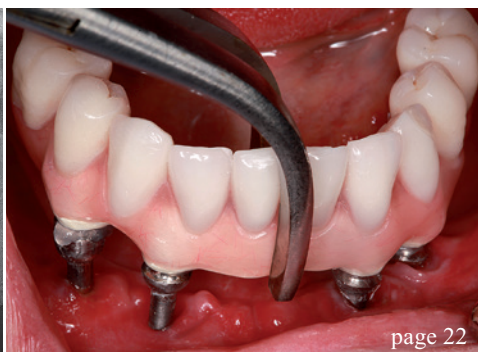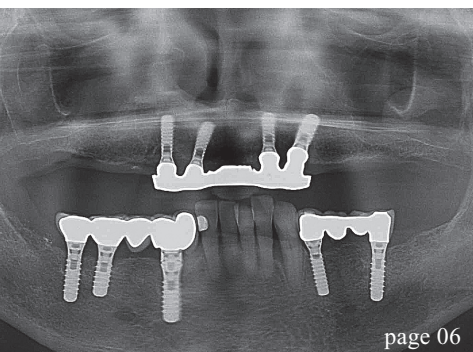
Which leaves me only to wish you a pleasant and informative reading of this latest issue of **implants international magazine of oral implantology**, hoping that it will give you helpful input for your decision-making process.

For this, you can find us at the IDS booth of OT medical (hall 11.2., L060), our long-term industrial partner and main sponsor of our annual congresses. You can also learn more about our international annual congresses and other international educational events and activities. Please contact the DGZI headquarters if you wish to make appointments in advance.

With warm collegial regards,

Dr Rolf Vollmer

First Vice President and Treasurer of the German Association of Dental Implantology



**editorial**

- 03 **Full speed ahead—Implantology in 2017**  
Dr Rolf Vollmer

**overview**

- 06 The “Ts” in **implantology**—  
of **triumphs** and **tragedies**  
Dr Georg Bach

**case report**

- 16 The **post-extraction** immediate implant  
Prof. Dr Mauro Labanca, Dr Ernesto Amosso &  
Prof. Dr Luigi F. Rodella

**industry**

- 22 **TRINIA™**—**Metal-free** restorations  
Prof. Dr Rolf Ewers, Paolo Perpetuini,  
Dr Vincent J. Morgan, Prof. Dr Mauro Marincola,  
Richard Wu & PD Dr Rudolf Seemann
- 28 **Dynamic** navigation for **precise** implantation  
in cases of **critical** anatomy  
Dr David Burgess

- 32 **Osteo-mucous restoration** and **implant-**  
**supported overdenture**  
Dr Ugo Torquati Gritti, Dr Daniele Vrespa,  
MDT Buongiovanni Armando & MDT Giancarlo Riva

**interview**

- 36 “The RFA **technique** must be **accurate**  
and **reliable**”

**events**

- 42 **Japan Annual Meeting 2016**  
of **ISOI** and **DGZI** in **Tokyo**  
Dr Rolf Vollmer

**news**

- 38 **manufacturer news**
- 46 **news**

**about the publisher**

- 50 **imprint**



Cover image courtesy of ClaroNav Inc.  
[www.claronav.com](http://www.claronav.com)

a perfect fit™

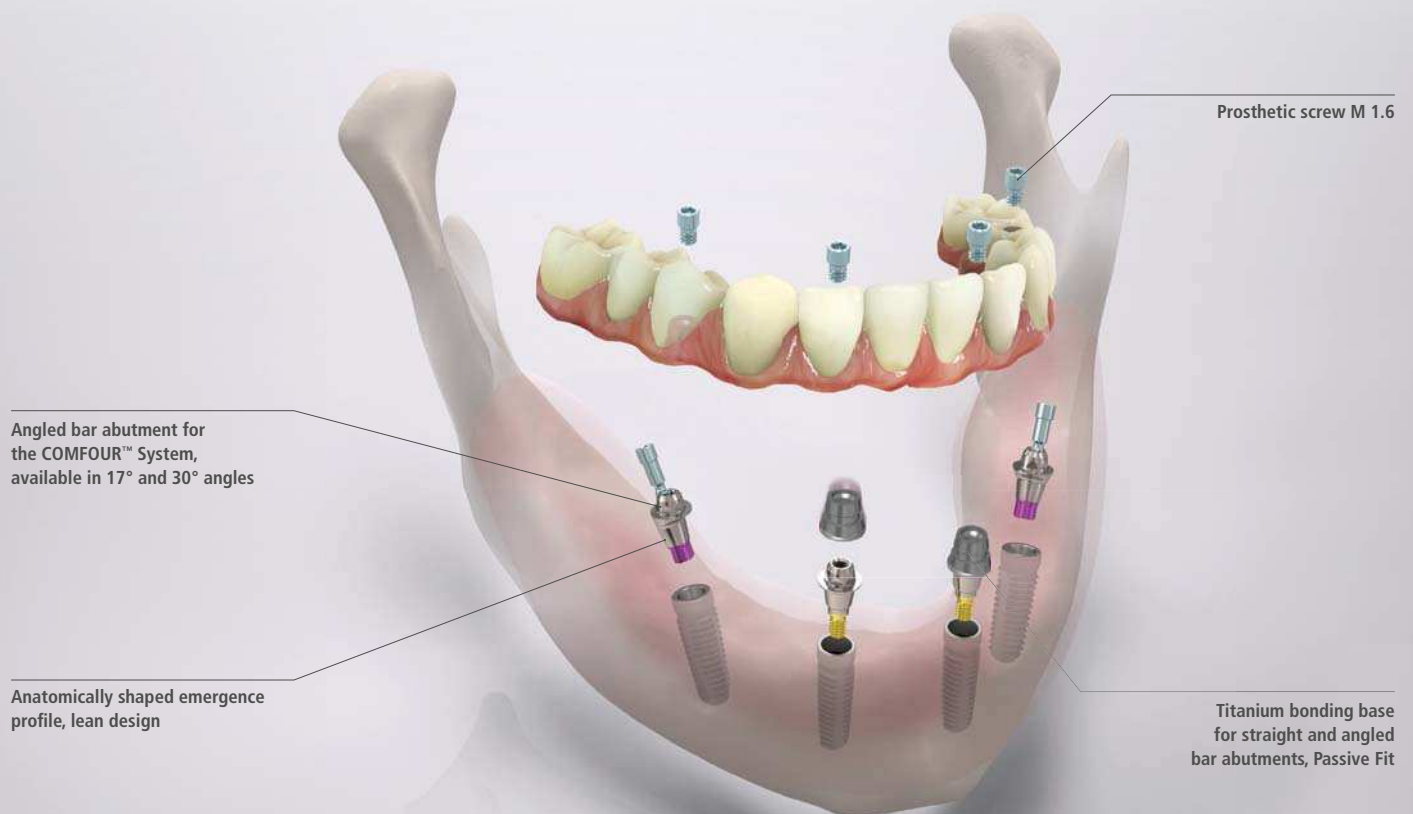camlog

## THE NEW COMFORT CLASS.

The COMFOUR™ Abutment System for occlusal screw-retained restorations is an ideal addition to the CAMLOG® and the CONELOG® Implant System. With the COMFOUR™ System, you can offer your edentulous patients the option of an immediate, comfortable and permanent denture on four or six implants – and thus a considerable gain in quality of life. [www.camlog.com](http://www.camlog.com)

CAMLOG®  
SYSTEM

CONELOG®  
SYSTEM



Aligning tool



Scanning cap



Titanium cap



Flexible handle

COMFOUR™ offers you a range of options to overcome the challenges you face in your implant practice, making them easier while saving time.

# The “Ts” in implantology—of triumphs and tragedies

**Author:** Dr Georg Bach, Germany

## Introduction

Implantology has become a commonplace in dentistry. Indeed, insertion techniques have progressed more and more in the past two decades, while the dental industry has provided users with improved implant surfaces and instruments. Hardly any other dental discipline has experienced more innovation and investments within such a short time span. These developments have been rewarded with a comprehensive product range and highly increased numbers of inserted implants that seemed out of reach only one and a half decades ago. However—despite all of this euphoria—implantology does not exclusively entail positive facets. Therefore, this article is designed

to report on the “Ts” in implantology, on triumphs and tragedies.

## Triumphs

Three case examples, differing in their respective initial situation and indications, are presented: 1) Implant-based denture of a maxillary anterior tooth; 2) complete restoration of the edentulous maxilla and a mandibular with residual frontal dentition via implant-based fixed dentures; 3) complete restoration of the edentulous maxilla with removable prostheses and a partially edentulous mandibular with fixed dentures. All three patients were loaded with tissue-level implants (Straumann) and now feature a positive long-term prognosis.

## Data Case 1

Implant regio 11  
Insertion: April 1999  
Prosthetic restoration: Juli 1999  
X-ray controls: post-operatively, 2001, 2004, 2007, 2010, 2013 and 2016  
Recall: bianullay  
Special characteristics: none

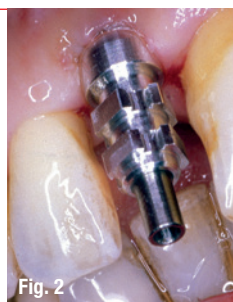

Fig. 2

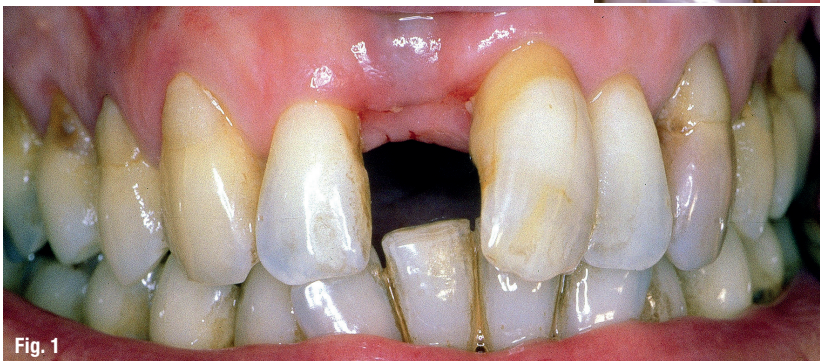

Fig. 1

**Fig. 1:** Initial situation. – **Fig. 2:** Impression taking.

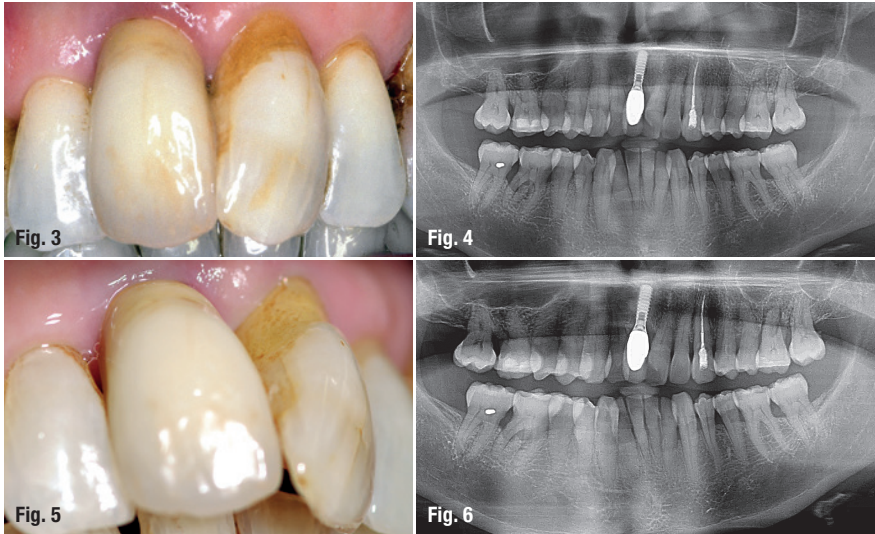
## Case 1

A female patient and teacher, 56 years old at the time of implant insertion, was facing a possible loss of tooth 11 due to a reduction in supporting tissue. Before, a progressed periodontopathy with a reduction in supporting tissue had been restored and the patient was already in the recall phase of this process. Tooth 11 thus was the last legacy of this past periodontal disease.

After tooth extraction, an implant was inserted and loaded with a crown after three months. The dental technician was able to integrate the crown harmoniously in the patient's dentition which was markedly influenced by recession and reduction in supporting tissue. The patient diligently observed recall dates every six months, which have been combined with a professional hygiene session since 2005.

X-ray controls and clinical results did not indicate any pathological findings at the implant, only show-

Visit us @ IDS  
Hall 4.2 Booth G070 / J079



**Fig. 3:** After implant integration. – **Fig. 4:** OPG 1999. – **Fig. 5:** Check-up 2016. – **Fig. 6:** OPG 2016.

ing that the bifurcation at 46 and 36 had increased minimally since the beginning of the treatment (Figs. 1–6).

In conclusion, this case proved to be ideal – long-term stability and a both motivated and cooperative patient.

#### Case 2

Shortly before his 60<sup>th</sup> birthday, a university professor wanted to end his state of suffering from an edentulous maxilla and a partly edentulous mandible. Most of all, he wanted to exchange his total prosthesis in the maxilla and partial prosthesis in the mandible for fixed dentures.

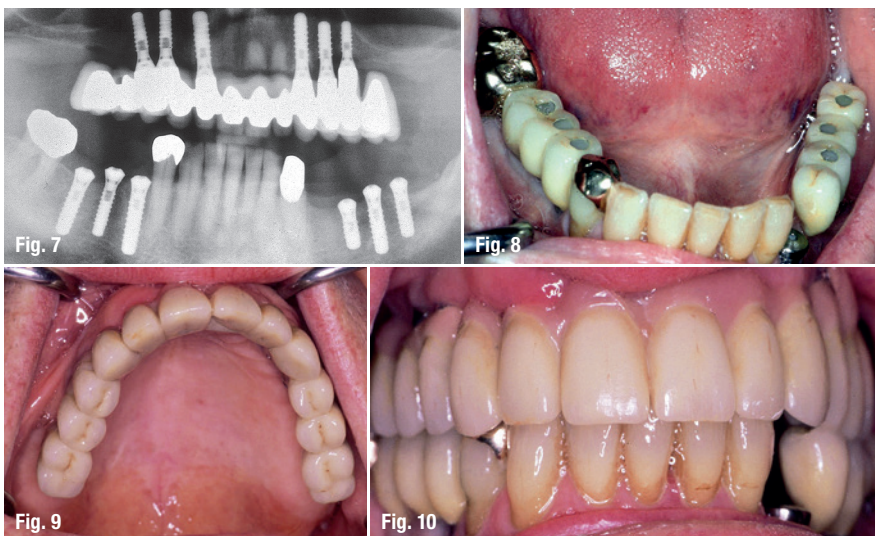Thirteen implants were inserted in two sessions and loaded with a continuous

bridge 16 to 26 in the maxilla and exclusively implant-based crowns and an extension bridge in the left mandible.

There were no regular control sessions, as the patient did not attend these in 2003, 2005 und 2008. In 2009, we achieved that he attended one control date and one professional hygiene session at least once every year.

X-ray controls and intraoral examinations did not indicate any decrease in the constitution of the residual dentition or implants (Figs. 7–14).

In conclusion, this case exhibits long-term stability of fixed, implant-based dentures and only partial compliance of the patient.



**Fig. 7:** OPG after Implantation 1996. – **Fig. 8:** Mandible after implant integration 1996. – **Fig. 9:** Maxilla after implant integration 1996. – **Fig. 10:** Frontal view 1996.



## Shortest Implants – Longest History.

## Think Short!

For more than 30 years Bicon® short implants are unchanged in clinical use.

According to the 11<sup>th</sup> European Consensus Conference (EuCC) 2016 in Cologne, provided the specific treatment parameters are observed, the use of short, angulated or diameter-reduced implants in sites with reduced bone volume can be a reliable treatment option, given the risks associated with the use of standard-dimension implants in combination with augmentation procedures.

For more Information:

**Bicon Europe Ltd.**

Hauptstr. 1

55491 Buechenbeuren

Germany

Phone +49 (0)6543 818200

germany@bicon.com

[www.bicon.de.com](http://www.bicon.de.com)



**bicon**  
DENTAL IMPLANTS

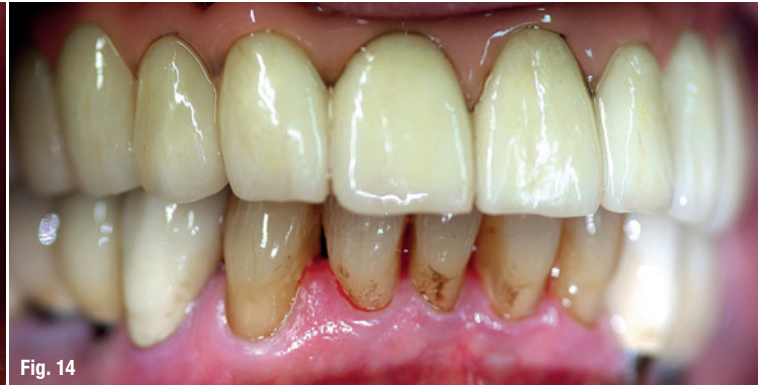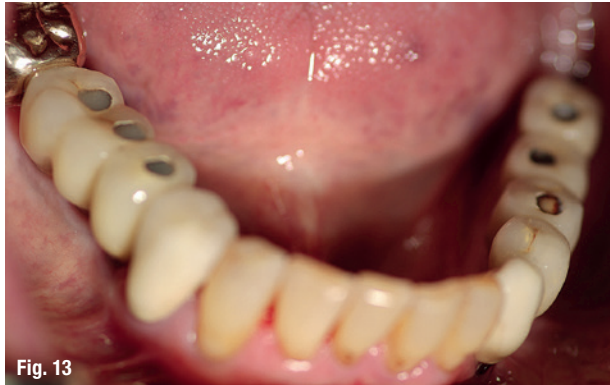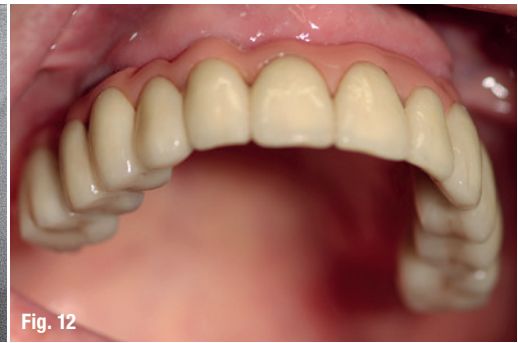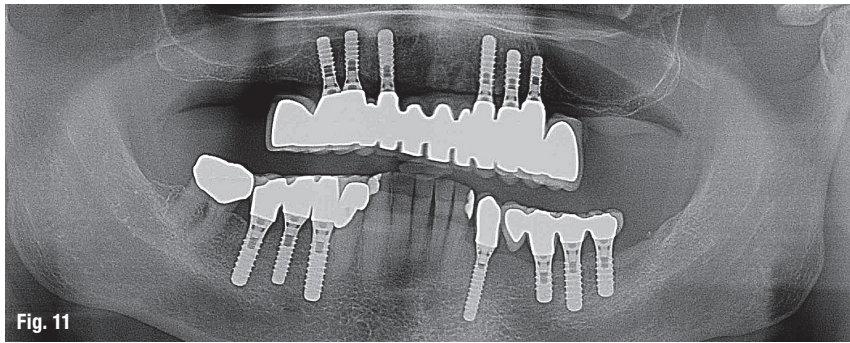


Fig. 11: OPG 2016. – Fig. 12: Maxillary situation 2016. – Fig. 13: Mandibular situation 2016. – Fig. 14: Frontal view 2016.

### Case 3

A then 50-year-old female patient had suffered from an edentulous maxilla since she was 46 years old. Handling her total prosthesis in everyday life was difficult for her, especially as it covered her covered, which made singing difficult for her. In addition, she also suffered from an edentulous mandible.

Due to a reduced bone volume in the posterior region of the maxilla, a manifest atrophy, the patient chose removable dentures for the maxilla and fixed, implant-based dentures in the posterior region of the mandible. The maxilla was restored in the beginning of 1996, while the mandible was treated in the autumn of the same year. Patient acceptance for the newly integrated prosthesis was high and her compliance has proved to be exemplary. In the past two decades, she rigorously attended each biannual control and dental hygiene

date. She still wears the same prostheses, except for two artificial teeth which had to be replaced after a fall (Figs. 15–21).

In conclusion, extensive augmentations were avoided and the patient was granted chewing comfort similar to that of fixed dentures because of a milled bar in the maxilla and implantation in the extended maxillary anterior teeth. Implants were inserted as the bone volume in the posterior mandible was favourable, making fixed, implant-based dentures in the posterior region possible. A highly motivated, compliant and very reliable patient was a further beneficial factor for the long-term success of this case of implant treatment.

### Tragedies

Implant restorations can fail. This failure may occur early or later after loading of the implants and

### Data Case 2

Maxilla (n=6): October 1995  
 Mandible (n=7): February 1997  
 Prosthetic restoration: March 1996 (maxilla) and June 1997 (mandible)  
 X-ray controls: postoperatively, 1999, 2001, 2004, 2007, 2012, 2016  
 Recall: biannually until 2012, no controls in 2003, 2005 and 2008, since 2009 once every year  
 Special characteristics: none

### Data Case 3

Maxilla (n=4): January 1996  
 Mandible (n=5): November 1996  
 Prosthetic restoration: April 1996 (maxilla) and September 1996 (mandible)  
 X-ray controls: post-operatively, 1998, 2001, 2004, 2007, 2010, 2013, 2016  
 Recall: biannually  
 Special characteristics: none



**IDS<sup>®</sup>**  
**2017**

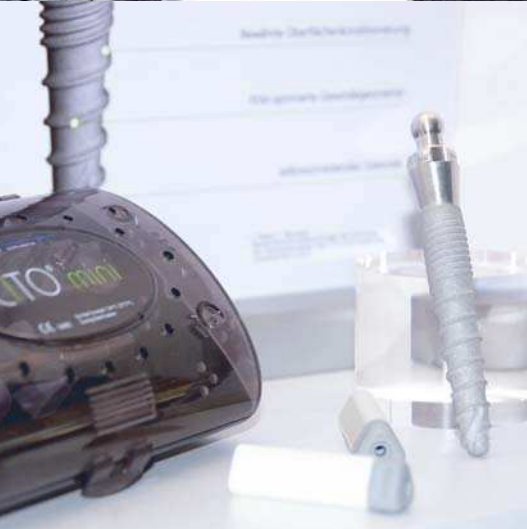**21. - 25.3.2017**  
**HALL 10.1 STAND E10/F11**



*tiologic<sup>®</sup>*



## IMPLANTS FROM DENTAURUM



CITO mini<sup>®</sup>



DENTAURUM  
QUALITY  
WORLDWIDE  
UNIQUE



Dentaaurum was founded over 130 years ago and has been developing and manufacturing dental implants in Germany for more than 20 years. The number of users around the world is growing continuously and users are happy to see a steady flow of innovations, improvements and extended indications in the product portfolio.

And they are impressed by our training center CDC and the large number of training courses there are at all levels.

Come to the Dentaaurum Group stand and find out about the latest product developments and courses on offer for implantologists and for those in the making.

**The Dentaaurum Implants team is looking forward to meeting you.**

 **DENTAURUM  
IMPLANTS**

Turnstr. 31 | 75228 Ispringen | Germany | Telephone +49 72 31/803-0 | Fax +49 72 31/803-295  
[www.dentaaurum-implants.com](http://www.dentaaurum-implants.com) | [info@dentaaurum-implants.com](mailto:info@dentaaurum-implants.com)

its causes are manifold. This is illustrated by the two following examples:

**Case 4: Augmentation failure**

The following case presents early failure of an implant-based restoration. A sinus lift was performed at a maxillofacial practice in order to later insert implants for the rehabilitation of a free-end situation. Both augmentation and healing phase were uneventful.

Implant insertion was planned to be performed in the same practice. However, it was finally carried out in a different practice upon request of the patient. The graft, consisting of a mixture of synthetic bone substitute and autogenous bone was assessed to be healed and loadable following DVT control. In addition, the insertion of three implants and their prosthetic loading were uneventful and without any special occurrences.

After six months, the patient experienced side effects and inflammation of the periimplant soft tissue: a complete failure of the periimplant soft tissue sleeve with the highest-possible probing depth and symptoms such as pain had occurred and ultimately lead to the removal of the implant restorations. Not only was this implantological T a tragedy, but it also can be rightfully declared a total failure (incidentally also starting with a T), moreover one at a very early stage (Figs. 22–29).

In conclusion, this case illustrates a classical early implant failure.

**Case 5: Total failure**

The final case presentation is an example of a late failure. The 59-year-old patient was characterised by, firstly, being constantly stressed, and, secondly, never having any time to spend for anything. His leading role in sales took its toll and was sometimes

Fig. 15: Edentulous maxilla 1996.

Fig. 16: Bar in the mouth 1996.

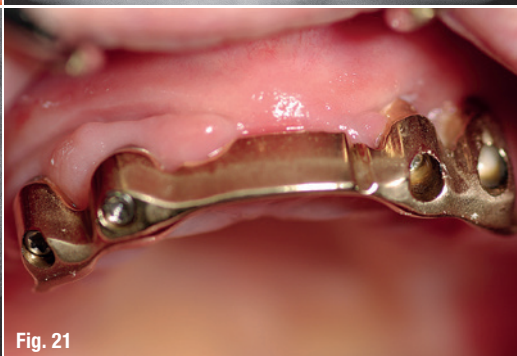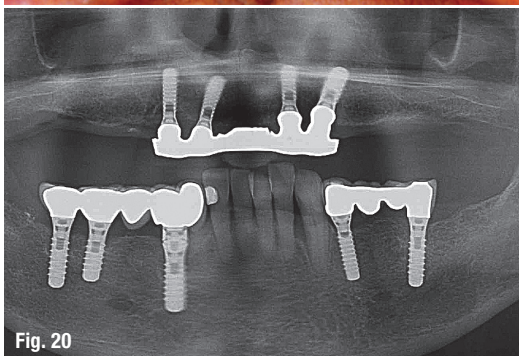
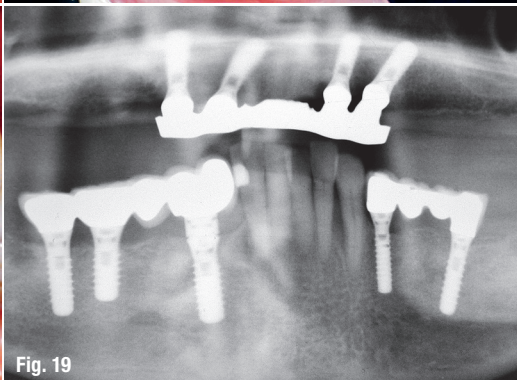
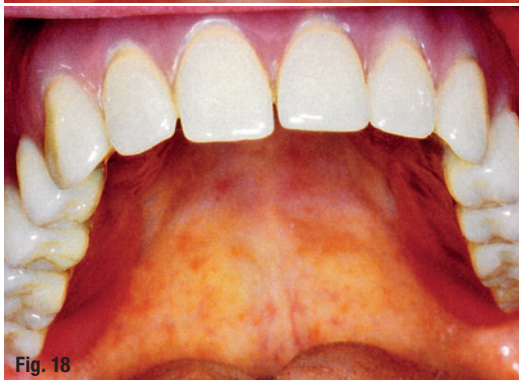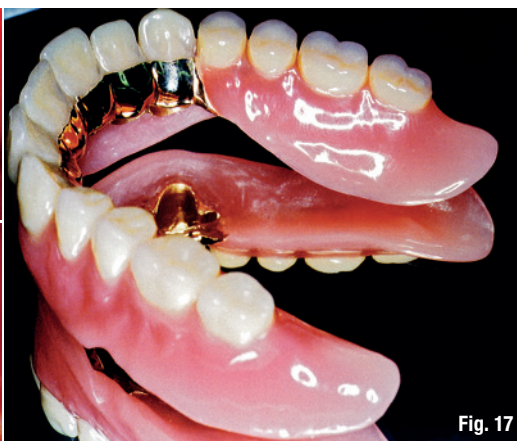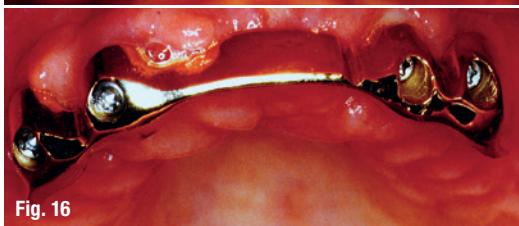
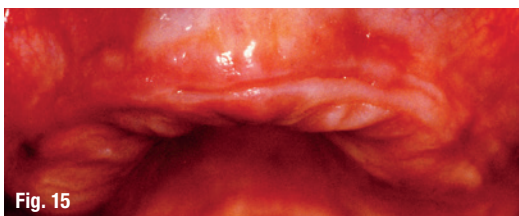
Fig. 17: Partial prosthesis before integration.


Fig. 18: Integration.

Fig. 19: OPG 2004.

Fig. 20: OPG 2016.

Fig. 21: Maxillary bar.





Dentsply Sirona does not waive any right to its trademarks by not using the symbols or 3267114-USX1610 © 2016 Dentsply Sirona. All rights reserved.

Astra Tech Implant System®

# Our world is not flat

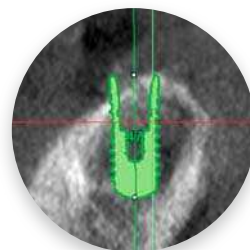
Neither is the anatomy of your implant patients

Your world is already full of clinical challenges so why work harder because of conventional thinking? Instead of augmenting sloped ridges to accommodate flat-top implants, it's time to discover a simpler solution by using an implant that follows the bone. Because sloped-ridge situations call for anatomically designed sloped implants.

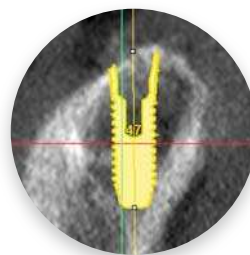
**OsseoSpeed® Profile EV** - It's time to challenge conventional thinking



[www.profiledentalimplants.com](http://www.profiledentalimplants.com)



Conventional vs innovative approach



 **Dentsply  
Sirona**  
Implants

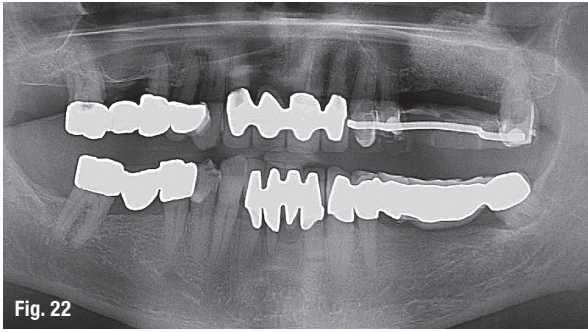


Fig. 22

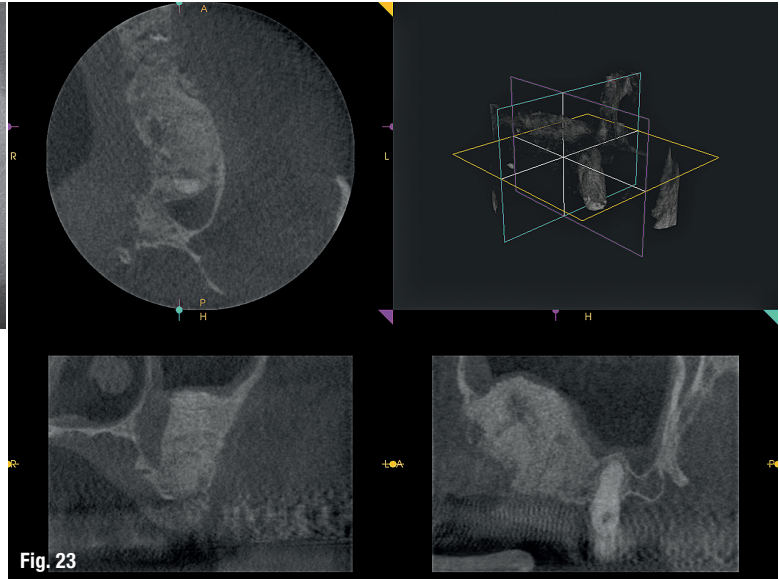


Fig. 23

### Data Case 4

DVT (controls of the augmentation performed alio loco):  
 October 2014  
 Implantation: December 2014 (regio 25, 26, 27)  
 Prosthetic restoration: March 2015  
 Explantation of all three implants, including  
 supraconstruction: March 2016

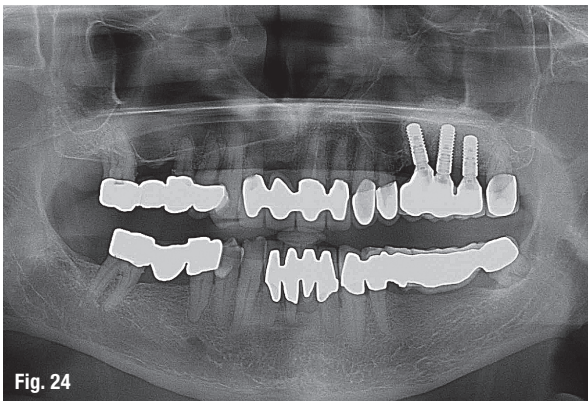


Fig. 24

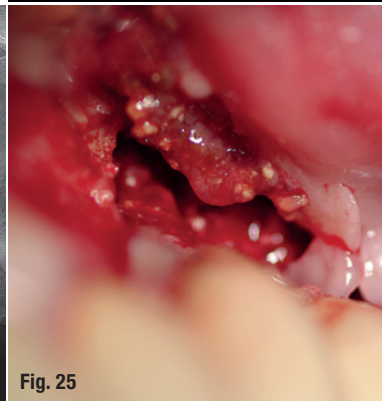


Fig. 25

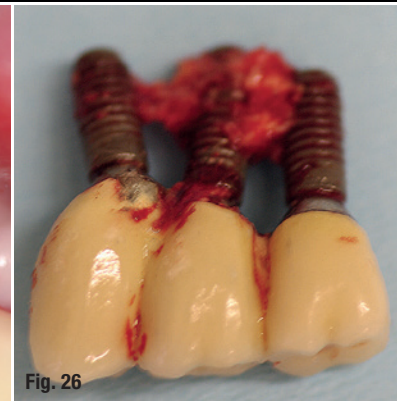


Fig. 26

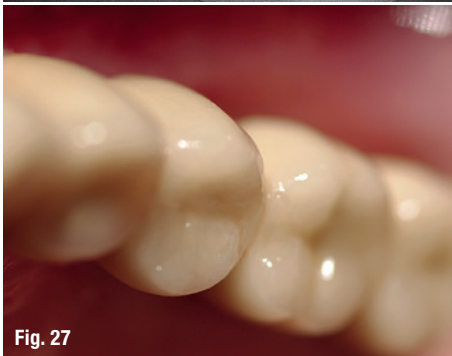

Fig. 27

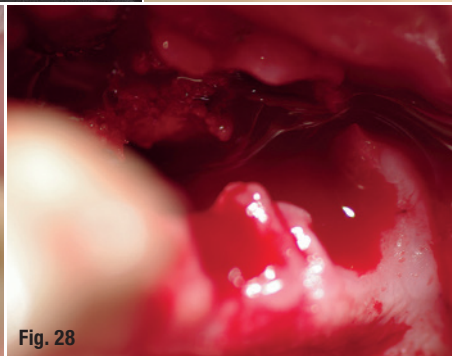


Fig. 28

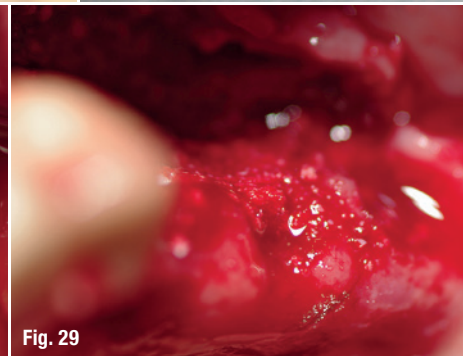


Fig. 29

**Fig. 22:** OPG of the initial situation.  
**Fig. 23:** CBCT check-up of the augmentation.  
**Fig. 24:** OPG after Implantation.  
**Fig. 25:** Supraconstruction.  
**Fig. 26:** Augmentation residues at the opening.  
**Fig. 27:** Explant.  
**Fig. 28:** Defect after explantation.  
**Fig. 29:** After defect reconstruction.

compensated by an increased nicotine intake. The patient spent the little free time he had at his disposal by extensive travels abroad, rather than attending consultations at his dentist's, which probably made him the first patient who managed to miss twenty-two recall sessions in fifteen years.

However, there were phases of increased dental activity, mostly when he had lost one or more of his residual teeth due to periodontal lesions or inflammatory exacerbations.

Yet, the case had had a promising start, as the patient's periodontal restoration at the turn of the millennium had resulted in a restored, albeit re-

duced, periodontium. Free-end situations resulting from the extraction of non-retainable teeth in the right maxilla and mandible were treated with two implants each.

The teeth 14,12 and 44 could not be retained in the following years due to severe periodontal relapses. As a result, they were replaced by implants. At this point it became clear that the patient did not belong to the most reliable kind of patients as he missed some of his recall sessions as well as professional tooth cleanings.

In the end, this estimation proved true: Between 2008 and 2015, all contact to the patient ceased.

# Cutting-edge design based on 45 years of experience



Jack Hahn,  
DDS



## PRODUCT HIGHLIGHTS

- Contemporary design based on decades of clinical experience.
- Unique thread pattern offers speedy insertion and precise control against palatal bone.
- Provides high primary stability required for extraction sites and immediate load opportunities.

Official Implant of the



## Special Offer



Hahn™ Tapered Implant Surgical Kit

Purchase 20 implants (100 € each) and  
1 surgical kit (900 €) for only

**2.900 €**

\*JJT906\*

\*Offer expires 31/5/2017



*Precision-fit conical  
connection for secure  
biologic seal*

*Platform-shifted  
design to preserve  
crestal bone and  
surrounding soft tissue*

Hahn Tapered Implant is a trademark of Prismatic Dentalcraft, Inc.

For more information

+49 69 50600-5312

glidewelldirect.com | orders@glidewelldental.de

**GLIDEWELL DIRECT** EUROPE  
CLINICAL AND LABORATORY PRODUCTS

GLEU-482-021317

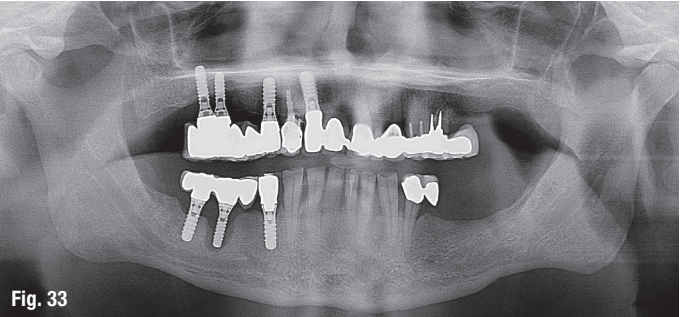
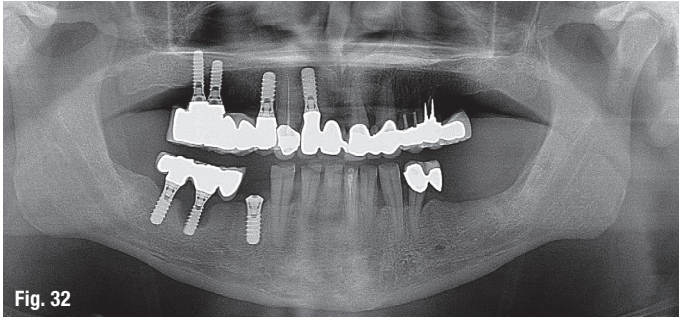
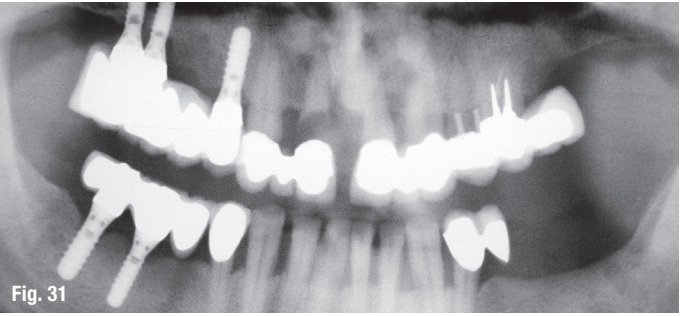


Fig. 30: OPG 2001. – Fig. 31: OPG 2004 after expansion. – Fig. 32: Peri-implantitis manifestation. – Fig. 33: Bowl-shaped defects.

In the spring of 2016, he made an appointment due to severe pain. A suspected peri-implantitis at the implants placed in 2000 was confirmed by panoramic X-ray. As a consequence, the implants had to be removed, leaving again free-end situations and two significant bone defect situations (Figs. 30–37).

Given the lack of patient cooperation, combined with meagre starting conditions and the continued presence of periodontopathy, the result is not surprising. Acknowledging shortcomings the

flawed patient selection. In addition, the insertion of the implants can be critically evaluated.

**Success? Failure? Learning curves.**

Implants have become a fixed component of prosthetic concepts. To what degree implantology has become established in dentistry is reflected in the high patient acceptance of this form of treatment.

Implants are actively requested by patients, as, from their points of view, their evaluation seems

**Data Case 5**

January 2000 (regio 47, 46, 16, 15), May 2002 (regio 14), February/April 2005 (regio 12,44)  
 Prosthetic treatment: June 2000, August 2000, April and July 2005  
 X-ray examinations: directly post-operative, 2001, 2004, 2016  
 Recall: 2001, 2002, 2004, 2005, 2016; 2008–2015 no dental check-ups  
 Special characteristics: explantation OK/UK right hand side

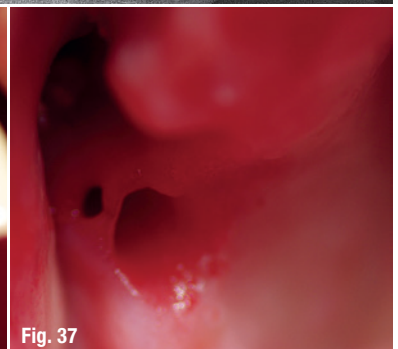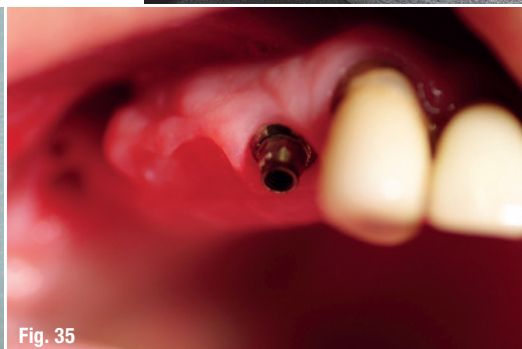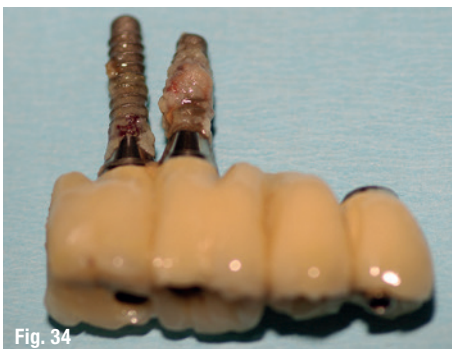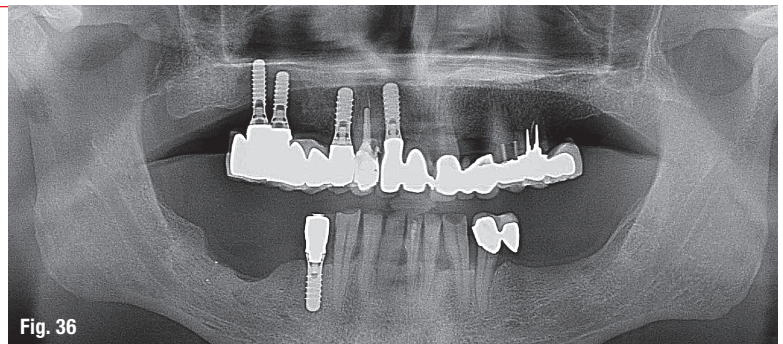


Fig. 34: Explant. – Fig. 35: After explantation. – Fig. 36: OPG after mandibular explantation. – Fig. 37: Post-explant defect.

easy: compared to an often long-lasting and painful periodontal therapy, implant therapy features the advantage of a singular, minimally-invasive implant insertion. In addition, implants are claimed to be life-long restorations. From the dentist's point of view, this estimation of implant therapy can neither be confirmed nor supported without restrictions, as it should predominantly be based on long-term results.

### Long-term success of implants

The experiences of the last three years regarding the insertion of artificial dental piers and their treatment with dentures are positive. Independently of the kind of insertion, implants show very good long-term success rates. This long-term success is slightly less evident in the maxilla than in the mandible and yet compared with other forms of treatment the loss rate is low.

### Risk factors

Limiting the long-term success are for example life-style factors (nicotine consumption), incorrect insertion techniques, shortcomings of the aftercare, oral hygiene as well as unrestored periodontal diseases.

### Learning curves

Cases 1 to 3 confirm the positive experiences previously made in implant therapy, if an optimal indication is given, insertion is done carefully and there are regular check-ups. Even after two decades, patients are content with their implant-prosthetic restorations and there are no significant negative tendencies. From the author's point of view, it seems impressive that long-term stability seems a given even if the patient does not fulfil all requirements, for instance the low compliance in case 2. If, however, the patient disposition is mainly characterised by negative properties (insufficient compliance, bad oral hygiene, non-restored periodontal diseases, nicotine abuse), implant therapy can become a tragedy, as can be seen from case 5.

Severe complications can also be traced back to inadequate operation techniques. Hence, only one step of the treatment chain in case 4 was imperfect: the augmentation *ali loco* (sinus lift). Whereas the CBCT findings were inconspicuous, the newly-created implant site was insuffi-

cient and unable to support the inserted implants for more than a year. This resulted in the loss of three implants and the supra-contraction as well as a significant defect – a total failure!

### Personal résumé


One thing is certain: Implantology epitomises the crucial development that has been taking place in dentistry over the course of the last 30 years. Thanks to the current state of implantology and the options it presents, we can now treat patients successfully that in the past were given conventional, not implant-based dentures that left them unsatisfied.

Due to much improved implant surfaces and honed insertion techniques, implantology has become established and turned into a reliable and secure procedure. Early complications that were much feared during the initial stage of oral implantology, have now become a rarity.

However, implantology still holds both highlights and lowlights. Besides the individual abilities of the implantologist and his limitations, aspects such as the correct classification of the degree of severity and the assessment of the patient and his compliance, carry a growing importance.

Furthermore, due to its large degree of invasion, the incurred costs and the fact that to place an implant is always a procedure based on choice, implantology must be – per se – committed to sustainability. Also, implantology is not as easy as it is often conveyed. It entails triumphs as well as risks.

Author details



### contact

#### Dr Georg Bach

Fachzahnarzt für Oralchirurgie  
Rathausgasse 36  
79098 Freiburg/Breisgau, Germany  
doc.bach@t-online.de

**SKYonics**  
IMPLANTOLOGY MEETS BIONICS

*fast & fixed*

BioHPP

visio.lign®

**The SKY® fast & fixed Therapy**

Train the bone – save the tissue with Bionic framework and veneering materials. 10 years success in immediate full arch restoration.

- Easy to use
- Aesthetic results
- Increase profit

Call (+49) 0 73 09 / 8 72-4 41 to get more information about the indications and the versatility of the SKY® fast & fixed therapy.

**SKY**  
IMPLANT SYSTEM



# The **post-extraction** immediate implant

## A new approach for filling **residual bone defects**

**Authors:** Prof. Dr Mauro Labanca, Dr Ernesto Amosso & Prof. Dr Luigi F. Rodella, Italy



### Introduction

In international literature, a growing number of studies have assessed and quantified alveolar bone resorption following an extraction procedure.<sup>1-4</sup> After dental extraction, height and width of the residual bone ridge suffer a reduction that appears to be greater in the first 30 days<sup>1</sup> and about 50 per cent of the total resorption in the first 3 months<sup>2</sup>. The exact causes of this mechanism are controversial and currently under discussion.<sup>4-8</sup> In order to limit bone resorption after the act of extraction, several techniques have been proposed.

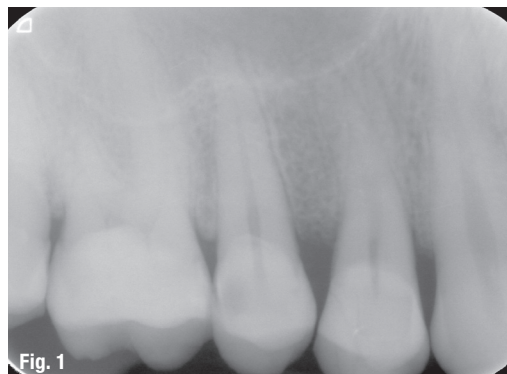Different regenerative procedures designed to preserve the alveolar bone crest have been used over the years and analysed in the literature. However, despite these procedures reducing buccolingual resorption, it has been demonstrated that there is still a loss of bone after healing.<sup>9-11</sup> Paolantonio (2001) was the first to argue that post-extraction implant placement could prevent bone resorption.<sup>12</sup> Others have dismissed this hypothesis after ample studies on humans<sup>4,13-17</sup> and animals<sup>19,20</sup> that, despite positioning of the fixture, there is still buccolingual resorption of the ridge. The principle that determines the peri-implant bone loss has not yet been ade-

quately clarified, but several factors appear to be implicated such as localisation (anterior/posterior), the thickness of the buccal wall, the gap between the implant surface and the bone wall, the type of surgical technique used (with/without flap), the presence of interdental osseous peaks and the surface treatment of the implant.<sup>19,22</sup>

Moreover, due to a frequent radicular anatomical variability with respect to the profile of the implant, after positioning of a post-extraction fixture there is often a gap between the implant surface and the bone wall (residual bone implant gap, BIG).<sup>16</sup> Although the BIG can be reduced by the presence of a blood clot,<sup>18</sup> the use of biomaterials as support has been verified and validated by several studies on animals<sup>20,30-32</sup> and humans<sup>21,25-29</sup>. As demonstrated in a study by Han et al. (2011), the regeneration of the peri-implant defect with biomaterial, associated or not associated with the membrane, increases the percentage of bone to implant contact (BIC).<sup>33</sup>

During the above-described regenerative procedure, usually priority is given to the most coronal portion with the objective of limiting bone resorption, maintaining interproximal peaks if present, better managing gingival aesthetics and preventing invagination of soft tissue in the defect. Instead, our protocol provides for the positioning of biomaterial even before implant placement. This allows greater primary implant stability already during insertion. Also, in consideration of the fact that most of the existing fixtures are self-tapping, the macrostructure of the implant favours progression of the inserted particulate downward by first placing it in those areas of apical defect otherwise not easily accessible in the next phase. It should also be remembered that it is the more vascularised apical portion that originates the regenerative push that will then progress in the coronal direction, thus increasing the BIC.<sup>34</sup>

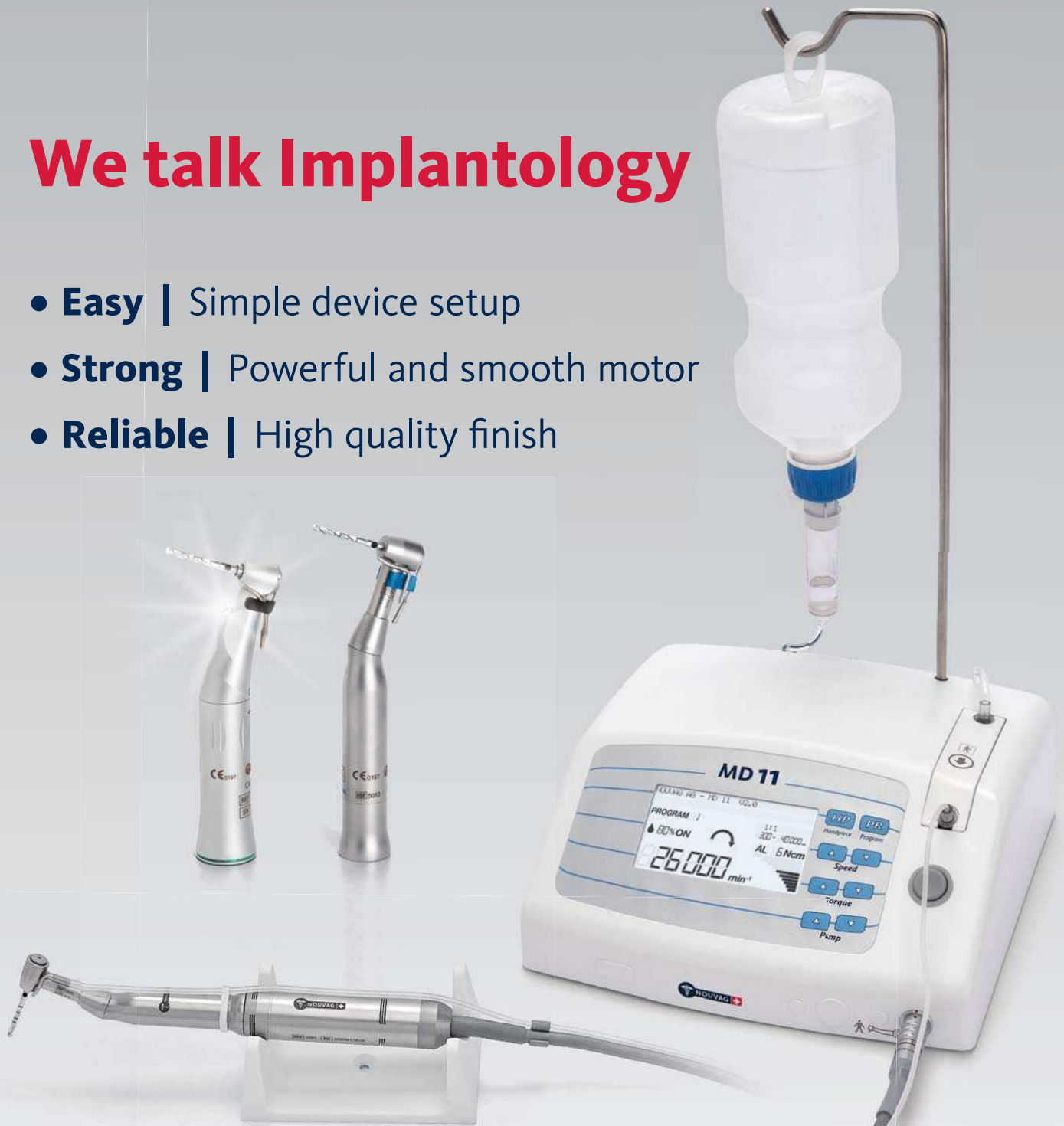**Fig. 1:** Preoperative periapical X-ray image evidenced dental fracture on 14.





# We talk Implantology

- **Easy** | Simple device setup
- **Strong** | Powerful and smooth motor
- **Reliable** | High quality finish



Scan me to be linked to the  
NOUVAG contact form ▶▶▶



Nouvag AG  
St.Gallerstrasse 23 – 25  
CH-9403 Goldach  
Phone +41 (0)71 846 66 00  
[info@nouvag.com](mailto:info@nouvag.com)  
[www.nouvag.com](http://www.nouvag.com)



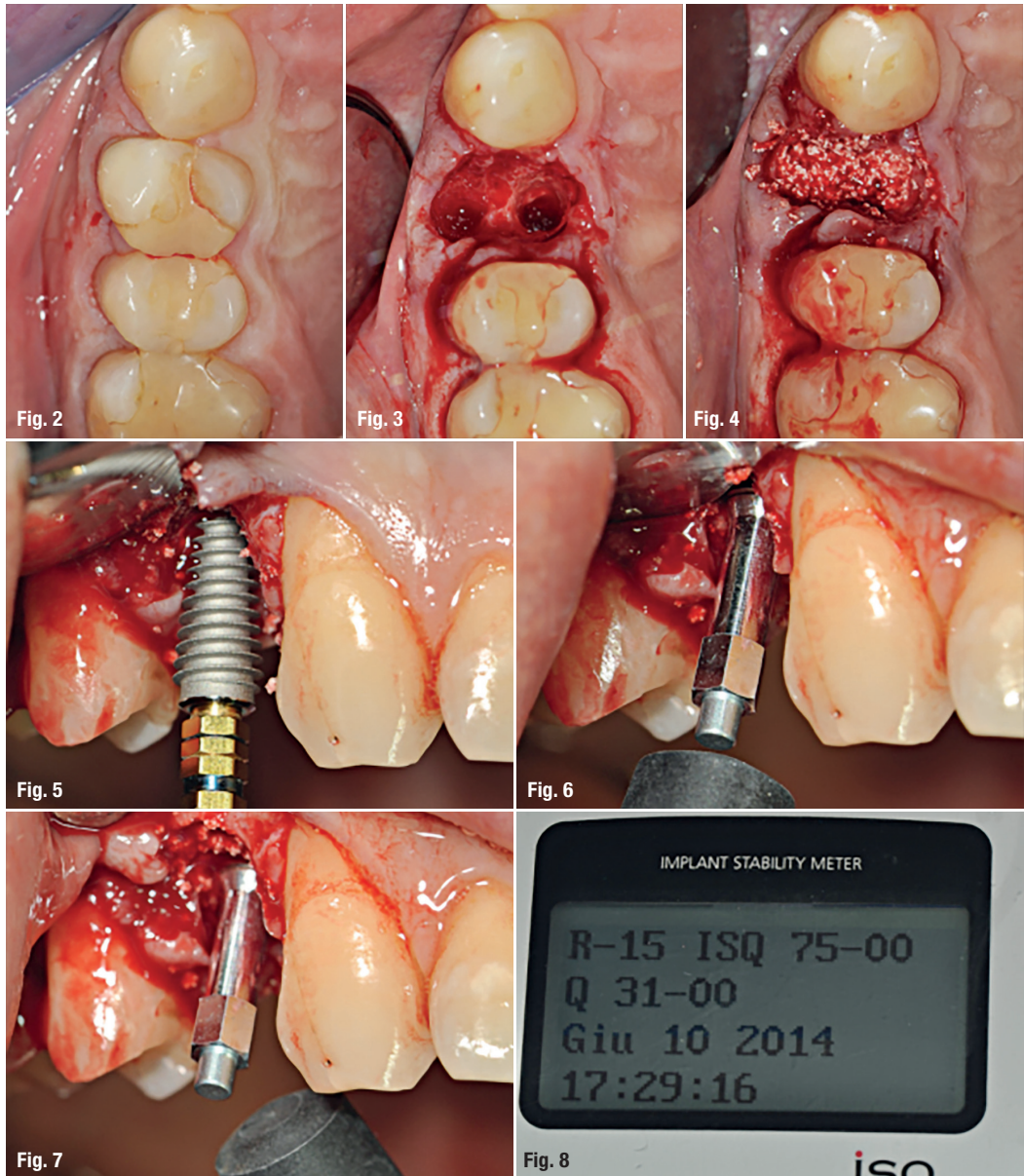
**Fig. 2:** Preoperative image, occlusal view.

**Fig. 3:** Perioperative image, dental root has been extracted preserving buccal plate.

**Fig. 4:** Perioperative image, implant site has been prepared and filled with beta-Tricalcium phosphate.

**Fig. 5:** Perioperative image, dental implant has been inserted.

**Fig. 6–8:** Perioperative image, implant stability has been checked with Osstell ISQ®.



The purpose of this study is therefore the demonstration of a way of operating that aims to improve the primary stability of the implant and to obtain a more predictable regeneration also of those alveolar parts not accessible with conventional methods. Described below is one case selected among those who have so far been treated with this suggested protocol. This study was conducted in accordance with the Declaration of Helsinki of 1975 and revised in 2000. Informed consent was obtained from the subjects for participation in this study.


### Clinical case

A 52-year-old male patient presented with soreness in position 1.4. Clinical evaluation accompanied by intraoral X-ray revealed a complete vertical fracture (Figs. 1 & 2). An atraumatic avulsion was performed with piezoelectric instruments (Piezosur-

gery®, Mectron; Fig. 3). The implant site was prepared with ultrasonic inserts (Piezosurgery®, Mectron) at the palatal root. Site preparation was then completed with implant drills, as always performed and suggested by the authors.<sup>35</sup> Before insertion of the implant, the post-extraction socket (in both the vestibular and palatal space) is filled with biomaterial (used in this case was calcium triphosphate, R.T.R.®, Septodont; Fig. 4). The fixture was then inserted (AnyRidge®, 4 x 13 mm, Megagen Implants; Fig. 5) and the primary stability achieved and verified with Osstell® (65 ISQ; Figs. 6–8). The coronal gap, as usual, was then filled with additional biomaterial (Figs. 9–11). The postoperative intraoral X-ray shows the correct position of the implant (Fig. 12). Finally, the patient was instructed in home hygiene and care with chlorhexidine rinses (0.2%, every 12 hours for 10 days) and antibiotic therapy (amoxicillin and clavulanic acid, 1 g, every 8 hours for 6 days).

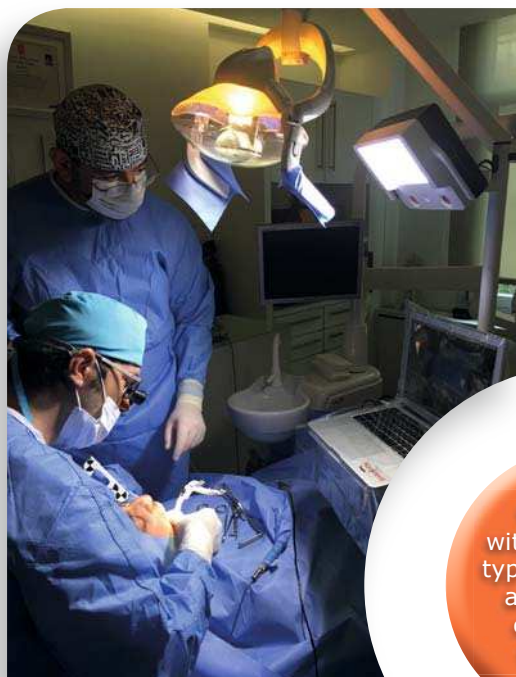# Navident

# Targeting Perfection



## Dynamic navigation for freehanded dental implant placement

See for yourself how freehanded guided surgery aids more accurate implant placement. Navident tracks the drill and the patient's jaw, providing real-time tactile guidance and visual feedback.



- Precision guidance for increased accuracy within 0.5mm of treatment plan\*
- Easy to use, reducing time and expense with a simplified workflow
- Provides even greater value from your CBCT data
- Enables minimally invasive flapless drilling without a physical guide

Compatible with any implant type, drill system and all CBCTs currently on the market

"Navident is the future of guidance in dental implantology as it leads to precise placement of dental implants which is one of the most critical keys for long term success of implants and successful dental prosthesis."

Dr. Yakup ÜSTÜN, Dr. Noyan BAŞAL,  
Dr. Hakan UYSAL, Dr. Tolga AKOVA,  
SEE Implant Dentistry Training Team



Try Navident's precision guidance for yourself.

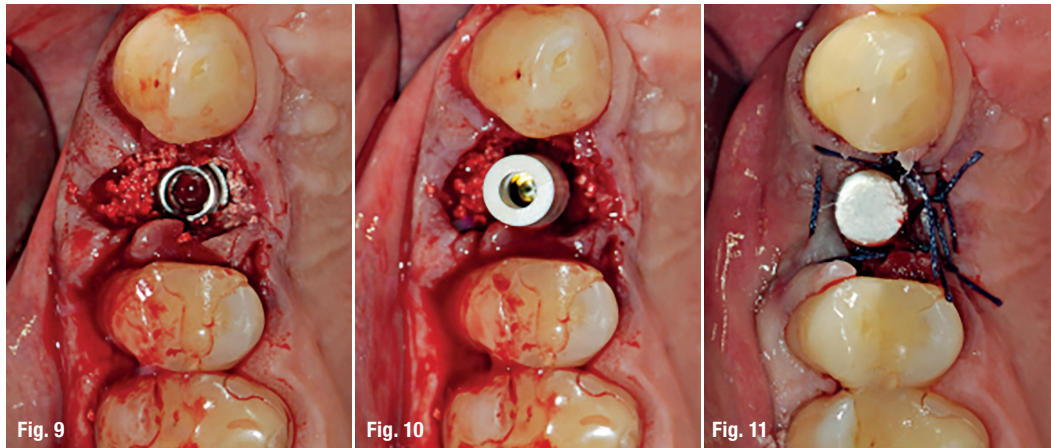
Call +32.475.75.52.26 or email [info@claronav.com](mailto:info@claronav.com)

Visit us at IDS 2017. We are located in Hall 2.2 Aisle A No: 061



[www.claronav.com](http://www.claronav.com)

**Fig. 9–11:** Perioperative image, implant inserted in the correct position, occlusal view.



## Results

The insertion of biomaterial to fill the BIG even before insertion of the implant seems to determine the best functional results in prosthetic-implant rehabilitation. This protocol, indeed, not only results in an improvement in the primary stability of the implant, but also allows regeneration of those alveolar parts otherwise inaccessible with other techniques.

## Discussion

The positioning of an implant in a bone defect usually leaves a space between the implant surface and the alveolar bone wall. With the aim to improve osseointegration and limit resorption of the ridge, autologous, heterologous and alloplastic bone, with/without membrane, has been used in combination in order to improve bone formation in these defects.<sup>38–40</sup> Nevertheless, procedures for regeneration of the post-extraction site associated with immediate implant placement have been shown to limit resorption, although a complete preservation of the site has never been documented.<sup>9,11,41</sup>

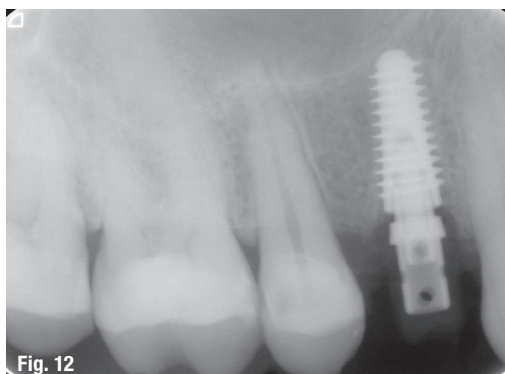
Another fundamental parameter is the size of the BIG. A value of 1.5 to 2 mm can determine healing without compromising the degree of osseointegration. However, whether the width of the space between the surface of the implant and the bone crest

plays a role in the remodelling is still under discussion.<sup>20</sup> Also currently considered important is the location of the implant in relation to the level of the crestal bone of the site. Other studies have shown that vertical resorption may be limited not only by filling the gap, but also by excess regeneration of the upper portion of the crest. To achieve this, the graft material should be placed in the most coronal portion of the site and on the buccal side of the outer surface of the alveolus.<sup>46–48</sup>

Taken together, current knowledge indicates that post-extraction implant placement cannot prevent dimensional changes of the ridge, but association with biomaterials seems, to date, to be the treatment of choice to limit resorption. Nevertheless, if the element to be extracted is associated with periapical disease and/or uncontrolled periodontal disease, post-extraction placement of the implant is to be excluded; in this case, the resorption of the alveolar ridge cannot be preserved and a more traditional implant procedure should be performed.<sup>49</sup>

Finally, our findings are consistent with previous results,<sup>14–16,29,36,37</sup> showing that the insertion of biomaterial to fill the BIG even before insertion of the implant determine the best functional results in prosthetic-implant rehabilitation. Further investigation need to evaluate the resorption of the alveolar ridge associated with the placement of post-extraction implants using the surgical protocol described by the authors.

**Fig. 12:** Postoperative periapical X-ray evidenced the correct position of dental implant.



## contact

**Prof. Dr Mauro Labanca**  
 Studio Professor Mauro Labanca  
 Corso Magenta, 32  
 20123 Milano, Italy  
 Tel.: +39 02 804246  
 mauro@maurolabanca.com

Author details



# OT EQUATOR

**INNOVATIVE DESIGN AND FUNCTIONALITY ON YOUR IMPLANT**  
*The Smallest Dimensional Titanium Abutment in the Market*

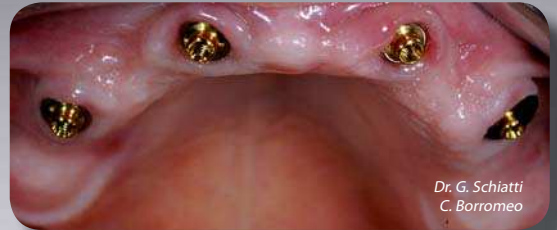

**STAINLESS STEEL HOUSING**  
 2,1mm HEIGHT  
 4,4mm DIAMETER

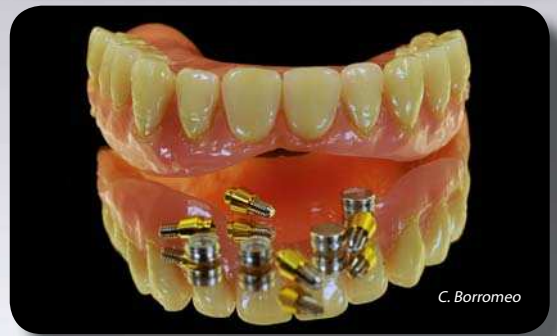**RETENTIVE NYLONCAP**  
 SHOCK ABSORBING  
 FUNCTIONALITY

**TIN COATED TITANIUM**  
 1600 VICKERS  
 HARDNESS

**OT EQUATOR THREAD**  
 COMPATIBLE TO ALL  
 IMPLANT PLATFORMS



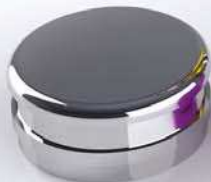*Dr. G. Schiatti  
 C. Borromeo*



*C. Borromeo*

## RETENTIVE CAPS LINE

ELASTICITY AND MECHANICAL RETENTION TO ENSURE A SUPERIOR FUNCTIONALITY FOR THE PROSTHESIS



METAL HOUSING



STRONG RETENTION



STANDARD RETENTION



SOFT RETENTION



EXTRA SOFT RETENTION



THE OT EQUATOR ATTACHMENTS ARE AVAILABLE FOR THE MAJOR IMPLANT BRANDS. UPON REQUEST WE CAN CUSTOMIZE THEM FOR ANY KIND OF IMPLANTS. WHEN ORDERING, PLEASE ALWAYS INDICATE: IMPLANT BRAND, IMPLANT DIAMETER AND CUFF HEIGHT. CUFF AVAILABLE UP TO 7mm.



Via E.Zago 10/abc 40128 Bologna (Italy) Tel. +39 051244510

[www.rhein83.com](http://www.rhein83.com) • [info@rhein83.com](mailto:info@rhein83.com)

# TRINIA™

## Metal-free restorations

**Authors:** Prof. Dr Dr Rolf Ewers, Paolo Perpetuini, Dr Vincent J. Morgan, Prof. Dr Mauro Marincola, Richard Wu & PD DI Dr Rudolf Seemann, Austria/Italy/USA



### Introduction

There are several reasons not to use dental restorations made of metal. Possible disadvantages of metal are for instance the potential allergenicity (type IV allergy) and weight, density, as well as the long processing time. Furthermore, the colour of metals differs visibly from gingiva and teeth. Metal has in fact a great strength, but it is, however, much harder than the natural tooth. Metals are very good thermal conductors and isolate from temperature much worse than teeth. Every patient with deep fillings or cast gold inlays probably knows about these properties.

For the named reasons, the problematic aesthetics of metals and their alloys as well as their mechanical properties, the search for other materials has not ended yet. Furthermore, allergological and biological concerns of patients and doctors have gained more importance in the last years.

TRINIA™ was developed to provide dentists with CAD/CAM-milled metal-free restorations.

This report presents TRINIA™, a metal-free fibre-reinforced CAD/CAM material. Due to its flexural strength, it is comparable to dentin and simulates the function of Sharpey's fibres. Its properties provided excellent results for 101 bridges and full-arch prostheses in a period of up to 64 months with very little complications. The following case presentations demonstrate the elegant CAD/CAM planning and milling procedures for difficult situations like the treatment of extremely severe maxillary and mandibular atrophy (class VI). The concurrence of the flexural strength of TRINIA™ and the attributes of the short Bicon implants provided successful results for our treatment of atrophic maxillae and mandibles with minimal implant losses and 100 per cent successful full-arch TRINIA™ prosthetic treatments.

### Material properties

TRINIA™ CAD/CAM discs and blocks (Fig. 1) are composed of multidirectional interlacings of fibre-glass and resin in several layers.<sup>1</sup> In addition to the advantage of being a lightweight, TRINIA™ has great

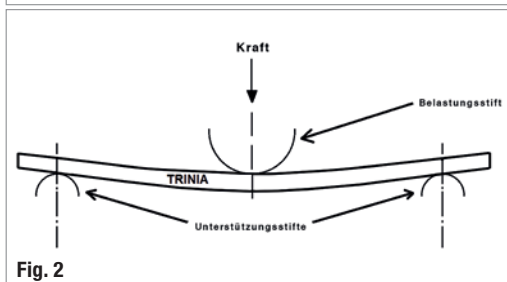
**Fig. 1:** TRINIA™ products.

**Fig. 2:** Setup for measuring flexural strength.

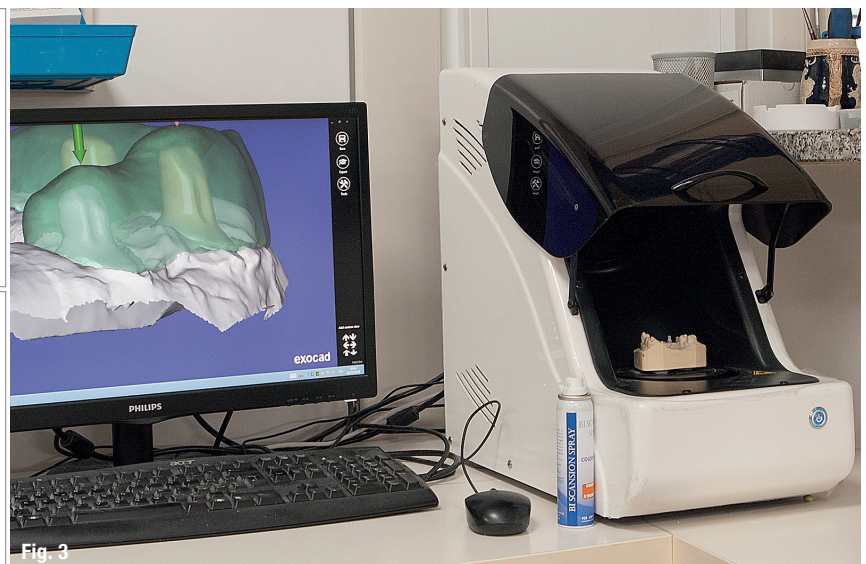
**Fig. 3:** CAD-based planning.



**Fig. 1**



**Fig. 2**



**Fig. 3**




Fig. 4a




Fig. 4b

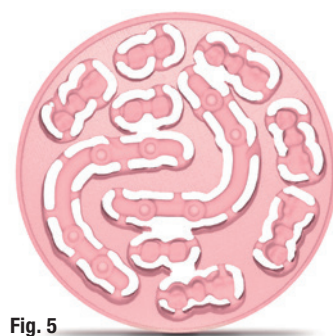


Fig. 5

flexural strength and a flexural modulus of elasticity similar to dentin.

The flexural strength is determined by means of the loading device in the classical three-point bending test (Fig. 2). The tested material—in this case TRINIA™—bends under load. As long as the material does not deform under load, i. e. returns to its original form when the force declines, it remains within the elastic range. If the acting force exceeds the load limit, the material deforms (plastic range) and breaks in the end. The range when that happens to TRINIA™ is similar to that of dentin. In other words: The flexural modulus of elasticity of TRINIA™ is 18.8 GPa, compared to that of dentin being 12–14 GPa<sup>2</sup> and of titanium being 102–118 GPa<sup>3,4</sup>

As TRINIA™ features a flexural modulus of elasticity that is comparable to dentin, it will behave similarly. TRINIA™ is an American product for permanent restorations approved by the FDA. Fibre-reinforced composites (FRC) by TRINIA™ are composed of 40 per cent of epoxy resin and 60 per cent of fibreglass. Its most outstanding characteristics are the great elasticity featuring a flexural strength of 390 MPa (N/mm<sup>2</sup>) and very low water adsorption of

0.03 per cent. Because of the high level of resilience of TRINIA™ material, every construction or bridge construction features the so-called buffering, comparable to the effect of Sharpey's fibres. The bond of TRINIA™ and abutments is very stable and reaches 18 MPa with 3M RelyX Unicem 2 Automix and 18.6 MPa with Cera Resin Bond (SHOFU).<sup>5,6</sup>

### TRINIA™ CAD/CAM

The relatively simple design and manufacture of prosthetic constructions using CAD techniques is a good alternative to conventional methods (Fig. 3). TRINIA™ can be machined with customary wet- or dry-milling machine systems using nano-diamond burs (Figs. 4 & 5). TRINIA™ is suitable for making copings, substructures or frameworks for permanent and transitional anterior or posterior crowns, bridge-work, and substructures on natural teeth or implants. TRINIA™ constructions can be used either with cemented or uncemented restorations as well as with screwed or telescopic restorations (Figs. 6 & 7). The versatility of TRINIA™ material permits the use for permanent supply with e.g. inlays, onlays, crowns, bridges, veneers or partials. The material is supplied in ivory and in pink (Fig. 8).

**Figs. 4a & b:** CAM-based milling.  
**Fig. 5:** TRINIA™ disc after milling.

**Fig. 6:** Completed TRINIA™ construction.  
**Fig. 7:** Frontal view on the TRINIA™ prosthesis.  
**Fig. 8:** Palatine view on a completed, TRINIA™ prosthesis.  
**Fig. 9:** Panoramic radiograph of a 59-year-old female.  
**Fig. 10:** Plaster model.  
**Fig. 11:** Caudal view of the completed prosthesis.

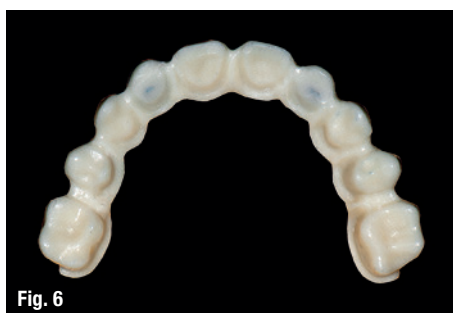

Fig. 6

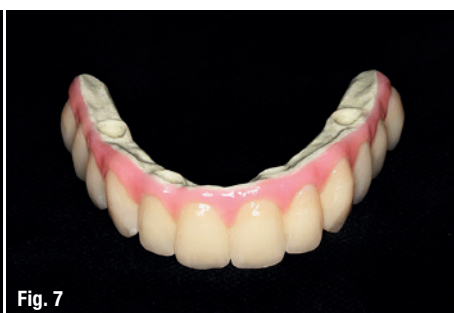

Fig. 7

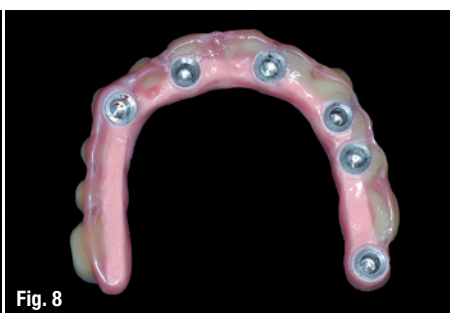

Fig. 8

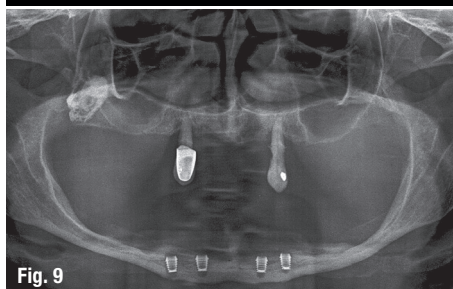


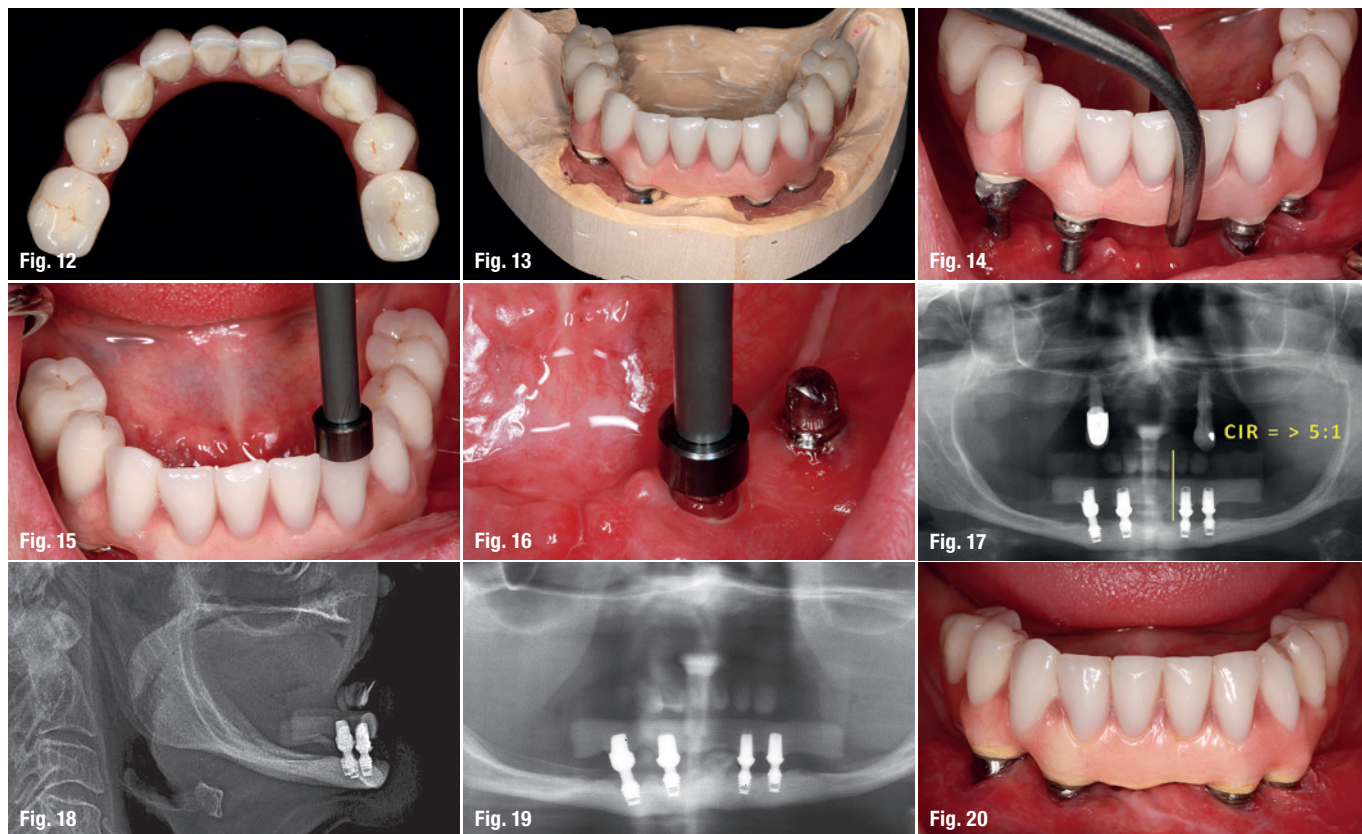
Fig. 9

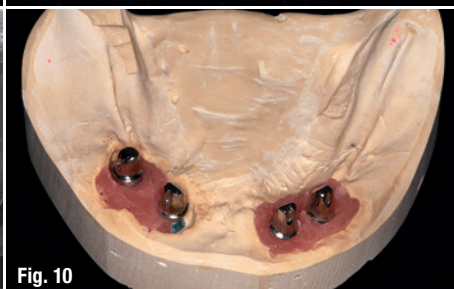

Fig. 10

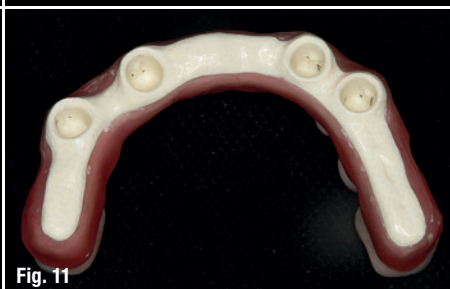

Fig. 11



**Fig. 12:** Cranial view of the completed prosthesis.  
**Fig. 13:** Completed prosthesis in the plaster model.  
**Fig. 14:** Insertion of four abutments in the implant shafts.  
**Fig. 15:** Tapping the abutments in the prosthesis.  
**Fig. 16:** Final tapping of the abutments, resulting in cold shut.  
**Fig. 17:** Panoramic view with inserted abutments and prosthesis.  
**Fig. 18:** Lateral cephalometric radiography.  
**Fig. 19:** Panoramic view at the control after 51 months.  
**Fig. 20:** Intraoral image of the mandibular prosthesis after 51 months.

Flexural rigidity and compression strength of TRINIA™ are high despite the minimal CAD/CAM processing time. TRINIA™ can be processed extra-orally as well as intra-orally. Its wearing comfort high excellent thanks to its light weight.

### Case presentation

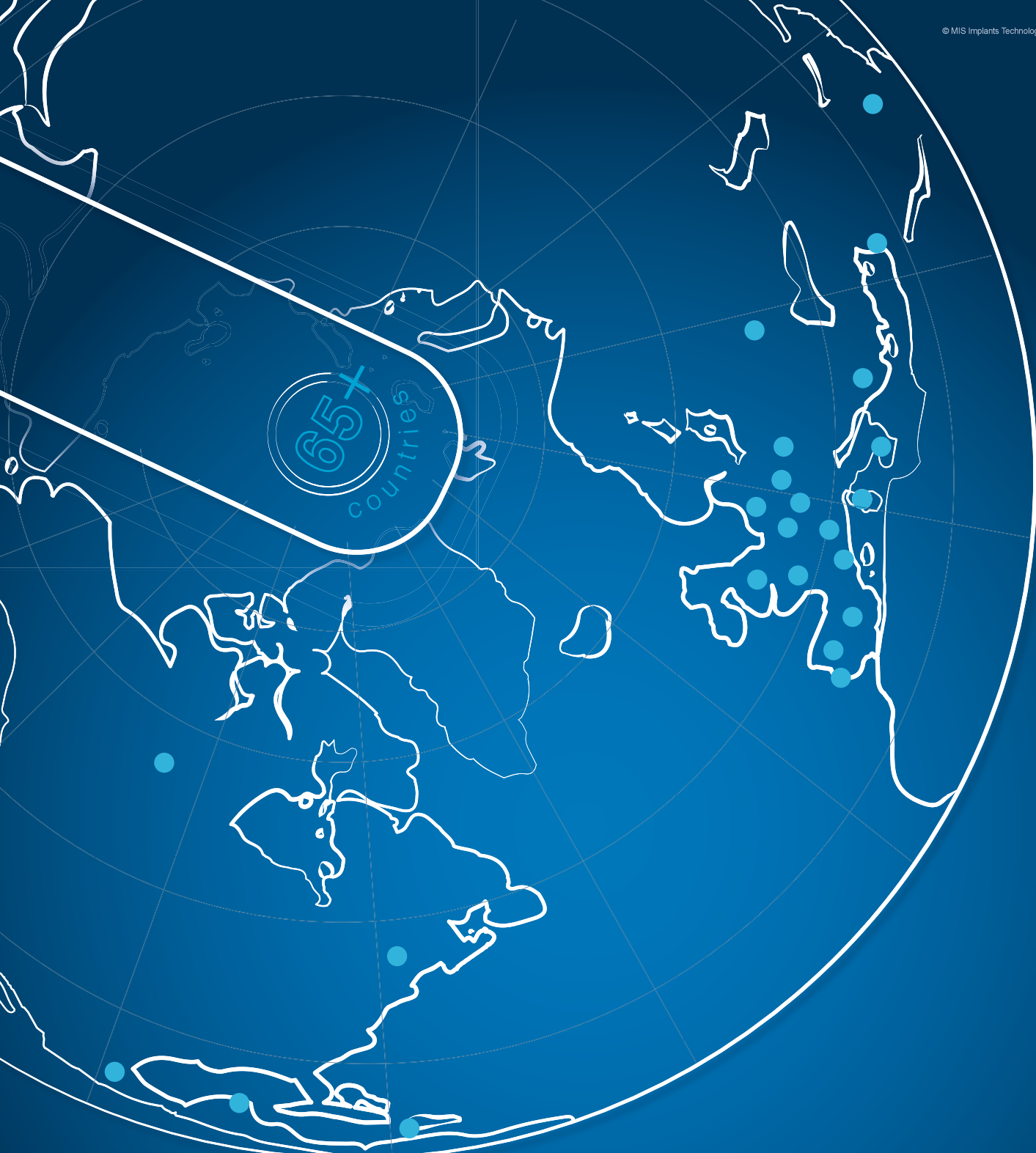The cases described in the following represent only a small portion of the possibilities for this material. Figure 9 shows a panoramic radiograph of a 59-year-old female patient with extreme mandibular atrophy class VI according to Cawood and Howell<sup>7</sup> after the insertion of four 4.0x5.0 mm short Bicon implants. After an integration time of three months, the appropriate model can be prepared after exposure and dental imprint (Fig. 10). Then, the ten-piece prosthesis can be manufactured applying the CAD/CAM method (Figs. 11–13). The corresponding implant shafts are found by means of the abutment temporarily fixed with Vaseline in the prosthesis (Fig. 14) and then the abutments are tapped via the prosthesis (Fig. 15). Then, the individual abutments are tapped again to fix them in the implants (Fig. 16). Because the abutment is end-tapered by 1.5 degrees towards the inner shaft, so-called cold welding happens.<sup>8</sup> The panoramic radiograph after the insertion of the cemented bridge illustrates the crown-implant ratio (CIR) of more than 5:1 (Fig. 17) and the lateral cephalometric radiography shows pseudoprogenia due to the severely atrophic maxilla

(Fig. 18). The crown-implant ratio of 1:1 does not apply to the short Bicon implants anymore.<sup>9–12</sup> Figure 19 shows the panoramic radiograph and figure 20 the clinical image from the follow-up examination 51 months later.

The 59-year-old female patient presented in the following also suffers from distinct mandibular atrophy class VI<sup>7</sup> (Fig. 21). In that case, the four 4.0x5.0 mm short Bicon implants were tilted too far in the labial direction (Fig. 22), so that the prosthesis could be fixed only by means of screwed abutments to be placed in front of the mandibular anterior teeth. This resulted in very long cantilever segments on the distal side of the posterior implants. Despite the extremely heavy load of the TRINIA™ material, it did not break yet even after 64 months of wearing (Figs. 23 & 24).

With our first ten patients with mandibular atrophy class VI<sup>7</sup>, we measured a ratio of 4.3:1 from bridge span to implants span for 40 short 4.0x5.0 mm Bicon implants (Fig. 25).<sup>12</sup> With 16 patients treated for atrophic mandibles class VI<sup>7</sup> wearing four 4.0x5.0 mm short Bicon implants, we have lost one implant in the observation period of up to 5.6 years. This corresponds to a survival rate of 98.4 per cent. The patient had lost the left middle implant seven days after the initial treatment, which correlates to implant loss due to lacking osseointegration. Since then, she has been putting the load on the remaining






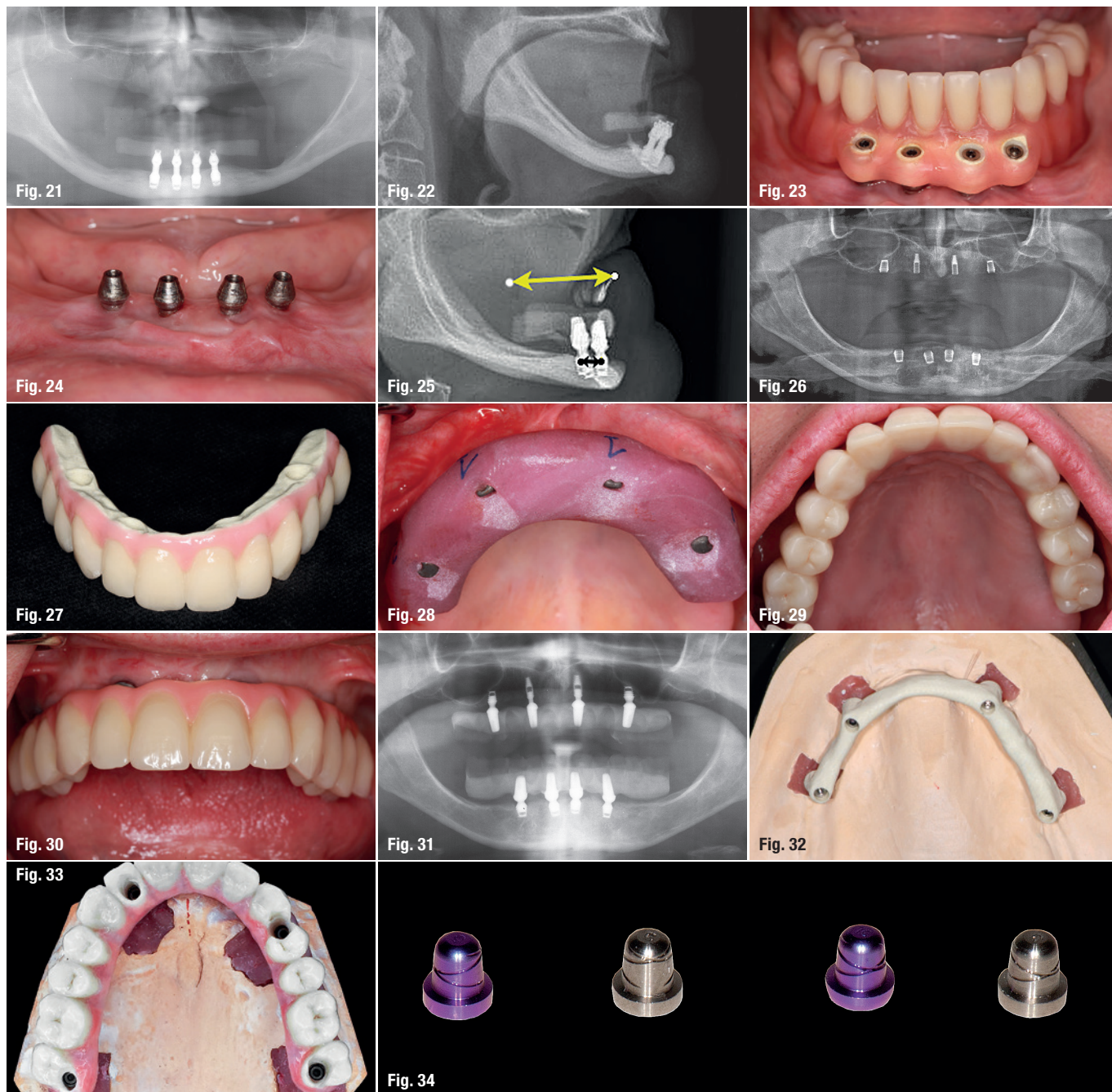
To learn more about our innovative products,  
please visit us at IDS, Cologne, March 21-25:  
Hall 4.1, Aisle B-030/D-039

**EXPERIENCE THE GLOBAL SUCCESS**  
**MAKE IT SIMPLE**



MIS is a global leader in the development and production of advanced products and innovative solutions aimed to simplify implant dentistry. Successfully sold and distributed in over 65 countries worldwide, MIS provides unparalleled service to our customers. To learn more, visit our website: [www.mis-implants.com](http://www.mis-implants.com)



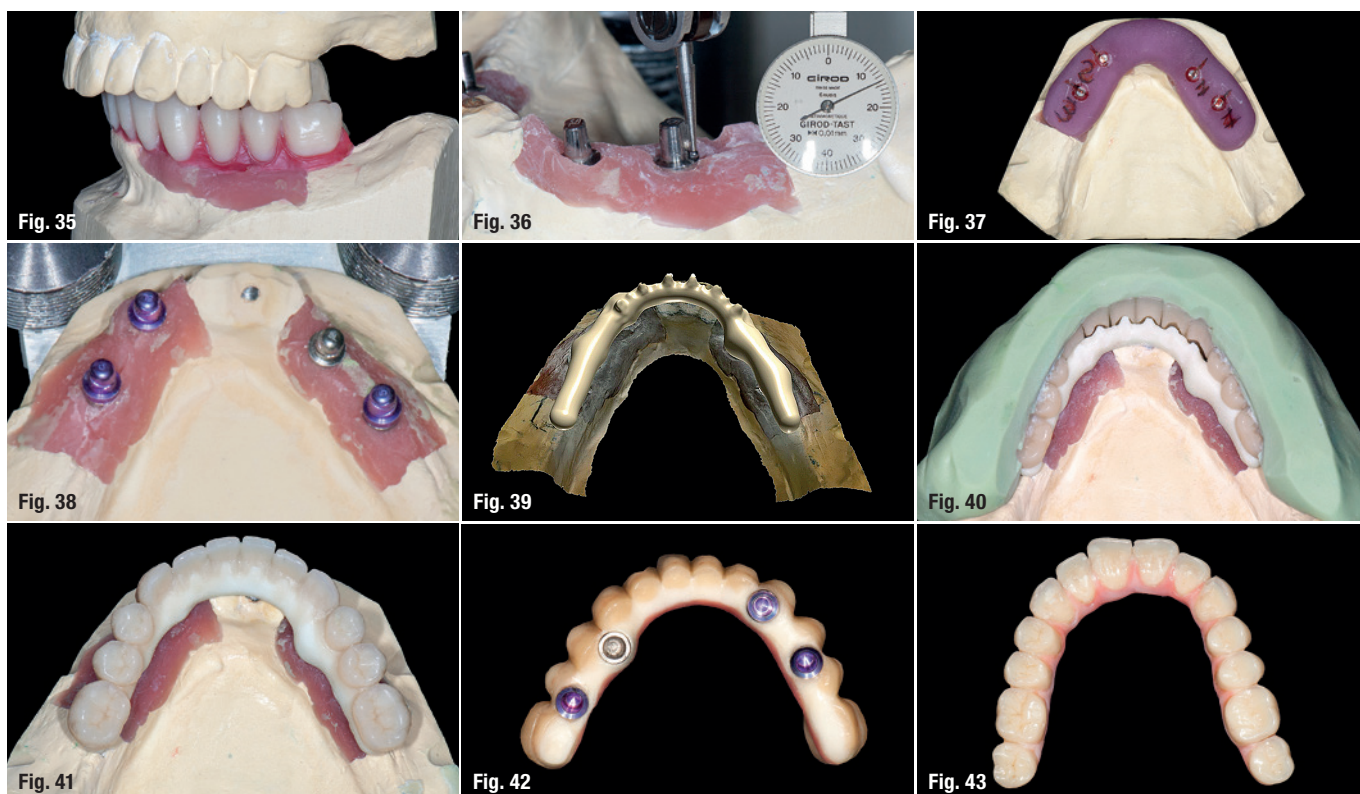


**Fig. 21:** Panoramic view of a 59-year-old female patient with pronounced mandibular atrophy (class VI) after 64 months of wearing the prosthesis. – **Fig. 22:** Lateral cephalometric radiography. – **Fig. 23:** Intraoral view with mandibular prosthesis. The image was taken after 64 months of wearing the prosthesis. – **Fig. 24:** Intraoral view after 64 of wearing the prosthesis. – **Fig. 25:** Lateral cephalometric view. – **Fig. 26:** Panoramic radiograph of a 69-year-old patient with extreme maxillary atrophy (class VI). – **Fig. 27:** Fronto-cranial view of a twelve-piece prosthesis. – **Fig. 28:** Intraoral view of a positioning splint. – **Fig. 29:** Intraoral mirror radiograph of the twelve-piece prosthesis. – **Fig. 30:** Situation after 39 months. – **Fig. 31:** Panoramic radiograph after 39 months of wearing the prosthesis. – **Fig. 32:** Screw-retained TRINIA™ construction on the plaster model. – **Fig. 33:** Twelve-piece screw-retained prosthesis. – **Fig. 34:** Retentive and passive (middle) telescope caps.

three implants of her prosthesis for 47 months. Therefore, the statistics of mandibular prosthetics show 100 per cent success for these 16 patients.

The next 69-year-old patient suffers from extreme maxillary atrophy class VI.<sup>7</sup> In such extreme cases, they used to perform Horseshoe Le Fort I osteotomy using interpositional bone grafts from the iliac crest – a very complex surgery under endotracheal anaesthesia.<sup>13,14</sup> We, in contrast, inserted two 4.0x5.0 mm

short and two 3.0x8.0 mm Bicon implants in a very brief procedure under local anaesthesia (Fig. 26). Twelve-piece TRINIA™ prostheses were integrated in the maxilla too (Fig. 27). To position the abutments easier, you can use a positioning splint made of light-cure GC plastic, on which the dental technician indicates the most favourable insertion sequence for the abutments (Fig. 28). The patients enjoy prosthetics that leave the palate free (Fig. 29). The prosthesis is either cemented, screwed or telescoped via the four



abutments. The follow-up after 39 months resulted in very satisfying radiological and clinical results (Figs. 30 & 31).

The CAD/CAM planning and milling technology facilitate the manufacture of cemented, screwed (Fig. 32 & 33) or standardised copings with two different frictions (retentive or passive, Fig. 34). Meanwhile we supplied 20 patients suffering from atrophic maxilla class VI<sup>7</sup> with 80 implants. We have lost three implants in an observation period of up to 3.2 years. The implant survival rate fell from 98.6 percent in year one to 93.5 per cent in year three. As these three patients have worn their prosthesis on three implants until the fourth implant was replaced, these again are 100 per cent of prosthetic success.

The following patient demonstration shows the CAD/CAM procedure to manufacture the retentive TRINIA™ telescopic prosthesis. After the first step comprising the setup and clinical evaluation, including the wax fitting (Fig. 35), you need to choose the adequate angular difference of two to three degrees to ensure sufficient friction (Fig. 36). A positioning splint made of light-cure GC plastic helps positioning the abutment (Fig. 37). Three retentive copings suffice for sufficient friction of the telescopic prosthesis (Fig. 38). The next step is the CAD design (Fig. 39). After having manufactured the TRINIA™ framework in the CAM milling procedure, it is positioned between the telescopic copings and the synthetic teeth (Fig. 40) and then the framework

is bonded to the teeth (Fig. 41). Figures 42 & 43 show the finished 12-piece telescopic prosthesis.

In the meantime, we have installed either multi-part bridges or complete prostheses made of TRINIA™ material in altogether 101 patients. In the observation period of 64 months, the material did not chip yet and only one broke.

## Conclusion

The observation period of 64 months for 101 TRINIA™ bridges and prostheses allows the conclusion that this is a method comparable to metal ceramic restorations.

## contact

### Prof. Dr Rolf Ewers


Chairman of CMF Institute Vienna  
Schumanngasse 15  
1180 Vienna, Austria  
rolf@cmf-vienna.com  
www.cmf-vienna.com

### Prof. Dr Mauro Marincola

Via dei Gracchi, 285  
00192 Roma, Italy

### Dr Vincent J. Morgan

DMD/Boston



**Fig. 35:** Setup of the mandibular prosthesis in the articulator.

**Fig. 36:** Measuring the angular difference of two to three degrees in order to achieve adequate friction.

**Fig. 37:** Positioning splint for positioning the abutment (numbers show the sequence of the abutment insertion) with relation to the implant axes.

**Fig. 38:** Only three retentive telescope caps (violet) are necessary for a save retention.

**Fig. 39:** Computer image of the TRINIA™ construction's CAD design.

**Fig. 40:** The milled TRINIA™ construction is positioned between the abutments and the synthetic teeth.

**Fig. 41:** The synthetic teeth are fixed on the TRINIA™ construction.

**Fig. 42:** Caudal view on the completed TRINIA™ prosthesis.

**Fig. 43:** Occlusal view on the completed twelve-piece TRINIA™ prosthesis.

# Dynamic navigation for precise implantation in cases of critical anatomy

**Author:** Dr David Burgess, United Kingdom

## Introduction

Using the CBCT image as a map, dynamic navigation guides surgeons just like a GPS guides drivers. The clinician virtually plans where implants should be placed. During surgery, the navigation system dynamically tracks the drill and the patient's jaw, providing guidance and visual feedback to ensure the implants are placed according to plan.

There are several advantages with dynamic navigation. The technology allows clinicians to place implants more accurately than free-hand. This results in improved safety and aesthetics, as it helps the clinician to anticipate and to avoid potential complications.

Other advantages are the ability to have more minimal invasive treatments, which means less chair time, less patient discomfort and less recovery time. This treatment option has generally been seen as a 'blind' procedure in the past, but the ability to avoid delicate anatomical structures due to the real-time surgical feedback makes so-called flapless surgery a valuable option.

In the following case report, Dr David Burgess describes how using computer-guided dynamic navigation helped him overcome clinical challenges for dental implant placement in the lower posterior region.

## Case report

A 75-year-old male patient had endured a gap for five years, following removal of his lower left second molar, due to an acute apical infection. He was finding mastication increasingly difficult and sought advice about the treatment options available.

## Planning for optimum implant positioning

As there was no tooth distal to the space, conventional fixed bridgework was not possible. The treatment options were either a unilateral single saddle



## info

Dr Burgess is holding four hands-on courses in 2017 for experienced implant dentists who want to incorporate dynamic navigation into their digital workflow.

Courses are available on 28 April, 16 June, 11 August and 22 September.

For further information, course reservations or other related requests, email: [dns@claronav.com](mailto:dns@claronav.com)

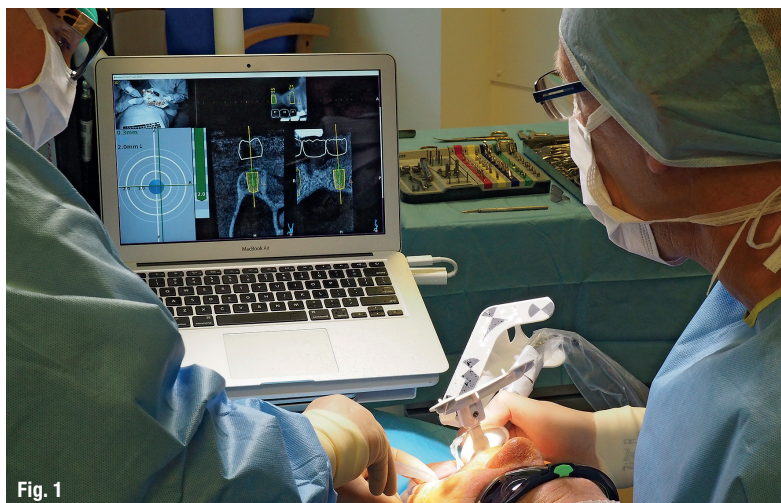


Fig. 1

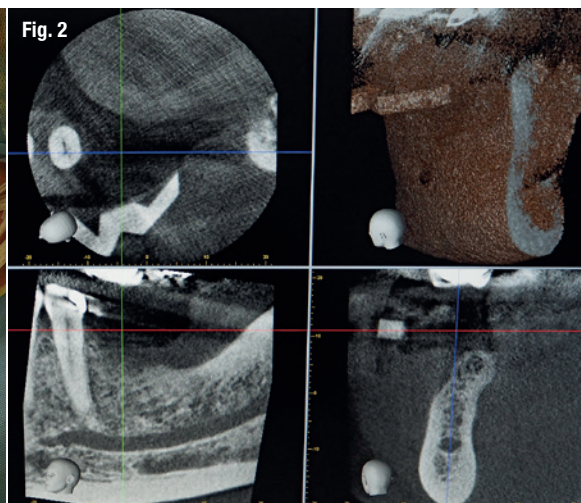


Fig. 2

**Fig. 1:** An illustrative image of Dr Burgess using Navident. – **Fig. 2:** A CBCT scan was taken two weeks prior to surgery. – **Fig. 3:** The treatment plan was created immediately after the scan. – **Fig. 4:** The patient was able to see the proposed treatment displayed by the Navident software.

lower partial denture or restoration of the space with two dental implants. The patient chose to have dental implant treatment as he did not wish to have any form of removable prosthesis.

What makes Navident dynamic navigation stand out is it precisely guides the surgeon to prepare and place the implant in a pre-determined position (Fig. 1). This allows me to achieve greater accuracy and certainty than I have previously been able to, using conventional protocols. Whilst there is no physical guide, a simple scanning template (NaviStent) is used to hold the fiducial in place whilst taking the CT scan, and secure the jaw reference (JawTag) for the navigated osteotomy.

In this case, the NaviStent was fabricated, the fiducial marker attached and a CBCT scan taken two weeks prior to surgery (Fig. 2). The treatment plan was created immediately after the scan (Fig. 3), with the patient present. He was able to see the proposed treatment displayed by the Navident software and appreciated that great care was being taken to achieve the optimum implant positioning, with minimal risk of potential complications (Fig. 4). The patient was impressed with, and reassured by, the state-of-the-art technology.

### Confidence from continuous feedback

Treatment was carried out under local anaesthesia. Prior to preparation of the implant sites, the simple Navident protocol for calibration and verification of the drill axis and drill tip was carried out. A crestal incision was made, with a minimal flap reflected. The software shows the drill position on

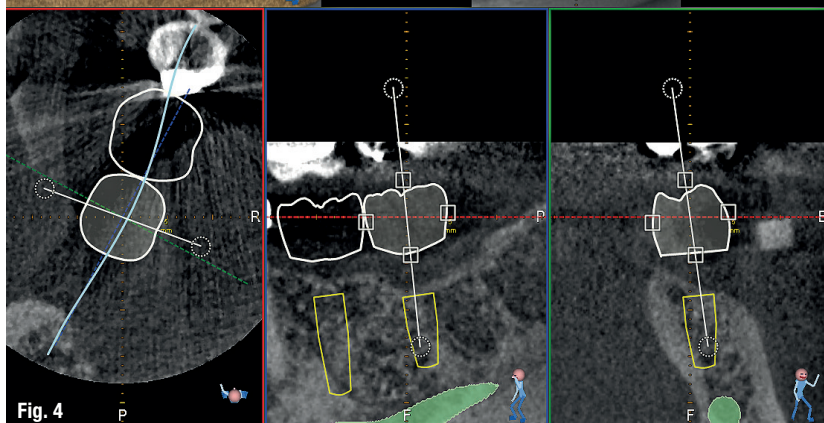
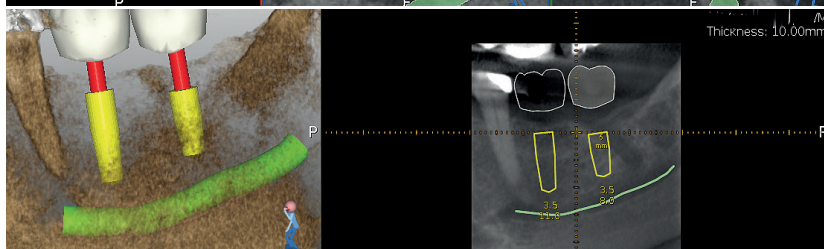
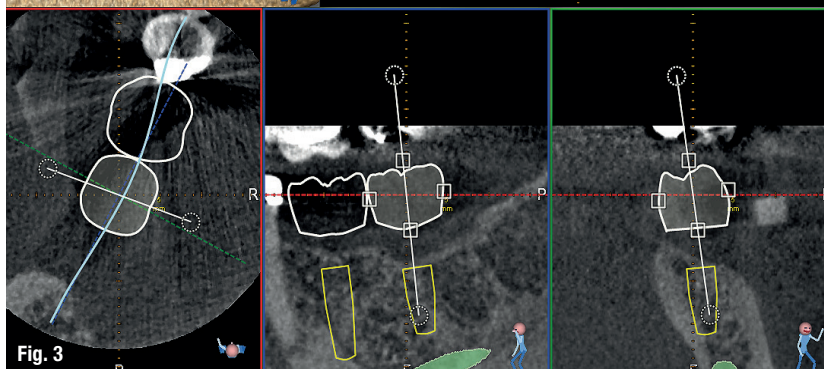
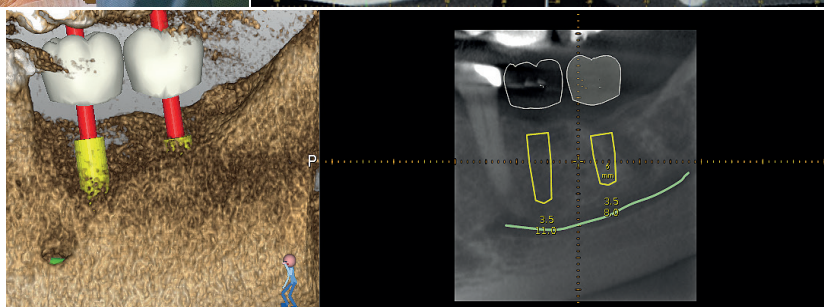
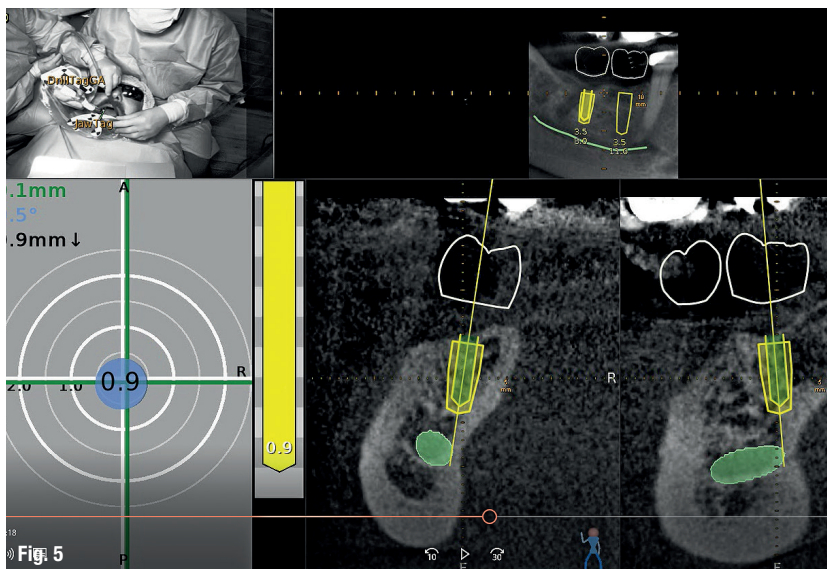


Fig. 4



**Fig. 5:** I was able to achieve the best buccal and lingual position of the implants, and their relation to each other and to adjacent teeth.

the scan in real time, as it enters the jaw. This allows adjustments to be made, if necessary, whilst the site is being drilled. Two Dentsply Ankylos® CX 3.5 mm diameter dental implants were placed sub-crestally in the lower left first and second molar sites, with implant lengths of 11 mm and 9.5 mm respectively.

Avoiding damage to the inferior alveolar nerve was a crucial factor in the treatment planning of this case. Access was difficult, due to the limited opening of the patient's mouth. The issue was compounded by the plan to place an implant as distal as the second molar. These challenges were overcome using Navident's continuous internal visual feedback, which gave the author the confidence to use the optimum length of implant, whilst staying within a safe distance from the inferior alveolar nerve and avoiding post-surgical complications, such as paraesthesia.

Navident provided guidance for accurate implant location, even with restricted visibility and the drill being impeded by opposing teeth. Tactile feedback can often be reduced when using a physical drill guide. Dynamic navigation removes this obstacle. The author was able to achieve the best-possible buccal and lingual position of the implants, and their relation to each other and to adjacent teeth (Fig. 5). This would allow for optimal shape, position and occlusal function of the final restorations.

Ankylos® Balance posterior sulcus formers were fitted and the incision was closed with simple interrupted sutures. There was no need for bone augmentation. Two to three months after surgery, the implants will be restored with Atlantis® custom-made CAD/CAM titanium abutments and screw-retained linked zirconia crowns.

## Conclusion

The clinical outcome was excellent. The planned placement was restoratively driven and the implants were well positioned, with good primary stability. Having used the Navident dynamic navigation system for more than a year, the author would not want to go back to preparing and placing dental implants without its 3-D visual guidance. The patient was comfortable and reassured, with no postoperative pain, swelling, bruising or paraesthesia. He was delighted and, if he needed any implant treatment in the future, would insist on dynamic navigation.

## About Dr David Burgess BDS DPDS MScConSed

David Burgess has been principal of Carbis Bay Dental Care in Cornwall since 1988 and has placed over 2,000 implants. Throughout his career, David has striven to combine clinical perfection with the ultimate in patient care. He has been a willing pioneer of new technology, particularly in the field of digital dentistry. David was the first UK clinician to introduce the Navident dynamic navigation system into his implant treatment workflow, with the objective of achieving a higher degree of precision and greater patient comfort.

David Burgess is also a member of the Dynamic Navigation Society as a Master Clinical Trainer, providing courses for implantologists who wish to experience how dynamic navigation can help to simplify their digital workflow. More information can be found on <http://dns.claronav.com>.

## contact

### Dr David Burgess

Carbis Bay Dental Care  
6-7 Boskerris Terrace  
St Ives Road, Carbis Bay, St Ives  
Cornwall TR26 2SF, United Kingdom  
Tel.: +44 1736 793090  
carbisbaydental@btconnect.com  
www.carbisbaydental.co.uk

Author details






# Penguin<sup>RFA</sup>

MONITOR OSSEOINTEGRATION



- ▶ Autoclavable  
20 times
- ▶ ISQ Standard  
Calibrated™
- ▶ Optimal platform fit
- ▶ Laser marked with  
type number



The ISQ-scale is from 1–99 and tells you how stable your implants are.

# Osteo-mucous restoration and implant- supported overdenture

**Authors:** Dr Ugo Torquati Gritti, Dr Daniele Vrespa, MDT Buongiovanni Armando & MDT Giancarlo Riva, Italy

The improvements of living conditions and medical care in the Western world have helped to increase the life expectancy in the population. The simultaneous evolution of prophylaxis in dentistry has also influenced the raising age, in which edentulism manifests. Nevertheless, even in the presence of undeniable improvements in dental care there is registered an increase of edentulous patients that need a full rehabilitation. Indeed, a statistical analysis carried out in the US in 1991 shows that 33.6 million people need a full denture and also points out that in 2020 this number will increase to 37.9 million people (Fig. 1).

According to the US Census Bureau, in 2005 there were 5 million senior citizens over 85 years, with a forecast of 20 million in 2020.<sup>1</sup> In Europe, the situation is not so different: Some authors report data assessing that among 65-year-olds there is the same number of fixed and removable rehabilitations within the population (Fig. 2). The removable prosthesis be-

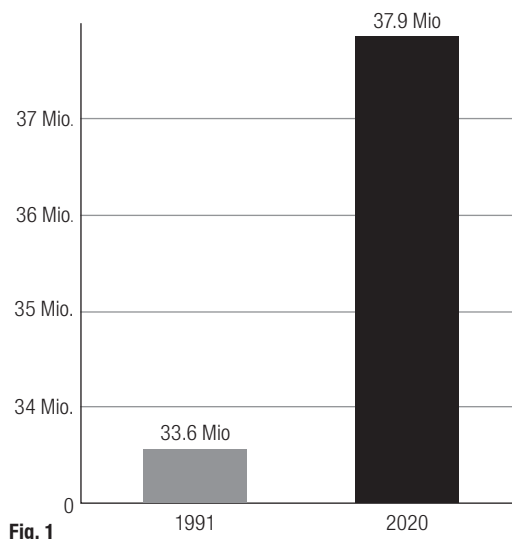
comes more and more predominant as long as the patient's age is increasing, particularly in those patients that have a low socio-economic status and education.<sup>2</sup> Both the economic situation and the increase of migration flows lead us to choose rehabilitations which are better affordable from the economic point of view.

## Prerequisite for stable dentures

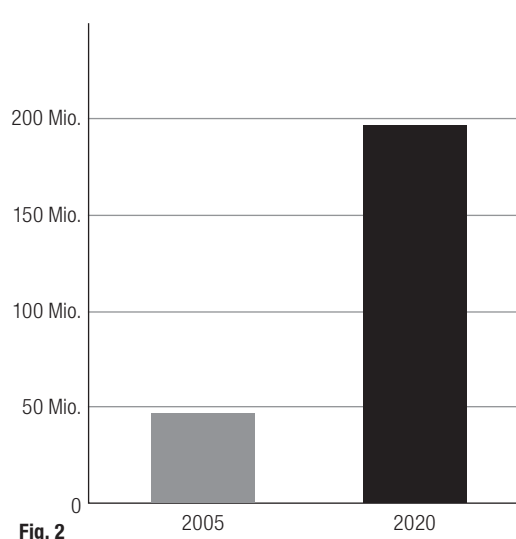
A mucous-supported or implant-supported removable prosthesis is nowadays no longer synonymous with aging as it was in the past. Even more, one of our goals when we build prosthesis is not only to improve the masticatory function, but also be able to give the illusion of a natural dentition (Fig. 3). The functional success of full denture rehabilitation, as already seen, depends on multiple factors. Clinically, not only the correct maxillar relationship and the static positioning of the dental elements are manda-

**Fig. 1:** An increasing population and life expectancy in the US will lead to a growing demand for prosthetic dentistry in 2020. Currently, 40% of those over sixty are fully edentulous.

**Fig. 2:** In Italy, 30% of the population which are more than 70 years old are edentulous.

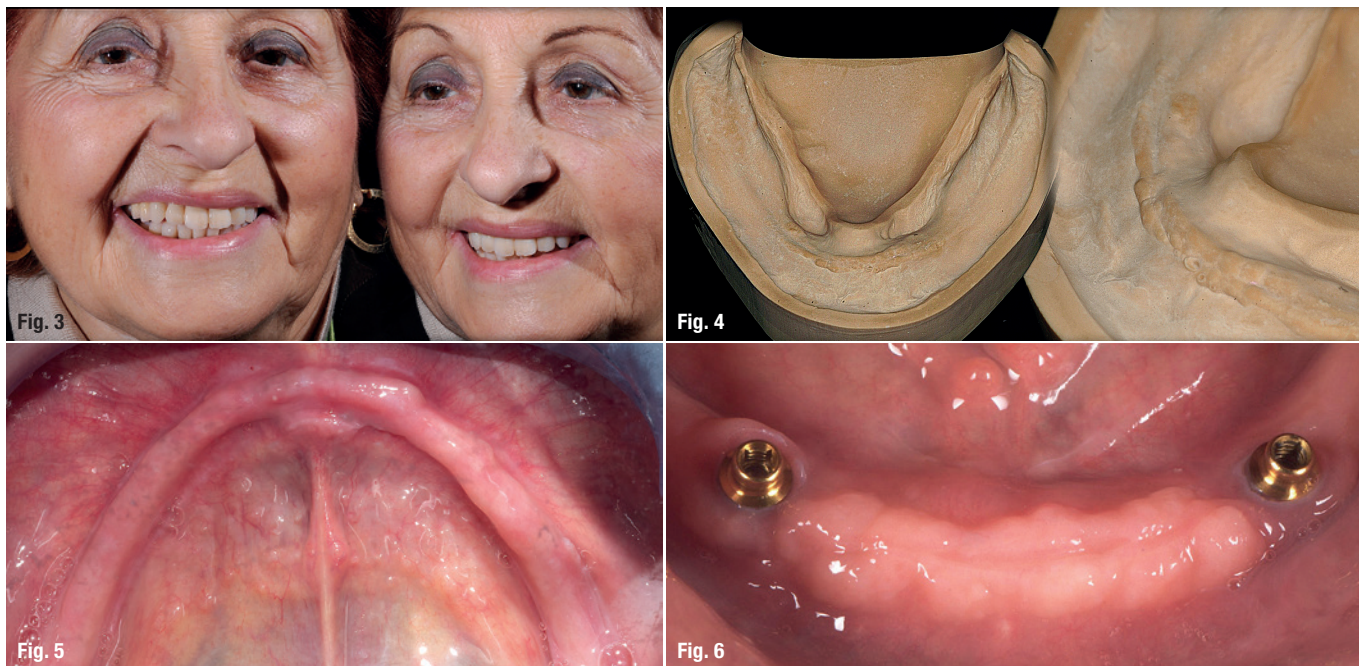


**Fig. 1**



**Fig. 2**





tory but also the general stability of the denture is a crucial point, since it is decisive for a better patient acceptance of the prosthesis.

Generally, in an edentulous patient a large and well-preserved ridge with steep sides and a correct amount of resilient mucosa is considered to be a prerequisite for a good seal and thus stability. Indeed, a well-preserved bone crest represents a good mechanical retention to the horizontal forces that are applied to the prosthesis. With a completely flat ridge instead, the prosthesis lacks any kind of retention. In this situation, the physical mechanisms of adhesion and cohesion, and the stabilising function of the muscles become clearly predominant (Fig. 4).

These considerations suggest that the presence of physical factors distinguished in adhesion and cohesion forces are a prerequisite for a stable denture, devoid of any type of mechanical anchoring. Adhesion and cohesion forces act in the interface between prosthesis and mucosa, and reach the maximum expression when the surface of the prosthesis is as wide as possible and the space between the denture base and the mucosa is as thin as possible.

### Mucous-supported dentures

The success of a treatment with an osteo-mucous-supported denture depends on the patient's acceptance and his/her sufficient adaptability to overcome unavoidable limitations that a prosthesis provides.<sup>3</sup> Accordingly, the ability of the patient to develop newly acquired reflexes plays a key role. Anyway, this ability decreases with the increasing of age, resulting in a reduction to adapt and deal with any in-

tervention in the oral cavity. This process is a fact that can threaten their physical and mental integrity.

A number of factors like denture wearing, chewing and phonetic discomfort contribute to the patient's satisfaction or not.<sup>4</sup> Often patients complain about the difficulty of eating hard foods. In consequence, they develop the habit of avoiding them, which is a well-described habit (Fig. 5). In order to increase the masticatory efficiency of the mandible, the positioning of implants represent an undeniable benefit. However, there are few objective evaluations published that suggest this to be the better solution compared to the traditional technique (Fig. 6).

Such studies would allow making more rational decisions about the best practice to put in act, in order to satisfy the patient's needs and to be in line with the widespread conviction to base a treatment on scientific evidence. The evidence of the biological success and psychosocial satisfaction lead to a general consensus that identifies the overdenture retained with two implants as the best choice for an edentulous mandible (Fig. 7).

### Implant-based dentures

The opinion of implant-based denture as best practice has been questioned. Some authors, for instance, claim that this evidence does not confirm the assertion that the implants are necessary or advisable for all edentulous patients. Literature shows that the patient's acceptance of specific therapeutic modalities is modified by social and cultural influences, financial resources and adaptability. There is also no evidence of a single mode of treatment for the edentulous

**Fig. 3:** Priority required was not to increase stability but to restore the smile line and the lip support to achieve a younger appearance of the patient's face.

**Fig. 4:** Even with critical bone ridges prosthesis can be constructed with a good seal, if the supporting surface is wide enough and with a thin gap between denture base and mucosa.

**Fig. 5:** The masticatory efficiency depends on the stability of the prosthesis; the more stable the prosthesis is the greater can be the developed forces.

**Fig. 6:** The widespread success of this evidence has led to a general consensus for a standardised proposal for overdentures anchored to two implants.

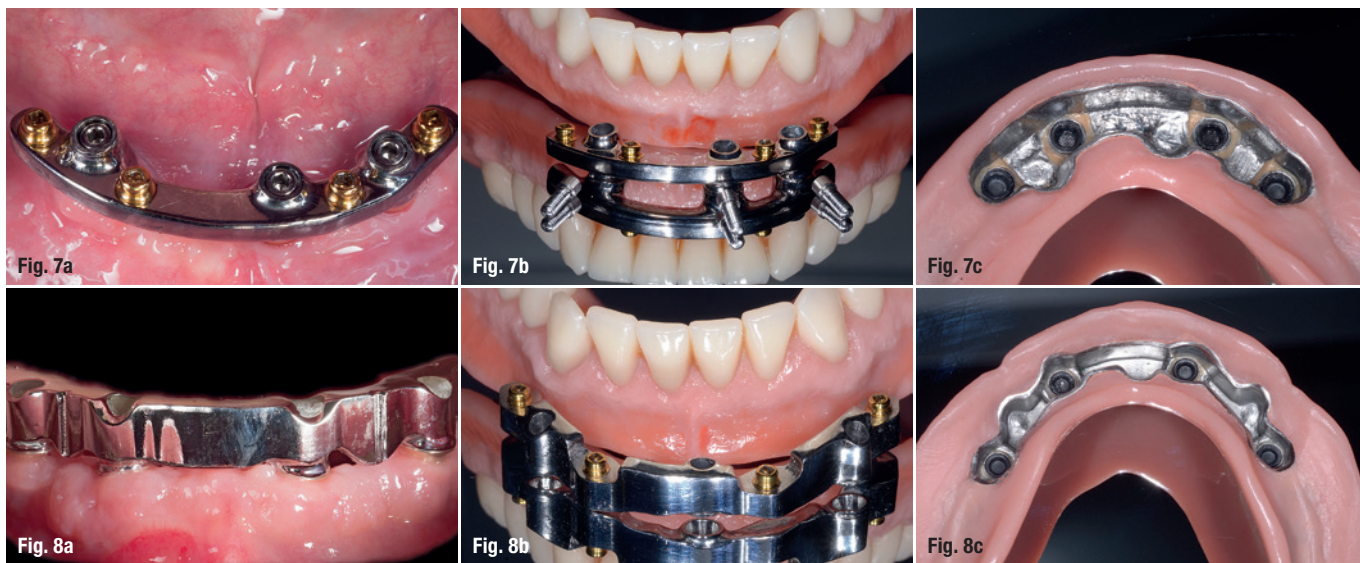


Fig. 7a

Fig. 7b

Fig. 7c

Fig. 8a

Fig. 8b

Fig. 8c

- Fig. 7a:** Implant overdenture: Attachments provide a spatial location of the prosthodontics.
- Fig. 7b:** Peripheral mucosal support provides prosthetic stability.
- Fig. 7c:** Retentive devices prevent the removal of the prosthesis from the tissues.
- Fig. 8a:** Implant-supported overdenture ensures retention and allows support during the application of the occlusal forces.
- Fig. 8b:** The insertion axis perpendicular to the occlusal plane will produce a continuous and correct relocation of the prosthodontics that avoids tensions to implant structures.
- Fig. 8c:** The peripheral seal prevents accumulation of food under the dentures.

mandible.<sup>8</sup> There is no doubt that implants, particularly in the mandibular bone, allow to better anchor dentures and thus improving their stability and retention (Fig. 6).

The question that arises may be this: How many implants do we have to insert in the jaw? Better splint them or not? The satisfaction the patient declares with the simplest prosthetic project, i.e. an overdenture with two direct spherical attachments, is not significantly different from that given by two or four implants with connecting bar (Figs. 9a & b). The choice of connecting implants between bars may be the lack of parallelism; and, if in presence of bars, it is necessary to make some distinctions.

### Implant-retained vs. implant-supported

A classification<sup>10,11</sup> divides overdentures in implant-retained and implant-supported overdentures. The first represents the best choice for those patients that have already a complete but unstable and with no retention removable denture. In this case, both the implants (from 2 to 4) and the soft tissues contribute to the retention and stability with a more economic project compared to the milled bars and counter-bars.

Different types of attachments allow the overdenture to be retained to the implants; those resilient anchoring systems guarantee moderate vertical and rotational movements of the prosthesis (Figs. 7a-c). To achieve this kind of result, Dolder bars are usually used. Both bars and the ball attachments, not connected to each other, showed no clinical differences in the patient's satisfaction and implant survival rates.<sup>12</sup> Also the maintenance of the systems shows no difference between the bars and the ball attachments.<sup>13</sup>

The second group of overdentures are supported by implants, typically anchored on a milled bar; the latter receives all the functional loads so that there is no direct contact between the prosthesis and the soft tissues. The prosthesis is removable but seats rigidly on the bar, so that all the lateral and rotational movements are limited. In addition, the full distribution of the masticatory loads on the fixture only is useful to the preservation of the bone and also positively affects the implant integration (Figs. 8a-c). Contrary to the resilient prosthodontics supported by the mucosa and retained by the implants, a milled bar prevents rotational movement of the prosthesis.<sup>14</sup>

Aside the different conception and construction of the two types of overdenture, a further differ-

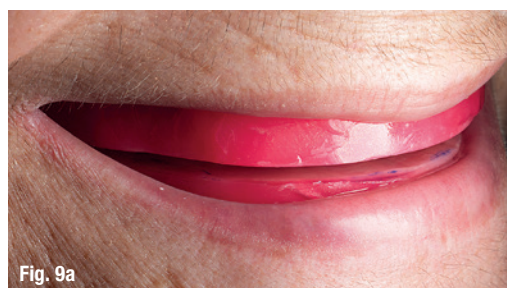

Fig. 9a

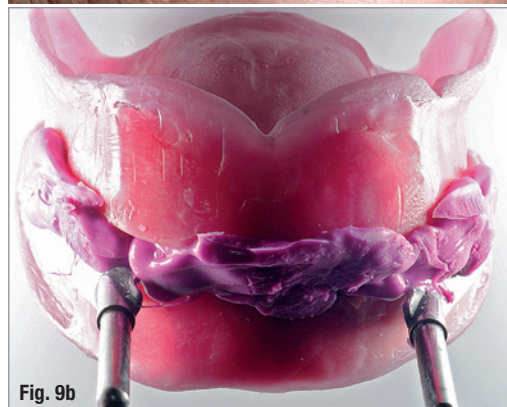


Fig. 9b

ence is the kind of maintenance to be done. The milled bars and counter-bars are more complex but they do not need the replacement of the retentive attachments. The use of an implant-supported prosthesis in the jaw can be considered a feasible option for the treatment of those patients that require clinical advantages similar to those of a fixed prosthesis but which also require the advantages of a removable denture.<sup>15</sup> For the jaw it can be concluded that bone resorption, patient satisfaction and prosthetic complications are independent of the number of implants.

This shows that it is not possible to establish anything that is the optimal number of implants for an implant-supported overdenture.<sup>16</sup> In addition, using implants in the lower jaw and using a conventional prosthesis in the upper jaw will likely encounter a full success. Not only the implants in the mandible have a higher success rate compared to those in the upper jaw, but also using a conventional upper prosthesis will decrease the stress that the implant prosthesis is subject to.

## Conclusion

In the rehabilitation of edentulous patients we have no clinical parameters that can guide us during the treatment as we have in fixed prosthesis (Figs. 9a & b). Once positioned the front group and thereby established aesthetic and phonetic parameters of the patient, a pivotal role on the choice of the type of rehabilitation is played by the vertical dimension or, better, the available space between the arches. According to some authors, the therapeutic possibilities and the optimal type of prosthetic restoration is related to the distance between the maxillary and the mandibular arch; this proposes a classification, which considers the available vertical size for the rehabilitation, defined as the distance between the mucosa and the incisal/occlusal edge of the tooth properly positioned (prosthetic space).<sup>17</sup>

These parameters, which are often ignored during the diagnostic phase, are the key to determine success of both aesthetic and functional rehabilitation. In cases where there is a large prosthetic space (class 1 more or equal to 15 mm) available, choosing a traditional fixed prosthesis would lead to unpleasant aesthetics, i. e. long teeth and lack of lip support giving an aged expression to the patient's face. On the other hand, with a reduced prosthetic space (class 4, less than 7 mm of prosthetic space) opting for a hybrid prosthesis or an overdenture, we would not have enough space to insert the components, resulting in an alteration of the correct vertical dimension or misplacement of the occlusal plane.

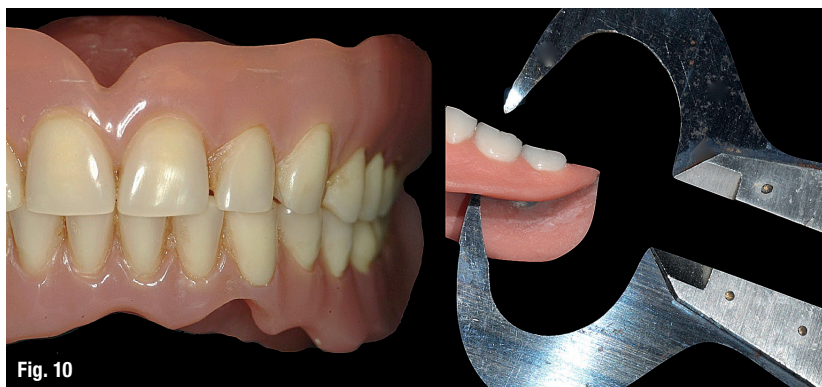

Fig. 10

According to this, the diagnostic phase becomes the most important step in which the implant position is determined as well as the resulting kind of anchorage. It may be useful to choose between two methods:

1. Detection of the impressions for the preliminary models and the mounting in the articulator with the occlusal rims. The latter will also provide the smile line and the occlusal plane parallel to the Camper plane.
2. Using the existing dentures it should be analysed, if the vertical dimension and the smile line are correct; using the Gutowsky caliper, the distance between the occlusal plane and gum from the inside of the reconstructions should also be measured (Fig. 10).

It is therefore clear that the initial diagnostic process is essential to prevent complications during treatment.

**Fig. 9a:** The correct detection of the intermaxillary relationship is one of the decisive factors for maintaining the implants' and prosthesis' stability.

**Fig. 9b:** The detection of the centric relation can be established with two methods: First, operator-dependent, where the clinician guides the mandible in centric position; second, non-operator-dependent, where the patient performs limited movements and thereby determines the centric position.

**Fig. 10:** The space available between the arches is defined by the distance of mucosa and incisal/occlusal edge of the teeth once properly positioned.



## contact

### Dr Ugo Torquati Gritti

Via Pietro Lissoni 4  
20832 Desio (MB), Italy  
Tel.: +39 0362 302102  
ugotorquatigritti@gmail.com

### Author details



# “The RFA technique must be accurate and reliable”

Resonance Frequency Analysis (RFA) is today a standard method to measure implant stability, but the measurement unit ISQ itself needs to be explained. Prof. Lars Sennerby is one of the developers and researchers behind the RFA technique and will sort things out for us below.

## Prof. Sennerby, what is your experience of the RFA technique?

Prof. Neil Meredith showed me a prototype of his invention already in 1992 and we have since then used RFA for implant stability measurements in numerous experimental and clinical studies: first as part of the early development work and Dr Meredith's Swedish PhD thesis (1997), which I supervised, and then as a clinical routine diagnostic instrument. I find it to give valuable and relevant information about implant stability at any time point during implant treatment and follow-up.

## What is the background to the ISQ unit?

The whole purpose of introducing the ISQ (Implant Stability Quotient) was to give clinicians a unique and easy quantity on a scale from 1–100; the higher the value the better the stability. ISQ was introduced in 2001 and derives from a linear recalculation of the resonance frequencies (RF) in Hertz (Hz) obtained from measurements of dental implants with the first generation of wire-bound transducers.

## How do you define the ISQ unit?

ISQ is calculated from the underlying RF of the transducer peg using a mathematical equation. The ISQ unit has not yet been defined using any other general or specific unit, simply because there is no such unit available. Instead, empirical data from more than 800 scientific publications has guided clinicians how to use the ISQ scale clinically.



Fig. 2



Fig. 1: The MulTipeg device.

Fig. 2: Prof. Lars Sennerby.

## How do we then know that implants with the same stability have the same ISQ?

It is of course desirable that different pegs for different implant designs give the same ISQ value if they have the same implant stability. This is a known problem when calibrating transducer pegs for different implant designs. It has not been so easy to solve, since implant stability per se has not been defined using any other quantity, and a reference had to be created. The reference can then be used when transducers are designed and developed. To explain the problem, think of two different implant designs that are placed in identical material and two different ISQ values are obtained. It is impossible to know if the difference depends on the fact that the two pegs are different or if it is because the stability is actually different, or a combination of the two. So a reference is indeed necessary.

**So how did you solve this problem?**

Studies have shown that bone density at the implant site determines the ISQ value and that it correlates with the implant's micro-mobility. This reflects the clamping ability of the bone, which in turn defines the micro-mobility. The problem is that different implant designs behave differently also in the same bone density, depending on surgical technique, design and self-tapping properties. So when calibrating pegs for different implant types, we embedded the different implant types in a dense material in an identical way. In addition, we gave all implants an identical outer geometry by molding each implant type into identical cylinders. The stability of each implant/cylinder can then be varied with a clamping device in a standardised manner. This also gave us the possibility to calibrate the pegs over the full ISQ scale and not only for a single value.

**How do you use this calibration method?**

With the method described above, a reference ISQ/stability relationship has been established, which is used when manufacturing Multipegs for different implant designs. Each type of Multipeg is designed to follow the standard ISQ/stability curve to assure that different types of implants show the same ISQ value

for the same stability. It is also an excellent method to assure that the peg has an optimal fit to the implant.

**Why is the above important?**

RFA is a great clinical tool, however, it is absolutely necessary that the technique is accurate, reliable and is based on a standard reference so that the stability of different implant types can be compared. This is particularly important if the academic and scientific community is going to agree on different clinical protocols based on ISQ values, for instance, when it is safe to apply immediate/early loading protocols.

**Thank you for the interview.**

**contact****Integration Diagnostics Sweden AB**

Nedergårdsgatan 5  
416 54 Göteborg, Sweden  
Tel.: +46 733 842860  
info@penguinRFA.com  
www.penguinrfa.com

AD

# 10<sup>th</sup> Arab-German Congress of Dental Implantology




12<sup>th</sup> – 13<sup>th</sup> May 2017 | Universiapolis, Agadir, Morocco

[www.agci2017.e-polytechnique.ma](http://www.agci2017.e-polytechnique.ma)

E-Mail: [AGCI2017@gmail.com](mailto:AGCI2017@gmail.com)

## Nouvag

### Let's talk Implantology



The latest development in the field of implantology by Nouvag AG is the motor system MD 11 that is now available in version 2.0. The company has now implemented the function of thread cutting and made the device handling even easier than it already was. During its development, much attention has been given to a quiet, low-vibration motor running, which is the most likely perceived feature for patient and surgeon as well. The insertion of the tubing set is done with very little effort due to the great visibility of the

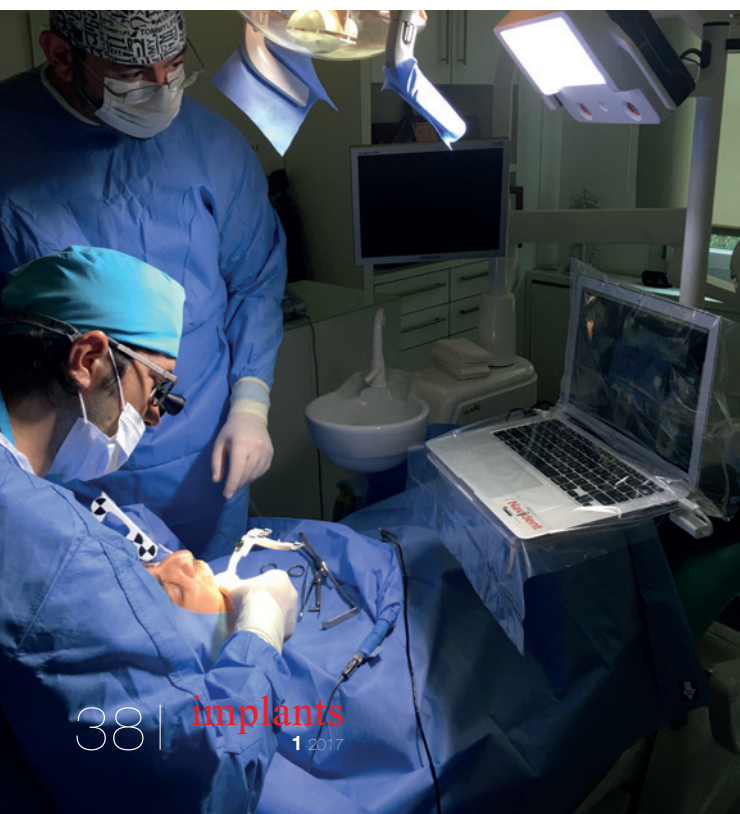mounting bracket and easy to reach notches in the bracket. To make the set of the MD 11 complete, Nouvag offers all required Contra Angles such as the 1:1, 16:1, 20:1, 32:1 and a 70:1. The 20:1 Contra Angle, available also with LED spotlight, covers the largest field of the implantologist's tasks, thanks to the sophisticated motor control of the MD 11, which provides sufficient torque from the lowest possible speed of 15 rpm to the highest speed of 1,700 rpm. At the new 20:1 Mini-E-Type Contra Angle, in conjunction with the new electronic motor with

a shorter handpiece carrier, the resting point lies between the surgeon's thumb and index finger, allowing for a better balance and force delivery to the drill. Customers can ask sales representatives any question about the MD 11 via the company's website and will soon receive a detailed answer with a quote and the address of a local dealer. With any Nouvag device and accessory comes a piece of safety, precision and reliability, made in Switzerland.

**Nouvag AG**  
**Schulthaißstraße 15**  
**78462 Constance, Germany**  
**www.nouvag.com**

## ClaroNav

### Affordable image-guided navigation system



Navident is a dynamic navigation system for dental implants developed by ClaroNav Inc. that is used all over the United States, Canada, Asia and Europe. It offers dental surgeons, for the first time ever, an affordable image-guided navigation system that provides real time access to information about the advance of the drill tip: its exact location, depth and angulation in the patient's jaw relative to the dental implant plan. Implantation procedures can be less invasive, more accurate, safer, faster and less stressful. Subsequent restorations can be easier and less costly. Recently, ClaroNav launched the Dynamic Navigation Society (DNS), its educational division that provides peer-to-peer education. DNS organises courses worldwide, bringing experienced clinicians together with interested doctors for courses, over-the-shoulder sessions and live surgeries. Courses are offered in a variety of formats (half day, 1-day, 2-day, weekday or weekend) to accommodate the clinician's schedule. For more information, email [info@claronav.com](mailto:info@claronav.com) or visit us at IDS 2017 (Hall 2.2, A.061).

**ClaroNav Inc.**  
**1140 Sheppard Avenue West, Unit 10**  
**Toronto, Ontario, Canada**  
**www.claronav.com**

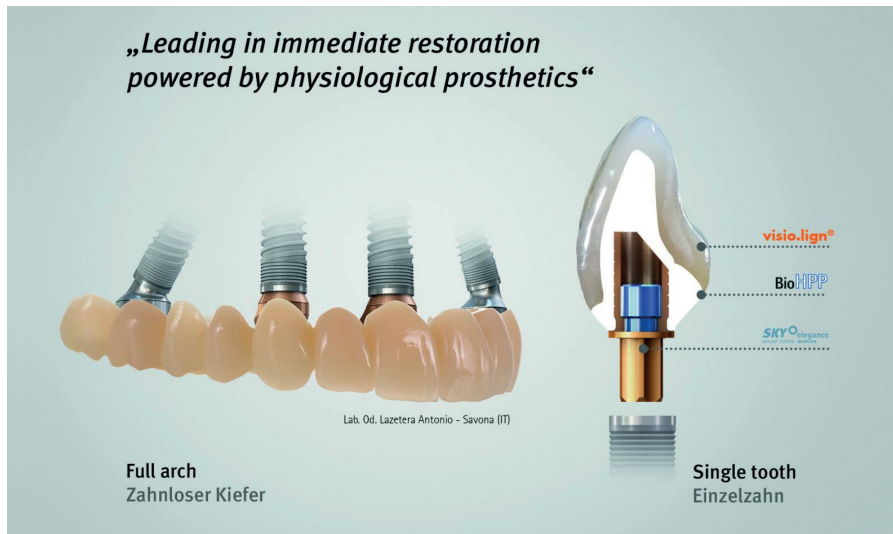
## Immediate restoration for any indication

In the event of a loss of teeth, patients desire a cost-effective and rapid restoration. Using an immediate restoration, the treatment time is

shortened and therefore costs are also reduced. Using the BioHPP SKY elegance hybrid abutment by bredent medical, single tooth resto-

rations can be carried out and small bridges can be restored immediately. Because the BioHPP SKY elegance hybrid abutments are as elastic as a temporary abutment, they can be inserted straight after the implantation. This type of restoration has already proven successful for 5 years and has demonstrated exceptional results in clinical practice.

The immediate restoration from the SKY fast & fixed treatment has even proven itself in patients whose jaws are becoming edentulous. Almost 30,000 patients have been treated with this system in the last 10 years. The blueSKY implants are inserted as soon as the last teeth have been extracted and are treated using a temporary bridge, according to a standardised protocol.



**bredent medical GmbH & Co. KG**  
**Weißenhörner Straße 2**  
**89250 Senden, Germany**  
**www.bredent-medical.com**

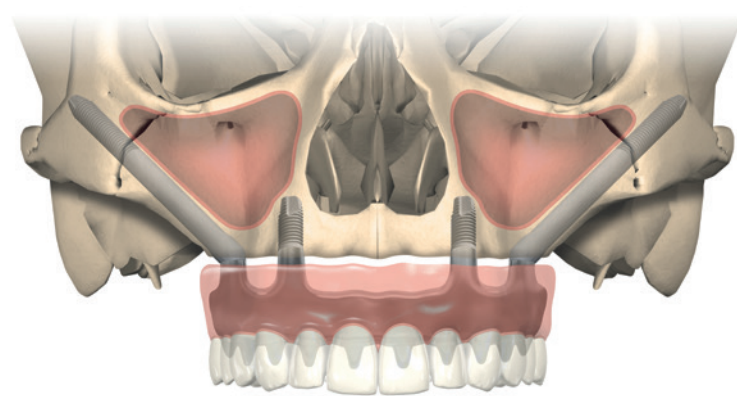
## Graftless treatment of severe maxillary resorption

For patients with severe maxillary resorption, extensive grafting procedures can mean lengthy treatment times. But there is an alternative: By anchoring in the zygomatic bone, the NobelZygoma implant system can enable an immediate loading protocol for a graftless treatment. This dramatically shortens time-to-teeth and can allow patients with severely resorbed maxillae to return to a normal quality of life.<sup>1</sup>

The new NobelZygoma 0° and NobelZygoma 45° implants anchor in zygomatic bone and provide an excellent option for treating severe maxillary resorption. They have an unthreaded implant body designed to interface with soft tissue, and depending on the anatomical situation parts of the implant body can be located outside of the maxillary sinus. For the extra-maxillary placement, the coronal part of the implant should still have bone support. This technique enables a position of the implant head close to the crest of the alveolar ridge

that facilitates a prosthetic procedure which in turn offers easier cleaning and better comfort for the patient<sup>2</sup> while improving phonetics<sup>3</sup>.

The straight implant head and mount-free insertion of the NobelZygoma 0° implant allow for greater flexibility during implant placement. The clinician can also enjoy prosthetic versatility with the new 45° and 60° Multi-unit Abutments. The NobelZygoma 45° implant comes in an ex-



tended range of implant lengths, from 30 mm to 52.5 mm, all with an external hex connection.

Attending IDS? Head to the Nobel Biocare booth in Hall 10.1 to see for yourself.

**Nobel Biocare Services AG**  
**P.O. Box**  
**8058 Zurich-Airport, Switzerland**  
**www.nobelbiocare.com**

References



## NucleOSS

### Expansion on German-speaking market

NucleOSS has seen an enormous interest in their home market in Turkey as well as in other countries worldwide on the T6 implant line. This well-approved implant offers a stable internal connection and a simple handling combined with

a completely colour coded system which makes the usage for customers easy and time effective. Furthermore, the T6 implant system is evaluated and approved by the NucleOSS' scientific committee TFI academy.

Based on the increased demands from the German-speaking market, NucleOSS Europe GmbH has strengthened its management team with Wolfgang Müller, who has precious and longstanding management experiences in the area of dental implants. One of the next steps will be to enlarge the German office and warehouse for the German, Swiss and Austrian market, so that the company will be prepared for the increasing demands and be able to offer the best customer service possible, as Salih Sanli, CEO and founder of NucleOSS, states. At the same time, the company announces its newly developed product line which will soon be introduced to the dental market. NucleOSS is convinced that the advantages of its system covering all treatment options in the field of prosthetics will be assessed as an innovative and modern system, offering a high class implant with all surface structures for an attractive price of only 69 EUR.



**NucleOSS Europe GmbH**  
Floßhafenstraße 6  
41460 Neuss, Germany  
[www.nucleoss.com](http://www.nucleoss.com)

## Dentaurum Implants

### Become a certified “Expert in Dental Implantology”

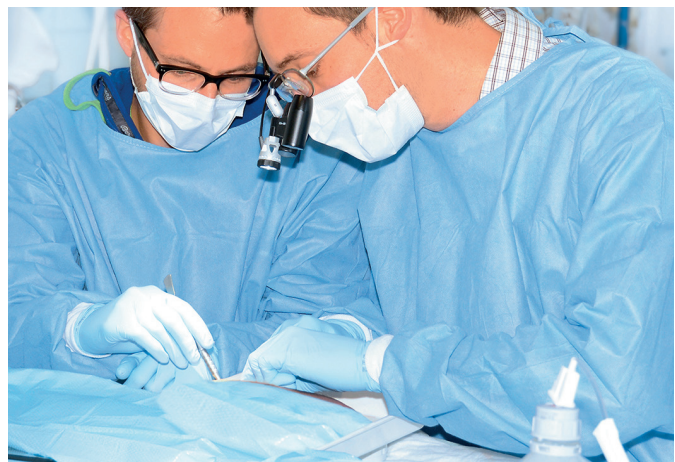Would you like to know how to achieve perfect aesthetics when working with implants? Are you interested in finding out what possibilities there are when not enough bone material is available? Would you like to have comprehensive training in implantology? Then you really should save this date in May 2017. Dentaurum Implants is holding a series of courses under the title “Expert in Dental Implantology”, offering participants the chance to improve specialist knowledge in the field of implantology. The courses have been specially coordinated to provide broad information covering various aspects such as implant planning, implant insertion, dental technical variants, management of hard- and soft-tissue, augmentation processes as well as anatomy and operation techniques, all taught using human specimens.

With the help of an expert team, the courses will give an insight into the world of implantology. Emphasis is placed on practical work; hands-on exercises will help to transfer the newly-acquired knowledge to the daily work in the dental practice.

The courses are run in cooperation with the Faculty of Medicine at the Friedrich-Alexander University (FAU) Erlangen-Nürnberg, Germany. In the spirit of the uni-

versity's motto “Advance through networks”, the faculties and departments work together. Participants, too, can benefit from the interdisciplinary teaching and research. The course will be from 8 to 16 May 2017 with a restricted number of participants.

**Dentaurum Implants GmbH**  
Turnstraße 31  
75228 Ispringen, Germany  
[www.dentaurum-implants.com](http://www.dentaurum-implants.com)





## Dentsply Sirona

### Enhanced range of TiBases for more implant systems

At the 25<sup>th</sup> Annual Scientific Congress of the European Association of Osseointegration (EAO) in Paris, Dentsply Sirona CAD/CAM presented CEREC's enhanced range of TiBases: Together with the corresponding scanposts, these enable hybrid custom abutments and/or screw retained crowns to be delivered in a single patient visit.

With the new TiBases, further implant systems are now supported in CEREC, in particular those from Dentsply Sirona Implants with Ankylos® & Astra Tech Implant System EV® which, up to now, were not part of the CEREC portfolio. TiBases and scanposts have been introduced for these as well as for BioHorizons (internal connection) and OSSTEM TS.

TiBases form the basis for two-part customised abutments. Hybrid abutments with a TiBase can be used as a screw-retained crown, as a



provisional restoration and as a customised healing abutment. They can be processed and inserted directly in the dental practice. Hybrid abutments with a meso-structure made up of zirconium dioxide boast, compared to those made of titanium, improved apposition on the gingiva and enable better aesthetics to be achieved. In addition to zirconium oxide, further materials from CEREC material partners can be used, such as IPS e.max from Ivoclar Vivadent.

**Dentsply Sirona**  
**Sirona Straße 1**  
**5071 Wals/Salzburg, Austria**  
**www.dentsplysirona.com**

## Integration Diagnostics Sweden

### Customer-oriented product design and a strong market impact

Integration Diagnostics Sweden is rapidly growing by adding distributors to its global network, with a close cooperation with most major implant companies and constantly adding more implant systems to its Multipeg assortment. PenguinRFA is now available in more than 30 countries by 17 distributors, currently covering more than 36 implant systems with Multipegs.

Multipegs are made from durable, tissue-friendly titanium and has sealed magnets, which makes it possible to autoclave them at least 20 times. They are also laser marked with type number to avoid mix-ups or using the wrong Multipeg. The PenguinRFA concept is affordable, uncomplicated and with reusable Multipegs—just what

clinicians are asking for. The instrument is handheld and very user friendly, which makes the learning curve very short, fulfilling the customers' demands. Strong business partners add to the market success.

In addition the RFA technique has become even more accurate by creating an ISQ standard calibration system, which means minimised variance between different Multipegs. Due to the reference system, physical misfit between components can be detected and eliminated. In the future, Integration Diagnostics Sweden will continue to build its distributor network globally and intensify the research around implant diagnostics.

**Integration Diagnostics Sweden AB**  
**Nedergårdsgatan 5**  
**416 54 Göteborg, Sweden**  
**www.penguinrfa.com**




## MIS

### Fixed restorations for atrophic ridges

The MIS MULTIFIX solution allows for a comprehensive treatment plan for edentulous patients, of full-arch, immediate restoration, using Multi-Unit abutments on just four implants. This greatly reduces patient treatment time and alleviates the need for multiple visits.

Patients who have undergone the MULTIFIX procedure report an improved quality of life, a regain of their lost social confidence and improved function and overall appearance. For these patients, who are completely edentulous or close to it, the greatest advantage is the time and discomfort saved. Procedures

which may have taken months to complete and included complicated surgery and bone grafting, have now been simplified



and optimised, enabling a full-arch prosthesis to be seated on four implants on the same day of placement.

Additionally, the straight and 30° angulated Multi-Unit abutments allow for optimal distribution of force thanks to the unique insertion tool of the angulated units, as well as high stability which is achieved by the longer implants and posterior angulated placement of them.

**MIS Implants Technologies GmbH**  
**Simeonscarré 2**  
**32423 Minden, Germany**  
**www.mis-implants.com**



© Ray\_of\_Light/Shutterstock.com

# Japan Annual Meeting 2016 of ISOI and DGZI in Tokyo

**Author:** Dr Rolf Vollmer, Germany

From 12 to 13 November 2016, the annual ISOI meeting of the Japanese DGZI fellow society took place in Tokyo. Having been founded ten years ago and now featuring more than 700 members, the International Society of Oral Implantology (ISOI) is among the most important DGZI partner societies. Both DGZI and ISOI members greatly appreciated the palpable hospitality and close personal relationships during the congress.

At last year's ISOI meeting, the DGZI was represented by its 1<sup>st</sup> Vice President and Treasurer Dr Rolf Vollmer. Keynote speaker from Germany was oral surgeon Dr Manfred Nilus. On the eve of the congress, a traditional party for speakers and members of the board as well as all members who were involved in the congress was held. Prof. Dr Naotaka Sugiyama, ISOI President, and Dr Hitoshi Yamawaki, ISOI Vice President, as well as members of the board Dr Takatomo Arai, Dr Waturo Komuro and Dr Osamu Yamashita addressed the audience in short introductory speeches. Dr Sugiyama pointed towards the friendly

relationship between DGZI and ISOI and expressed his regret that he had not been able to partake in the DGZI congress in Munich due to personal reasons. Dr Rolf Vollmer responded to this in his introductory speech by presenting Dr Sugiyama with a small Munich souvenir, hoping to make up for the missed opportunity to visit the Oktoberfest. On Saturday, participants were given the chance to visit workshops. In addition, the ISOI conducted tests for their qualification "Authority in Dental Implantology".

On Sunday morning, Dr Sugiyama welcomed the nearly 400 congress participants at the Maihama Hotel, which is situated at the Tokyo Bay near Disneyland. This year, the congress seemed to have been modelled according to DGZI tradition, taking place at the hotel and featuring snack breaks in which participants chatted with representatives from the dental industry. This new congress design received general approval. In his introductory speech, Dr Sugiyama also outlined the significance of education and a thorough knowledge of anatomic structures for protecting the

Author details





Fig. 1

**Fig. 1:** Participants of the ISOI (International Society of Oral Implantology) meeting 2017.

patient from any disadvantages or impairments. He further stated that this premise had not always been a given in the past, resulting in serious emergencies.

Dr Vollmer likewise highlighted to the DGZI educational structures, the international relationships of the society and the special importance of its Japanese partner ISOI in his introductory speech. His presentation was completed by images from the past years and the DGZI Congress in Munich. He also mentioned that Dr Komuro, ISOI member of the board, successfully passed his exam as expert in oral implantology. The chairman thanked Dr Sugiyama and Dr Vollmer for their introductions and handed over to Dr Manfred Nilius.

Dr Manfred Nilius' speech was titled "Digitalisation in Modern Implantology and Maxillofacial Applications", raising the questions if digitalisation was mandatory or dispensable in these disciplines. He answered this question with case examples, which illustrated indications and opportunities of digital applications in implantology and oral surgery. His concept follows the principle "from simple to complicated" and especially relies on interdisciplinary cooperation. The first part of his speech discussed

a simple, minimally invasive implant procedure, whereas the second part addressed the digital capture and planning of autologous bone augmentation. The third part focussed on guided implantation with laboratory-fabricated templates. The fourth part explained the concept of dental and facial harmonisation. Dr Nilius introduced the case of a 30-year-old female patient, who presented with the wish to change the aesthetic appearance of her teeth and her whole face. An intraoral scanner was used to capture the anatomic data of both teeth and extraoral facial features. Face and tooth shape were then measured and the digitally optimised tooth form was used to prepare the teeth, which were then scanned again. After the data sets had been coordinated, the intraoral as well as extraoral situation became visible. Postsurgical pictures show a harmonious face which corresponded to the patient's wishes.

The last case gave impressive evidence of how the harmony of facial expressions can be improved. A male patient presented with a high need of maxillofacial reconstruction. A harmonious facial expression was restored with the help of maxillofacial surgery, implantology and osseous surgery (osteotomy/chin

**Fig. 2:** DGZI and ISOI Treasurers Dr Takatomo Arai and Dr Rolf Vollmer.

**Fig. 3:** Dr Vollmer presents Dr Komuro with his expert certificate.



Fig. 2



Fig. 3



Fig. 4

**Fig. 4:** ISOI members of the board with international speakers, among them from Germany: Dr Rolf Vollmer (centre), Dr Manfred Nilius (fifth person from the right side).

**Fig. 5:** Kenchoji Temple in Kamakura.

resection). The following treatment steps were performed:

- Diagnosis
- Evaluation of the three-dimensional proportions and depth of the bone
- Discussion of alternative treatments
- Additional findings and a precise analysis of defect proportions
- Selection of the implant design
- Treatment method
- Informing the patient.

Advantages:

- Advantages in scheduling the treatment
- Reduced operating time due to exact planning and workflow integration
- Forensic advantages
- 3-D documentation for any legal affairs

Speakers agreed that digitalisation has become obligatory in dental implantology and maxillofacial surgery.

The following speaker, Dr Yasutomo Yasima, talked about "Dentistry and Dental Implants" and the consequences of a treatment which does not follow professional standards. He reported on serious cases with severe consequences for both dentist and patient. Furthermore, he discussed digitalisation in dentistry and implantology and spoke on the opportunities of CAD/CAM constructions and productions.

After the break and expert discussions, Dr Henry Kwek talked about the importance of soft- and hard-tissue management. Providing impressive examples, he explained how to achieve long-term success. The documentation of the surgery and follow-up of up to nine years showed excellent results.

Dr Madahiko Kamesiro reported on the application of auxiliary implants for immediate stabilisation of dentures after implantation and their advantages compared to immediate loading of implants.

The congress concluded with speeches by Dr Yosimi Kakumoto and dental technician Akihide Itou on the opportunities provided by intraoral imaging and its application in CAD/CAM technology. They extensively illustrated the use of these technologies in general dentistry as well as dental implantology. Dr Sugiyama and Dr Vollmer thanked the participants for their attendance and interesting speeches representing the state-of-the-art 2016. The next DGZI congress will take place from 29 to 30 September 2017 in Berlin. \_



Fig. 5

## contact

### DGZI Central Office

Paulusstraße 1  
40237 Düsseldorf, Germany  
Tel.: +49 211 16970-77  
Fax: +49 211 16970-66  
sekretariat@dgzi-info.de  
www.dgzi.de

About the society



# Membership Application Form

I hereby to apply for membership of the DGZI – German Association of Dental Implantology (Deutsche Gesellschaft für Zahnärztliche Implantologie e.V.).

Please send this form via FAX to +49 211 16970-66.

Do you have experience in implantology? (mandatory)

- Yes  No

I hereby agree to have my personal data processed for all purposes of the DGZI.

- Full membership (outside Germany)** ⇒ 125 Euro p.a.   
 **Assistant doctors (outside Germany)** ⇒ 60 Euro p.a.   
 **Students/auxiliaries (outside Germany)** ⇒ free of charge for first-degree students of dentistry

- I have transferred the annual fee to the DGZI bank account c/o Dr Rolf Vollmer:  
 IBAN: DE33 5735 1030 0050 0304 36 | KSK Altenkirchen | SWIFT/BIC: MALADE51AKI

## Personal Data

Name	First Name	Date of birth
Title	Citizenship	
Street	City, ZIP code	Country
Phone, Country and Area code	Fax	
E-Mail	Homepage	
Special qualification	Spoken languages	

## Payment (by credit card)

Please use your: (Please mark as appropriate)

- Visa  MasterCard

Card holder's name	Card number
Expiry date	
Signature	Place, Date

Please complete this application form in block letters.

**FOR FURTHER INFORMATION PLEASE CONTACT**



Deutsche Gesellschaft für Zahnärztliche Implantologie e.V.  
 Central Office: Paulusstraße 1, 40237 Düsseldorf, Germany  
 Phone: +49 211 16970-77 | Fax: + 49 211 16970-66 | office@dgzi-info.de | www.dgzi.de



DGZI and Maghreb countries agree on

## Partnership and Meetings

**Libyan Health Minister welcomed Partnership**  
On the fringes of the United Nations climate conference on 16 November 2016, DGZI member Dr Ali Elmalih, who is a DGZI representative in the Maghreb region, met the Minister of the Libyan Health Dr Omar Bashir Al-TaHER. At the meeting in Marrakech, Morocco, Dr Elmalih handed

the minister a letter from DGZI Vice President Dr Rolf Vollmer, and also a memorial shield from the DGZI. Dr Elmalih discussed with the Minister the 10<sup>th</sup> Arab-German Congress of Dental Implantology, which will be held in the city of Agadir, Morocco, accompanied by the first German-Maghreb Countries Meeting of Dental Implantology. The minister welcomed this matter and wished the congress and the DGZI good success in the region.

### First German-Maghreb Countries Meeting

For many years now, the DGZI maintains a close partnership with members and colleagues in the Arab world, which manifests in regularly held meetings—the Arab-German Congress. For the 10<sup>th</sup> time, the Congress will take place on 12 and 13 May 2017. This year's hosting place will be Agadir in Morocco—with this, the DGZI expands its Arab-German

partnership to the Maghreb region for the first time, which includes the countries Lybia, Tunisia, Algeria, Mauritania and Morocco. Under the supervision of DGZI Vice President Dr Rolf Vollmer and Head of the International Section Prof. Dr Mazen Tamimi, DGZI member Dr Ali Elmalih invites all interested to the 10<sup>th</sup> Arab-German Congress and first German-Maghreb Countries Meeting of Dental Implantology. There will be much space for exchanging expertise between Arab Maghreb people and Germans and thus creating an international social community. For more details about the scientific programme, exhibition map, registration and fees visit the congress' website under <http://AGCi2017.e-polytechnique.ma>.



DGZI mourning the death of

## Dr med. Wolfgang Schwab (1956–2016)

If you ask professionally active physicians and dentists which university professors left the most persisting impression on them during their course of studies, anatomists are most frequently named. The Dresden anatomist Wolfgang Schwab, who recently passed away following a long severe illness, was one of these teachers.

Despite his routinely large teaching burden he pursued new scientific questions in anatomy focusing particularly on dental development and the histology, cell biology and microbiology of normal and osteoarthrotic cartilage. He focused his work primarily on caveolins, integral membrane protein molecules of caveolae, presenting new and relevant findings on their expression, regulation and function in articular chondrocytes. This work on the biology of cartilage cells lead to his habilitation in 2006 in the medical faculty of the TU Dresden. He submitted a very extensive text titled, "Structure, function and pathological aspects of the chondrocytes and joint cartilage".

Further cell-biological and molecular-biological contributions followed, focusing on the biology of dental epithelial cells. In the past several years,



Wolfgang Schwab was very much involved in clinical-anatomical advanced training and continuing education for physicians and dentists, especially in courses aimed at dental implantologists. He increasingly dealt with questions arising from the clinical point of view using macroscopic and histological methods and presented numerous new clinically relevant findings on humans, e.g. on the nervous supply to the jaw regions.

Dr Schwab has supported the DGZI since 1999 with his anatomy courses. He also participated in establishing an extensive manuscript which formed the foundation for the DGZI Curriculum Anatomy and will be applied by many students in the future years.

Wolfgang Schwab leaves behind his wife and three sons. His former students, his colleagues and scientific peers will always remember him with gratitude for his exemplary commitment to teaching, and, above all, for his distinctive personality. The curriculum for students of dentistry, which he had shaped over the years will be continued in his spirit.

*Prof. Dr Werner Götz, Prof. Dr Michael Kasper, Dr Ute Nimtschke*



# 3<sup>RD</sup> ANNUAL MEETING OF


# ISMI | INT. SOCIETY OF METAL FREE IMPLANTOLOGY



May 5–6, 2017

Constance, Germany — Hedicke Gastro Benefits

BOOK ONLINE / CONGRESS PROGRAM



www.ismi-meeting.com

**Metal-free Implantology—  
Defining its position**

**Scientific Director  
Dr Karl Ulrich Volz/Constance (DE)**

## PRE-CONGRESS

FRIDAY, May 5, 2017

### SYMPOSIUM CAMLOG


10.00–12.00 **Dr. Frederic Hermann/Zug (CH)**  
Two-piece zirconium dioxide implants—Scientific and clinical aspects

**Jens Strohm/Wimsheim (DE) (CAMLOG)**  
Introduction of the CERALOG implant system.  
Components and indications


**Dr Siegmund Döttelmayer/Bad Aussee (AT)**  
Examples of use and case presentation in respect to the live operation

12.00–13.00 **Opening BBQ**  
Opening of the Dental Exhibition


### LIVE OP

13.00–14.00 **Live OP 1**  
 Implantation with CERALOG implantat system  
**Dr Siegmund Döttelmayer/Bad Aussee (AT)**

14.00–14.30 Break/Visit of the Dental Exhibition

14.30–15.30 **Live OP 2**  
 WhiteBeauty—Implantation in the anterior or posterior region  
**Priv.-Doz. Dr Armin Nedjat/Flonheim (DE)**

15.30–16.00 Break/Visit of the Dental Exhibition

16.00–17.00 **Live OP 3**  
 Sinus lift with the new SDS sinus implant without bone replacement material  
**Sabine Hutfilz/Chemnitz (DE)**

### SYMPOSIUM SWISS DENTAL SOLUTIONS

10.00–12.00 **Dr Karl Ulrich Volz/Constance (DE)**  
New implants and concepts in 2017:  
– The new BONE-GROWING IMPLANTS  
– The new SHORT IMPLANTS  
– The new surgical/implantological concepts (BTP Biological Treatment Protocol, The Swiss Biohealth Concept, ALL IN ONE CONCEPT and many more)

### LIVE OP

13.00–15.00 **Live OP 4**  
 Immediate implant placement in maxillary region with immediate restoration  
**Dr Karl Ulrich Volz/Constance (DE)**

**Note:** Please note that the symposium Swiss Dental Solutions and live operations will take place at Swiss Biohealth Clinic. SWISS BIOHEALTH AG, Brückenstr. 13–17, 8280 Kreuzlingen, Schwitserland. www.swiss-biohealth.com

### EVENING EVENT | ISMI WHITE NIGHT

Hotel Villa Barleben am See, Constance

17.30 onwards: Apéro and get-together with small delicacies from the region

19.30 dinner: Barbecue specialties and selected wines enjoyed in the historic villa's beautiful garden surroundings Barleben (Finish: midnight)

Price per person: 120,- € plus VAT

Registration is required for the evening event (limited numbers of participants). Please indicate your wish to participate on the registration form.

## MAIN CONGRESS

SATURDAY, May 6, 2017

Including breaks and discussions

(Simultaneous translation German/English, English/German)

09.05 – 09.20 **Dr Karl Ulrich Volz/Constance (DE)**  
Greeting and opening  
Ceramic implants state of the art – Where we stand and where we intend to go?

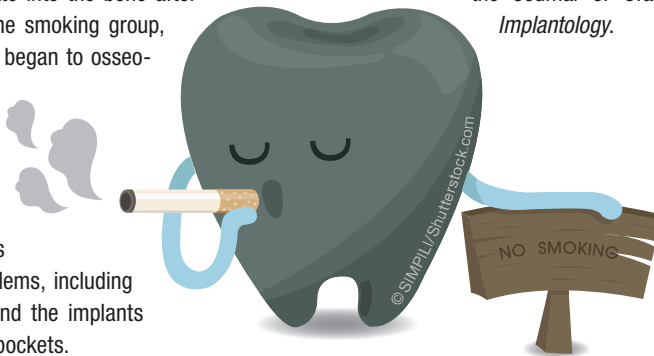
9.20 – 09.50 **Dr Karl Ulrich Volz/Constance (DE)**  
BONE-GROWING IMPLANTS: A quick and reliable path to success with new implant types and smart bone management

## Implant treatment plan should feature Adaptations for smokers

A Chinese study has found that smoking did not affect the overall success of implant surgery. In the current study, 45 ITI (Straumann) implants were placed in the partially edentulous posterior mandibles of 32 male patients, including 16 who were heavy smokers and 16 who did not smoke at all. Implant stability and peri-implant tissue response were assessed at three, four, six, eight and 12 weeks post-surgery.

In non-smokers, stability improved and implants began to better integrate into the bone after the second week. In the smoking group, however, implants only began to osseointegrate and become more stable after the third week. Despite successful short-term outcomes in both groups, smokers experienced more problems, including greater bone loss around the implants and deeper soft-tissue pockets.

In light of the findings, the researchers suggested that surgeons might need to change their standard implant loading schedule for patients who smoke heavily. The report, titled "Effect of heavy smoking on dental implants placed in male patients posterior mandibles: A prospective clinical study," was conducted by researchers at the First Affiliated Hospital of Xi'an Jiaotong University in Xi'an in China. The results were published in the December 2016 issue of the *Journal of Oral Implantology*.



## Oestrogen therapy helps reduce Periodontitis in postmenopausal women

A new study has now shown that this oestrogen treatment could also lower the prevalence of severe periodontitis in postmenopausal women. The study included 492 postmenopausal women, 113 of whom received osteoporosis treatment and 379 who did not. It showed that those who received systemic oestrogen alone, or oestrogen plus progestin, and calcium and vitamin D supplements for at least six months had lower periodontal probing depth, less clinical attachment loss and less gingival bleeding than women not receiving treatment

for osteoporosis. In particular, the prevalence of severe periodontitis was 44 per cent lower in the osteoporosis treatment group than in the other group.

The study, titled "Association between osteoporosis treatment and severe periodontitis in postmenopausal women," was published online ahead of print on Feb. 20 in *Menopause*, the journal of the North American Menopause Society. It was conducted at several scientific and state health institutions in Brazil in collaboration with the State University of New York.



© Kunst Bilder/Shutterstock.com

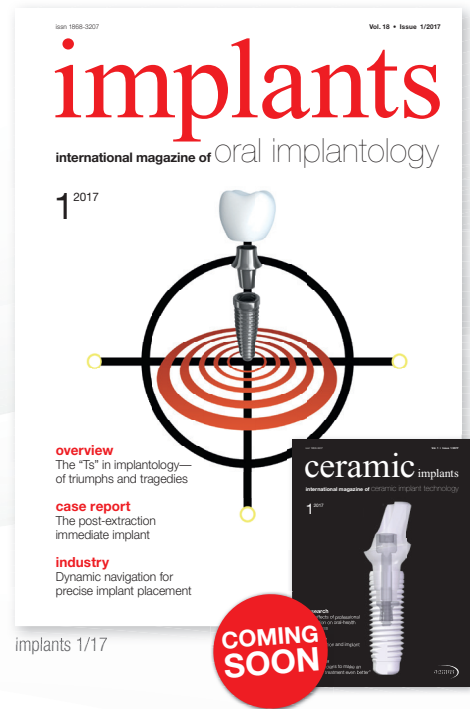# SUBSCRIBE NOW!

implants – international magazine of oral implantology

ONLINE SUBSCRIPTION HERE



www.oemus.com/abo



implants 1/17

## Fax +49 341 48474-290

I would like to subscribe for the following journals:

- implants – international magazine of oral implantology  
4 issues p.a. 44.– €\*
- ceramic implants – international magazine of oral implantology  
2 issues p.a. 30.– €\*

Terms & Conditions: The subscription may be cancelled in written form without due justification within 14 days of order by contacting OEMUS MEDIA AG, Holbeinstraße 29, 04229 Leipzig, Germany. Dispatching notification in good time will suffice. The subscription is automatically extended by another twelve months if it is not cancelled in written form 6 weeks prior to the end of the reference period.

\* All prices include VAT and shipping (within Germany).  
Conditions for international subscriptions upon request.

\_\_\_\_\_  
Last Name, First Name

\_\_\_\_\_  
Company

\_\_\_\_\_  
Street

\_\_\_\_\_  
ZIP/City/County

\_\_\_\_\_  
E-Mail

\_\_\_\_\_  
Signature

PayPal

Credit Card

\_\_\_\_\_  
Credit Card Number

\_\_\_\_\_  
Expiration Date

\_\_\_\_\_  
Security Code

Holbeinstraße 29 · 04229 Leipzig · Tel.: 0341 48474-201 · grasse@oemus-media.de

OEMUS MEDIA AG



# 10<sup>th</sup> Arab-German Congress of Dental Implantology

---

12<sup>th</sup> – 13<sup>th</sup> May 2017  
Universiapolis, Agadir, Morocco



[www.agci2017.e-polytechnique.ma](http://www.agci2017.e-polytechnique.ma)  
E-Mail: [AGCI2017@gmail.com](mailto:AGCI2017@gmail.com)



# Congresses, courses and symposia



## Nobel Biocare Dubai Symposium

4–5 May 2017

Venue: Dubai, UAE

[www.nobelbiocare.com](http://www.nobelbiocare.com)



## ITI World Symposium

4–6 May 2017

Venue: Basel, Switzerland

[www.iti.org/worldsymposium2017](http://www.iti.org/worldsymposium2017)



## 3<sup>rd</sup> Annual Meeting of ISMI

5–6 May 2017

Venue: Constance, Germany

[www.ismi-meeting.com](http://www.ismi-meeting.com)



## 3<sup>rd</sup> Giornate Romane

19–20 May 2017

Venue: Rome, Italy

[www.giornate-romane.info](http://www.giornate-romane.info)



## 47<sup>th</sup> International Annual DGZI Congress

29–30 September 2017

Venue: Berlin, Germany

[www.dgzi-jahreskongress.de](http://www.dgzi-jahreskongress.de)



# implants

international magazine of oral implantology



## Imprint

### Publisher

Torsten R. Oemus  
[oemus@oemus-media.de](mailto:oemus@oemus-media.de)

### CEO

Ingolf Döbbecke  
[doebbecke@oemus-media.de](mailto:doebbecke@oemus-media.de)

### Members of the Board

Jürgen Isbaner  
[isbaner@oemus-media.de](mailto:isbaner@oemus-media.de)

Lutz V. Hiller

[hiller@oemus-media.de](mailto:hiller@oemus-media.de)

### Chief Editorial Manager

Dr Torsten Hartmann (V. i. S. d. P.)  
[hartmann@dentalnet.de](mailto:hartmann@dentalnet.de)

### Editorial Council

Dr Rolf Vollmer  
[info.vollmer@t-online.de](mailto:info.vollmer@t-online.de)

Dr Georg Bach

[doc.bach@t-online.de](mailto:doc.bach@t-online.de)

Prof (CAI) Dr Roland Hille

[dr-hille@t-online.de](mailto:dr-hille@t-online.de)

Dr Suheil Boutros

[SMBoutros@aol.com](mailto:SMBoutros@aol.com)

### Editorial Office

Georg Isbaner  
[g.isbaner@oemus-media.de](mailto:g.isbaner@oemus-media.de)

Claudia Jahn

[c.jahn@oemus-media.de](mailto:c.jahn@oemus-media.de)

### Executive Producer

Gernot Meyer  
[meyer@oemus-media.de](mailto:meyer@oemus-media.de)

### Product Manager

Timo Krause  
[t.krause@oemus-media.de](mailto:t.krause@oemus-media.de)

### Designer

Sandra Ehnert  
[s.ehnert@oemus-media.de](mailto:s.ehnert@oemus-media.de)

Stephan Krause

[s.krause@oemus-media.de](mailto:s.krause@oemus-media.de)

### Customer Service

Marius Mezger  
[m.mezger@oemus-media.de](mailto:m.mezger@oemus-media.de)

### Published by

OEMUS MEDIA AG  
Holbeinstraße 29  
04229 Leipzig, Germany  
Tel.: +49 341 48474-0  
Fax: +49 341 48474-290  
[kontakt@oemus-media.de](mailto:kontakt@oemus-media.de)

### Printed by

Silber Druck oHG  
Am Waldstrauch 1  
34266 Niestetal, Germany

### implants

international magazine of oral implantology is published in cooperation with the German Association of Dental Implantology (DGZI).

### DGZI

DGZI Central Office  
Paulusstraße 1  
40237 Düsseldorf, Germany  
Tel.: +49 211 16970-77  
Fax: +49 211 16970-66  
[office@dgzi-info.de](mailto:office@dgzi-info.de)

[www.dgzi.de](http://www.dgzi.de)

[www.oemus.com](http://www.oemus.com)

[www.implants.de](http://www.implants.de)

### Copyright Regulations

implants international magazine of oral implantology is published by OEMUS MEDIA AG and will appear in 2017 with one issue every quarter. The magazine and all articles and illustrations therein are protected by copyright. Any utilization without the prior consent of editor and publisher is inadmissible and liable to prosecution. This applies in particular to duplicate copies, translations, microfilms, and storage and processing in electronic systems. Reproductions, including extracts, may only be made with the permission of the publisher. Given no statement to the contrary, any submissions to the editorial department are understood to be in agreement with a full or partial publishing of said submission. The editorial department reserves the right to check all submitted articles for formal errors and factual authority, and to make amendments if necessary. No responsibility shall be taken for unsolicited books and manuscripts. Articles bearing symbols other than that of the editorial department, or which are distinguished by the name of the author, represent the opinion of the afore-mentioned, and do not have to comply with the views of OEMUS MEDIA AG. Responsibility for such articles shall be borne by the author. Responsibility for advertisements and other specially labeled items shall not be borne by the editorial department. Likewise, no responsibility shall be assumed for information published about associations, companies and commercial markets. All cases of consequential liability arising from inaccurate or faulty representation are excluded. General terms and conditions apply, legal venue is Leipzig, Germany.

## (R)Evolution for Implantologists **Champions "(R)Evolution White" implant**

... the elastic and solid zircon implant  
made from the patented pZircono

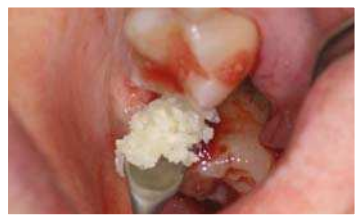The Champions (R)Evolution® White  
implant differs from other zircon  
implants in the following aspects:

- ★ No risk of fracture
- ★ Successful osseointegration
- ★ Rough and hydrophilic surface
- ★ Affordable
- ★ Insertion aid
- ★ Screw
- ★ Healing cap
- ★ Impression tool

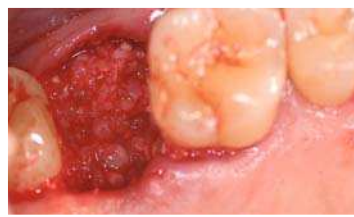

## (R)Evolution for every dental office **The Champions Smart Grinder**

You can avoid vol. 50% of alveolar resorption  
after extraction thanks to socket preserva-  
tion with autologous bone graft using teeth,  
chair-side – in less than 15 minutes!



Placing the bone graft



Placed bone graft

Visit us

**IDS COLOGNE**  
HALL 4.1 | B071  
21 – 25 MARCH

champions  implants

Champions-Implants GmbH

Champions Platz 1 | D-55237 Flonheim

fon +49 (0)6734 91 40 80

info@champions-implants.com



[www.facebook.com/ChampionsImplants](https://www.facebook.com/ChampionsImplants)

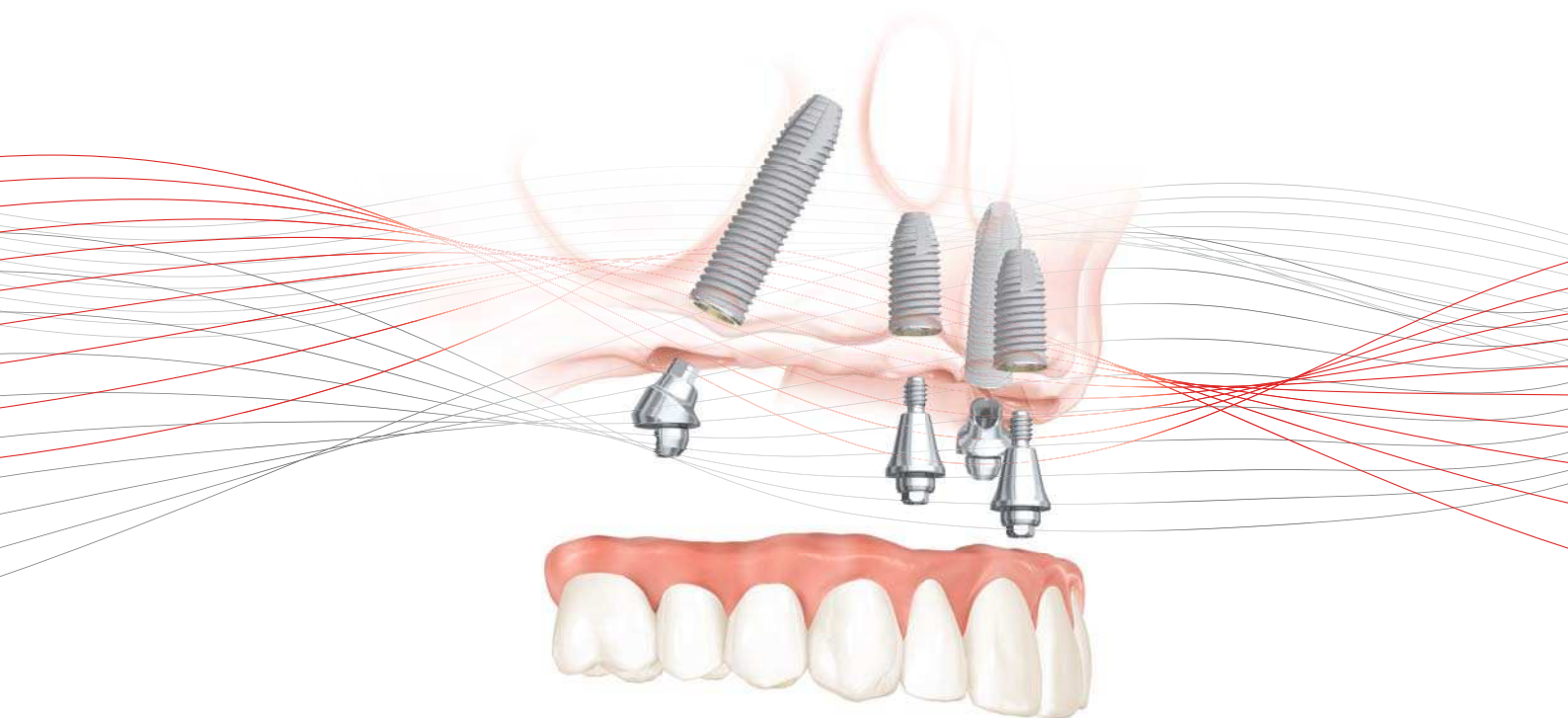
Scientific studies at:

[www.champions-implants.com](http://www.champions-implants.com)

# Original. Proven. Life changing.

**IDS  
2017**

Join the journey at  
IDS Cologne  
March 21–25, 2017  
Hall 10.1, H20/J29



## The All-on-4<sup>®</sup> treatment concept

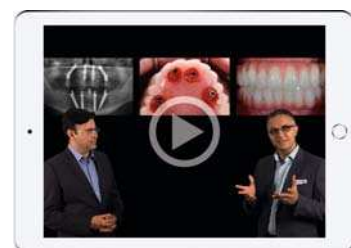**Four implants. A fixed full-arch provisional prosthesis. Same day.\***

Since it was first introduced in 1998, the All-on-4<sup>®</sup> treatment concept has changed the lives of hundreds of thousands of patients. Today, the concept is established as the best in its class of solutions, but only when Nobel Biocare products are combined.

Now supported by 34 clinical studies featuring 2400 patients, many have tried to mirror this groundbreaking concept, but only Nobel Biocare has the scientifically documented success to back it up.

Offer your patient life-changing treatment you can both rely on.

\*Provided stability criteria for immediate loading are fulfilled.



**New All-on-4<sup>®</sup> treatment concept  
online course**

**Register at  
[nobelbiocare.com/all-on-4course](http://nobelbiocare.com/all-on-4course)**

