Histomorphological changes in human bone

After *in vivo* Er:YAG laser and ultrasound osteotomy

Authors: Bistra Y. Blagova, Elena G. Poriazova, Petia F. Pechalova & Prof. Georgi T. Tomov, Bulgaria

Introduction

Bone surgical interventions are performed using two major techniques: an osteoplasty and osteotomy. They are carried out by a great number of tools (osteotomes) which cause certain changes in bone morphology, i.e. cell vitality and physiology.[1-14] The applicability of different osteotomes in bone surgery depends on the severity of tissues damage and the healing process afterwards.[1] Therefore, the features of bone repair have been object of a many histomorphological research trials performed on laboratory animals.[1-3] The analyses of the results published showed tissue recovery following ultrasound and laser osteotomy to be superior to the procedures performed by conventional rotary tools.[1,4,5] However, the conclusions from these researches are not automatically relevant to humans. Therefore, the aim of this study was to evaluate the histological changes in the border area following *in vivo* human bone cutting by an ultrasonic device and an Er:YAG laser during extractions of impacted mandible wisdom teeth.

Tab. 1: Histopathological changes in 60 bone specimens taken *in vivo* from human mandibles by ultrasound- and Er:YAG-laser osteotomy.

Histopathological changes in 60 bone specimens

Histomorphological changes	Woodpecker®	LiteTouch™, Light Instruments
border configuration/ margins	sharp, severely fragmented and irregular (Figs. 1 & 2)	sharp, precise configuration (Figs. 3 & 4)
debris fragments	a satellite zone of numerous debris fragments (Figs. 1 & 2)	no smear layer of debris fragments (Figs. 3 & 4)
thermal damage/ carbonisation	no significant signs, preserved bone microstructure (Figs. 1 & 2)	no significant signs, mildly expressed darker superficial area (Figs. 3 & 4)

Materials and methods

Objects in this study were outpatients aged between 18 and 35 in order to minimise age-related bone changes. All patients were indicated for surgical extraction of their mandibular third molars. Presence of any co-morbidities or bone infection were considered as exclusion criteria. The research objects were sixty bone specimens divided into two groups equal in number according to the tool used for their collection: an ultrasonic surgical device (Woodpecker Ultrasurgery®, China) and an Er:YAG laser (LiteTouch, Light Instruments®, Israel). All bone samples were obtained by a trained oral surgeon. No complications occurred either intra- or postoperatively. A standard setup of both devices for bone manipulations were used as follows:

- Ultrasonic unit—Bone function—Bone quality 1—frequency utilised up to 29.5 kHz—water pump 5;
- LiteTouch™ Er:YAG laser—wavelength 2.94 µm (2,940 nm)—bone remodeling—Hard Tissue—Non-Contact mode—300 mJ—25 Hz—water spray 8.

Laser specimens were obtained using a cylinder sapphire tip of 1.3 mm in diameter and 19 mm in length (LiteTouch™, Light Instruments, Israel) in a non-contact mode at a distance of 1–2 mm from the target surface. Ultrasound-obtained bone chips were taken by a tip # US 1.

All samples were fixed in 10% buffered formalin, decalcified and cut into slices within 3–5 µm each. The slices were stained with haematoxilin-eosin (H&E)

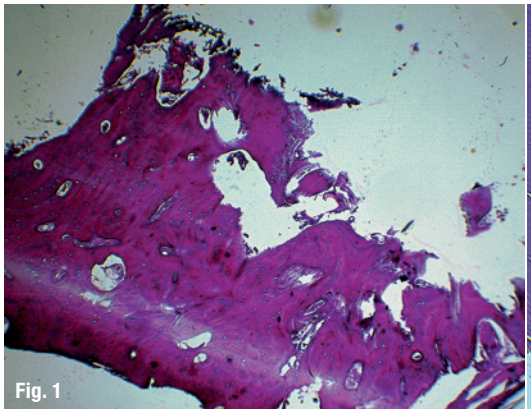
Fig. 1

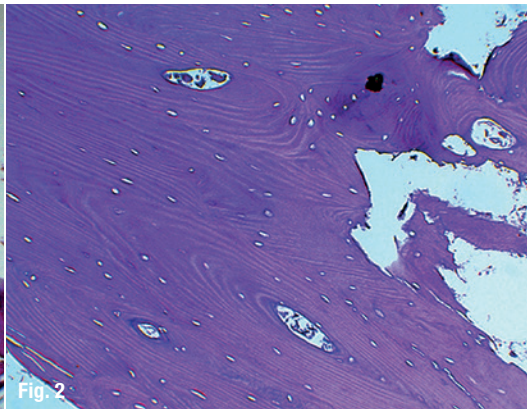
Fig. 2

Fig. 1: Ultrasound obtained human bone specimen (H&E x100).
Fig. 2: Ultrasound obtained human bone specimen (H&E x400).

(Bio-Optica®, Italy). The microscopic observations were performed by pathologist in a blind manner under optical microscope (Olympus®, Japan) at magnifications of x100 and x400.

The histomorphological evaluation included groups of observation:
1. border configuration/margins quality;
2. presence of debris fragments;
3. thermal damage/carbonisation.

All the sixty bone fragments were investigated according to the above-mentioned histological criteria.

Results

The histomorphological findings in both groups (30 specimens for each) are summarised in Table 1.

Discussion

Osteotomes, technical characteristics and principles of action determine their biological effects reported in different trials on laboratory animals. Based on extensive studies, fundamental differences between humans and animals in bone morphology and physiology were proved.[11] These publications led our team to verify on human bone in real-time procedures, the tissue changes following osteotomy performed by ultrasound- and Er:YAG-laser and to compare them to the ones reported in animals.

Ultrasound obtained specimen from human bone

Ultrasonic devices work through mechanical waves within frequencies of approximately 25–30 kHz created by the piezoelectric effect.[8] Bone cutting is performed by vibrations of lineally oscillating movements within 20–80 microns. Exactly these parameters establish the micro-precision of the ultrasound-assisted osteotomy and its effects only on mineralised tissues as well as the depth of insertion into them.[8,12] Histologically, *in vivo* ultrasound obtained specimens from human lower jaw showed sharp margins[1,6,7] corresponding to these observed by Romeo et al. in their *in vitro* study on fresh porcine mandibles (Figs. 1 & 2).[1] Meanwhile, the configuration of the cutting area on the investigated bioptata was irregular with clearly detectable layer of bone debris attached to the main fragment (Figs. 1 & 2). No signs of morphology alteration were detected during the collection of human bone chips. All examined *in vivo* ultrasound obtained specimens revealed a preserved microstructure (Figs. 1 & 2). The open vascular canals observed were likely to improve nutrition during the early healing phase of the bone repair sequence as reported by Sohn DS et al.[7] Based on the histopathological findings established in the presented study and the non-complicated postoperative period in our patients, we confirmed that ultrasound-assisted bone

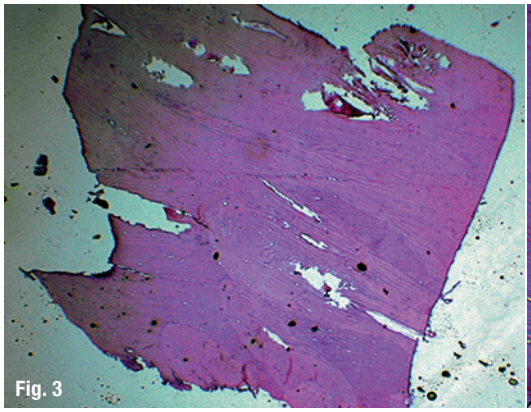
Fig. 3

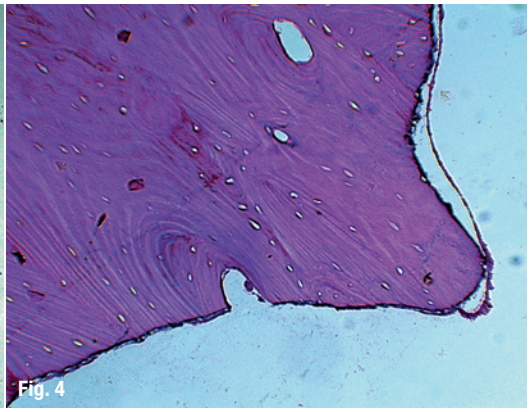
Fig. 4

Fig. 3: Laser obtained human bone specimen (H&E x100).
Fig. 4: Laser obtained human bone specimen (H&E x400).

surgery in humans is an atraumatic and minimally invasive procedure. Same conclusions were reported by Berengo M. et al.[13]

Er:YAG laser obtained specimens from human bone

Er:YAG lasers emit infrared light with a wavelength of 2.94 µm which is absorbed predominantly by water and hydroxyapatite.[14] The Er:YAG radiation is an efficient tool in bone surgery. In contrast with ultrasound devices, osteotomy by laser is performed in a non-contact mode. The laser tip is positioned 1–2 mm away from the target surface and there is no collateral friction damage to surrounding tissues.

Under light microscopy observation, the cutting surfaces in laser obtained bone chips from our patients revealed a precise border configuration (Figs. 3 & 4) confirming previously-published statements based on animal models for clear and effective osteotomy achieved by thermo-mechanical laser ablation.[1,9,10] In all laser ablated human bone samples, a mildly expressed darker amorphous layer within microns was observed superficially near to the incision line (Figs. 3 & 4). Romeo and Panduric et al. reported analogous tissue characteristics found in laboratory research on porcine mandibles and ribs respectively.[1,10] The reason for detected bone changes in all specimens in the group could be the cumulative heat deposition within the area surrounding the lased tissue.[1,10] Compared to the ultrasound-obtained specimens, laser-obtained human bioptata in our study showed no smear layer or debris bone fragments attached to the cutting surface (Figs. 3 & 4). Those findings correlated to the results of Romeo et al. in their *in vitro* trial on fresh porcine mandibles and also could explained the benefits for bone healing after laser bone ablation proved by Kesler et al. in rats models.[1,4] Probably the increased blood elements adhaesion potential ensured by laser irradiation due to the absence of any smear layer enhancde the start of the remodeling process.[1,10] The non-complicated postoperative period in our study confirmed that all tissue changes histologically approved on the biopsied specimens were harmless with regard to the bone healing in humans.

Conclusion

The microscopic observations in the presented study showed that both the type and quality of bone transformations is attributed to the cutting mechanism per se. Tissue changes in human bone following *in vivo* laser- and ultrasound-assisted osteotomy established on the evaluated samples proved the tolerable effects of the two studied tools toward the vital human bone. The choice of adequate osteotome should be always influenced by evidence-based results. The Er:YAG laser offers advantages over ultrasound osteotomy techniques because of the non-contact intervention, with no mechanical vibration, free-of-debris cutting lines and aseptic effects. Nevertheless, with adequate training and experience, the surgeon is able to use this device for certain and selective procedures in bone surgery._

Acknowledgement: This research was funded by Medical University of Plovdiv (Grant SDP-06/2015).

contact

Prof. Georgi Tomov
DDS, MS, PhD
Associate Professor and Chair of the Department of Oral Pathology,
Faculty of Dental Medicine
dr.g.tomov@gmail.com

Author details

Kurz & bündig

Im Vorfeld zum Verfassen des Artikels recherchierten die Autoren ihre Analyseergebnisse zur Zellregeneration nach Ultraschall sowie Laserosteotomie im Vergleich zu rotierenden Instrumenten. Da die bisher vorliegenden Studien zu diesen Themen nicht zwingend auf menschliche Zellen anwendbar waren, zielt der hier präsentierte Bericht auf einen histologischen Vergleich der Zellveränderungen nach *In-vivo*-Einschnitten in menschlichen Knochen durch Ultraschall sowie Er:YAG-Laser während der Extraktion geschädigter mandibulärer Weisheitszähne.

Die mikroskopischen Untersuchungen zeigten, dass sowohl Art als auch Qualität der Knochenveränderungen in starker Abhängigkeit zu den angewendeten Schneidmechanismen standen. Zellveränderungen im menschlichen Knochen in *In-vivo*-Laser- sowie Ultraschallosteotomie resultierten in den untersuchten Proben tolerierbare Effektive der zwei Instrumente auf das vitale humane Knochengewebe. Die Auswahl des passenden Osteotoms sollte immer auf evidenzbasierten Ergebnissen beruhen. Aufgrund der kontaktfreien Intervation ohne mechanische Vibration, ablagerungsfreien Schnittkanten sowie seiner aseptischen Effekte besitze der Er:YAG-Laser deutliche Vorteile im Vergleich zur Ultraschalltechnologie.

Literature

SUBSCRIBE NOW!

laser – international magazine of laser dentistry

Interdisciplinary & transparent & market orientated

ONLINE
SUBSCRIPTION HERE

www.oemus.com/abo







Fax +49 341 48474-290

I would like to subscribe for the following journals:

☐ laser – international magazine of laser dentistry	4 issues p.a.	44.– €*
☐ implants – international magazine of oral implantology	4 issues p.a.	44.– €*
☐ ceramic implants – international magazine of oral ceramic implant technology	2 issues p.a.	30.– €*

Terms & Conditions: The subscription may be cancelled in written form without due justification within 14 days of order by contacting OEMUS MEDIA AG, Holbeinstraße 29, 04229 Leipzig, Germany. Dispatching notification in good time will suffice. The subscription is automatically extended by another twelve months if it is not cancelled in written form 6 weeks prior to the end of the reference period.

*All prices include VAT and shipping (within Germany).
Conditions for international subscriptions upon request.

Last Name, First Name

Company

Street

ZIP/City/County

E-Mail

Signature

○ PayPal
○ Credit Card Credit Card Number Expiration Date Security Code

OEMUS MEDIA AG

Holbeinstraße 29 · 04229 Leipzig · Germany · Phone: +49 341 48474-308 · grasse@oemus-media.de