Diode lasers and microsurgery

Author: Dr Isabelle Nguyen, France

Many families of dental lasers have become available in recent years. Throughout this article we will review a diode laser, which is unusual in that it supports three different wavelengths in the same device. A large number of studies have awakened interest in near infrared wavelengths, 970 nm for example, which enable the use of high penetration lasers for disinfecting endodontic canals and periodontic pockets. The 660 nm wavelength promotes biostimulation.

Diode lasers can be used for surgical applications in mucous tissue, though it should be noted that bleeding from the tissue has always occurred because the rays penetrate the tissue below, thus requiring caution when heating the tissue underlying the target tissue. The factors above resulted in a new wavelength of 445 nm—in the blue range—as a potential solution for dealing with mucous tissue as it is more readily absorbed by haemoglobin (Fig. 1). As it is not possible to cover the wide range of potential uses of diode lasers in a single article, we will focus here on their microsurgical applications.

Creating pontics

In the presented case, there was an old bridge with three incisors and reduced intercanine space, but the patient refused orthodontic treatment. Figure 2a shows the initial state in which two pontics were implemented with a 970 nm 3 W CW diode laser to recreate the emplacement for two central posts under local anaesthesia with air/water irrigation (Fig. 2b). There was no bleeding, which simplified the work of preparing and installing the temporary resin bridge (Fig. 2c). An examination of scar healing was performed seven days later (Fig. 2d). An impression was then made for the permanent bridge (Fig. 2e). Figure 2f shows the permanent bridge when installed.

Widening the sulcus

The diode laser is an excellent alternative to the conventional technique for widening the sulcus before creating an impression. It makes avoiding undesired secondary gingival retractions possible as its use in these cases requires less force, and since the

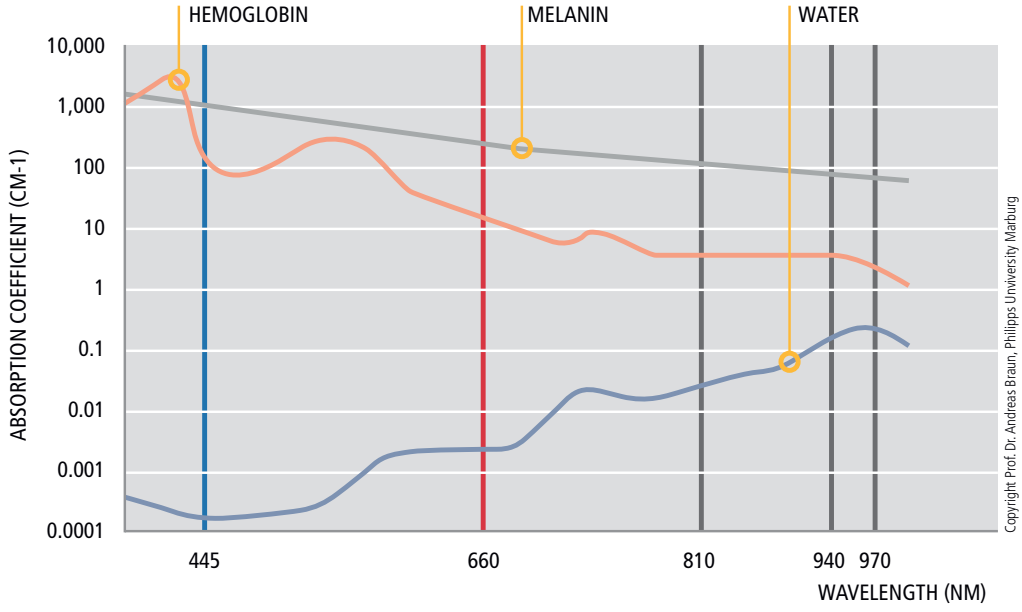

Fig. 1: Influence of different laser wavelengths on haemoglobin, melanin and water.


Fig. 2a


Fig. 2b


Fig. 2c


Fig. 2d


Fig. 2e


Fig. 2f

Fig. 2a: Initial state: two pontics were implemented with a 970 nm 3 W CW diode laser.
Fig. 2b: Recreation of the emplacement for two central posts under local anaesthesia with air/water irrigation.
Fig. 2c: Preparation and installation of the temporary resin bridge.
Fig. 2d: Examination of scar healing after seven days.
Fig. 2e: Impression-taking for the permanent bridge.
Fig. 2f: Installation of the permanent bridge.

temperature remains under 60 °C, the treatment is always in the reversible range and the tissue that is removed will be restored (Table 1). With its biostimulatory action, the diode laser promotes high-quality healing of wounds in the target tissue.

Figure 3a shows the peripheral subgingival preparation of tooth 16. Figure 3b shows the opening of the sulcus with a 970 nm, 1.2 W diode laser with air/water irrigation and without anaesthesia. The CEREC® crown can then be bonded within one hour under supragingival conditions (Fig. 3c). A follow-up examination on D+7 shows that the gingiva had returned to its original position (Fig. 3d).

Detaching the implant and implant abutment

In implant applications, it is important to note the axis of the laser fibre to avoid aiming it directly at the implant or touching it. Working with an air/water irrigation circuit prevents the implant system from be-

Temperature °C	Thermal effect of laser energy on soft tissue
45	Vasodilation
50	Disruption of cellular activity
60	Denaturation of proteins
70	Denaturation of collagen
80	Carbonization and cellular necrosis
100	Dehydration by vaporization of water
> 100	Evaporation of tissues

Tab. 1: Overview on thermal effects of laser on soft tissue.

Fig. 3a: Peripheral subgingival preparation of tooth 16.
Fig. 3b: Opening of the sulcus at 970 nm, 1.2 W (diode laser) with air/water irrigation and without anaesthesia.
Fig. 3c: Bonding of the CEREC® crown after one hour.
Fig. 3d: Follow-up examination after seven days.
Fig. 4a: Covering of implant head 14.
Fig. 4b: Introduction of a wider, higher gingiva former.
Fig. 4c: Wound healing after two days, impression-taking.
Fig. 4d: Bridge on implants 14/16 in location.
Fig. 5a: Biostimulation at 660 nm to induce bleeding.
Fig. 5b: Haemostasis.
Fig. 6a: Surgical exposure with a 970 nm 3 W laser and bonding of the bracket at 23.
Fig. 6b: Follow-up after one day.
Fig. 6c: Follow-up after five months.


Fig. 3a


Fig. 3b


Fig. 3c


Fig. 3d

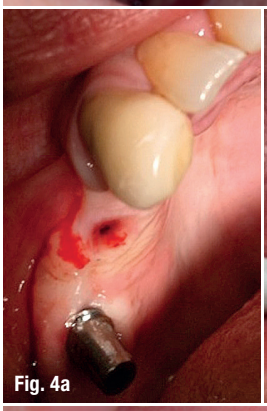
Fig. 4a

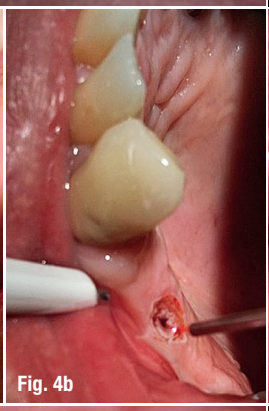
Fig. 4b


Fig. 4c

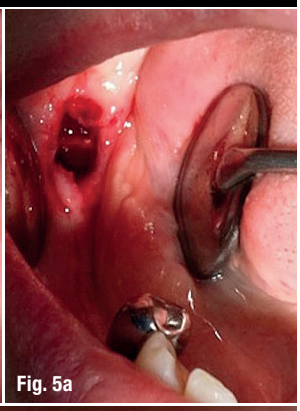
Fig. 5a


Fig. 4d

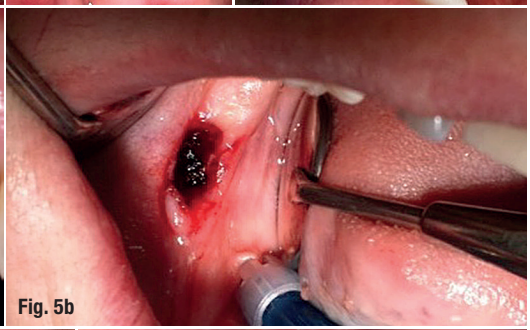
Fig. 5b

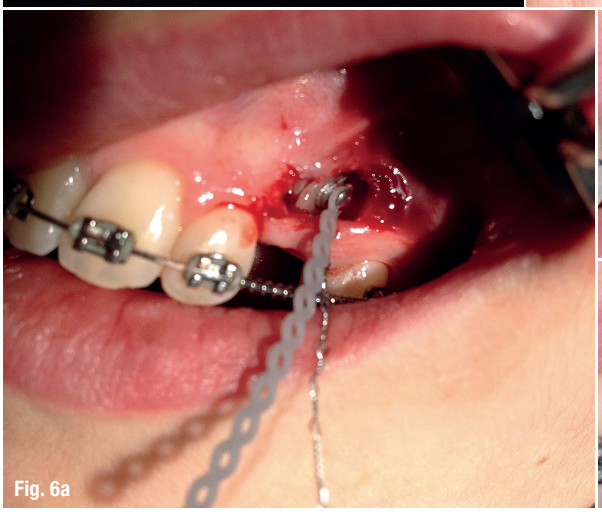
Fig. 6a


Fig. 6b


Fig. 6c

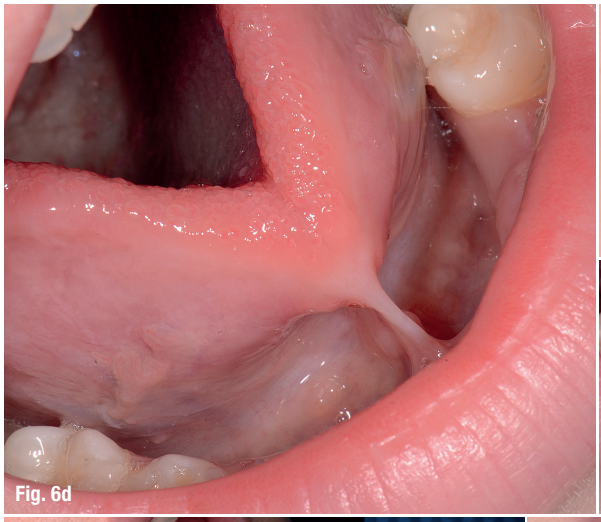
Fig. 6d


Fig. 6e


Fig. 6f


Fig. 6g


Fig. 6h

Fig. 6d: Initial frenulum.
Fig. 6e: Rapid frenectomy with 445 nm 2 W laser under local anaesthesia.
Fig. 6f: Follow-up after five days.
Fig. 6g: Lateral view of the tongue before frenectomy.
Fig. 6h: Lateral view of the tongue after frenectomy.

coming heated. Now we turn to irreversible gingivectomies (Table 1).

Of course in this clinical context, as the gingival thickness conditions are favourable, there was no need to thicken the gingiva by creating a tissue flap. The implant head 14 was covered (Fig. 4a), and it was exposed with the 970 nm 3 W CW laser before the introduction of a wider, higher gingiva former (Fig. 4b). Figure 4c shows wound healing on D+2; the impression was then made. Finally, the bridge on implants 14/16 were in location (Fig. 4d).

Haemostasis

Clinical case: extraction from alveolus 38. The interradicular alveolar wall is still visible just after the extraction, and it was decided to biostimulate at 660 nm to induce bleeding (Fig. 5a). Haemostasis with the 445 nm 2 W diode laser at a distance of 2 mm is shown in Figure 5b.

Laser and orthodontics

The general dental practitioner can also use a laser as an aid in certain orthodontic treatments, such as gingivectomies in cases of hypertrophy, thus improving the dental hygiene of young patients, and also for gaining traction on impacted teeth (Figs. 6a to 6c) and for frenectomies (Figs. 6d to 6h).

Surgical exposure with a 970 nm 3 W laser and bonding of the bracket at 23 is shown in Figure 6a. Follow-up at D+1 month is seen in Figure 6b. Follow-up at D+5 months in Figure 6c and the initial frenulum is shown in Figure 6d. Rapid frenectomy with 445 nm 2 W laser under local anaesthesia is shown in Figure 6e, along with the follow-up at D+5 in Figure 6f. The lateral view of the tongue before is displayed in Figure 6g and after in Figure 6h.

Realignment of crowns

Preprosthetic treatment of mucous tissue with diode laser promotes rapid, painless wound healing; healing times are faster and fewer dental appointments are required. The initial state is depicted in Figure 7a. The crowns at 21, 22 and 23 must be realigned after determination of the depth of the biological space and of the gingival heights.

The mock-up serves as a guide for marking out the new crowns with the 445 nm 2 W diode laser (Figs. 7b and 7c). Preparation and digital impression are completed on the same day under periapical anaesthesia. Examination of the surgery and CEREC

Fig. 7a: Initial state.
Figs. 7b & c: The mock-up serves as a guide for marking out the new crowns with the 445 nm 2 W diode laser.
Fig. 7d: Examination of the surgery and CEREC walls at 13 to 23.
Fig. 7e: Follow-up examination of the gingiva after one month.
Fig. 7f: Patient's smile before surgery.
Fig. 7g: Patient's smile after surgery.



walls at 13 to 23 shows that the fibrin is already visible (Fig. 7d). Follow-up examination of gingiva D+1 month is shown in Figure 7e. The patient's smile before the surgery is shown in Figure 7f and after the surgery in Figure 7g.

Conclusion

Patients treated with diode lasers unanimously agree that the surgery causes them no discomfort. Clinically, we observe rapid wound healing and high-quality results from diode lasers. Surgeries performed with a wavelength of 445 nm are effective because they are completed faster and cause less contact bleeding than surgeries using a wavelength of 970 nm. Use of the laser in general dental practices increases the level of operating comfort for the dental team and considerably increases patient satisfaction as well._

contact

Dr Isabelle Nguyen
is a dental surgeon practicing in Marcheprime en Gironde.
She is also a consulting specialist for Sirolaser and a CAD/CAM ambassador.

Author details

Kurz & bündig

Die Autorin stellt im Artikel das breit gefächerte mikrochirurgische Anwendungsspektrum des Diodenlasers vor. Dabei werden unterschiedliche Laserwellenlängen zwischen 445 nm und 970 nm evaluiert. Anwendungsfelder wie das Erstellen von Pontics, Sulkuserweiterungen, das Herausnehmen von Implantaten oder Implant-Abutments, die Hämostase, die Neusausrichtung von Kronen und der Lasereinsatz in der Kieferorthopädie werden anhand von Beispielfällen umrissen. Abschließend fasst die Autorin zusammen, dass Patienten durch den Einsatz des Diodenlasers weniger Unannehmlichkeiten nach einer chirurgischen Behandlung verspüren. Klinisch wurden nach Anwendung des Diodenlasers eine schnellere Wundheilung und hochqualitative Behandlungsergebnisse beobachtet. Außerdem werden laut Artikel operative Eingriffe, die mithilfe eines 445 nm-Diodenlasers durchgeführt wurden, effektiver umgesetzt, da sie in kürzerer Zeit beendet werden können und dabei weniger Kontaktblutungen auftreten als bei einer Wellenlänge von 970 nm. Die Anwendung von Lasern in allgemeinzahnmedizinischen Praxen habe den Anwenderkomfort auch für das Praxisteam erhöht und die Patientenzufriedenheit deutlich verstärkt.



Master of Science (M.Sc.) in Laser in Dentistry

Next Start: 02nd October 2017 | Aachen, Germany | 4 semesters







Become part of the International Dental Elite

- Create new economic potential for your practice
- Two year career-accompanying postgraduate programme at the University of Excellence RWTH Aachen
- Combination of lectures, skill training sessions, live ops, tutorials, and practical workshops
- Internationally accepted and accredited by the German Governent, the European Union, the Washington Accord and the Bologna Process
- Science-based and practice-orientated on highest national and international level
- Increased patient satisfaction: minimal contact reduced vibration and pain

RWTH INTERNATIONAL ACADEMY AACHEN UNIVERSITY

RWTH International Academy
Kackertstraße 10 | 52072 Aachen | Germany
phone +49 241 80 23543 | fax +49 241 80 92525
info@academy.rwth-aachen.de
www.academy rwth-aachen.de

AALZ
Aachen Dental Laser Center

AALZ GmbH
Pauwelsstraße 17 | 52074 Aachen | Germany
phone +49241 47 57 13 10 | fax +49 241 47 57 13 29
info@aalz.de
www.aalz.de

ASIIN e.V. accredited degree program

PROFESSIONAL EDUCATION PROGRAMMES

Your contact for more information: Leon Vanweersch • vanweersch@aalz.de - www.aalz.de