The application of erbium laser in dental surgery

Author: Dr Kinga Grzech-Lesniak, Poland

Laser therapy has become a real and extremely promising alternative to classical surgical approaches in dental surgery. Beside their cutting and tissue ablating power, the lasers have a number of effects on tissues which can be used in healing enhancement. The application of high-power lasers in dental surgery has been known for many years. The literature gives the examples of laser usage in procedures such as frenectomy, operculectomy, preparation of the prosthetic field, removal of the lesions of the oral mucosa. Lasers are described as particularly useful tools because of their coagulation properties, especially in hard-to-reach areas, where suturing or hemostasis is difficult.

The use of Er:YAG laser with a wavelength of 2,940 nm to perform almost end-to-end flap procedures is no more a novelty described in the literature and neither is it controversial. On the contrary, it has been observed that the time needed for the procedure and wound healing is shorter and generates lower cost.

Figs. 1–3: Pre-op situation.
Figs. 4–6: Incision along the bursa gingivalis from the vestibular side with the use of Varian/H14 fiber (Fotona).


Fig. 1


Fig. 2


Fig. 3


Fig. 4



Fig. 5


Fig. 6


Fig. 7


Fig. 8


Fig. 9


Fig. 11


Fig. 10



Fig. 12


Fig. 13

Figs. 7–9: Incision from the palatal side.
Figs. 10–13: After separating the full-thickness flap, the flap and the bone cavity is cleaned from the granulation tissue.

This laser is used in surgery, because, besides of the cutting process, there are effects of photocoagulation and ablation obtained by evaporation of the tissues. Absorption and penetration of laser light depends on its physical parameters, such as wavelength, power, dose of energy, water, haemoglobin and melanin content in the tissue, extent and type of lesion.[1] Advantages of this tool are high precision of cutting due to the possibility of strong focusing of the laser beam and high selectivity, that is, affecting only the tissues absorbing a specific wavelength. Another advantage is the possibility of non-contact treatment of tissues (with non-contact laser tips).

Due to the use of laser therapy the procedures until now performed with classical surgery, which had previously been very onerous for the patient, now are safer, less invasive and often more successful than classic ways of treatment.[2] High-power laser is also effective in removing laesions such as epulis, fibroma, papilloma, and precise treatment of the periodontium, such as gingivectomy and the removal of vascular lesions.[3,4]


Fig. 14


Fig. 15



Fig. 16

Figs. 14–16: Periodontal debridement, removal of subgingival calculus and from the root surface.

Figs. 17–19: View of the cavity cleaned by Er:YAG laser just before the closing of the flap.
Figs. 20–21: Stitching up the surgical area.
Figs. 22–23: Check-up two weeks post-op.
Fig. 24–27: Pre-op situation.
Figs. 28 & 29: Patient after hygienic procedures, prepared for the surgical procedure.


Fig. 17


Fig. 18


Fig. 19


Fig. 20


Fig. 21


Fig. 22


Fig. 23


Fig. 24


Fig. 25


Fig. 27


Fig. 26


Fig. 28


Fig. 29



Fig. 30


Fig. 31


Fig. 32


Fig. 33


Fig. 34



Fig. 35


Fig. 36

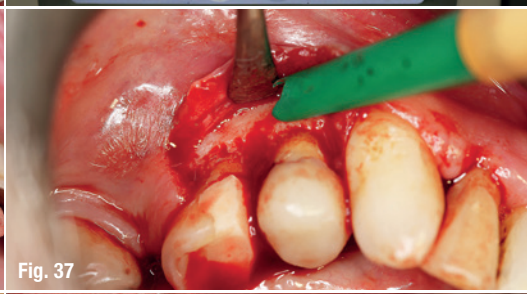
Fig. 37

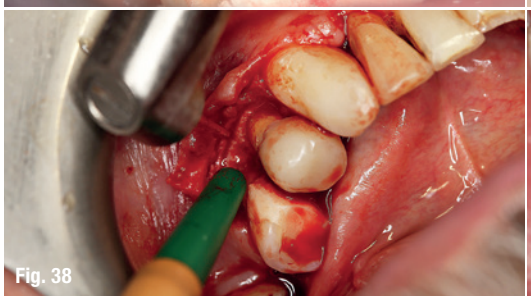
Fig. 38


Fig. 39

Figs. 30–32: Laser incision of the soft tissue.
Figs. 33–38: Osteoplasty, laser crown lengthening.
Fig. 39: Stitching up the surgical area.

Vescovi et al. described the surgical treatment of osteonecrosis of the jaws (ONJ) by means of Er:YAG laser in patients during bisphosphonates therapy (BPT). They documented that early surgical treatment with the use of Er:YAG laser associated with LLLT laser therapy, bisphosphonates therapy in patients with osteonecrosis of the jaws (ONJ) is more successful, compared to the conventional therapy.[5]

Lasers are also sucessfully used in surgical crown lenghening. Stages of these procedure include:

– Performing an incision in order to create a flap. In these cases Er:YAG LightWalker (Fotona) laser was used, with the handle H14 with Varian tip (in Case 1) and sapphire tip (in Case 2). The energy of 55 mJ, 20 Hz, power of 1.10 W with Varian tip, and 40 mJ, 10 Hz, 0.4 W using the tip intended for cutting soft tissues (contact mode).

Fig. 40: Situation two days post-op.

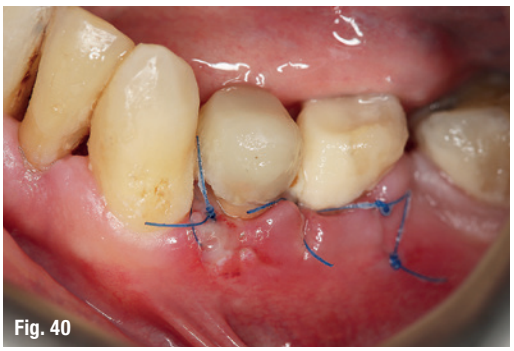

- Removal of granulation tissue with the chisel type tip (1.5 x 0.5 mm) with 180 mJ, 20 Hz, 3.6 W.
- Laser periodontal debridement—40 mJ, 40 Hz, 1.6 W (Varian tip).
- Deepithelialisation of the flap, suturing with microsurgical sutures and post-op patient instruction.

Case 1

A 43-year-old female patient has been referred by her dentist in order to perform surgical crown lengthening because of tooth 14 distal part of the root caries. Due to the fact that the patient is a diabetic, the procedure was performed with a Er:YAG laser with a wavelength of 2,940 nm (LightWalker, Fotona). Each surgical procedure in patients with diabetes involves high risk of complications, thus reduction of bacteremia, increased sterility and immediate disinfection of soft- and hard-tissues are advisable.

Case 2

A 52-year-old male patient was referred by his dentist for surgical crown lengthening flap procedure due to teeth 34 and 35 root caries. Laser incision, cleaning of granulation tissue from the flap and the bone defect with the use of laser (periodontal debridement) and osteoplasty were performed. In this case a conventional laser tip was used (chisel sapphire tip 1.5 x 0.5 mm).

Summary

In the presented cases, flap procedures performed with the use of Er:YAG LightWalker improved the healing-tissue parameters significantly, shortened the healing time, and reduced the costs of the surgery. From the patient's point of view, there was a significant improvement in the treatment comfort and effectiveness through the anti inflammatory and sanitising effect of the laser.

Nowadays the usefulness of erbium lasers both in surgical procedures in daily work of the dentist is highly estimated and will grow significantly in future years. The enhanced effects of the procedure and better healing of soft- and hard-tissues afterwards undoubtedly affects comfort, mental well-being, and the quality of life of the patient._

contact

Dr n med. Kinga Grzech-Lesniak
Periodontoligst
Specialist Periodontist and Assistant Professor
at the Wrocław Medical University,
Department of Oral Surgery
President of the Polish Society of
Laser Dentistry, PTSL
ul. Poznanska 8
30-012 Kraków, Poland
ptsl@laser.org.pl
kgl@periocare.pl

Author details

Kurz & bündig

Nachdem die Autorin die Vorteile von Laseranwendungen im Dentalbereich beschreibt, geht sie auf die einzelnen Behandlungsschritte der laserbasierten chirurgischen Kronenverlängerung ein. Dabei wird in einem ersten Schritt ein Einschnitt für die Lappenbildung gemacht. In den später vorgestellten Patientenfällen wurde dazu ein Er:YAG-Laser der Firma Fotona (LightWalker) mit einem H14-Handstück sowie der Varian-Spitze (Fall 1) und Saphirspitze (Fall 2) verwendet. In Fall 1 wurden eine Energiestärke von 55 mJ, 20 Hz und eine Leistung 1,10 W, in Fall 2 40 mJ, 10 Hz, 0,4 W verwendet. Dabei wurde die Spitze für einen sanften Gewebeschnitt (Kontaktmodus) genutzt. Es folgte die Entfernung von Granulationsgewebe mit der Saphiermeißel-Arbeitsspitze (1,5 x 0,5 mm) mit 180 mJ, 20 Hz und 3,6 W. Nach dem Laserscaling der Wurzeloberfläche (Varian-Spitze, 40 mJ, 40 Hz, 1,6 W) wurde abschließend eine Deepitheliasierung des Lappens durchgeführt. Vernäht wurde mit mikrochirurgischem Nahtmaterial 6/0. Abschließend erhielt der Patient Empfehlungen für die Nachsorge. Nachdem die Autorin kurz zwei Fallbeispiele erläutert, fasst sie abschließend die Vorteile der Laseranwendung zusammen: Durch die Laseranwendung habe sich in den vorgestellten Fällen die Gewebeheilung erheblich verbessert, die Heilungsdauer und die Behandlungskosten reduziert. Weiterhin führe der Laser zusätzlich zu entzündungshemmenden und desinfizierenden Effekten, sodass sich insgesamt der Behandlungskomfort für den Patienten deutlich verbessere.

Literature

Return address:
Deutsche Gesellschaft für Laserzahnheilkunde e.V.
c/o Universitätsklinikum Aachen
Klinik für Zahnerhaltung
Pauwelsstraße 30
52074 Aachen, Germany

Tel.: +49 241 8088164
Fax: +49 241 803388164
Credit institute: Sparkasse Aachen
IBAN: DE56 3905 0000 0042 0339 44
BIC.: AACSDE 33

Membership application form

Name/title: _____

Surname: _____

Date of birth: _____

Approbation: _____

Status: ☐ self-employed ☐ employed ☐ civil servant ☐ student ☐ dental assistant

Address:

Street: _____ Phone: _____

ZIP/city: _____ Fax: _____

Country: _____ E-Mail: _____

With the application for membership I ensure that

☐ I am owing an own practice since _____ and are working with the laser type _____ (exact name).

☐ I am employed at the practice _____

☐ I am employed at the University _____

I apply for membership in the German Association of Laser Dentistry (Deutsche Gesellschaft für Laserzahnheilkunde e.V.)

_____

Place, date Signature

Annual fee: for voting members with direct debit € 150

In case of no direct debit authorisation, an administration charge of € 31 p.a. becomes due.

DIRECT DEBIT AUTHORISATION

I agree that the members fee is debited from my bank account

Name: _____ IBAN: _____

BIC: _____ Credit institute: _____

_____

Signature of account holder This declaration is valid until written notice of its revocation