

# Periodontal therapy of deep localised pockets larger than 9 mm

## Adjunctive laser irradiation without antibiotics or open surgery

**Author:** Dr Gottfried Gisler, MSc, Switzerland

### 1. Introduction

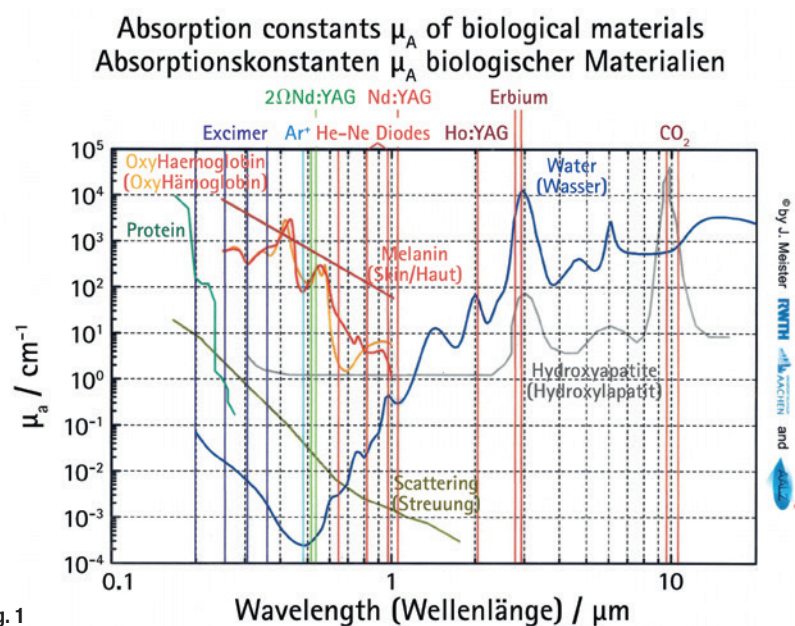
The aim of this paper is to demonstrate that even "hopeless" teeth with very deep periodontal pockets of 10 mm and more pocket depth can be saved. Lasers as adjunctive therapy in periodontics have been described for a long time for the following reasons: Bactericidal effect of low-level laser application in photodynamic therapies<sup>1-4</sup> and decrease of immune-inflammatory mediators<sup>5</sup>, stimulation of wound healing with application of low-level lasers<sup>6-9</sup>, bactericidal effect<sup>10-12</sup> or better wound healing for lasers in the near infrared like diode lasers<sup>13</sup> or Nd:YAG lasers<sup>14,15</sup>,

calculus removing<sup>16,17</sup>, and bactericidal effect with lasers in the middle infrared<sup>18-20</sup> and stimulation of bone healing with Er:YAG lasers<sup>21</sup>.

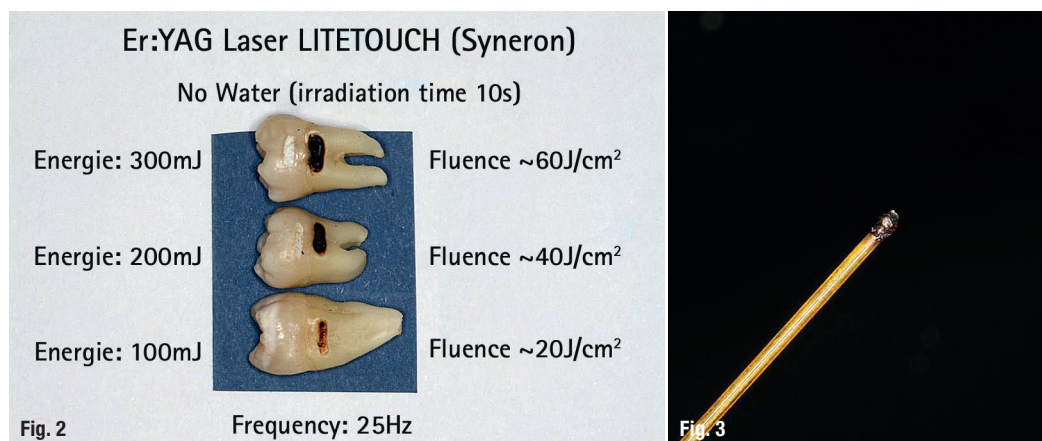
To achieve the above-mentioned effects of laser irradiation, the laser energy must be absorbed in the specific chromophores or absorbers of the tissues. The graph by Meister et al.<sup>22</sup> in Fig. 1 gives a perfect overview about the different wavelengths and their chromophores applied in clinical situations. It can be seen that there is a high absorption in water for lasers in the mid-infrared like Er:YAG or Er,Cr:YSGG. A lower absorption was found for hydroxyapatite. The absorption constant of  $10^2/\text{cm}$  in hydroxyapatite can lead to misunderstandings of ablation in hydroxyapatite containing tissues like bone or dental hard tissues. If ablation in these tissues would occur by absorption in the secondary absorber for these wavelengths in the mid-infrared, the hydroxyapatite crystals would be strongly heated above the melting point and the generated heat would be transferred by conduction directly in the irradiated hard tissue.

Ablation of dental hard tissues and bone occurs by absorption in water for the wavelengths in the middle infrared. As can be seen in Fig. 1, the absorption curve shows a very high absorption in water at about  $10^4/\text{cm}$ . If water covers the irradiated surface during ablation, dental hard tissue and bone removal is achieved by explosive (water-mediated) ablation, so-called thermo-mechanical ablation.<sup>23</sup> In this process, light is absorbed by water molecules, rapidly heating a small volume. The vaporisation of water

**Fig. 1:** Light absorption constants  $\mu_A$  of biological materials.<sup>22</sup>



**Fig. 1**



**Fig. 2:** Irradiation effect by absorption of the Er:YAG laser energy in hydroxyapatite in dentine. After 10 s of irradiation with no water at 25 Hz, dentine will be carbonised even with an applied fluence of only 20 J/cm<sup>2</sup>. A tooth irradiated for 10 s with a fluence of ~60 J/cm<sup>2</sup> becomes very hot, quite warm at ~40 J/cm<sup>2</sup> and still warm at ~20 J/cm<sup>2</sup>. In enamel there is less ablation but a strong heating.

**Fig. 3:** A "hot spot" at the fibre end of the diode laser is black burned tissue. Energies emitted with such a fibre end would bring the contrary desired therapeutic effect.

creates a strong subsurface pressure and leads to an explosive removal of the surrounding mineral.<sup>24,25</sup> The removal of hard tissue is done by micro-explosions far below the melting point of these tissues. If water does not cover the irradiated surface of bone or teeth, e.g. when the dentist's assistant sucks off the water spray during cavity preparation, the tissue water of the hard substances would be consumed by absorption very fast and the absorption takes place in the secondary absorber, the hydroxyapatite, which leads immediately to a strong overheating.<sup>26</sup> The clinical effect is carbonisation of the irradiated tissue (Fig. 2).

The chromophores that an Er:YAG or Er,Cr:YSGG laser in a periodontal pocket can identify are water or hydroxyapatite (Fig. 1). The laser user executing a closed curettage by such a laser has to avoid any absorption in hydroxyapatite. Therefore, the tissue water in the pocket must be sufficient to provide an absorption of the energy solely in water.

Calculus removal in a closed subgingival situation working with an Er:YAG laser must obey the same biophysical background. The water content of calculus<sup>27</sup> is similar to fresh dentin. Therefore the ablation threshold for both materials must be close together. If big masses of subgingival calculus should be removed only by an Er:YAG or Er,Cr:YSGG laser, working efficiently demands high energy densities. The risk to remove healthy subgingival dentin by a wrong angulation of the laser tip towards dentin or a too high energy (180 mJ) then is very high.<sup>28</sup> In safety guidelines for laser removal of dental calculus<sup>29</sup> the Japanese society for laser dentistry recommends that the laser tip should be parallel<sup>30,31</sup> to the root surface and the applied laser energy be about 40 mJ.

Er:YAG and Er,Cr:YSGG lasers are suitable tools for working in the subgingival periodontal area because of its biophysical background. Ablation of soft and hard subgingival deposits without any pathological thermal side effects is possible, bactericidal ef-

fects<sup>18-20</sup> with energy densities far below 10 J/cm<sup>2</sup> are given, bone healing is stimulated<sup>21</sup>, and no discomfort for the patients after treatment is to be expected. The most important thing for closed working in very deep pockets of 10 mm and more with these wavelengths is to avoid any absorption of the laser energy in hydroxyapatite. There are many authors<sup>32-35</sup> working in a closed subgingival setting with Er:YAG lasers and power settings of 160 mJ, 10 Hz and energy densities of 20 J/cm<sup>2</sup> and more. But it is obvious that the higher the applied energies and the deeper the periodontal pockets are, the greater is the risk of causing damage in the hydroxyapatite-containing tissues like alveolar bone or root dentine because of absorption of the laser energy in the secondary absorber. To minimise this risk, we present seven cases working with the Er:YAG laser with energy densities close above the ablation threshold of bone and dentin.<sup>36</sup>

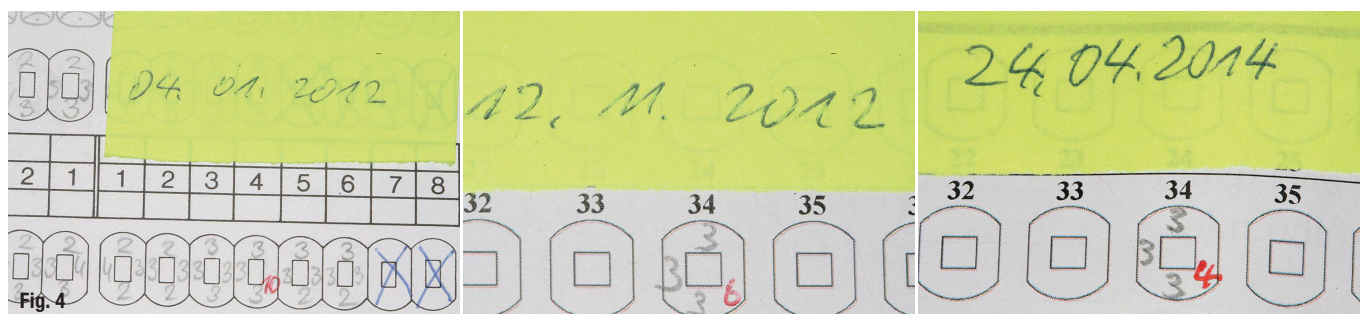
## 2. Material and Methods

Seven clinical cases, four of women and three of men aged between 48 and 74 years are presented. Eight periodontal pockets larger than 9 mm were treated with pocket depths between 10 and 12 mm. The tooth mobility degree (TM) of six teeth was 4. Not only was the horizontal mobility measured, but also the vertical mobility. One tooth 33 in case 4 had been already fixed by a crown to the neighbouring tooth and tooth 16 in case 5 had enough stability despite the 11 mm deep pocket.

All patients had to pass a strict therapy protocol including:

- patient instruction for an adequate oral hygiene,
- evaluation and elimination of the pockets' cause,
- splinting the teeth except TM < 3
- conventional pocket therapy with scaling and root planing (SRP)
- laser irradiation

Laser irradiation includes three wavelengths of  $\lambda = 670$  nm,  $\lambda = 810$  nm, and  $\lambda = 2,940$  nm.



**Fig. 4:** Development of the clinical pocket depth. From the left: 4 January 2012, 12 November 2012 and 24 April 2014.

## 2.1 The conventional treatment protocol

The patient had to pass an oral hygiene phase prior to pocket treatment, followed by a first pocket treatment session, including:

- Splinting the tooth with wire and traditional or acrylic and glass fibre reinforced composites (ever-Stick®).
- Elimination of the pockets cause or causes, e.g.
  - endo/perio lesions → begin endodontic treatment,
  - occlusal traumata → eliminate pre-contacts or hyperbalances etc.,
  - food impaction (FI) → close the gap with reconstructive methods,
  - foreign bodies → remove them,
  - no attached gingiva → if periodontal treatment is successful → free gingival graft (FGG),
  - special pathogen bacteria like Aa → decontamination by laser light.
- SRP under local anaesthesia.

In up to three or four following sessions, the conventional treatment always consists of only ultrasonic cleaning of the treated pockets to remove any plaque formation without anaesthesia and finishing of the conservative therapies (endodontic treatment, fillings, occlusion, FGG, etc.).

The therapy of deep pockets greater than 9 mm demands at least three, oftentimes four laser applications in time intervals between four to ten days. During the whole treatment period, when common prophylactic actions in the treated area are impossible or contra productive, the patients have to rinse their mouth with 0.2% Chlorhexidine (CHX) solution. The healing of the periodontally treated area with correctly applied

laser therapy is almost painless for the patient, fast and without any uncomfortable side effects.

To understand why the local application of laser energy is able to replace antibiotics and to substitute augmentation procedures in many cases, it is indispensable to know the biophysical background of the therapeutic effects of the different laser wavelengths. Antibiotics must be applied only when the general health state demands antibiosis and augmentation procedures are needed in aesthetically very sensitive areas.

## 2.2 The laser treatment protocol

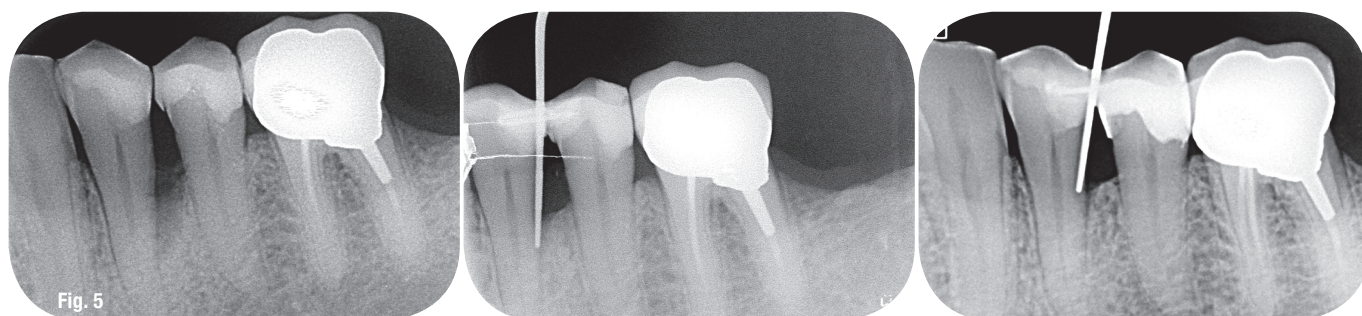
**2.2.1** The first laser treatment session follows directly after the conventional SRP under anaesthesia. The curettage is not done by conventional instruments, but by laser irradiation of an Er:YAG laser for two reasons:

- The laser in the middle infrared region stimulates bone growth factors.<sup>21</sup>
- The soft tissue is removed by the laser in a sterile way because of its ablation mechanism and disinfects the remaining soft and hard tissues.<sup>18</sup>

If we do a closed curettage of a very deep pocket of 10 mm and more pocket depth with an Er:YAG laser, it is impossible that during such irradiation the water spray gets inside of the deep pocket. The water spray has only a cooling effect from outside. Therefore, the tissue water in the pocket must be sufficient to provide an absorption of the energy solely in water. This can be safely achieved by special settings and a special technique of application. Our setting for closed pocket curettage with the Er:YAG Laser (LiteTouch, Syneron) are:

- fluence < 10 J/cm<sup>2</sup>
- energy on the device display: 50 mJ

**Fig. 5:** Radiological situation of bone regeneration. From the left: 4 January 2012, 12 November 2012 and 24 April 2014.





AVAILABLE  
**NOW**



Introducing

**Waterlase**  
*express*

&

**Epic**  
*pro*

The Smallest, Easiest and Most Cost-Effective Erbium Laser from BIOLASE yet!

Waterlase Express™ is the **all-new, fifth-generation Er,Cr:YSGG laser** from BIOLASE that features powerful clinical animations included for each procedure. You can start performing REPAIR™ Perio and Implant laser treatment — plus many other procedures with our smallest, most cost-effective Erbium laser yet.

Soft Tissue Management Redefined.

Epic Pro™ is the **first premium diode laser** in dentistry and offers practical, clinical, and financial value to dental practices looking to redefine what it means to manage soft tissue.

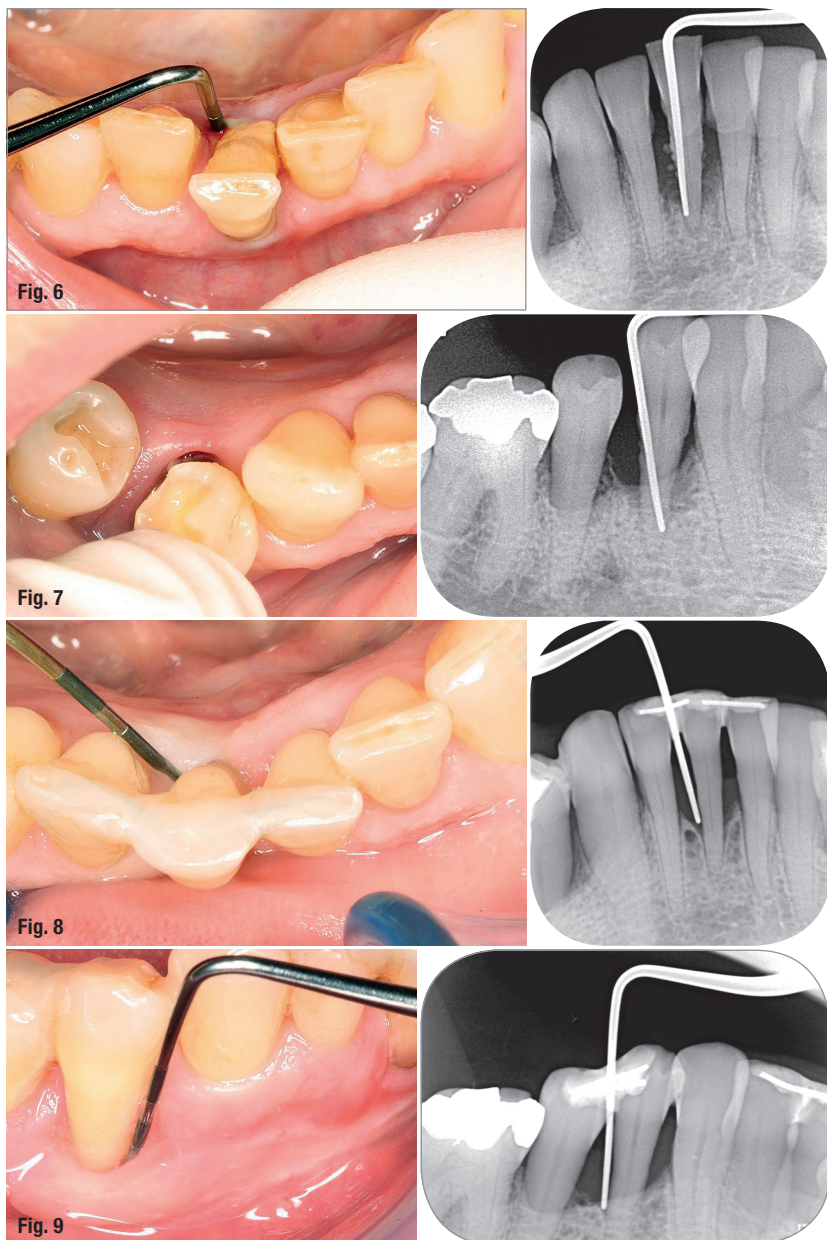
EXPERIENCE THE **ALL-NEW**  
WATERLASE EXPRESS AND EPIC PRO AT IDS 2017!

**Hall 04.2, Stand L060 M061**

**BIOLASE**

biolase.com





**Fig. 6:** Tooth 41, initial clinical situation (left) and radiological situation (right).

**Fig. 7:** Tooth 44, initial clinical situation (left) and radiological situation (right).

**Fig. 8:** Tooth 41, final clinical situation (left) and radiological situation (right), 15 months later.

**Fig. 9:** Tooth 44, final clinical situation (left) and radiological situation (right), 15 months later.

- frequency: 15–20 Hz
- saphir tip: chisel (15 mm long)
- water spray ~ 35–40 ml/min

This setting with a fluence of about  $6 \text{ J/cm}^2$  allows the operator to work with minimal risk for the patient to overheat the irradiated tissues or even carbonisation of dentine or bone in the subgingival area. The only thing to be considered is safely reaching the ablation threshold of the irradiated tissues like alveolar bone and root dentine at about a fluence of  $2\text{--}4 \text{ J/cm}^2$  respectively.<sup>36</sup>

#### Application technique

1. Irradiation of the subgingival root surface: The laser beam must be parallel<sup>29,30</sup> to the root surface and the movement is from crown to pocket bottom. The pocket should be slightly enlarged by this

movement and little rests of calculus can be removed. The irradiation time is only a few seconds.

2. Curettage: The inflamed soft tissue in the periodontal crater must be removed completely. The direction of the laser beam inside of the pocket is slightly directed towards the soft tissue and the movement of the chisel is from the margin of the gum to the pocket bottom. This irradiation lasts several minutes for each deep pocket. The curettage is finished when the chisel "reads" the osseous pocket bottom and can feel its anatomy. The pocket crater must be free of soft tissue.
3. Irradiation and stimulation of the bony pocket crater by removing some micrometers of the superficial surface: It's a fresh-up of the alveolar pocket bottom. This irradiation lasts about one minute for each deep pocket.

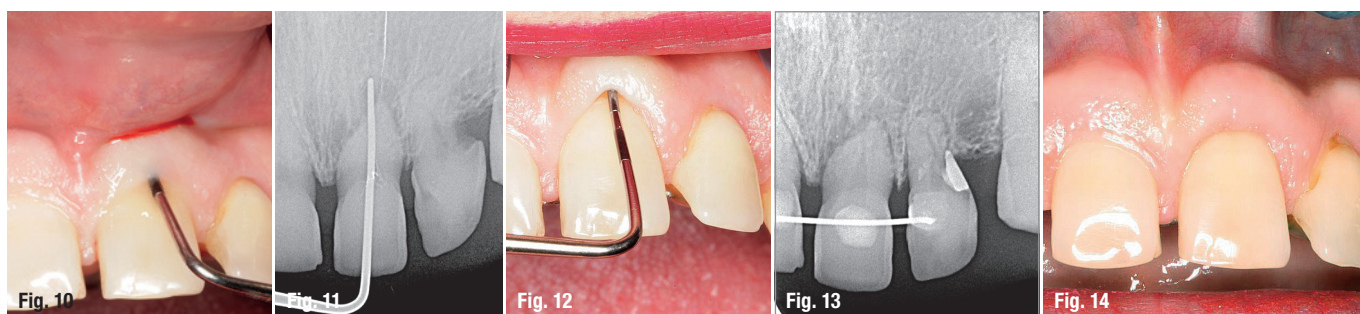
The expected effects in a closed periodontal treatment with lasers in the middle infrared in the first session are:

- Removal of little rests of concretions on the subgingival root dentin.<sup>29</sup>
- Complete de-epithelization of the inner pocket up to the margin of the gum.
- Removing of the inflamed pocket soft tissue.
- Decontamination of the whole pocket including root surface, osseous and soft tissue parts with energy densities far below  $10 \text{ J/cm}^2$ .<sup>19,20</sup>
- Stimulation of the osseous pocket crater for bone regeneration.<sup>21</sup>

The whole irradiation time of a deep pocket is between five to eight minutes. To avoid any carbonisation in hard tissues (Fig. 2), such closed curettage by lasers with wavelengths in the mid-infrared need time. It is therefore totally different from an open curettage with high laser settings, where the water spray prevents absorption of the energy in hydroxyapatite.

There is an easy home experiment to demonstrate the effect of laser irradiation on dental hard tissues without water. One takes a freshly extracted wisdom tooth between one's fingers and irradiates dentine at these wavelengths without water with laser settings as illustrated in Fig. 2. If the fluence is about  $60 \text{ J/cm}^2$ , then after some pulses of irradiation the tissue water of dentine is totally consumed and absorption in hydroxyapatite starts immediately. After some seconds one is no more able to hold the irradiated wisdom tooth between one's fingers. It becomes too hot! The clinical effect is carbonisation of the dentine. In enamel there is less ablation but high heat generation (Fig. 2).

Directly after Er:YAG irradiation of the pocket, transmucosal photodynamic therapy (tPDT) with a soft laser (Med-701, LASOTRONIC®) is applied. The tPDT is done with a buffered 1% methylene blue



solution as a photosensitiser and a softlaser of 670 nm wavelength having a maximal output power of 300 milliwatt (mW) in continuous wave (cw) mode. The Er:YAG-irradiated pocket needs to be completely coloured with the methylene blue solution. After one minute, the pocket is washed out with a 3%  $H_2O_2$  solution and then irradiated during one minute with the softlaser at 670 nm and a maximum output power of about 250 to 300 mW from the buccal and oral sides. After the Er:YAG irradiation the pocket is always bleeding because of the intervention by itself and the very low duty cycle<sup>37</sup> of the Er:YAG pulse. The blood must be washed out with water or an isotonic saline solution, otherwise the laser energy will be absorbed in the blood and cannot enter deep enough into the pocket tissue. Figure 1 shows that the laser has an absorption coefficient of about  $10^1/cm$  for venous blood at 670 nm. The penetration depth of the laser energy is per definitionem the reciprocal value of the absorption coefficient and in our example  $\sim 10^{-1} cm$  or  $\sim 1 mm$ . In this layer, about 2/3 of the emitted laser energy is already absorbed (Beer-Lambert absorption law). For the same reason, methylene blue colouration of the outside of the gum must be avoided. The patient must not feel any warmth. The expected therapeutic effect is decontamination of the pocket due to formation of oxygen radicals by absorption of the

energy in the coloured cell walls of the bacteria<sup>1-4</sup> and stimulation of wound healing.<sup>6-9</sup>

**2.2.2** The second treatment session for the patient is normally one week after the first treatment and is done without anaesthesia. The conventional pocket treatment is only an ultrasonic cleaning of the pocket followed by the second laser treatment:

First, a diode hardlaser with a wavelength of 810 nm (White Star) is applied directly after the conventional pocket treatment. The output power is 1 Watt in cw mode, and the application time lasts three times 30 seconds for each pocket side. The laser fibre has a diameter of 0.4 mm. The energy is emitted at the fibre end with a divergence angle of about  $12^\circ$ . The fibre is placed at the pocket bottom. In his other hand, the operator holds e.g. a 5 ml syringe with physiological NaCl solution. Before starting the laser, blood in the pocket is washed out with the rinsing solution. To avoid any formation of "hotspots" (Fig. 3) at the end of the laser fibre, the pocket is rinsed simultaneously with the isotonic saline solution during the application of the laser energy. A "hot spot" is black burned soft tissue at the fibre end. The emitted energy will be absorbed there with an absorption coefficient of about  $10^2/cm$  (Fig. 1). For this reason, the fibre end

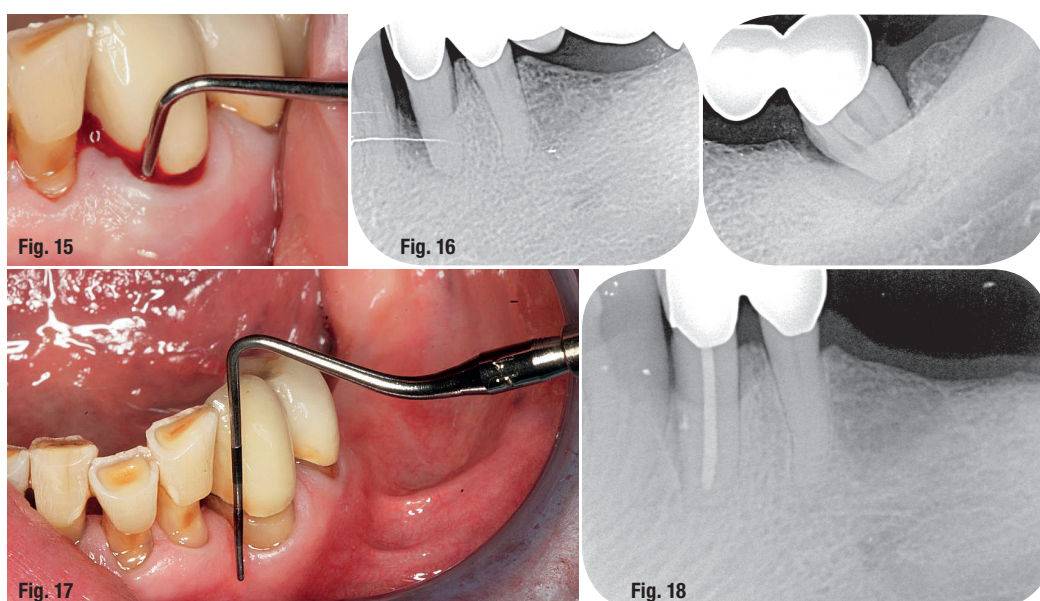
**Fig. 10:** An 11-mm pocket on the buccal side 21.

**Fig. 11:** X-ray shows the deep pocket on 21 and a heavy subgingival resorption distally from 22.

**Fig. 12:** Restitutio ad integrum, clinically.

**Fig. 13:** Radiological health,  $CO_2$  positive.

**Fig. 14:** Three years later, a healthy periodontal situation at 21.



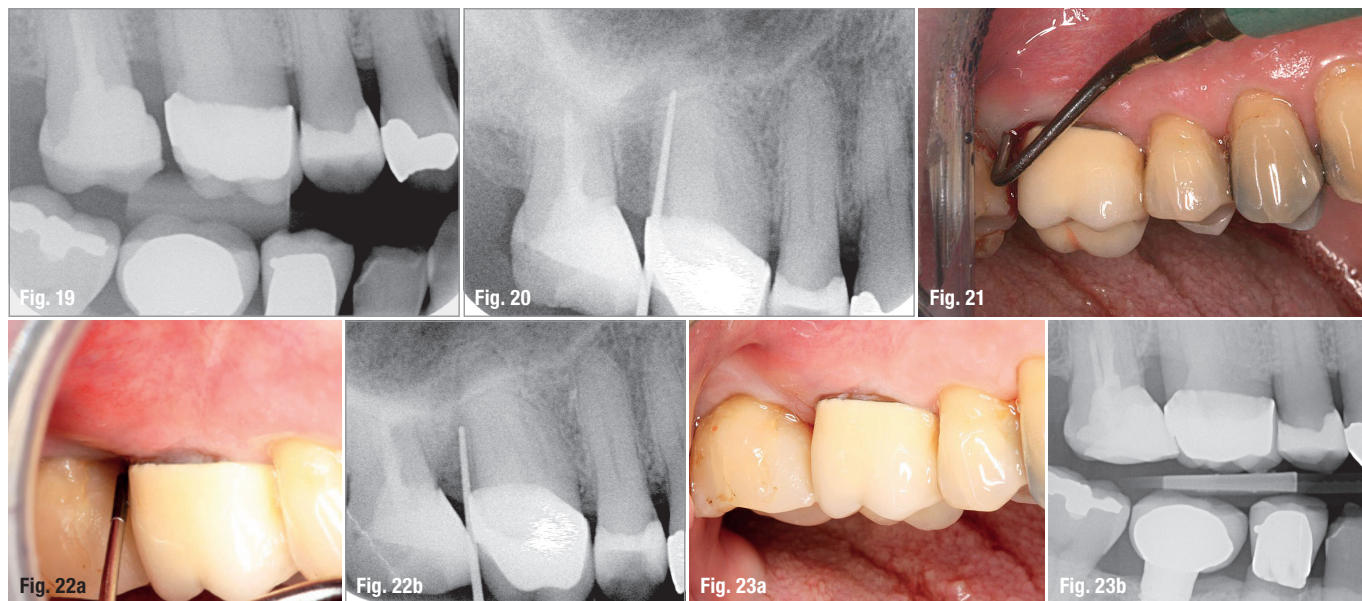
**Fig. 15:** A 12-mm active pocket mesially from tooth 33.

**Fig. 16:** X-ray, teeth 33, 34 and 37.

**Fig. 17:** Ten months later: A small recession of the gum.

**Fig. 18:** Ten months later: regeneration of the periodontal bone.





**Fig. 19:** Cause of the 11 mm deep pocket distally from 16: FI.

**Fig. 20:** Pocket's cause restored.

**Fig. 21:** An 11 mm deep pocket, active.

**Fig. 22a:** Eight months later: 6 mm inactive pocket.

**Fig. 22b:** The corresponding X-ray with bone regeneration.

**Fig. 23a:** Two years later: healthy clinical situation.

**Fig. 23b:** Corresponding bite wing.

becomes very hot and damages the surrounding tissue by overheating.

The laser fibre is guided from the pocket bottom to the papilla or the margin of the gum in uniform movements and several times during 30 s. This is repeated three times for each pocket. The optical property of non- or less-pigmented tissue allow a deep penetration of the laser light (Fig. 1). The expected therapeutic effects will be decontamination of pigmented bacteria<sup>10,11</sup> and stimulation of bone regeneration and wound healing<sup>12,13</sup> without any generation of heat. Directly after the diode laser treatment the pocket undergoes tPDT.

**2.2.3** The third treatment session for the patient is normally one week after the second session and is identical to the second session with:

- ultrasonic cleaning of the pocket
- diode laser irradiation
- tPDT

If necessary, it can be added one week later a fourth session identical to session two and three.

### 3. Case presentation

#### Case 1

Patient MU, a 69-year-old man complained on food impaction at tooth 34. The clinical situation showed an occlusal gap between 34 und 35 due to a fractured composite filling. The X-ray showed a 10 mm deep pocket crater distolingually from 34. The treatment of this pocket under local anaesthesia followed the general periodontal treatment protocol described in point 2.1 with two new composite fillings and 34 and 35 splinted together. The laser protocol was added. This first treatment session was followed by four

other laser sessions, a combination of a diode laser at 810 nm and tPDT as described under section 2.2.2. In Figures 4 and 5, the clinical and radiological development of the pocket on 34 is shown: Complete regeneration of the alveolar bone. The clinical state is stable until today (2017).

#### Case 2

Patient SA, a 74-year-old woman, came to see us because of a loose bridge in the upper jaw. Incidental findings: 10 mm pocket distolingually from 41, TM 4 and 10 mm pocket circularly 44, TM 4. Pocket's causes 41: calculus, food impaction, occlusal pre-contacts, and 44: occlusal dysfunction, food impaction, calculus, no attached gingiva on the buccal side. Tooth 41 (Fig. 6) and 44 (Fig. 7) were extremely mobile and could be easily brought into their original situation. They were fixed with wire and composite to the other lower incisors and to 45, respectively. In the same session, calculus removal, correction of the occlusal dysfunction and adding the laser protocol were performed. Tooth 44 got an FGG from 45 to 41 three months later. Figures 8 & 9 show the final clinical and radiological situation of 41 and 44 15 months after beginning the pocket treatment.

#### Case 3

Patient ED, a 48-year-old woman came into our practice due to fear of losing two upper-front teeth because of their high mobility, teeth 21 and 22, TM4. Tooth 21 on the buccal side featured a periodontal pocket of 11 mm. Pockets' cause: occlusal dysfunction. All upper front teeth were CO<sub>2</sub> positive. Figure 10 shows the clinical periodontal situation and Figure 11 the radiological situation of 21 and 22. Tooth 21 was splinted on the palatal side with a wire and composite to the neighbouring teeth 11 and 22, similar to an orthodontic retainer. Under anaesthesia, SRP and laser





LIGHT INSTRUMENTS  
RISE ABOVE TECHNOLOGY

# LITETOUCH™

Er:YAG Laser-in-Handpiece



Get the best results with the smallest all-tissue laser

**IDS**  
**2017**

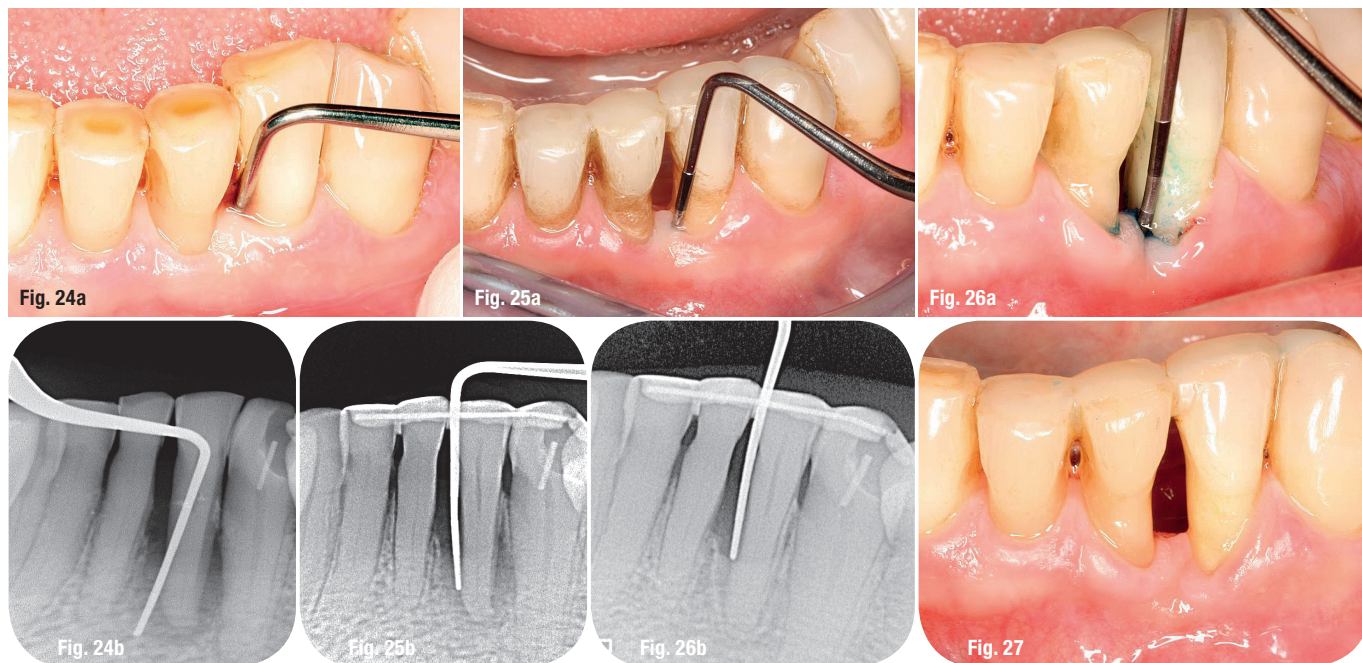
**VISIT US AT IDS 2017**  
37<sup>th</sup> International Dental Show  
Hall 4.2, Aisle N, Booth: 048  
Cologne, Germany March 21-25, 2017



**ON-BOARD**  
Scientific Conference  
20-27 August 2017  
ALASKA

RSVP at [office@light-inst.com](mailto:office@light-inst.com), <http://light-inst.com>





**Fig. 24a:** A 12 mm deep pocket mb to ml 32.

**Fig. 24b:** Initial X-ray.

**Fig. 25a:** Three months later: 7 mm pocket depth.

**Fig. 25b:** Beginning bone regeneration.

**Fig. 26a:** Eleven months later, 5 mm pocket depth.

**Fig. 26b:** Final bone regeneration.

**Fig. 27:** Two years later, healthy clinical situation.

protocol were applied. Here, it was very important to not go deeper than about 8 mm to prevent a devitalisation of 21 by SRP or laser irradiation. Figures 12 & 13 depict the situation six months later. The periodontal situation was normal and both teeth 21 and 22 had normal CO<sub>2</sub> vitality. Figure 14 shows a clinically healthy periodontal situation three years later, lessened symptoms and both teeth 21/22 CO<sub>2</sub> positive.

#### Case 4

Patient TA, a 70-year-old man came for a general consultation into our practice, with no pain. Canine 33 had an active, 12 mm deep periodontal pocket, shown in Figure 15 and the X-ray of 33 in Figure 16. The tooth was CO<sub>2</sub> negative, the pocket's cause: Endo/Perio. In the same session, we started endodontic treatment for 33, the bridge was separated distally from 34, and we removed 37, did SRP for 33, and applied laser treatment protocol. Ten months later Figure 17 shows a little recession of the gum, a healthy periodontium, and in Figure 18 a very nice bone regeneration corresponding to the pocket's anatomy. Five years later, no change in the periodontal situation of 33 was seen.

#### Case 5

Patient BA, 71-year-old man was referred for periodontal treatment of tooth 16, with a 11 mm deep active pocket distobuccally and distopalatally. Pocket's cause: food impaction as seen in Figure 19 between 16 and 17. Tooth 16 was CO<sub>2</sub> vital and crowned. In a first session, we restored tooth 17 with a new composite filling to close the gap. Figures 20 & 21 show the periodontal situation. In a second session, SRP was done and laser protocol was followed with four sessions.

Eight months later, Figure 22a shows a healthy periodontal situation with a small recession of the gum and in Figure 22b the corresponding X-ray and visible regeneration of the bone can be seen. Two years later, we found a clinical, inactive 6 mm pocket (Fig. 23a), and in Figure 23b a radiologically acceptable situation. Because of a heavy calculus formation we recommended that the patient visit the dental hygienist three times a year.

#### Case 6

Patient BL, a 69-year-old woman was referred for laser treatment of the 12 mm deep pocket at the mesiobuccal to mesiolingual side of tooth 32, with no pain, TM 4 and CO<sub>2</sub> vitality. Pocket's cause: occlusal dysfunction. Fig. 24a shows the initial clinical periodontal situation and Fig. 24b the initial X-ray of 32.

After following the conventional treatment protocol described in section 2.1, splinting 32 to 33, 41, 31, occlusal reseating and applying laser protocol in three sessions. Figure 25a shows the clinical state with 7 mm pocket depth and Figure 25b the beginning bone regeneration. After eleven months, 5 mm pocket depth remained as depicted in Figures 26a & b (final bone regeneration). Figure 27 shows the healthy clinical situation two years later.

#### Case 7

Patient BS, a 55-year-old woman, was referred by her diabetologist for a general periodontal consultation. The only heavy periodontal problem was an active pocket of 12 mm mesially from tooth 24 and 11 mm distally and mesiopalatally from 23 due to food impaction and occlusal dysfunction, with TM 4 for tooth 24 and TM 3 for tooth 23. The pathogenic



bacteria found in the analysis were *Porphyromonas gingivalis* and *Tannerella forsythia*. Figure 28a shows the initial clinical and Figure 28b the initial radiological situation before laser treatment. On the X-ray, no calculus can be seen in the interdental area 23/24 and neither mesially from 23. The therapy of choice was therefore to splint the teeth together, to eliminate the occlusal dysfunction and to eliminate the pathogenic bacteria. After SRP followed laser protocol in four sessions.

Eight years later, the whole regenerated bone mesial of 23 was stable and the bone had regenerated interdentally at 23/24 according to the pockets' anatomy. Clinically, both teeth in Figure 29a present normal periodontal clinical values and Figure 29b shows osseous regeneration ad integrum mesially from 23 and the maximally possible bone regeneration interdentally at 23/24.

The reduction of the pocket depth to an inflammation-free, painless and long-term satisfactory periodontal situation has always been described as a combination of gingival shrinking and bone regeneration. Bone regeneration was in all patients dependant of the pockets' anatomy and is rather well predictable, whereas the predictability of the extent of gingival recession after such a treatment is less safe.

#### 4. Discussion

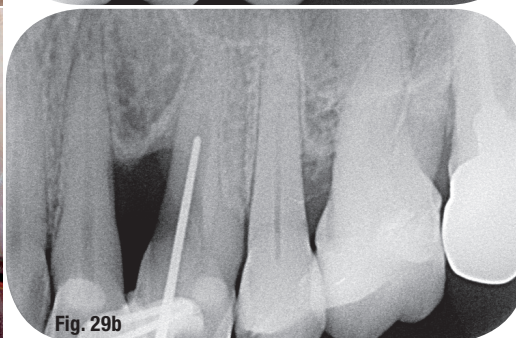
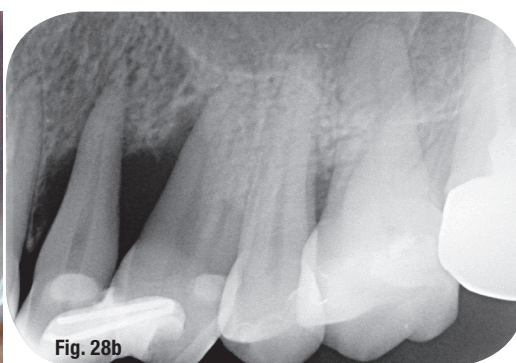
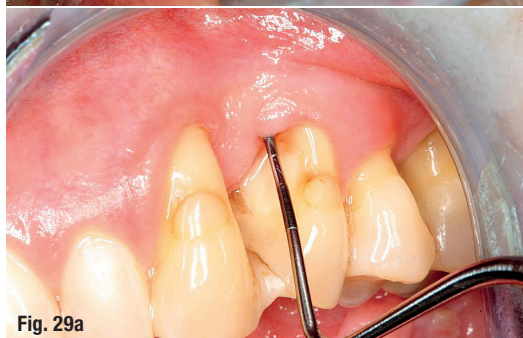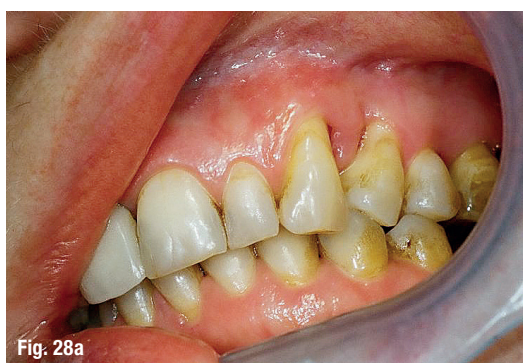When we started with lasers in our practice nine years ago, we had only the wavelength of 670 nm and methylene blue at our disposal. We then treated a young lady of 37 years with a 12 mm deep pocket dis-

tally at 23 (Fig. 30). We remember that we told her this would be a very long and expensive treatment with augmentation procedures. She was really shocked about the future costs. Then we informed her that another therapy exists but no guarantee for success would be given. She agreed to commence this treatment. The pocket was caused by *Actinobacillus actinomycetemcomitans* (Fig. 31).

After SRP and curettage under local anaesthesia we added four sessions only with tPDT as described under section 2.2.2. No antibiotics or augmentation procedures were applied. Five months later, Figure 32 shows that all pathologic bacterial flora was eliminated only by the correct application of tPDT. Nine years later, the patient is very happy and completely satisfied with the stable result.

In September 2009, the author, 62 years old at the time, was immatriculated at RWTH university of Aachen for the master course of lasers in dentistry. He finished two years later.

The literature for lasers in dentistry in periodontal treatments is still contradictory. There are many authors that cannot find better therapeutic results compared to conventional closed periodontal treatments alone or with adjunctive lasers. Neither a PDT with toluidine blue and a laser wavelength of 632 nm<sup>38</sup> could improve the clinical parameters of bleeding and probing, probing pocket depth and clinical attachment level nor did a diode adjunctive laser<sup>39</sup> therapy improve the above mentioned clinical parameters and the measured gingival cervical fluid inflammatory mediator interleukin-1 $\beta$  (IL-1 $\beta$ ). Even the



**Fig. 28a:** Clinical initial situation of teeth 23 and 24.

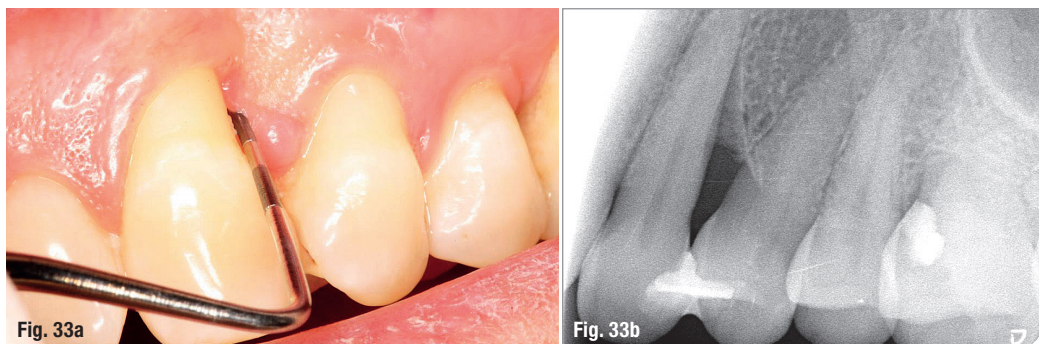
**Fig. 28b:** Radiological initial situation after splinting 23/24.

**Fig. 29a:** Clinical situation eight years later.

**Fig. 29b:** Corresponding X-ray: mesial 23 restituito ad integrum and interdental 23/24, the maximally possible bone regeneration.







**Fig. 33a:** Clinical situation nine years after the beginning of the conventional closed periodontal treatment with adjunctive laser therapy.

**Fig. 33b:** Radiological situation.

scalers and curettes. The regeneration of the alveolar bone progressed according to the pockets anatomy.

## 5. Conclusion

The successful clinical treatment of very deep periodontal localised pockets of 10 mm and more without antibiotics or augmentation procedures can be achieved by consequently following the conventional periodontal therapy principles and by performing adjunct laser irradiation.

Laser irradiation is a local decontamination of the treated areas by formation of oxygen radicals (PDT) or absorption of the laser energy in the chromophores of the bacteria-like pigments (diode lasers in near infrared) and water (erbium group in mid-infrared). In addition, the three presented wavelengths have inhibitory effects of the inflammation process of the soft tissues after treatment and stimulate wound healing and osseous regeneration. The patients do not experience any uncomfortable side effects from the correct laser application and the wound healing is fast

and almost painless. To minimise the risk for iatrogenically generated tissue damages by laser application, for example overheating or carbonisation of the irradiated tissues, the applied power settings are laser much lower than generally described in the literature for diode (810 nm) and the Er:YAG (2,940 nm). To achieve the best clinical results, it is indispensable to know the biophysical background of the applied laser wavelengths and to assess correctly the optical properties of the irradiated tissues.

## contact

### Dr Gottfried Gisler, MSc

Praxis Dres. med. dent. Gottfried  
& Vanessa Gisler  
Bahnhofstr. 14  
8708 Männedorf, Switzerland  
Tel.: +41 44 9200453  
info@zahnarzt-gisler.ch  
www.zahnarzt-gisler.ch

Author details



## Kurz & bündig

Die Eliminierung von pathogenen Keimen in der parodontalen tiefen Tasche ohne Antibiotika als ein wesentliches Behandlungsziel wird mittels Lasereinsatz von verschiedenen Wellenlängen sicher und zweckmäßig erreicht, sei es durch Bildung von Sauerstoffradikalen in photodynamischen Therapien<sup>1-4</sup> oder durch Absorption der Laserenergie in den Pigmenten (naher Infrarotbereich)<sup>10-12</sup> oder im Wasser (mittlerer Infrarotbereich)<sup>18-20</sup> der Bakterien. Die zusätzliche entzündungshemmende und biostimulative Wirkung von Laserlicht<sup>5-9,13-15</sup> verkürzt die Abheilungszeit und macht den Eingriff für den Patienten erträglicher und schmerzärmer. Die geschlossene Parodontalbehandlung von sogenannten „hoffnungslosen“ Zähnen mit Taschentiefen von 10 mm und mehr erlebt dank adjunktiver Lasertherapie erstaunliche, ja verblüffende, mit viel Knochenregeneration stabile Langzeitergebnisse, was in den beschriebenen Fällen gezeigt werden konnte. Voraussetzung für solche Resultate ist der korrekte Einsatz der Laserenergie und das Einhalten allgemeingültiger Therapiegrundsätze konventioneller Zahnmedizin und hier speziell der parodontalprophylaktischen Maßnahmen. Um iatrogenen Gewebeschäden durch Laserbestrahlung möglichst vorzubeugen, wurden hier sowohl für den Diodenlaser wie auch für den Er:YAG-Laser viel tiefere Laserleistungen eingesetzt als häufig in der Literatur beschrieben.<sup>32-35</sup> Grundsätzlich gilt es beim Einsatz von Lasern im mittleren Infrarotbereich eine Absorption der Energie im Hydroxylapatit zu vermeiden, bei Lasern im nahen Infrarotbereich die Bildung eines „Hotspots“ am Faserende zu verhindern und bei der trans mukosalen photodynamischen Therapie mit Methylenblau im sichtbaren Rotbereich das durch die Behandlung im Operationsgebiet ausgetretene Blut simultan während der Irradiation auszuwaschen. Wer Laserlicht als Therapie einsetzt, muss die biophysikalischen Grundlagen und Wechselwirkungen der einzelnen Wellenlängen mit dem Gewebe kennen und die optischen Eigenschaften des bestrahlten Gewebes richtig einschätzen – man denke an Zahnstein, Dentin und Erbium-Laser!

Literature

