

Immediate restoration in the digital workflow

Part I

Authors: José Eduardo Maté Sánchez de Val & José Luis Calvo Guirado, Spain

Endosseous implants have consistently achieved high success rates in partially and completely edentulous patients. Clinicians have therefore begun to offer selected patients immediate and early implant placement options. The long-term success of immediately loaded implants has been investigated in animals^{1,2} and humans,³ with encouraging results. However, most of the studies were performed with implants placed in the anterior mandible, where primary implant stability is easily achieved.

In the anterior maxilla, clinicians seeking to load implants immediately must be concerned not only about achieving adequate implant stability, but also about fulfilling patients' desires for aesthetic results that resemble the natural dentition. To achieve this, it is essential to maintain as much of the bone height around the implant neck as possible, controlling the biologic width.⁴

Bone loss around the implant always occurs when an abutment is connected to a dental implant at the crestal level. It has been demonstrated that the gap between the implant and the abutment has a direct effect on bone loss, regardless of whether the two parts are connected at the time of integration of the implant or later.⁵ This phenomenon occurs whether the implant is loaded or not and ap-

pears to be unrelated to the type of implant surface.^{5,6} Hermann et al. demonstrated that crestal bone remodels to a level about 2.0 mm apical to the implant-abutment junction (IAJ),^{5,7,8} while Lazzara and Porter reported crestal bone levels about 1.5 to 2 mm below the IAJ at one year after restoration.⁹ Tarnow et al. documented a horizontal component that results in 1.3 to 1.4 mm of resorption from the IAJ to the bone in a horizontal direction.^{10,11} When the biologic width is in the wake of such osseous changes, the soft-tissue architecture, including the appearance of the papillae, is affected. The interproximal bone influences the interdental papillae by acting as a guidepost for the soft-tissue contours.

In addition to several ideas aimed at limiting crestal bone resorption, the concept of platform switching appears to be promising. Platform switching refers to the use of a smaller-diameter abutment on a larger-diameter implant collar. This type of connection shifts the perimeter of the IAJ inward toward the central axis of the implant.^{12,13} The time limitation in implant treatments is an important bias when it comes to planning and developing rehabilitation therapies. In this sense, the inclusion of new materials that allow for immediate loading in a single session without having to replace prosthetic components facilitate optimal results in terms of gingival attachment and minimize

peri-implant bone loss after prosthetic abutments have been manipulated. Ceramically reinforced PEEK is of great interest as it allows a single attachment to be retained in place throughout the entire treatment and avoids handling-related overload. Its mechanical and physical properties have been tested in animal experiments and in humans, showing the material to be ideal for one-step X protocols.



Fig. 1: Implants and abutments used (left to right). blueSKY implant, SKY esthetic abutment titanium, SKY elegance abutment.

The physical and mechanical properties of the prosthetic components govern the success of the long-term restoration. Resistance to occlusal loads such as masticatory movements and para-function should be adequate to allow denture survival. The modulus of elasticity and bending resistance of the material should be adequate to prevent undesirable fractures or micromovements.¹³

Furthermore, components used require a high degree of biocompatibility to prevent the occurrence of abnormal tissue reactions such as initial peri-implant inflammation and mucositis, which may result in more severe complications such as peri-implantitis.¹⁴ Polyetheretherketone (PEEK) is a polymer from the polyaryletherketone family, a relatively newly developed family of high-temperature thermoplastic polymers having of an aromatic backbone interconnected by ketone and functional ether groups.¹ In medicine, PEEK has been found to be an excellent substitute for titanium in orthopaedic applications^{15,16} and has been used in dental implants, provisional abutments, implantsupported bars, or clamp material in removable dentures.^{17,18} PEEK is biocompatible and

has a natural tooth-coloured appearance, unlike metal reconstructions.

Ceramically reinforced PEEK materials were developed to improve the mechanical properties and the colour of dental restorations. One of these materials is BioHPP (bredent medical, Senden, Germany). In abutments, the BioHPP is directly injectionmoulded to a titanium base and forms a monolithic hybrid abutment called "elegance" abutment, with a screw seat in titanium for long-term stability plus a resilient body made of ceramically reinforced PEEK.

To shorten procedures and eliminate intermediate prosthetic steps, digital technologies were developed that allow the intraoral scanning of models and attachments with a high degree of precision and reproducibility. Chairside CAD/CAM systems such as CEREC (Sirona) allow direct scanning of the abutments and the realization of immediate crowns. The ceramically reinforced hybrid abutments with a PEEK body and titanium base are easily scannable, yielding restorations of high quality with a good prognosis. Problems caused by removing and reinserting different

AD

47TH DGZI INTERNATIONAL ANNUAL CONGRESS

29./30. September 2017
Berlin – Maritim Hotel

ONLINE CONGRESS PROGRAMME



www.dgzi-jahreskongress.de

Fax Reply
+49 341 48474-290

I would like to receive further information on the 47TH DGZI INTERNATIONAL ANNUAL CONGRESS

Title, Surname, Name

E-mail address (for digital programme)

Stamp

IM 2/17

Holbeinstraße 29 · 04229 Leipzig · Tel.: +49 341 48474-308 · event@oemus-media.de

Theme:

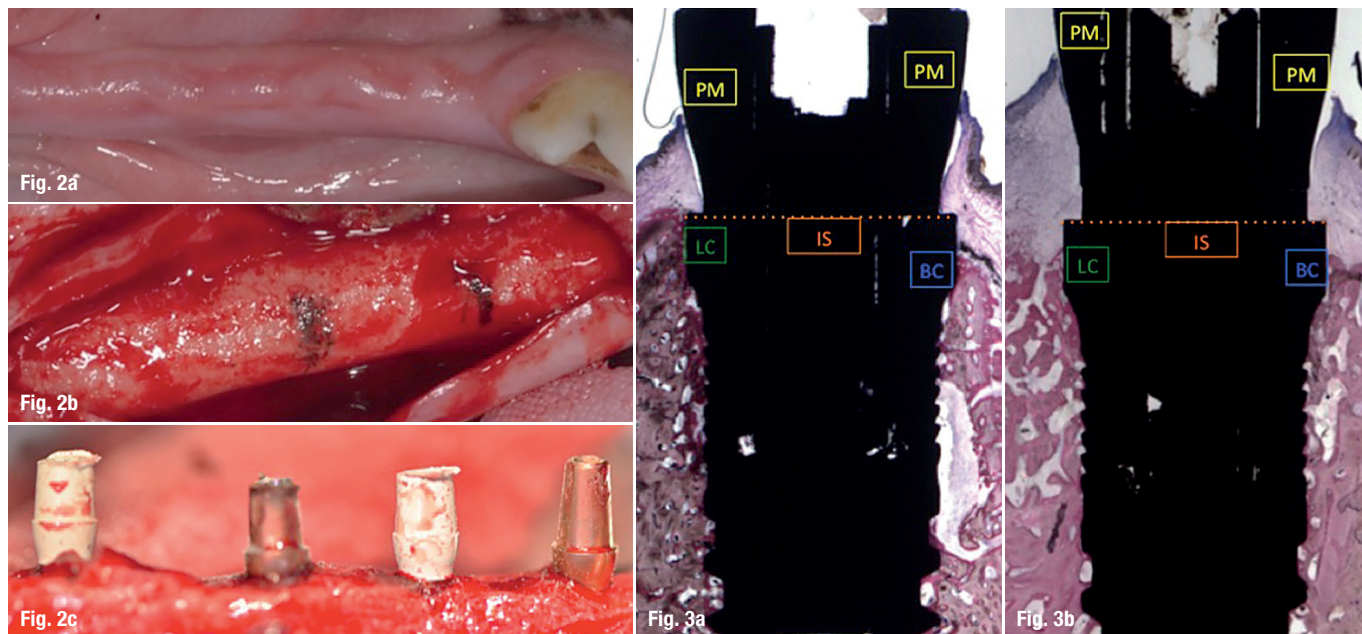
Does biology still play a role?

Organiser/Scientific chair:

Prof. (CAI) Dr. Roland Hille

Organisation:

OEMUS MEDIA AG
Holbeinstraße 29 | 04229 Leipzig
Tel.: +49 341 48474-308 | Fax: +49 341 48474-290
event@oemus-media.de | www.oemus.com



Figs. 2a–c: Animal study protocol with immediate loading.

Figs. 3a & b: Linear measurements (in mm): peri-implant mucosa (PM), buccal bone crest (BC), lingual bone crest (LC), top of the implant shoulder (IS), bone crest (BC), distance from the implant shoulder at buccal bone crest (IS-BC), distance from the implant shoulder at lingual bone crest (IS-LC).

prosthetic components—such as loss of soft tissue or early marginal bone loss—are reduced or eliminated. This article demonstrates the reliability of the single-session protocol using digital methods for scanning and producing crowns complemented with platform switching and evaluates the peri-implant soft-tissue seal.

Material and methods

Animal protocol

An animal experiment was conducted to evaluate an implant placement protocol with immediate loading using PEEK and CEREC and to assess the peri-implant soft tissue. Forty-eight blueSKY implants (bredent medical) were placed in healing bone. Thirty-two SKY elegance abutments (bredent medical) were used in the test group and sixteen titanium abutments in the control group (Fig. 1).

A randomization scheme was generated using the website www.randomization.com. The Ethics Committee for Animal Research of the University of Murcia, Spain, approved the study protocol, which followed the guidelines established by Directive 2010/63/EU on the protection of animals used for scientific purposes. Six American Foxhound dogs approximately one year of age, each weighing approximately 13–15 kg, were used in the study.

Day 0 (first stage)

The animals were pre-anaesthetized and taken to the operating theatre where, at the earliest opportunity, an intravenous catheter was inserted into the cephalic vein and propofol was infused at the rate of 0.4 mg/kg/min as a slow constant-rate infusion. Conventional dental infiltration anaesthesia

was administered at the surgical sites. Premolar and molar extractions (P2, P3, P4, M1) were performed in both mandibular quadrants of each dog.

Day 60 (second stage)

After drilling, the sequence of placement of four implants by hemi-mandible was randomly planned (using randomization as mentioned). The implants were inserted in healed bone at the sites of the mandibular premolars and molars (P2, P3, P4, M1), with an insertion torque of 30 Ncm or more (Figs. 2a–c).

Analysis (eight weeks after implantation)

- Histological and histomorphometric analysis of the bone-to-implant contact area (BIC) with linear measurements in millimetres: peri-implant mucosa (PM), buccal bone crest (BC), lingual bone crest (LC), top of the implant shoulder (IS), bone crest (BC), distance from the implant shoulder at buccal bone crest (IS-BC), distance from the implant shoulder at lingual bone crest (IS-LC) (Figs. 3a & b).
- Primary stability was evaluated by measuring the ISQ by Osstell Mentor at the time of placement.
- The radiological analysis was performed using a standardized protocol.

Human protocol

The research protocol called for recruitment of subjects among patients referred to the Department of General Dentistry, University of Murcia, Spain, during an 18-month period. All those in need of anterior oral rehabilitation that would include single-implant placement were invited to take part in the study, which was overseen by the institutional review board.




SiMPL^e

SiMPL^e

Fig. 4: SKY elegance abutment.

Additional criteria for inclusion in the study included sufficient bone height and width to allow the placement of implants with a minimum diameter of 4.1 mm and a minimum length of 10 mm and an occlusal pattern that allowed for bilateral stability. All subjects needed to have at least 3 mm of soft tissue (vertically) to allow for the establishment of an adequate biologic width and to reduce bone resorption. Exclusion criteria included severe maxillomandibular skeletal discrepancies, non-controlled diabetes, haemophilia, metabolic bone disorders, a history of renal failure or radiation treatment of the head or neck region, ongoing chemotherapy, pregnancy, drug or alcohol abuse, poor oral hygiene, insufficient bone volume at the recipient site, and the need for bone augmentation prior to implant placement.



three and five months using a one-position paralleling system. The analysis was performed with the ImageJ software (Wayne Rasband, NIH, Bethesda, USA). The distances between the platforms and the points of first bone contact were recorded.

- ISQ stability analysis: Stability measurements were made on day 0 to assess the primary stability of the implant required for the immediate-loading protocol. An ISQ of 65 was defined as the minimum value needed (Osstell Mentor; Osstell, Göteborg, Sweden).

- Mucogingival analysis and clinical findings: The bleeding index was recorded one, three and five months after implant placement by means of a special peri-implant probe. Moreover, any post-insertion loss of peri-implant mucosa or height were recorded. Bleeding on probing (0 = absent, 1 = present) was measured at one, three and five months. The insertion length was measured with a conventional plastic probe by one examiner per examination period and six measurements for each implant. The results were presented as means of six measurements.

- Statistical analysis: Values were recorded as mean \pm standard deviation (SD) and median. The non-parametric Friedman test was applied to compare sample values. The level of significance was set at $p < 0.05$.

Editorial note: To be continued in implants 3/2017 with results and discussion.

This article was first published in EDI Journal No 1/2016.


Day 0 (surgical planning and protocol)

A full-thickness incision was made with a No. 15c blade, combining an intrasulcular with a crestal incision in the palatal area. A full flap was reflected using a periosteotome. The manufacturer's implant placement protocol for blueSKY implants (bredent medical) was followed. After placement, the site was closed using 4-0 polypropylene single sutures.

- Postsurgical care: All patients received anti-inflammatory treatment (NSAID), ibuprofen 3x400 mg/day for three days and two chlorhexidine 0,12% rinses per day for two days.
- Implants: Ten blueSKY implants (bredent medical) 3.5-4 mm in diameter and 10-12 mm in length were randomly assigned and placed crestally in the premolar zone (P1 or P2) of the maxilla.
- Abutments: Ten BioHPP SKY elegance abutments were connected at the time of implant placement (immediate loading). The SKY elegance is a hybrid abutment with a body made of BioHPP moulded directly onto the titanium base without a gap. These abutments are used for single-session immediate-restoration treatments, since they combine the properties of a temporary and a definitive abutment, i.e. it is not necessary to change the abutment. All crowns were realized using the CEREC system (Sirona, Bensheim, Germany) with IPS Empress CAD CEREC/InLab (Ivoclar Vivadent, Schaan, Liechtenstein) feldspar ceramics. The crowns were cemented with RelyX self-adhesive cement (3M ESPE, Neuss, Germany; Fig. 4). All implants were loaded using a platform-switching protocol.

Analysis


- Radiological analysis: Standardized radiographs were taken on the day of placement and at one,



contact

José Eduardo Maté Sánchez de Val

Plaza de Luceros n. 15, bj. izq.
03004 Alicante, Spain
jemate@ucam.edu



Dentsply Sirona does not waive any right to its trademarks by not using the symbols or™, 3267114-USX1610 © 2016 Dentsply Sirona. All rights reserved.

Astra Tech Implant System®

Our world is not flat

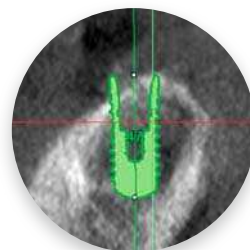
Neither is the anatomy of your implant patients

Your world is already full of clinical challenges so why work harder because of conventional thinking? Instead of augmenting sloped ridges to accommodate flat-top implants, it's time to discover a simpler solution by using an implant that follows the bone. Because sloped-ridge situations call for anatomically designed sloped implants.

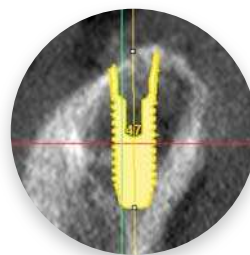
OsseoSpeed® Profile EV - It's time to challenge conventional thinking



www.profiledentalimplants.com



Conventional vs innovative approach



 **Dentsply
Sirona**
Implants