

# implants

international magazine of oral implantology

2<sup>2017</sup>



**research**

Immediate restoration in the digital workflow—Part I

**case report**

Sinus elevation with short implant

**industry**

Augmentation and defect filling in oral surgery



# BE MORE

*We offer you more effective solutions with;*



## T6 much more implant

- more esthetical
- more comfy
- more user-friendly
- more simple
- more durable
- more economic



[www.nucleoss.de](http://www.nucleoss.de)

# DGZI— globally engaged



Dr Rolf Vollmer

Dear colleagues,

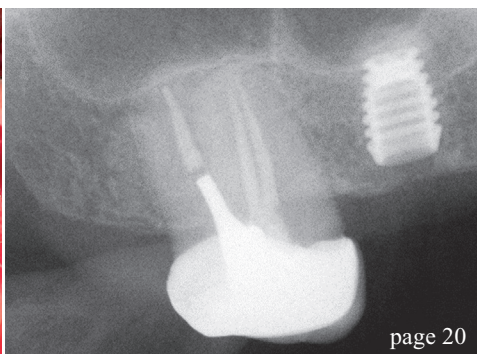
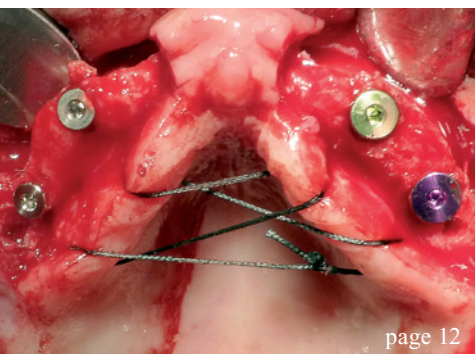
The first half of this year had scheduled numerous international events in the field of implantology in which we as the German Association of Dental Implantology (DGZI e.V.) participated representing our members and readers of this journal. Especially worth mentioning among those events is the annual meeting of the American Academy of Osseointegration (AO) with more than 2,500 participants. Attending the impressive congress with a delegation of DGZI members, we maintained our existing contacts and also made some new ones. The international exchange of expertise in the field of implantology is an essential part of our work as expert association and ensures a high standard of quality in practice and teaching while at the same time providing an important basis for the scientific conception of our annual DGZI congresses. As a result of our personal contacts and conversations, internationally renowned speakers as well as young and ambitious colleagues are encouraged to participate and engage. Referring to the exchange of expertise, Dr Pollack, AO President, said to the participants of this year's AO congress: "The majority of what we take home from meetings like this arises from sharing ideas and problems with our colleagues. Sitting in the auditorium next to someone who is practicing at the other end of the country or even the world, someone who has different perspectives and preconditions and thus applies different procedures, is eye opening and presents a variety of possibilities."

In addition, the 37<sup>th</sup> International Dental Show (IDS) in Cologne was another major event for all involved in the dental community. On the one hand, there seems to be no other event like the IDS offering such a broad overview of current technologies and trends in the area of implantology. As could be seen in Cologne, the promises that have been made over the last couple of years concerning the digital workflow in guided surgery in implantology are slowly being fulfilled; more and more integrated measures enter the market. On the other hand, the IDS constitutes the best place to meet old and new interlocutors for joint projects. With the help of OT medical, our long-term industrial partner and main sponsor of our annual congresses, the DGZI were able to present a point of contact at this year's IDS. For this we are especially thankful!

One last word regarding our scientific activities: On the occasion of the 47<sup>th</sup> annual congress on 29 and 30 September 2017 in Berlin, we once again present our DGZI awards. This includes the DGZI Implant Dentistry Award 2017 (5,000 Euro) as well as the DGZI Thesis Award 2017 (2,000 Euro). The closing date for both awards is 31 May 2017. Further details and conditions of participation are available at our website [www.dgzi.de](http://www.dgzi.de). I now wish you a pleasant and informative reading of this issue of **implants international magazine of oral implantology**.

Yours

Dr Rolf Vollmer  
First Vice President and Treasurer of the German Association of Dental Implantology



## editorial

- 03 **DGZI**—globally engaged  
Dr Rolf Vollmer

## research

- 06 **Immediate** restoration in the **digital** workflow  
José Eduardo Maté Sánchez de Val & José Luis Calvo Guirado

## case report

- 12 **Implant-prosthesis** treatment in case of **total edentulism**  
Prof. Massimo Pasi
- 20 **Sinus elevation** with short implant  
Prof. Dr Mauro Marincola, Prof. Dr Rolf Ewers, Prof. Giorgio Lombardo & Prof. Miguel Simancas Pallares

## industry

- 26 **Augmentation** and **defect filling** in oral surgery  
Henriette Lerner
- 32 Vertical bone **augmentation** procedures—**Part II**  
Prof. Dr Florian G. Draenert, M.D., D.D.S., Ph.D.

## special

- 38 How **safe** is your implant?  
Dr Dirk U. Duddeck

## interview

- 40 Become a **champion!**  
Katrin Maiterth

## events

- 42 2017 **AO** Annual Meeting Orlando  
Dr Rolf Vollmer

## news

- 44 **manufacturer news**
- 48 **news**

## about the publisher

- 50 imprint



Cover image courtesy of NucleOSS Europe GmbH  
[www.nucleoss.com](http://www.nucleoss.com)

a perfect fit™

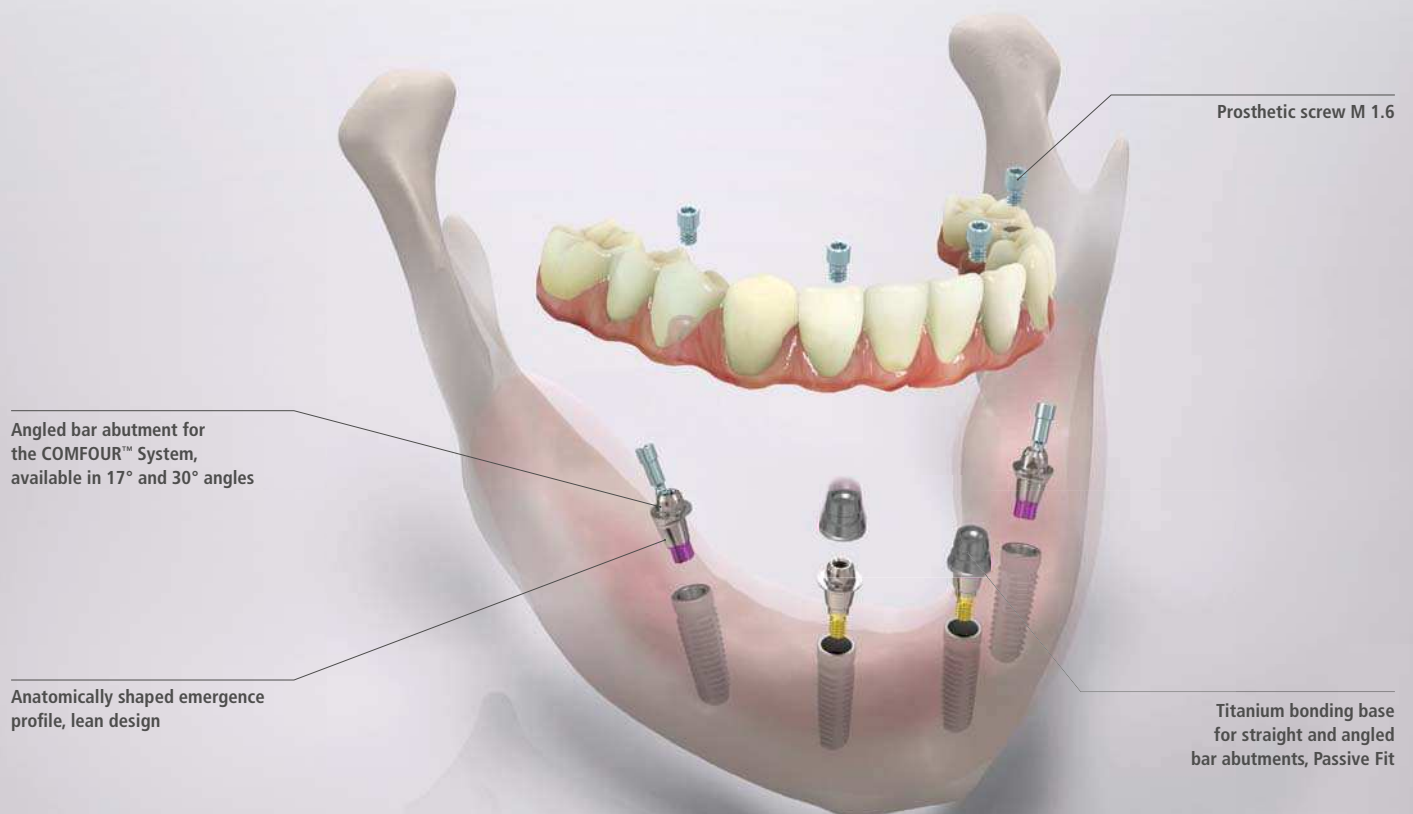camlog

## THE NEW COMFORT CLASS.

The COMFOUR™ Abutment System for occlusal screw-retained restorations is an ideal addition to the CAMLOG® and the CONELOG® Implant System. With the COMFOUR™ System, you can offer your edentulous patients the option of an immediate, comfortable and permanent denture on four or six implants – and thus a considerable gain in quality of life. [www.camlog.com](http://www.camlog.com)

CAMLOG®  
SYSTEM

CONELOG®  
SYSTEM



Aligning tool



Scanning cap



Titanium cap



Flexible handle

COMFOUR™ offers you a range of options to overcome the challenges you face in your implant practice, making them easier while saving time.

# Immediate restoration in the digital workflow

## Part I

**Authors:** José Eduardo Maté Sánchez de Val & José Luis Calvo Guirado, Spain

**Endosseous implants have consistently** achieved high success rates in partially and completely edentulous patients. Clinicians have therefore begun to offer selected patients immediate and early implant placement options. The long-term success of immediately loaded implants has been investigated in animals<sup>1,2</sup> and humans,<sup>3</sup> with encouraging results. However, most of the studies were performed with implants placed in the anterior mandible, where primary implant stability is easily achieved.

In the anterior maxilla, clinicians seeking to load implants immediately must be concerned not only about achieving adequate implant stability, but also about fulfilling patients' desires for aesthetic results that resemble the natural dentition. To achieve this, it is essential to maintain as much of the bone height around the implant neck as possible, controlling the biologic width.<sup>4</sup>

Bone loss around the implant always occurs when an abutment is connected to a dental implant at the crestal level. It has been demonstrated that the gap between the implant and the abutment has a direct effect on bone loss, regardless of whether the two parts are connected at the time of integration of the implant or later.<sup>5</sup> This phenomenon occurs whether the implant is loaded or not and ap-

pears to be unrelated to the type of implant surface.<sup>5,6</sup> Hermann et al. demonstrated that crestal bone remodels to a level about 2.0 mm apical to the implant-abutment junction (IAJ),<sup>5,7,8</sup> while Lazzara and Porter reported crestal bone levels about 1.5 to 2 mm below the IAJ at one year after restoration.<sup>9</sup> Tarnow et al. documented a horizontal component that results in 1.3 to 1.4 mm of resorption from the IAJ to the bone in a horizontal direction.<sup>10,11</sup> When the biologic width is in the wake of such osseous changes, the soft-tissue architecture, including the appearance of the papillae, is affected. The interproximal bone influences the interdental papillae by acting as a guidepost for the soft-tissue contours.

In addition to several ideas aimed at limiting crestal bone resorption, the concept of platform switching appears to be promising. Platform switching refers to the use of a smaller-diameter abutment on a larger-diameter implant collar. This type of connection shifts the perimeter of the IAJ inward toward the central axis of the implant.<sup>12,13</sup> The time limitation in implant treatments is an important bias when it comes to planning and developing rehabilitation therapies. In this sense, the inclusion of new materials that allow for immediate loading in a single session without having to replace prosthetic components facilitate optimal results in terms of gingival attachment and minimize

peri-implant bone loss after prosthetic abutments have been manipulated. Ceramically reinforced PEEK is of great interest as it allows a single attachment to be retained in place throughout the entire treatment and avoids handling-related overload. Its mechanical and physical properties have been tested in animal experiments and in humans, showing the material to be ideal for one-step X protocols.



**Fig. 1:** Implants and abutments used (left to right). blueSKY implant, SKY esthetic abutment titanium, SKY elegance abutment.

The physical and mechanical properties of the prosthetic components govern the success of the long-term restoration. Resistance to occlusal loads such as masticatory movements and para-function should be adequate to allow denture survival. The modulus of elasticity and bending resistance of the material should be adequate to prevent undesirable fractures or micromovements.<sup>13</sup>

Furthermore, components used require a high degree of biocompatibility to prevent the occurrence of abnormal tissue reactions such as initial peri-implant inflammation and mucositis, which may result in more severe complications such as peri-implantitis.<sup>14</sup> Polyetheretherketone (PEEK) is a polymer from the polyaryletherketone family, a relatively newly developed family of high-temperature thermoplastic polymers having of an aromatic backbone interconnected by ketone and functional ether groups.<sup>1</sup> In medicine, PEEK has been found to be an excellent substitute for titanium in orthopaedic applications<sup>15,16</sup> and has been used in dental implants, provisional abutments, implantsupported bars, or clamp material in removable dentures.<sup>17,18</sup> PEEK is biocompatible and

has a natural tooth-coloured appearance, unlike metal reconstructions.

Ceramically reinforced PEEK materials were developed to improve the mechanical properties and the colour of dental restorations. One of these materials is BioHPP (bredent medical, Senden, Germany). In abutments, the BioHPP is directly injectionmoulded to a titanium base and forms a monolithic hybrid abutment called "elegance" abutment, with a screw seat in titanium for long-term stability plus a resilient body made of ceramically reinforced PEEK.

To shorten procedures and eliminate intermediate prosthetic steps, digital technologies were developed that allow the intraoral scanning of models and attachments with a high degree of precision and reproducibility. Chairside CAD/CAM systems such as CEREC (Sirona) allow direct scanning of the abutments and the realization of immediate crowns. The ceramically reinforced hybrid abutments with a PEEK body and titanium base are easily scannable, yielding restorations of high quality with a good prognosis. Problems caused by removing and reinserting different

AD

# 47<sup>TH</sup> DGZI INTERNATIONAL ANNUAL CONGRESS

29./30. September 2017  
Berlin – Maritim Hotel

ONLINE CONGRESS PROGRAMME



www.dgzi-jahreskongress.de

Fax Reply  
**+49 341 48474-290**

I would like to receive further information on the 47<sup>TH</sup> DGZI INTERNATIONAL ANNUAL CONGRESS

\_\_\_\_\_  
Title, Surname, Name

\_\_\_\_\_

\_\_\_\_\_  
E-mail address (for digital programme)

Stamp

IM 2/17

Holbeinstraße 29 · 04229 Leipzig · Tel.: +49 341 48474-308 · event@oemus-media.de

**Theme:**

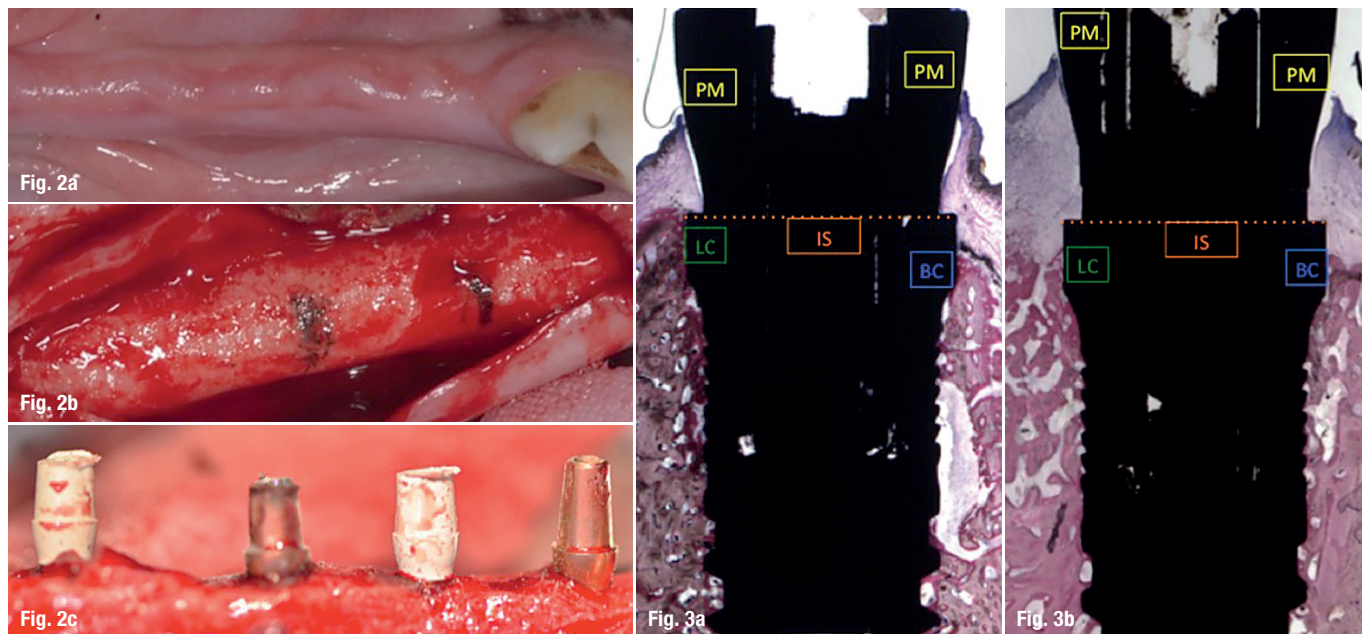
**Does biology still play a role?**

**Organiser/Scientific chair:**

Prof. (CAI) Dr. Roland Hille

**Organisation:**

OEMUS MEDIA AG  
Holbeinstraße 29 | 04229 Leipzig  
Tel.: +49 341 48474-308 | Fax: +49 341 48474-290  
event@oemus-media.de | www.oemus.com



**Figs. 2a–c:** Animal study protocol with immediate loading.

**Figs. 3a & b:** Linear measurements (in mm): peri-implant mucosa (PM), buccal bone crest (BC), lingual bone crest (LC), top of the implant shoulder (IS), bone crest (BC), distance from the implant shoulder at buccal bone crest (IS-BC), distance from the implant shoulder at lingual bone crest (IS-LC).

prosthetic components—such as loss of soft tissue or early marginal bone loss—are reduced or eliminated. This article demonstrates the reliability of the single-session protocol using digital methods for scanning and producing crowns complemented with platform switching and evaluates the peri-implant soft-tissue seal.

## Material and methods

### Animal protocol

An animal experiment was conducted to evaluate an implant placement protocol with immediate loading using PEEK and CEREC and to assess the peri-implant soft tissue. Forty-eight blueSKY implants (bredent medical) were placed in healing bone. Thirty-two SKY elegance abutments (bredent medical) were used in the test group and sixteen titanium abutments in the control group (Fig. 1).

A randomization scheme was generated using the website [www.randomization.com](http://www.randomization.com). The Ethics Committee for Animal Research of the University of Murcia, Spain, approved the study protocol, which followed the guidelines established by Directive 2010/63/EU on the protection of animals used for scientific purposes. Six American Foxhound dogs approximately one year of age, each weighing approximately 13–15 kg, were used in the study.

### Day 0 (first stage)

The animals were pre-anaesthetized and taken to the operating theatre where, at the earliest opportunity, an intravenous catheter was inserted into the cephalic vein and propofol was infused at the rate of 0.4 mg/kg/min as a slow constant-rate infusion. Conventional dental infiltration anaesthesia

was administered at the surgical sites. Premolar and molar extractions (P2, P3, P4, M1) were performed in both mandibular quadrants of each dog.

### Day 60 (second stage)

After drilling, the sequence of placement of four implants by hemi-mandible was randomly planned (using randomization as mentioned). The implants were inserted in healed bone at the sites of the mandibular premolars and molars (P2, P3, P4, M1), with an insertion torque of 30 Ncm or more (Figs. 2a–c).

### Analysis (eight weeks after implantation)

- Histological and histomorphometric analysis of the bone-to-implant contact area (BIC) with linear measurements in millimetres: peri-implant mucosa (PM), buccal bone crest (BC), lingual bone crest (LC), top of the implant shoulder (IS), bone crest (BC), distance from the implant shoulder at buccal bone crest (IS-BC), distance from the implant shoulder at lingual bone crest (IS-LC) (Figs. 3a & b).
- Primary stability was evaluated by measuring the ISQ by Osstell Mentor at the time of placement.
- The radiological analysis was performed using a standardized protocol.

### Human protocol

The research protocol called for recruitment of subjects among patients referred to the Department of General Dentistry, University of Murcia, Spain, during an 18-month period. All those in need of anterior oral rehabilitation that would include single-implant placement were invited to take part in the study, which was overseen by the institutional review board.






# SiMPL<sup>e</sup>

SiMPL<sup>e</sup>

**Fig. 4:** SKY elegance abutment.

Additional criteria for inclusion in the study included sufficient bone height and width to allow the placement of implants with a minimum diameter of 4.1 mm and a minimum length of 10 mm and an occlusal pattern that allowed for bilateral stability. All subjects needed to have at least 3 mm of soft tissue (vertically) to allow for the establishment of an adequate biologic width and to reduce bone resorption. Exclusion criteria included severe maxillomandibular skeletal discrepancies, non-controlled diabetes, haemophilia, metabolic bone disorders, a history of renal failure or radiation treatment of the head or neck region, ongoing chemotherapy, pregnancy, drug or alcohol abuse, poor oral hygiene, insufficient bone volume at the recipient site, and the need for bone augmentation prior to implant placement.



three and five months using a one-position paralleling system. The analysis was performed with the ImageJ software (Wayne Rasband, NIH, Bethesda, USA). The distances between the platforms and the points of first bone contact were recorded.

– ISQ stability analysis: Stability measurements were made on day 0 to assess the primary stability of the implant required for the immediate-loading protocol. An ISQ of 65 was defined as the minimum value needed (Osstell Mentor; Osstell, Göteborg, Sweden).

– Mucogingival analysis and clinical findings: The bleeding index was recorded one, three and five months after implant placement by means of a special peri-implant probe. Moreover, any post-insertion loss of peri-implant mucosa or height were recorded. Bleeding on probing (0 = absent, 1 = present) was measured at one, three and five months. The insertion length was measured with a conventional plastic probe by one examiner per examination period and six measurements for each implant. The results were presented as means of six measurements.

– Statistical analysis: Values were recorded as mean  $\pm$  standard deviation (SD) and median. The non-parametric Friedman test was applied to compare sample values. The level of significance was set at  $p < 0.05$ .

*Editorial note: To be continued in implants 3/2017 with results and discussion.*

*This article was first published in EDI Journal No 1/2016.*


#### Day 0 (surgical planning and protocol)

A full-thickness incision was made with a No. 15c blade, combining an intrasulcular with a crestal incision in the palatal area. A full flap was reflected using a periosteotome. The manufacturer's implant placement protocol for blueSKY implants (bredent medical) was followed. After placement, the site was closed using 4-0 polypropylene single sutures.

- Postsurgical care: All patients received anti-inflammatory treatment (NSAID), ibuprofen 3x400 mg/day for three days and two chlorhexidine 0,12% rinses per day for two days.
- Implants: Ten blueSKY implants (bredent medical) 3.5–4 mm in diameter and 10–12 mm in length were randomly assigned and placed crestally in the premolar zone (P1 or P2) of the maxilla.
- Abutments: Ten BioHPP SKY elegance abutments were connected at the time of implant placement (immediate loading). The SKY elegance is a hybrid abutment with a body made of BioHPP moulded directly onto the titanium base without a gap. These abutments are used for single-session immediate-restoration treatments, since they combine the properties of a temporary and a definitive abutment, i.e. it is not necessary to change the abutment. All crowns were realized using the CEREC system (Sirona, Bensheim, Germany) with IPS Empress CAD CEREC/InLab (Ivoclar Vivadent, Schaan, Liechtenstein) feldspar ceramics. The crowns were cemented with RelyX self-adhesive cement (3M ESPE, Neuss, Germany; Fig. 4). All implants were loaded using a platform-switching protocol.

#### Analysis


- Radiological analysis: Standardized radiographs were taken on the day of placement and at one,



#### contact

**José Eduardo Maté Sánchez de Val**

Plaza de Luceros n. 15, bj. izq.  
03004 Alicante, Spain  
jemate@ucam.edu



Dentsply Sirona does not waive any right to its trademarks by not using the symbols or 3267114-USX1610 © 2016 Dentsply Sirona. All rights reserved.

Astra Tech Implant System®

# Our world is not flat

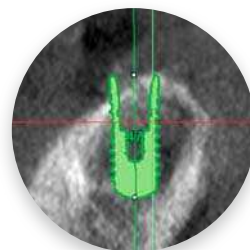
Neither is the anatomy of your implant patients

Your world is already full of clinical challenges so why work harder because of conventional thinking? Instead of augmenting sloped ridges to accommodate flat-top implants, it's time to discover a simpler solution by using an implant that follows the bone. Because sloped-ridge situations call for anatomically designed sloped implants.

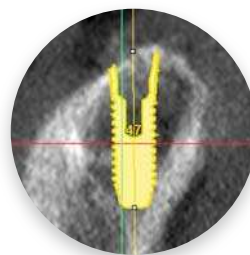
**OsseoSpeed® Profile EV** - It's time to challenge conventional thinking



[www.profiledentalimplants.com](http://www.profiledentalimplants.com)



Conventional vs innovative approach



 **Dentsply  
Sirona**  
Implants

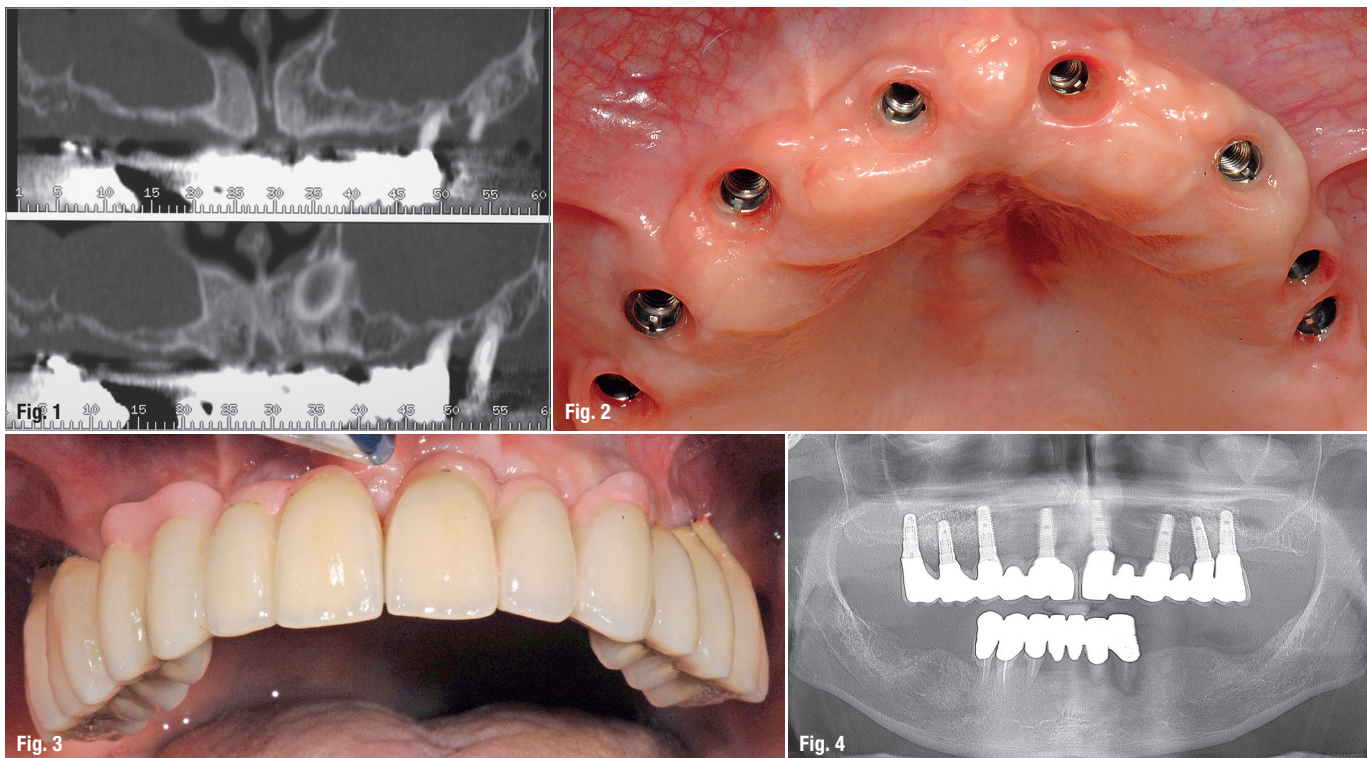
# Implant-prosthesis treatment in case of total edentulism

**Author:** Prof. Massimo Pasi, Italy

Total edentulism is a serious handicap that still affects almost 25 per cent of the population aged 65 years and older. Loss of teeth leads to a severe impairment of life quality of those affected, not only with regard to their ability to chew but also for their social life and their psychological attitude. In case of total edentulism, a prosthesis improves both chewing efficiency and way of life. Since a denture in the maxilla is often well accepted, the minimum of acceptable treatment in the lower jaw are overdentures anchored by two implants.

## Introduction

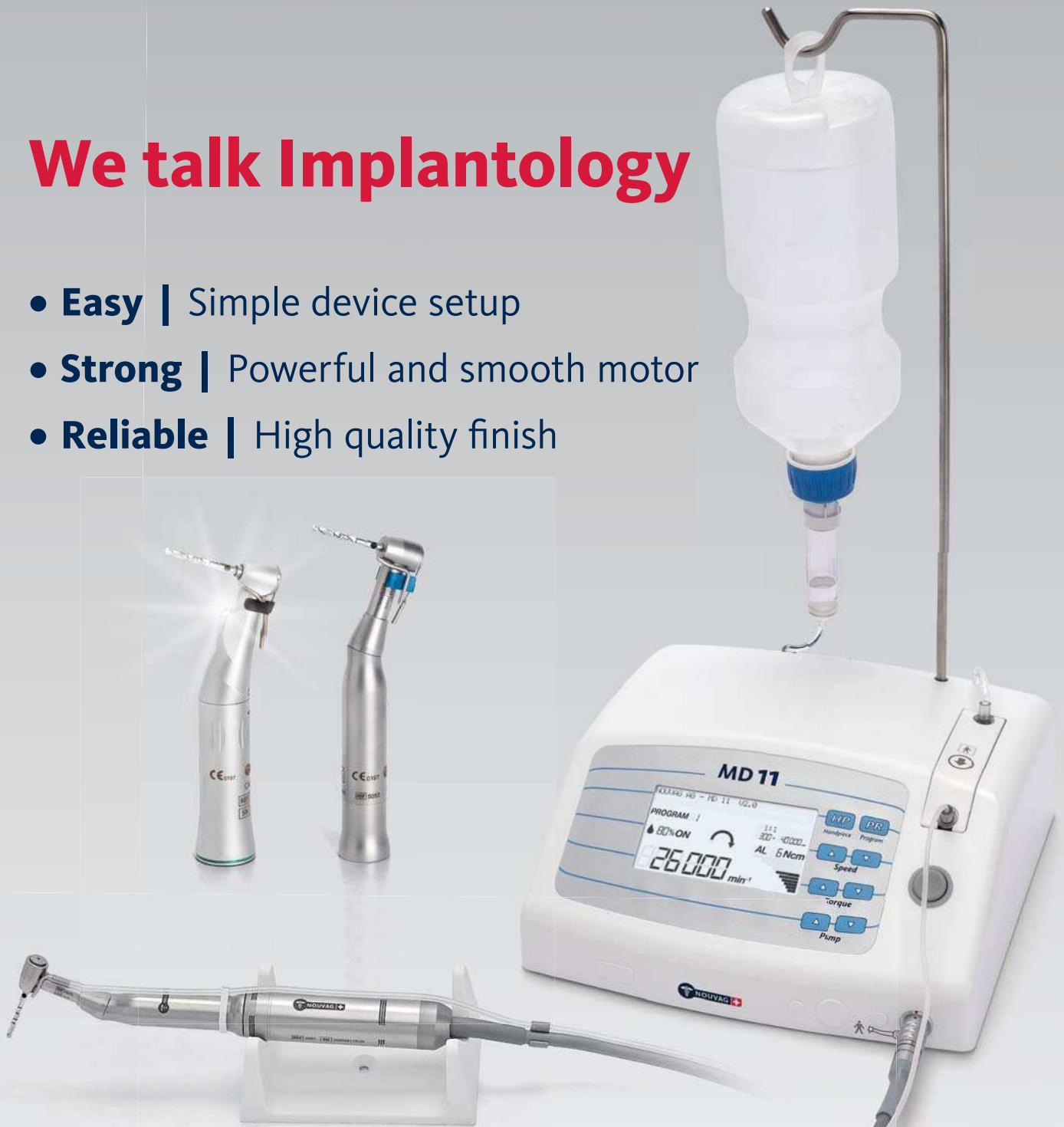The latest available data on edentulism in Italy dates back to an ISTAT survey of 2005, published in 2008.<sup>1</sup> This work shows that the total absence of teeth affects 22.6 per cent of the population between 65 and 69 years, jumping to 60 per cent of those over 80 years old. Only 52.2 per cent of the subjects have replaced their missing teeth with implants. This is influenced by the fact that edentulism is prevalent among people of lower social status,



**Fig. 1:** CBCT showing iperpneumatic maxillary sinuses and low residual bone in the upper jaw. – **Fig. 2:** Inclusion of eight CAMLOG® implants after rising sinuses maxillary and bone grafts affixing vestibular bilaterally. – **Fig. 3:** Finally fixed prosthesis; small pink flanges in ceramic were sufficient to improve the support of soft tissue without compromising the ability of oral hygiene. – **Fig. 4:** Final radiograph showing bone regeneration.

# We talk Implantology

- **Easy** | Simple device setup
- **Strong** | Powerful and smooth motor
- **Reliable** | High quality finish

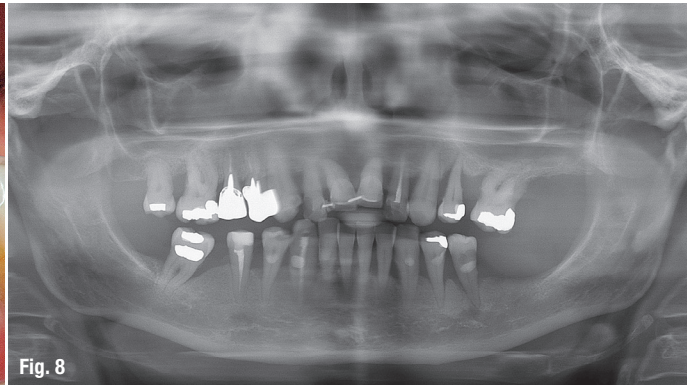
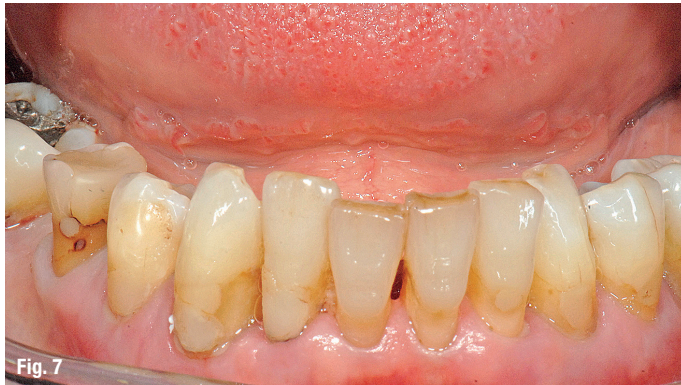
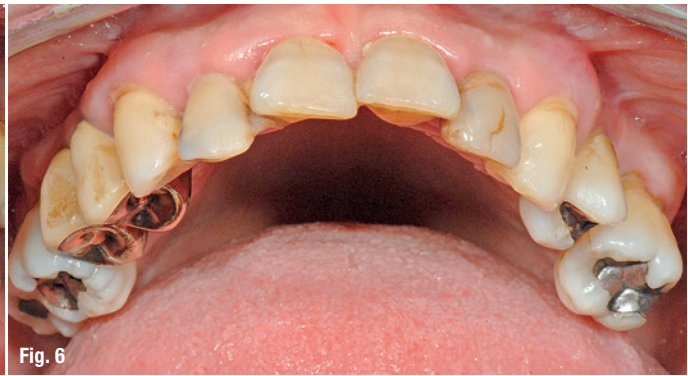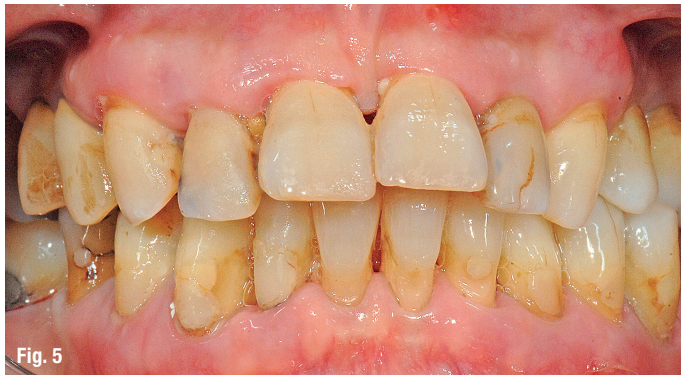Scan me to be linked to the  
NOUVAG contact form ▶▶▶



Nouvag AG  
St.Gallerstrasse 23 – 25  
CH-9403 Goldach  
Phone +41 (0)71 846 66 00  
[info@nouvag.com](mailto:info@nouvag.com)  
[www.nouvag.com](http://www.nouvag.com)





**Fig. 5:** Initial dental situation after a first professional dental hygiene.

**Fig. 6:** Upper arch.

**Fig. 7:** Lower jaw.

**Fig. 8:** Initial orthopantomography.

which therefore do not have the financial ability and/or cultural demand to replace missing teeth. In such cases, teeth have mostly been lost due to carelessness (caries and periodontitis),<sup>2,3</sup> iatrogenic damage (dental treatments not performed according the state-of-the-art),<sup>4</sup> systemic diseases such as diabetes and immunosuppression,<sup>5</sup> or incorrect lifestyle (eating habits, drug use, smoking)<sup>6</sup>.

No prosthesis is able to completely restore the chewing ability,<sup>7</sup> but anyway, life quality of patients with prosthesis is much better than in those cases who have no prosthesis<sup>8-10</sup>. In the maxilla, a high percentage of patients accept a traditional removable prosthesis, while in the lower arch this solution is extremely uncomfortable and not functional. Therefore, it is widely believed in the scientific community that the minimal functional solution in the lower jaw is the inclusion of two implants to stabilise the removable prosthesis.<sup>11-16</sup>

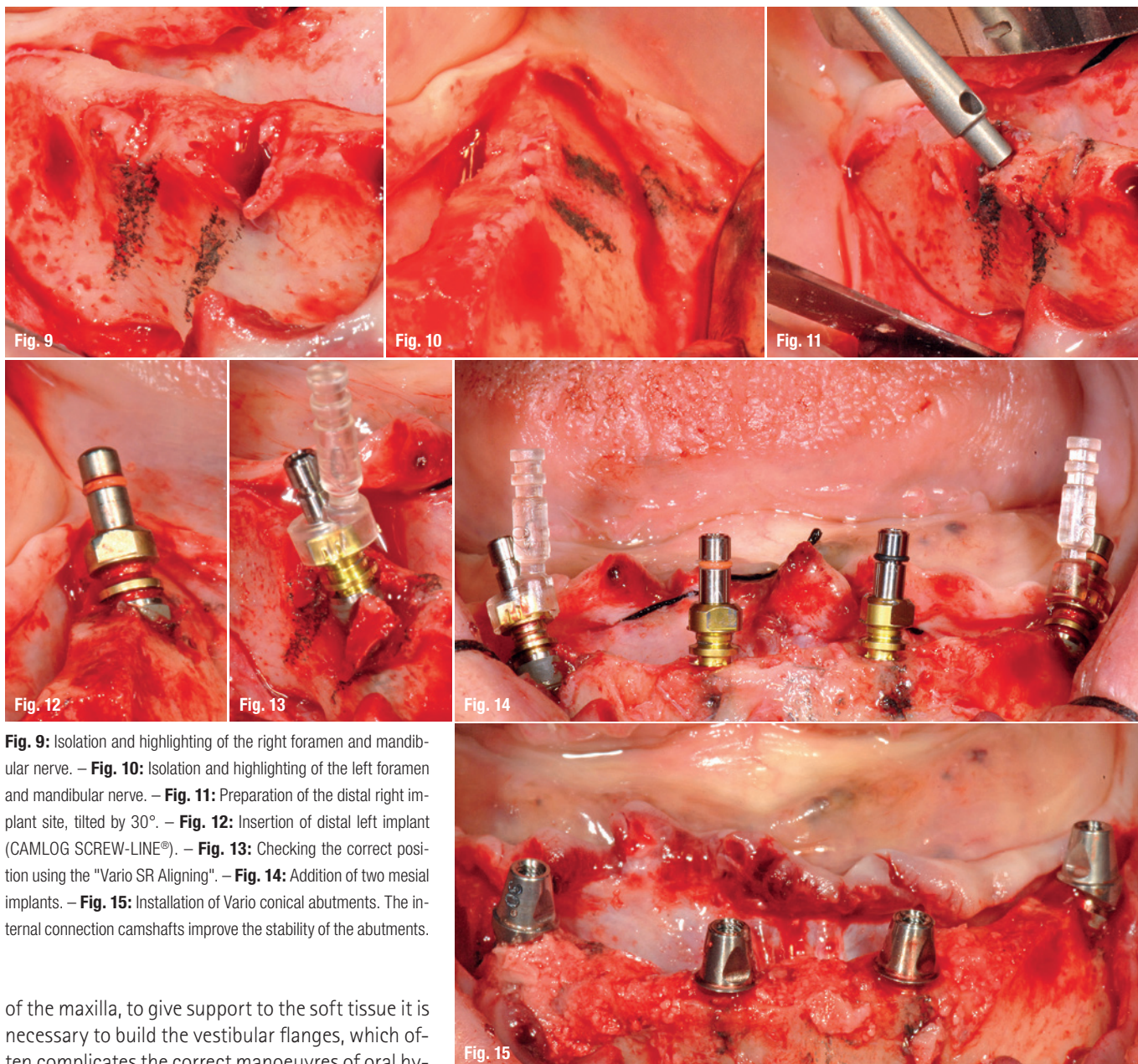
The restoration of edentulism with a fixed implant-supported prosthesis seems to be the best solution. But, especially in the upper arch, this solution is hardly feasible for insufficiency of the remaining bone, for weak support of soft tissues (lips and cheeks) and, consequently, for unsatisfying aesthetics and phonetics. These factors often require pre-implant bone reconstruction with a significant increase of time, costs and morbidity (Figs. 1-4).

The easiest and handiest way therefore seem to be overdentures stabilised by a reduced number of

implants. In the upper jaw we can sensibly limit the extent of the palate, improve the general comfort of the patient and his gustatory perception and at the same time decrease inflammatory and/or infectious mucositis.<sup>17,18</sup>

We have already reported that in the edentulous mandible the minimally accepted therapy is an overdenture stabilised by two implants.<sup>11,14</sup> The best results in terms of implant survival and prostheses outcome in the upper jaw is obtained with at least four implants bonded by a bar.<sup>19,20</sup> On the other hand, in the mandible there have not been reported differences regarding implant survival and patient comfort by inserting two or four implants bonded by a bar or using non-bonded implants (ball-attachment or locator).<sup>21</sup> Even scientific publications attested that still today the validity of a removable denture stabilised by implants<sup>22</sup> placed ten years ago were given a further opportunity to resolve total edentulism with a fixed prosthesis supported by a reduced number of implants.

Since the first publication of Maló et al.,<sup>23</sup> the systematic "All-on-4" has gained approval by operators and patients. The concept "All-on-4" allows to have a fixed denture in acrylic resin supported by only four implants of which the two distal inclined as much as possible to displace distal the prosthetic emergency; the prosthesis is screwed to the implants immediately after their placement (within 48 hours). In subsequent years, this method has been confirmed to be safe and reliable.<sup>24-26</sup> By contrast, in severe atrophy



**Fig. 9:** Isolation and highlighting of the right foramen and mandibular nerve. – **Fig. 10:** Isolation and highlighting of the left foramen and mandibular nerve. – **Fig. 11:** Preparation of the distal right implant site, tilted by 30°. – **Fig. 12:** Insertion of distal left implant (CAMLOG SCREW-LINE®). – **Fig. 13:** Checking the correct position using the "Vario SR Aligning". – **Fig. 14:** Addition of two mesial implants. – **Fig. 15:** Installation of Vario conical abutments. The internal connection camshafts improve the stability of the abutments.

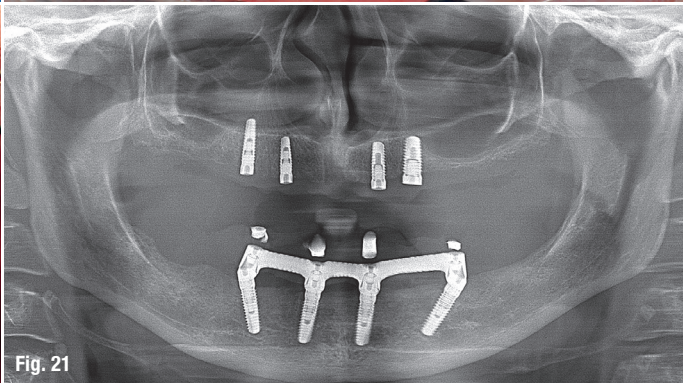
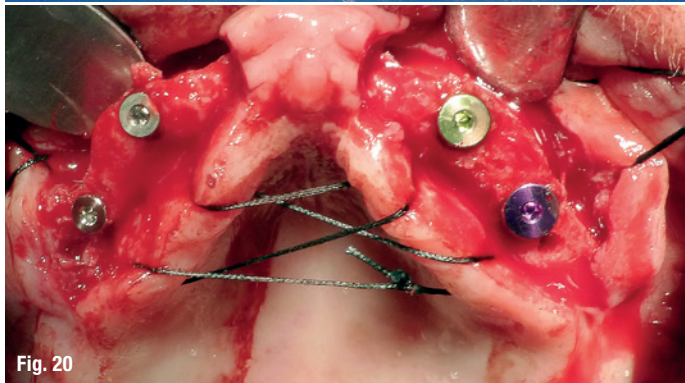
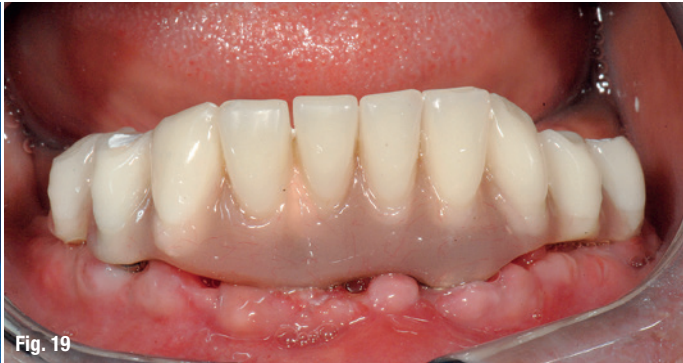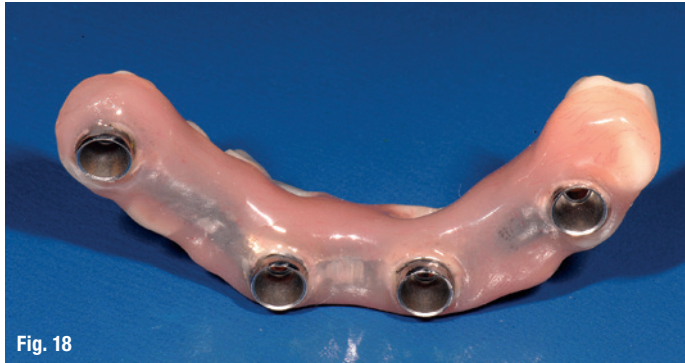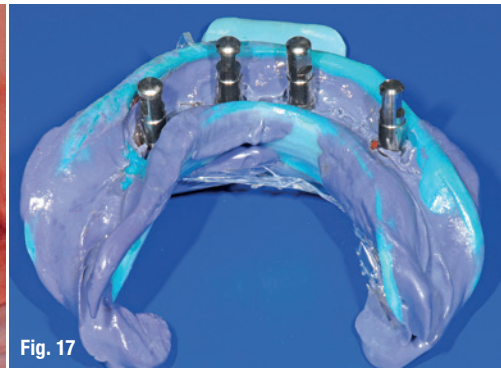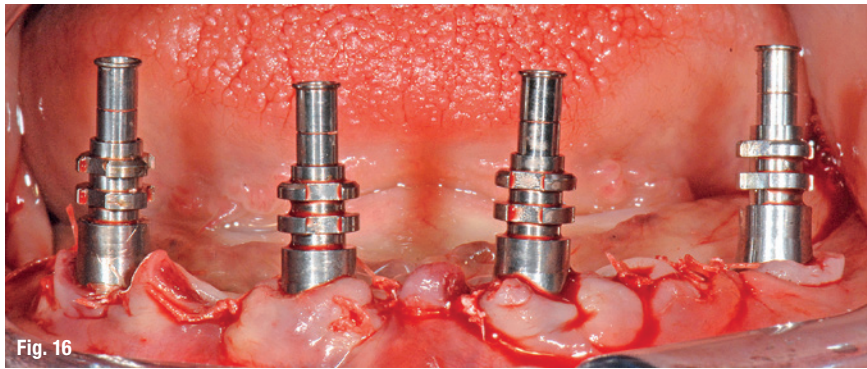
of the maxilla, to give support to the soft tissue it is necessary to build the vestibular flanges, which often complicates the correct manoeuvres of oral hygiene, since it is impossible for the patient to remove the prosthesis. There we have to keep in mind that oftentimes edentulous patients are elderly and thus their manual ability may not be sufficient to maintain a correct hygiene that ensures a positive long-term outcome.<sup>27</sup> Therefore, the "All-on-4" protocol has to be evaluated with regard to function, aesthetics and the patient's ability to properly maintain the hygiene of the prosthesis.

### Clinical case

The patient, 56 years old, has no systemic diseases but has been smoking for the last 30 years (more than 20 cigarettes per day). She reports to have a TMJ pain, tooth mobility with toothache and halitosis for several months now. The patient has a poor oral hygiene, compounded by fear of further dis-

location of the teeth while brushing, having already suffered the spontaneous loss of three molars in the months prior to her visit (Figs. 5–8). For professional reasons, the patient has close contact with the public. She thus requests for a solution in a reasonably short time, a less invasive surgery due to her phobia and less time between teeth extraction and prosthesis replacement so that she can continue her job without serious disruption.

Considering the vast bone atrophy of the maxilla, the loss of vertical dimension and the already weak lip support, I proposed an upper overdenture preceded by a removable prosthesis during the months needed for the implants to osseointegrate and a fixed prosthesis in the mandible prepared for immediate loading according to the "All-on-4" con-



**Fig. 16:** Abutments impression.  
**Fig. 17:** Detection of the impression: the four implants appear parallel thanks to the 30°-angled abutment mounted on the two distal, which compensates the inclination of the implants.  
**Fig. 18:** Temporary restoration: in transparency the stabilising bar implant. Notice the smooth surface and convex which allows easy hygiene by means of brush or floss.  
**Fig. 19:** Temporary restoration applied in the mouth.  
**Fig. 20:** Four CAMLOG SCREW-LINE® implants inserted in the maxilla.  
**Fig. 21:** Panoramic radiograph four months after implant surgery.

cept. At the same time, an accurate and professional oral hygiene was done to improve the health of the gums and the patient was instructed on proper oral hygiene at home. With the help of a doctor, she stopped smoking and changed her eating habits, which means the reduction of an excessive consumption of food as well as avoidance of acidifying and sweetened drinks.

We then proceeded with the maxilla tooth extractions and the immediate implementation of a full denture. After a few days of adaptation to the new situation, surgical and prosthetic operation for the application of the lower denture was planned. Once the teeth had been extracted, the bone ridge had been regularised and the mental foramen had been highlighted and isolated, we followed the "All-on-4" protocol by inserting two CAMLOG SCREW-LINE Promote plus® inclined distally with 30°, placed as distally as possible (Figs. 9–13) with the emergency above the foramen. Once checked the correct alignment with the "Vario SR Aligning"

device we introduced the two medial implants and the Vario abutments, which will no longer be removed (Figs. 14 & 15).

Once having sutured the wound with an absorbable wire we proceeded with the connection of the impression copings by means of a resin with a very low ratio of contraction (Figs. 16 & 17) and with the polyether impression. The occlusal indexes have been identified beforehand. In the late afternoon of the same day it was applied to the temporary prosthesis with a metal framework to grant rigidity to the implants. The prosthesis was extended up to the second premolar, with this achieving a "protection" of the distal extensions (Figs. 18 & 19). Four months after the implant positioning in the upper arch (Figs. 20 & 21) we took an optical impression for the milling of the bar. After that we took the conventional impression in order to have a good mucous adaptation of the removable prosthesis (Figs. 22–26). For the retention of the prosthesis without the palate four OT Equator® attachments were screwed on the bar.



# Membership Application Form

I hereby to apply for membership of the DGZI – German Association of Dental Implantology (Deutsche Gesellschaft für Zahnärztliche Implantologie e.V.).

Please send this form via FAX to +49 211 16970-66.

Do you have experience in implantology? (mandatory)

- Yes  No

I hereby agree to have my personal data processed for all purposes of the DGZI.

- Full membership (outside Germany)** ⇒ 125 Euro p.a.     **Assistant doctors (outside Germany)** ⇒ 60 Euro p.a.     **Students/auxiliaries (outside Germany)** ⇒ free of charge for first-degree students of dentistry

- I have transferred the annual fee to the DGZI bank account c/o Dr Rolf Vollmer:  
IBAN: DE33 5735 1030 0050 0304 36 | KSK Altenkirchen | SWIFT/BIC: MALADE51AKI

## Personal Data

..... Name	..... First Name	..... Date of birth
..... Title	..... Citizenship	
..... Street	..... City, ZIP code	..... Country
..... Phone, Country and Area code	..... Fax	
..... E-Mail	..... Homepage	
..... Special qualification	..... Spoken languages	

## Payment (by credit card)

Please use your: (Please mark as appropriate)

- Visa  MasterCard

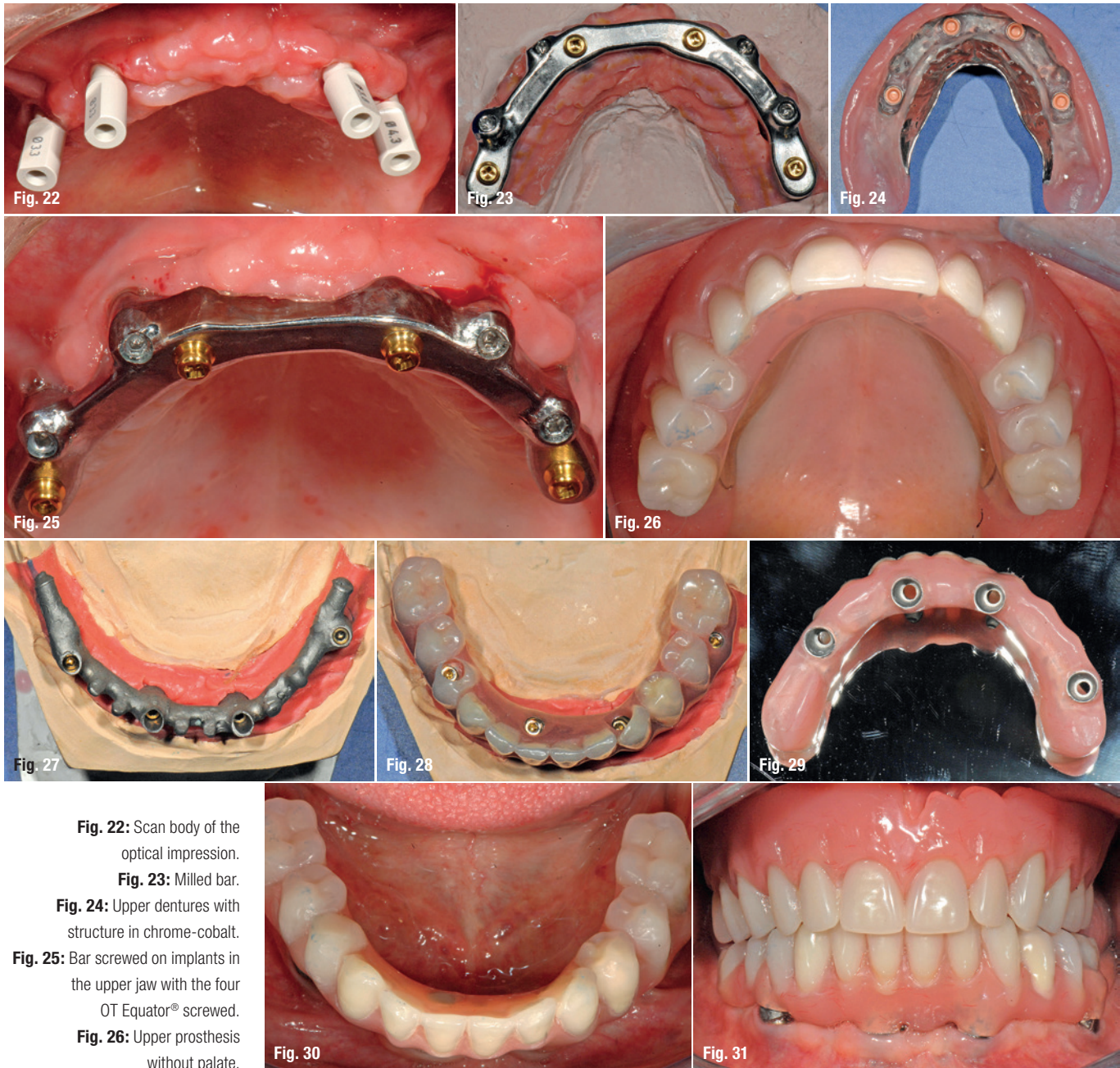..... Card holder's name	..... Card number
..... Expiry date	
..... Signature	..... Place, Date

Please complete this application form in block letters.

**FOR FURTHER INFORMATION PLEASE CONTACT**



Deutsche Gesellschaft für Zahnärztliche Implantologie e.V.  
Central Office: Paulusstraße 1, 40237 Düsseldorf, Germany  
Phone: +49 211 16970-77 | Fax: + 49 211 16970-66 | office@dgzi-info.de | www.dgzi.de



**Fig. 22:** Scan body of the optical impression.  
**Fig. 23:** Milled bar.  
**Fig. 24:** Upper dentures with structure in chrome-cobalt.  
**Fig. 25:** Bar screwed on implants in the upper jaw with the four OT Equator® screwed.  
**Fig. 26:** Upper prosthesis without palate.  
**Fig. 27:** Reinforcement bar of the mandibular permanent prosthesis.  
**Fig. 28:** Mandibular prosthesis ultimately extended to the first molar.  
**Fig. 29:** Overview of the side facing the mucosa.  
**Fig. 30:** Mandibular prosthesis screwed. The holes were closed with composite.  
**Fig. 31:** The two prosthesis in occlusion.

Seven months after insertion of the mandibular implants, we proceeded with the definitive impression of the face bow. The technician proceeded with the construction of the bar and the acrylic prosthesis with a good hygienic mucous (Figs. 27–29). The provisory prosthesis was then replaced by the definitive one with the occlusal extended to the first molar (Figs. 30&31). The support of the soft tissues provided a correct vertical dimension and also the healing of the cheilitis that affected the patient before the treatment as well as the protrusion of the lips and a mechanical lifting of the wrinkles (Figs. 32–35). The orthopantomography six months after the treatment confirms the stability of the implant restoration (Fig. 36).

**Conclusion**

Total and partial edentulism is a serious handicap for people who are affected. Edentulism is often-times a self-made problem, beginning early with a careless oral hygiene and unfavourable habits. Thus, as dentists we should encourage our patients at a very early stage of age to follow a healthy lifestyle, including personal hygiene, nutrition, physical activity and regular dental check-ups from elementary school on, involving of course the families. At the moment a person becomes edentulous however, it is our duty to try to improve the quality of his life in restoring his proper chewing function (not to further jeopardise the state of his health) and to improve his social life (not to compromise the psychological situation).

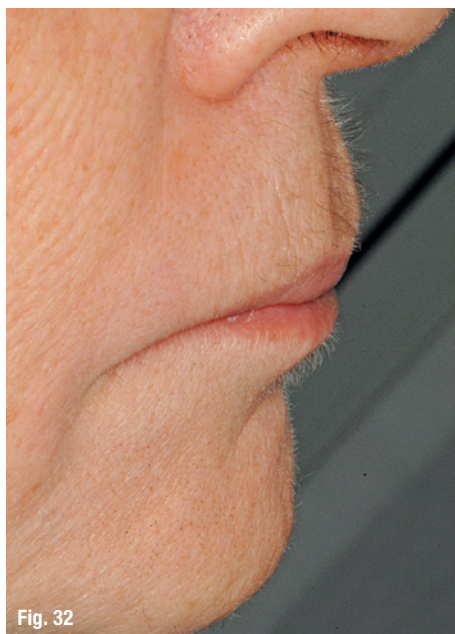

Fig. 32

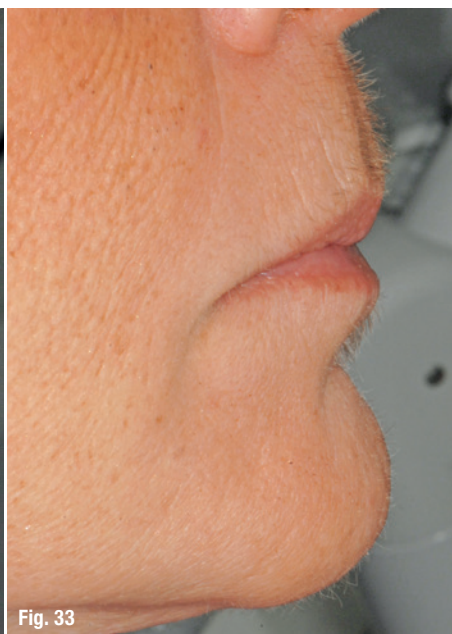

Fig. 33

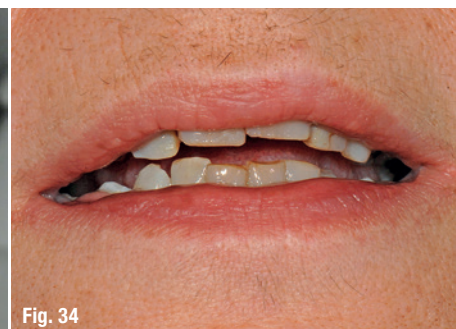

Fig. 34

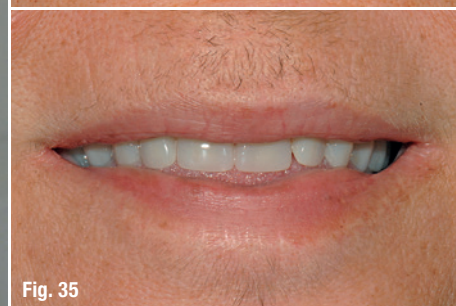

Fig. 35

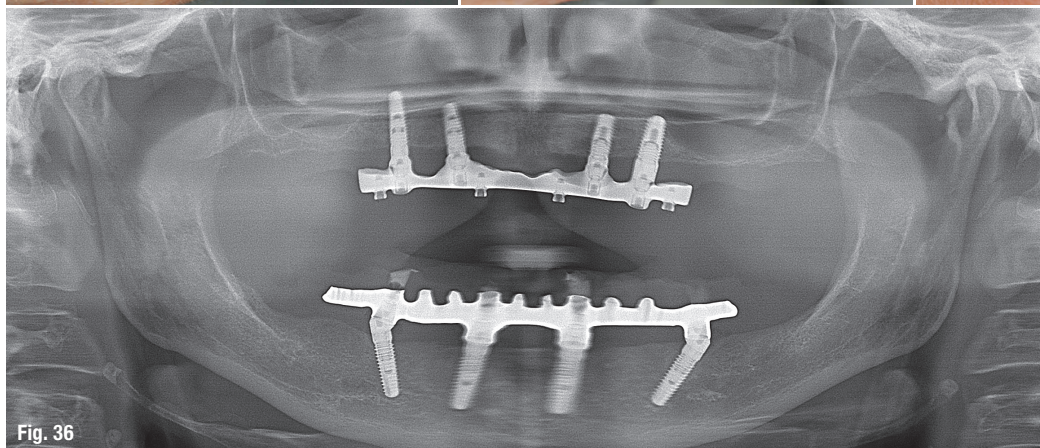


Fig. 36

**Fig. 32:** Profile of the patient before treatment: note the lack of visibility of the lip vermilion.

**Fig. 33:** Different lip support at the end of the treatment.

**Fig. 34:** Angular cheilitis at the beginning of the treatment.


**Fig. 35:** Healing at the end of the treatment and disappearance of most of the skin wrinkles.

**Fig. 36:** Orthopantomography control six months after rehabilitation.

The simple replacement of the missing teeth with a full denture may be an appropriate solution in the maxilla for many patients. But a full denture in the lower arch is absolutely incongruous because it does not allow a sufficient chewing efficiency and, because of instability due to a poor tissue support and tongue and cheek movement, often creates soreness and discomfort in social life. Therefore, it is necessary to inform people facing mandibular edentulism that they can regain comfort and masticatory function with the insertion of two implants to stabilise the prosthesis.

Definitely a big step forward in the resolution of edentulism was done with the "All-on-4" systematic, which is surgically minimally invasive, fast and economically acceptable. This solution is however not applicable in all cases, since it is necessary to have good manual skills for a correct maintenance and a proper oral hygiene; it is not always adequate from a functional and aesthetic point of view. Therefore, the solution of edentulism with an overdenture stabilised by four systems can be, especially in the maxilla, the

most appropriate therapy without having to perform a surgically invasive operation and regenerative therapy, which both are often not well accepted by patients.



contact

**Prof. Massimo Pasi**  
 Studio Medico Dentistico  
 Via Francesco D'Ovidio, 1  
 20131 Milan, Italy  
 Tel.: +39 2 70633631  
 mpasi@massimopasi.it

Author details



# Sinus elevation with short implant

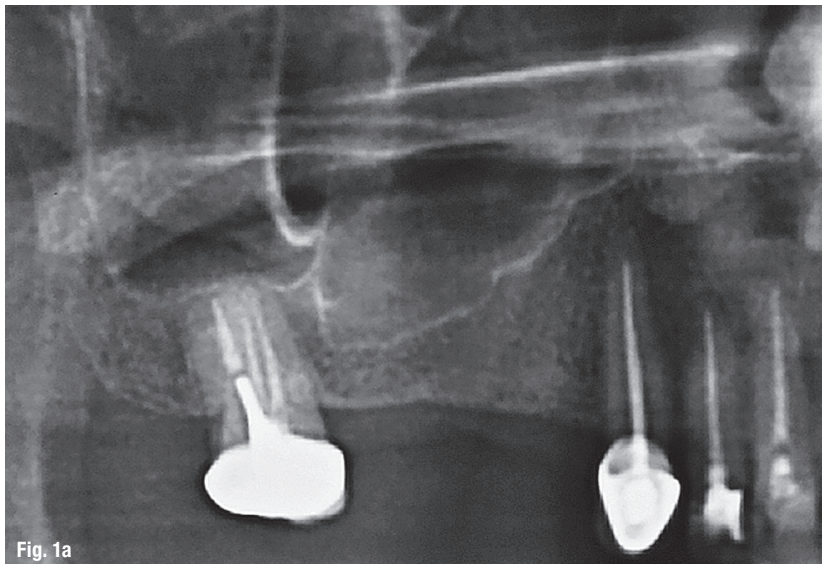
**Authors:** Prof. Dr Mauro Marincola, Prof. Dr Rolf Ewers, Prof. Giorgio Lombardo (University of Verona) & Prof. Miguel Simancas Pallares (University of Cartagena), Austria/Italy/Colombia

## Introduction

An upper posterior edentulous maxilla with diminished bone height usually represents a challenging situation for clinicians when dental implantation is the solution for tooth absence. Bone decrease is the result of a reduction in both height and width of the alveolar process due to the maxillary sinus pneumatization.<sup>1</sup>

Two main options have been proposed to lift the Schneiderian membrane and then create some space to place implants: the lateral approach that increases treatment-related costs, postoperative morbidity and also surgical time, and the osteotome sinus floor elevation (OSFE) firstly introduced in 1986 by Tatum. Then in 1994 Summers introduced the maxillary sinus lifting internal sinus lift (ISL) technique by the use of osteotomes, in which bone is added to the apical part of the implant to improve implant primary stability.<sup>2,3</sup> This technique was shown to be less invasive, less time consuming and reduces postoperative discomfort to the patient.

**Fig. 1:** Pre-operative patient assessment: X-ray of the edentulous space showing maxillary sinus pneumatization.



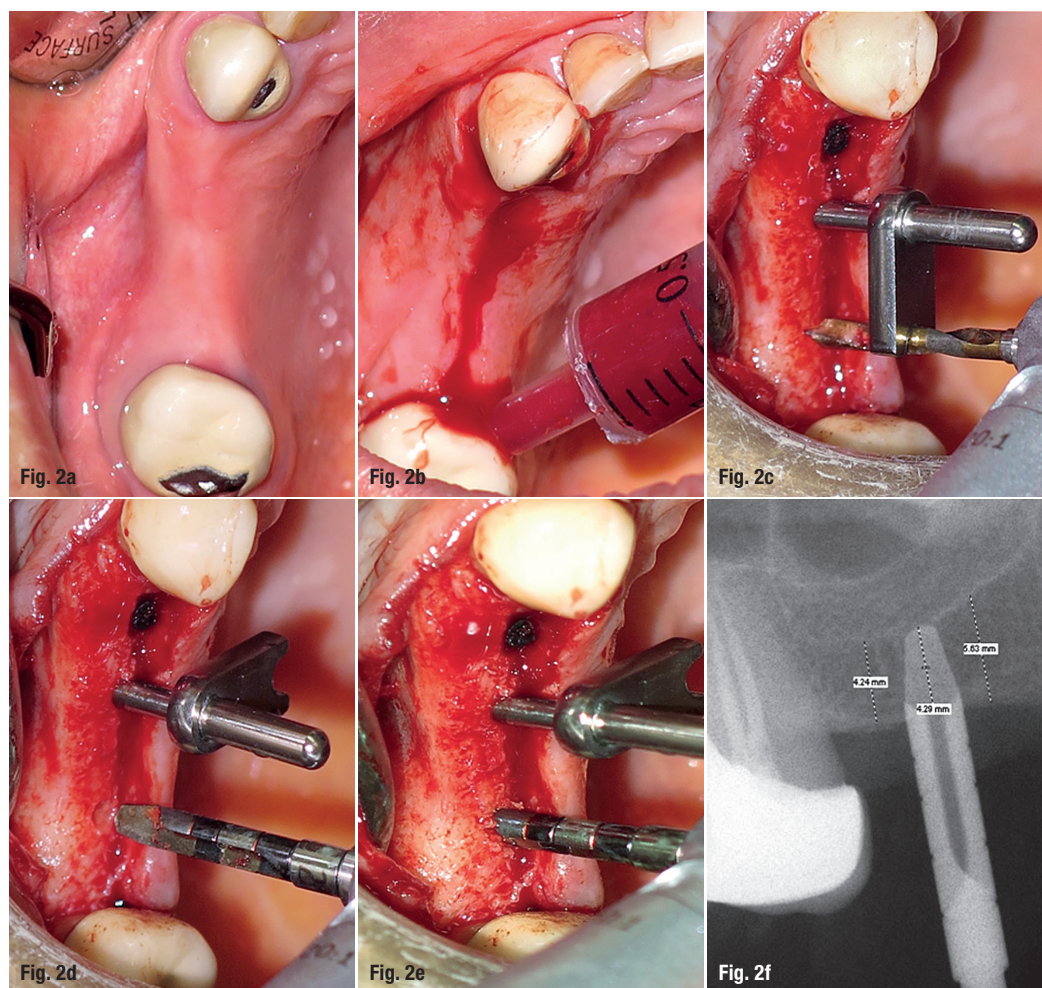
ISL is indicated when residual bone height (RBH) is between 5 and 7 mm. Other authors perform ISL in RBH extreme conditions such as  $\leq 4$  mm.<sup>4</sup>

There's an increasing debate whether a bone graft is needed into the elevated area to maintain the space for new bone formation in the future. According to Summers' original report, autogenous, allogenic or xenogeneic grafting materials are often placed.<sup>5</sup> Recently Nedir et al. showed no differences ( $P > 0.05$ ) between ISL procedures performed with or without bone graft on the apical portion.<sup>6</sup> However, the main clinical challenge arises when a bone graft is placed and the bone around the implant-abutment interface needs to be maintained.

Rammelsberg et al. performed ISL but without bone graft in a retrospective study in 66 patients with 101 dental implants in 2015. By using X-rays, they determined bone changes over the time.<sup>7</sup> They further obtained results that mesial and distal mean apical bone gain (initial-final bone height) were 0.5 mm and 0.4 mm respectively, thus recommending that implants placed in combination with ISL without graft material would have bone gain.

Likewise, Nedir et al. compared dental implants plus ISL placed in combination with and without bone graft in 2013. They concluded that, although more bone is observed when the grafting material is used (5 mm) in comparison with non-grafted sites (3 mm,  $P < 0.05$ ), this may not be required to promote endo-sinus gain.

Although there's no consensus whether bone graft should be placed via ISL procedure or not, this option is highly recommended due to the benefits regarding osseous level maintenance. The aim of this study was to describe radiographic parameters of minimally-invasive internal sinus elevation in combination with plateau-form short implants. Thus this paper is intended to describe the surgical technique



**Fig. 2:** Description of the surgical procedure: **a)** clinical condition of the alveolar ridge that shows the edentulous area of teeth 14, 15 and 16 prior the beginning of the surgical procedure; **b)** crestal incision and blood collection with a sterile syringe for further bone graft; **c)** pilot drilling at the site of dental implantation with simultaneous ISL; **d)** 2.5 mm latch reamer with no cutting edge to start osteotomy widening at the crestal bone; **e)** 2.5 mm latch reamer perforation in the bone starting the osseous widening; **f)** X-ray showing RBH (4.24 mm) and also 2.5 mm latch reamer insertion into the bone (4.29 mm).

of a predictable procedure we developed during our 20 years of practical hands-on training with students and course participants.

## Case report

A female 58-year-old patient consulted us because of her desire of functional and aesthetic repairment. The patient did not relate any medical background of clinical interest. She also signed informed consent prior the beginning of study, held ASA I status and required dental implantation in the upper posterior maxilla with at least 4 mm on RBH and measured through a digital periapical radiograph by a single operator calibrated for this (Intraclass Correlation Coefficient: 0.83).

Amoxicillin 500 mg was prescribed to the patient two days prior the surgical procedure, once every eight hours in order to avoid infections. Surgical procedure was performed by a different trained clinician with more than 25 years of experience in the field.

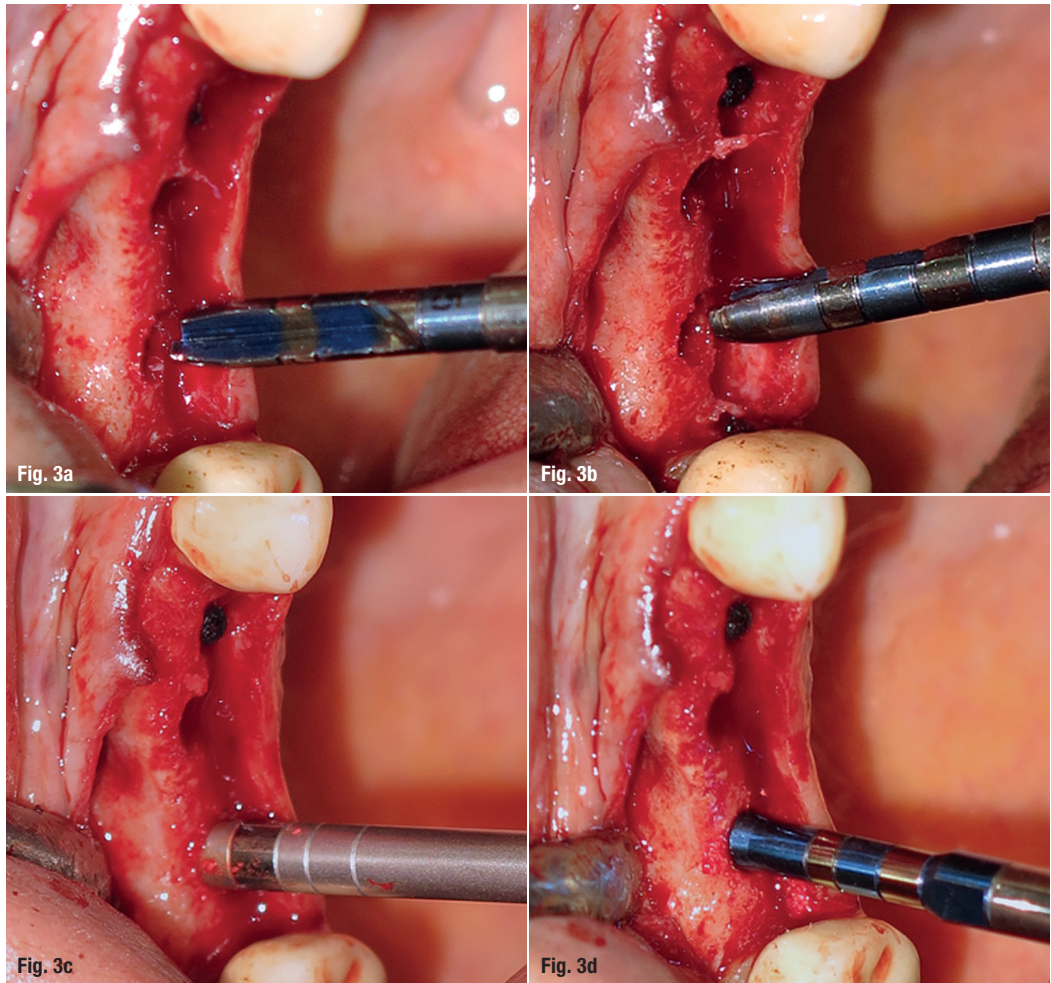
## Surgical Technique

Infiltrative anaesthesia was used in the procedure. Initially, a non-epinephrine anaesthesia was used

(PRICANEST 4%, Ropsohn Therapeutics, Bogotá, Colombia) in order to collect blood (Fig. 2b) to mix with the grafting material (50–500  $\mu$ m Synthograft, Bicon Dental Implants, Boston, USA). Then 2% Xylocaine (Dentsply Pharmaceutical, York, USA) was used to complete the surgical procedure.

Intrasulcular incision was performed by using a size 15 blade in a Bard-Parker scalpel. Full thickness flap was obtained in the area and then a previously published protocol<sup>8</sup> was followed to perform ISL: pilot (2 mm diameter) drilling to achieve cortical perforation was started. Pilot drilling length (1–2 mm) was determined upon residual bone height prior measurement (Fig. 1b). This high-speed 1,100 rpm drill is used with external water irrigation and has a cutting edge at the apical portion. The pilot osteotomy should be 1 to 2 mm shorter than the calculated RBH measured on the periapical xR. The following steps are achieved with latch reamers at 50 rpm without water irrigation. The reamer consists of two vertical cutting edges, which stops 2 mm before the apical portion. The apex is tapered and without a cutting edge to avoid Schneiderian membrane perforation. A 2.5 mm latch (mechanical) reamer was inserted to start the widening of the crestal cortical bone and to deepen

**Fig. 3:** Microfracture points along the cortical zone performed with the 3.5 mm hand reamer. **a)** First microfracture at distal, **b)** third microfracture at buccal and the fourth microfracture was performed at distal. **c)** Clinical picture of the grafting material being injected and **d)** the 3.5 mm osteotome first insertion into the cavity.



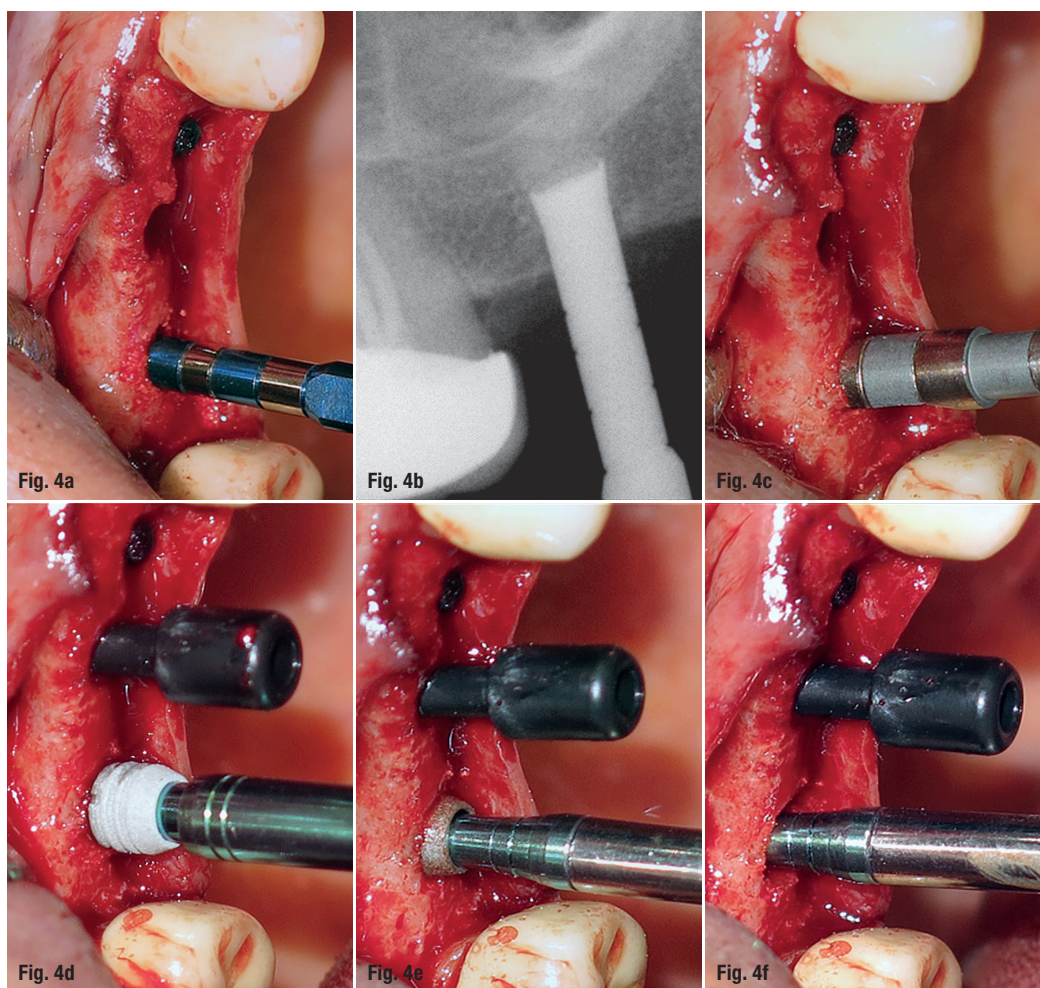
the bur with finger pressure towards the cortical bone of the sinus floor. The pressure allows the non-cutting edge to be pressed through the smooth cancellous bone but stops at the hard tissue of the sinus floor (Fig. 2d). With this 2.5 mm latch reamer, an X-ray was taken to determine the reaming final length before sinus floor (Fig. 2f). The RBH was measured to determine the final drilling length and the latch reamer series with 0.5 mm diameter improvement were inserted until the 4.5 mm implant diameter was reached.

The following step describes the microfracture technique of the sinus floor. With the 3.5 mm hand reamer that has a single vertical cutting edge and ends with a knife-edge at the apex of the reamer, we tapped the sharp tip of the hand reamer at four different points along the buccopalatal and mesiodistal axis to facilitate the microfracture of the sinus floor cortical bone. The first fracture point was the lowest RBH on the periapical. We started the fracture at the distal aspect of the osteotomy (Fig. 3a). The second and fourth fracture points are always the buccal (Fig. 3b) and the palatal because of their higher pneumatisation towards the buckle. The third point in this case is the mesial aspect.

A synthetic and bacteriostatic grafting material (Synthograft,  $\beta$ -TCP, size 50–500  $\mu$ m) was mixed with the collected blood until getting a putty consistency and no liquid was obvious in the mixture. A 4.0 mm bone graft syringe was used to place a bone graft material into the apical portion of the osteotomy (Figs. 3c). Once resistance against the Schneiderian membrane was detected, a slow retraction of the syringe while continuously injecting was done. After bone graft material was injected, a 3.5 mm Summer osteotome was used to gently push the material into the osteotomy. With the graft material in place, the osteotome was advanced via gentle tapping until the cortical bone was fully fractured, and lifted with the sinus mucosa (Figs. 3d, 4a–c).

A 4.5 x 6.0 mm Implant (Bicon Dental Implants, Boston, USA) was inserted into the grafted osteotomy using first an implant inserter and retriever mounted in a straight handle and then by gently tapping with a seating tip (Figs. 4d–f).

If the remaining RBH is more than 3 mm, the first plateaus following the sloping shoulder will be engaged against the osteotomy walls and this press fit implant will not move during the healing because a



**Fig. 4:** **a)** The 3.5 mm osteotome inserted into the osteotomy pushing the material against the Schneiderian membrane; **b)** X-ray image showing the 3.5 mm osteotome position and also the grafting material; **c)** 4 mm osteotome performing the green stick fracture; **d-f)** implant insertion into the osteotomy with the straight handle and the 3 mm seating tip.

primary stability is achieved. When a RBH  $\leq 3$  mm is present, a sinus lift abutment (Bicon Dental Implants, Boston, USA) needs to be placed in order to avoid implant displacement into the lifted sinus. This implant design will not have a primary stability along the osteotomy walls because it is placed 2 mm under the crest and the implant body would be fully immersed into the grafting material. Plateau-formed implants with healing chambers between the plateaus do not need a primary stability but the internal sinus abutment stabilises the implant into its final prosthetic position. Single suture with polyglycolic acid (PGA) was used to close the mesial and distal relieving incisions (ACE Surgical Supply CO, Brockton, USA). After implant insertion, immediate post-op X-ray was performed (Fig. 5). The Patient received post-op instructions and homecare instructions. Antibiotics (Amoxicillin) and analgesics (Nimesulide) were prescribed to avoid infections and pain/swelling.

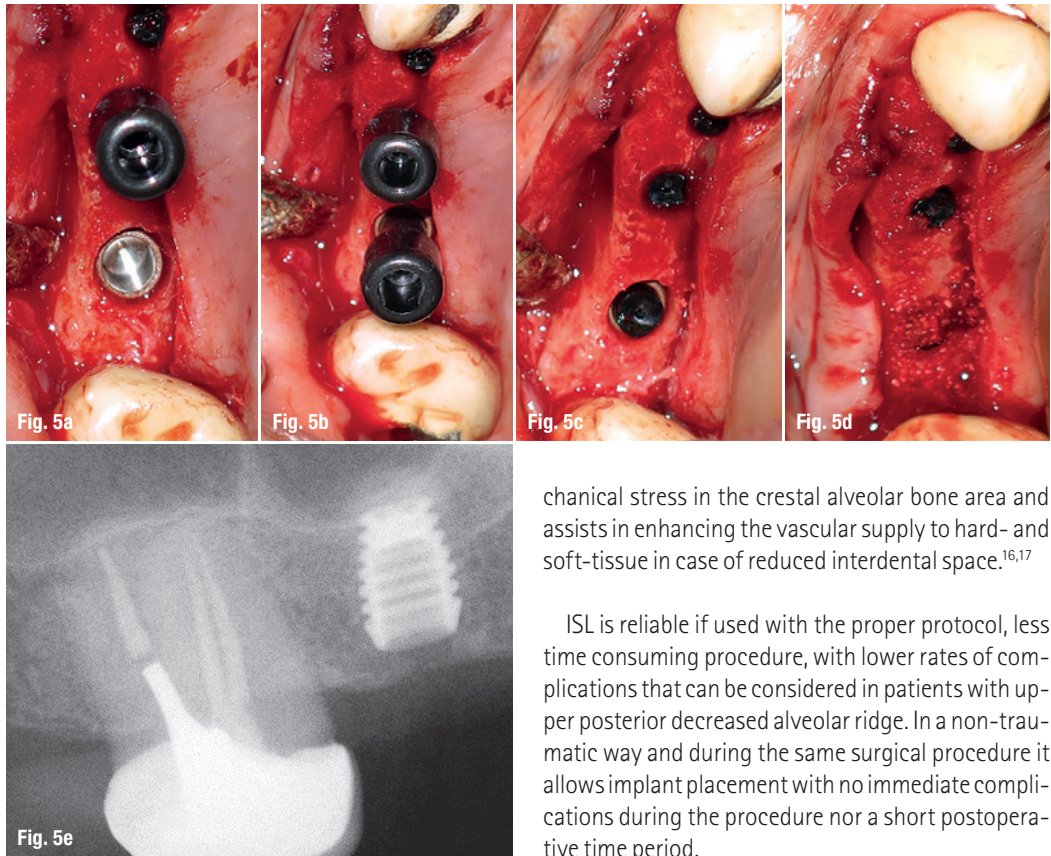
## Discussion

Dental implantation is still the most effective approach to replace a missing tooth due to the observed survival rates over the time. However, some-

times the anatomic conditions could restrict implant positioning into the ideal space, thus limiting the prosthetic options.<sup>9</sup> Maxillary sinus pneumatization occurs as the result of the upper posterior tooth loss. As a consequence, internal sinus lift (ISL) has been documented as one of the surgical approaches to accomplish implant placement in the same surgical procedure.<sup>10</sup> Results of this case report suggest that ISL and simultaneous implantation were successfully performed on the patient with no intraoperative or early postoperative complications.

The employment of sinus grafting in conjunction with the ISL procedure is still open to debate. According to Summers' recommendation, autogenous, allogenic or xenogenic grafting materials are often inserted into the elevated area to maintain the space for new bone formation. Moreover, several studies have suggested that the Schneiderian membrane elevation by itself promotes bone regeneration by means of the formation of a fibrin clot in the created space. This clot, which is stabilised and protected from external trauma and intra-sinus pressure, would have the potential to stimulate bone formation.<sup>11,12</sup> However, this option is highly susceptible to membrane perforation or membrane invagination around the implant apex.

**Fig. 5:** **a)** Clinical picture showing the implant position after its placement via gentle tapping; **b)** placed implant with the healing plug; **c)** cutted view of the healing plug for the placed implants in the zone; **d)** autologous bone graft over the implant with the collected bone during the osteotomy; **e)** immediate final X-ray views of the placed implant together the internal sinus lifts procedure. On the apical portion of the implant the grafting material is observable.



chanical stress in the crestal alveolar bone area and assists in enhancing the vascular supply to hard- and soft-tissue in case of reduced interdental space.<sup>16,17</sup>

ISL is reliable if used with the proper protocol, less time consuming procedure, with lower rates of complications that can be considered in patients with upper posterior decreased alveolar ridge. In a non-traumatic way and during the same surgical procedure it allows implant placement with no immediate complications during the procedure nor a short postoperative time period.


We then decided to use pure-phase tricalcium phosphate, a synthetic material into the created space to avoid the collapse of the Schneiderian membrane around the internal sinus implant portion and promote bone formation during the osseointegration period also around the implant apex.

Associated complications with the sinus augmentation procedures are well described in the literature. The most common complication is membrane perforation during procedure and its prevalence is between 7 and 44%. Haemorrhage, infection and rhinosinusitis are also described as expected complications.<sup>13</sup> However, none of them were present in our patient, indicating an immediately successful surgical procedure which was specially developed for clinicians with no experience in sinus lift elevation.

Implant survival placed in conjunction with ISL has been also well reported in the literature ranging from 94% to 100%.<sup>14,15</sup> Nevertheless, the most critical issue is the crestal bone level maintenance over the time. This is achieved by placing the implant in a subcrestal (submerged) fashion and by the usage of an implant with convergent crest module, represented by the sloping shoulder geometry, which enhances the platform switching (PS) to occur. This PS allows an increase in residual crestal alveolar bone volume around the neck of the implant, repositions the papilla to a more aesthetic and apposite level, reduces me-

*Conflict of interest statement: Authors declare they do not have any conflict of interest.*

*Source of funding: None*



**contact**

**Miguel Simancas Pallares**

Avenue Del Consulado 48-152  
 University of Cartagena  
 Health Sciences Campus  
 Faculty of Dentistry, Research Department, Suite 301  
 Cra. 6 #36, Cartagena, Bolívar, Colombia  
 Tel.: +57 5 6698172-110  
 msimancasp@unicartagena.edu.co



## THE SELF-ALIGNING OT EQUATOR HOUSING

Metal to metal rotational core

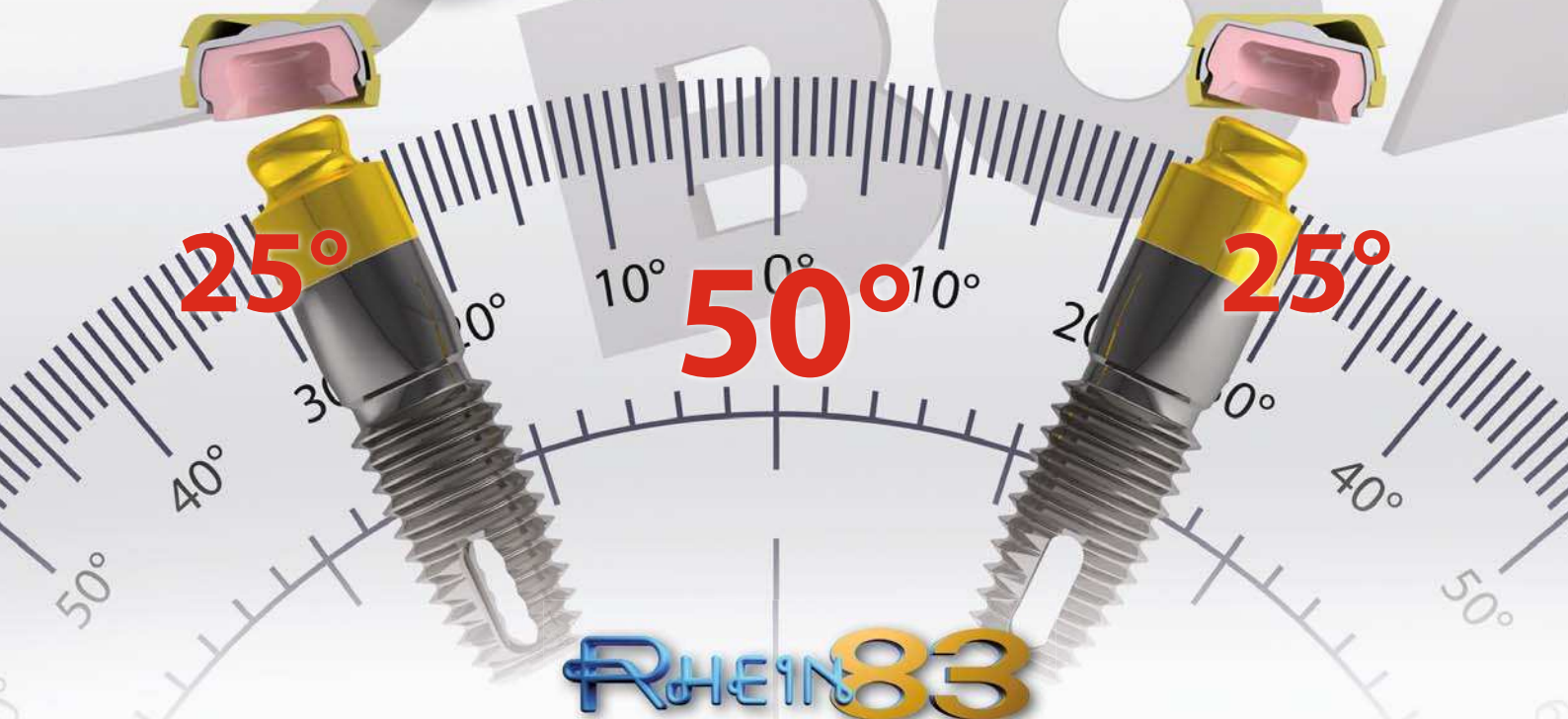Titanium housing with TiN coating

Titanium liner

Elastic Cap

Passive insertion  
reduces trauma

Correct divergency  
up to 50°



# Augmentation and defect filling in oral surgery

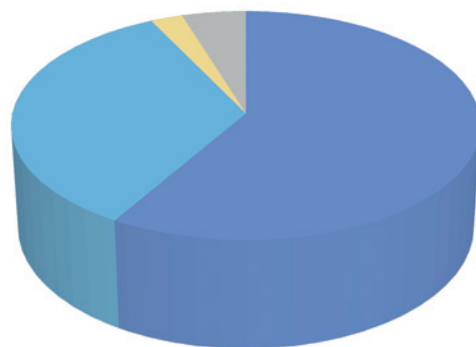
## A multicentre non-interventional study

**Author:** Henriette Lerner, Germany

### Introduction

There is considerable demand for bone replacement and augmentation materials in the field of dental medicine, especially in oral and maxillofacial surgery. A wide variety of biological and synthetic replacement materials is now available. In recent years synthetic substances containing calcium and phosphate have been developed. These require minimal effort, present no practical problems and can be used efficiently and economically. They are usually accepted by the body without problems; their tissue tolerability is excellent and they are neither locally nor systemically toxic. Unlike materials of biological origin they do not pose any risk of infection or sensitisation. In all cases it is of course necessary to take into account the individual hard tissue situation at the site at which bone regeneration material is to be used. A product that is easy to apply is especially useful for filling smaller defects; CERASORB® Paste, which has been available for some time, is such a product.

### Tolerability (n = 41)



**Fig. 1:** Overall assessment of tolerability by the dentist carrying out treatment.

■ very good  
■ good  
■ satisfactory  
■ unsatisfactory  
■ no answer

The aim was to perform a non-interventional study to evaluate its use by as many independent users as possible; handling and usefulness were to be studied in different oral surgical indications under everyday conditions in different dental practices.

### Material and methodology

An account is given of experience with the use of the  $\beta$ -tricalcium phosphate preparation CERASORB® Paste within a multicentre study. It was intended that dental practices throughout Germany, independent from one another, participate. Goal and methods were defined in an observation plan to ensure that the procedure was consistent. All results were entered on prepared recording sheets. Because of the non-interventional nature of this study, no particular therapeutic or application plan was imposed; users were instead referred to the instructions given in the information for use. Patients aged between 18 and 70 years with the following pre-operative diagnoses or indications were to be enrolled in the study:

- alveolar defect
- apicoectomy
- preparation of implant bed
- post exstirpational cyst filling
- internal sinus lift
- periodontal pocket
- further indications equivalent to those already mentioned

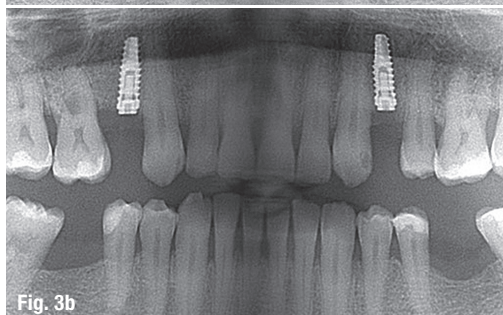
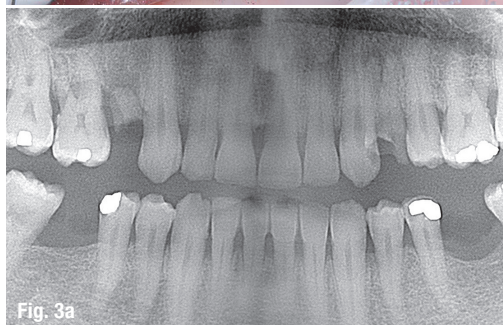
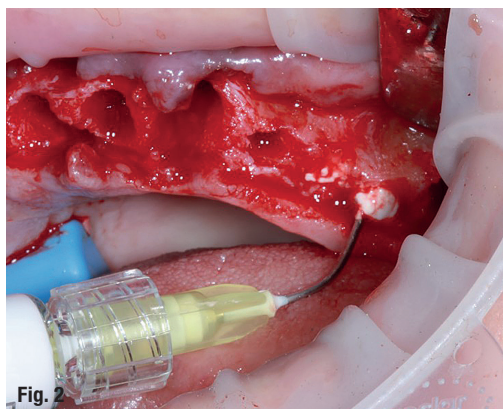
Patients were not to be included in the study if they were unsuitable for bone regeneration procedures because of general medical exclusion criteria or local inflammation in the surgical area, or if they regularly took medication that could influence wound healing (such as cortisone preparations and immunosuppressants).

**Tab. 1: Pre-operative diagnoses**

Pre-operative diagnosis	Number (n = 41)
Apicoectomy	7
Cyst	6
Periodontitis/periimplantitis	6
Bone defect	4
Augmentation for implantation	4
Filling of alveolar sockets after extraction	3
Tooth loosening/implant loosening	2
Intrabony pocket	2
Augmentation for implantation	2
Tooth not worth maintaining	2
Implant loss	1
Incomplete root canal filling	1
Bone sequestrum	1

The subject of the study was CERASORB® Paste (curasan AG, Kleinostheim, Germany), a three-phase bone regeneration material in paste form containing powdered  $\beta$ -TCP in a matrix of hyaluronic acid and methyl cellulose; it is based on CERASORB®, a well-known product that has been in use for many years. During the process of manufacturing  $\beta$ -TCP, CERASORB® ceramic particles with an average size of 63  $\mu$ m are created by sintering and grinding. These are mixed with an aqueous polymer solution in the ratio (by weight) 70% ceramics and 30% polymer solution. When using this product, as in all augmentation procedures, it is important to ensure that all soft tissue is completely removed so that it is possible for the paste to make direct contact with bone; in the process heavy bleeding should be stopped to make it possible for the material to adhere well to the bone.

After history-taking and an initial examination (documented with X-ray images if possible) with explanation of the procedure and consent to the operation, records were made of the treatment and follow-up examinations that had been performed; follow-up examinations were carried out one to two weeks postoperatively, after three, six and twelve months and later if necessary depending on the

**Fig. 2:** Application of CERASORB® Paste in an extraction socket.

**Fig. 3a:** Case example. Patient: HM, male, 51 years, remainder of teeth 14 and 24. Orthopantomograph (OPG) of initial state, extraction and filling of sockets with paste on 18 November 2014.

**Fig. 3b:** Implantation on both sides on 1 April 2015, postoperative OPG four and a half months after augmentation with CERASORB® Paste and placement of two implants.

healing and bone-regeneration process. The dentist carrying out the treatment was responsible for deciding when and how frequently follow-up examinations occurred. When explaining the procedure to the patient it is not necessary to mention the possible complications of bone harvesting, or problems relating to rejection reactions and potential risk of allergic sensitisation and infection, as is the case with biological materials.

Parameters for judging successful bone healing with CERASORB® Paste ("effectiveness parameters"):

- bone structure as seen in follow-up X-rays
- current clinical status (such as state of mucous membranes, suture dehiscence)
- bone situation at implantation
- global evaluation of effectiveness/therapeutic success by the dentist carrying out treatment
- cases in which treatment was terminated or changed because of lack of effectiveness

After the study had been completed, the recording sheets were examined centrally to check completeness and subjected to quality control. After double

**Tab. 2: Treated sites/frequencies: (n = 77 in 41 patients)**

1 <sup>st</sup> quadrant	2 <sup>nd</sup> quadrant	3 <sup>rd</sup> quadrant	4 <sup>th</sup> quadrant
11–2	21–5	31–0	41–1
12–4	22–2	32–0	42–0
13–1	23–3	33–0	43–0
<b>14–6</b>	<b>24–7</b>	34–1	44–2
15–3	25–4	35–2	45–1
16–4	26–5	<b>36–5</b>	<b>46–5</b>
17–4	27–4	37–3	47–1
18–2	28–0	38–0	48–0

□ = 26 (33.77%)   □ = 30 (38.96%)   □ = 11 (14.28%)   □ = 10 (12.99%)

data entry a purely descriptive evaluation was carried out as is usual for studies of this kind.

**Results**

Altogether twelve dental practices and dental surgery practices from all over Germany took part. The observation period (from the first treatment day of the first patient to the last treatment day of the last patient) extended from August 2013 to June 2015. It was possible to evaluate recording sheets on 41 patients (19 female, 22 male) aged 22 to 74 years (mean age: 55.2 years, median age: 57 years). Patients with certification of appropriate pre-operative diagnoses or indications were included in the study. In the process it became apparent that CERASORB® Paste was used with very different diagnoses in daily routine work:

A total of 23 concomitant illnesses in 16 patients were reported. The most frequent were hypertension in six patients, allergic reactions in four patients and

tinnitus, rheumatism and Tension Neck Syndrome in two patients each. Four participants were smokers. Six patients were taking nine different medications altogether, the most frequent being 100mg aspirin in three cases. Augmentation or defect filling was carried out at a total of 77 sites in the 41 patients (Table 2).

CERASORB® Paste was most often used in 1 ml volumes (n=31 patients [76%]) (range: 0.5–3.0 ml). In none of the cases was autologous cancellous bone mixed in. Twenty membranes were used in 18 cases (19 resorbable, one non-resorbable). Complete primary wound closure was achieved in 36 cases.

Antibiotics were applied in 24 cases (58%), only pre-operatively in five patients and only postoperatively in 19 patients. The most frequently-used antibiotics were clindamycin (in 20 patients) and amoxicillin (n = 2). They were taken for a duration of five to ten days, the mean and most frequent duration being ten days. The surgical operations and postoperative periods were free from complications.

At the clinical follow-up examination performed one to two weeks after the operation, an evaluation was made of the state of the membranes, the extent of inflammation and patient compliance. The soft-tissue healing was classified as very good or good in 93% of cases (Table 3). The membrane situation was also classed as very good in 36% of cases and as good in 51%. These results were certainly also due to good patient compliance.

26 patients (= 63%) indicated that they rinsed regularly; this was done by far the most frequently (in 18 cases) with chlorhexidine. It was suggested to the dentists carrying out the treatment that clinical evaluations of the progress and success of new bone formation (by comparison with the initial state on the day of the operation) should be made after about three, six, nine and twelve months. Analysis of the results revealed undisturbed healing and a continual decrease in the amount of synthetic bone regeneration material

**Tab. 3: Follow-up examination after one to two weeks**

	Number				Mean(1–3)
	Very good (1)	Good (2)	Satisfactory (3)	No answer	
<b>Evaluation of soft-tissue healing [n=41 patients]:</b>	24 (59%)	14 (34%)	3 (7%)		1.48
<b>Evaluation of membrane [n=18 patients]:</b>	6 (33.3%)	11 (61.1%)	0	1 (5.6%)	1.64

with time. After twelve months, bone regeneration material was still visible in five patients (12.2%). Abnormalities were reported in four patients: in two cases, seromas were found at the three-month examination. At the follow-up operation which was necessary, neither augmentation material nor newly-formed bone was found. Augmentation was therefore repeated. After six months, one patient did not have the necessary primary stability for the planned implant. After nine months, another patient showed radiolucency following placement of two implants at #35 and #37. It was found that, in the vast majority of cases, the treatment was complete after a little more than six months; the defects in the above-mentioned patients also healed somewhat later without problems.

The dentist carrying out the treatment then gave a final summarising assessment of the success of the treatment and the tolerability of the materials used. This assessment was made at the last observation point/last appointment of the patient at the dental practice in each case. If the "very good" and "good" judgements are added together, the results for effectiveness are almost 80% and for tolerability are over 90% (see Table 4, final evaluation of the defect filling/augmentation).

Handling and healing were also judged to be very good or good in most cases. The rate of complications can be considered low and not abnormal; it decreased continually with time.

## Discussion

In the first few years after the introduction of  $\beta$ -TCP CERASORB®, many users still tended to mix this bioceramic product with autologous bone before using it. This became progressively less common because of all the positive experience gained from using the product on its own. As long ago as 2000, Szucs and colleagues reported that, in 52 patients with different dental or surgical indications, the implanted  $\beta$ -TCP had been completely transformed into bone within twelve months and that bone tissue stable enough to hold implants had formed within four to six months.<sup>1</sup> They came to the conclusion that it is not necessary to use autologous bone for a sinus lift or the filling of cysts because CERASORB® alone has shown itself

to be a suitable material for these applications. These results are supported by many publications including Hoch, Palti, Foitzik et al., Basa et al., Horch et al., Szabo et al. and Schermer.<sup>2-10</sup>

While the use of  $\beta$ -TCP to fill bone defects is now accepted, the need to use membranes in association with augmentation procedures is still controversial. In smaller procedures, where the mucous membranes are in good condition and the wound has been closed without tension, it may not be necessary to use a membrane. Appropriate membranes should be used if wound dehiscence occurs, or is to be expected, and whenever additional protection seems helpful for undisturbed bone regeneration. Both resorbable (e.g. Osgide®) and non-resorbable membranes (e.g. PTFE membrane) are available depending on the indication and the aim of treatment. When choosing a membrane it is crucial that the indication and the technology are suitable for each other. Although the use of synthetic materials based on  $\beta$ -TCP can now be considered established, the "granular" form of the product was repeatedly criticised; this led to the development of products that were easier to handle and more user-friendly. CERASORB® Paste—the subject of this study—was developed to fill smaller defects. The main properties of this product can be summarised as follows. It is based on CERASORB® M Granules with their interconnecting pore system, which have been optimised in over 15 years of clinical use and serve as a mechanical framework for the formation of new bone. Parallely to the formation of new bone, the granular material is completely absorbed. Because of its entirely synthetic manufacture there is no risk of the immune reactions and infections that can occur with donor material of human or animal origin.

The paste can be completely and accurately applied directly from the sterile pre-filled syringe to fill small bone defects. The syringe also makes it possible to use the material effectively in sites that are hard to reach. After complete filling of the defect the paste maintains optimal contact with the surrounding healthy bone. The hydrogel does harden during and after application. This means that the paste keeps its long-term plasticity when in the defect and its volume remains stable; it can fill the defect completely so that it is flush with the edge. After

**visio.lign®**

**BioHPP**

**BioHPP SKYonics elegance**

**SKYonics**  
IMPLANTOLOGY MEETS BIONICS

**The one-time therapy**

Prof. Dr. José Eduardo Maté Sánchez de M...

Train the bone – save the tissue with hybrid abutments made of titanium and BioHPP®. Immediate restoration without abutment change.

- Perfect soft tissue attachment
- Natural colour
- Increase profit

Call (+49) 0 73 09 / 8 72-4 41 to get more information about the indications and the versatility of the SKY® fast & fixed therapy.

**SKY**  
IMPLANT SYSTEM



**Tab. 4: Final evaluation of defect filling/augmentation**

Pre-operative diagnosis	Bone augmentation/ regeneration (n = 41)	Tolerability (n = 41)
Very good	21 (51.2%)	24 (34.2%)
Good	11 (26.8%)	14 (58.5%)
Satisfactory	3 (7.3%)	0
Unsatisfactory	4 (9.8%)	1 (2.4%)
No answer	2 (4.9%)	2 (4.9%)

**Tab. 4:** After a total of 54–664 days (mean: 342 days; median: 381 days).

application the paste takes up growth factors by diffusion from the bony bed. In this process, the hyaluronic acid gel presents the incoming cells with a matrix through which the fine CERASORB® Granules can be made accessible. The result is early vascularisation and rapid formation of new bone.

The hyaluronic acid contained by the paste is a natural component of the extracellular matrix in humans. Because of the water-rich, plastic hydrogel structure of CERASORB® Paste, the growth factors, proteins and minerals that are needed for bone formation can be rapidly taken up without a diffusion barrier. The end-products of the metabolic process of bone formation are absorbed into the hydrogel or passed on to the surrounding blood-vessels and broken down by the body. According to the results of recent research, hyaluronic acid also stimulates the differentiation of stem cells into osteoblasts and has an anti-inflammatory effect.<sup>11</sup>

In two animal experiments (with rabbits) CERASORB® Paste was examined in detail in the distal femur and proximal tibia respectively. In both studies complete reconstruction of the bone structure was achieved in six months. There was no evidence of inflammation, allergy or a foreign body reaction, which indicates that the paste was well tolerated biologically.<sup>11,12</sup> In another study (with sheep) CERASORB® Paste was used in a scapula defect. It was found that bone regeneration had occurred in the defects after six months and that the original bone structure with cortical bone and cancellous bone had been completely restored after twelve months. In all these studies both the  $\beta$ -TCP particles and the carrier substances were completely absorbed in parallel with the formation of new bone.<sup>13</sup>

If residues of CERASORB® particles are still visible on the X-rays, this is not automatically a sign of poor stability in the augmentation area or an absence of


bone regeneration. It should always be remembered that an X-ray is a two-dimensional image of a three-dimensional space. Histologically it has been shown in many cases that the absorption of the granules and the rebuilding of autochthonous bone were much more advanced than was thought to be visible on the X-ray.

The main goal of this non-interventional study was to find out how the new product is applied and how it performs in standard dental procedures carried out by different users who are independent of each other. CERASORB® Paste proved to be an ideal synthetic bone regeneration material for the filling and augmentation of small dental bone defects; this material is absorbed while the body forms new bone of its own, as has already been reported by other authors.<sup>14</sup> In 13 patients who took part in this non-interventional study, a total of 37 implants were placed, most frequently at #24, #26 and #14. 36 out of 37 implants were primarily stable. The bone quality at the time of implantation was judged to be optimal in twelve of 22 cases, as good in six cases, as adequate in one case and as inadequate in three cases.

## Summary

CERASORB® Paste is a new type of bone regeneration material in paste form based on fine  $\beta$ -TCP granules and hyaluronic acid matrix. In the present open multicentre study under everyday conditions this material showed itself to be suitable for filling smaller jaw defects, in particular because it is also easy to handle. It is noteworthy that no side effects of any kind and no intolerance reactions were observed.

*Editorial note: This article was first published in DENTIMPLANTOL 21, 2, 84–89 (2017).*



## contact

### Henriette Lerner

HL-Dentclinic  
Ludwig-Wilhelm-Straße 17  
76530 Baden-Baden, Germany  
Tel.: +49 7221 39873-0  
Fax: +49 7221 39873-10  
info@hl-dentclinic.de

Author details



# (R)Evolution for Implantologists **Champions "(R)Evolution White" Implant**

... the elastic and tough zircon implant  
made from the patented pZircono

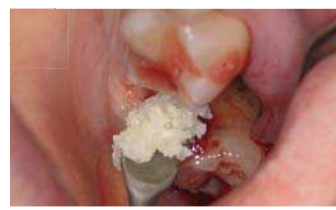The Champions (R)Evolution® White  
implant differs from other zircon  
implants in the following aspects:

- ★ No risk of fracture
- ★ Successful osseointegration
- ★ Rough and hydrophilic surface
- ★ Affordable
- ★ Insertion aid
- ★ Screw
- ★ Healing cap
- ★ Impression tool

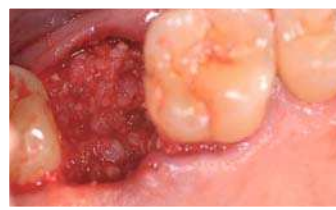

## (R)Evolution for every dental office **The Champions Smart Grinder**

You can avoid vol. 50% of alveolar resorption  
after extraction thanks to socket preserva-  
tion with autologous bone graft using teeth,  
chair-side – in less than 15 minutes!



Placing the obtained bone graft



Placed bone graft



You can see an immediate  
implantation (extraction and  
implantation in one session)  
and the use of the Champions  
Smart Grinder on vimeo.

Scientific studies at:  
[www.champions-implants.com](http://www.champions-implants.com)

champions  implants

Champions-Implants GmbH  
Champions Platz 1 | D-55237 Flonheim  
fon +49 (0)6734 91 40 80  
info@champions-implants.com

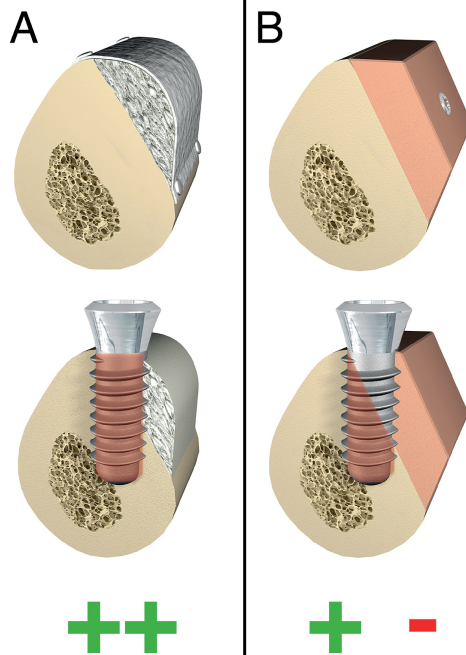

 [www.facebook.com/ChampionsImplants](https://www.facebook.com/ChampionsImplants)

# Vertical bone augmentation procedures—Part II

**Author:** Prof. Dr Dr Florian G. Draenert, M.D., D.D.S., Ph.D., Germany

Adequate alveolar bone at the desired implant site and bony support of the gingival soft tissue is the prerequisite for a successful dental implantation and ideal aesthetic outcome. Complex augmentations are challenging and represent a

hotspot of research. This article discusses complex bone augmentation techniques and their alternatives. This work is a sequel of the publication "Vertical bone augmentation procedures—Part I" published in *implants* 4/2013 that takes into account other publications.<sup>1-3</sup>



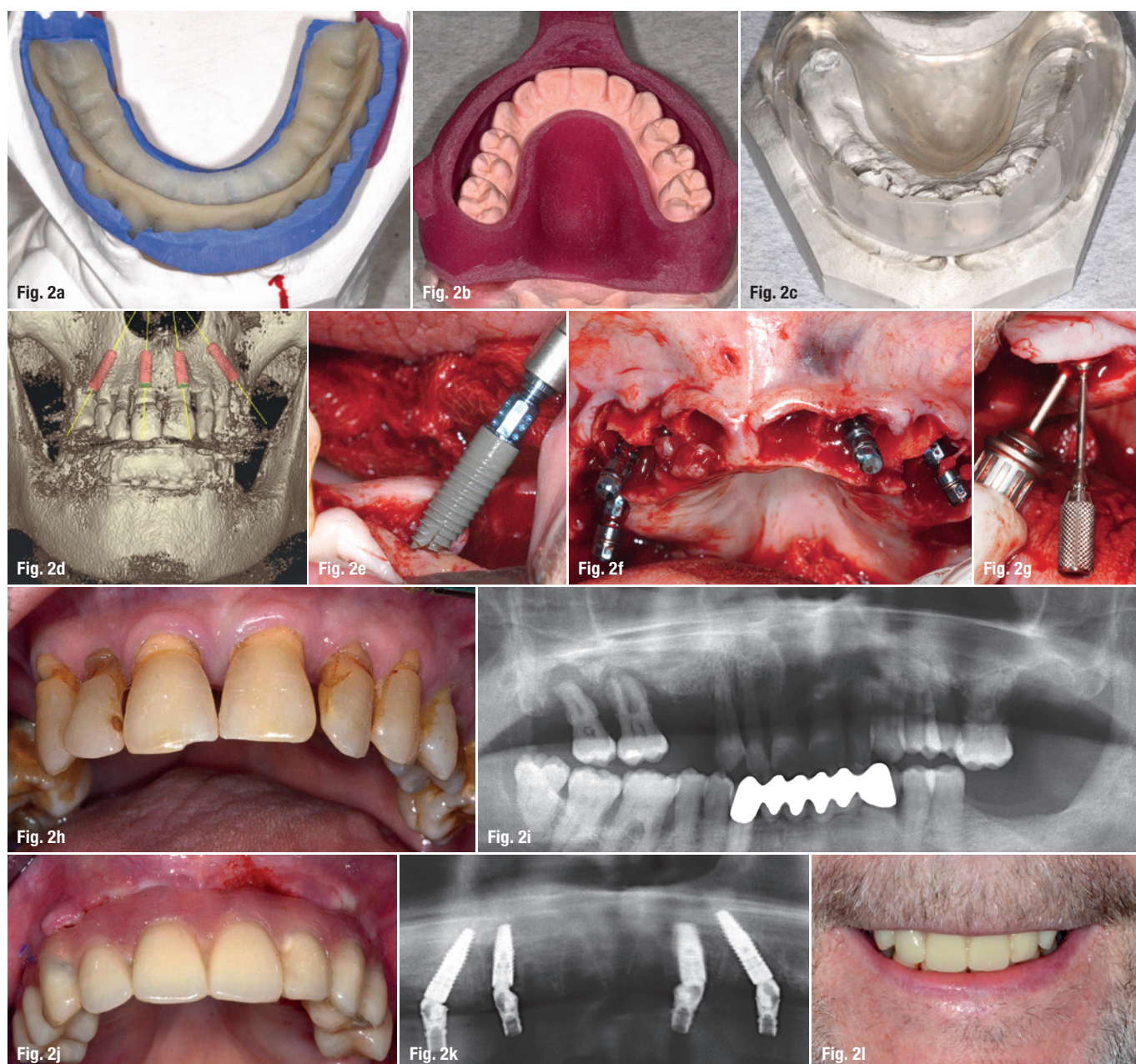
**Fig. 1:** Comparison of the shell (A) and block techniques (B).

Institut Straumann AG is one of the few global implant companies which, along with the Scandinavians, pioneered the field of implant dentistry. Straumann provides a classic range of tissue-level implants and modern bone-level implants. Implants from this company are some of the few that have a scientifically proven improved third surface technology, the SLActive surface, in addition to general sandblasting and acid etching providing better osseointegration by hydrophilisation.<sup>4</sup> It is the only company that offers this triple technology for all implants. The company also offers Roxolid, a metal alloy made of titanium and zirconium, with an increased fracture strength as well as good osseointegration.<sup>5</sup>

At the IDS in 2015, the company launched a second version of the bone-level implants with the same prosthetic connection. The BLT, Bone Level Tapered, implant was introduced to supplement the BL implant line. Based on the ten years' experience with the BL implant, the apex of the implant was tapered, which leads to an increase in the primary stability with no increase of pressure at the marginal implant interface.<sup>6</sup> The angle of the tip was selected so that the tapered tip is longer at 5 mm than other tapered implants and therefore achieves better site-relieving stability. The remaining body has parallel walls and allows a calculable site pressure in complex augmented situations.

Tissue level concepts are well known.<sup>7</sup> This concept has the drawback of a supragingival material edge that cannot be reliably avoided. It has a classic design that achieves very good marginal bone preservation over a very long period. Nevertheless, correctly restored modern bone-level implants can achieve adequate





**Fig. 2:** Fixed immediate restoration with angled implants Straumann Pro Arch: **a–c)** laboratory preparation; **d)** dental Wings planning; **e&f)** Straumann BLT implantation; **g)** Pro Arch multi-unit abutment; **h–l)** situation before and after the restoration.

success and therefore dominate the market across the board.<sup>8</sup> Not all systems meet the ideal requirements to preserve marginal bone, however. Five essential elements contribute to this:

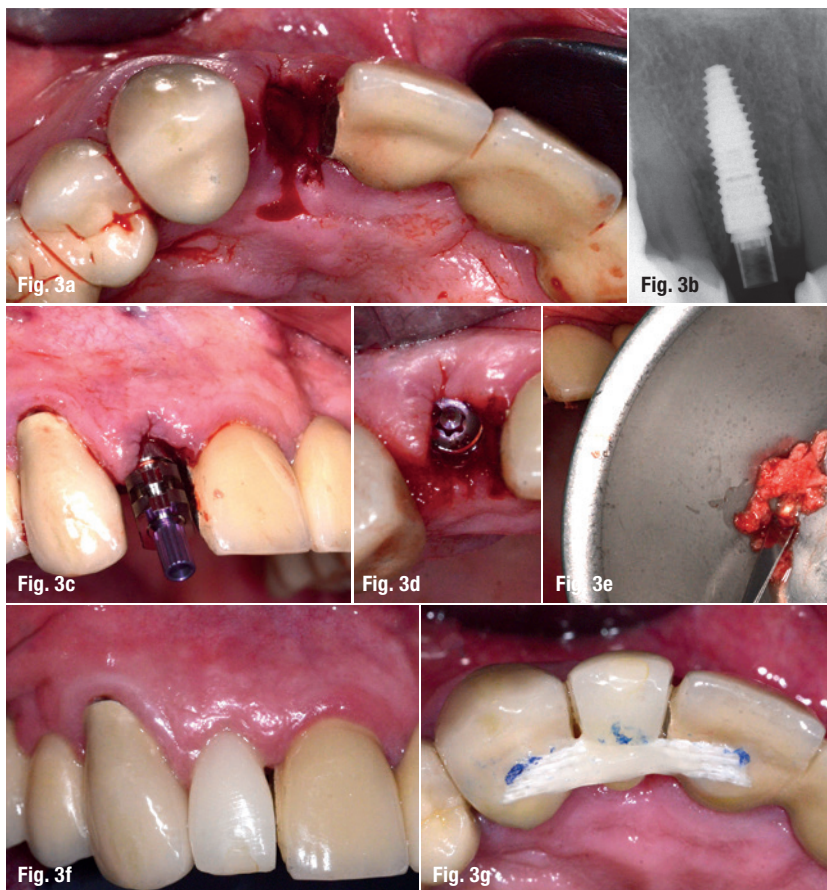
1. Conical connection to prevent microleakage.
2. Triple treated surface to optimise the transition from primary to secondary stability.
3. Platform switching to accommodate the biologic width.
4. Reduced-waist design transition to the abutment to favour contraction of the gingiva.
5. Prospective clinical trials that document the outcome.

This case series features applications of the Straumann BLT system.

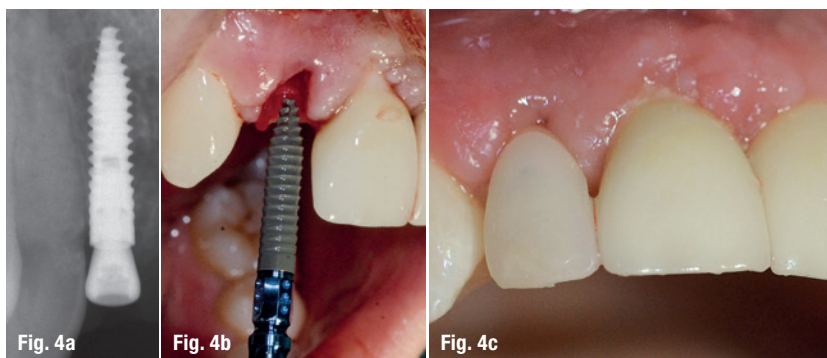
## Principles of bone healing and augmentation

To understand bone healing and the options for augmentation of complex defects, refer to the previous publications.<sup>1–3</sup> We also repeat essential knowledge of the previous article (*implants* 4/2013). In summary, the following applies:

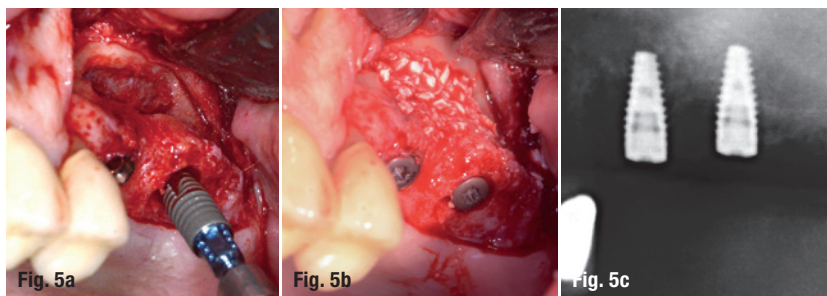
- Overall, there are three different techniques (Fig. 1):
- Shell techniques: stable GBR with alloplastic shells, bone shell techniques
  - Block techniques: solid blocks or blocks with interconnecting pore system (autologous, allogeneic, xenogeneic or alloplastic)
  - Osteotomy techniques: distraction osteogenesis, sandwich techniques and bone splitting



**Fig. 3:** Immediate implantation and load-free restoration in the anterior region in the upper jaw: **a)** atraumatic tooth extraction to preserve soft tissues; **b)** positioning of the angled implant (Straumann BLT SLActive); **c)** impression taking; **d)** cover screw; **e)** particulate augmentation with autogenous bone; **f)** fixed interim restoration; **g)** stabilisation on the adjacent teeth with Ribbond.



**Fig. 4:** Immediate implantation and load-free restoration in the anterior region on the lower jaw: **a)** Straumann BLT 2.9 mm; **b)** positioning of the implant; **c)** interim restoration with immediate implant crown.



**Fig. 5:** Direct sinus floor elevation: **a)** osteoplastic window and implant insertion (Straumann BLT SLActive); **b)** inserted implant and augmentation with Geistlich BioOss; **c)** radiographic check.

A detailed description of these various techniques and the meaningful options are discussed in more detailed articles because many new technical issues have arisen and current developments are still being integrated into this field since the original review article was published in 2013. The current situation is:

Autogenous bone is the best material if it is applied either as particles or as fresh cancellous bone. Analogously to the gap healing of fractures, there are four phases:<sup>9-12</sup>

- aseptic inflammation leading to chemotaxis of pluripotent cells,
- loose replacement tissue (soft callus),
- specific tissue differentiation (mineralisation to hard callus),
- remodelling to functional restitution of the bone.

A useful complex augmentation technique is the shell technique.<sup>2,13-17</sup> There are a number of different applied techniques of this concept: autologous shells (Khoury shells), lactide membranes (Iglhaut technique), metal-reinforced PTFE membranes, titanium membranes and under some conditions allogeneic bone shells as well. The Yxoss titanium grid from ReOss/Geistlich and the 3-D adapted membranes (Draenert-modified Iglhaut technique) are some of the modern 3-D-based improvements.<sup>2</sup>

Incisions should, where possible, avoid large openings and the risk of dehiscence.

### Augmentation techniques and alternatives

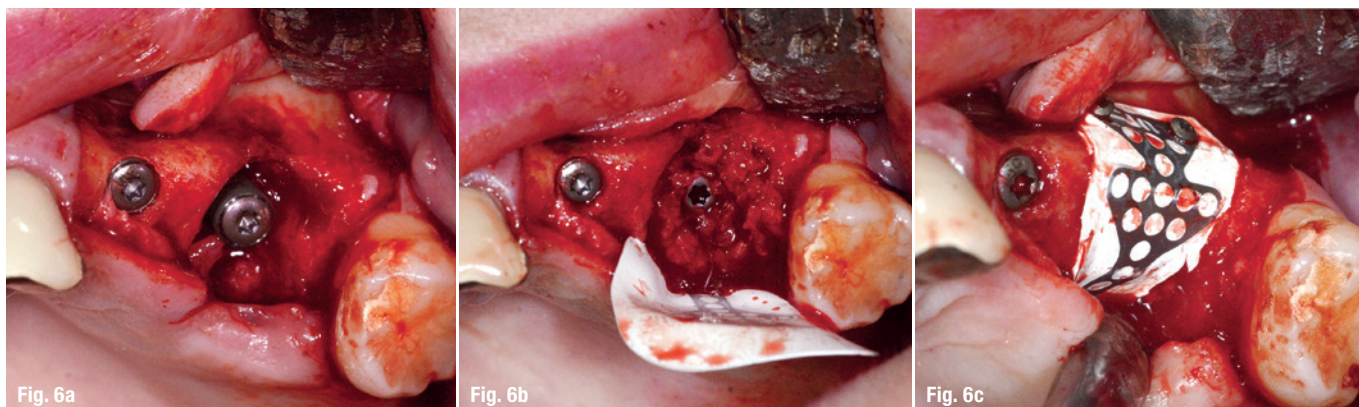
#### The bone defect after tooth loss

In pre-prosthetic surgery prior to dental implantation, a bone defect is a common indication for surgical treatment.<sup>18</sup> Edentulism leads to bone resorption in the jaws.<sup>19-21</sup> Analogous to the indications for bone augmentation, complex bone defects can be differentiated specifically by indication. There are in principle five applications that can be differentiated:

- complete edentulism in one jaw
- the anterior jaw region
- indirect and direct sinus floor elevation
- alveolar ridge augmentation in the posterior teeth of the upper jaw
- alveolar ridge augmentation in the posterior teeth of the lower jaw

#### Complete edentulism in one jaw

With a completely edentulous jaw, the pressing question when planning an implant prosthetic restoration is whether a fixed or removable prosthesis will be used because this has a considerable influ-



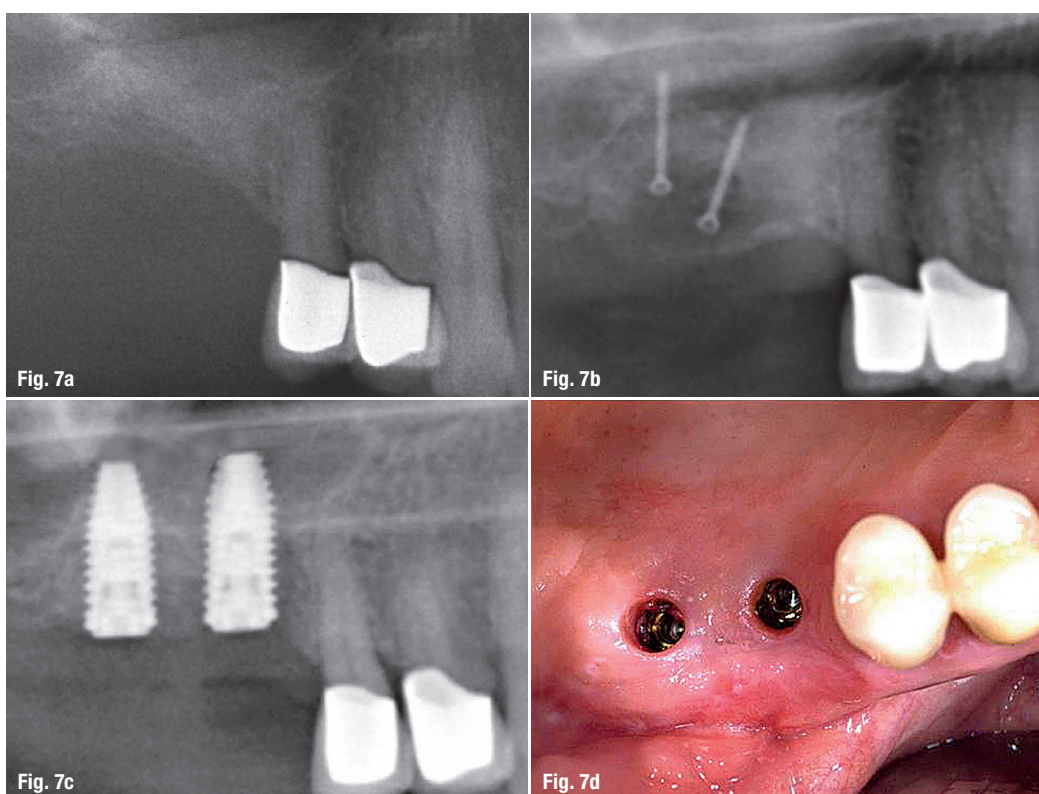
**Fig. 6:** Stable GBR technique with titanium PTFE mesh: **a)** horizontal defect situation; **b)** simultaneous implant insertion (Straumann BLT SLActive), autogenous bone augmentation and Neoss PTFE membrane as the shell; **c)** closed and fixed with KLS Martin osteosynthesis screws.

ence on the need for augmentation. The question of the resorption status of the jaw is also important because narrowing of the alveolar ridge and vertical resorption does not occur locally or in isolation but is associated with resorption-related prognathism and a relative transversal narrowing of the upper jaw. Because checking the basis for the prosthetic and surgical planning is difficult because of the lack of options for orientation to the remaining teeth, 3-D planning checks may be useful. All augmentation techniques can be applied according to the desired prosthetic concept and the defect situation given. Alternative to augmentations can be the application of angled implants.

**Augmentation alternative in complete edentulism**

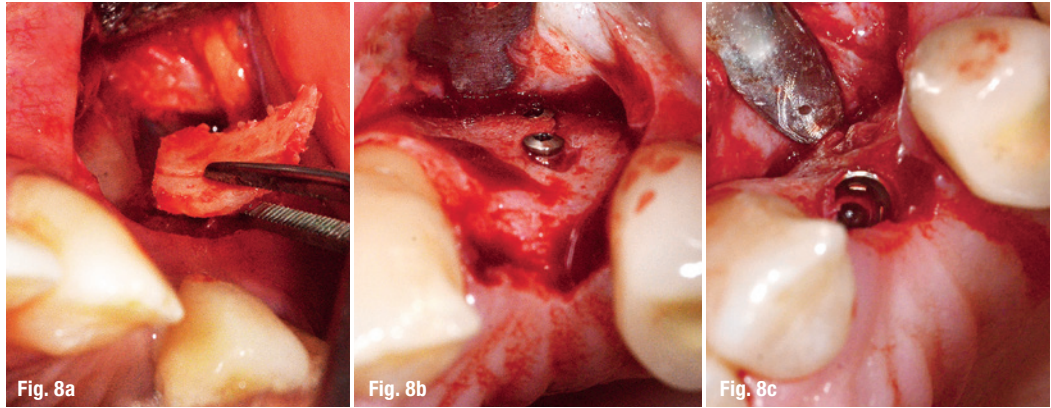
The analogous names for these restorations are scientifically "all-on" restorations or the brand modifi-

cations derived from this, "All-on-4" (Nobel Biocare) or "Pro Arch" (Straumann). Angled implants are one option to avoid the maxillary sinus and the inferior alveolar nerve while still achieving a broad support polygon with no vertical bone augmentation.<sup>22-25</sup> They are therefore an option for cases in which bone augmentation is not possible and, where applicable, also for immediate load indication (Figs. 2a-l). The restoration must be splinted. Experience supports the data in the literature and shows good results. It is recommended for this application to interlock over an implant bridge, which allows a mechanically favourable force distribution. Alternatively, a bar restoration is possible for a removable prosthesis and for certain bite heights makes sense in principle. The technique was and is still hotly debated. For the correct indication and when carried out correctly, the method is, however, a good option for certain patient groups.



**Fig. 7:** Autologous shell using the Khoury technique: **a)** defect situation in the upper right jaw; **b)** status after three months regio 26 and 27; **c)** another three months after implant insertion; **d)** result after soft tissue management.

**Fig. 8:** Autologous shell using the Gellrich technique: **a)** removal of the chip; **b)** status after three months regio 24; **c)** implant insertion (Straumann BLT SLActive).



**The anterior region**

After the loss of anterior teeth, there is a rapid loss of alveolar bone, particularly in the vertical and sagittal directions.<sup>19,20</sup> Initially, the anterior bone is resorbed as a result of the thin vestibular bone lamellae and this later changes to vertical losses. In most cases, bone augmentation is necessary if a sensible immediate implantation has been missed.<sup>26</sup> A sensibly planned immediate implantation is to be preferred. Anatoform implant designs can optimise this approach.<sup>27</sup> An immediate loading concept is also possible and can preserve and even restore the buckle bone without a complex bone augmentation, applying autologous bone chip augmentation only (Figs. 3a–g).<sup>28–32</sup> Results that contradict these data must also be discussed in terms of the implant design and the biomaterial surfaces.<sup>33–35</sup> In the anterior mandible and the pos-

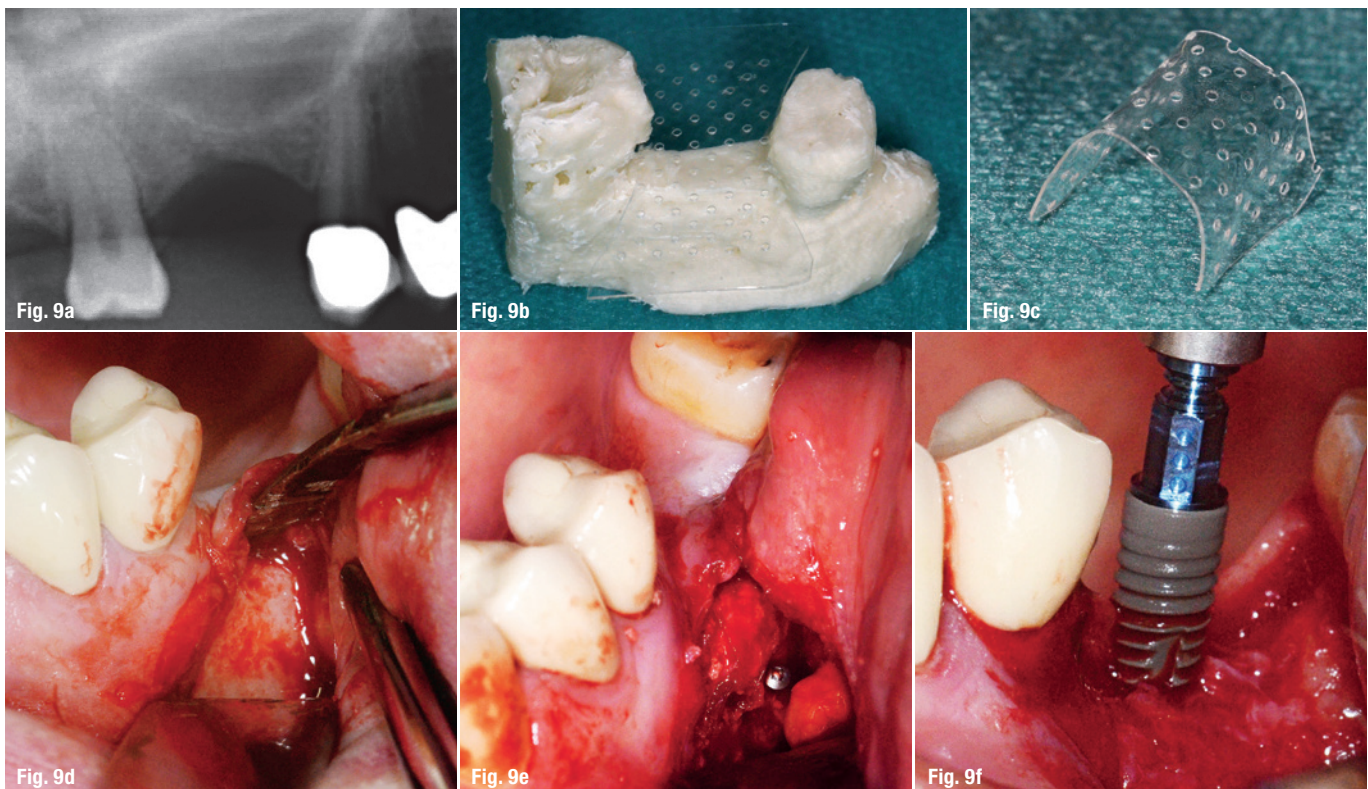
terior mandibular incisor regions low-profile implants with a diameter of 3 mm or less are indicated and are one possible option for a single crown restoration (Figs. 4a–c).

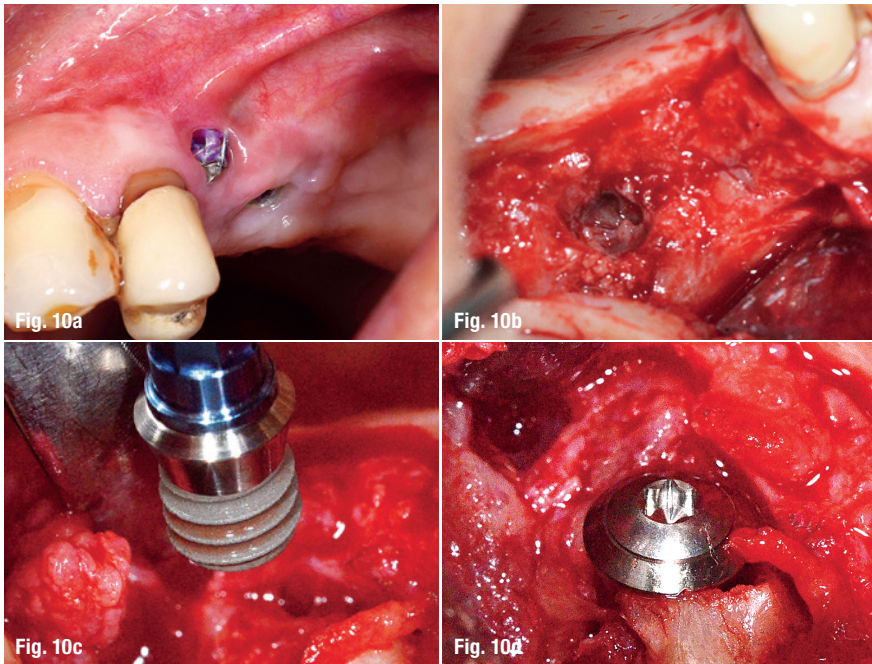
**Indirect and direct sinus floor elevation**

When posterior teeth are lost from the upper jaw, there is initially an expansion of the maxillary sinus with bone resorption proceeding from the cranial to the caudal direction with no change in the alveolar ridge height and this must be treated by elevating the maxillary sinus floor with corresponding augmentation (sinus floor elevation).<sup>36</sup> Two techniques are differentiated here:

- Direct sinus floor elevation is carried out transversally with the sinus membrane being preserved (Figs. 5a–c).<sup>37,38</sup>

**Fig. 9:** **a)** Panoramic radiograph; **b)** 2-D cutting of the membrane; **c)** 3-D thermally shaped shell; **d)** tunnel approach regio 16; **e)** inserted shell with particulate augmentation and screw fixation; **f)** implant insertion during the woven bone phase (Straumann BLT SLActive).





**Fig. 10:** Short implant "Shorty": **a)** complication after pre-treatment elsewhere; **b)** defect after removal of the titanium membrane and implants; **c)** the patient requested a solution that did not involve augmentation: 4 mm Ultra-Shorty (Straumann ITI 4.1/4 mm SLActive); **d)** the inserted implant.

– The indirect Summers technique.<sup>39,40</sup> With this technique the sinus floor is indirectly elevated using osteotomes with a crestal approach via the drill hole access.

#### Complex alveolar ridge augmentation

In the case of a true loss of alveolar ridge, vertical bone augmentation, or lateral ridge augmentation for large lateral defects, may be indicated. For minor complex defects, a shell technique using a PTFE membrane, with simultaneous implantation where applicable (Figs. 6a–c). For medium-sized and large vertical defects, particularly with a free-end situation, the autologous shell technique is useful (Figs. 7a–d; Figs. 8a–c). 3-D shell techniques are advantageous and shorten surgery times with a better fit (Figs. 9a–f).<sup>2</sup> This complex and difficult indication requires more extensive discussions elsewhere.


#### Ultra-short implants as alternatives in the posterior region

In cases of low bone height and if bone augmentation is refused, a restoration can be carried out with short implants (Figs. 10a–d). The basic idea behind this technique is the known force distribution in the first 5 mm of the marginal bone.<sup>41,42</sup>

Numerous studies have demonstrated long-term success, in particular when considering the complications associated with vertical bone augmentation as alternative.<sup>48–51</sup> A splinted prosthetic restoration with implants of normal length appears useful.<sup>43–46</sup>



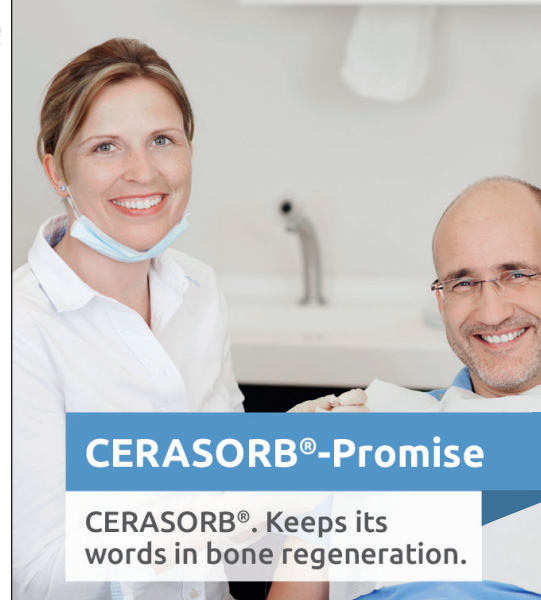Author details



Literature

#### contact

**Prof. Dr med. Dr med. dent.**  
**Florian G. Draenert**  
D Implant Institute  
Tal 4  
80331 Munich, Germany  
Tel.: +49 89 24206800  
info@profdraenert.de  
www.profdraenert.de



## CERASORB®-Promise

CERASORB®. Keeps its words in bone regeneration.



### CERASORB® M

- +** big and microporous surface increases osteoconductivity
- +** shortened duration of resorption by fast penetration with body own bone supporting structure



### CERASORB® Foam

- +** easy handling thanks to defect-adapted modelling and comfortable positioning

**CERASORB® – Always First Choice.**

Manufacturer:  
**curasan AG**  
Lindigstrasse 4  
63801 Kleinostheim  
Germany  
cerasorb@curasan.de  
www.curasan.de

**curasan**  
Regenerative Medicine

# How **safe** is your implant?

## Global initiative for clean dental implants

**Author:** Dr Dirk U. Duddack, Germany

**Fig. 1:** CleanImplant Kick-off meeting at IDS 2017 with renowned manufacturers and scientists: Prof. Tomas Albrektsson, Prof. Ann Wennerberg, Luigi Canullo, Prof. Jaafar Mouhyi (Scientific Advisory Board), Dr Dirk Duddack (Managing Director CleanImplant Foundation), Jonas Ehinger (Osstell), Shelly Akazany (MIS), Sergey Shulezhko, Vladlena Shulezhko (Trate), Marcellus große Holthaus (BEGO), Dr Christian Rähle, Dr Markus Kraft (CAMLOG), Salva Gregori (BTI), Dr Kwang Bum Park, Sian Matthews, Young Choi (MegaGen), Rüdger Rubbert (Natural Dental Implants), Prof. Sergio Bernades (Neodent), Armin Vollmer and Dr Michael Hotze (Straumann).

**Residues on sterile packaged implants**, in particular organic particles from the production or packaging process, are highly suspected of being responsible for an incomplete osseointegration of dental implants or even a loss of bone in the early healing period. Studies from recent years have shown that neither the CE mark nor the FDA clearance can provide a reliable indication of the cleanliness of dental implants. In March 2017, a new initiative was presented at the IDS in Cologne, which is focusing on this topic for the protection of both the users and the patients.

In three consecutive SEM studies, scientists of the University of Cologne and the Charité-University Berlin have analysed more than 200 sterile packaged implants since 2007. Results from the most recent study and comparisons with previous years showed an alarming increase in implants with conspicuous residues. The question we must ask is: How can the clinician know which implants are not affected by these impurities? Due to the variety of implant systems offered on the market, it has become quite difficult for the individual dentist to find a safe system for their practice.


The CleanImplant Foundation was established in 2016 and has set itself the goal of providing exactly this information worldwide. This independent non-profit organisation is supported by a Scientific Advisory Board, which is chaired by renowned scientists and practitioners such as Professor Tomas Albrektsson (University of Gothenburg, Sweden), Professor Ann Wennerberg (Malmö University, Sweden), Professor Florian Beuer (Charité-University Medicine Berlin, Germany), Professor Jaafar Mouhyi (University of Agadir, Morocco), Luigi Canullo (Rome, Italy) and Michael Norton (London, UK), the recently elected President of the US Academy of Osseointegration.

Technically it is possible to produce residue-free implants, as many of the implants have shown in the recent quality assessment studies. If, on the other hand, quality control steps are reduced for production and economic reasons, medical devices of inferior quality are the result despite the existence of a CE certification. However, implants with worrying impurities can only be found in the market if there are uninformed dentists who buy these implants.

If one follows the discussions on professional internet forums it is surprising to discover that apparently little attention is paid to clean medical products by some medical professionals and implantologists: "Do not make a big deal out of it... Can you convince me that super clean implants have significantly better outcome...? Dental implants have been dirty in the last 40 years and they still keep working." If it is the maxim of these colleagues to rely on the immune defense of the patients entrusted to them, then we can also take off our sterile gloves in the operating room again in order to ensure a better tactility during the implantation, commented Dr Dirk Duddack, head of the CleanImplant project. In order to offer no further room for this kind of misunderstanding, there is a need for a sustained information campaign, which will raise the importance for the awareness of clean dental implants.



Fig. 1



**Fig. 2:** Organic pollution on a titanium-made implant (SEM x500), left.

**Fig. 3:** Organic pollution on a zirconia-made implant (SEM x500), right.

At IDS 2017, members of the Scientific Advisory Board, supporting companies and interested implant manufacturers joined the first CleanImplant group meeting. The CleanImplant Foundation presented a new global quality mark, which is designed to enable clinicians to see at a glance whether the appropriate type of implant meets a minimum of cleanliness. The "CleanImplant Trusted Quality" award can be given to implants which have previously shown in a comprehensive neutral analysis that they are free of significant organic impurities (Figs. 2&3) and free of particles containing e.g. copper, chromium, nickel, iron, tin, zinc, bronze, stainless steel or antimony sticking on the implant surface.

To this end, five implants per type are examined, at least two of which are purchased through blind purchase from practices. The analytical reports are screened and released by the Scientific Advisory Board in a peer review process, that is, two board members have to come to the same conclusion independently of each other. "Through these procedures we want to make absolutely sure that there is no connection between the financial support of the project and the analysis result," says Dr Dirk Duddeck. "The biggest difference to all previous attempts to develop such a quality mark is that we not only reevaluate the results with new implants of the same type every two years, but also regularly tighten the criteria for this quality mark. To this end, the existing analytics will be substantially expanded in the coming years."

The results will be published on the project's website [www.cleanimplant.com](http://www.cleanimplant.com). This will allow interested implantologists a quick and easy way to find comprehensive information about the variety of possible implant pollution as well as numerous analysis results of contaminated and clean implants. The project is open to every dentist and manufacturer, which are

particularly concerned about the protection of patients from potentially inferior medical devices.

According to Albrektsson, we should abide to his fundamental guiding principle written in an article a decade ago that we should not only believe, but rather have to know that the implants we use do not harm our patients. To cut a long story short: Patients trust in our decision for the right dental implant system. Dentists should have an independent guide to find out which implant system meets the expectation of a high quality medical device. The CleanImplant Foundation will support future research on the clinical impact of impurities and extend the periodic analyses of dental implants all over the globe in order to provide dentists with independent research results and evaluate improvements in the manufacturing process of previous analysed implants. More information and a correspondent newsletter are available at the project's homepage: [www.cleanimplant.com](http://www.cleanimplant.com).



## contact

### Dr Dirk U. Duddeck

Managing Director  
CleanImplant Foundation CIF GmbH  
Pariser Platz 4a  
10117 Berlin, Germany  
Tel.: +49 171 5477991  
[duddeck@cleanimplant.com](mailto:duddeck@cleanimplant.com)  
[www.cleanimplant.com](http://www.cleanimplant.com)



# Become a champion!

**Author:** Katrin Maiterth, Germany

**Fig. 1:** Priv.-Doz. Dr Armin Nedjat, CEO and Managing Director of Champions-Implants.

**Founded eleven years ago**, the company Champions-Implants distributes implant systems and innovative products such as Smart Grinder, in Germany, Europe and worldwide. At this year's IDS in Cologne, **implants** spoke to Priv.-Doz. Dr med. dent. Armin Nedjat, CEO and Managing Director, about the company's beginnings, his work as both a practising dentist as well as Managing Director, the company's future plans and, of course, how to become a champion!

## **Dr Nedjat, where did you get the idea of founding Champions-Implants?**

The idea for Champions-Implants came to me at a very early stage. After having graduated in Frankfurt am Main in 1993, I first entered my father's practice in 1994. My father had started his implantological work again in 1976. In the further education training sessions, which I started to give from an early point on in my career, I introduced different implant systems to dentists—also two-component systems. The problem which presented itself to me during that time was obvious: Implant systems were far too expensive for the general dentist and thus not suitable for the broader public. I then decided to develop a system available for everyone.

## **Who is the company's target group?**

Our main customers are the generally practicing dentists; meaning those doing endodontics as well as the so called „small surgery“. The Smart Grinder for example is a device which generates valuable, autologous bone substitutes from extracted, and patients own teeth and is thus an absolute must-have for any

dental practice extracting teeth. With this device, the volume of hard- and soft-tissue is maintained.

## **How has your dental work helped you to succeed as Managing Director?**

My daily work experiences as a dentist have a major influence on my work as Managing Director, since ideas for new products mainly arise out of the dental practice. Moreover, a lot of input is coming from the practitioners themselves who contact me via phone or during one of our training sessions at the Champions® Future Center. From what they suggest and my own experiences, we develop and design something of great relevance to the daily practice.

## **Who is developing the products at Champions-Implants?**

The product development is done by Norbert Bomba, Vice CEO and Managing Director of the company, and my person. We also rely, of course, on a great network of experts. In the area of zirconium, we have been working for a long time now with Dr Wolfgang Burger and his team. Regarding the development of the Smart Grinder, we cooperated with Itzhak Binderman from Tel Aviv, Israel, and his son Amit Bindermann from New York, USA, to whom we keep up a very friendly relationship till today. Working with such a great team is absolutely fantastic!

## **Which was the first product in the Champions-Implants' portfolio?**

Our initial product was the one-piece square-shaped implant followed by the one-pieced, ball-



shaped implant. In 2011, we developed the two-piece Champions (R)Evolution® implant, which was and still is our most popular product to date, since most implantologists work with two-piece implants. Thanks to Dr Burger and his team, we can now also use the material pZircono to manufacture the implant body of the (R)Evolution®.

**Champions-Implants is well-known worldwide. In which countries are you mainly present?**

First and foremost, we are working in German-speaking countries, but also in Europe, and some other countries in Africa, Asia and America.


**With Vice CEO Norbert Bomba you have a dental technician on board at Champions-Implants. What makes the company interesting for dental technicians?**

For me it is very important to have a dental technician at management level. In my view, dentists and dental technicians have to be treated as equals. Due to the increasingly important digital workflow, it is crucial for dentists and dental technicians to continuously cooperate on a high level and function as a team.

**Shortly before the IDS, Champions-Implants introduced a new zirconia implant, the (R)Evolution White. What differentiates this implant from other zirconia implants?**

This is a very good question! I think, we were very lucky to have had the opportunity to work with Dr Wolfgang Burger during the past years as he developed a special type of zirconium, a tough one in terms of elasticity. Every company wants to make their materials more solid, us included. However, in addition, we aim for "elastic-tough" in our material. With this, the (R)Evolution White implant is far more break-proof than comparable systems. Another special feature is the surface quality: Our zirconia implant has—like titanium implants—a micro-rough structure, on which laser can be applied. In many cases, acids are used for this, which we did not want to do.

**With 426 participants from all over the world, the Champions® Symposium in March this year has proven the international success of your company. What are you striving for next?**



We will always strive for one thing: that ordinary people can afford high-quality dentures. This is something that is often not taken into account. Although the economic situation is—especially in Germany—generally very good, certainly not everyone can pay for high-quality care costing thousands of Euros per implant. Thus, the average price for an implant has to be lowered in the future. You can see that already with other companies that buy cheaper materials to offer lower priced systems.

**How do you manage to combine high quality with low prices?**

By not having an armada of sales representatives! We do not have a single sales rep poking around dental practices and winding up affairs. Our customers are coming to us, and to our professional trainings. Additionally, we have a fantastic association in place which supports us greatly—the Association for Innovatively Practicing Dentists (VIP-ZM).

**Last question: How do you become a real champion?**

It's simple: By having fun in what you are doing—regardless of the system in use—and by working in the patient's very best interest. The future of our practices is the minimally invasive method of implantology (MIMI®) and immediate implants. This can be done by every dentist without having to invest in micromotor and DVT.

## contact

### Champions-Implants GmbH

Champions Platz 1  
55237 Flonheim, Germany  
Tel.: +49 6734 914080  
info@championsimplants.com  
www.championsimplants.com

**Fig. 2:** Shortly before IDS 2017, the zirconium implant (R)Evolution White was introduced.

**Fig. 3:** In January 2016, Champions-Implants opened their Champions® Future Center in Flonheim, which is equipped with treatment rooms for live surgeries and training rooms with 3-D video transmission.



# 2017 AO Annual Meeting Orlando

**Author:** Dr Rolf Vollmer, Germany



Author details

On behalf of the Annual Meeting Program Committee, Program Committee Chair Dr Jeffrey Ganeles and the president Dr Alan Pollack welcomed more than 2,500 attendees to Orlando and the 2017 Annual Meeting of the Academy of Osseointegration (AO). As part of his remarks, Dr Pollack also provided his presidential address in which he stated, "Much of the 'take-away' from these meetings derives from sharing ideas and problems with colleagues. Sitting next to someone in the lecture halls who may practice across the country or across the globe, in a different practice setting and performing procedures that you don't, or wouldn't do yourself offers the opportunity to open your mind to different perspectives and share disparate experiences."

This year's event was inspired by author Jim Collins, who's book titled, "Good to Great®" described how companies transition from being good companies to great companies. Dr Jeffrey Ganeles pointed out that this drive for constant improvement envelopes our field in implant dentistry and captures the enthusiasm of the synergistic partnership. To quote from the last paragraph of the book: "When all these pieces come together, not only does your work move towards greatness, but so does your life. For, in the end, it is impossible to have a great life unless it is a meaningful

life. And it is very difficult to have a meaningful life without meaningful work." On that note, Dr Ganeles concluded: "On behalf of the committee, I hope you are amazed and frustrated, challenged and stimulated and overwhelmingly motivated by our meeting."

Before the Annual Meeting officially kicked off, many educational opportunities were available. Wednesday, 15 March, two unique and fascinating presentations on dental radiology and cellular and biomechanical aspects of osseointegration were given by experts particularly useful to fulfill academic requirements for the AO Certificate Program.

Thursday morning brought a strong Corporate Forum. Then the Opening Symposium on Thursday afternoon featured keynote speaker Dr Jill Helms, followed by lectures from five well-known international experts. Friday, 17 March began at 7:00 am with an innovative new session called "Business of Implant Dentistry—SWOT Analysis of Implant Dental Care Delivery Models". Its speakers represented traditional referral based practices. Parallel this session, there were the Masters sessions presented by Drs Anthony Sclar, Lawrence Brecht, Thomas Taylor, HP Weber, Mauricio Araujo, Stephen Parel and Tiziano Testori.

**Fig. 1:** Dr Mazen Tamimi (middle) at the ACTEON exhibition booth.

**Fig. 2:** Dr Mario Rodrigues (left) and Dr Rainer Valentin.

**Fig. 3:** Dr Suheil Boutros.



Fig. 1




Fig. 2

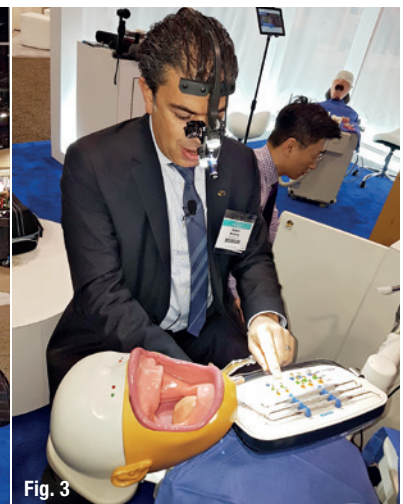

Fig. 3



Fig. 4

**Fig. 4:** Dr Mazen Tamimi, Dr Rolf Vollmer, Dr Stephen Wheeler and wife, Dr Edward Sevetz and wife and Dr Rainer Valentin (from the left).

Friday was continued with surgical and restorative tracks featuring leading clinicians as well as lesser known, creative rising stars who discussed different aspects of implant dentistry ranging from surgical strategies and techniques to complications management to treatment flow, digital dentistry, materials, science and future trends. In the surgical track, there was a session devoted to a 2017 update of the landmark 1997 AO Sinus Consensus Conference featuring Drs Alan Herford, Craig Misch, Paul Fugazzotto and Eric Dierks. Drs Michael Block, Vince Iacono and Ole Jensen coordinated a special session on sinus grafting, updating the original AO consensus conference from 20 years ago.

Following AO's tradition of supporting research and innovation, the oral clinical research abstract session was held Friday morning and the Oral Scientific and Clinical Innovations sessions were presented Friday afternoon. Another session focused on managing anterior aesthetics in addition to others concentrating on managing biologic complications, "New Concepts and Materials for Site Development" and "Image Guidance and Digital Workflow for Planning and Treatment." On Friday evening, Dr Alan Pollack hosted the President's Reception at the Latin-themed Mango's Tropical Café.

Saturday's main program returned to the "Good to Great®" refrain as well, looking toward future advances in all aspects of the dental implantology field. Topics included new technologies, short implants, imaging, digital planning and guided treatment, socket management and site redevelopment. The multidisciplinary approach was particularly evident in the afternoon team presentations, where internationally renowned groups illustrated their evaluation and treatment methods to elegantly tackle difficult patient problems.

Saturday also offered full-day programs for both Allied Staff Professionals and Dental Laboratory Technicians. In the afternoon, an innovative and enjoyable group completed the meeting with "Good to Great®: Optimizing the Patient Experience with Ideal Team Interaction." This panel was comprised of a surgeon, a restorative dentist, a laboratory technician and industry representatives including manufacturers and financing, who provided their input on creating great patient experiences in implant dentistry. It was obvious that the Program Committee worked hard to provide an innovative, balanced, fascinating program that would be clinically relevant. A fantastic blend of "veteran" speakers with undiscovered rising stars was elected covering both traditional subjects as well as new topics that will demand to be considered as we are heading into this next era of dental implant therapy.

DGZI Germany was represented by Vice President and Treasurer Dr Rolf Vollmer and members of the board Dr Rainer Valentin and Dr Mazen Tamimi, who is also the international representative of the DGZI in Jordania.

*Editorial remark: The 'GOOD TO GREAT' trademark is owned by The Good to Great Project LLC. Used under license.*

## contact

### DGZI Central Office

Paulusstraße 1  
40237 Düsseldorf, Germany  
Tel.: +49 211 16970-77  
sekretariat@dgzi-info.de  
www.dgzi.de

About the society



## NucleOSS

### Optimal service for customers

NucleOSS has seen an enormous interest in their home market in Turkey as well as in other countries worldwide on the T6 implant line. This well-approved implant offers a stable internal connection and a simple handling combined with a completely colour coded system which makes the usage for customers easy and time

effective. Furthermore, the T6 implant system is evaluated and approved by the NucleOSS' scientific committee TFI academy. Within its growth and expansion strategy, the company now has shifted his German head office and has been strengthened with additional personnel to meet the increasing customer demand and ensure an optimal service for customers and partners. With Wolfgang Müller the management team has lately been reinforced with a managing expert in the area of dental implants.

At the same time, the company announces its newly developed product line which will soon be introduced to the dental market. NucleOSS is convinced that the advantages of its system covering all treatment options in the field of prosthetics will be assessed as an innovative and modern system, offering a high-class implant.

**NucleOSS Europe GmbH**  
 Graben 17  
 64646 Heppenheim, Germany  
[www.nucleoss.com](http://www.nucleoss.com)



## Bicon

### Time proven design

The Bicon SHORT® Implant is an example of a time proven geometric design that successfully transfers the occlusal forces on its prosthesis to its surrounding bone by appropriately integrating the following features: a bacterially-sealed, 1.5 degree locking taper abutment to implant connection and a sub-crestally placed, sloping shouldered implant with a plateaued tapered root form body. Additionally, these integrated features compensate for the implant's ankylosed nature by successfully transforming occlusal forces to acceptable strains within the bone, provide for healthy and gingivally aesthetic peri-implant tissues, as well as for the callus formation of cortical like bone with central vascular systems.



**Bicon Europe Ltd.**  
 Hauptstraße 1  
 55491 Buechenbeuren, Germany  
[www.bicon.com](http://www.bicon.com)

## bredent medical

### Implantology meets Bionics

Restoration of implants anchored firmly in the bone using bionic prosthetic materials is the latest trend in the field of implantology. The bredent group is achieving high growth rates with BioHPP®—a ceramically-reinforced PEEK—as frame and abutment material and the visio.lign veneer system made from composite materials.

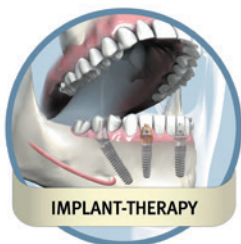
These bionic materials form the basis of one-time treatment in immediate restoration of individual teeth, i.e. the implants are fitted and once primary stability is sufficient, restoration is

immediately carried out using a crown. Once the implant has healed, the crown is then replaced, where necessary. The soft tissue accumulated on the abutment is not disturbed. The treatment times are reduced as a result of this new workflow and the number of visits that patients

have to make to the practice is therefore also reduced. What is more, less material is required, thereby reducing the costs of treatment. This type of material is a good value alternative to a conventional 3-part bridge on ground natural teeth.

**SKYonics**  
 IMPLANTOLOGY MEETS BIONICS

**bredent medical GmbH & Co. KG**  
 Weißenhorner Straße 2  
 89250 Senden, Germany  
[www.bredent-medical.com](http://www.bredent-medical.com)



## MIS

# Biological Organic Contact

At this year's IDS, MIS Implants Technologies officially launched its latest product in implant engineering, the B+ implant surface. The B+ molecules bond chemically with the surface of the titanium dioxide of an implant and integrate with existing and newly forming bone, achieving greater initial osseointegration and long-term stability.

The specific bone-bonding properties of B+ have proven to produce greater fixation of the implant in the early stages post-placement, as well as greater stability later. B+ consists of a monolayer of multi-phosphonate molecules. These have a very high affinity to titanium dioxide, enabling a true covalent bond. The unique properties of this layer also make it extremely hydrophilic, which facilitates the colonization of cells on the surface naturally. Research has even shown that blood vessels grow directly into the surface of the implant, which is unaffected by the oral environment and has been proven very stable in different pH levels.

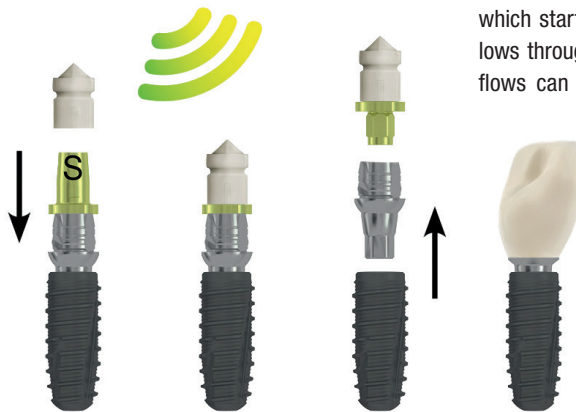


**MIS Implants  
Technologies GmbH**  
Simeons carré 2  
32423 Minden, Germany  
[www.mis-implant.com](http://www.mis-implant.com)

## CAMLOG

# One click, one scan, one shift

Since its market launch in 2013, the core concept of the iSy® Implant System has focused on the efficiency of surgical and prosthetic workflows. With this, iSy® stands for a reduction in the complexity of oral implant dentistry. The transgingival concept is designed to streamline the workflow. It is based on a reduced drill protocol and single patient drill. Regardless of



whether analogue or digital processes are used, the iSy® Implant base is only taken once for the final restoration and replaced by the definitive abutment. The "One-shift concept" describes this principle of a single abutment change, which is to bring additional benefits for the long-term stability of the peri-implant hard and soft tissue. "One click, one scan, one shift" is how iSy® describes the digital workflow for CEREC® users, which starts directly after implantation and follows through to the final restoration. The workflows can be streamlined even more with the new iSy® Scanning adapter, which is compatible with the Sirona Scanbodies S and allows making a definitive restoration with the One-shift concept in only one day.

**CAMLOG Biotechnologies AG**  
Margarethenstr. 38  
4053 Basel, Switzerland  
[www.isy-implant.com](http://www.isy-implant.com)

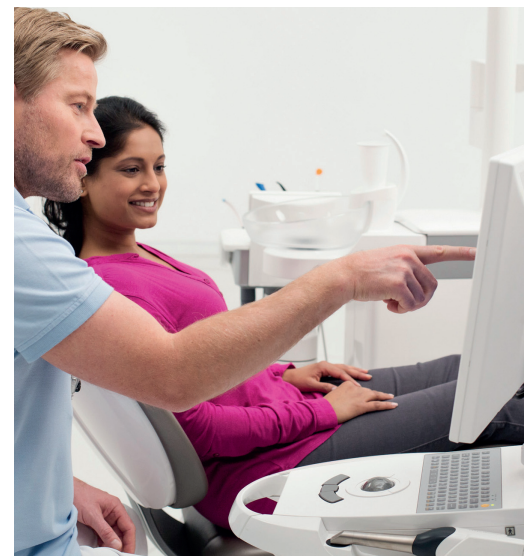## Dentsply Sirona

# Integrated solutions for efficient workflows

Dentsply Sirona's integrated solutions for implant dentistry enable dental professionals to deliver safer and more efficient treatment processes as well as increased comfort and improved quality of life for their patients. The company offers implant systems and procedures for all indications. With different types of macro- and micro-design and connective geometries, these products are set apart by a high degree of mechanical and biomechanical durability and by long-term clinical results. The Astra Tech Implant System EV has been specially optimized for digital workflows and hence fits perfectly into digital work processes. SmartFix is a treatment concept in which edentulous patients are fitted immediately with a full-arch fixed prosthesis supported by only four implants. The concept is available for all Dentsply Sirona's implant systems: Ankylos, Astra Tech Implant System and Xive. With Symbios Bone Regenerative solutions, the clinician has access to a wide range of bone

augmentation materials, membranes, and instruments.

**Dentsply Sirona –  
The Dental Solutions Company™**  
Sirona Straße 1  
5071 Wals/Salzburg, Austria  
[www.dentsplysirona.com](http://www.dentsplysirona.com)



## Nobel Biocare

### Treat more patients better—Genesis of a project

At the 2016 Nobel Biocare Global Symposium in New York, Trefoil was introduced to an international audience. This treatment approach offers the possibility of same-day rehabilitation of the edentulous mandible or a failing dentition in the lower jaw with a definitive implant supported prosthesis. An innovative compensation mechanism incorporated into a prefabricated framework allows adjustment to a precision fit on three implants, making Trefoil unique.

#### Based on a heritage of innovation

Over several decades, Prof. Brånemark and Barbro Brånemark travelled the globe in order to provide care to hundreds of patients suffering from acquired or congenital cranio-maxillo-facial defects, something they did without direct financial compensation. Brånemark recognised the high global incidence of edentulism and the universal problem of affordability for implant rehabilitation. In 1999, as a potential solution for this predicament he introduced Novum, which was the forerunner and progenitor of the Trefoil concept.

Novum was a pioneering landmark using immediate loading of implants combined with analogue-guided surgery. Favourable short-term results of implant and prosthesis survival rates were reported by multiple centres; however, a concerning incidence of post-surgical prosthetic complications was also documented. These restorative problems, coupled with the unforgiving nature of surgery, resulted in a decision by Nobel Biocare to discontinue Novum in 2007.

Based upon positive clinical results with over 70 patients treated using the Novum procedure in private practice and similar experiences from other surgeons it became clear



that the unforgiving surgical requirements of Novum and the high incidence of post-surgical restorative problems being reported were often related to misfit between the prefabricated framework and the three misaligned implants.

#### Trefoil: collaborative innovation

Over a four-year period, 2012–2016, the Trefoil team undertook an intense process of collaborative innovation, which included multiple engineers and clinical specialists. The Trefoil team focused on rectifying the deficiencies of Novum using engineering and clinical technology not available in the mid-1990s.

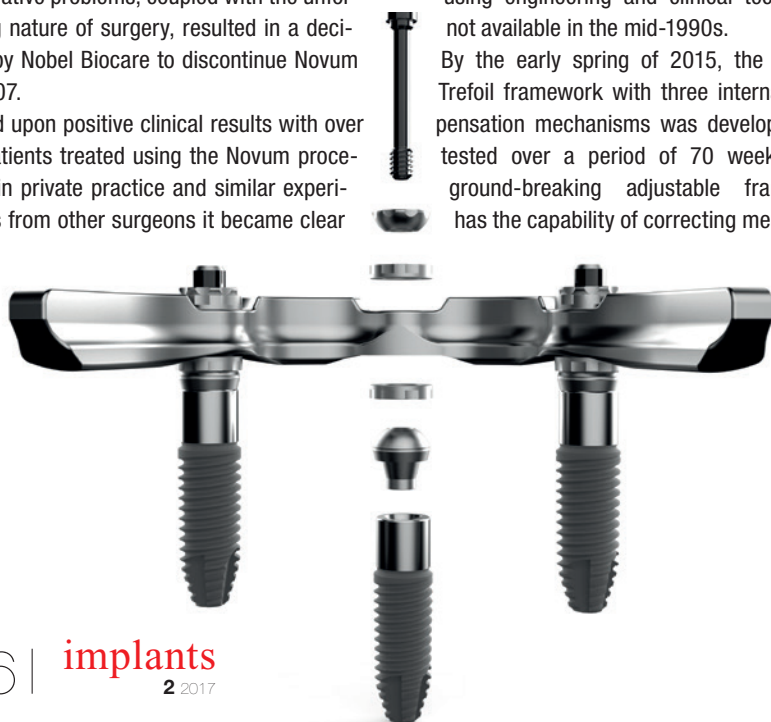
By the early spring of 2015, the present Trefoil framework with three internal compensation mechanisms was developed and tested over a period of 70 weeks. This ground-breaking adjustable framework has the capability of correcting meaningful

horizontal, vertical and angular misalignment of the three implants placed with guided surgery to achieve a precise fit. This collaborative development required three years of bi-weekly meetings during which 25 framework iterations and over 100 component design changes were evaluated. In April 2016, an international 5-year multicentre post market trial was commenced. By the end of December 2016, completed enrolment of 90 patients in the study was anticipated. To date, excellent early results have been reported in this prospective long-term study.

The Trefoil concept embodies the Nobel Biocare objective, “to treat more patients better,” by offering a reduction in cost using a simplified clinical workflow, a standardised prefabricated framework, and minimised componentry that reduces treatment time. The Trefoil concept was conceived and developed to extend the benefits of osseointegration to a new patient population. It is not intended to replace any of the current edentulous solutions presently available, but offers a more affordable premium alternative for an entirely new patient population instead.

Author: Dr Kenji W. Higuchi

**Nobel Biocare Services AG**  
P.O. Box  
8058 Zurich-Airport, Switzerland  
[nobelbiocare.com/trefoil](http://nobelbiocare.com/trefoil)



Nouvag

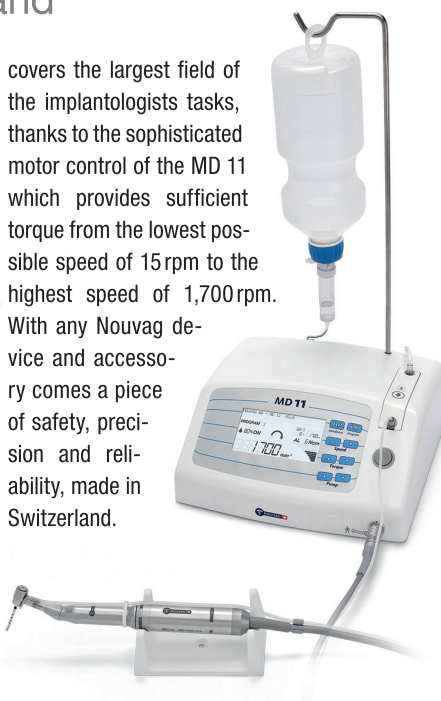
## Safety made in Switzerland

For 45 years Nouvag AG has committed itself to the development and manufacturing of medical devices and instruments and is famous throughout the world for its legendary Physio Dispenser. The device was the first equipped with a peristaltic pump to deliver a sodium chloride water solution for the cooling of the rotating instruments to eliminate the feared necrotisation of bone and its surrounding tissues.

Nouvag's latest development in the field of Implantology is the motor system MD 11. Drilling, thread cutting, screwing in the implants and placing the cover screw are now organised in separate programmes. The insertion of the tubing set is done with very little effort due to the great visibility of the mounting bracket and easy to reach notches in the bracket. The display shows all information at a glance, no key pressing necessary. Even the activation of the cooling pump and the changing of the pump speed is conveniently done by pressing switches on the pedal.

To make the set of the MD 11 complete, Nouvag offers all required contra angles such as the 1:1, 16:1, 20:1, 32:1 and a 70:1. The 20:1 contra angle, also available with LED spotlight,

covers the largest field of the implantologists tasks, thanks to the sophisticated motor control of the MD 11 which provides sufficient torque from the lowest possible speed of 15rpm to the highest speed of 1,700rpm. With any Nouvag device and accessory comes a piece of safety, precision and reliability, made in Switzerland.



**Nouvag AG**  
**St. Gallerstr. 23-25**  
**9403 Goldach, Switzerland**  
**www.nouvag.com**

Straumann

## Small, strong and enduring

The Straumann® Bone Level Tapered Implant Ø 2.9mm (aka "the SmallOne") is a dedicated small-diameter implant that has all to inspire trust in implant-borne restorations for narrow interdental spaces or ridges.

This new member of the Straumann® Dental Implant System has been specifically engineered to address aesthetic challenges in compromised situations such as narrow interdental spaces or reduced bone availability. It possesses the outstanding mechanical strength

of the Straumann® Roxolid® material and the extensive healing potential of the Straumann® SLActive® surface. This made it possible to engineer an implant with a diameter as narrow as 2.9 mm that is reliable without compromising on strength. New prosthetic components in a unique oval design address the aesthetic challenges. They provide enough space for surrounding soft tissue to achieve pleasing aesthetic results in the anterior region. With this product you can treat your patients with confidence and offer an ideal treatment solution to increase patient acceptance.

**Institut Straumann AG**  
**Peter Merian-Weg 12**  
**4052 Basel, Switzerland**  
**www.straumann.com**



## Shortest Implants – Longest History.

## Think Short!

For more than 30 years Bicon® short implants are unchanged in clinical use.

According to the 11<sup>th</sup> European Consensus Conference (EuCC) 2016 in Cologne, provided the specific treatment parameters are observed, the use of short, angulated or diameter-reduced implants in sites with reduced bone volume can be a reliable treatment option, given the risks associated with the use of standard-dimension implants in combination with augmentation procedures.

For more Information:

**Bicon Europe Ltd.**

Hauptstr. 1

55491 Buechenbeuren

Germany

Phone +49 (0)6543 818200

germany@bicon.com

**www.bicon.de.com**



**bicon**  
 DENTAL IMPLANTS

## Germany's first implantologist

### Prof. Dr Hans L. Grafelmann turns 92

The founder of dental implantology in Germany, Prof. Dr Hans L. Grafelmann, today looks back on a full and eventful life. In 1968, he pioneered in placing Germany's first dental implants in the form of extension implants in his dental practice. Today, his former patient still carries her fully functional dentures.

In fact, Prof. Dr Grafelmann's CV, the resume of a dentist, an inventor, a patent holder, specialist author and the editor of the first implantological specialist magazine "Orale Implantologie", is a whirl of plans and activities. In January 1970, along with six co-founders, he established Europe's oldest specialist society for dental implantology in Bremen/Germany: the DGZI e.V. (German Association of Dental Implantology). His international engagement and perseverance in gaining acknowledgement for dental implantology and implant prosthetics are unceasing. In Germany alone, he held and headed 25 educational implant congresses in the years between 1970 and 1993. In all of his endeavors, he is motivated by the fundamental principle that implant therapy will serve the purpose of a worldwide improvement of people's quality of life. His experience as a dental

specialist has taught him that often, implants have a longer functional life than the natural dentition. To this date, Prof. Dr Grafelmann advocates the addition of oral implantology to academic education, always also arguing for a close connection to the dental practice: "The best place to learn and teach is the dental chair in which we operate."

This philosophy of dedication, future- and patient-oriented science and practice-oriented education is the legacy which Prof. Dr Grafelmann will leave to dental and implantological experts worldwide, together with his extensive knowledge and experience. On 16 February 2017, he celebrated his 92<sup>nd</sup> birthday.



## Obstructive Sleep Apnea causes

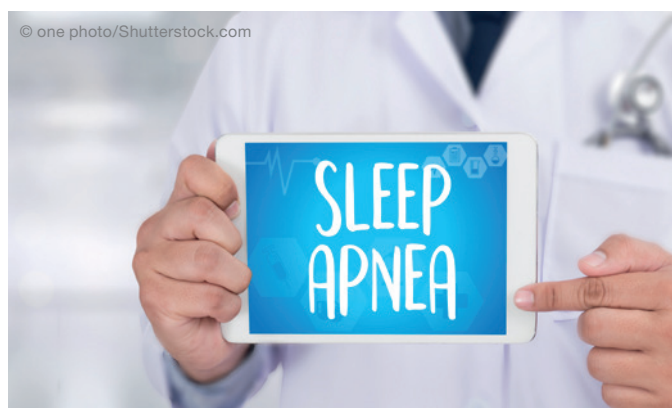### Complications in implant-borne prostheses

Researchers from OSI Araba University Hospital in Victoria, Spain, published a study that investigated how Obstructive Sleep Apnea (OSA) affects implant-borne prostheses. The frequency with which a complication occurred and the type of complication were studied in 67 patients. Contradictory to

their initial hypothesis, the researchers found a high instance of complications related to OSA.

Of the 67 patients included in the study, the researchers found that 16 experienced complications; 13 of which had OSA. Among these 16 patients with complications, there were 22 prostheses with a total of 30 issues. The researchers found these complications consisted of porcelain fracture, fracture of the screw/implant, loosening of the screw, and decementation. The average time for a complication to occur was 73 months' post-implantation. During the study, the researchers also noted a strong relation between individuals who suffer from OSA and those who suffer from bruxism. Past studies revealed that those afflicted with bruxism had a higher instance (6/10) of complications with implant prostheses than those without bruxism (13/75). This shows that people suffering from OSA and/or bruxism have a more difficult time with successful prosthetic implantation.


This study shows that 81 per cent of patients with OSA experienced complications with their prostheses. Given that the success rate of implants is reported to be between 92 and 97 per cent, there is a strong correlation between OSA and prosthetic complications.





## This year's IDS sets

# New record in attendees



More than 155,000 people from 157 countries visited the International Dental Show (IDS) 2017, according to the latest figures released by organiser Koelnmesse. This is an increase of 12 per cent compared with IDS 2015. Furthermore, the number of international attendees rose by almost 20 per cent to around

60 per cent. There was also a slight increase in national visitors. In a visitor survey, about three-quarters of respondents were very satisfied or satisfied with IDS 2017, as well as with achieving their targets for the exhibition. The majority of those surveyed (90 per cent) would recommend IDS to business partners, and

70 per cent said they plan to visit IDS in 2019. At the fair, 2,305 companies from 59 countries (compared with 2,182 companies from 56 countries in 2015) exhibited in an overall area of 163,000 m<sup>2</sup> (158,200 m<sup>2</sup> in 2015). These included 624 exhibitors and 20 additionally represented companies from Germany (636 and 19, respectively, in 2015), as well as 1,617 exhibitors and 44 additionally represented companies from abroad (1,480 and 44, respectively, in 2015). The proportion of foreign companies was 72 per cent (70 per cent in 2015). Of the more than 155,000 visitors from 157 countries (138,500 visitors from 151 countries in 2015), around 60 per cent (compared with 51 per cent in 2015) came from abroad. IDS 2017 focused on digital production and diagnostics, intelligent networking solutions for practices and laboratories, smart services for dentists and dental technicians, as well as the further improvement of patient care and thus oral health worldwide. The next IDS will take place from 12 to 16 March 2019.

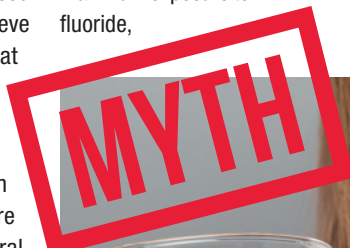## Survey exposes truth about

# Our oral health habits

FDI World Dental Federation is myth busting what people around the world believe to be good oral health practices, encouraging them to become better informed and take action. Oral health is integral to our general health and well-being; impacting every aspect of our lives. The results from a survey carried out in 12 countries, by YouGov on behalf of FDI, exposed a significant gap between what people believe to be good oral health practices, versus what they actually do. Eight of the countries reported that 50 per cent or more of the people surveyed think it is important to brush your teeth straight after every main meal. Brazil, Mexico, Egypt and Poland were the worst offenders of this incorrect oral health practice (84%, 81%, 62% and 60% respectively). FDI recommends waiting at least 30 minutes after eating to brush your teeth to avoid weakening tooth enamel.

The majority of countries surveyed incorrectly believe that rinsing the mouth out with water after brushing is important; Brazil, South Africa, Mexico, India and Canada were found to practice this myth the most (77%, 75%, 73%, 67% and 67% respectively). It is actually recommended not to rinse with water straight after brushing to allow maximum exposure to fluoride,

which will optimize the preventative effects. Nearly half the population surveyed in India, South Africa, Brazil and Poland (52%, 49%, 48% and 42% respectively), felt that drinking fruit juice rather than fizzy drinks was important for good oral health. Fruit juice however, can also be high in sugar which can cause tooth decay. FDI recommends keeping consumption of sugary drinks to a minimum as part of a healthy, balanced diet.



# Congresses, courses and symposia



## 5th International Z-SYSTEMS Congress

16–17 June 2017  
Venue: Nice, France  
[www.zsystems.com/event](http://www.zsystems.com/event)



## World Summit Tour – Dentsply Sirona Implants

23–24 June 2017  
Venue: Nice, France  
[www.worldsummittour.com/nice](http://www.worldsummittour.com/nice)



## 47th International Annual DGZI Congress

29–30 September 2017  
Venue: Berlin, Germany  
[www.dgzi-jahreskongress.de](http://www.dgzi-jahreskongress.de)



## 26th EAO Annual Scientific Meeting

5–7 October 2017  
Venue: Madrid, Spain  
[www.eao-sepes2017.com](http://www.eao-sepes2017.com)



## 66th Annual AAID Conference

11–14 October 2017  
Venue: San Diego, USA  
[www.aaid.com](http://www.aaid.com)

# implants

international magazine of oral implantology



## Imprint

### Publisher

Torsten R. Oemus  
[oemus@oemus-media.de](mailto:oemus@oemus-media.de)

### CEO

Ingolf Döbbecke  
[doebbecke@oemus-media.de](mailto:doebbecke@oemus-media.de)

### Members of the Board

Jürgen Isbaner  
[isbaner@oemus-media.de](mailto:isbaner@oemus-media.de)

Lutz V. Hiller

[hiller@oemus-media.de](mailto:hiller@oemus-media.de)

### Chief Editorial Manager

Dr Torsten Hartmann (V. i. S. d. P.)  
[hartmann@dentalnet.de](mailto:hartmann@dentalnet.de)

### Editorial Council

Dr Rolf Vollmer  
[info.vollmer@t-online.de](mailto:info.vollmer@t-online.de)

Dr Georg Bach

[doc.bach@t-online.de](mailto:doc.bach@t-online.de)

Prof (CAI) Dr Roland Hille

[dr-hille@t-online.de](mailto:dr-hille@t-online.de)

Dr Suheil Boutros

[SMBoutros@aol.com](mailto:SMBoutros@aol.com)

### Editorial Office

Georg Isbaner  
[g.isbaner@oemus-media.de](mailto:g.isbaner@oemus-media.de)

Claudia Jahn

[c.jahn@oemus-media.de](mailto:c.jahn@oemus-media.de)

### Executive Producer

Gernot Meyer

[meyer@oemus-media.de](mailto:meyer@oemus-media.de)

### Product Manager

Timo Krause

[t.krause@oemus-media.de](mailto:t.krause@oemus-media.de)

### Designer

Sandra Ehnert  
[s.ehnert@oemus-media.de](mailto:s.ehnert@oemus-media.de)

Stephan Krause

[s.krause@oemus-media.de](mailto:s.krause@oemus-media.de)

### Customer Service

Marius Mezger

[m.mezger@oemus-media.de](mailto:m.mezger@oemus-media.de)

### Published by

OEMUS MEDIA AG  
Holbeinstraße 29  
04229 Leipzig, Germany  
Tel.: +49 341 48474-0  
Fax: +49 341 48474-290  
[kontakt@oemus-media.de](mailto:kontakt@oemus-media.de)

### Printed by

Silber Druck oHG  
Am Waldstrauch 1  
34266 Niestetal, Germany

### implants

international magazine of oral implantology is published in cooperation with the German Association of Dental Implantology (DGZI).

### DGZI

DGZI Central Office  
Paulusstraße 1  
40237 Düsseldorf, Germany  
Tel.: +49 211 16970-77  
Fax: +49 211 16970-66  
[office@dgzi-info.de](mailto:office@dgzi-info.de)

[www.dgzi.de](http://www.dgzi.de)

[www.oemus.com](http://www.oemus.com)

[www.implants.de](http://www.implants.de)

### Copyright Regulations

implants international magazine of oral implantology is published by OEMUS MEDIA AG and will appear in 2017 with one issue every quarter. The magazine and all articles and illustrations therein are protected by copyright. Any utilization without the prior consent of editor and publisher is inadmissible and liable to prosecution. This applies in particular to duplicate copies, translations, microfilms, and storage and processing in electronic systems. Reproductions, including extracts, may only be made with the permission of the publisher. Given no statement to the contrary, any submissions to the editorial department are understood to be in agreement with a full or partial publishing of said submission. The editorial department reserves the right to check all submitted articles for formal errors and factual authority, and to make amendments if necessary. No responsibility shall be taken for unsolicited books and manuscripts. Articles bearing symbols other than that of the editorial department, or which are distinguished by the name of the author, represent the opinion of the afore-mentioned, and do not have to comply with the views of OEMUS MEDIA AG. Responsibility for such articles shall be borne by the author. Responsibility for advertisements and other specially labeled items shall not be borne by the editorial department. Likewise, no responsibility shall be assumed for information published about associations, companies and commercial markets. All cases of consequential liability arising from inaccurate or faulty representation are excluded. General terms and conditions apply, legal venue is Leipzig, Germany.

Straumann® BLT Ø 2.9 mm – the SmallOne  
Another legend is born:  
Small, strong and enduring.



**LESS INVASIVE\***  
A perfect combination  
of shape, strength and  
healing power.



**NATURAL LOOKING  
ESTHETICS**  
Novel prosthetic design  
that closely matches the  
anatomy of teeth.



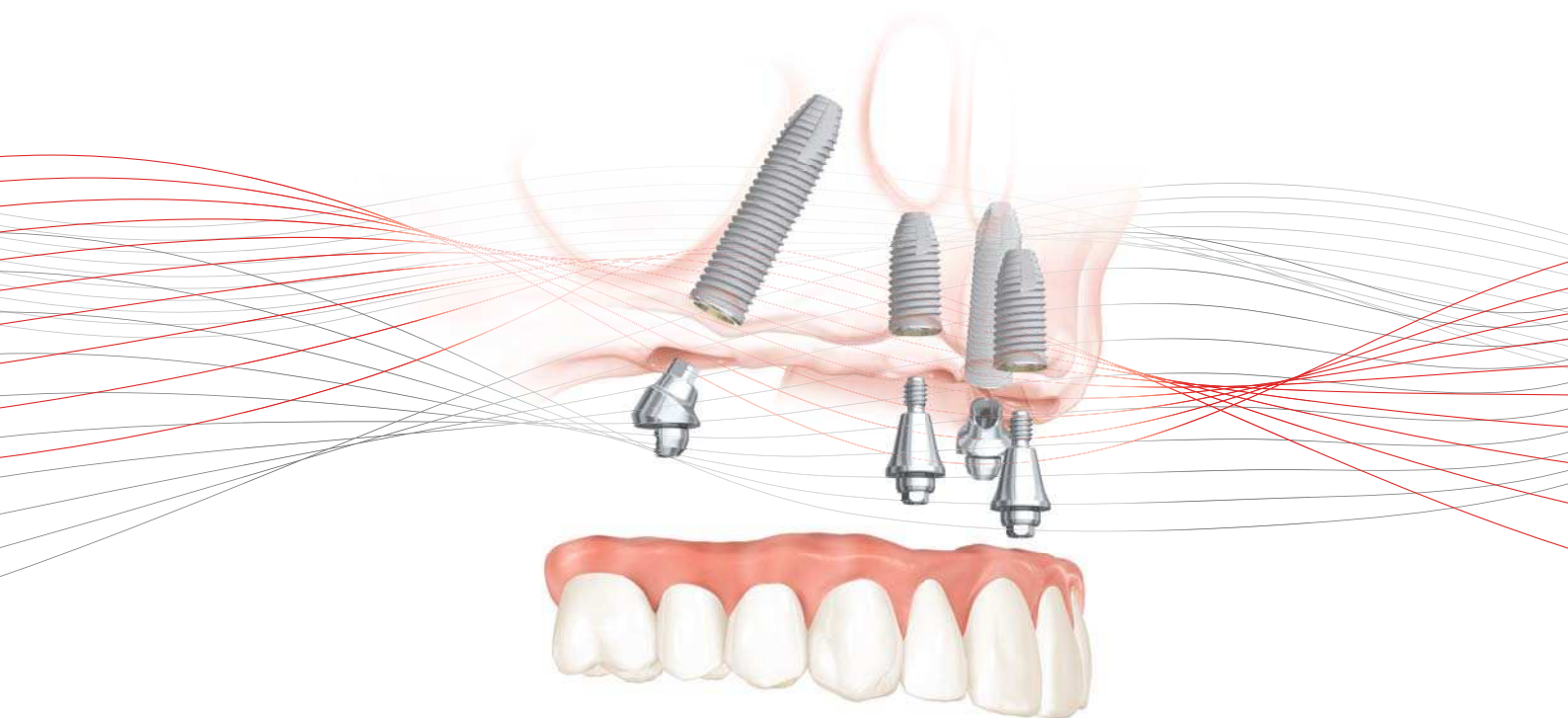
**FULL STRENGTH**  
A strong and reliable  
treatment option  
thanks to Roxolid®.



Contact your local Straumann® representative today to find out  
more about the SmallOne. Or visit [smallone.straumann.com](http://smallone.straumann.com).

\*if GBR can be avoided

# Original. Proven. Life changing.



## The All-on-4<sup>®</sup> treatment concept

**Four implants. A fixed full-arch provisional prosthesis. Same day.\***

Since it was first introduced in 1998, the All-on-4<sup>®</sup> treatment concept has changed the lives of hundreds of thousands of patients. Today, the concept is established as the best in its class of solutions, but only when Nobel Biocare products are combined.

Now supported by 34 clinical studies featuring 2400 patients, many have tried to mirror this groundbreaking concept, but only Nobel Biocare has the scientifically documented success to back it up.

Offer your patient life-changing treatment you can both rely on.

\*Provided stability criteria for immediate loading are fulfilled.



**New All-on-4<sup>®</sup> treatment concept  
online course**

**Register at  
[nobelbiocare.com/all-on-4course](http://nobelbiocare.com/all-on-4course)**

