

Immediate temporisation using tapered implants

Author: Dr Mohamad El Moheb, France

Immediate loading of implants is a predictable and successful¹ treatment option if it is well planned and well executed. An adequate implant stability is mandatory to permit early loading of the implant.² This treatment allows an immediate restoring of aesthetics and offers a more comfortable provisional for the patient.

Immediate temporisation (immediate loading) is a predictable technique. There are no significant differences concerning the implant survival, or marginal bone loss when it is compared to the conventional loading procedure.³

The patient selection in addition to the primary stability of the implant and the patient compliance with the surgeon's recommendations are important factors of the success of the immediate implant loading.⁴

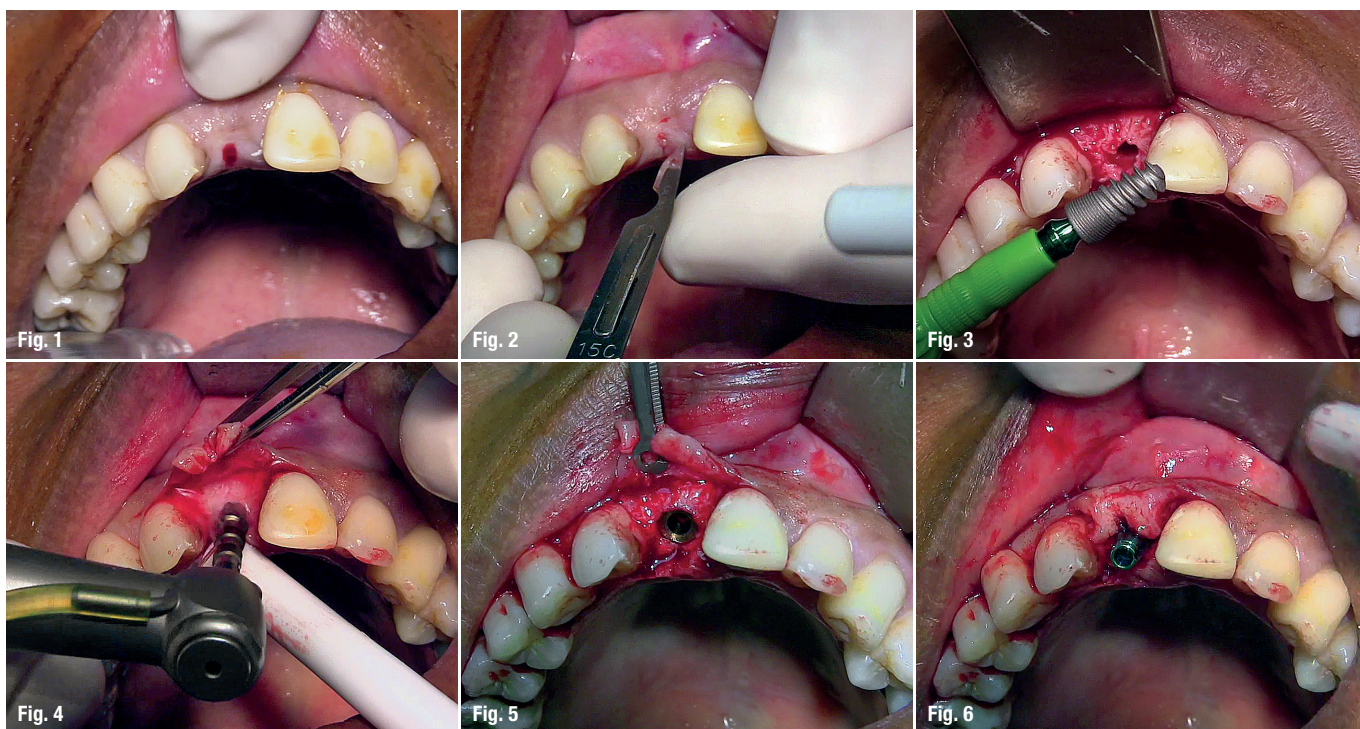
Background

Immediate temporisation of an implant in the anterior zone⁵ to replace a missing tooth is well documented. It is a predictable procedure and its results can be compared to a delayed one⁶ if an implant stability of 35 N can be reached⁷ and if the provisional crown is out of occlusion.

To achieve a high insertion torque and stability, the choice of which implant shall be used is primordial. The implant surface seems to play a role in the stability of the implant during insertion. This is due to the augmentation of the roughness, which will increase the friction coefficient⁸ and demand a larger insertion torque.

The implant design plays a key role in primary stability as well as the insertion torque. It has been

- Fig. 1:** Central incisor had been missing for several years.
- Fig. 2:** Concave semilunar incision towards the palate.
- Fig. 3:** Self-taping implant increases bone density by condensation.
- Fig. 4:** Drilling.
- Fig. 5:** Implant insertion at 35 N.
- Fig. 6:** Implant abutment.

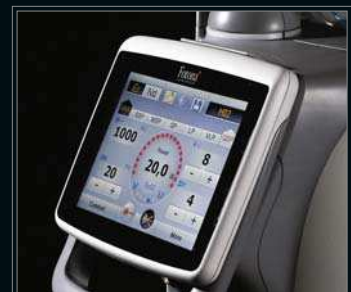

The universe at your fingertips.

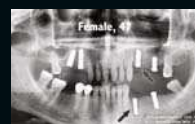
TwinLight[®] Peri-implantitis Treatment

A simple and effective procedure that offers the power to treat peri-implantitis – an increasing threat to oral health.

- Minimally-invasive technique
- Fast regeneration/healing
- Reduced inflammatory response
- Highly effective treatment
- No antibiotics needed



Peri-implantitis treatment video



LightWalker[®]

www.lightwalkerlaser.com

demonstrated that the tapered implant offers a better primary stability and the highest insertion torque.⁹ The thread design is also a major factor in the stability of the implant.¹⁰

Clinical case

A female patient, 50 years old, presented with a central incisor which had been missing for several years (Fig. 1). The patient was wearing a removable prosthesis to replace the missing tooth. The colour of the tooth had started to change and the patient was not happy with the solution any longer. As the medical questionnaire showed, the patient does not have any systemic diseases. All in all, the patient was in a good general health.

The extraoral and the dynamic examination showed a normal opening trajectory with no deviation. The intraoral examination revealed missing teeth in the left posterior mandibular. The patient was wearing also a removable prosthesis. There were some obturations but all in all the oral hygiene was good.

The patient's major complaint concerned the aesthetic. She wanted to replace the removable prosthesis as soon as possible with a fixed tooth. This removable prosthesis was an obstacle that disturbed her in her professional and personal life.

The cone beam of the patient showed enough thickness of the bone that allows a high primary

stability¹¹, which is a crucial factor for immediate loading.¹² Therefore, it was decided to perform implant placement and immediate loading or immediate temporisation in this case.

After the injection of anaesthetics, the first incision design is very important. It allows to create an interdental papilla during the healing phase. Therefore, the incision has to be a concave semilunar incision towards the palate (Fig. 2). The implant system chosen in this case was ROOTT Form (TRATE) because of its macro design that allows a high and predictable stability. The system is a self-taping and bone condensing implant.¹³ This type of implant can increase the implant stability by increasing the bone density by condensation (Fig. 3).

After the drilling (Fig. 4) and implant insertion at 35 N¹⁴ (Fig. 5), the implant abutment (Fig. 6) was placed and a temporary crown was done (Fig. 7). The temporary was out of occlusion, its aim was only to restore the aesthetic, to create a good emergence profile and to maintain the new papillae. Two months later, the temporary crown was taken out (Fig. 8) to make an impression (Figs. 9 & 10) and place a final crown (Figs. 11–13).

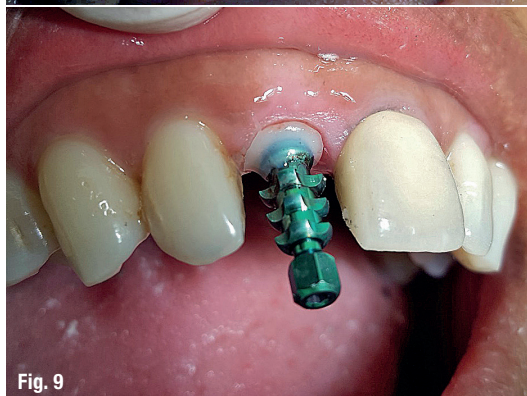Discussion

Immediate loading or immediate temporisation is a well-documented procedure. The Immediate loading of implants in the maxilla is a successful

Fig. 7: Temporary crown.

Fig. 8: Two months later: temporary crown was taken out.

Figs. 9 & 10: Impression making.

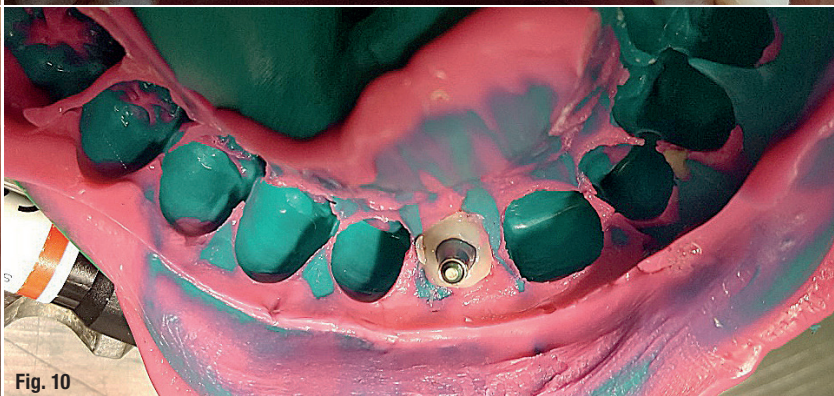
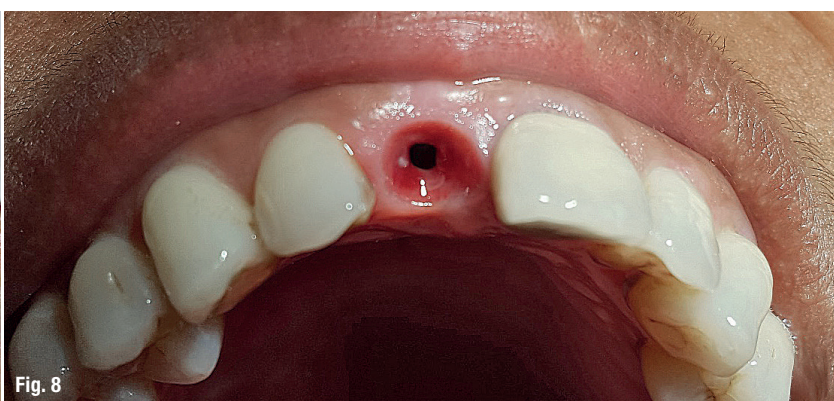
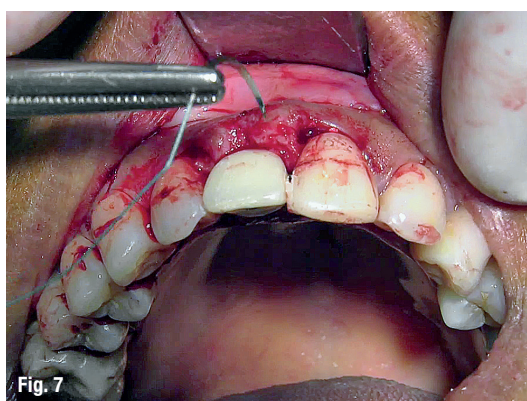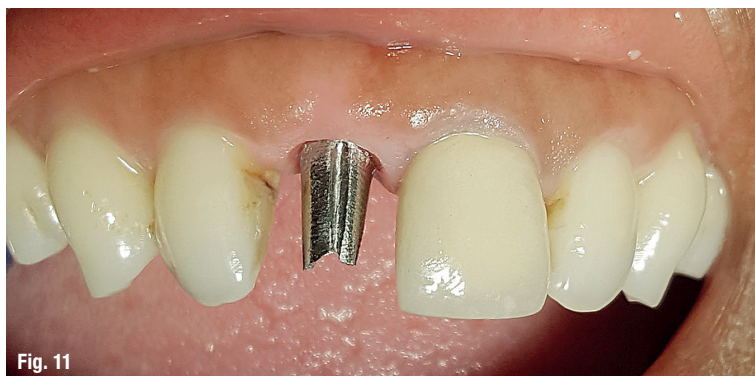




Fig. 11

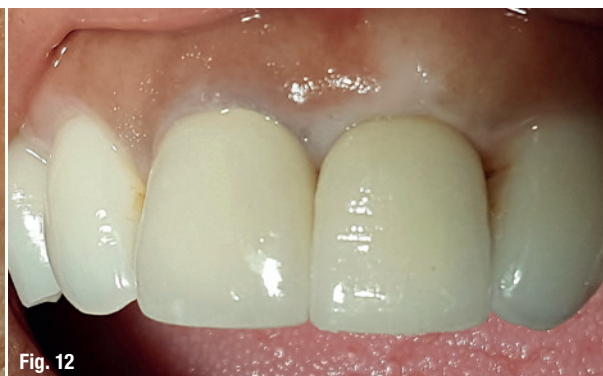

Fig. 12

and predictable treatment option with failure rates approaching those of the traditional two-stage surgery.¹⁴ The most important factors of immediate loading are the primary stability and immediate torque. The torque should be at 35 N at least.¹⁴ The choice of the implant or the surgical procedure is also important to achieve a high-insertion torque. It seems that a self-taping implant may increase implant stability and high-insertion torque.¹³

The macro-design of the implant is very important because a tapered implant may condense the bone around the implant to achieve greater implant stability.¹⁵ Immediate temporisation can be an interesting technique to reduce the treatment time and to make it more comfortable for the patient. This technique is predictable if the conditions of insertion torque and the provisional crown being out of occlusion are respected. The patient selection and cooperation are also crucial factors for the treatment success.

Conclusion

Before starting the surgery, the surgeon should decide if he or she wants to perform an immediate load procedure or not. The decision should be based on the surgeon's ability, the residual bone height and width, the occlusion of the patient and the patient's motivation and hygiene.

As the stability is one of the crucial factors in the success of the immediate loading or immediate temporisation procedure⁴, the surgeon should be able to secure this stability of at least 35 N⁷ by following an appropriate drilling protocol and choosing the right implant. The combination of implant design and surgical osteotomy plays an important role in the implant stability. In this case, we chose an implant that allowed us to achieve this crucial condition in almost all cases.

To achieve a high primary stability which allows to use the immediate load procedure, it is better to

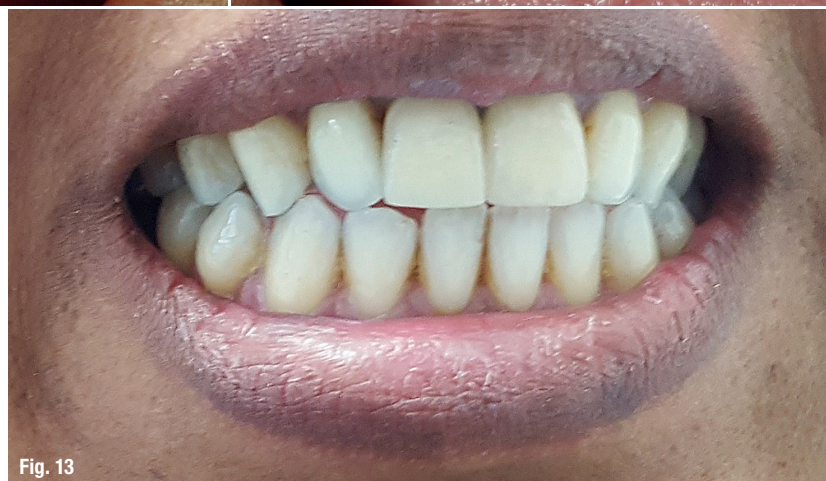

Fig. 13

choose a tapered implant that facilitates bone condensation around the implant and with this offering the wanted primary stability. The implant length is also important: the bigger the implant, the bigger the implant/bone contact and the bigger the stability. A long implant also allows a fixation in the cortical area which increases the stability of the implant.

Figs. 11–13: Final crown.

contact

Dr Mohamad El Moheb

148 Avenue Jean Jaurès
93320 Les Pavillons-sous-Bois, France
Tel.: +33 148 486358

Author details



Literature

