

# Overcoming a difficult aesthetic situation

**Author:** Prof. Dr Dr M. Kemal Unsal, Turkey

## Introduction

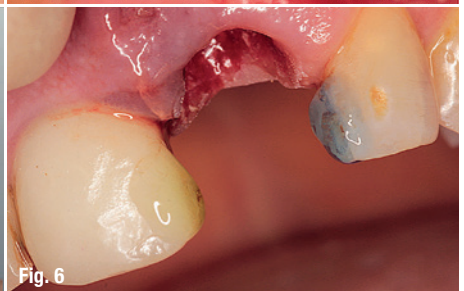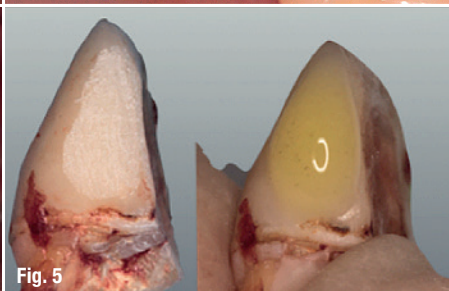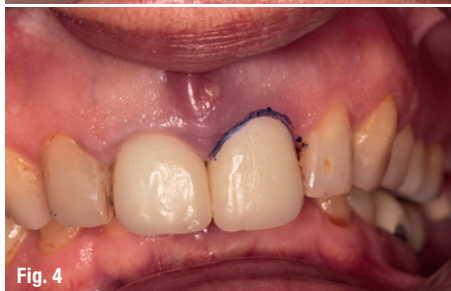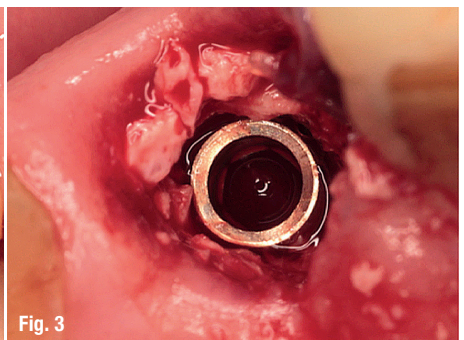
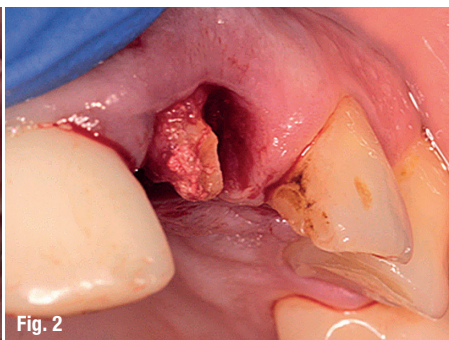
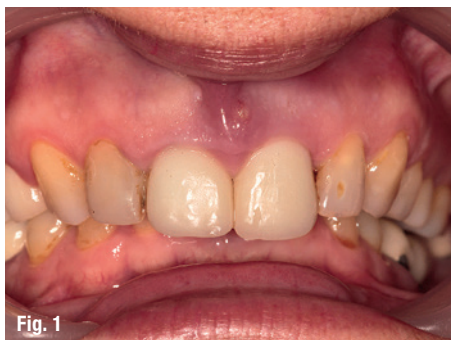Immediate implantation is becoming frequently applied in implant dentistry. Although this technique can be used in many situations, the cases which benefit most are the trauma cases. Associated with an aesthetic issue, the teeth suffering the most from trauma are the incisors. Immediate implant treatment can be the preference of the clinician who would like to cope with time restrictions and aesthetic issues. However, primary stability issues do not always meet immediate loading protocols. In that case, it is the responsibility of the surgeon not only to have an acceptable level of primary stability, but to predict the insertion depth of the implant in order to achieve an aesthetic outcome. In the presented case, the resorption prediction was not accurate enough. This special challenge was successfully mastered with the help of the implant manufacturer. The custom abutment prepared for this case was added to the NucleOSS catalogue as an option for all users of the system.

## Case report

A 58-year-old woman without any systemic disorders attended our clinic. Her main complaint was the increased mobility of her upper left central incisor #21. The mentioned tooth had received a root treatment and a ceramic laminate restoration ten years ago (Fig. 1). Upon intraoral and radiographic examination, the tooth was diagnosed with a horizontal crack and decided to be extracted (Fig. 2). The remaining broken root piece was also extracted as a single piece. An immediate NucleOSS T6 implant with a length of 12 mm and a width of 4.1 mm was inserted. The buccal aspect of the extraction socket was filled with a xenograft. As the buccal bone wall was intact, no membrane was used (Fig. 3).

It is quite possible to observe bone resorption around immediately placed implants. In order to avoid possible aesthetic problems due to this bone loss, clinicians generally tend to position the implant a bit deeper and palatally. The loss of a central upper incisor

- Fig. 1:** The tooth had received a root treatment and a ceramic laminate restoration ten years ago.
- Fig. 2:** Upon intraoral and radiographic examination, the tooth was diagnosed with a horizontal crack and decided to be extracted.
- Fig. 3:** As the buccal bone wall was intact, no membrane was used.
- Fig. 4:** Marking the gum level with a permanent pen just before extraction.
- Fig. 5:** Roughening of the glazed surface of the ceramic restorations with diamond burs.
- Fig. 6:** Application of only orthophosphoric acid of 36 per cent on the natural enamel of tooth #22 for 30 seconds and composite bonding.



CITO mini®

YES!



I WANT

THE CITO MINI®

MADE BY DENTAURUM.

More than 20 years of expertise, reliability  
and innovation in implantology – worldwide.  
Say yes!

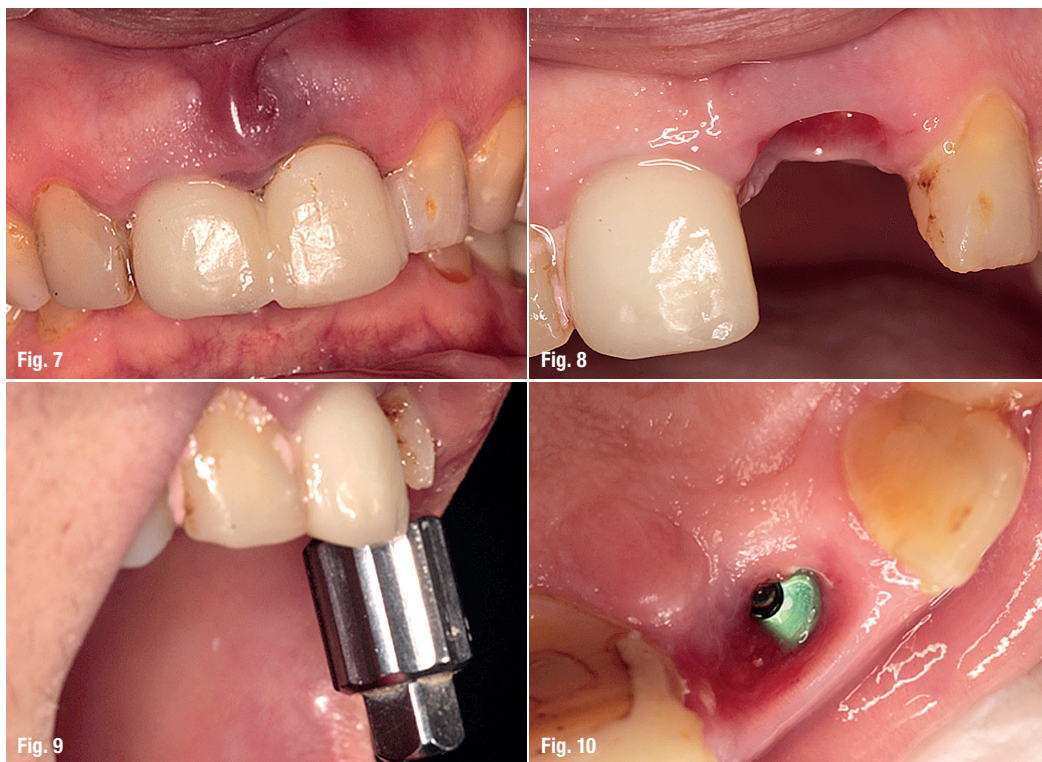


 **DENTAURUM**  
IMPLANTS

Turnstr. 31 | 75228 Ispringen | Germany | Phone +497231/803-0 | Fax +497231/803-295  
[www.dentaurum-implants.com](http://www.dentaurum-implants.com) | [info@dentaurum-implants.com](mailto:info@dentaurum-implants.com)



- Fig. 7:** The patient was advised to follow a soft diet and discharged.
- Fig. 8:** Minimum soft-tissue loss and an acceptable tissue contour.
- Fig. 9:** Checking the insertion angle of the implant.
- Fig. 10:** Removal of the cover screw.



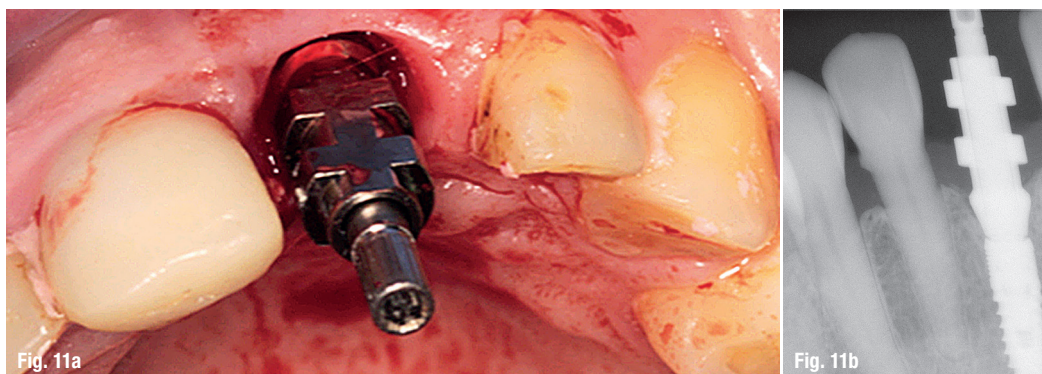
needs an immediate temporary restoration. The most time-saving and aesthetic restoration type is an immediate temporary crown attached to the implant. However, this practice needs an insertion torque of 30 Ncm or more. This case did not meet this criterion. Therefore, the idea of using the coronal part of the extracted tooth as a temporary restoration was considered. The gum level was marked with a permanent pen just before extraction (Fig. 4).

Due to an extensive deep bite, there was no room to use a fibre splint in order to achieve retention via the neighbouring teeth. The only remaining alternative was to attach the extracted coronal part using light-cured composite. One of the neighbouring teeth and the extracted coronal part was carrying a ceramic laminate, whereas the tooth #22 was yet untreated. Therefore, the glazed surface of the ceramic restorations was roughened with diamond burs and nine per cent HFl acid was applied, followed by silane and

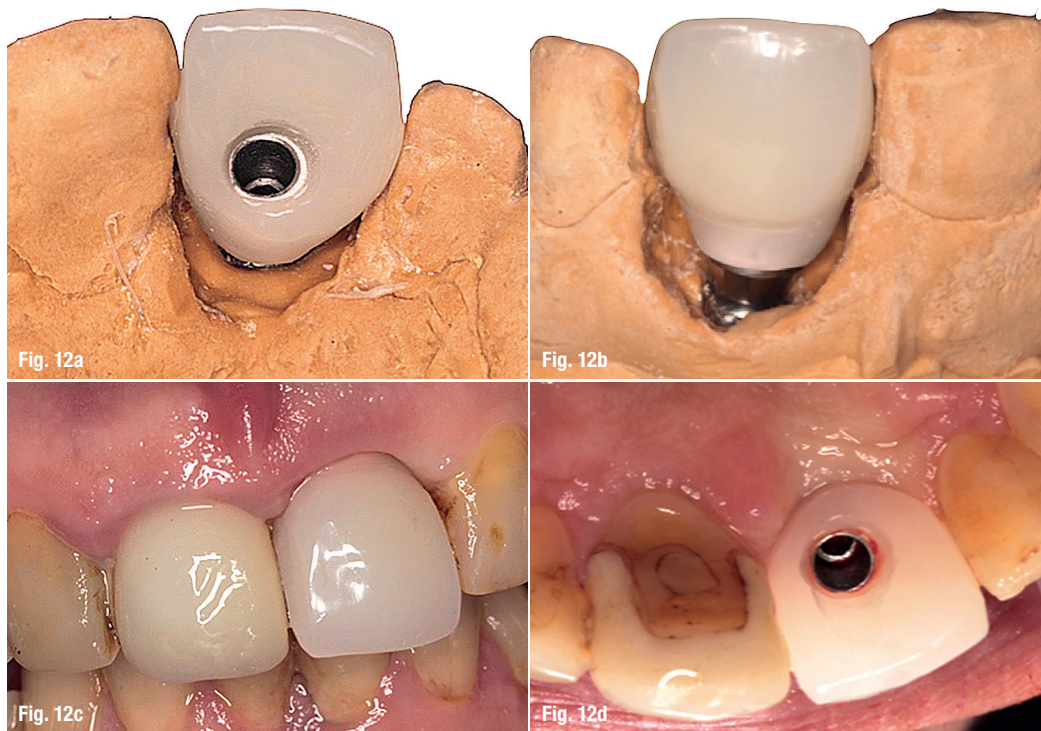
bond application (Fig. 5). On the natural enamel of tooth #22 only orthophosphoric acid of 36 per cent was used for 30 seconds followed by a composite bonding material application (Fig. 6). The patient was advised to follow a soft diet and discharged (Fig. 7). During the three-month healing period, the crown was de-attached twice. However, these appointments were also considered as an advantage as it allowed the clinician to add light curing composite material beneath the extracted crown. This way, a better crown profile was attained.

When osseointegration was achieved, the soft-tissue loss was minimal and an acceptable tissue contour was observed (Fig. 8). The insertion angle of the implant was checked (Fig. 9). In order to not damage the delicate soft tissue which could cause aesthetic problems, the cover screw was removed without surgical intervention (Fig. 10). An open-tray impression post was inserted, an X-ray was taken to verify the fit

**Figs. 11a & b:** Insertion of an open-tray impression post and X-ray.







**Figs. 12a–d:** Manufacturing and attachment of a screw-retained, temporary crown.

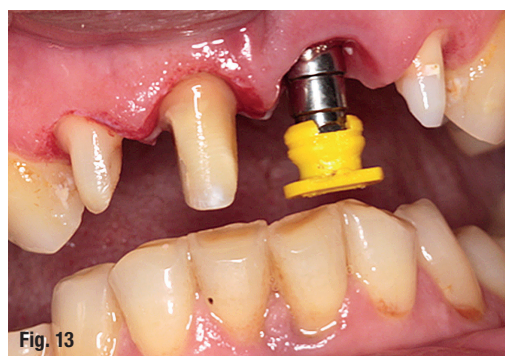and the impression was made (Figs. 11a & b). A screw-retained, temporary crown was manufactured and attached to the implant in order to achieve a better soft-tissue contour (Figs. 12a–d).

Following the final gum-tissue conditioning, a closed tray impression was made. However, due to the aesthetic demands of the patient, teeth #12, 11 and 22 were also prepared for metal-free ceramic restorations (Fig. 13) and the impression was taken. A custom-milled Zr abutment on a Ti-Base was ordered for the implant-retained restoration. Other teeth would receive a metal-free ceramic restoration.

At the try-in appointment, however, the clinician was unable to attach the custom-made abutment. The periapical radiography revealed the reason (Fig. 14). The implant was intentionally positioned deep in the coronal direction to avoid any aesthetic problems. However, Ti-Base custom abutments of nearly all companies have a shoulder design, on

which the custom-made Zr should stand. Ti-Base design is mainly used in aesthetic regions so it is very understandable that all designs intend to position the shoulder at the deepest level of the Ti-Base abutment. The design of a standard NucleOSS Ti-Base abutment is very similar to other companies' products. Its design can be seen in Figure 15.

The bone surrounding the implant did not allow the standard Ti-Base abutment to fit on the implant. This



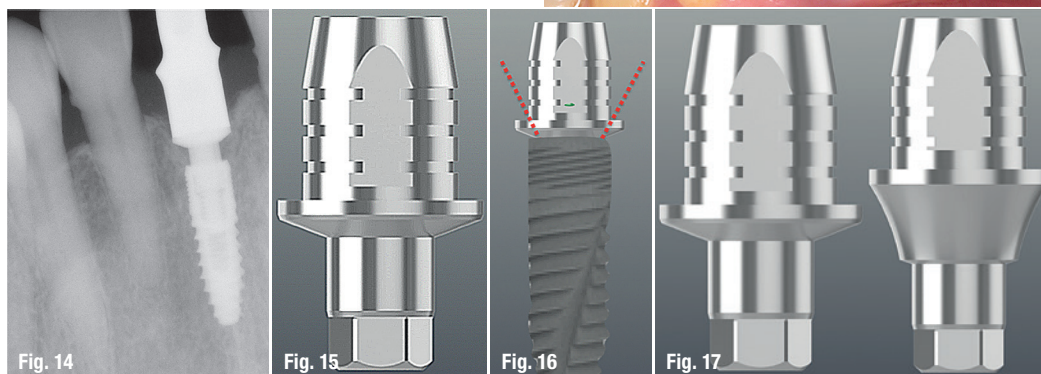
**Fig. 13:** Closed tray impression was made and preparation of tooth #12, 11 and 22 for metal-free ceramic restorations.

**Fig. 14:** At the try-in appointment the clinician was unable to attach the custom-made abutment.

**Fig. 15:** Design of a standard NucleOSS Ti-Base abutment.

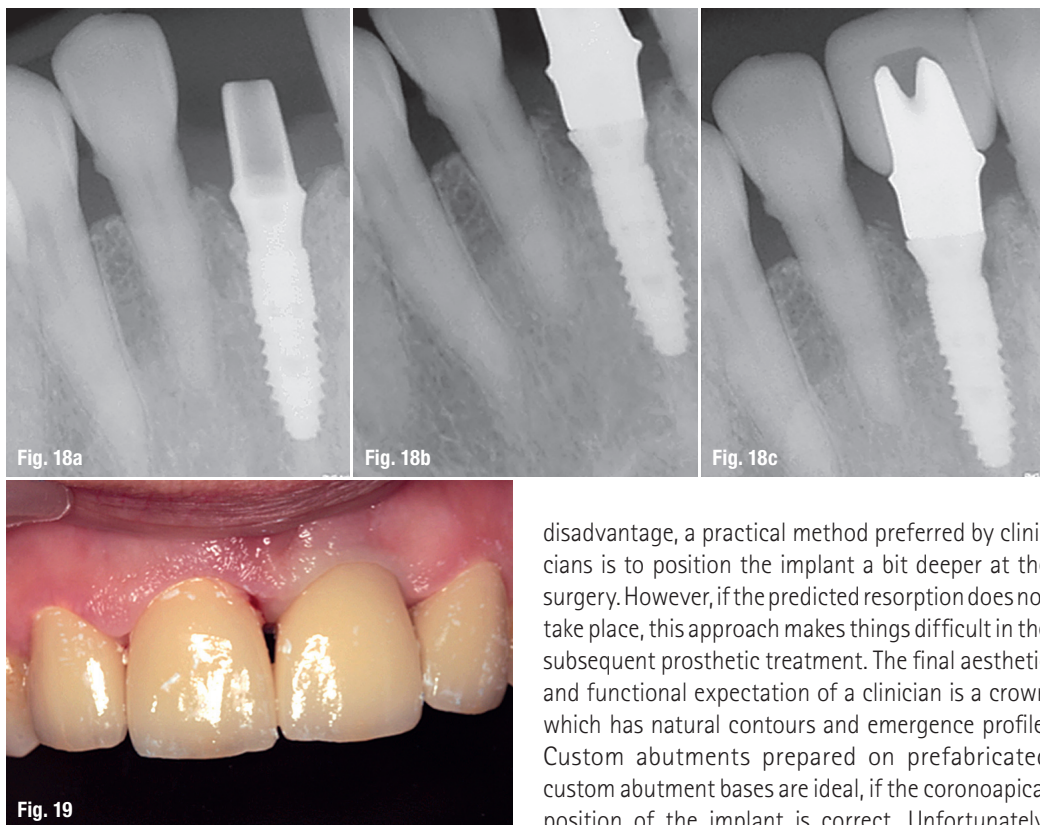
**Fig. 16:** The red-dotted lines demonstrating why the standard Ti-Base abutment was not able to meet the angle for the required fitting accuracy.

**Fig. 17:** Comparison of the new and old design of both Ti-Base abutments.



**Figs. 18a–c:** Radiographs at each stage of the new design.

**Fig. 19:** Final intraoral view of the patient.



situation could not be observed at the impression stage as the impression coping design were conical and did not pose any problems. The red-dotted lines in Figure 16 clearly demonstrates why the standard Ti-Base abutment was not able to meet the angle for the required fitting accuracy. At that stage, the only way to manufacture an acceptable restoration was an additional surgery which would re-contour the bone around the coronal portion of the implant. Such an intervention would not only lengthen the treatment time but carry a very high risk of aesthetic failure. In order to avoid such an outcome, the manufacturer designed a new custom Ti-Base abutment to be applied in these situations. The new and old design of both Ti-Base abutments can be seen in Figure 17 side by side.

The new design solved the problem for this case and now the product is available for general use. Radiographs at each stage of the new design can be seen in Figures 18a to c. The final intraoral view of the patient can be seen in Figure 19.

### Conclusion

Immediate implantation following tooth extraction is a popular treatment modality. It does not only shorten the whole treatment time but furthermore reduces the surgical procedure overall. However, it is not always easy to predict the postsurgical amount of resorption in every case. In order to overcome this

disadvantage, a practical method preferred by clinicians is to position the implant a bit deeper at the surgery. However, if the predicted resorption does not take place, this approach makes things difficult in the subsequent prosthetic treatment. The final aesthetic and functional expectation of a clinician is a crown which has natural contours and emergence profile. Custom abutments prepared on prefabricated custom abutment bases are ideal, if the coronal position of the implant is correct. Unfortunately, many implant companies do not offer variable gingival height options for these custom abutment bases.

The above case was such a misprediction of postsurgical resorption amount by the clinician, so that it was impossible to reach an aesthetic and functional emergence profile with the custom Ti-Base. The only way to reach a satisfying result was to perform an additional surgery which would be time wasting, costly and perhaps painful postoperatively. In order to overcome all disadvantages, the manufacturer thus enlarged its product line with a custom Ti-Base that has increased gingival height. With this new design, the clinician was finally able to reach his goal. Furthermore, the manufacturer included this new product in their catalogue for other clinicians who might face the same problem.

### contact

**Prof. Dr M. Kemal Unsal**  
 Prosthodontist  
 Gaziosmanpasa Mahallesi  
 Filistin sokak 2/8  
 06700 Cankaya/Ankara, Turkey  
 mkemalunsal@gmail.com

Author details






NucleOSS™

↑ uploaded.



With NucleOSS Implant App, we aim to provide a fast accesibility and updated information about our company, events, products, clinical cases,surgical manuals, prosthetic manuals and the latest developments.

*Available at Android, iOS and web browsers via PC.*



[www.muchmoreimplant.com](http://www.muchmoreimplant.com)

