

implants

international magazine of oral implantology

3 2017

case report

Natural preservation of the emergence profile

industry

Dynamic navigation in fully edentulous maxilla

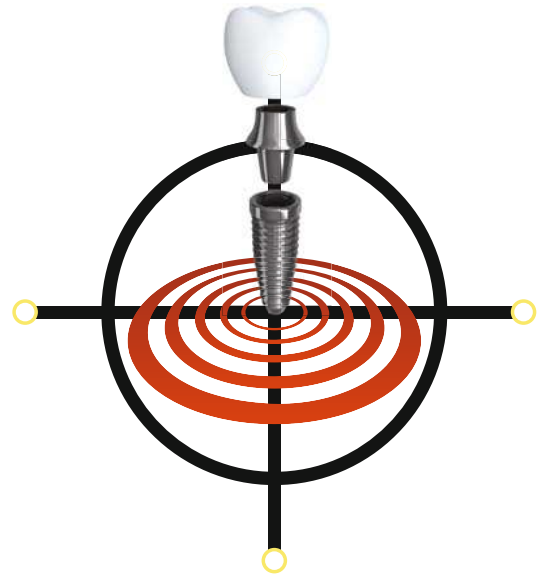
events

Joint meeting of the EAO and SEPES



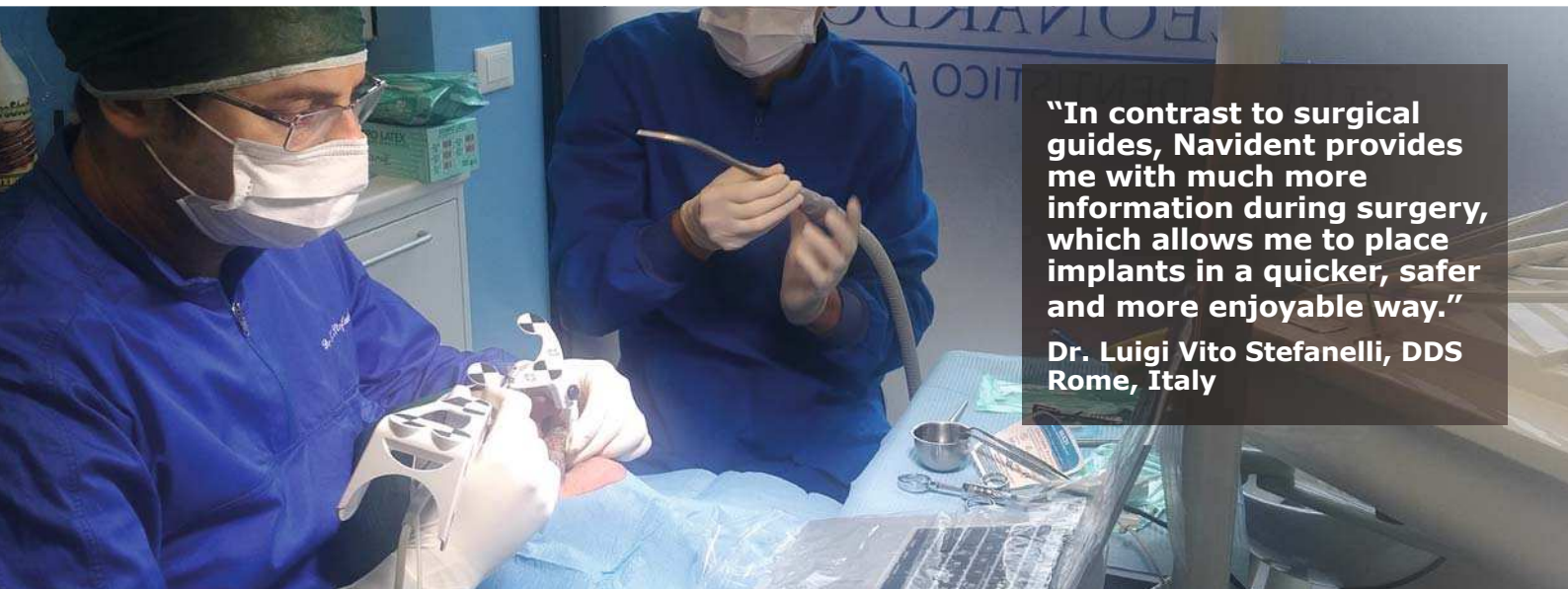Navident

Targeting Perfection



Dynamic navigation for freehanded dental implant placement

See for yourself how freehanded guided surgery aids more accurate implant placement. Navident tracks the drill and the patient's jaw, providing real-time tactile guidance and visual feedback.



"In contrast to surgical guides, Navident provides me with much more information during surgery, which allows me to place implants in a quicker, safer and more enjoyable way."

**Dr. Luigi Vito Stefanelli, DDS
Rome, Italy**

Compatible with any implant type, drill system and all CBCTs currently on the market

- Precision guidance for increased accuracy within 0.5mm of treatment plan*
- Provides even greater value from your CBCT data
- Easy to use, reducing time and expense with a simplified workflow
- Enables minimally invasive flapless drilling without a physical guide



Try Navident's precision guidance for yourself.

Call +32.475.75.52.26 or email info@claronav.com

Visit us at Booth n° S31 at EAO-SEPES joint meeting 2017

ClaroNav
www.claronav.com

*Average error of 0.4mm in internal bench tests with a range of operating conditions.

Does **biology** still matter?



Prof. (CAI) Dr Roland Hille

On 29 and 30 September 2017, the German Association of Dental Implantology (DGZI) and dental implant professionals will meet for the 47th International Annual Congress in Berlin, Germany. At the heart of the two day congress stands the question of "Does biology still matter?". Our thoughts and actions today are increasingly defined by "higher, faster, further". But is this really the best and safest treatment strategy for our patients or would it not be more effective to combine implantology and biology in order to reach a successful treatment outcome? Various treatment strategies have already been tried and proven in practice and are science-based and largely foreseeable. Practitioners should follow and strive for those examples, particularly when entering implantology for the very first time. Because the challenges in this field are far from small. Our patients' wishes and expectations are often impossible to meet from a biological, physiological and hence aesthetic point of view.

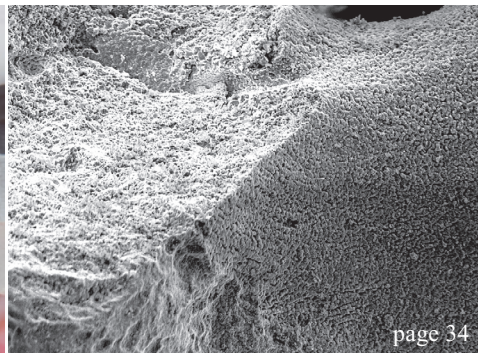
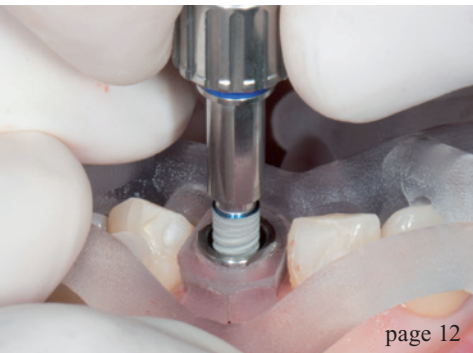
In addition, this year's update comprises the field of implantological prosthetics. Intensive discussions will focus here on the question of to what extent the conventionally practiced workflow is still contemporary. Or has the digital workflow already taken over the lead? In this light, it is crucial to examine the qualitative output and the preconditions that are required in order to ensure an adequate and standardised implementation. Furthermore, another important point of discussion will be the multi-morbidity of our patients with regards to extensive medication prescriptions. In this context, dentists are required to look outside their respective treatment areas and recognise the complexity of their patients' full clinical pictures. This, in turn, enables practitioners to fully assess possible risks involved in performing extensive surgical interventions. However, equally important for the implant success are the implant's biomechanics and the implant material, whether titan or ceramic is used. Which indication requires which implant, and what foreseeable difficulties might arise for the practitioner, based on those decisions, has also to be taken into account. Failure discussions, including identifying possible causes of the problem, will determine the future story of success.

Please come and join our panel discussion "DGZI kontrovers". Two experienced university professors will be talking about current scientific evidence and their practical experiences in using short implants while pursuing the question "Are shorties the all-purpose weapon in implantology?". High-quality training and celebrating are hallmarks of the DGZI! Therefore, on Friday we will celebrate as part of the legendary live show "Stars in Concert" and plunge into the sparkling world of show business. Excitement guaranteed!

And last but not least, Berlin is calling. The capital is always worth a visit and so are the practice-oriented international congresses of the DGZI!

Warm regards

Prof. (CAI) Dr Roland Hille
Vice President of the DGZI



| editorial

- 03 Does **biology still** matter?
Prof. (CAI) Dr Roland Hille

| research

- 06 **Immediate** restoration in the **digital** workflow
José Eduardo Maté Sánchez de Val &
José Luis Calvo Guirado

| case report

- 12 Natural **preservation** of the **emergence** profile
Dr Umut Baysal & Dr Arzu Tuna
- 18 Immediate **temporisation** using **tapered** implants
Dr Mohamad El Moheb

| industry

- 22 Overcoming a **difficult aesthetic** situation
Prof. Dr Dr M. Kemal Unsal
- 28 From **granules** to **foam**
Prof. Dr Dr Stefan Schermer

- 34 **Xenogeneic** bone **grafting** materials
Dr Mike Barbeck, Dr Ronald Unger,
Prof. Dr Frank Witte, Prof. Dr Sabine Wenisch &
Prof. Dr Dr Reiner Schnettler

- 38 **Dynamic** navigation in **fully** edentulous **maxilla**
Prof. Dr Hakan Uysal & Dr Noyan Başal

| events

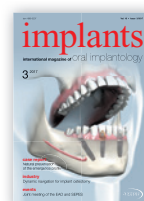- 52 **Arabian flair** and **French** charm
Dr Rolf Vollmer
- 54 Joint **meeting** of the **EAO** and **SEPES**

| news

- 42 **manufacturer news**
- 56 **news**

| about the publisher

- 58 **imprint**



Cover image courtesy of bredent medical GmbH & Co. KG
www.bredent-medical.com

a perfect fit™

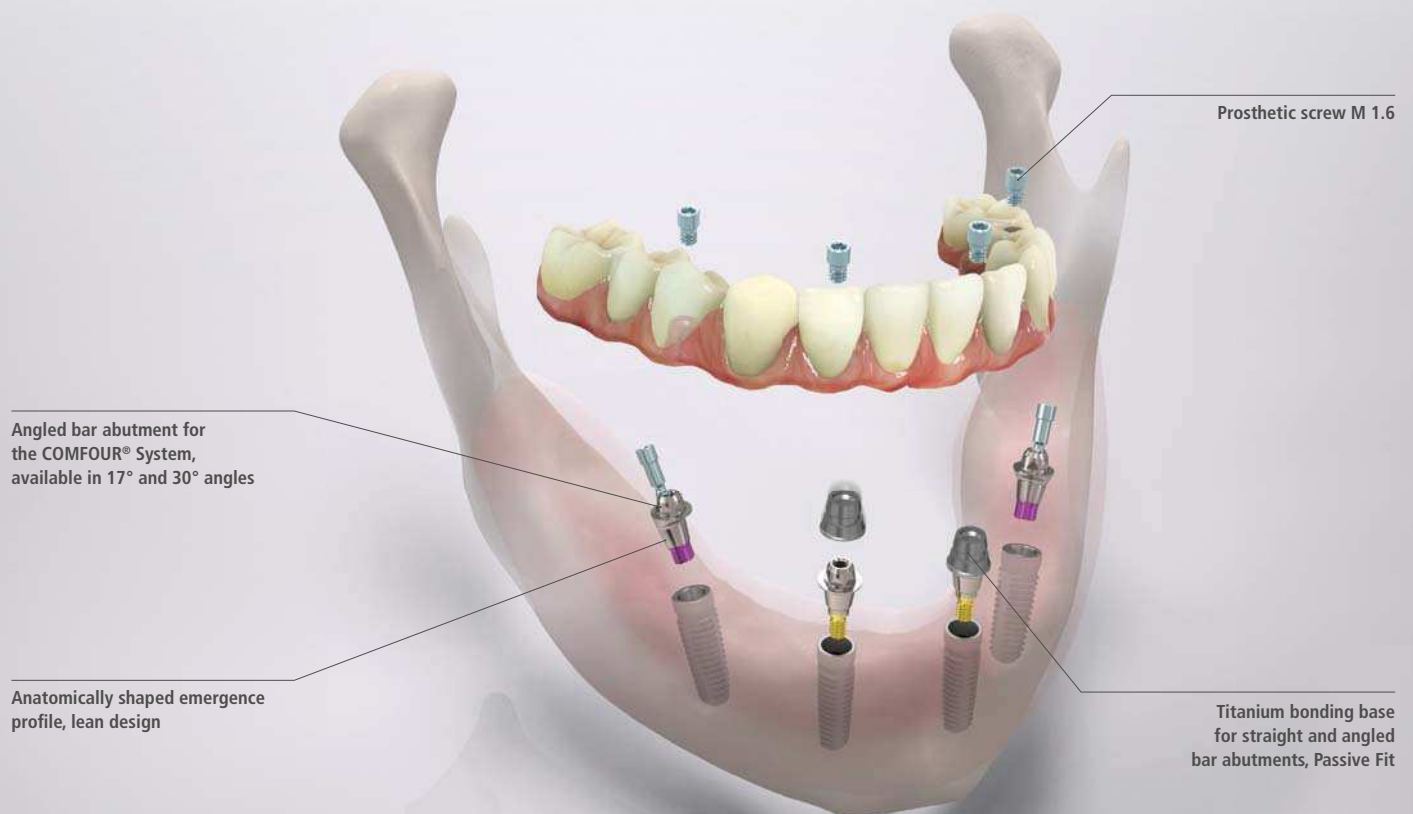camlog

THE NEW COMFORT CLASS.

The COMFOUR® Abutment System for occlusal screw-retained restorations is an ideal addition to the CAMLOG® and the CONELOG® Implant System. With the COMFOUR® System, you can offer your edentulous patients the option of an immediate, comfortable and permanent denture on four or six implants – and thus a considerable gain in quality of life. www.camlog.com

CAMLOG®
SYSTEM

CONELOG®
SYSTEM



Aligning tool



Scanning cap



Titanium cap



Flexible handle

COMFOUR® offers you a range of options to overcome the challenges you face in your implant practice, making them easier while saving time.

Immediate restoration in the digital workflow

Part II: Results and discussion

Authors: José Eduardo Maté Sánchez de Val & José Luis Calvo Guirado, Spain



The success of immediately placed implants has been investigated in various studies with encouraging results already. But what is rather simple in the anterior mandible needs more attention when it comes to the anterior maxilla. Here, clinicians are oftentimes concerned not only about achieving adequate implant stability, but also about fulfilling patients' desires for aesthetic results that resemble the natural dentition. To shorten procedures and eliminate intermediate prosthetic steps, digital technologies were developed that allow the intraoral scanning of models and attachments with a high degree of precision and reproducibility.

The article demonstrates the reliability of the single-session protocol using digital methods for scanning and producing crowns complemented with platform switching and evaluates the peri-implant soft-tissue seal. In part I of the article (published in *implants 2/17*), the authors described materials and methods used in an experiment with animals and in the treatment of humans. In part II of the article, the results are presented and discussed.

Rationale for immediate restoration

Research has shown that, for two-stage implants, marginal bone loss occurs primarily during the first year following placement and that this has mainly been attributed to the establishment of biologic width adjacent to the implant.¹⁹ Some studies have shown that bone remodelling can be biologically ascribed to bacterial colonisation of the micro-leakage present in a two-stage implant system and subsequent inflammation.²⁰ The crestal bone loss around implants has both horizontal and vertical components. Following abutment connection, crestal bone has been shown to recede from the implant/abutment junction microgap by 1.3 to 1.4 mm, measured horizontally.²¹

Animal study

Immediate implant placement and restoration minimise the harmful contamination of the peri-implant biological space and the resultant bone resorption. Immediate loading requires that certain prerequisites are met. The best way to objectively quantify the feasibility of immediate loading clinically is to analyse implant stability either by measuring the insertion torque, recommended at above 30 Ncm, or using the Osstell Mentor ultrasonic stability measuring device that returns ISQ values, which if above 65–70 allow us to load immediately with some confidence (Tab. 1).

Changes in the peri-implant tissue can be quantified by histomorphometry and histological evaluation in experimental studies (Tabs. 2 & 3). The radiological results of the animal experiments are documented in Figures 1a & b and Table 4. The histological connection between the soft tissue and the SKY elegance abutment is tight. In combination with platform switching, this produces a high level of bone stability at the implant collar (Figs. 2a & b).

Tab. 1: Friedman test of ISQ analysis and measurements at initial day. Results as mean and medians.

No significant differences with $p < 0.05$ were found.

Tab. 2: Friedman test of BIC values. Comparison between titanium and hybrid PEEK-Ti abutments. Follow-up eight weeks after implant placement. Data shows mean, Sd and medians.

No significant differences with $p < 0.05$ were found.

ISQ value	Insertion		p value
	Mean ± Sd	Median	
BioHPP abutment	74.46 ± 4.55	74.46	0.16
Titanium abutment	74.19 ± 4.29	74.19	0.23

Table 1

BIC (%)	Titanium	PEEK	p value
Mean ± Sd	61.29 ± 1.45	62.52 ± 4.63	0.32
Median	61.29	62.52	

Table 2

		Titanium	PEEK	p value
PM-BC	Mean ± Sd	2.74 ± 0.41	3.11 ± 0.26 *	0.032
	Median	2.74	3.11	
PM-LC	Mean ± Sd	2.91 ± 0.03	3.71 ± 0.18 *	0.008
	Median	2.91	3.71	
PM buccal-IS	Mean ± Sd	2.35 ± 0.87	2.95 ± 0.53 *	0.015
	Median	2.35	2.95	
PM lingual-IS	Mean ± Sd	2.65 ± 0.43	3.57 ± 0.38 *	0.003
	Median	2.65	3.57	
IS-BC	Mean ± Sd	2.04 ± 0.11 *	1.53 ± 0.21	0.011
	Median	2.04	1.53	
IS-LC	Mean ± Sd	1.93 ± 0.14 *	1.41 ± 0.19	0.029
	Median	1.93	1.41	

Table 3

Linear measurements in millimetre: PM-BC: distance from the peri-implant mucosa to the buccal bone crest; PM-LC: distance from the peri-implant mucosa to the lingual bone crest; PM buccal-IS: distance from peri-implant mucosa to the implant shoulder in the buccal aspect; PM lingual-IS: distance from peri-implant mucosa to the implant shoulder in the lingual aspect; IS-BC: distance from the top of the implant shoulder to the first bone-to-implant contact in the buccal aspect; IS-LC: distance from the top of the implant shoulder to the lingual bone crest. Values as mean ± Sd and median.

Tab. 3: Non-parametric Friedman test to related samples. (*) Significant differences with $p < 0.05$.

Rationale for platform switching

The switch in implant platform diameter prevents apical migration of the epithelial attachment and soft-tissue ingrowth at the top of the platform by reducing bacterial migration and, consequently, of soft-tissue ingrowth and peri-implant bone loss. Marginal bone loss is drastically reduced and the objective criteria for peri-implant inflammation are greatly improved.²²

Human study

Table 5 lists clinical parameters from human studies at one, three and five months. Figures 3a to h show radiological findings at one, three and five months. Figures 4a and b show the customisation of a SKY elegance abutment.

Rationale for single-stage treatments

Successive insertions and reconnections when restoring an implant accord-

ing to conventional protocols provoke bacterial invasion and colonisation of the biological space and mark the onset of marginal bone loss. Offering treatment in a single session provides the biological benefits described and saves time and money, increasing patient satisfaction.²³

Intraoral scanning

Fabricating a CEREC crown requires a step prior to intraoral scanning, namely the adaptation of the prosthetic support. The SKY elegance abutment can be cut and customised in the mouth, more or less like dentin, which means a reduction in time and cost. Also required are a delicate surface polish and preparation of the profiles to be recognised by the intraoral scanner. The restoration margins should be well-defined and prepared to the gingival or subgingival level.^{24,25} The SKY elegance abutment anatomy allows to create a proper emergency profile that can be customised for



Shortest Implants – Longest History.

Think Short!

For more than 30 years Bicon® short implants are unchanged in clinical use.

According to the 11th European Consensus Conference (EuCC) 2016 in Cologne, provided the specific treatment parameters are observed, the use of short, angulated or diameter-reduced implants in sites with reduced bone volume can be a reliable treatment option, given the risks associated with the use of standard-dimension implants in combination with augmentation procedures.

For more information:

Bicon Europe Ltd.

Hauptstr. 1

55491 Buechenbeuren

Germany

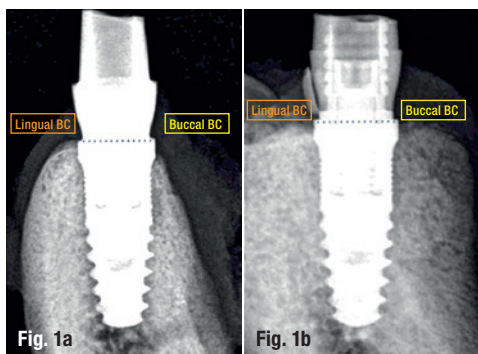
Phone +49 (0)6543 818200

germany@bicon.com

www.bicon.de.com



bicon
DENTAL IMPLANTS



Figs. 1a & b: Radiological analysis. Comparison between a titanium abutment (a) and a SKY elegance abutment (b).

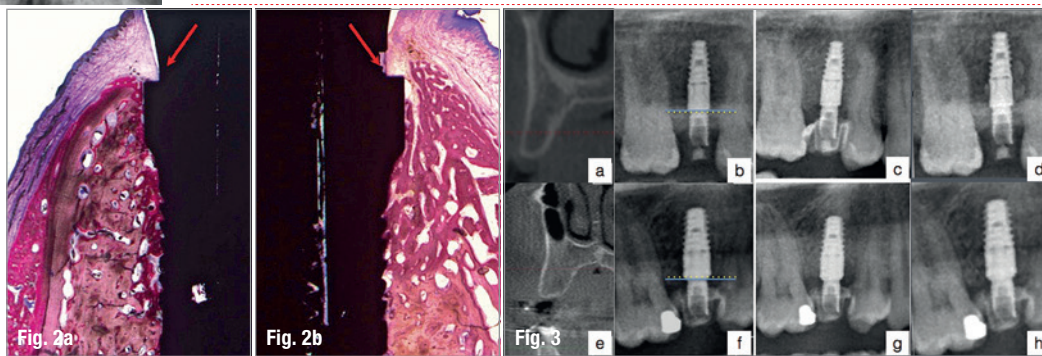
Tab. 4: Radiological analysis of bone first contact distance to the implant shoulder. Values as mean ± Sd and median. Non-parametric Friedman test analysis. (*) Significant differences with $p < 0.05$.

Figs. 2a & b: Histological analysis of the SKY elegance abutment. Detail of platform switching and connective-tissue insertion over platform. Connective tissue at four weeks (a). Connective tissue at eight weeks (b).

Figs. 3a–h: Radiological analysis. Preoperative (a, e), at one month (b, f), at three months (c, g), and at five months (d, h).

		Titanium	PEEK	p value
Buccal bone	Mean ± Sd	1.96 ± 0.21 *	1.43 ± 0.11	0.013
	Median	1.96	1.43	
Lingual bone	Mean ± Sd	1.78 ± 0.33 *	1.28 ± 0.43	0.031
	Median	1.78	1.28	

Table 4



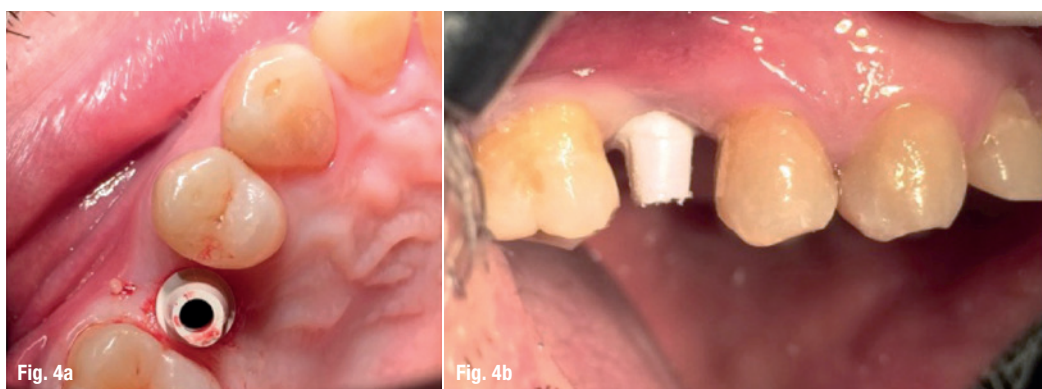
each patient (Fig. 5). The next step is to obtain relative relative isolation, with any hint of moisture removed, to ensure a good intraoral impression. The savings in terms of time and money are evident, as is the increase in patient comfort.

Fabricating a CEREC crown

The choice of restorative material to use on an implant requires familiarity with the way masticatory forces are transmitted via the crown and abutment

to the bone-to-implant contact area. Biomimetics is the study of the materials that allow us to adapt prosthetic elements to their intended proper function, based on similarity to the receiving environment.²⁶ Knowing how forces are transmitted is essential to avoid loads that can lead to bone loss or implant failure.

The SKY elegance is a hybrid abutment with a titanium base and a ceramically reinforced PEEK body, so the transmission of forces from the crown to the



Figs. 4a & b: Customisation of a SKY elegance abutment.

Tab. 5: Human study, values as mean ± Sd. Non-parametric Friedman test. Values of bleeding on probing (0 = no bleeding on probing and 1 = bleeding on probing).


		1 month	3 months	5 months	p value
Mean ± Sd	First bone contact to platform (mm)	0.50 ± 0.41	1.07 ± 1.12	1.17 ± 0.87	0.044
	ISQ value (%)	68.10 ± 4.93	69.34 ± 1.22	71.43 ± 3.01	0.12
	Bleeding on probing (0–1)	0.21 ± 0.01	0.16 ± 0.05	0.06 ± 0.02	0.014
	Insertion length (mm)	3.64 ± 1.02	4.19 ± 1.05	4.11 ± 1.02	0.029

Table 5



MIS GLOBAL
CONFERENCE 2018

360° IMPLANTOLOGY NASSAU PARADISE ISLAND, BAHAMAS, 8-11.02, 2018



LEARN THE EASY WAY. MAKE IT SIMPLE

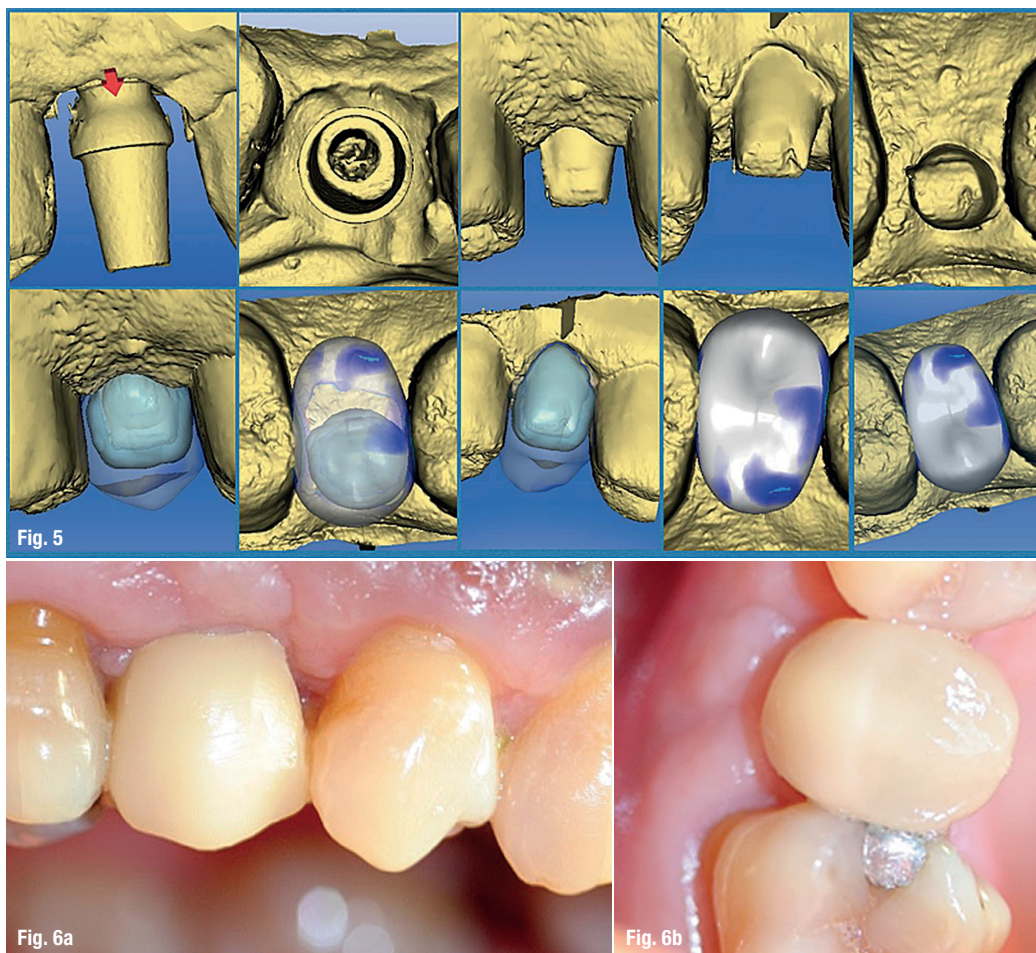
MIS is pleased and honored to invite you to the 4th MIS Global Conference: 360 IMPLANTOLOGY, in beautiful Nassau Paradise Island, Bahamas. This Global Conference will deliver an intense and unforgettable experience in every aspect: scientific, professional and personal. [For registration, please contact your local MIS Representative.](#)

mis[®]

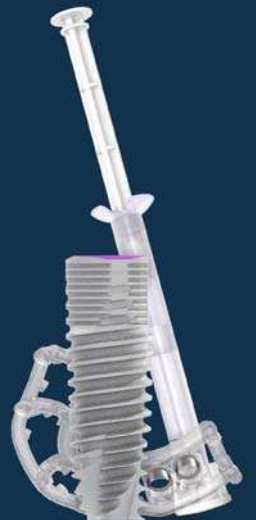

Fig. 5: Customising the SKY elegance abutment and crown design with CEREC.

Fig. 6: Final restoration at the day of surgery **(a)**. Detail of soft-tissue attachment **(b)**.



implant proceeds gradually and progressively. This helps avoid crown fractures due to internal or external tension between a ceramic crown and an all-ceramic abutment.


Using a hybrid abutment approach, there is a choice of resin or ceramic base materials, from feldspar ceramics to ceramics with a silicate base. This still leaves the interface to consider; here, the crown is best connected to the abutment using a resin-based composite cement that facilitates the gradual transmission of forces; also, these cements are more stable biomechanically than ionomer cements or derivatives (Figs. 6a & b).

Conclusion

The establishment of a stable peri-implant seal to maintain gingival health around implant-supported restorations must be a primary objective of any implant treatment. The single-stage approach allows the establishment of an initial peri-implant soft-tissue attachment that will be preserved as the abutment is not removed; hence, no violation of the biologic space will occur, allowing for greater tissue stability and yielding better aesthetics and an improved bone and soft-tissue stability.


The integration of digital technology (CEREC) in the implant/restorative process shortens the treatment time and reduces the cost for the patient. The SKY elegance abutment helps treat patients with predictable results.

This article was first published in EDI Journal No 1/2016.



contact

José Eduardo Maté Sánchez de Val
 Plaza de Luceros n. 15, bj. izq.
 03004 Alicante, Spain
 jemate@ucam.edu



Dentsply Sirona does not waive any right to its trademarks by not using the symbols or 3267114-USX1610 © 2016 Dentsply Sirona. All rights reserved.

Astra Tech Implant System®

Our world is not flat

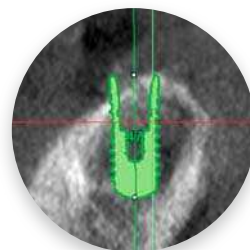
Neither is the anatomy of your implant patients

Your world is already full of clinical challenges so why work harder because of conventional thinking? Instead of augmenting sloped ridges to accommodate flat-top implants, it's time to discover a simpler solution by using an implant that follows the bone. Because sloped-ridge situations call for anatomically designed sloped implants.

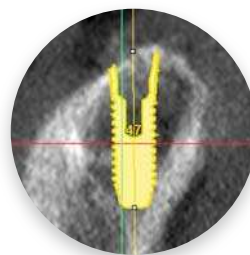
OsseoSpeed® Profile EV - It's time to challenge conventional thinking



www.profiledentalimplants.com



Conventional vs innovative approach



 **Dentsply
Sirona**
Implants

Natural preservation of the emergence profile

Authors: Dr Umut Baysal & Dr Arzu Tuna, Germany

Supplying single-tooth gaps with implants in the aesthetic zone is subject to strict evaluation. Objectively verifiable criteria like the "pink and white aesthetic score" were elaborated^{1,2} and scientific works focused mostly on the reconstruction of hard- and soft-tissue. However, these concepts are based on the principle of tissue reconstruction after tissue loss. The following case history pursues the approach of preventing resorption processes after tooth extraction.

Introduction

An implant that does not differ from the neighbouring, natural teeth, meets the demands of dentist and patient. Imitating nature is the top priority. The creation of natural, true-to-life surface structures allowing for the distribution of light reflection and absorption is key to perfect aesthetics. Modern ceramic materials facilitate the true-to-life reconstruction of dental hard tissue. If the tissue is not defective and allows for correct positioning of the implant, we can expect an aesthetically satisfying result.

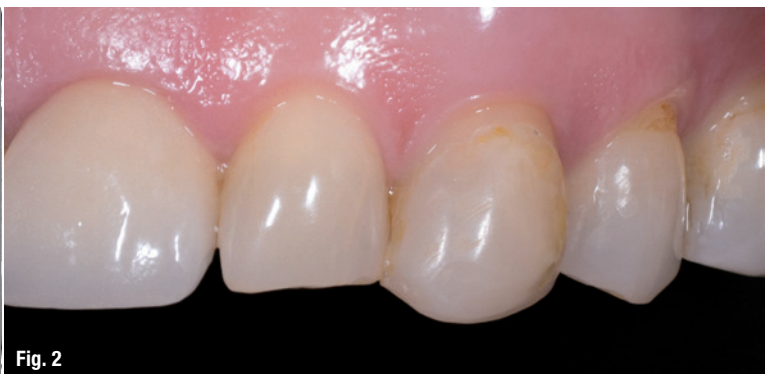If hard- and soft-tissues show deficits though, adequate augmentation is required. Despite various therapeutic options, the reconstruction of three-dimensional defects still requires great effort and cannot always be achieved completely.^{3,4} Many concepts in implantology deal with the principle of tissue re-

construction after tissue loss, even though methods of primary prevention of resorption processes are the actual key to success. Consequently, various methods like "socket preservation" and "ridge preservation" were developed in order to limit the horizontal and vertical changes after tooth extraction. In their overview survey, Darby et al. did not provide any conclusive references that these published techniques improved the potential implant locations.⁵ Another technique, the immediate implant, per se is not a ridge-preserving measure, which was proved in animal and clinical studies.^{6,7}

The procedure applied in the following is based on the "tissue master concept" by Stefan Neumeyer. Neumeyer was able to show that replanting root segments or highly resected teeth after extraction prevents the alveolar collapse and the subsequent extrusion leads to coronal movement of the alveolar tissue structures.⁸ After a period of stabilisation between three and six months, the cavities of the residual alveolar bone were filled entirely with osseous tissue. According to his case analyses, the cause seems to be the periodontal ligament (minimum width: 2 mm), which is able to convert mechanical stimulations into tissue reactions. Complete preservation and vertical gain of alveolar hard- and soft-tissue are predictable and clinically stable in the long term.⁹ Additional extrusion may induce the vertical gain of soft- and hard-tissue structures.^{9,10}

Fig. 1: Initial condition of tooth 23 on single-tooth radiograph.

Fig. 2: Intraoral initial condition of tooth 23.

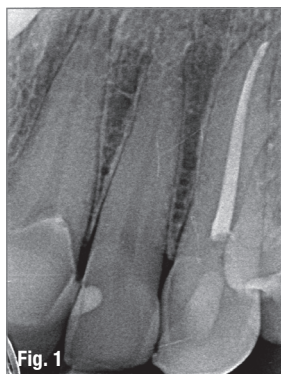

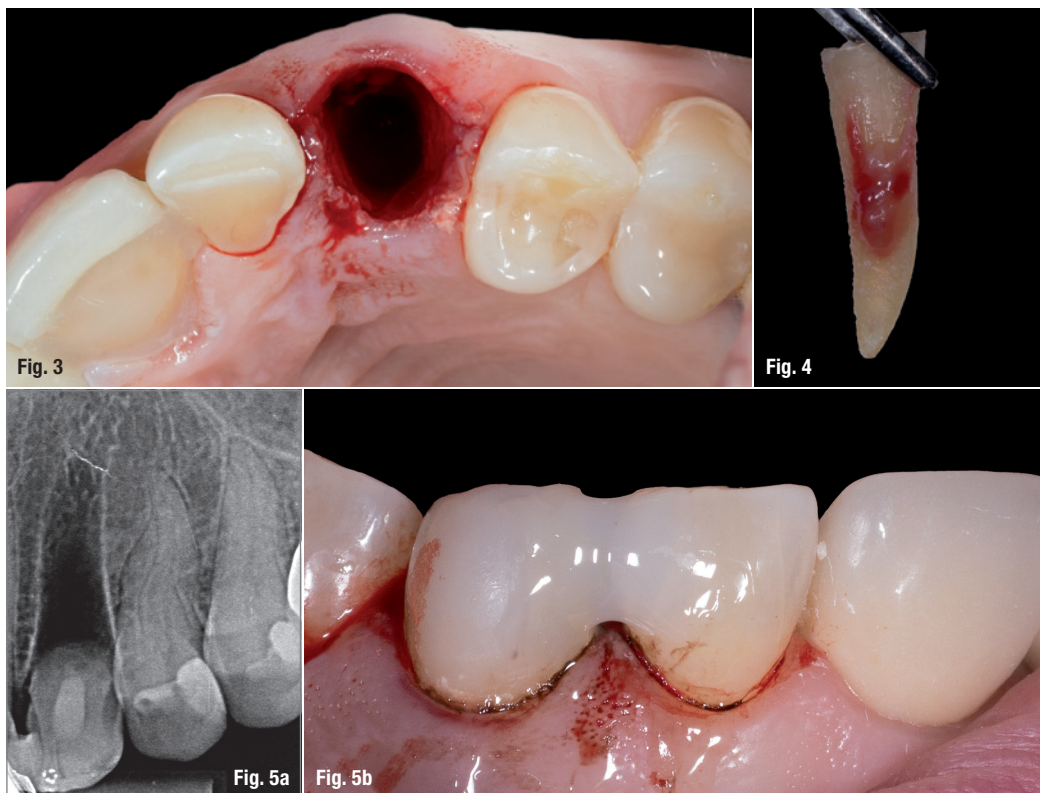


Fig. 3: Condition after extraction.

The inflammatory processes on the buccal side are clearly visible.

Fig. 4: Separated root and inflammatory process in medium third.

Fig. 5a: Single-tooth radiograph after replantation of dental crown.

Fig. 5b: Condition after replantation of dental crown (intraoral). Splinting with SDR® (Dentsply Sirona) to adjacent tooth.

Case history and treatment

A 44-year-old patient visited our practice due to problems with tooth 23 for the first time in January 2016. The patient was healthy at the time of the consultation and suffered neither from acute nor chronic general diseases.

The labial surface in the medium third of the root of tooth 23 was very sensitive to percussion. A dental X-ray scan of region 21–24 did not show any signs of resorptive processes (Fig. 1). The therapeutic goal was to restore the proper function of tooth 23 and to remediate the inflammatory processes. We suggested various therapeutic options and chose the implantological treatment.

Extraction and replantation

Treating the alveolar bone and the surrounding tissue with care during the extraction may positively influence the formation of defects.¹¹ After cutting all periodontal fibres to be reached from the intrasulcular side using a micro scalpel blade, the tooth was removed from the alveolar bone axially using forceps. Figure 2 shows the situation before and figure 3 right after the extraction. The resorptive processes in the labial area are barely perceptible in figure 3, are confirmed though in figure 4, which shows the separated root and the internal resorption of the labial region. Crown and root were separated 2 mm below the enamel cement junction. If there was no root canal

filling available, the dental pulp areas were to be cleaned and filled with composite filler. For replantation, a pre-manufactured palatinal silicone key was used to attach the crown to adjacent tooth 22 by means of acid etching (phosphoric acid, Adhese® Universal, Ivoclar Vivadent) and composite filler (SDR®, Dentsply Sirona). Figures 5a and b show the situation right after replantation and fixing.

Extrusion

After ten days, a loss of approximately 1 mm of marginal gingiva in apical direction became evident (Fig. 6). We intended to recapture that by means of extrusion. The replanted crown was separated in the upper third (Fig. 7) after a healing time of ten days and extruded by 1 mm using rubber bands for 24 hours (Fig. 8). You can see the reactive tissue in the marginal area very nicely. The soft tissue is the first to follow the traction, then the bone. The stabilisation phase until the implantation was 16 weeks.

Implant planning and implant procedure

The aesthetic result depends on the three-dimensional positioning of the implant. After replantation and extrusion, volume loss was prevented and complete ossification of the alveolar extraction site was achieved. Figures 9 and 10 show the radiographical findings right before the implantation. In particular, the volume in orovestibular direction (Fig. 9, centre) prevents that the implant is positioned too far into the

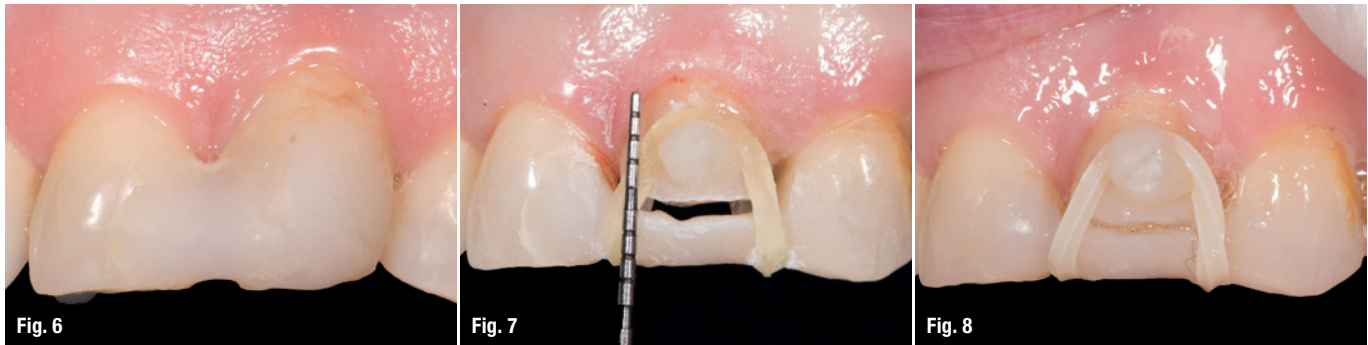
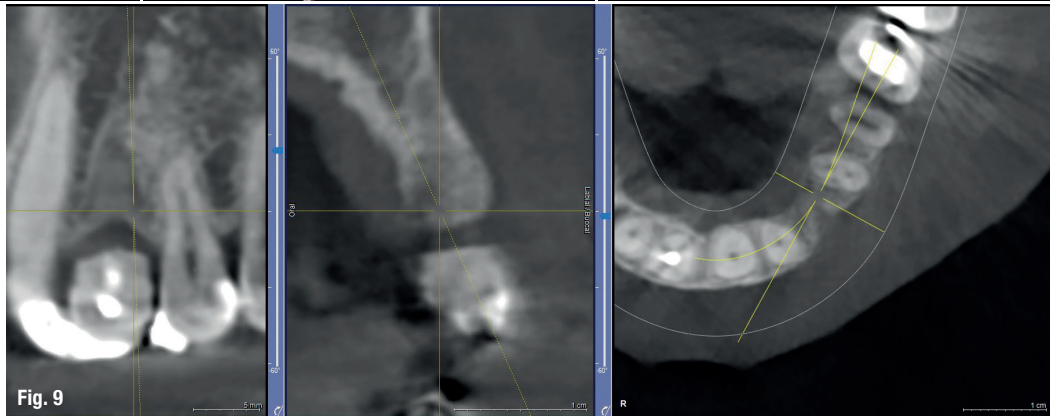


Fig. 6: After ten days already, a loss of marginal gingiva of about 1 mm in apical direction is evident.

Fig. 7: Condition prior to extrusion by means of rubber bands over a period of 24 hours.

Fig. 8: Condition after 24 hours. The reactive tissue in the marginal area is very nicely shown. The soft tissue is the first to follow the traction, then the bone.

Fig. 9: Three-dimensional imaging shows that volume loss is prevented and complete ossification of the extraction alveole could be induced.



palatal direction with sufficient osseous volume of 2 mm on the buccal side. The replanted crown makes it possible to plan the implant position allowing for the prosthetic component in terms of backward planning. A template-guided implantation facilitates the incision-free technique and shorter treatment period, reduced patient morbidity, and better surface texture of the soft tissue. Figure 11 shows the situation after removal of the replanted crown and prior to the implantation. Using a micro scalpel blade, access to the bone was established (Fig. 12). Afterwards, the pilot hole was drilled using the template (MIS Guide, Fig. 13) and the further preparation performed with osteotomes (Fig. 14) after inspection of the buccal bone lamella. Despite the preventive measures, the purely subtractive preparation of the implant bed using drills was not indicated. We used a 3.3/11.5 mm implant in a special triangular design of the crest, which increases the bone deposit in the critical zone additionally (V3, MIS; Figs. 15 and 16).

After the implantation, the crown was replanted. Figures 16a und 17a show the status of the soft tissue right after the implantation. The atraumatic status and the complete preservation of the emergence profile are remarkable. A single-tooth radiograph was prepared to check the implantation (Fig. 17b).

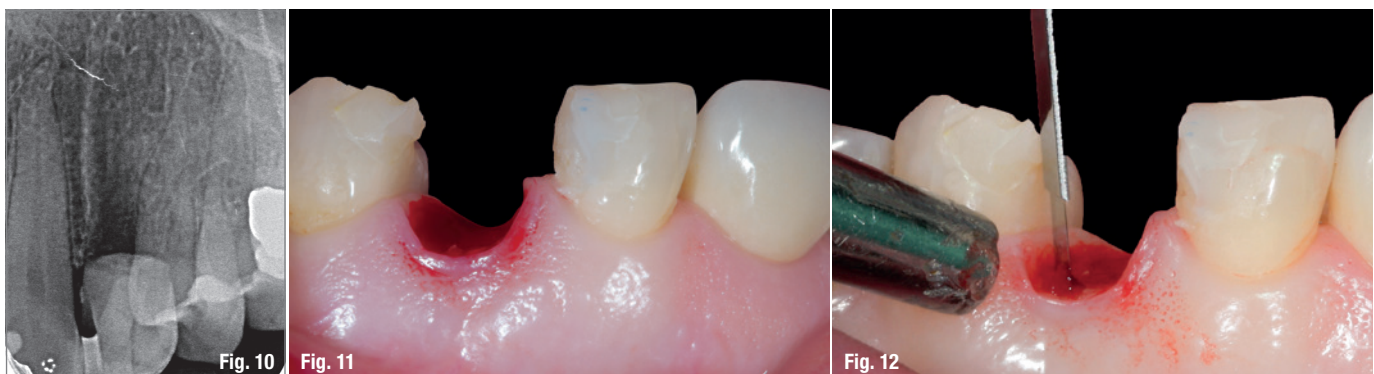
Exposure and dental impressions

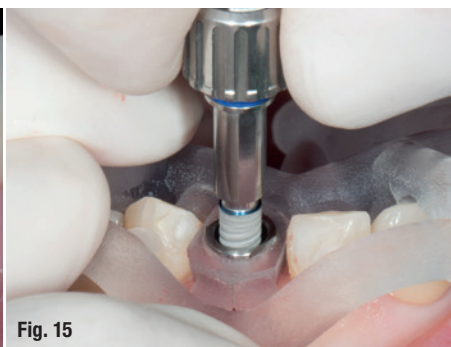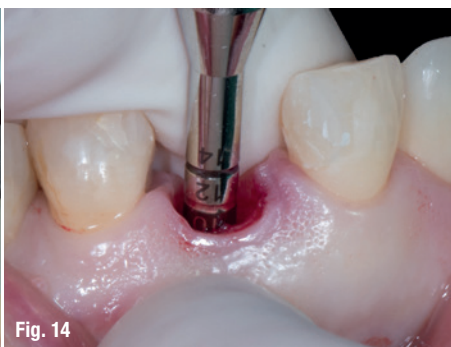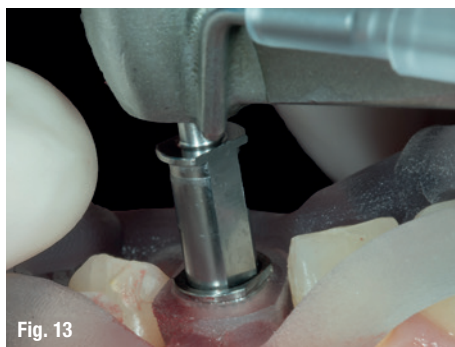The implant was re-exposed three months after the initial implantation. In the meantime, the bonding of the replanted crown had failed once. Because of the slightly undercutting points of the composite, the replanted crown is not lost, but only becomes loose and is retained well by fibres and ligaments. The patient wears a splint at night for protection against aspiration or swallowing. The atraumatic exposure and removal of the replanted crown and the subsequent exposure of the implant using a micro scalpel blade cannot be compared to the typical exposure technique.

Fig. 10: Single-tooth radiograph of region 23 after complete ossification.

Fig. 11: Condition after removal of replanted crown and prior to implantation.

Fig. 12: Access to the bone was established by means of a micro scalpel blade.





The dental impressions were taken in an analogue procedure using a closed tray via a transfer cap (Fig. 18). The next step was the manufacture of an individual hybrid abutment (titanium adhesive bonding, zircon abutment) at the laboratory. A digital dental impression would have the advantage that data scanned before the tooth extraction could be matched with the impression after exposure, thus enabling an exact copy of the natural tooth in line with the "biogeneric copy" concept.¹⁰ In the present case, we abstained from the digital workflow because the crown was individually manufactured in laminated ceramics. The dental crown was replanted again after the impression was taken.

In the next session, the definite abutment (Fig. 19) and a synthetic crown were tried on for aesthetic analysis. We removed the composite residues from the adjacent teeth and fixed the abutment tightly using a new screw according to the manufacturer's instructions (Fig. 20). A new silicone impression was made in filament technique. This impression serves to manufacture of the crown with the newly defined contact points to the adjacent teeth. Previously, the laboratory had manufactured an analogue to the abutment of super-hard plaster to ensure the exact preparation of the crown margin. Figure 21 shows the abutment after removal of the composite residues from the adjacent teeth. The synthetic crown was fixed using provisional cement (Telio CS Link, Ivoclar Vivadent). We were thus able to abstain from another replantation of the dental crown. The synthetic crown provides us with diagnostic value with regard to the

final appearance of the peri-implant soft tissue and the form of the crown.¹² Additional optimisation by applying and removing provisional masses to form the emergence is not necessary anymore in most cases. This shortens the treatment duration considerably. Figure 22 shows the definite crown right after its placement (Variolink Esthetic DC, Ivoclar Vivadent).

Discussion

Prerequisite for aesthetic prosthesis with long-lasting stable soft tissue is the correct positioning within the three regional comfort zones. If no tissue defects are available, predictable results involving single-tooth implant crowns of the anterior teeth can be achieved.¹² The adjacent teeth contribute to supporting the peri-implant tissue and determine the height of the papilla.

Schropp et al. reported though that the extraction of teeth promotes the resorption of the adjacent tissue.¹³ After three months, cervical resorption reaches an extent of 30 per cent and labial resorption an extent of up to 50 per cent. The initial resorption processes after tooth extraction are physiological processes that cannot be prevented from today's point of view. Reference literature describes the implementation of various augmentation strategies to optimise the volume in case of available defects in detail. Horizontal ridge augmentation to widen the alveolar ridge effectively are available and provide for stable results in the long term. The described techniques to augment the alveolar ridge, however, are consider-

Fig. 13: Template-guided pilot hole (MIS Guide).

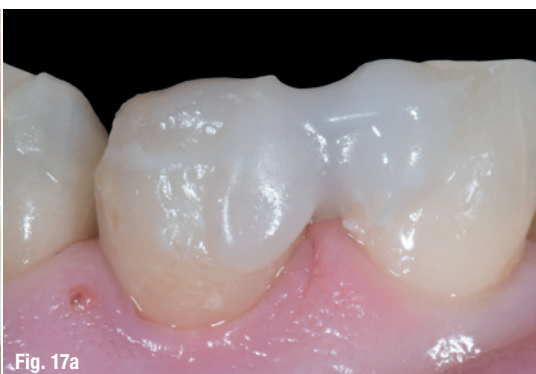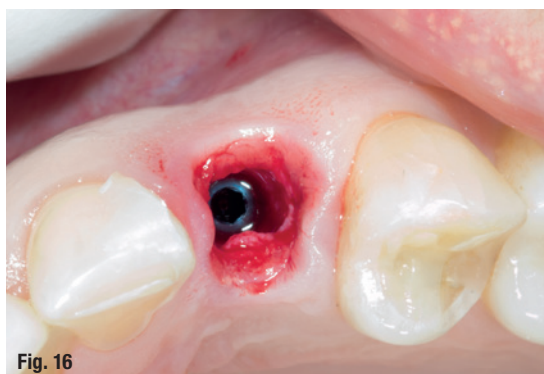Fig. 14: After the pilot hole, the implant bed was further prepared, exclusively with osteotomes.

Fig. 15: A 3.3/11.5 mm implant in a special triangular design of the crest, which increases the bone deposit in the critical zone additionally used (V3, MIS Implants).

Fig. 16: Condition after implantation and prior to replantation of dental crown. The atraumatic status and the complete preservation of the emergence profile are remarkable.

Fig. 17a: Condition right after implantation.

Fig. 17b: Single-tooth radiograph after implantation.

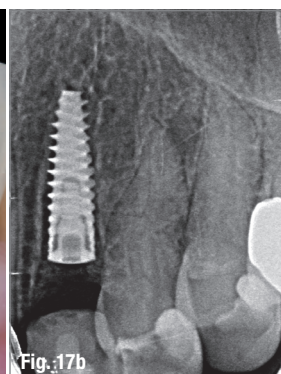

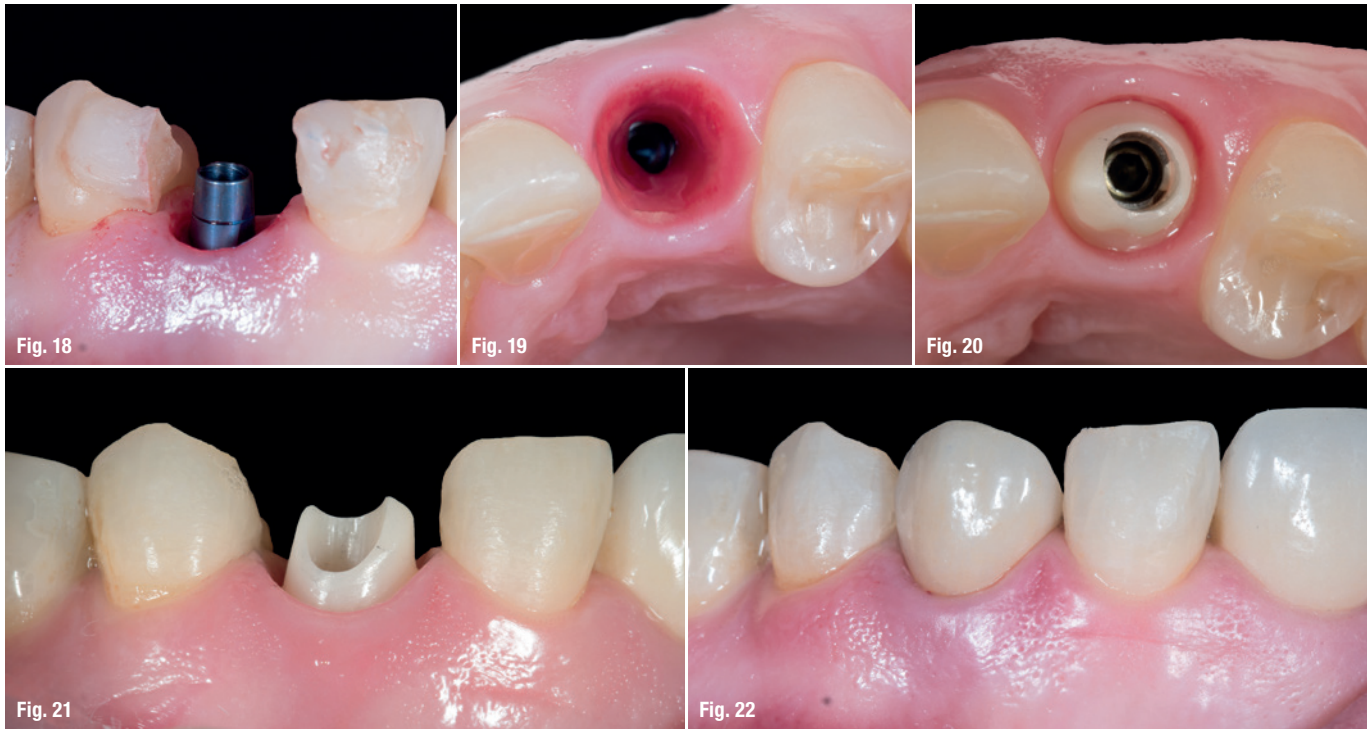


Fig. 18: Condition after exposure and prior to dental impression.

Fig. 19: To try the definite abutment on, the composite residues were removed from the adjacent teeth.

Fig. 20: The abutment was fixed tightly using a new screw according to the manufacturer's instructions.

A new silicone impression was made in filament technique. This impression serves to manufacture the crown with the newly defined contact points to the adjacent teeth.

Fig. 21: Buccal view.

Fig. 22: Condition right after placement of crown.

ably less predictable.¹⁴ High biological and technical complication rates had to be expected. Consequently, reliable concepts were required and developed to create optimal initial conditions. Ridge-preserving measures involving different approaches and combinations were developed.

Among others, inserting thick free mucosa grafts into the coronal part of the alveolar extraction site, thickening the soft tissue on the buccal side of the alveolar extraction site using connective tissue grafts, filling the alveolar extraction site using bone or bone replacement material, and the application of the GBR method are described measures.¹⁵ Regarding the filler techniques, Fickl's workgroup was able to show, when comparing the different methods, that none of the examined techniques prevented the resorption of the buccal bone lamella and the formation of tissue defects.¹⁶ Likewise, one cannot achieve the complete compensation of the defect formation by means of closing the alveolar extraction site with a free mucosa graft.^{16,17} That is why many new concepts in implantology still engage in the principle of tissue reconstruction after tissue loss.

There is one thing, however, all the described methods, whether mere tissue reconstruction through augmentation or ridge-preserving measures, have in common: The intervention takes place always when tooth was extracted completely. The tissue master concept pursues a whole new approach. Because of the crown replanting, the extraction is incomplete and thus the alveolar fibre structure and periodontal ligament are preserved. The initial resorption pro-

cesses do not seem to take place and healing processes proceed, preserving the alveolar volume almost completely.⁹ Other convincing aspects in this regard are the reduced number of surgical interventions, the abstinence from bone replacement material, the shorter treatment time, and the altogether better patient comfort.

Conclusion

This case report reveals that the intervention implementing ridge-preserving measures before the tooth is fully extracted should be taken into consideration. This biological approach represents the primary prevention of resorption processes and thus facilitates the abstinence from time-consuming and cost-intensive augmentation measures.

contact

Dr Umut Baysal
Dr Arzu Tuna
 Große Brinkgasse 29
 50672 Cologne, Germany
 u.baysal@me.com
 www.myveneers.de

Author details



Author details

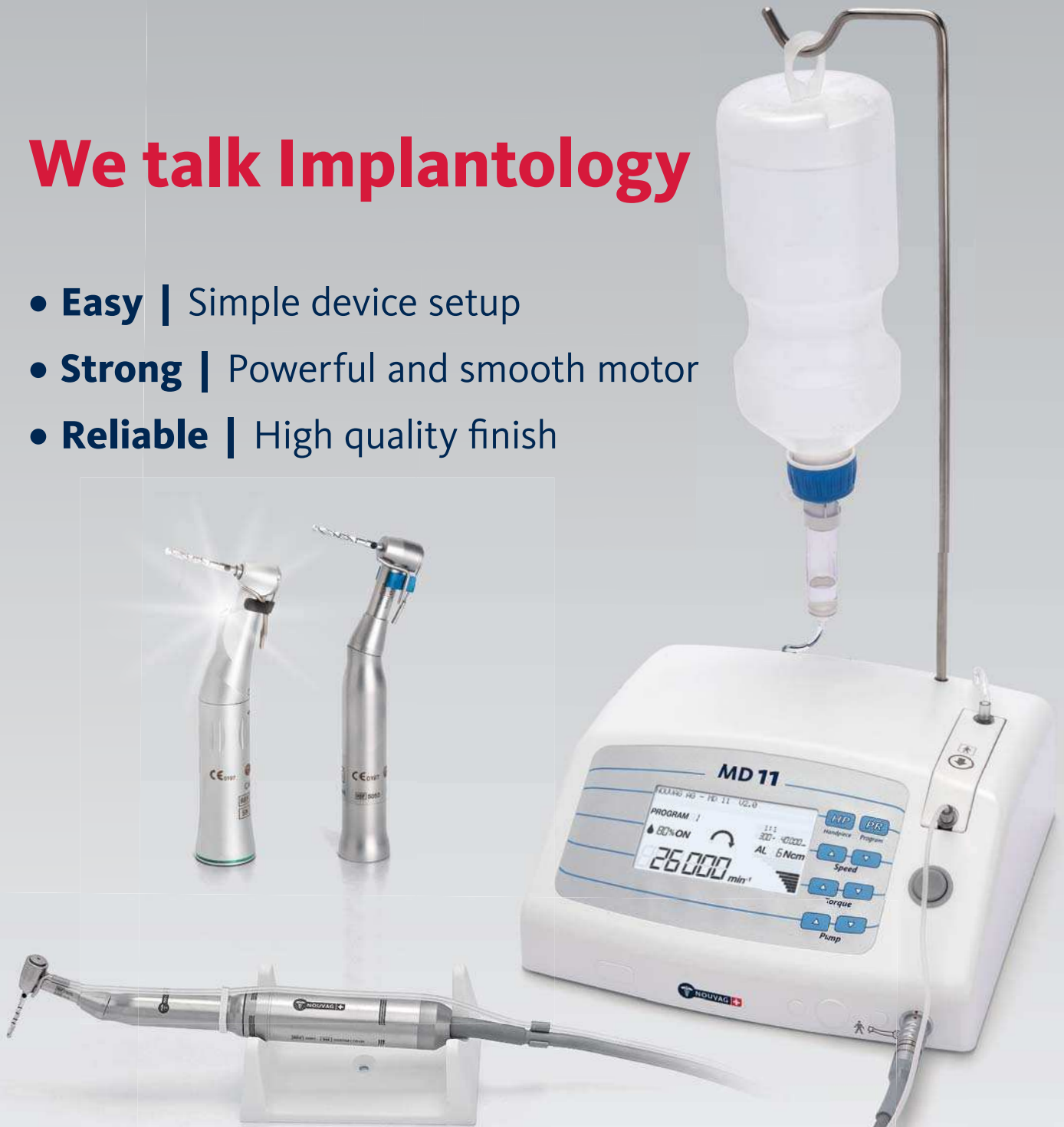

Literature



We talk Implantology

- **Easy** | Simple device setup
- **Strong** | Powerful and smooth motor
- **Reliable** | High quality finish



Scan me to be linked to the
NOUVAG contact form ▶▶▶



Nouvag AG
St.Gallerstrasse 23 – 25
CH-9403 Goldach
Phone +41 (0)71 846 66 00
info@nouvag.com
www.nouvag.com



Immediate temporisation using tapered implants

Author: Dr Mohamad El Moheb, France

Immediate loading of implants is a predictable and successful¹ treatment option if it is well planned and well executed. An adequate implant stability is mandatory to permit early loading of the implant.² This treatment allows an immediate restoring of aesthetics and offers a more comfortable provisional for the patient.

Immediate temporisation (immediate loading) is a predictable technique. There are no significant differences concerning the implant survival, or marginal bone loss when it is compared to the conventional loading procedure.³

The patient selection in addition to the primary stability of the implant and the patient compliance with the surgeon's recommendations are important factors of the success of the immediate implant loading.⁴

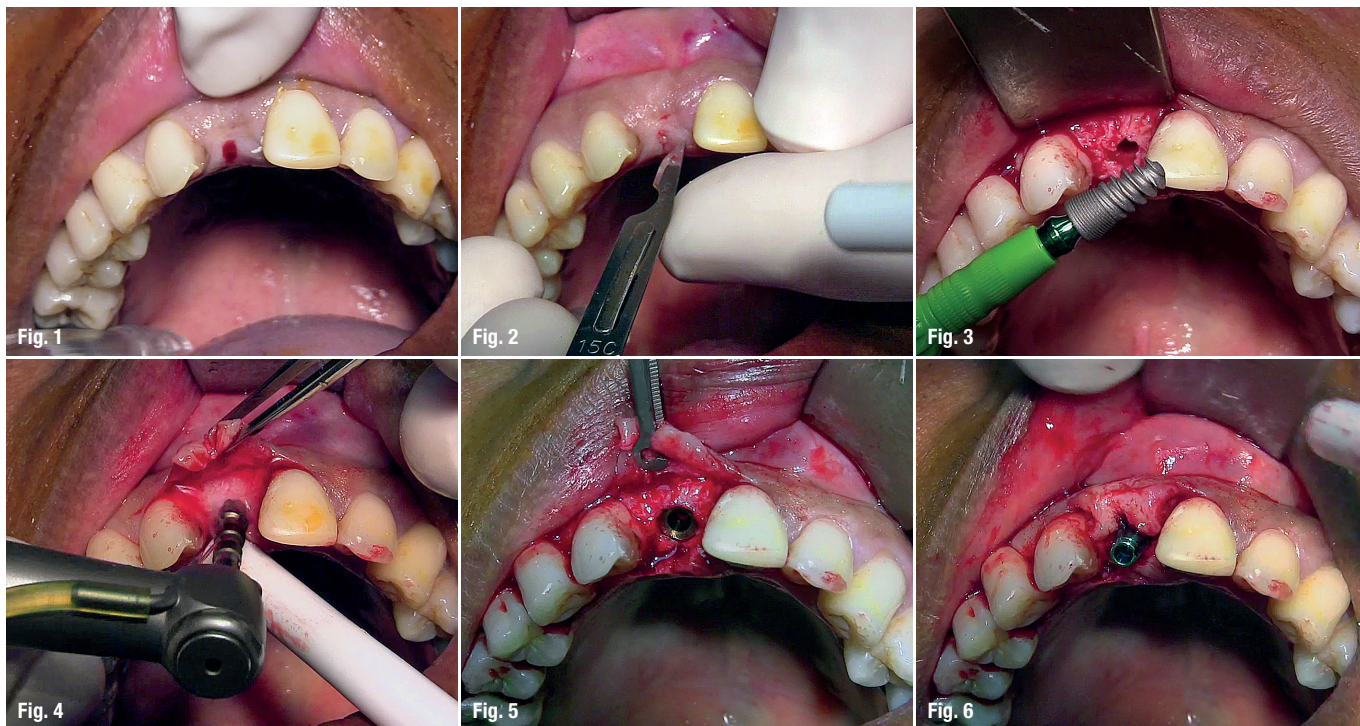
Background

Immediate temporisation of an implant in the anterior zone⁵ to replace a missing tooth is well documented. It is a predictable procedure and its results can be compared to a delayed one⁶ if an implant stability of 35 N can be reached⁷ and if the provisional crown is out of occlusion.

To achieve a high insertion torque and stability, the choice of which implant shall be used is primordial. The implant surface seems to play a role in the stability of the implant during insertion. This is due to the augmentation of the roughness, which will increase the friction coefficient⁸ and demand a larger insertion torque.

The implant design plays a key role in primary stability as well as the insertion torque. It has been

- Fig. 1:** Central incisor had been missing for several years.
- Fig. 2:** Concave semilunar incision towards the palate.
- Fig. 3:** Self-taping implant increases bone density by condensation.
- Fig. 4:** Drilling.
- Fig. 5:** Implant insertion at 35 N.
- Fig. 6:** Implant abutment.

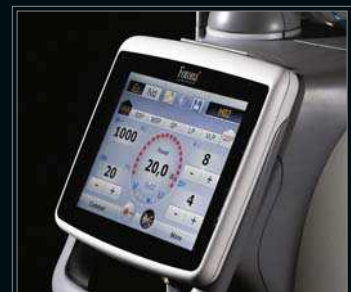

The universe at your fingertips.

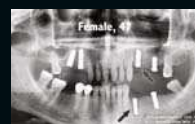
TwinLight[®] Peri-implantitis Treatment

A simple and effective procedure that offers the power to treat peri-implantitis – an increasing threat to oral health.

- Minimally-invasive technique
- Fast regeneration/healing
- Reduced inflammatory response
- Highly effective treatment
- No antibiotics needed



Peri-implantitis treatment video



LightWalker[®]

www.lightwalkerlaser.com

demonstrated that the tapered implant offers a better primary stability and the highest insertion torque.⁹ The thread design is also a major factor in the stability of the implant.¹⁰

Clinical case

A female patient, 50 years old, presented with a central incisor which had been missing for several years (Fig. 1). The patient was wearing a removable prosthesis to replace the missing tooth. The colour of the tooth had started to change and the patient was not happy with the solution any longer. As the medical questionnaire showed, the patient does not have any systemic diseases. All in all, the patient was in a good general health.

The extraoral and the dynamic examinations showed a normal opening trajectory with no deviation. The intraoral examination revealed missing teeth in the left posterior mandibular. The patient was wearing also a removable prosthesis. There were some obturations but all in all the oral hygiene was good.

The patient's major complaint concerned the aesthetic. She wanted to replace the removable prosthesis as soon as possible with a fixed tooth. This removable prosthesis was an obstacle that disturbed her in her professional and personal life.

The cone beam of the patient showed enough thickness of the bone that allows a high primary

stability¹¹, which is a crucial factor for immediate loading.¹² Therefore, it was decided to perform implant placement and immediate loading or immediate temporisation in this case.

After the injection of anaesthetics, the first incision design is very important. It allows to create an interdental papilla during the healing phase. Therefore, the incision has to be a concave semilunar incision towards the palate (Fig. 2). The implant system chosen in this case was ROOTT Form (TRATE) because of its macro design that allows a high and predictable stability. The system is a self-taping and bone condensing implant.¹³ This type of implant can increase the implant stability by increasing the bone density by condensation (Fig. 3).

After the drilling (Fig. 4) and implant insertion at 35 N¹⁴ (Fig. 5), the implant abutment (Fig. 6) was placed and a temporary crown was done (Fig. 7). The temporary was out of occlusion, its aim was only to restore the aesthetic, to create a good emergence profile and to maintain the new papillae. Two months later, the temporary crown was taken out (Fig. 8) to make an impression (Figs. 9 & 10) and place a final crown (Figs. 11–13).

Discussion

Immediate loading or immediate temporisation is a well-documented procedure. The Immediate loading of implants in the maxilla is a successful

Fig. 7: Temporary crown.
Fig. 8: Two months later: temporary crown was taken out.
Figs. 9 & 10: Impression making.

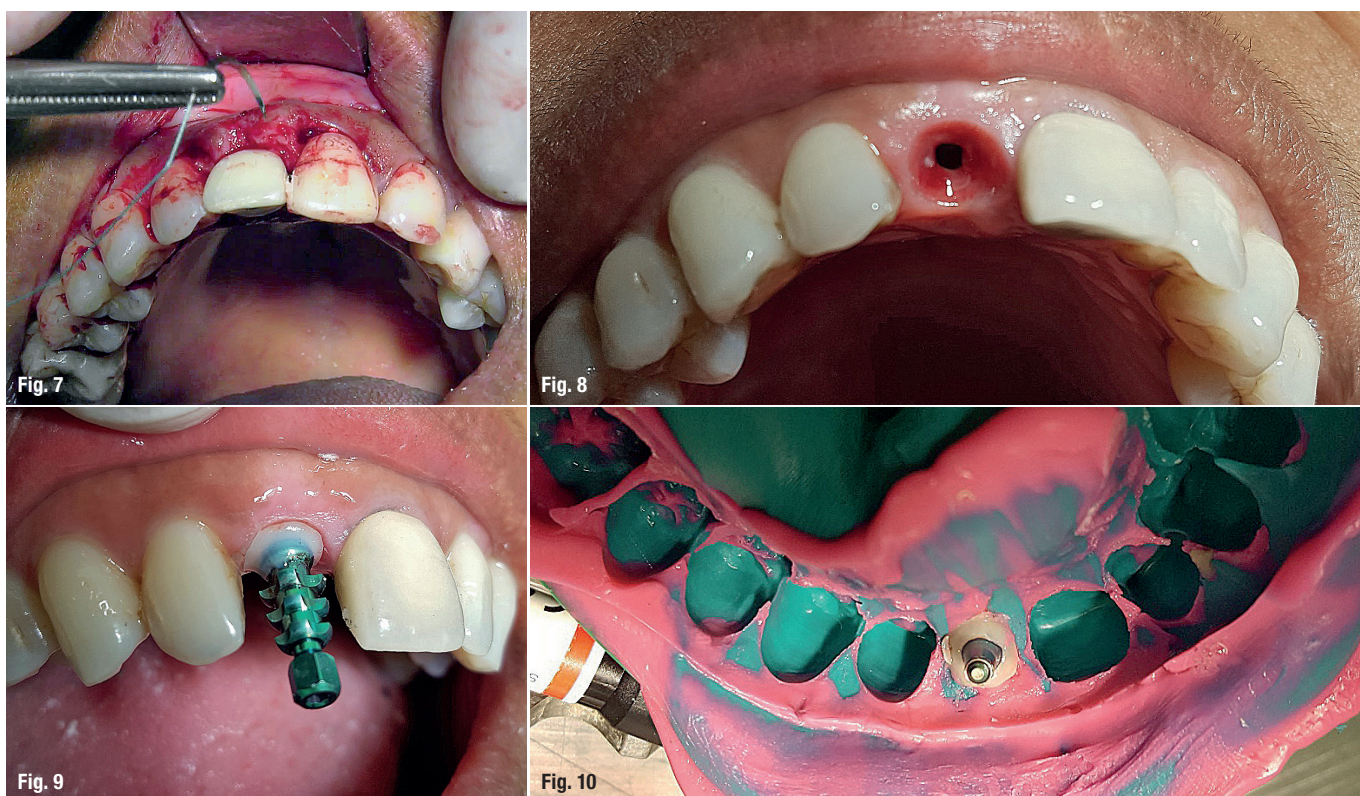

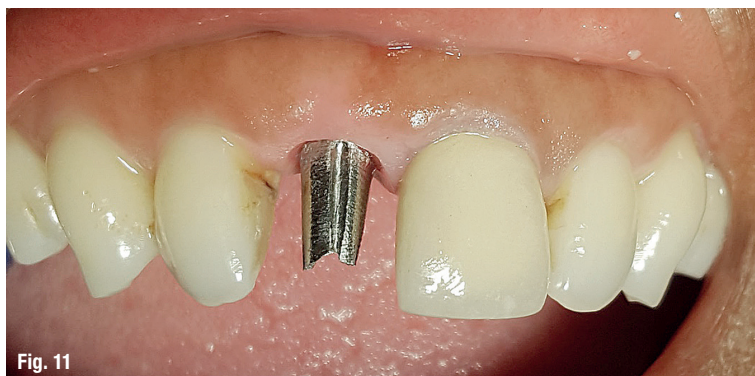


Fig. 11

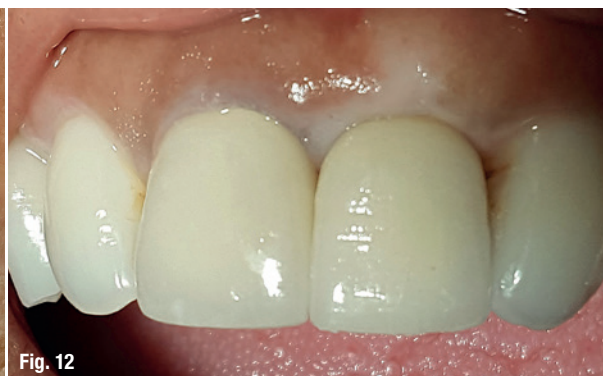

Fig. 12

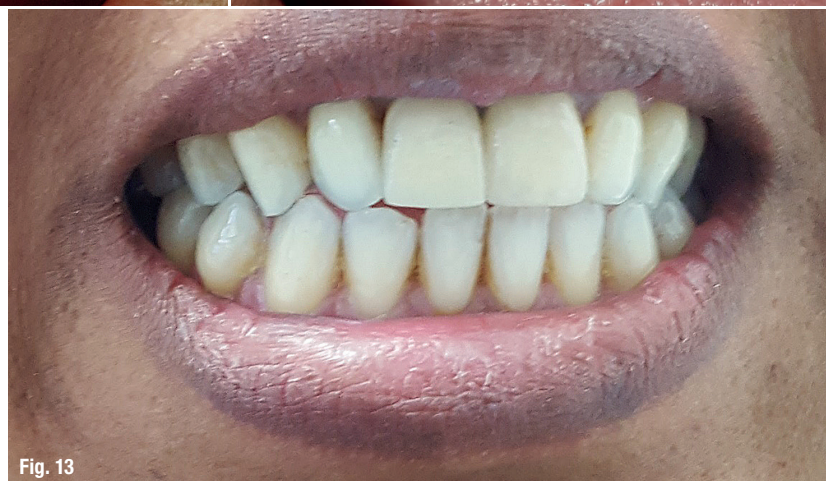

Fig. 13

and predictable treatment option with failure rates approaching those of the traditional two-stage surgery.¹⁴ The most important factors of immediate loading are the primary stability and immediate torque. The torque should be at 35 N at least.¹⁴ The choice of the implant or the surgical procedure is also important to achieve a high-insertion torque. It seems that a self-taping implant may increase implant stability and high-insertion torque.¹³

The macro-design of the implant is very important because a tapered implant may condense the bone around the implant to achieve greater implant stability.¹⁵ Immediate temporisation can be an interesting technique to reduce the treatment time and to make it more comfortable for the patient. This technique is predictable if the conditions of insertion torque and the provisional crown being out of occlusion are respected. The patient selection and cooperation are also crucial factors for the treatment success.

Conclusion

Before starting the surgery, the surgeon should decide if he or she wants to perform an immediate load procedure or not. The decision should be based on the surgeon's ability, the residual bone height and width, the occlusion of the patient and the patient's motivation and hygiene.

As the stability is one of the crucial factors in the success of the immediate loading or immediate temporisation procedure⁴, the surgeon should be able to secure this stability of at least 35 N⁷ by following an appropriate drilling protocol and choosing the right implant. The combination of implant design and surgical osteotomy plays an important role in the implant stability. In this case, we chose an implant that allowed us to achieve this crucial condition in almost all cases.

To achieve a high primary stability which allows to use the immediate load procedure, it is better to

choose a tapered implant that facilitates bone condensation around the implant and with this offering the wanted primary stability. The implant length is also important: the bigger the implant, the bigger the implant/bone contact and the bigger the stability. A long implant also allows a fixation in the cortical area which increases the stability of the implant.

Figs. 11–13: Final crown.

contact

Dr Mohamad El Moheb

148 Avenue Jean Jaurès
93320 Les Pavillons-sous-Bois, France
Tel.: +33 148 486358

Author details



Literature



Overcoming a difficult aesthetic situation

Author: Prof. Dr Dr M. Kemal Unsal, Turkey

Introduction

Immediate implantation is becoming frequently applied in implant dentistry. Although this technique can be used in many situations, the cases which benefit most are the trauma cases. Associated with an aesthetic issue, the teeth suffering the most from trauma are the incisors. Immediate implant treatment can be the preference of the clinician who would like to cope with time restrictions and aesthetic issues. However, primary stability issues do not always meet immediate loading protocols. In that case, it is the responsibility of the surgeon not only to have an acceptable level of primary stability, but to predict the insertion depth of the implant in order to achieve an aesthetic outcome. In the presented case, the resorption prediction was not accurate enough. This special challenge was successfully mastered with the help of the implant manufacturer. The custom abutment prepared for this case was added to the NucleOSS catalogue as an option for all users of the system.

Case report

A 58-year-old woman without any systemic disorders attended our clinic. Her main complaint was the increased mobility of her upper left central incisor #21. The mentioned tooth had received a root treatment and a ceramic laminate restoration ten years ago (Fig. 1). Upon intraoral and radiographic examination, the tooth was diagnosed with a horizontal crack and decided to be extracted (Fig. 2). The remaining broken root piece was also extracted as a single piece. An immediate NucleOSS T6 implant with a length of 12 mm and a width of 4.1 mm was inserted. The buccal aspect of the extraction socket was filled with a xenograft. As the buccal bone wall was intact, no membrane was used (Fig. 3).

It is quite possible to observe bone resorption around immediately placed implants. In order to avoid possible aesthetic problems due to this bone loss, clinicians generally tend to position the implant a bit deeper and palatally. The loss of a central upper incisor

Fig. 1: The tooth had received a root treatment and a ceramic laminate restoration ten years ago.

Fig. 2: Upon intraoral and radiographic examination, the tooth was diagnosed with a horizontal crack and decided to be extracted.

Fig. 3: As the buccal bone wall was intact, no membrane was used.

Fig. 4: Marking the gum level with a permanent pen just before extraction.

Fig. 5: Roughening of the glazed surface of the ceramic restorations with diamond burs.

Fig. 6: Application of only orthophosphoric acid of 36 per cent on the natural enamel of tooth #22 for 30 seconds and composite bonding.

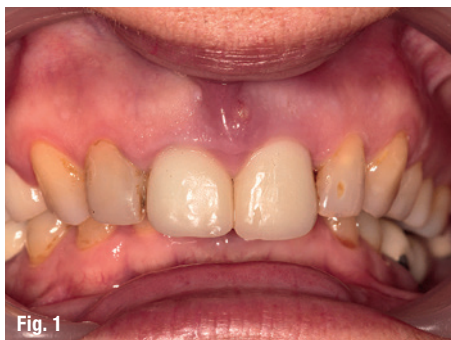

Fig. 1

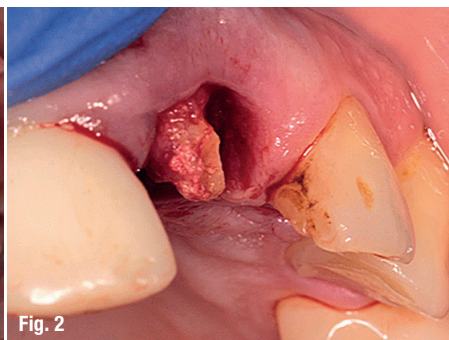


Fig. 2

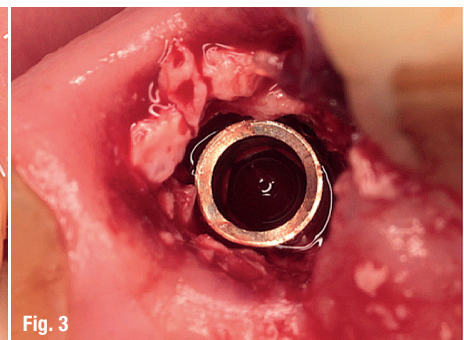


Fig. 3

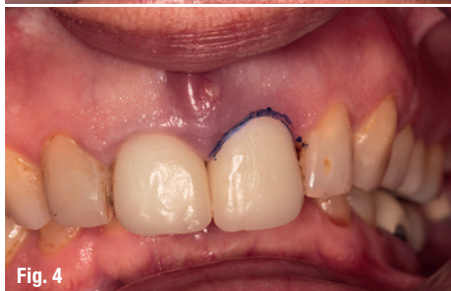

Fig. 4

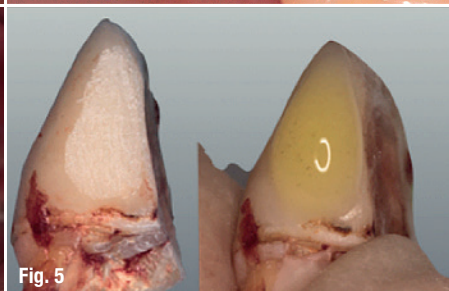

Fig. 5

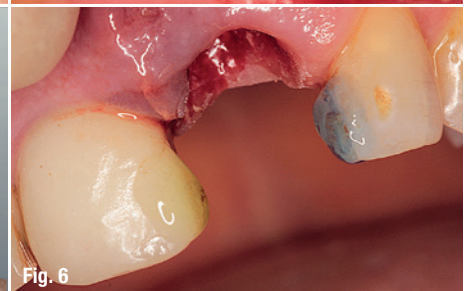

Fig. 6

CITO mini®

YES!



I WANT

THE CITO MINI®

MADE BY DENTAURUM.

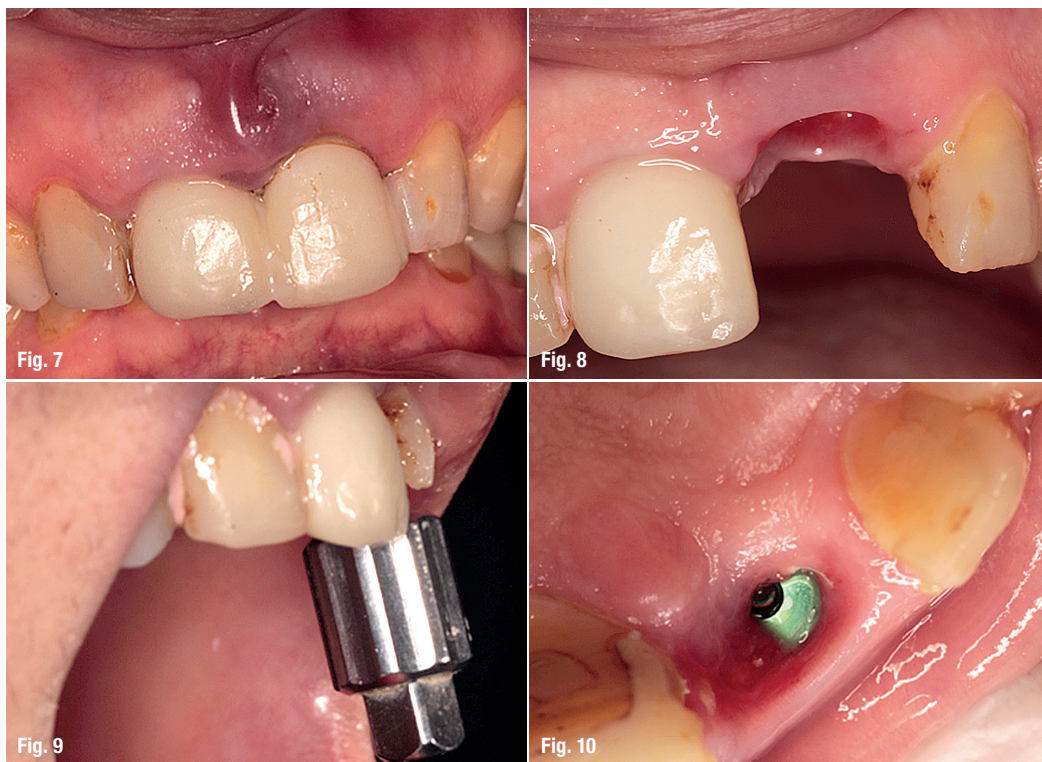
More than 20 years of expertise, reliability
and innovation in implantology – worldwide.
Say yes!



 **DENTAURUM**
IMPLANTS

Turnstr. 31 | 75228 Ispringen | Germany | Phone +497231/803-0 | Fax +497231/803-295
www.dentaurum-implants.com | info@dentaurum-implants.com

- Fig. 7:** The patient was advised to follow a soft diet and discharged.
- Fig. 8:** Minimum soft-tissue loss and an acceptable tissue contour.
- Fig. 9:** Checking the insertion angle of the implant.
- Fig. 10:** Removal of the cover screw.



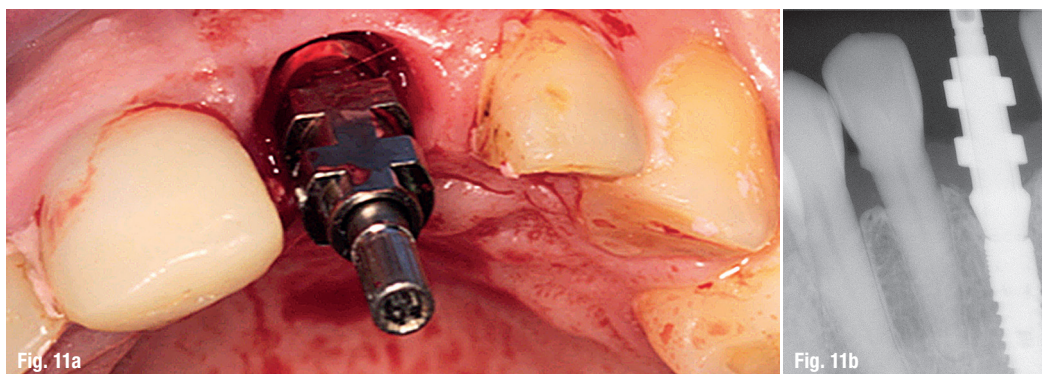
needs an immediate temporary restoration. The most time-saving and aesthetic restoration type is an immediate temporary crown attached to the implant. However, this practice needs an insertion torque of 30 Ncm or more. This case did not meet this criterion. Therefore, the idea of using the coronal part of the extracted tooth as a temporary restoration was considered. The gum level was marked with a permanent pen just before extraction (Fig. 4).

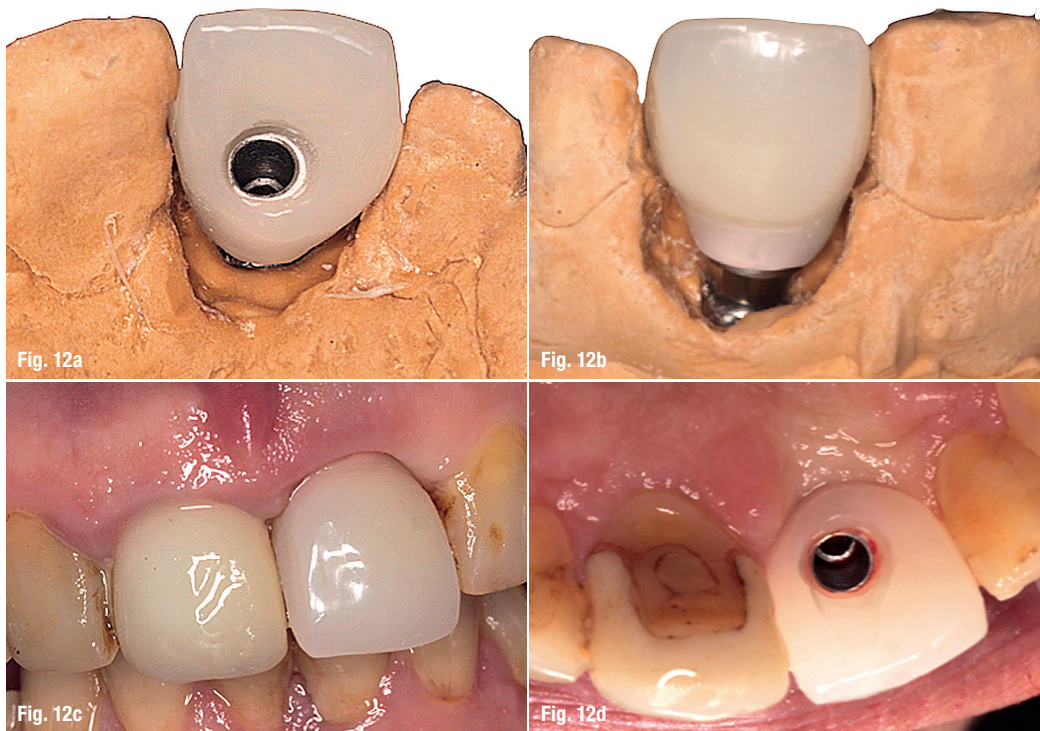
Due to an extensive deep bite, there was no room to use a fibre splint in order to achieve retention via the neighbouring teeth. The only remaining alternative was to attach the extracted coronal part using light-cured composite. One of the neighbouring teeth and the extracted coronal part was carrying a ceramic laminate, whereas the tooth #22 was yet untreated. Therefore, the glazed surface of the ceramic restorations was roughened with diamond burs and nine per cent HFl acid was applied, followed by silane and

bond application (Fig. 5). On the natural enamel of tooth #22 only orthophosphoric acid of 36 per cent was used for 30 seconds followed by a composite bonding material application (Fig. 6). The patient was advised to follow a soft diet and discharged (Fig. 7). During the three-month healing period, the crown was de-attached twice. However, these appointments were also considered as an advantage as it allowed the clinician to add light curing composite material beneath the extracted crown. This way, a better crown profile was attained.

When osseointegration was achieved, the soft-tissue loss was minimal and an acceptable tissue contour was observed (Fig. 8). The insertion angle of the implant was checked (Fig. 9). In order to not damage the delicate soft tissue which could cause aesthetic problems, the cover screw was removed without surgical intervention (Fig. 10). An open-tray impression post was inserted, an X-ray was taken to verify the fit

Figs. 11a & b: Insertion of an open-tray impression post and X-ray.





Figs. 12a–d: Manufacturing and attachment of a screw-retained, temporary crown.

and the impression was made (Figs. 11a & b). A screw-retained, temporary crown was manufactured and attached to the implant in order to achieve a better soft-tissue contour (Figs. 12a–d).

Following the final gum-tissue conditioning, a closed tray impression was made. However, due to the aesthetic demands of the patient, teeth #12, 11 and 22 were also prepared for metal-free ceramic restorations (Fig. 13) and the impression was taken. A custom-milled Zr abutment on a Ti-Base was ordered for the implant-retained restoration. Other teeth would receive a metal-free ceramic restoration.

At the try-in appointment, however, the clinician was unable to attach the custom-made abutment. The periapical radiography revealed the reason (Fig. 14). The implant was intentionally positioned deep in the coronal direction to avoid any aesthetic problems. However, Ti-Base custom abutments of nearly all companies have a shoulder design, on

which the custom-made Zr should stand. Ti-Base design is mainly used in aesthetic regions so it is very understandable that all designs intend to position the shoulder at the deepest level of the Ti-Base abutment. The design of a standard NucleOSS Ti-Base abutment is very similar to other companies' products. Its design can be seen in Figure 15.

The bone surrounding the implant did not allow the standard Ti-Base abutment to fit on the implant. This

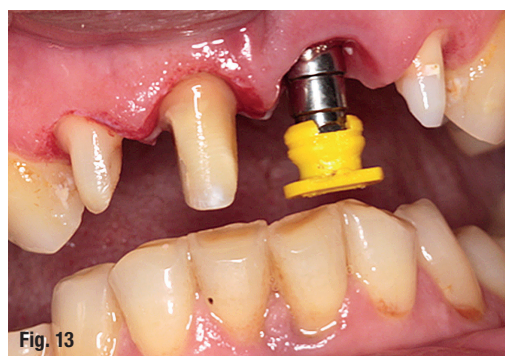

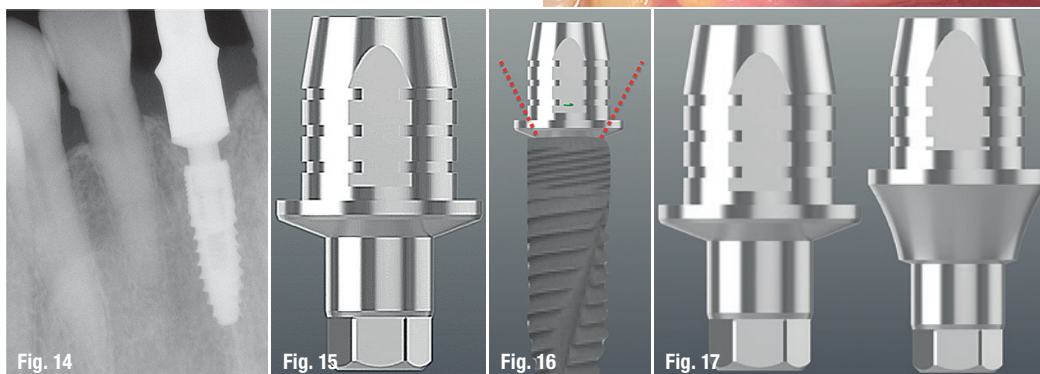
Fig. 13: Closed tray impression was made and preparation of tooth #12, 11 and 22 for metal-free ceramic restorations.

Fig. 14: At the try-in appointment the clinician was unable to attach the custom-made abutment.

Fig. 15: Design of a standard NucleOSS Ti-Base abutment.

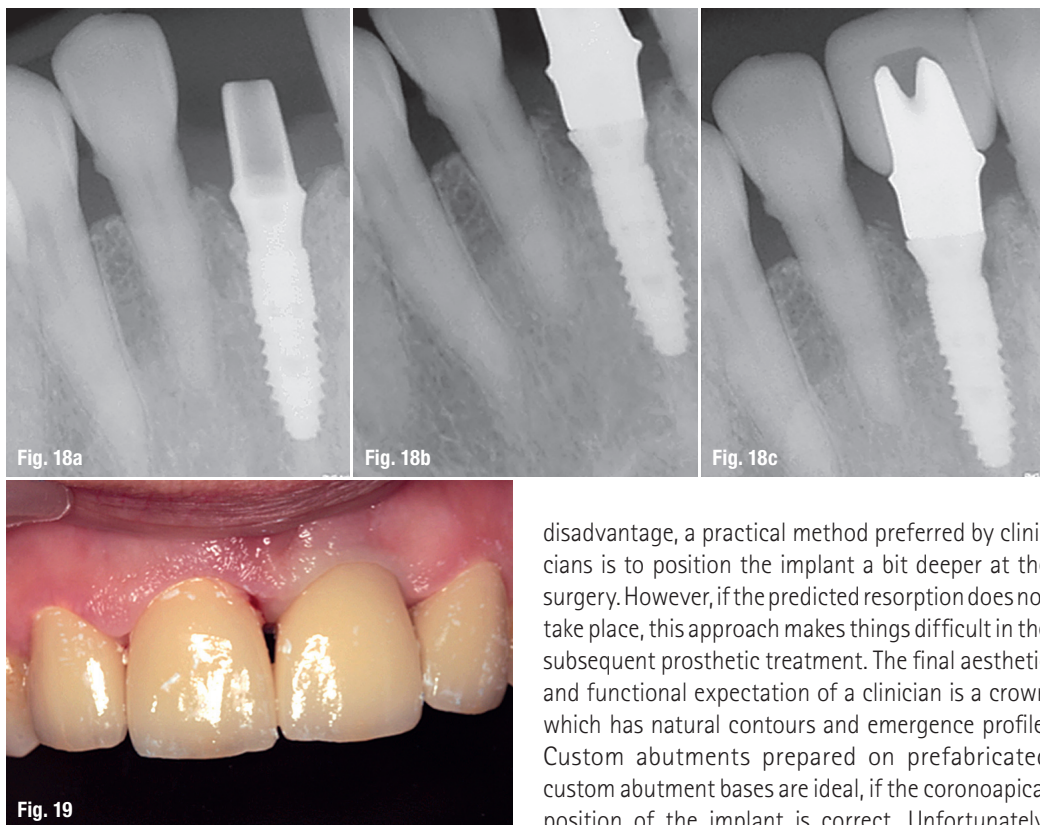
Fig. 16: The red-dotted lines demonstrating why the standard Ti-Base abutment was not able to meet the angle for the required fitting accuracy.

Fig. 17: Comparison of the new and old design of both Ti-Base abutments.



Figs. 18a–c: Radiographs at each stage of the new design.

Fig. 19: Final intraoral view of the patient.



situation could not be observed at the impression stage as the impression coping design were conical and did not pose any problems. The red-dotted lines in Figure 16 clearly demonstrates why the standard Ti-Base abutment was not able to meet the angle for the required fitting accuracy. At that stage, the only way to manufacture an acceptable restoration was an additional surgery which would re-contour the bone around the coronal portion of the implant. Such an intervention would not only lengthen the treatment time but carry a very high risk of aesthetic failure. In order to avoid such an outcome, the manufacturer designed a new custom Ti-Base abutment to be applied in these situations. The new and old design of both Ti-Base abutments can be seen in Figure 17 side by side.

The new design solved the problem for this case and now the product is available for general use. Radiographs at each stage of the new design can be seen in Figures 18a to c. The final intraoral view of the patient can be seen in Figure 19.

Conclusion

Immediate implantation following tooth extraction is a popular treatment modality. It does not only shorten the whole treatment time but furthermore reduces the surgical procedure overall. However, it is not always easy to predict the postsurgical amount of resorption in every case. In order to overcome this

disadvantage, a practical method preferred by clinicians is to position the implant a bit deeper at the surgery. However, if the predicted resorption does not take place, this approach makes things difficult in the subsequent prosthetic treatment. The final aesthetic and functional expectation of a clinician is a crown which has natural contours and emergence profile. Custom abutments prepared on prefabricated custom abutment bases are ideal, if the coronal position of the implant is correct. Unfortunately, many implant companies do not offer variable gingival height options for these custom abutment bases.

The above case was such a misprediction of postsurgical resorption amount by the clinician, so that it was impossible to reach an aesthetic and functional emergence profile with the custom Ti-Base. The only way to reach a satisfying result was to perform an additional surgery which would be time wasting, costly and perhaps painful postoperatively. In order to overcome all disadvantages, the manufacturer thus enlarged its product line with a custom Ti-Base that has increased gingival height. With this new design, the clinician was finally able to reach his goal. Furthermore, the manufacturer included this new product in their catalogue for other clinicians who might face the same problem.

contact


Prof. Dr M. Kemal Unsal
 Prosthodontist
 Gaziosmanpasa Mahallesi
 Filistin sokak 2/8
 06700 Cankaya/Ankara, Turkey
 mkemalunsal@gmail.com

Author details



NucleOSS™

↑ uploaded.



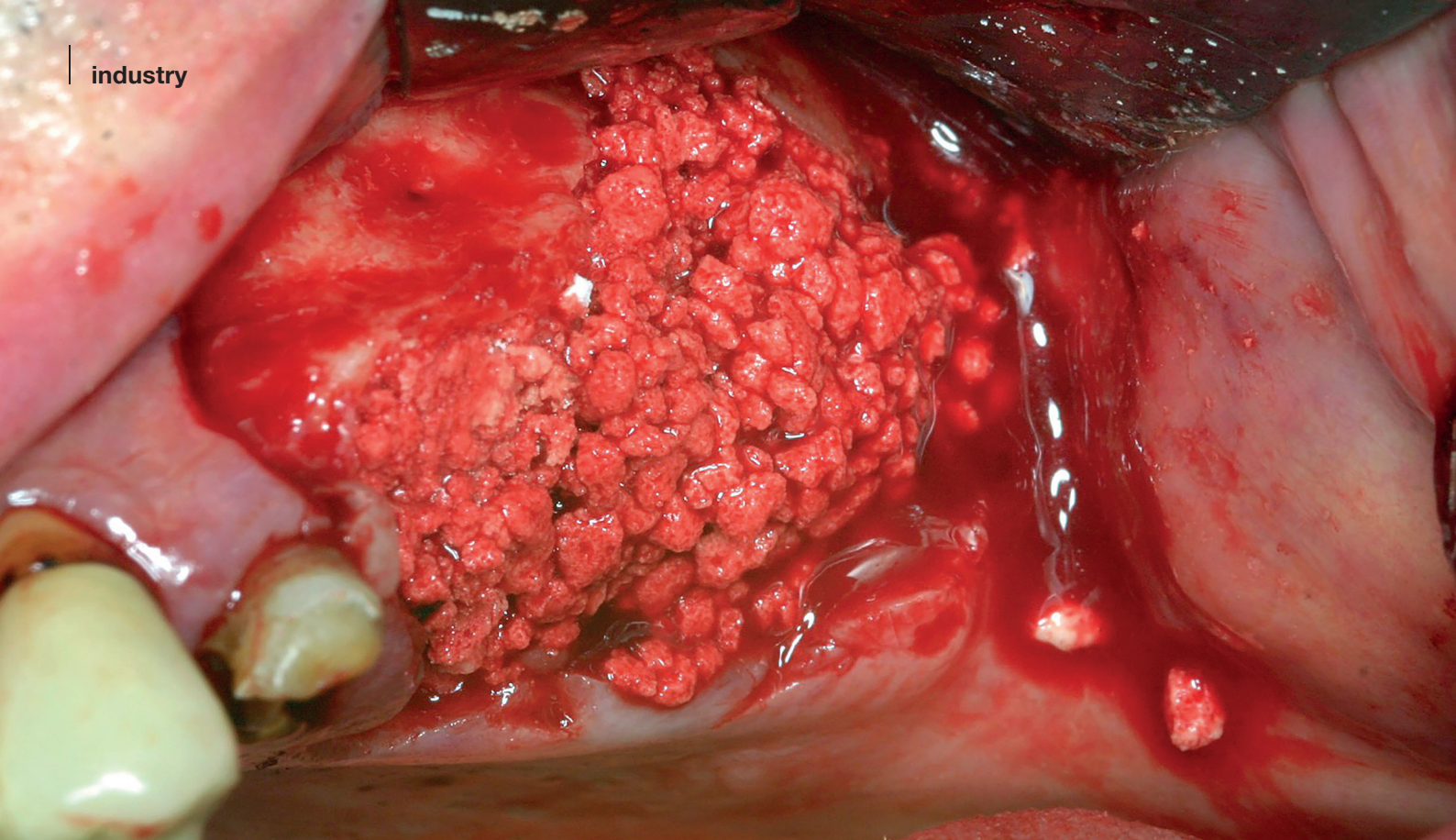
With NucleOSS Implant App, we aim to provide a fast accesibility and updated information about our company, events, products, clinical cases,surgical manuals, prosthetic manuals and the latest developments.

Available at Android, iOS and web browsers via PC.



www.muchmoreimplant.com





From granules to foam

Author: Prof. Dr Dr Stefan Schermer, Germany

Literature



In 1997 curasan launched its first β -TCP based bone regeneration material in granule form CERASORB®. Primary discussed very controversial as not comparable to the golden standard iliac crest spongiosa, the development of the biomimetic bone regenerating materials didn't stop, at least due to requirements of health politics and patients' sensitivity.¹ CERASORB® M, significantly closer to natural bone structure was a logical improvement of CERASORB® and ended up in CERASORB® Foam, where the β -TCP granules are imbedded in a collagen foam matrix, due to its flexibility enhancing the indication of β -TCP based bone regeneration materials considerably.

For more than a decade (16 years), the author attended the development of these modern augmentation materials, collecting clinical experience from hundreds of patients. In the following, some exemplary cases are shown, demonstrating the vast range of CERASORB® products.

Case 1: CERASORB®

The case documented in 2000 shows the use of the original rounded form of CERASORB®.

A patient came to the hospital with unclear discomfort in the right mandibular region. Radiologically (Fig. 1), a retained and displaced wisdom tooth with clear and impressive translucency in area 46 and 47 dominated. Block and damage of the inferior alveolar nerve was probable, as well as devitalisation of the two molars. Clinically, a prominent swelling in area 46 and 47 could be seen and a perforation of the soft tissue over the erupting wisdom tooth. After preparation of a soft-tissue flap (Fig. 2) and the sparing removal of the wisdom tooth, the cyst was carefully extirpated. The alveolar nerve could be saved and the enormous defect was filled with CERASORB® granules (Fig. 3). The final wound closure was done by readapting the soft-tissue flap and a sealed off suture. The vitality of the molars was kept, as well as the sensitivity of the inferior alveolar nerve. After nine months, a control panoramic scan was made and a sufficient bony consolidation with only a few residual CERASORB® granules was noticed (Fig. 4).

Case 2: CERASORB® M

The second case from 2005 documents the further development and improvement of CERASORB® into

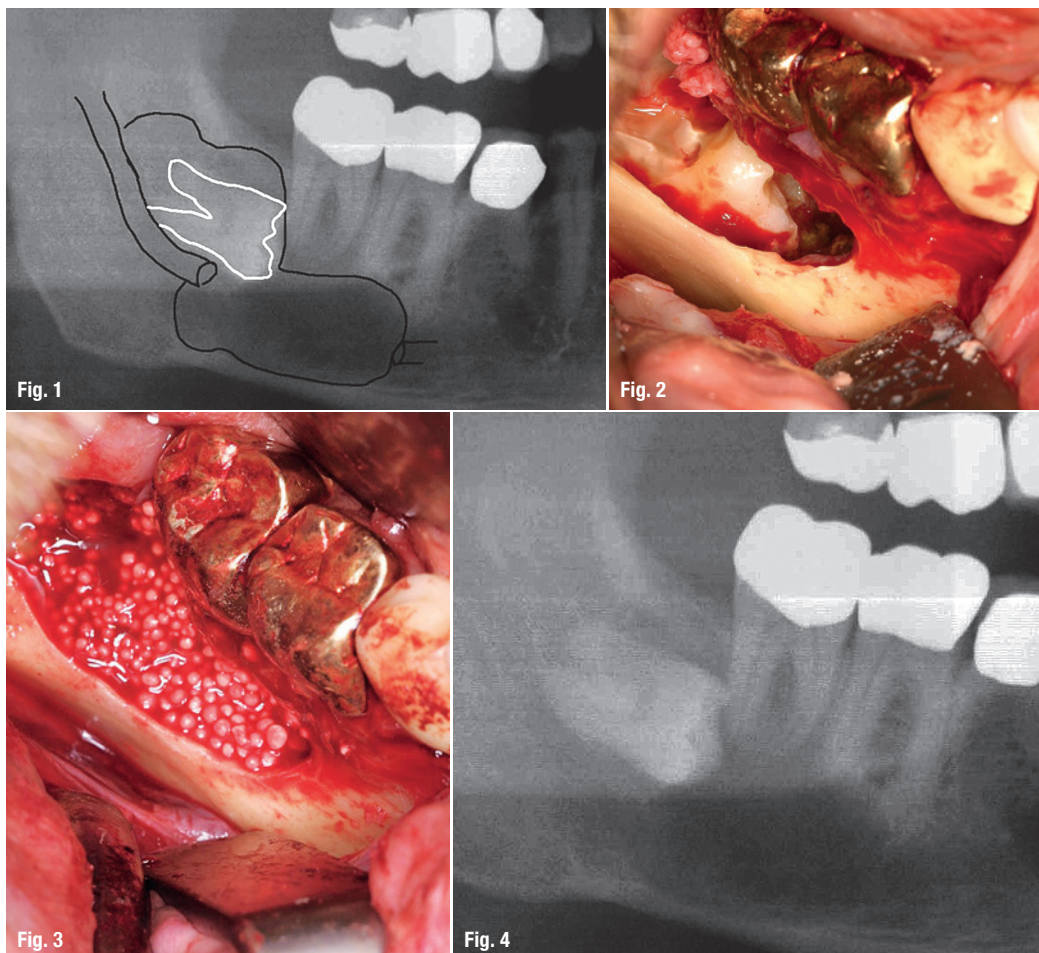


Fig. 1: Pre-op X-ray in right mandibular.

Fig. 2: After opening and preparation of a mucoperiosteal flap.

Fig. 3: Defect filling with CERASORB® Classic granules.

Fig. 4: Control X-ray after nine months shows a sufficient bony consolidation.

more porous and polygonal shaped CERASORB® M. Here, after removal of teeth #26, #27 and #28, the ridge was preserved with the new product.

The extraction of the deeply destroyed molar teeth and the dislocated wisdom tooth left an extensive hard- and soft-tissue defect (Fig. 5). The extraction sockets were filled with dry CERASORB® M granules to allow a better evaluation of the defect's bleeding capacity (Fig. 6). Regarding the extensive soft-tissue loss, the wound was additionally covered with a resorbable membrane (Epi-Guide®; Fig. 7) and fixed with sutures. The following healing process exposed a soft-tissue defect (Fig. 8), which afterwards healed completely. The control X-rayscan after six months showed a homogenous bony rehabilitation of the extraction sockets and a complete preservation of the alveolar ridge dimension (Fig. 9).

Case 3: CERASORB® Foam

In 2015 after surgical removal of teeth #16 and #17 following the "basic protocol" alio loco, the patient visited the clinic. After clinical examination, a compromised alveolar ridge, lowered sinus and an iatrogenic damage of the Schneiderian

membrane were noted. An implant treatment was the best choice in this situation (Fig. 10).

Firstly, a mucoperiosteal flap was designed and elevated. Then, the lateral window was cut to expose the Schneiderian membrane. After elevation of the Schneiderian membrane, CERASORB® Foam was inserted to provide outline and to keep the membrane elevated (Fig. 11). The residual space was filled with CERASORB® M granules (Fig. 15).

In area 17, an implant was inserted, which was not possible for the first molar area due to a lack of primary stability (Fig. 12).

The postsurgical healing process was absolutely uncomplicated. The postimplantation scan (Fig. 13) revealed a significant growth of volume in the grafted area, providing the basement for an additional implant.

Case 4: CERASORB® Foam, Epi-Guide® membrane

The patient introduced in 2015 to our clinic with a surgical and prosthetic treatment done in Switzerland in 2012/13 asked for rehabilitation with an implant-

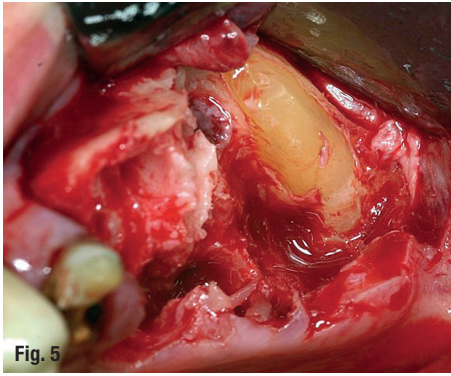


Fig. 5

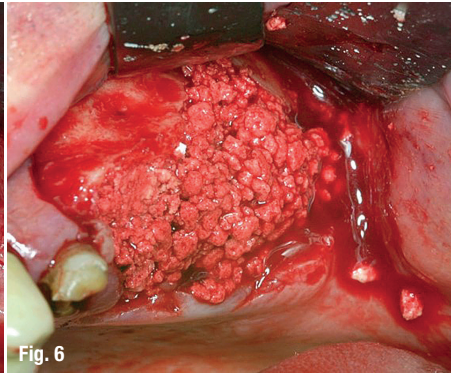


Fig. 6

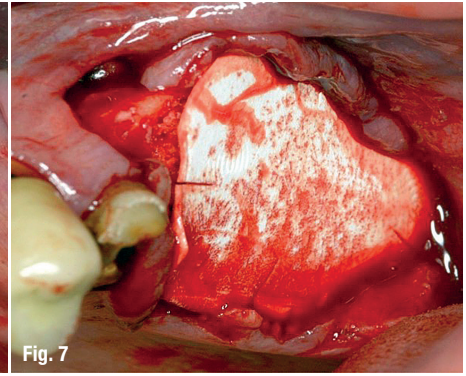


Fig. 7

Fig. 5: Extended hard- and soft-tissue defect after extraction.

Fig. 6: Dry CERASORB® M granules filled into the defect.

Fig. 7: Covering the wound area with a resorbable Epi-Guide® membrane.

Fig. 8: Soft-tissue dehiscence during the healing process.

Fig. 9: Control X-ray after six months: homogenous bony bridging and preservation of the alveolar crest dimension.

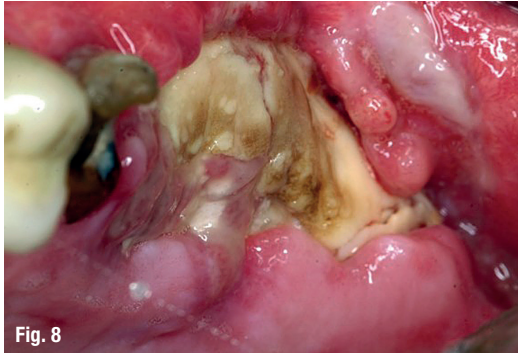


Fig. 8

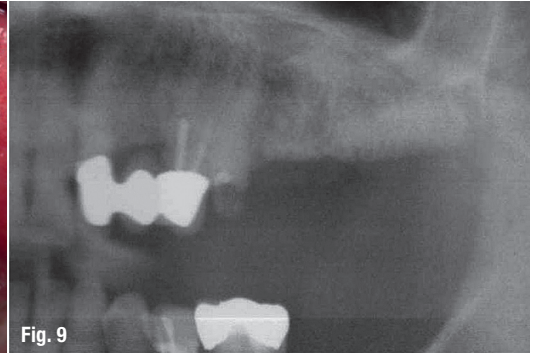


Fig. 9

based solution. The first inspection demonstrated the complexity of this case, that required a few interventions and posttreatments.

The CT scan (Fig. 14) displayed seven stainless steel leaf implants and a one-piece screw implant with partly relevant signs of osteolysis and an enormously big bone destruction. The complete construction had to be classified as inadequate and a complete clinical revision was needed.

The first surgical intervention in general anaesthesia was to remove the complete prosthetic construction and the implants. The implants were completely imbedded in inflammatory soft tissue. This provided a removal of the implants without any additional iatrogenic destruction of the considerable compromised alveolar bone.

After complete removal of the inflammatory soft tissue, there was a need for protection of the dam-

Fig. 10: Initial situation in the X-ray. Wish for implant solution.

Fig. 11: CERASORB® Foam for protection of the Schneiderian membrane.

Fig. 12: Implant in area 17. Defect reconstruction with CERASORB® M.

Fig. 13: Control X-ray after implant insertion.

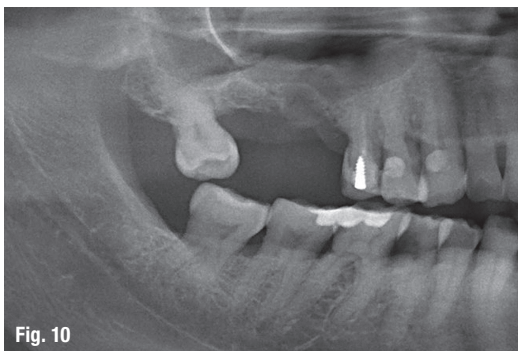


Fig. 10

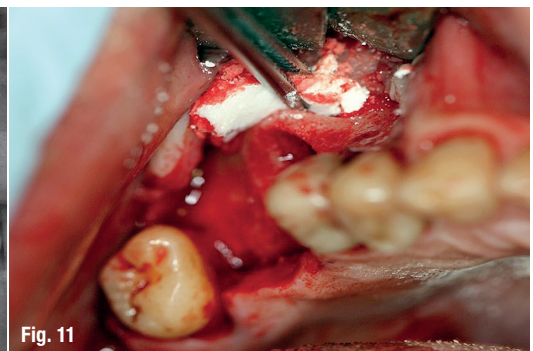


Fig. 11

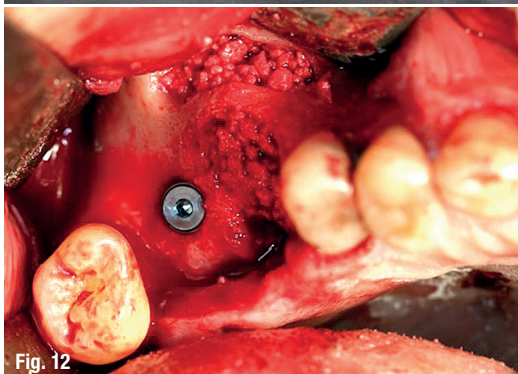


Fig. 12

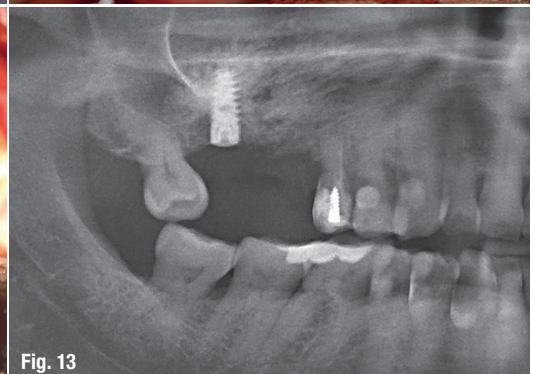

Fig. 13

Prof. Ofer Moses



Prof. Dieter Bosshardt



INTEGRATING RESEARCH AND PRACTICE

JOIN US!

5-7
OCTOBER

2017

MADRID,
SPAIN

Booth
S24

Industry Lunch Symposium

"The Way to Ithaka: From Vision to Clinical Implication".
Saturday, October 7 | Room 115 | 13:00-14:00^{hs}

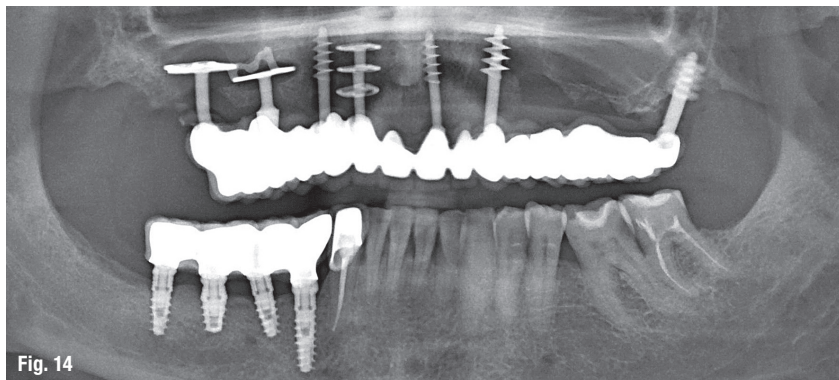


Fig. 14

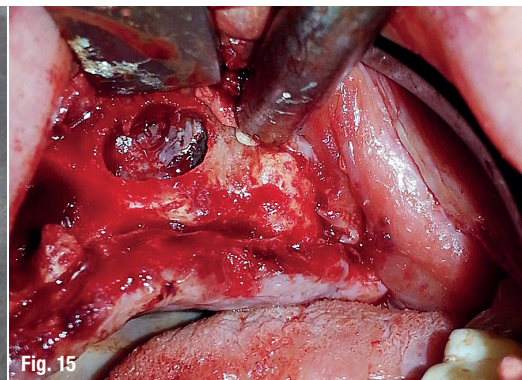


Fig. 15

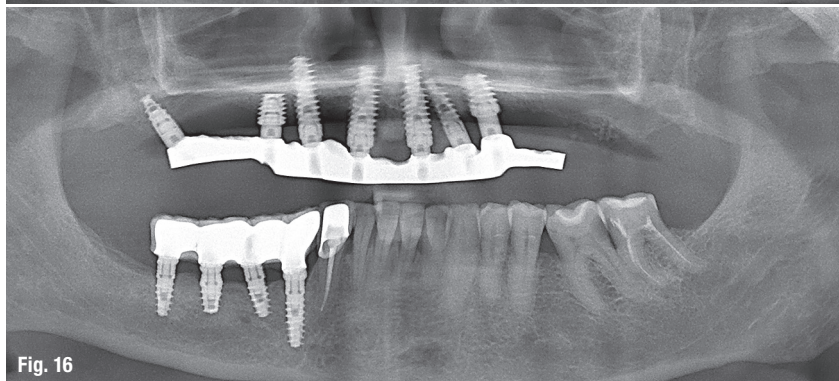


Fig. 16

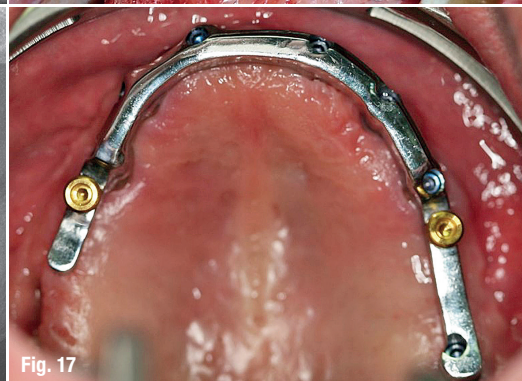


Fig. 17

Fig. 14: Initial situation (CT scan): massive hard-tissue defects with blade and screw type implants in the maxilla.

Fig. 15: Massively compromised sinus maxillaris on both sides.

Fig. 16: Second surgical treatment after nine months with implants and connecting rail.

Fig. 17: Milled rail with additional locators.

Fig. 18: Long-term provisory denture.

aged maxillary sinus (Fig. 15). This was done with CERASORB® Foam as a protective barrier. The residual defect was filled and reconstructed with CERASORB® M granules and for further stabilisation covered with an Epi-Guide® membrane. In the incisal area, three implants could be inserted. The reopening six months later was for insertion of four new implants. The removable, provisional prosthetic construction was created six months later and based on a rail and locators (Figs. 16 & 17). Even if the initial wish of the patient for a fixed construction is not yet fulfilled, a more than satisfactory solution was created (Fig. 18).

Summary

After first hostility, biomimetic bone regeneration materials and bone substitutes are established by a continuous development and improvement. A vast scientific data base certifies the high potential espe-

cially of the pure phase β -tricalcium phosphates to regenerate host bone.^{4,5} These materials are available in an unlimited amount and can avoid the morbidity of a donor bone site in most of the treatments.

Especially the collagen matrix imbedded β -TCP CERASORB® Foam earns a significant importance due to its easy application, protection of the Schneiderian membrane in sinus floor elevations and the collagen providing fast transformation to vital bone, which is important for most of the augmentation indications.

First, user observations and clinical studies are promising,^{6,7} particularly the histological results of biopsies prove the high potential for bone regeneration.^{8,9}

This article was first published in DENT IMPLANTOL 20, 5, 302-309 (2016).

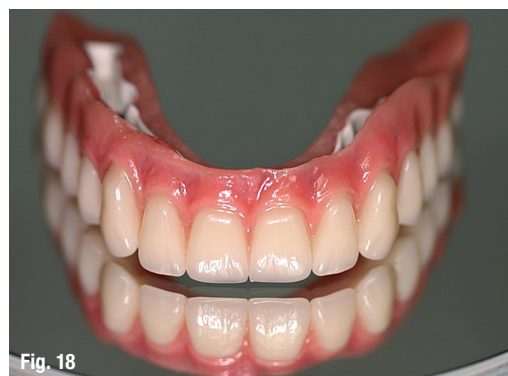

Fig. 18

contact

Prof. Dr Dr Stefan Schermer

Oral and Maxillofacial Surgery and Implantology, Berlin Clinic
 Leipziger Platz 3
 10117 Berlin, Germany
 Tel.: +49 30 206796-210
 chefarzt@berlin-klinik.de
 www.berlin-klinik.de

Author details



THE SELF-ALIGNING OT EQUATOR HOUSING

Metal to metal rotational core

Titanium anodized housing

Titanium liner

Elastic Cap

Passive insertion
reduces trauma

Correct divergency
up to 50°

25°

50°

25°

RHEIN83

Xenogeneic bone grafting materials

Authors: Dr Mike Barbeck, Dr Ronald Unger, Prof. Dr Frank Witte, Prof. Dr Sabine Wenisch & Prof. Dr Dr Reiner Schnettler, Germany



Nowadays, a variety of bone substitutes are available for the clinical user. Interestingly, these materials significantly differ regarding their raw materials or manufacturing processes. As an alternative to autologous bone tissue (autograft), which is still applied as "gold standard" due to its extensive regenerative properties, bone substitutes from other natural sources become more and more relevant in regenerative dentistry. These bone substitute materials are either derived from human (allograft) or animal origin (xenograft).

In case of these materials, the obtained bony extracellular matrix based on calcium phosphates should finally serve as bone substitute (Figs. 1–3). Based on the physicochemical similarity of this class of bone substitutes to the autologous bone tissue, it can be assumed that these materials are the ideal choice for osseous regeneration. Preferentially, bovine bone is used as source tissue in the daily dental practice, as in case of the two primarily applied bone substitute materials Bio-Oss™ and cerabone®.

Safety aspects and purification processes

For the clinical application of bone substitutes from natural sources it is inalienable to purify the donor tissue from immunogens to guarantee a re-




Fig. 1

generation process without complications such as rejections or disease transmissions. To ensure the safe application of such bone substitute materials, different purification steps of the donor tissue are applied.

The first step is the suitable selection of donor animals before the initiation of the purification process. Hence, for the production of Bio-Oss™ and cerabone® bovine femoral heads from registered suppliers located in Australia and New Zealand are processed as both countries are recognised to have a negligible BSE risk according to the World Organi-

Fig. 1: (Ultra-)Structure of a cerabone® particle revealing the preservation of its trabecular natural architecture.

Fig. 2: Surface pattern of a cerabone® particle showing the retention of the natural microstructure and the purification status based on cell-free osteocyte lacunae.

Fig. 3: Cross-section of a cerabone® particle (µ-CT) revealing the retention of the lamellar natural structure after completed purification of the xenogeneic bone graft.




Fig. 2

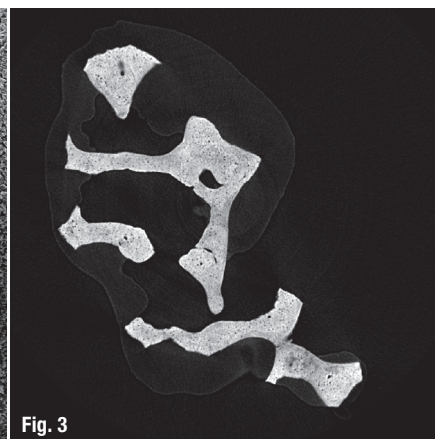


Fig. 3

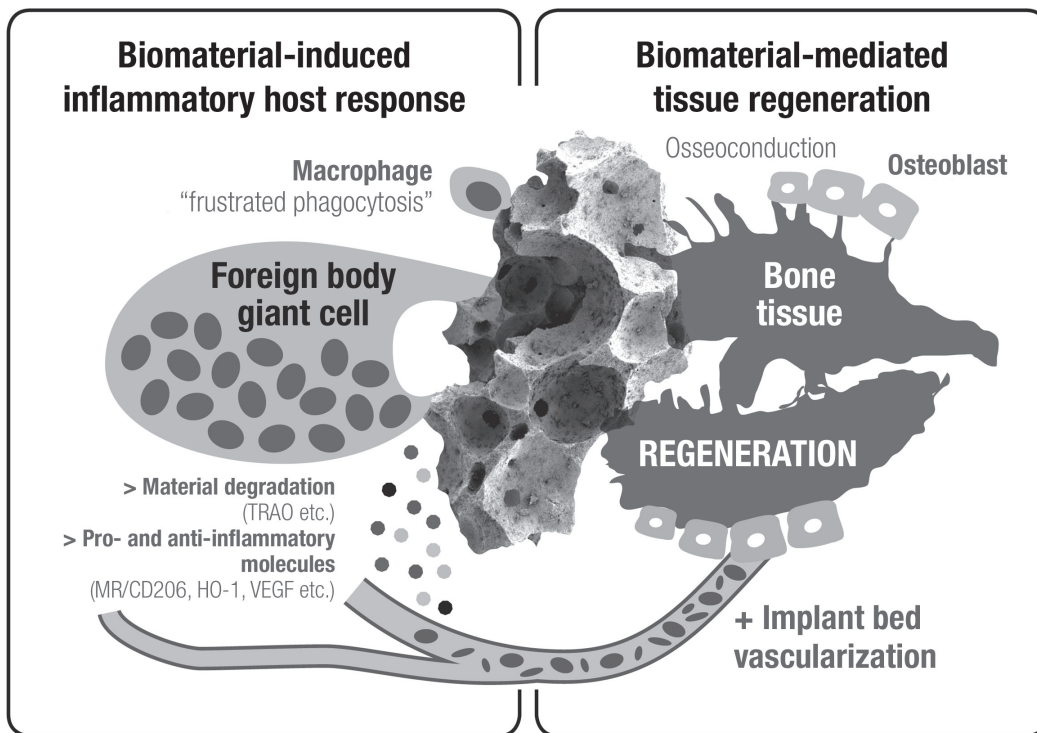


Fig. 4: Schematic illustration of the correlation between cellular and inflammatory processes caused by most of the applied bone grafting materials, the process of implant bed vascularisation and the process of bone tissue regeneration (based on a previous publication by Barbeck et al.⁹).

sation for Animal Health (OIE). Afterwards, complex purification steps including both chemical and physical methods are applied for a complete purification. However, those methods are occasionally discussed because of possible rejection reactions or a transfer of pathogens while applying bone grafting materials. In this context, the temperature treatment for the purification plays a major role. Bio-Oss™ is processed at temperatures of approximately 300 °C, while the bone substitute material cerabone® is purified by notably higher temperatures of up to 1,250 °C.^{1,2} This difference in temperature seems to be of significant importance for the safe application of xenogeneic bone substitutes.

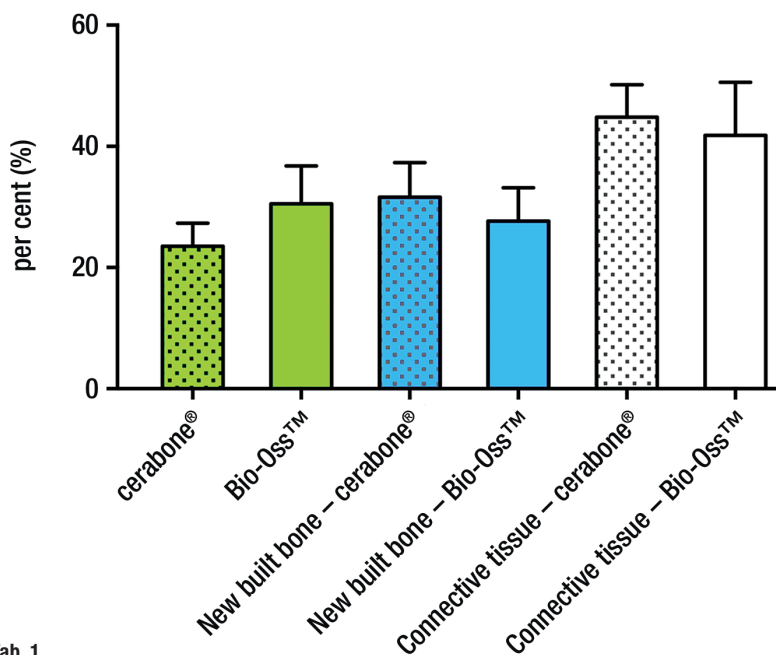
The purification process of bovine bone tissue was evaluated in a recent review by Kim et al.³ Interestingly, the authors concluded that the inactivation of prions in Bio-Oss™ is rather based on the applied

temperature than a result of the treatment with highly concentrated sodium hydroxide (NaOH). While this chemical process was described as efficient by Wenz et al.,⁴ the reliability and sensitivity of the used tests were questioned by Kim et al.³ In this review, the authors describe that prions will only be effectively destroyed by heating up to 1,000 °C for five minutes. Furthermore, the according EU-guidelines for medical devices utilising animal tissues and their derivatives (Part 1: Application of risk management, EN ISO 22442-1), point out that a treatment at temperatures above 800 °C is reducing the risk of the transmission of Transmissible Spongiform Encephalopathies (TSEs) to an acceptable minimum.

To assure a maximum level of safety, cerabone® is heated to temperatures above 1,200 °C during processing. Thus, organic parts like cells and proteins are removed and even potentially contained prions and



Fig. 5: The cerabone® product family—naturally, safe and pure.



Tab. 1

Tab. 1: Histomorphometrical results showing comparable values of newly formed bone, remaining bone grafting materials and connective tissue for Bio-Oss™ and cerabone® (based on previous publications^{2,5}).

other pathogens are destroyed. Despite the treatment at high temperatures, the natural bone structure is preserved (Figs. 1–3) making cerabone® a safe and reliable product for bone regeneration applications.

Inflammation and bone regeneration

Data from preclinical and clinical studies show comparable values for new bone formation, remaining bone grafting material and connective tissue for both xenogenic bone substitutes mentioned above (Tab. 1).^{1,2,5} These results refer to similar biological activities of Bio-Oss™ and cerabone®. However, in case of cerabone® higher numbers of multinucleated giant cells (MNGCs) were found within the first days after its implantation.² Furthermore, the comparison to different other studies shows that the initial number of MNGCs in case of cerabone® is significantly lower as found in the implant bed of fast degradable synthetic materials based on tricalcium phosphates. These results confirm several other studies claiming the long-term stability of xenogenic bone substitutes as it was shown that MNGCs are involved in the biodegradation of bone-grafting materials by phagocytosis.^{6,7}

Interestingly, the MNGCs were identified as foreign body giant cells (FBGCs) based on their molecule expression.⁸ However, more information is still needed to get further conclusion regarding their differentiation.^{8,9} Interestingly, the degradation process of bone substitutes and the process of bone tissue regeneration are closely connected via the relevant cell types such as macrophages and MNGCs (Fig. 4). In this context, it was shown that both

macrophages and MNGCs on the one side express pro-inflammatory molecules that are relevant for the degradation process, but also secrete anti-inflammatory substances needed for tissue regeneration.⁹ One of the most important signaling molecules is the vascular endothelial growth factor (VEGF), which has direct and indirect impact onto different processes important for successful tissue regeneration.^{8,9} Thus, VEGF induces angiogenesis at the implant site, which has indirectly a positive influence on bone tissue growth, and also direct influence on the development and activity of osteoblasts.^{8,10}

In case of the xenogenic bone substitute material cerabone®, it can be assumed that the observed higher numbers of MNGCs might have a positive effect on bone regeneration. Interestingly, an initially improved bioactivity for cerabone® combined with a higher vascularisation at the implant site was demonstrated, which might be based on the increased number of MNGCs compared to Bio-Oss™.² Thus, an improving effect on bone regeneration could be concluded after the application of cerabone®. In combination with the hydrophilic nature of this material,¹ which has been shown to significantly support the regeneration process by promoting the growth of osteoblasts, cerabone® can be considered as a reliable bone grafting material with an assured safety for both clinical user and patient.

Summary

Altogether, it can be concluded that the xenogenic bone substitute material cerabone® is able to ensure the highest possible safety from disease transmission due to the high temperature treatment. Furthermore, it is assumable that the relatively high numbers of multinucleated giant cells express high amounts of anti-inflammatory molecules and support a fast and high implant bed vascularisation and therefore, might favour the bone regeneration process.

contact

Dr Mike Barbeck

Julius Wolff Institute and Center for Musculoskeletal Surgery
Berlin-Brandenburg Center for Regenerative Therapies
Charité – Universitätsmedizin Berlin
Augustenburger Platz 1
13353 Berlin, Germany
Tel: +49 152 04165585
mike.barbeck@charite.de

Author details



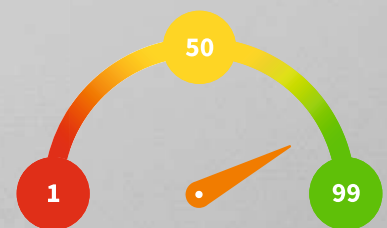


Penguin^{RFA}

MONITOR OSSEOINTEGRATION



- ▶ Autoclavable
20 times
- ▶ ISQ Standard
Calibrated™
- ▶ Optimal platform fit
- ▶ Laser marked with
type number



The ISQ-scale is from 1–99 and tells you how stable your implants are.

Dynamic navigation in fully edentulous maxilla

Authors: Prof. Dr Hakan Uysal & Dr Noyan Başal, Turkey



Preoperative planning is the most important part of a successful implant rehabilitation and requires multiple parameters to be considered for the precise placement of implants. The implants should be placed not only within anatomical boundaries but also be strategically located to support a prosthesis that will fulfil both functional and aesthetic requirements.

3-D virtual images are being used through computer software, which transforms CBCT scans into 3-D virtual models. However, after a precise planning or virtual realisation of the treatment, the osteotomy should also be executed precisely according to the plan and would likely require guidance of the drills and the implant.

For years, stereolithographic static guides have been used successfully for implant osteotomies, using detailed information implemented through 3-D virtual images.^{1,2} Static guides on the other hand present several disadvantages. The loss of tactile feeling during osteotomy and the fact of being limited to the

predesigned drilling trajectory are considered to be their major drawbacks.

Real-time navigation

A recent technology, which provides dynamic guidance through a real-time navigation for implant osteotomy, offers not only accuracy, but also additional valuable advantages during an operation.^{3,4} With this technology, the location and diameter of implants can be modified and a flap can be incised intraoperatively whenever needed.

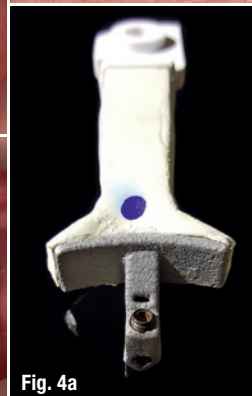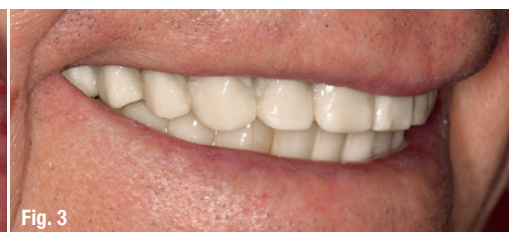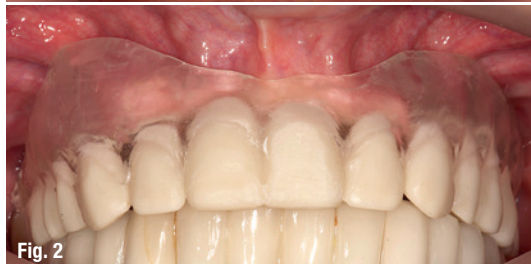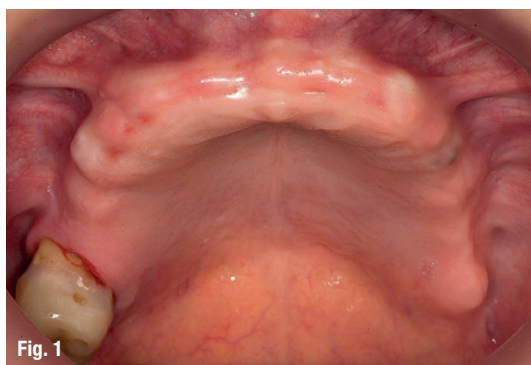Furthermore, dynamic navigation enables the surgeon to adjust the surgical plan during surgery. In case of an unexpected low bone quality, an additional implant could be planned with the software and placed additionally. Moreover, one of the most significant benefits of dynamic navigation is the ability to use it also for alveoplasty and reshape the alveolar crest's topography during the same surgery, together with the implant placement.

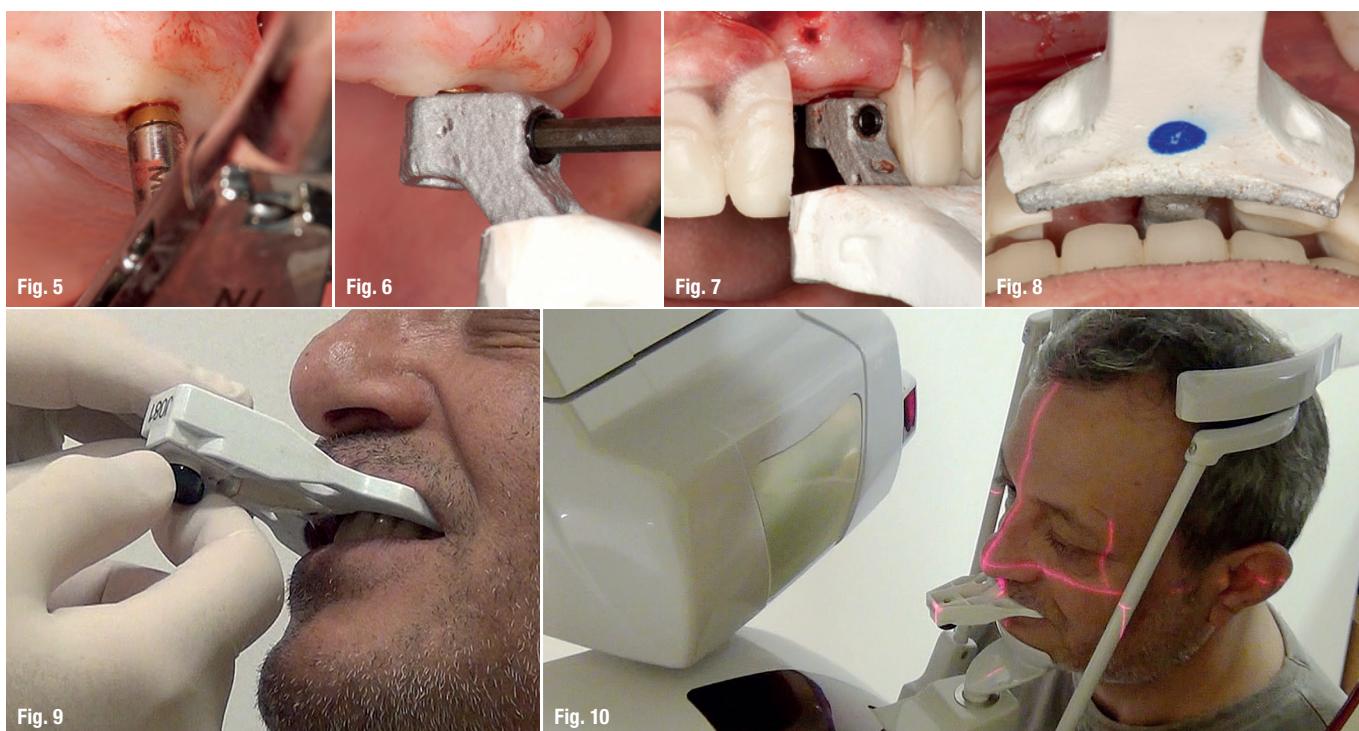
Fig. 1: Patient wants a screw-retained fixed prosthesis.

Fig. 2: Radio-opaque tooth set-up for prosthetic planning.

Fig. 3: Scan prosthesis at try-in to check its fit, aesthetics and maxilla mandibular relation.

Figs. 4a & b: Navident H-Arm (a) and V-Arm (b).





The precise location of implants is case-specific and determined by different factors. If an edentulous case is to be restored with an implant-supported screw-retained fixed prosthesis, implant locations should be critically examined whether they can provide screw access holes within occlusal or palatal/lingual parts of the restoration. Frequently, alveoplasty is required for the recontouring of the ridge in order to obtain sufficient bone thickness at the level of the implant's collar.

This crestal trimming of bone may also be necessary in order to increase the inter-arch space and provide a sufficient volume for the restorative material, since dentogingival prostheses are frequently required to enhance aesthetics. In such cases, dynamic guidance can be used to level the alveolar crests as planned on virtual images, followed by precise multiple osteotomies.

Case

The following case report describes the treatment of a 65-year-old male with an one-year history of maxillary partial edentulism (Fig. 1). He was discontent with the stability of his prosthesis and expressed that through the unstable prosthesis situation he has lost social self-confidence. In the initial appointment he thus stresses his need for a "fixed solution".

His medical history did not reveal any specific systemic disease or condition that contraindicates oral surgery. The patient's soft tissues on the edentulous ridges were healthy and panoramic X-rays showed

expanded sinuses at both sides and irregular alveolar ridges. The treatment plan, carried out for a maxillary screw-retained fixed prosthesis, included two implants at the pre-maxillary region and two tilted in the posterior maxilla to avoid a sinus lift surgery.

Stent placement

In order to acquire both anatomical and prosthetic information prior to the surgery, a scan prosthesis was manufactured by duplicating the maxillary denture (Fig. 2). It is important that the scan prosthesis has the same aesthetic and functional information as the complete denture or set-up. Thus, the scan prosthesis was checked for its fit, aesthetics and maxilla mandibular relation (Fig. 3). The scan prosthesis was then used together with a Navident Edentulous Kit for CBCT imaging.

The Navident edentulous protocol consists of a SDI (Small Diameter Implant of 2.2 mm or 2.5 mm diameter), which is inserted into the alveolar ridge of the arch to be operated, prior to the acquisition of the CT scan. This temporary SDI serves as a mount for the CT marker and for the Jaw Tag used for the registration of the CT scan to the patient and for tracking the patient's jaw during surgery.

The SDI can be placed either in a vertical position or in a horizontal position in relation to the alveolar crest. A special plastic arm with a proprietary aluminium bracket is then used for the connection of the CT marker and Jaw Tag to the SDI. Two types of arms are available: one for a vertically placed and another for a horizontally placed SDI (Figs. 4a & b). In the presented

Fig. 5: Placement of an SDI as anchor mount.

Fig. 6: Connecting the NaviStent Arm to the SDI.

Figs. 7 & 8: Adjusted scan prosthesis for combined scanning.

Fig. 9: Connecting the CT marker to the NaviStent.

Fig. 10: Patient positioning in the CBCT scanner.

case, the SDI has been placed vertically to achieve the required stability (Fig. 5).

The CT marker, containing the fiducial marker used for the registration of the CT scan to the patient, was attached to the V-type arm on the fix-plate at one end. At the other end, the assembly was placed over the SDI's square head and secured to it using a setscrew which was embedded in the aluminium bracket, with this creating a complete "NaviStent" (Fig. 6).

The scan prosthesis was then modified to accommodate the aluminium bracket before it was placed over the maxillary edentulous ridge (Figs. 7 & 8). For accuracy purpose, it is imperative that the scan prosthesis is stable, while at the same time it should not interfere with the NaviStent.

CT scan

The following CBCT imaging protocol for Navident dynamic navigation was applied during CT imaging.

Before the scanning procedures, both the modified scanning prosthesis and the NaviStent had been placed into the patient's upper jaw (Figs. 9 & 10). A CT marker was then connected to the NaviStent. A scout view had been acquired prior to the actual scan to verify the presence of the CT marker in the CT scan. In order to allow for accurate registration, at least three corners of the fiducial marker must be present in the scan. In order to maintain a high level of accuracy during navigation, it is mandatory that the slice thickness must not exceed a maximum of 0.4 mm. In this case, the slice thickness had been set to 0.3 mm. Afterwards, the scan was exported in DICOM format, then imported into Navident.

Osteotomy planning

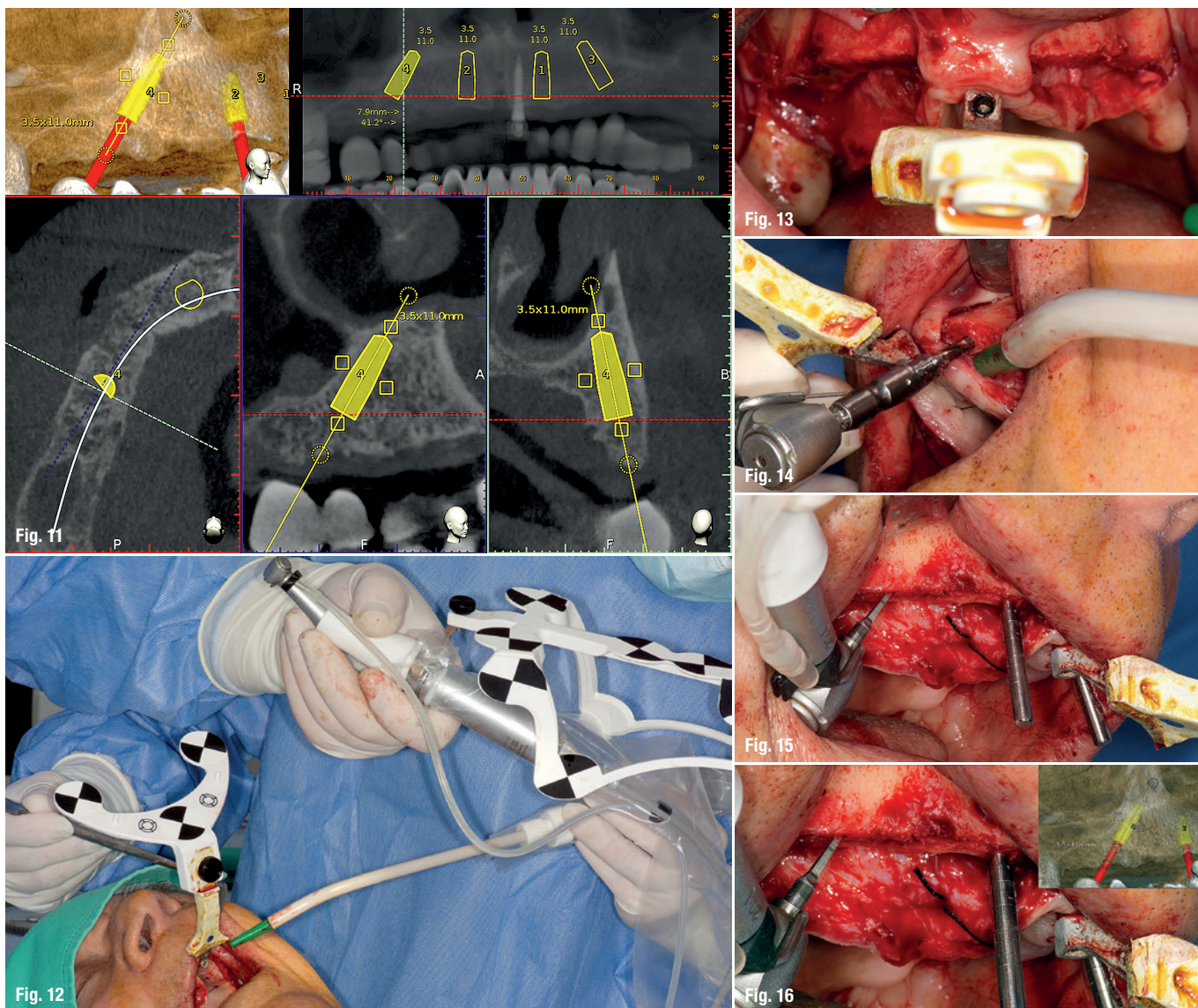
When the CT scan is imported into Navident, a proprietary algorithm detects the fiducial's image in the scan, then registers it with a mathematical model of the fiducial that is stored in the computer memory. This enables Navident to map the Jaw Tag, which is

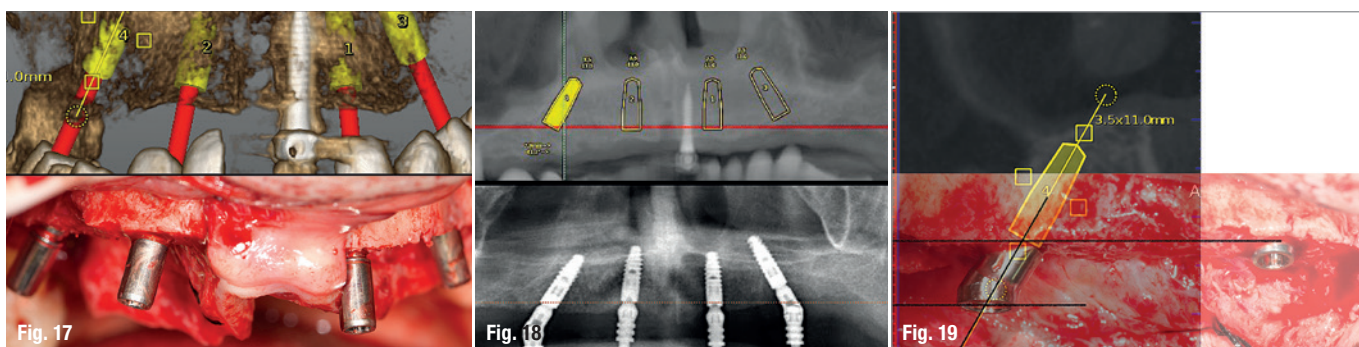
Fig. 11: Prosthetic implant planning using the Navident software.

Fig. 12: Real-time feedback is provided by Navident using a Jaw Tag and Drill Tag during surgery.

Fig. 13: The alveolar crest was levelled by a rongeur.

Figs. 14–16: Implants are placed exactly as planned.





the tag mounted onto the patient, to the CT image during navigation.

For this case, Ankylos dental implants had been selected. The implants with a diameter of 3.5 mm and a length of 11 mm were planned on the locations 15, 12, 22 and 25 using the Navident planning software (Fig. 11). The following parameters were considered when osteotomies were planned:

1. Alveolar ridges, though they had a sufficient bone height, were narrowing at the crestal 1/3. Without waiving or compromising the restorative information, the implant locations were planned to be deeper where at least 2 mm of buccal plate thickness could be achieved.
2. Straight implants were placed at 12 and 22 and tilted ones at 15 and 25.
3. Angulated distal implants were planned 1 mm mesially to the sinus wall.
4. The angle of distal abutments was planned to be 30 degrees to the occlusal plane to have the retaining screws access holes placed in the denture's occlusal aspect since screw-retained abutments have 30 degree joints.
5. The plane of the implant collars was planned to be parallel to the occlusal plane.

Surgery

Before surgery, the CT marker was disconnected from the NaviStent Arm and replaced by the Jaw Tag, which is detected by the Navident camera. A Drill Tag was installed onto the handpiece (Fig. 12). Together with the Jaw Tag, they provide real-time feedback during surgery, enable the surgeon to communicate with the software and place the implant as planned.

A crestal incision was made at either side. Pilot drills were used to start osteotomy followed by the Ankylos dental implant drilling protocol. All drills were navigated according to the planned trajectory, until real-time feedback confirmed that its tip has reached the apical end of the planned osteotomy. The alveolar crests were levelled by a rongeur (Fig. 13). Between each trimming attempt, the pilot drill was touched to

the trimmed surface of the crestal bone and its level was checked on the virtual image.

The trimming of the bone was completed under the guidance of dynamic navigation and the pilot drill was again touched to the newly formed alveolar crest. Implants were inserted in the osteotomies as planned (Figs. 14–16), the gingival tissue placed back and sutured with coated poly-gactin 910 sutures. The patient was medicated with antibiotics and chlorhexidine mouth rinse and was released with NSAID's.

Conclusion

The Navident navigation surgery system achieves a successful guidance both in alveoloplasty and implant osteotomies in the edentulous maxilla (Figs. 17–19). In the presented case, the proposed protocol was highly efficient in gathering 3-D prosthetic and anatomical information for the planning. Dynamic navigation provided a precise guidance in the execution of the planned osteotomies through a flexible surgical operation.

Figs. 17 & 18: Optimal surgical result.
Fig. 19: Exact angular position of posterior implants for angulated abutments.

contact

Prof. Dr Hakan Uysal

DDS, PhD, Prosthodontist
Abdi İpekçi Cad. 61 Tesvikiye
Istanbul, Turkey
Tel.: +90 212 2196744
uysalh@gmail.com

Author details



Dr Noyan Başal

Klinik212 dental clinic
Valikonağı Cad. No:86/A
Nişantaşı
Istanbul, Turkey
Tel.: +90 5324139118
noyanbasal@gmail.com

Author details



Nobel Biocare

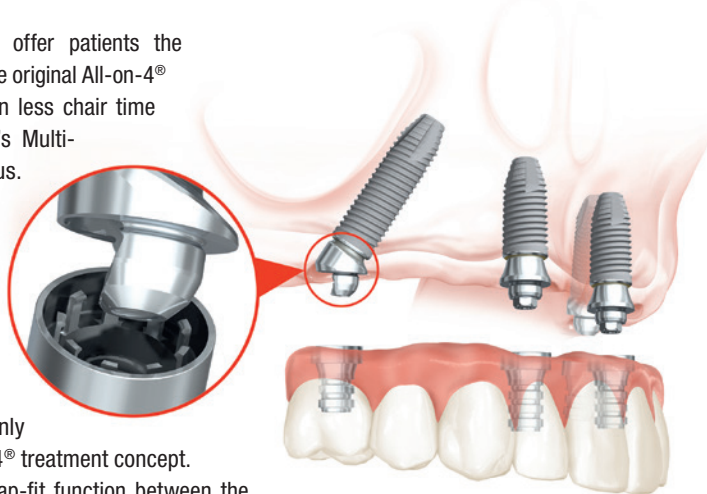
Added efficiency for All-on-4® treatments

Clinicians can now offer patients the proven benefits of the original All-on-4® treatment concept in less chair time with Nobel Biocare's Multi-unit Abutment Plus.

This next-generation component is designed to substantially reduce the time required to perform a denture conversion—a procedure commonly

used for the All-on-4® treatment concept.

By introducing a snap-fit function between the Temporary Snap Coping Multi-unit Plus and the abutment, screws are no longer required during the try-in process. This means the common practice of removing the temporary cylinders and the denture several times during the conversion process can be done in a few snaps, with no need to tighten and loosen four screws each time. This represents a significant time-saving opportunity for the clinician. It can also dramatically increase



patient comfort and eliminates any worry about the screws potentially dropping out.

Nobel Biocare Services AG
P.O. Box
8058 Zurich-Airport, Switzerland
www.nobelbiocare.com
Exhibitor at EA0 congress 2017

Bicon

Time-proven design

The Bicon SHORT® Implant is an example of a time-proven geometric design that successfully transfers the occlusal forces on its prosthesis to its surrounding bone by appropriately integrating the following features: a bacterially-sealed, 1.5 degree locking taper abutment to implant connection and a subcrestally placed, sloping shouldered implant with a plateaued tapered root form body. Additionally, these integrated features compensate for the implant's ankylosed nature by successfully transforming occlusal forces to acceptable strains within the bone, provide for healthy and gingivally aesthetic peri-implant tissues, as well as for the callus formation of cortical like bone with central vascular systems.



Bicon Europe Ltd.
Hauptstraße 1
55491 Büchenbeuren, Germany
www.bicon.com
Exhibitor at EA0 congress 2017

Dentsply Sirona

Integrated solutions and seamless workflows

Dentsply Sirona continues to drive the development of integrated implant dentistry: Digitally supported workflows and harmonised products and processes are combined to create efficient and reliable treatment results. During the World Summit Tour in Nice, visitors

from more than 25 countries could experience how Dentsply Sirona products enable optimally integrated workflows for individual patient treatment.

In workshops, presentations and in the exhibition area—called the Inspiration Hub—integrated

solutions in implant dentistry were presented from a treatment team and a patient perspective. The presentation of the digital implant workflow visualised a clinic-to-laboratory workflow and a chairside workflow. "This is the first time the entire process has been presented live. We are very proud to show that we can offer our customers everything they need in one place—Dentsply Sirona is the only company to offer this," says Lars Henrikson, Group Vice President, Dentsply Sirona Implants.



Dentsply Sirona –
The Dental Solutions Company™
Sirona Straße 1
5071 Wals/Salzburg, Austria
www.dentsplysirona.com
Exhibitor at the DGZI annual congress 2017
and EA0 congress 2017

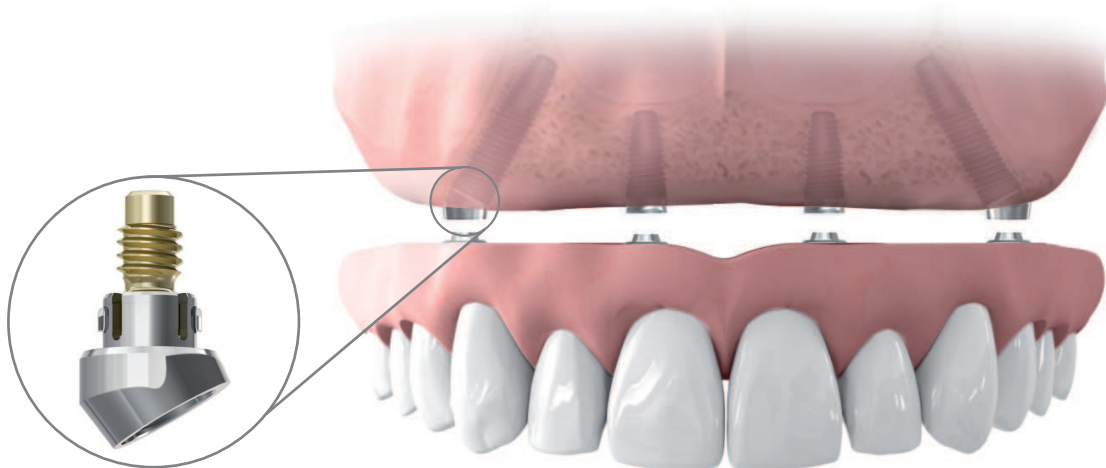
EAO)))

EUROPEAN ASSOCIATION FOR OSSEOINTEGRATION

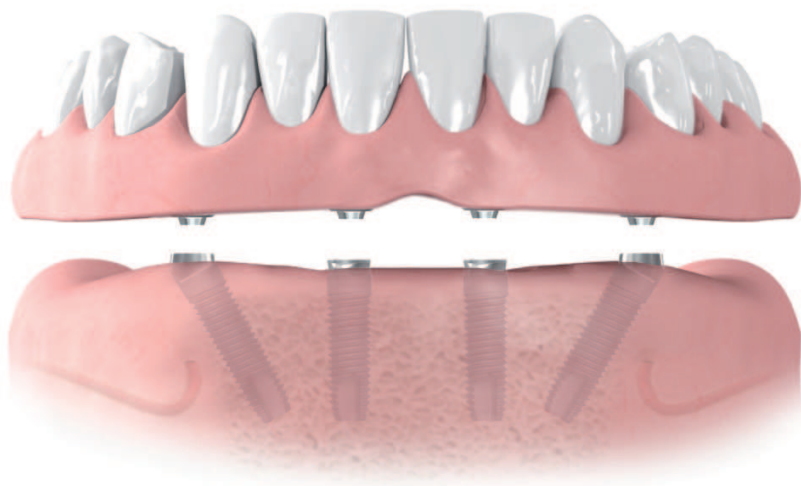CONGRESS

Visit us at Booth B16

neoss®



neoss 4+



botiss

New synthetic barrier membrane

With the introduction of permamem[®], botiss expands its regeneration system by offering an exceptionally thin, non-resorbable, biologically inert and biocompatible membrane made of 100% high-density polytetrafluoroethylene (PTFE). As such, it maintains its structural integrity during implantation and over time. Due to its dense structure, permamem[®] acts as an efficient barrier against bacterial and cellular penetration and is therefore indicated for open healing in certain clinical indications like socket and ridge preservation. The biocompatibility of the product has been proven by preclinical data *in vivo*. botiss has already received positive feedback from the market regarding the handling and clinical performance of the new



membrane. Internationally renowned clinical experts like Dr Marius Steigmann and Dr Stavros Pelekanos have reported their successful use of permamem[®] in alveolar socket management and Guided Bone Regeneration (GBR).

botiss biomaterials GmbH
Hauptstraße 28
15806 Zossen, Germany
www.botiss-dental.com
Exhibitor at EA0 congress 2017

CAMLOG

Prosthetic solutions on ceramic implants



The CERALOG[®] implant system includes two proven ceramic implants: the one-piece CERALOG[®] Monobloc implant and the CERALOG[®] Hexalobe implant, the first two-piece ceramic implant with reversibly screw-retained PEKK abutments. The Hexalobe connection design, which is suitable for ceramics, allows modern prosthetic solutions on a ceramic implant. The Hexalobe implant in its current configuration has been used successfully in clinical practice since 2013.

The demand for aesthetic and particularly tissue-friendly implant restorations is showing steady growth. Sophisticated ceramic implant systems are one solution. The company CAMLOG meets these requirements and entered the market for ceramic implants with CERALOG[®]. CAMLOG has been working on ceramic implants for several years, and in summer 2016 acquired a majority stake in AXIS biodental SA, a Swiss pioneer in the production of zirconium dioxide implants.

CERALOG[®] is initially only available in Germany, Austria and Switzerland, and is gradually being introduced in other countries.

CAMLOG Biotechnologies AG
Margarethenstr. 38
4053 Basel, Switzerland
www.camlog.com
Exhibitor at the DGZI annual congress 2017 and EA0 congress 2017

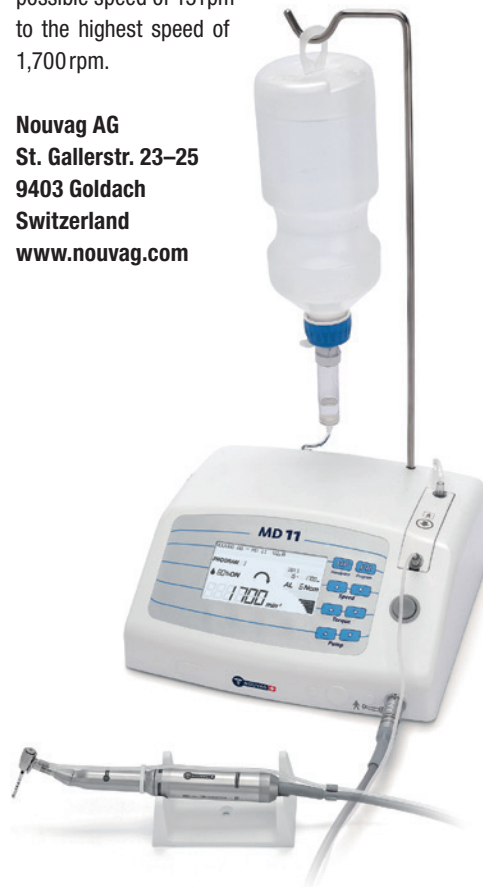Nouvag

Sophisticated motor management

Nouvag's latest development in the field of Implantology is the motor system MD 11. Drilling, thread cutting, screwing in the implants and placing the cover screw are now organised in separate programmes. The insertion of the tubing set is done with very little effort due to the great visibility of the mounting bracket and easy to reach notches in the bracket. The display shows all information at a glance, no key pressing necessary. Even the activation of the cooling pump and the changing of the pump speed is conveniently done by pressing switches on the pedal.

To make the set of the MD 11 complete, Nouvag offers all required contra angles such as the 1:1, 16:1, 20:1, 32:1 and a 70:1. The 20:1 contra angle, also available with LED spotlight, covers the largest field of the implantologists tasks, thanks to the sophisticated motor control of the MD 11 which provides sufficient torque from the lowest possible speed of 15 rpm to the highest speed of 1,700 rpm.

Nouvag AG
St. Gallerstr. 23–25
9403 Goldach
Switzerland
www.nouvag.com



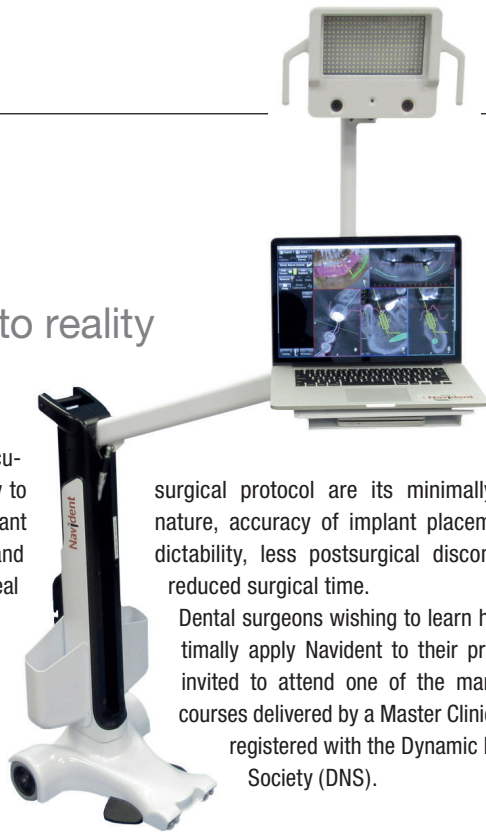
ClaroNav

Mapping virtual to reality

As breakthrough in computer-aided implantology, Navident offers clinicians an easy to use, accurate, portable and affordable way to plan desired restorations and implant placement on a virtual patient and then execute the plan on the real patient's jaw.

The virtual patient's jaw is created from the CBCT and, optionally, digital impression data in only seconds. The plan, including crowns and implants, is prepared in a few minutes and can be modified any time.

During surgery, Navident shows the advance of the drill tip or implant in the patient's jaw relative to the surrounding structures and the implantation plan. The advantages of this



surgical protocol are its minimally-invasive nature, accuracy of implant placement, predictability, less postsurgical discomfort and reduced surgical time.

Dental surgeons wishing to learn how to optimally apply Navident to their practice are invited to attend one of the many clinical courses delivered by a Master Clinical Trainer registered with the Dynamic Navigation Society (DNS).

ClaroNav

1140 Sheppard Avenue West, Unit 10
Toronto, Ontario M3K 2A2, Canada
www.claronav.com
Exhibitor at EA0 congress 2017

TRATE

Open implant system

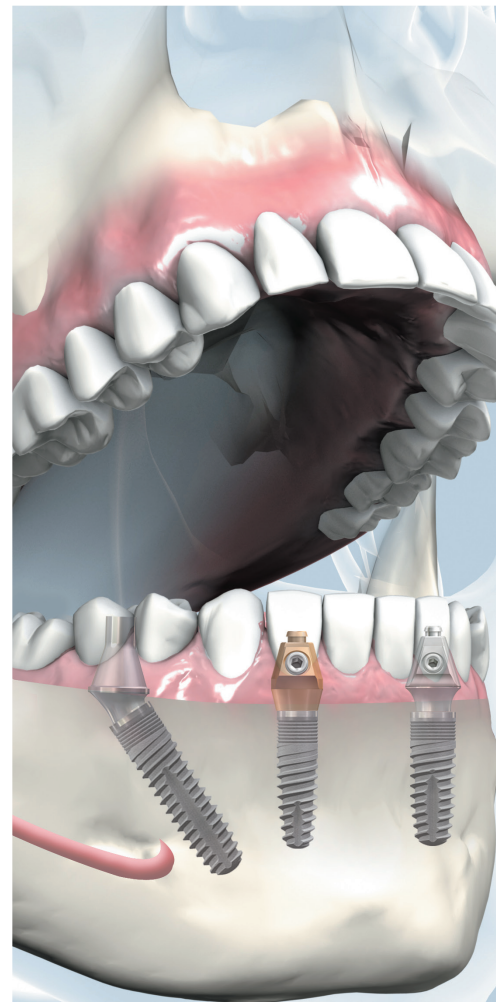
With the open implant system ROOTT, the company TRATE offers a fresh simplified outlook to modern concepts of implantology. The brand has three radically innovative implant family designs. The mainstay is the two-piece implant—ROOTFORM type—it has an aggressive implant body design with a deep tapered conical connection and an indexing hex. The wide variety of prosthetic options, including the multiunit connection, make it a very versatile system. ROOTT also has a refined selection of single-piece implants. The compression screw implant—COMPRESSIVE type—is ideal for simplified immediate loading protocols in healed edentulous ridges and the axial basal or bicortical

screw design is used to treat the more challenging cases with simplicity and efficiency. TRATE has its own production site within the EU, where ROOTT implants are manufactured in a state of the art facility with the highest quality standards. This is a very high value implant system at an affordable price, something every implantologist must try to have in their armamentarium.

TRATE AG

Seestr. 58
8806 Bäch, Switzerland
www.trate.com

Exhibitor at the EA0 Congress 2017



SKYonics

IMPLANTOLOGY MEETS BIONICS

The SKY® fast & fixed
Therapy



Train the bone –
save the tissue with
Bionic framework and
veneering materials.
10 years success in immediate
full arch restoration.

- Easy to use
- Aesthetic results
- Increase profit

Call (+49) 0 73 09 / 8 72-4 41
to get more information about
the indications and the versa-
tility of the SKY® fast & fixed
therapy.

SKY
IMPLANT SYSTEM



Straumann

Precision from a different angle



Expand your options to leverage the quality of Straumann® screw-retained restorations—with flexibility and precision from a different angle. The Angled Solution Systems combine angled screw channels and a best-in-class self-retaining screwdriver. They offer treatment options for a wide variety of indications in the anterior and posterior zone and give the choice for either a

conventional or digital design. The angled screw channel of the restoration has been refined to help achieve the best aesthetic and functional outcome. No matter the implant, the screw channel can be tilted up by up to 25° in all directions. Yet, its diameter has been designed as small as possible in order to leave more space for a restoration. The proven Straumann conical screw connection and insertion torque of 35 Ncm provide strong retentive power. Discover the Angled Solutions offering and use a screw-retained approach where otherwise a cement-retained approach would have

been the only choice.

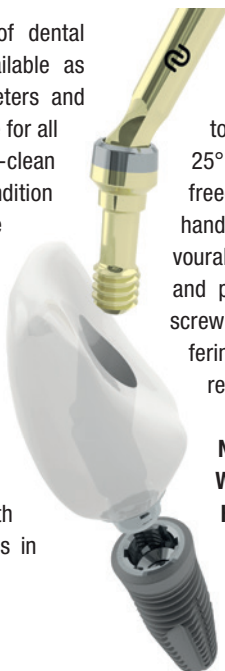
Institut Straumann AG
Peter Merian-Weg 12
4052 Basel, Switzerland
www.straumann.com

Exhibitor at the DGZI annual congress 2017
and EA0 congress 2017

Neoss

Screw-retained solutions for individual prosthetics

Neoss is an innovative developer of dental implant solutions. Implants are available as straight and tapered with six diameters and lengths of 7 to 17 mm and are suitable for all osseous qualities. The surface is ultra-clean and has high wettability as a precondition to successful osseointegration. The implant system has been designed to be intelligently simple offering unlimited prosthetic choices. With the single platform concept and single screwdriver restoration is simplified and unambiguous communication amongst the dental team is achieved. In addition, it gives you the prosthetic freedom to work with cemented or screw-retained solutions in titanium, gold, zirconia.



The Neoss angulated screw-access solution for individual prosthetics enables the freedom to design screw channels with up to 25° of angulation and 360° of rotational freedom. This solution improves both handling and aesthetics by enabling favourable screw channels in the anterior and posterior and by having a narrow screw channel diameter. The Neoss offering covers single and multiple unit restorations in a number of materials.

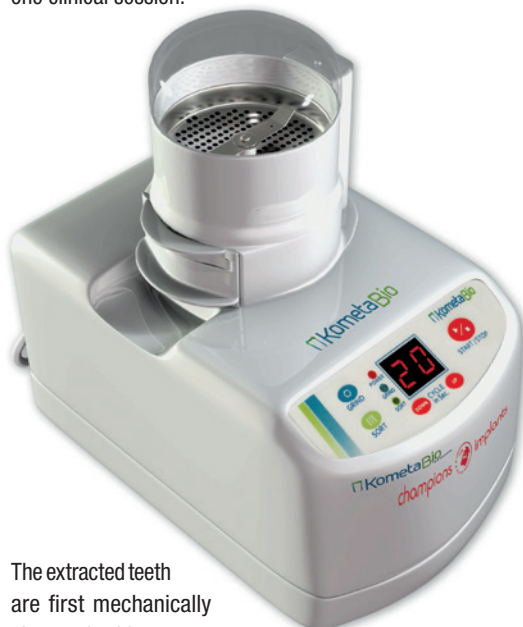Neoss Ltd
Windsor House, Cornwall Road
Harrogate HG1 2PW, UK
www.neoss.com

Exhibitor at EA0 congress 2017

Champions-Implants

From tooth to bone

The knowledge of the many advantages of autologous bone substitutes has long been established in dental medicine. With the Smart Grinder, natural dental tissue can be easily converted into a high-quality bone augmentation material. Since human tooth and bone are almost identical in their chemical and biological structure, the endogenous tooth can function as a worthy and cost-efficient augmentation material, if prepared correctly. Using the Smart Grinder is really easy: Tooth extraction and augmentation preparation can be done during one clinical session.



The extracted teeth are first mechanically cleansed with customary diamond or carbide drills that remove all filling materials. The now “clean” teeth are put into the milling chamber of the device, where they are pulverised in only a few seconds. After cleansing the particles with a sodium hydroxide solution and a phosphate buffered saline wash, the augmentation material is ready for use within 15 minutes. Thanks to its osteogenic characteristics, the augmentation material quickly differentiates into bone leading to faster healing and a predictable bone formation and bone remodelling without evoking any immunogenic reactions.

Champions-Implants GmbH
Champions Platz 1
55237 Flonheim, Germany
www.championsimplants.com

Exhibitor at the DGZI annual congress 2017



THE FUTURE OF GUIDED IMPLANTOLOGY

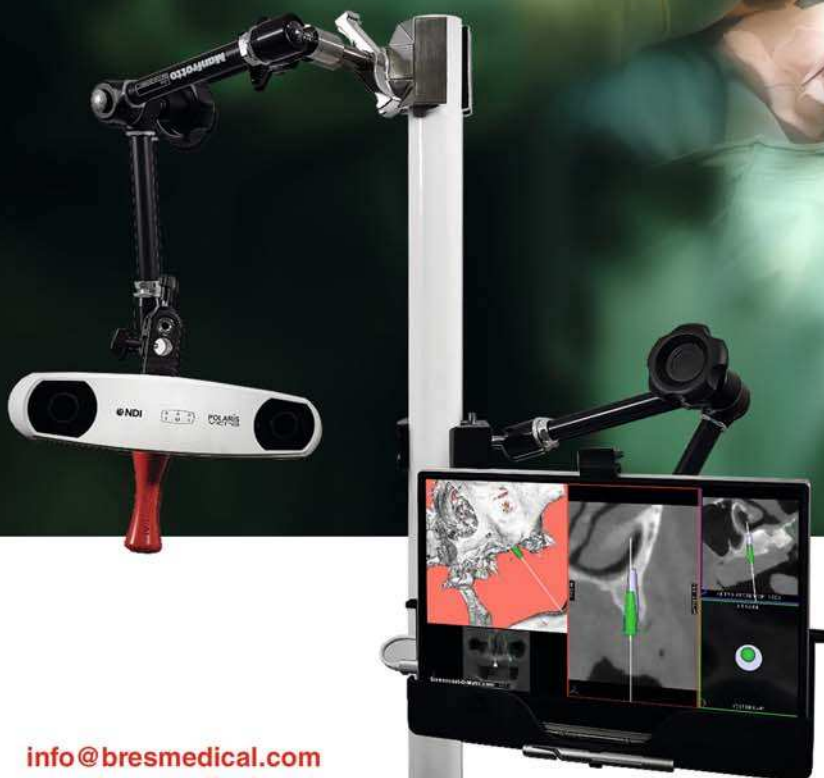Based on optical live tracking technology, **ImplaNav** has been designed to maximise accuracy in dental implantology and minimise invasiveness in advanced oral and maxillofacial surgery.

Features

- Miniaturised reference tools
- Optimised for edentulous patients
- Designed to be used with *Piezosurgery*[®]
- Compatible with any surgical handpiece/implant system

Clinical applications

- Flapless implant surgery
- Angulated implant socketing
- Zygomatic Implants
- Post-extractive implant surgery



info@bresmedical.com
www.bresmedical.com



Validated through Clinical Trials and numerous scientific publications.
Developed in Australia by BresMedical in collaboration with University of Bologna (Italy).

Dentaurum Implants

Complete CAD/CAM workflow

tioLogic® digital. provides dental technicians access to the entire CAD/CAM workflow and offers clever solutions for implants. The product range comprises all data sets and original materials for the fabrication of customised one-piece abutments, hybrid abutments as well as bar and bridge restorations using CAD/CAM technology. There are only two types of scanbodies and these cover all indications and enable a production workflow that is simplified, reproducible and precise. Each position is exactly reproduced in the CAM software, be it directly from the implant interface in case of customised one-piece abut-

ments and hybrid abutments, or from the meso-structure in case of bar and bridge restorations. Even angled abutments (AngleFix) are exactly reproduced digitally like the other abutments. Dentaurum Implants' service point for tioLogic® CAD/CAM can be reached at www.dentaurum-implants.com/tiologic-digital. Data sets for 3Shape, Dental Wings and exocad can be downloaded at the service point and integrated into the software.

Dentaurum Implants GmbH
Turnstraße 31
75228 Ispringen, Germany
www.dentaurum-implants.com
Exhibitor at the DGZI annual congress 2017



BresMedical

Minimally-invasive image-guided surgery

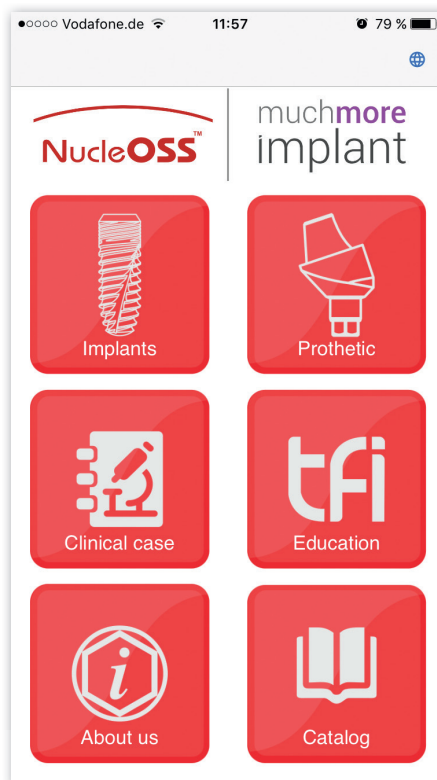
Based on optical live tracking technology, ImplaNav™ from BresMedical has been designed for use in minimally-invasive image-guided oral and maxillofacial surgery and dental implantology. Rigid micro assembly serves with live tracking support of the patient's anatomy using radiopaque markers for image-to-world registration. The lightweight reference tools guarantee rigidity and consistency through the tracking procedure. 3-D model and tomographic sections automatically show the live position of the surgical drill superimposed to the patient's anatomy. ImplaNav™ provides an environment for implant surgery planning and serves as dual solution for improving the accuracy and safety of surgical procedures in combination with automatic drill guide generation and live tracking of surgical instruments.



ImplaNav

BresMedical's strong collaboration with European oral and maxillofacial surgeons and the ability to provide solutions through precision and additive manufacturing technology has been the key to the development and launch of ImplaNav™. Visit us at the EAO congress—Booth B25—, the ImplaNav™ system and a large variety of clinical cases.

BresMedical Pty Ltd
45 Lancaster Street
NSW 2565 Ingleburn, Australia
www.bresmedical.com
Exhibitor at EAO congress 2017



NucleOSS

Mobile access to entire product spectrum

The implant manufacturer NucleOSS developed recently an App allowing practitioners and specialists a simple and mobile access to the company's wide range of products. The App is created in the special NucleOSS design and comprises the entire spectrum of the T implants series. Fact sheets provide users with in-depth information regarding the individual characteristics of each product. Furthermore, by tapping and sweeping, users are able to rotate the implants and choose between different sizes and abutment forms. The App also features company-related videos and presentations. Surgical operations and case reports including indications for prosthodontic treatment possibilities effectively facilitate the practitioner in choosing the right implant. Via the App, an online catalogue as well as a handbook and various certificates can be downloaded. Available in different languages, the App can be utilised by users worldwide to get in touch with respective distributors and receive individual and personal advice and information. The NucleOSS App is available for IOS, android and windows.

NucleOSS Europe GmbH
Graben 17
64646 Heppenheim, Germany
www.nucleoss.com
Exhibitor at the DGZI annual congress 2017 and EAO congress 2017

New Start Kit



22 implants
with superstructures and tools

1490€

The European Association for Osseointegration
Yearly scientific congress
October 5-7, Madrid, Spain

Stand S10

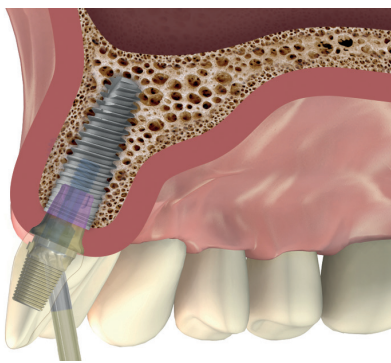


TRATE

trate.com

MIS

Abutment for screw-retained solutions



MIS has announced the release of a new Ti-Base abutment which offers a solution for anterior, screw-retained restorations. Restoration placement has never been simpler than with the EZ-Base system. The new abutment is designed for extreme angulation and offers safe handling within its screw channel. More angle options mean more comfort for the clinician performing anterior and posterior restorations with convenient handling and placement.

The EZ-Base screwdriver features a unique tip, which allows safe and reliable access from multiple angles, as well as gripping, tightening and loosening within the angulated screw-channel at a torque and with the convenience that are similar to a straight screw-channel. This system opens up an entire range of options for prosthetic restorations in the aesthetic zone. Where as in the past screw-retained restorations may not have been an option for many anterior zone cases, the EZ-Base system provides a solution.

The EZ-Base system is available for narrow, standard and wide platforms, in both conical and internal hex connections. It may be used in a digitally planned procedure, incorporating CAD/CAM technologies or using traditional methods. EZ-Base is also offered in both fixed gingival height and adjustable options for optimal customisation and convenience.

MIS Implants Technologies GmbH

Simeonscarré 2

32423 Minden, Germany

www.mis-implant.com

Exhibitor at the DGZI annual congress 2017 and EA0 congress 2017

bredent medical

Easy cleaning of bonded crowns and abutments

One of the main causes of peri-implantitis are residues of cement or adhesives on the surfaces of abutments. With the FGP insulation by the prosthetic specialist bredent medical, bonded crowns and abutments can now be cleaned with ease. The FGP insulation, an air-drying insulation varnish, prevents adhesive residues and excess primer from accumulating on the surface. The FGP insulation varnish must therefore be applied at the start of the adhesive process in order to insulate the surfaces. The green colour of the protective varnish guarantees a maximum level of control and accuracy, as it enables all contaminations to be easily recognised and removed.

In order to be able to keep up-to-date with the stringent hygiene requirements and avoid inflammations, the adhered abutment must be sterilised before it is inserted in the mouth. This can be carried out by using DTK adhesive, a light-curing



and self-curing composite adhesive produced by bredent medical that can be sterilised in autoclaves at a temperature of 134°C. The dual-curing DTK adhesive makes it easy to create a durable and secure bond and is available in both opaque and transparent variants, in order to guarantee optimal aesthetic results. *In vitro* tests have shown that sterilisation also increases the adhesion strength.

bredent medical GmbH & Co. KG

Weißenhörner Straße 2

89250 Senden, Germany

www.bredent-medical.com

Exhibitor at EA0 congress 2017

Integration Diagnostics Sweden

Customer-oriented product design and a strong market impact

Integration Diagnostics Sweden is rapidly growing by adding distributors to its global network, with a close cooperation with most major implant companies and constantly adding more implant systems to its MultiTipeg assortment.

PenguinRFA is now available in 37 countries through 24 distribution partners from which five industrial partners and covering more than 50 implant systems.

MultiTiegs are made from durable, tissue-friendly titanium and have sealed magnets, which makes it possible to autoclave them at least 20 times. They are also laser marked with type number to avoid mix-ups or using the wrong MultiTipeg. The PenguinRFA concept is affordable, uncomplicated and with reusable MultiTiegs—just what clinicians are asking for. The instrument is handheld and very user-friendly, which makes the

learning curve very short, fulfilling the customers' demands. Strong business partners add to the market success.

In addition the RFA technique has become even more accurate by creating an ISQ standard calibration system, which means minimised variance between different MultiTiegs. Due to the reference system, physical misfit between components can be detected and eliminated.

In the future, Integration Diagnostics Sweden will continue to build its distributor network globally and intensify the research around implant diagnostics.



Integration Diagnostics Sweden AB

Nedergårdsgatan 5

416 54 Göteborg, Sweden

www.penguinrfa.com

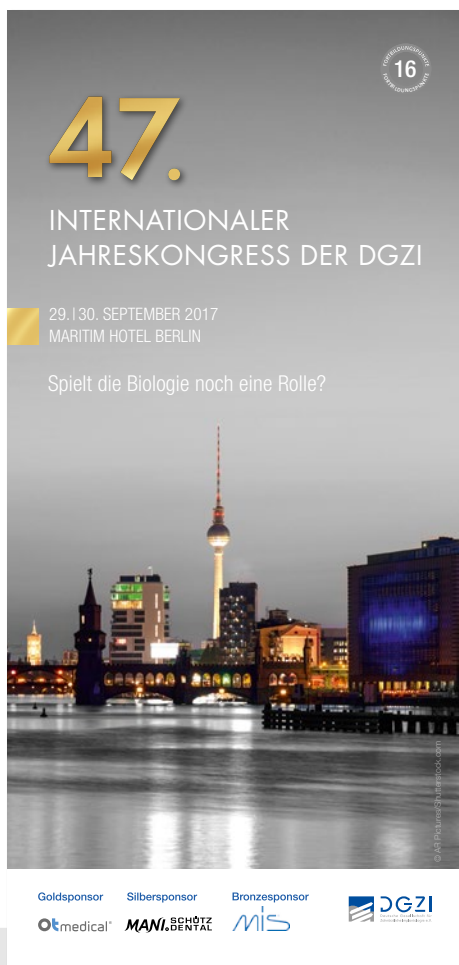47TH DGZI INTERNATIONAL ANNUAL CONGRESS

29/30 September 2017
Berlin – Maritim Hotel Berlin

ONLINE CONGRESS
PROGRAMME



www.dgzi-jahreskongress.de



Theme:
Does biology still play a role?

**Organiser/
Scientific chair:**

**Deutsche Gesellschaft für Zahnärztliche
Implantologie e.V. (DGZI)**
Paulusstraße 1 | 40237 Düsseldorf | Germany
Phone: +49 211 16970-77 | Fax: +49 211 16970-66
office@dgzi-info.de | www.dgzi.de

Organisation:

OEMUS MEDIA AG
Holbeinstraße 29 | 04229 Leipzig | Germany
Phone: +49 341 48474-308 | Fax: +49 341 48474-290
www.oemus.com | event@oemus-media.de

Sponsors:

Gold Sponsor Silber Sponsor Bronze Sponsor
Otmedical® MANI SCHÜTZ DENTAL MIS

Fax Reply **+49 341 48474-290**

I would like to receive further information on the
47TH DGZI INTERNATIONAL ANNUAL CONGRESS.

Title, Surname, Name

E-mail address (for digital programme)

Stamp

implants 3/17



Fig. 1

Arabian **flair** and **French** charm

Author: Dr Rolf Vollmer, Germany

Author details



On 12 and 13 May 2017, the 10th Arab German Congress of Dental Implantology took place in Morocco while, simultaneously, the 1st German Maghreb Countries Meeting of Dental Implantology was inaugurated. The foundation for the congress had been laid in the previous year with an agreement between DGZI and Universiapolis, Université Internationale d'Agadir. Dr Ali Elmalih, DGZI representative for the Maghreb states, organised the event in cooperation with the private University in Agadir.

Almost 150 participants and speakers from countries such as Germany, Morocco, Jordan, Qatar, Libya, Sudan and Ireland, travelled to Agadir to attend the event. The programme of the two-day congress was designed by 18 German speakers from the Maghreb countries. At the opening ceremony, congress president Dr Mazen Tamimi and scientific manager

Dr Rolf Vollmer, 1st Vice President and Treasurer of the DGZI, both emphasised the importance of international contacts and exchange. Special thanks went to Dr Aziz Bouslikhane, President of the university, and Dr Ilias Majdouline, Vice President, for enabling the event to take place at the university.

Dr Vollmer went on to explain the global importance of dental implantology, pointing out that all participants could benefit, particularly from the exchange of experiences. Furthermore, he referred to the importance of international friendships which evolve from congresses like these and help to strengthen the global community. International cooperation partners from countries such as the United States of America, Japan, the Middle East, Brazil, Australia and Africa, confirmed Dr Vollmer's statement. Another important point made by Dr Vollmer referred to the DGZI Postgraduate Programmes and the importance to open up participation in order for other countries to equally profit from the shared expertise. Those programmes have been proven successful for more than 15 years and are an essential part of dental education in Germany. While sitting in the auditorium next to someone who is pursuing his profession somewhere else in the world under different conditions, and utilising different methods, provides a unique

Become a member of the DGZI!

Become a member of the German Association of Dental Implantology (DGZI) under www.dgzi.de/ueber-uns/mitgliedschaft or scan the adjacent QR code.

Application form





Fig. 2



Fig. 3



Fig. 4

opportunity to widen one's own knowledge and gain another perspective on this specialist field, Dr Vollmer said.

The scientific programme was complemented by two workshops held by Dr Mazen Tamimi as well as Dr Arzu Tuna and Dr Umut Baysal. Dr Tamimi provided his workshop for implantswiss®, while Dr Tuna and Dr Baysal were sponsored by MIS Implants®. Fully booked with more than 45 participants, those practical sections of the congress were met with great interest. Dr Tuna and Dr Baysal addressed a variety of interesting questions in detail and provided a great deal of practical advice to the highly engaged workshop participants.

The lectures, however, dealt with more general medical aspects such as patient guidance, risk of bleeding, diabetes and implant surgical techniques, e.g. sinus lift, treatment in the atrophic jaw as well as aesthetic and minimally-invasive treatments.

In addition, keynote speaker Michael Anger introduced on day two of the congress the use of new and innovative materials in dental technology, hence covering the technical field of dental prosthetic. Keynote speaker of the first day was oral surgeon Dr Dr Manfred Nilius, M.Sc. who skilfully illustrated digitalisation in dental implantology and cosmetic surgery. Concluding his presentation, Dr Dr Nilius pointed out that "without a perfect coordination between the different specialties and fields of expertise, an excellent result can never be achieved". Dr Vollmer agreed with the statement, poignantly adding: "You always get what you plan."

Also from Germany, members of the New Generation study group, amongst them Dr Navid Salehi, Dr Rabi Omari, Dr Christopher Stüber, Dr Rainer Valentin and Dr Martina Vollmer, had been travelling to Agadir to participate in the event. The first successful day ended with a get-together and a speakers' dinner.

After the scientific programme came to a close on the second congress day, participants were invited to a gala evening at Domaine Villate Limoune. The beautiful farm offered a festive setting for the evening's gala dinner and the presentation of certificates. At the evening event, Dr Rolf Vollmer once again thanked the President and the Vice President of Universiapolis for the excellent organisation provided by all involved. Thanks also went to DGZI representative Dr Ali Elmalih, who had once himself successfully participated at one of the DGZI post-graduate programmes.

A second German Maghreb Countries Meeting of Dental Implantology is intended to be held on 30 and 31 March 2018.

Fig. 1: Participants of the 10th Arab German Congress of Dental Implantology.

Fig. 2: DGZI board Dr Rainer Valentin and Dr Rolf Vollmer.

Fig. 3: Dr Umut Baysal and...

Fig. 4: ...Dr Arzu Tuna, both members of the extended DGZI board and DGZI New Generation study group.

contact

DGZI Central Office

Paulusstraße 1
40237 Düsseldorf, Germany
Tel.: +49 211 16970-77
sekretariat@dgzi-info.de
www.dgzi.de

About the society



Fig. 5: Dr Navid Salehi (right) and dental technician Michael Anger (second from right) were also speakers in Agadir.



Fig. 5

Joint meeting of the EAO and SEPES

From 5 to 7 October 2017 the European Association for Osseointegration (EAO) will be hosting its 26th annual scientific meeting. This year, participants are invited to Madrid, Spain, where, in addition, the Spanish Society of Prosthodontic and Aesthetic Dentistry (SEPES) will meet for its 47th Congreso Annual. In a joint congress, both EAO and SEPES will bring together an international and highly specialised audience for three days of extraordinary scientific and collegial exchange.

Furthermore, the EAO and the Spanish Society of Periodontology and Osseointegration (SEPA) have joined forces to organise the fifth SEPA European

Symposium under the aegis of the EAO-SEPES joint meeting. The SEPA Symposium will take place on Saturday, 7 October, and will run dedicated sessions throughout the day.

For the three-day congress the scientific committees of the EAO, SEPES and SEPA have prepared an exciting programme covering several topics which will focus on the question: "Twenty-five years of Implant Dentistry. What have we learned?" The congress programme will feature world-renowned speakers, interactive elements which will engage the audience, and new and innovative formats such as surgical video sessions.

© S-F/Shutterstock.com





Exciting programme

On Thursday, the congress will open with a plenary session giving an overview on protocols of implant placement procedures from standard to advanced. In the subsequent diagnosis session, aesthetic diagnosis as a keystone of treatment planning in implant dentistry will be discussed. The plenary main sessions during the following two days including a series of interactive debates will further focus on the evolution of implant prosthodontics, diagnosis and treatment planning in implant dentistry in light of the prevalence of peri-implant diseases.

In the arena sessions, key topics will be explored in which 25 years of implantology are analysed to answer the question "How far have we come?". Amongst others, the evolution of bone regenerative protocols in implant dentistry will be illustrated, insights into surgical approaches to the treatment of peri-implantitis will be given and alternatives to titanium as an implant material and custom-made implants will be discussed. Further questions posed will concern the limitations of immediate implant placement and immediate restoration and the treatment of patients with hopeless implants.

A highlight of this year's congress will be the interactive surgical video sessions featuring in-depth discussions of videos showing surgical cases. In these video sessions, participants can experience the treatment of the anterior maxilla with deficient availability of bone, the treatment of peri-implant soft tissue deficiencies in the anterior maxilla and learn about biological and clinical keys for periodontal, bone and peri-implant regeneration.

Exchange new research results

In addition to the lectures, researchers and clinicians are encouraged to present, discuss and exchange new research results within the field of implant therapy and related disciplines via submission of scientific abstracts. During the numerous oral communication sessions starting on Thursday, delegates can attend short oral presentations held by authors whose abstracts were rated highest by the Abstract Committee.

Prosthodontics and aesthetic international journey sessions will focus amongst others on the role

of provisional restorations in aesthetic implant-supported prosthetic rehabilitations and the combination of dental implants and orthodontic therapy in the functional rehabilitation of partially edentulous patients. Another session will discuss the question of how to avoid nightmares when restoring the edentulous upper jaw. Further sessions for clinicians and technicians will focus on materials of choice for anterior restorations and the widely discussed question of analogue vs digital.

The scientific programme is rounded off by hands-on sessions organised by industry partners promoting new techniques and offering high-level practical training under the guidance of renowned experts. In these industry symposia, visitors can learn more about key subjects of various industry partners featuring new research and innovation.

Invited region is Latin America

Since its inception in the late 1980s, the EAO has been a forum for European researchers and clinicians. In recent years, increasing numbers of members from non-European countries have joined—from South/Central America, the Middle East, Eastern Europe, and Asia. As a mark of recognition and appreciation of this development, and because both SEPES and SEPA have members from this region, the EAO has chosen to welcome Latin America as a guest region during the joint meeting. Delegates from Latin America are be offered registration fees at discounted rates which are normally reserved for members only.

In addition, a section of the exhibition area will be dedicated to a "Latin American Corner" where regional associations can showcase their activities. Cultural events will also be organised to encourage exchange and networking between delegates from different countries.

contact

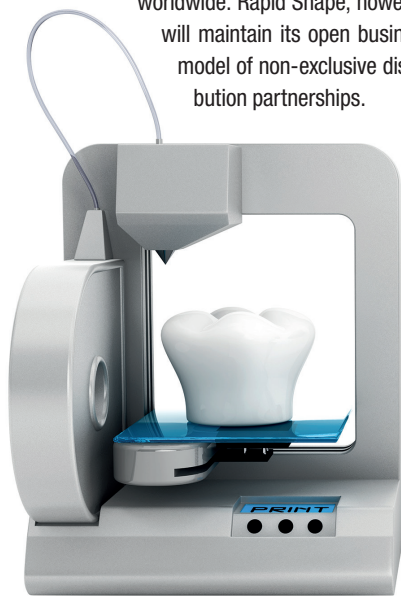
EAO Office

38 rue Croix des Petits Champs
75001 Paris, France
Tel.: +33 1 42366220
info@eao.org
www.eao.org

Straumann and Rapid Shape to Drive 3-D printing technology

In June, Straumann and Rapid Shape announced that they have expanded their partnership with the goal of accelerating the uptake of 3-D printing technology in dentistry. Straumann has purchased a 35 per cent non-controlling stake in the Germany-based company for an undisclosed sum, enabling Rapid Shape to invest further in development and production, as well as increasing its service footprint.

The acquisition follows a non-exclusive distribution agreement signed in March, allowing Straumann to supply Rapid Shape 3-D printers worldwide. Rapid Shape, however, will maintain its open business model of non-exclusive distribution partnerships.



© doomu/Shutterstock.com

Rapid Shape's 3-D printers are designed to enable dental laboratories to produce temporary prosthetic restorations, models and drill templates for guided surgery with certified precision very efficiently.

An open-system approach allows customers to choose from a wide variety of certified materials from multiple suppliers. Straumann will sell the printers under its own brand, offering seamless connectivity with its validated digital workflow for tooth replacement.

According to industry intelligence, the installed base and output of dental 3-D printers are expected to triple over the next five years, Straumann announced.



Alpha-Bio Tec launches its Scientific Research Collaboration Programme

At this year's EAO congress in Madrid, Spain, Alpha-Bio Tec will be launching its Scientific Research Collaboration Programme for the sponsorship of clinical and preclinical studies in dental implantology, tissue regeneration and dental prosthetics. Additionally, participants will be able to experience live Alpha-Bio Tec's new NeO implant and CAD/CAM guided surgery tool kit. Alpha-Bio Tec will also take part in the EAO research poster exhibition, offering a unique opportunity to meet Prof. Ofer Moses and Dr Zoabi Hasan, who will be presenting two studies selected by the EAO, which are an *in vitro* comparative study of bacterial growth on grooved and non-grooved healing abutments and

the effect of coronal implant design and drilling protocol on bone-to-implant contact.

At the lunch symposium, Alpha-Bio Tec will be hosting Prof. Ofer Moses and Prof. Dieter Bosshardt with their lecture "The way to Ithaka: From vision to clinical implication". The lecture will discuss the combination of vision, open minds, animal models and surgical skills in revolutionary surgical solutions exploring implant housing biology, and collaboration with histology experts to obtain high-quality results and the implications for academic and clinical use.

Source: Alpha-Bio Tec

Dr Karsten Wagner is now responsible for

The global development of Ankylos and Xive

Dr Karsten Wagner is taking over the position of Global Director Platform Implant Systems Ankylos/Xive at Dentsply Sirona Implants. This means that he will be responsible for product innovation and brand strategy for the Ankylos and Xive implant systems worldwide.

Dr Wagner, CEO of Dentsply Sirona Implants Germany, has initiated successful events for both implant systems with the Xive Roadshow and the Ankylos Congress in Germany, which also

attracted a great deal of interest internationally. Now he can bring his strategies to the global promotion of the premium dental implant brands. His excellent customer contacts and many years of experience in the dental market will be of great benefit in this role.

Dr Karsten Wagner is solidly anchored in medical technology. After working at Abbott, where he gained experience in sales, product management and later as Head of Key Account Management, he then switched to National Sales Manager of the former Astra Tech GmbH in 2004, and became Business Unit Director in 2008. With the merger of Astra Tech Dental and DENTSPLY Friadent into DENTSPLY Implants in 2013, Dr Wagner was first responsible for sales, then became CEO in Germany and took over the overall management of sales for the D-A-CH region (Germany, Austria, Switzerland). He is also retaining the function of CEO of Implants in Germany in order to oversee the planned restructuring measures in Germany.



**SUBSCRIBE
NOW!**

ONLINE
SUBSCRIPTION HERE



ceramic implants—
international magazine
of ceramic implant technology

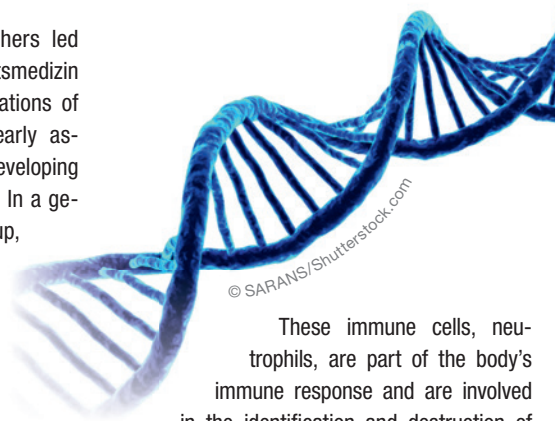
www.oemus.com/abo

Researchers identify

DNA sections responsible for periodontitis

An international network of researchers led by scientists at the Charité – Universitätsmedizin Berlin in Germany has identified variations of certain DNA sequences that are clearly associated with an increased risk of developing different forms of periodontal disease. In a genome-wide association study, the group, led by Prof. Arne Schäfer from the Charité Institute for Dental and Craniofacial Sciences, investigated the relationship between sequence differences in genetic information and the incidence of the disease in several thousand patients with aggressive and chronic periodontitis. The results were compared with healthy individuals.

The scientists found two gene regions that appeared to be associated with an increased risk of developing different forms of periodontitis. One of the two regions is responsible for the synthesis of alpha-defensins (antimicrobial peptides), which are produced by specialised immune cells.



© SARANS/Shutterstock.com

These immune cells, neutrophils, are part of the body's immune response and are involved in the identification and destruction of microorganisms. The second gene region inhibits the activation of these immune cells.

“Our results show that the different forms of gum disease share a common genetic origin,” said Schäfer. He emphasised: “This means that there are groups of patients who are susceptible to developing gum disease, but whose susceptibility is independent of other risk factors, such as smoking, oral hygiene or aging.”

Researcher aims to

Regrow teeth with biocompatible material

The ability to grow new teeth has long been a pipe dream in dentistry. Recent breakthroughs, however, have shown that it is possible to promote regeneration of dental tissue with the aim of reducing the use of filling material and helping teeth to self-repair. Dr Azam Ali from the University of Otago in New Zealand has now launched a research project that seeks to develop a biomaterials system that would allow regrowth of entire teeth.

Ali's “No drill, no fill” project was initially intended to create a suitable biocompatible alternative to traditional filling materials used to treat dental caries. The study's parameters soon expanded to producing new dental tissue as the potential of the materials to be used became apparent during preliminary testing.

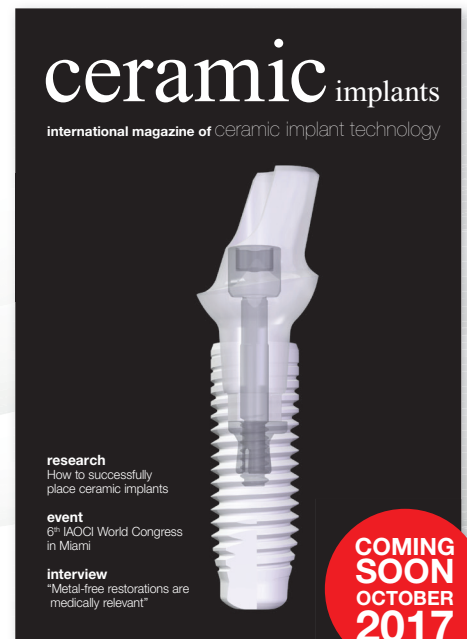In recognition of their innovation, Ali and his team have been awarded an explorer grant of A\$150,000 (US\$113,171) from the Health Research Council of New Zealand. This grant

is intended to provide financial support for the study for up to 24 months.

“Developing a technique to regrow teeth, for example, is an extraordinary concept and offers huge potential for people suffering dental health problems,” said Health Minister Dr Jonathan Coleman upon awarding the grant to Ali.



© naujicreative/Shutterstock.com



implants 3/17

Fax **+49 341 48474-290**

I would like to subscribe for the following journals:

ceramic implants — international magazine of oral implantology
2 issues € 30 p.a. *

implants — international magazine of oral implantology
4 issues € 44 p.a. *

Terms & Conditions: The subscription may be cancelled in written form without due justification within 14 days of order by contacting OEMUS MEDIA AG, Holbeinstraße 29, 04229 Leipzig, Germany. Dispatching notification in good time will suffice. The subscription is automatically extended by another twelve months if it is not cancelled in written form 6 weeks prior to the end of the reference period.

* All prices include VAT and shipping (within Germany).
Conditions for international subscriptions upon request.

Last Name, First Name

Company

Street

ZIP/City/Country

E-Mail

Signature

PayPal

Credit Card

Credit Card Number

Expiration Date

Security Code

Holbeinstraße 29 · 04229 Leipzig · Germany
Phone: +49 341 48474-201 · grasse@oemus-media.de

OEMUS MEDIA AG

Congresses, courses and symposia



47th International Annual DGZI Congress

29–30 September 2017
Venue: Berlin, Germany
www.dgzi-jahreskongress.de



26th EAO Annual Scientific Meeting

5–7 October 2017
Venue: Madrid, Spain
www.eao-sepes2017.com



66th Annual AAID Conference

11–14 October 2017
Venue: San Diego, USA
www.aaid.com



Nobel Biocare Symposium

10–11 November 2017
Venue: London, United Kingdom
www.nobelbiocare.com



IMPLANT EXPO®

1–2 December 2017
Venue: Düsseldorf, Germany
www.implantexpo.com

implants

international magazine of oral implantology



Imprint

Publisher

Torsten R. Oemus
oemus@oemus-media.de

CEO

Ingolf Döbbecke
doebbecke@oemus-media.de

Members of the Board

Jürgen Isbaner
isbaner@oemus-media.de

Lutz V. Hiller

hiller@oemus-media.de

Chief Editorial Manager

Dr Torsten Hartmann (V. i. S. d. P.)
hartmann@dentalnet.de

Editorial Council

Dr Rolf Vollmer
info.vollmer@t-online.de

Dr Georg Bach

doc.bach@t-online.de

Prof. (CAI) Dr Roland Hille

dr-hille@t-online.de

Dr Suheil Boutros

SMBoutros@aol.com

Editorial Office

Georg Isbaner
g.isbaner@oemus-media.de

Katrin Maiterth

k.maiterth@oemus-media.de

Executive Producer

Gernot Meyer

meyer@oemus-media.de

Product Manager

Timo Krause

t.krause@oemus-media.de

Designer

Sandra Ehnert
s.ehnert@oemus-media.de

Theresa Weise

t.weise@oemus-media.de

Customer Service

Marius Mezger
m.mezger@oemus-media.de

Published by

OEMUS MEDIA AG
Holbeinstraße 29
04229 Leipzig, Germany
Tel.: +49 341 48474-0
Fax: +49 341 48474-290
kontakt@oemus-media.de

Printed by

Silber Druck oHG
Am Waldstrauch 1
34266 Niestetal, Germany

implants

international magazine of oral implantology is published in cooperation with the German Association of Dental Implantology (DGZI).

DGZI

DGZI Central Office
Paulusstraße 1
40237 Düsseldorf, Germany
Tel.: +49 211 16970-77
Fax: +49 211 16970-66
office@dgzi-info.de

www.dgzi.de

www.oemus.com

www.implants.de

Copyright Regulations

implants international magazine of oral implantology is published by OEMUS MEDIA AG and will appear in 2017 with one issue every quarter. The magazine and all articles and illustrations therein are protected by copyright. Any utilization without the prior consent of editor and publisher is inadmissible and liable to prosecution. This applies in particular to duplicate copies, translations, microfilms, and storage and processing in electronic systems. Reproductions, including extracts, may only be made with the permission of the publisher. Given no statement to the contrary, any submissions to the editorial department are understood to be in agreement with a full or partial publishing of said submission. The editorial department reserves the right to check all submitted articles for formal errors and factual authority, and to make amendments if necessary. No responsibility shall be taken for unsolicited books and manuscripts. Articles bearing symbols other than that of the editorial department, or which are distinguished by the name of the author, represent the opinion of the afore-mentioned, and do not have to comply with the views of OEMUS MEDIA AG. Responsibility for such articles shall be borne by the author. Responsibility for advertisements and other specially labeled items shall not be borne by the editorial department. Likewise, no responsibility shall be assumed for information published about associations, companies and commercial markets. All cases of consequential liability arising from inaccurate or faulty representation are excluded. General terms and conditions apply, legal venue is Leipzig, Germany.

Straumann® BLT Ø 2.9 mm – the SmallOne
Another legend is born:
Small, strong and enduring.



LESS INVASIVE*

A perfect combination of shape, strength and healing power.



NATURAL LOOKING ESTHETICS

Novel prosthetic design that closely matches the anatomy of teeth.



FULL STRENGTH

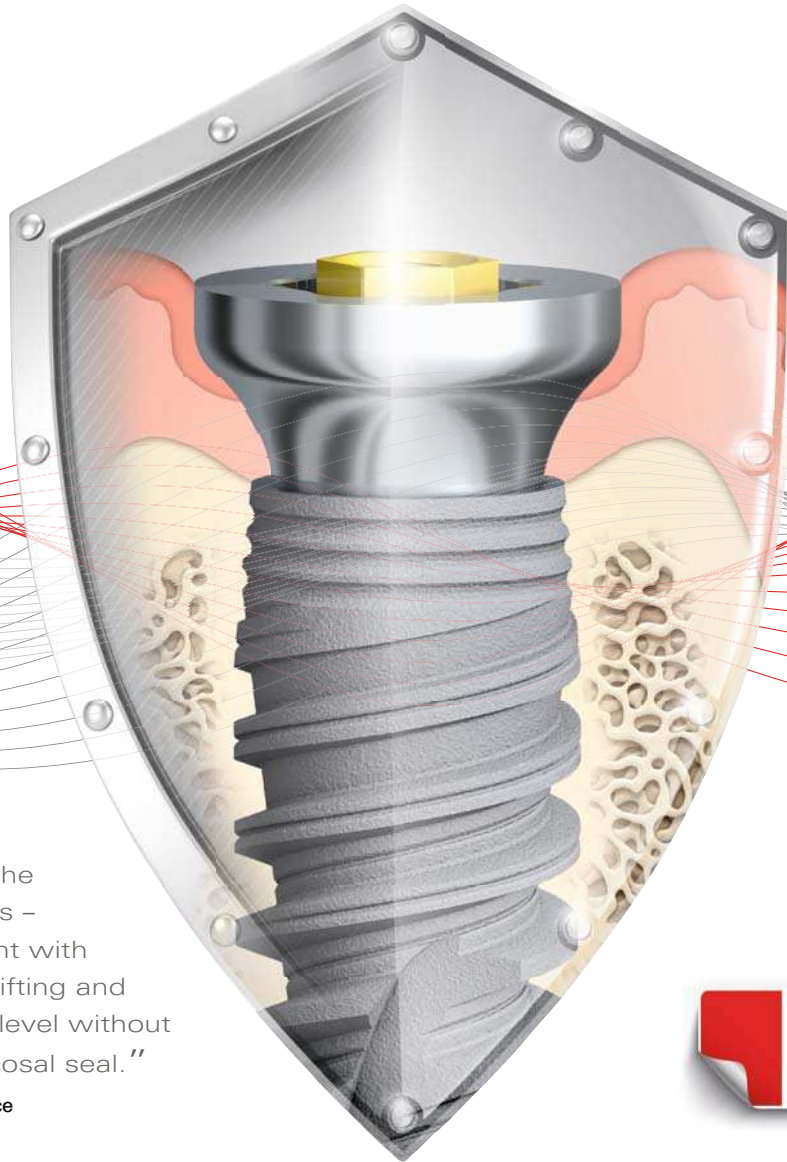
A strong and reliable treatment option thanks to Roxolid®.



Contact your local Straumann® representative today to find out more about the SmallOne. Or visit smallone.straumann.com.

*if GBR can be avoided

A shield never to be broken



“With On1 you get the best of both worlds – a bone-level implant with built-in platform shifting and restoring at tissue level without disturbing the mucosal seal.”

Prof. Bernard Touati, France

EAO 2017

Visit us at booth D3 and
hospitality suite H2.

On1™ concept

On1 is the first solution designed to preserve the natural shield created by the soft tissue attachment while offering full surgical and restorative flexibility. The unique On1 Base moves the restorative platform to tissue level, radically simplifying all restorative procedures.

Get your free interactive e-book at nobelbiocare.com/on1-ebook

