

Ceramic implants—naturally beautiful and clinically proven

Dr Frederic Hermann, M.Sc., Switzerland

Patients are increasingly requesting ceramic implants. Reasons behind their decisions are often related to their emotions, as “white” implants mean smiles appear even more radiant and soft tissue looks even healthier. As such, this kind of implants contribute to a better quality of life and higher levels of self-confidence. However, there are also medical reasons for using metal-free implants, especially for sensitive patients. This specialist article will outline the rehabilitation of a premolar in the upper jaw area with a two-part zirconium dioxide implant produced in a ceramic injection moulding procedure with a rough dual surface texture.

Modern-day ceramic implants are made from yttrium-stabilised zirconium dioxide. Previous studies have produced predominantly positive results in terms of cell attachment, osseointegration and durability.¹⁻⁶ The development of ceramic implants that has taken place during recent years shows that they are increasingly becoming a part of the dental indication spectrum. However, two-part implants are still subject of controversial discussions. Can they really be used as an alternative to titanium implants?⁷

Patients feel that treatment has been successful if they are satisfied with their subsequent appearance, as well as with the care they received. Ivory-coloured, translucent ceramic implants have a clear advantage here, as they are the most similar to the natural tooth root.⁸ Due to

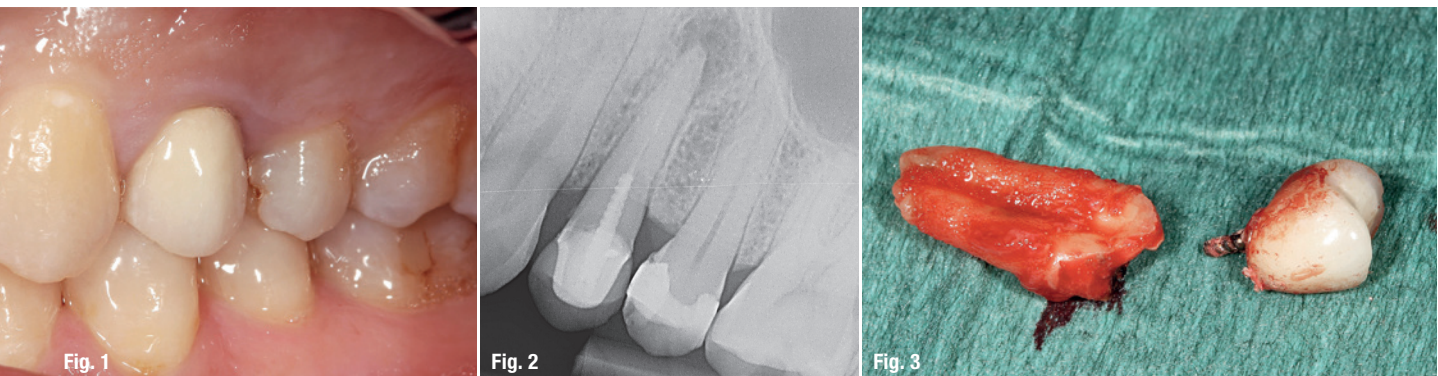
their colour and compatibility with soft tissue, these implants act as an aesthetic buffer, especially in clinically compromising situations, such as if patients have a thin gingiva biotype, or high smile line.

Zirconium dioxide implants osseointegrate like a titanium implant and encourage soft tissue to adapt well. This means that it is possible to achieve natural gingiva and dental aesthetics.^{2,9-11} Product quality and safety is substantiated by the manufacturer’s statement that each individual implant is subjected to extensive load tests and dimensional inspections before being packaged.

Medical history and planning

At the end of 2015, a 38-year-old patient was experiencing discomfort during biting and had recurrent fistulas in the left part of the upper jaw. She was a non-smoker with adequate oral hygiene and good compliance. An X-ray image evidenced that her teeth were in need of restoration and findings were endodontical and conservative.

She was diagnosed with apical periodontitis stemming from root-treated tooth 24, which also evidences a vertical fracture (Figs. 1 & 2). Due to the existing diagnosis, endodontic revision did not seem promising. There were not any particular findings from the functional check-up. According to the criteria specified in the SAC classifica-



Figs. 1 & 2: Apical periodontitis stemming from root-treated tooth 24, which also evidences a vertical fracture. **Fig. 3:** Minimally invasive procedure for removing tooth 24 whilst preserving buccal bone lamella.

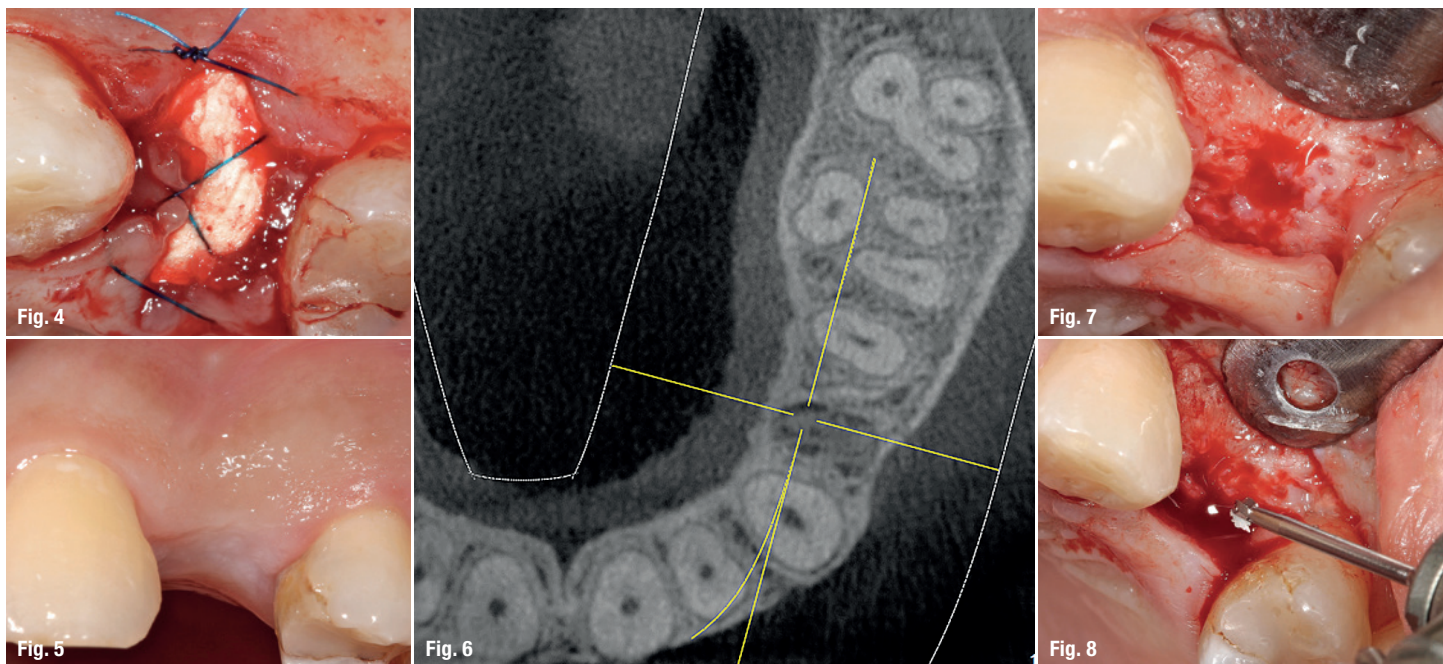


Fig. 4: The alveolus was cleaned and filled in with an alveolar cone made from collagen. **Fig. 5:** After four months of integration. **Fig. 6:** DVT image for planning purposes. **Fig. 7:** Minimally invasive flap formation. **Fig. 8:** Marking the position of the implant.

tion, a method which was first outlined by Sailer and Parolaro in 1996 as a means to categorise the complexity involved in implant surgery, the risk profile was low in terms of surgical, aesthetic and restorative evaluations.¹¹

The patient was made aware of a gentle tooth extraction procedure. She was extremely opposed to having a conventional bridge restoration and expressed that she would like a metal-free, fixed implant. She was made aware of the small amount of evidence-based documentation concerning ceramic implants, in comparison to the documentation available concerning titanium implants, and she was also informed about the advantages and disadvantages of two-part ceramic implants. The patient opted for the two-part implant as she did not want to wear the protective shield necessary to ensure that a one-part ceramic implant becomes integrated due to aesthetic reasons.

Pre-implant procedures

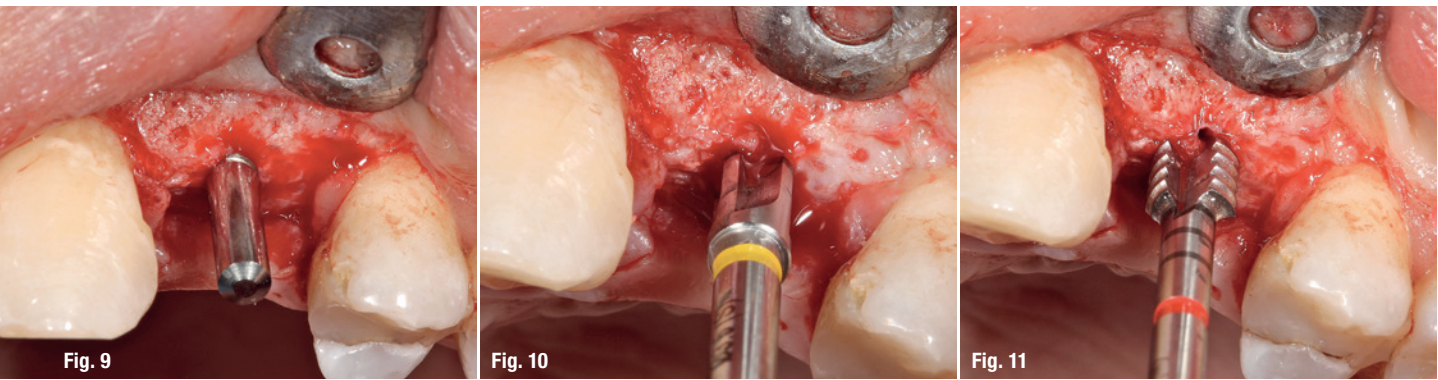
The first step was to extract tooth 24 with a minimally invasive and particularly gentle procedure (Fig. 3). It is imperative that the alveolar bone structure is preserved so that there is minimal resorption of hard- and soft-tissue postsurgery. By using periostomes, it means that desmodontal fibres rupture during this method of extraction and teeth, or more specifically the remains of the root, can be carefully removed whilst keeping the expansion of the alveolar bone to a minimum. Due to apical inflammation, and from an economical perspective, in order to save costs, the aim was to let the patient heal autologously, without any bone replacement material. The al-

veolus was cleaned and filled in with an alveolar cone made from collagen (PARASORB HD Cone, RESORBA Medical; Fig. 4). After approximately two weeks had passed, the extraction alveolus was closed with provisional connective tissue and the primary cancellous bone started to develop.

Inserting the implant

During the four-month recovery phase, the filling in tooth 25 was renewed, parodontal pretreatment was completed and the patient was taught about oral hygiene procedures. Before the implant was inserted, a DVT was produced in order to depict the anatomic structure of the surrounding area and to determine the exact position for the implant (Figs. 5 & 6). The bone bed is prepared for the implant (CERALOG Hexalobe, CAMLOG) to be inserted as per the surgical protocol specified.

After a minimally invasive flap formation procedure, the alveolar ridge was prepared (Fig. 7). In order to achieve a functional and aesthetic end result, the three-dimensional placement of the implant is of high importance. The implant shoulder should be two to three millimetres below the cementum-enamel junction of an adjacent tooth and displaced palatinal to a slight extent. In this way, the coronal emergence profile can be shaped in the best way to meet aesthetic criteria. According to these guidelines, the position of the implant was marked on the jawbone with a round bur (Fig. 8). The pilot hole was then drilled and the new three-dimensional position checked with paralleling pins.



Figs. 9–11: Pilot drill, paralleling pins, enlargement drilling and threading.

The pilot hole was drilled subsequent to the implant site being enlarged with a form drill (S 2.9 mm, M 3.4 mm). In order to avoid the potential increase in pressure that may arise when the implant is being inserted into the bone, we also used a thread cutter (Figs. 9–11). In order to avoid necrosis, the implant has to be inserted into the hole at a slower pace than a titanium implant, as zirconium dioxide is a poor conductor of heat. The implant used here was fixed in place in the implant site by hand, by making a few turns using an insertion device that had been taken out of sterile packaging and connected to a ratchet adapter.

Subsequently, it was manually inserted deep into the hole (Figs. 12–15). By using the hexalobe joint modified specially for use with the ceramic implant, the insertion tool was guided into the implant in an optimal fashion. The protocol specified a maximum of 15 revolutions per second and a torque of 35 Ncm. The shoulder was placed at 1.5 mm in a supracrestal position so that the prosthetic platform would be located around 0.5 mm under the soft tissue. This position corresponds to where the smooth ZrO₂ surface changes to have a coarse texture at the level of the bone. To enable open integration, the implant is sealed used a healing cap and the soft tissue is adaptively sewn using a 6-0 suture (Figs. 16–18).

Prosthetic restoration

Prosthetic restoration takes place after the four-month integration phase. The healing cap is removed with a screw driver and an impression is made with the pins for the open tray technique (Figs. 19–21). Dental technicians created a master model in a laboratory. The lab analogue (PEEK) was attached to the impression post using a screw, then the model was emptied and mounted on the articulator. The technician marked the anatomical coronal emergence profile on the plaster model and, using a bur, milled the profile up to the lab analogue (Fig. 22). Subsequently, the PEKK abutment was scanned and an occlusal screw-retained hybrid crown was designed from zirconium dioxide, which was then veneered buccally. Af-

ter checking the aesthetics, the crown was cemented to the PEKK abutment with a Multilink Hybrid Abutment (Ivoclar Vivadent; Figs. 23 & 24).

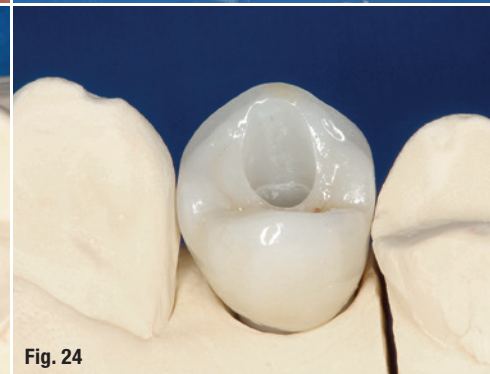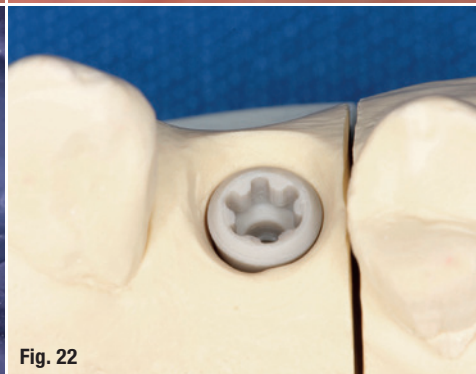
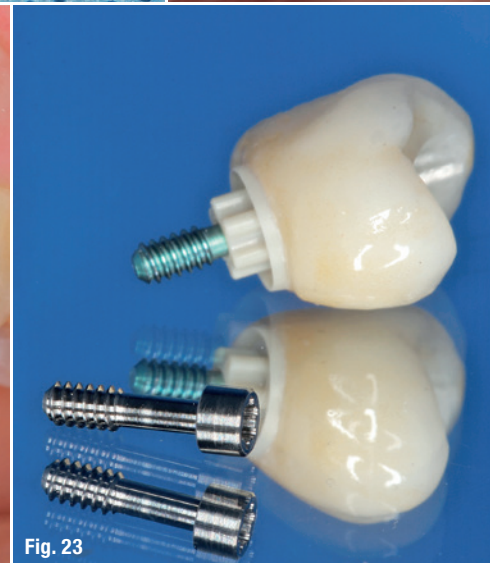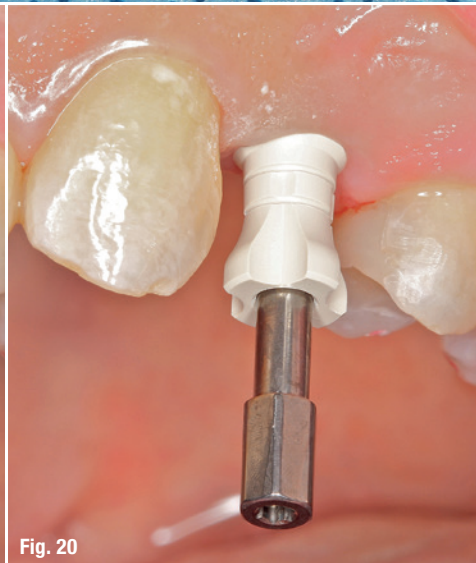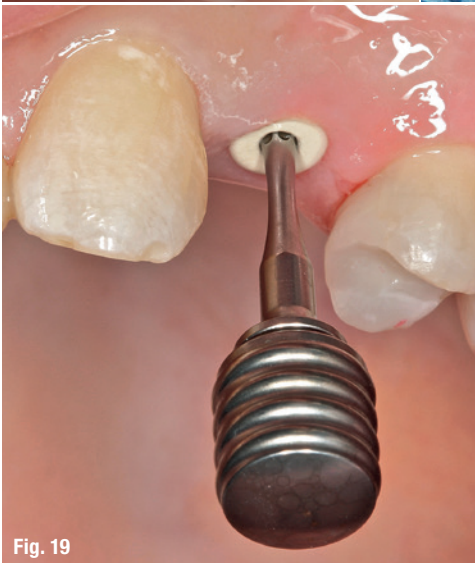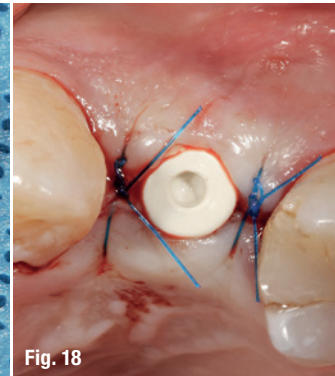
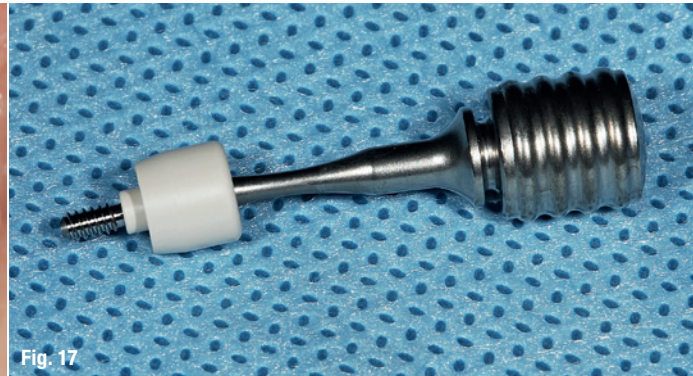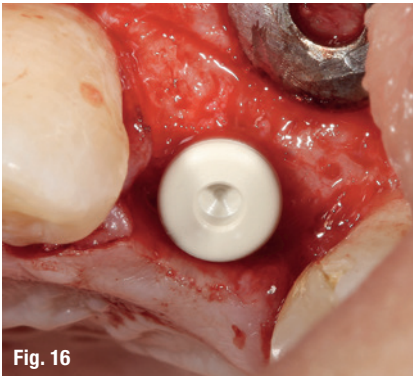
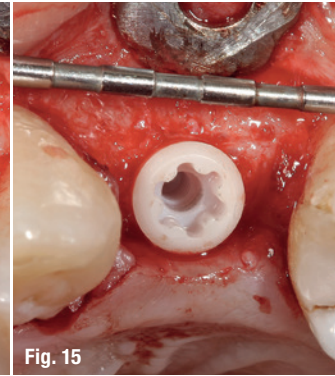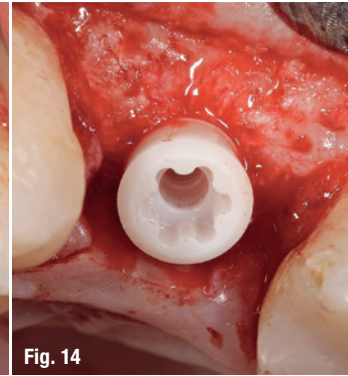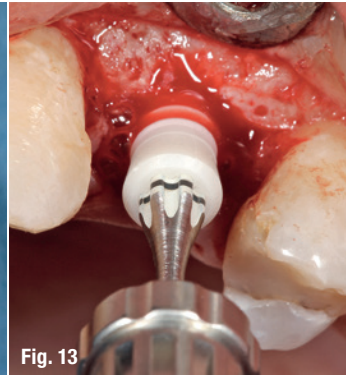
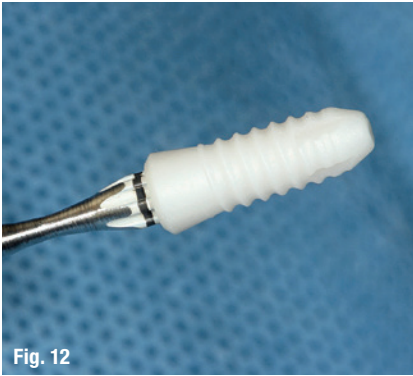Before the crown was integrated into the mouth, implant stability was checked using Osstell ISQ and an X-ray image was produced.^{10, 12, 13} When the PEEK gingiva former was removed, a peri-implant gingiva free from irritation could be seen (Figs. 25–27). The hybrid abutment crown was inserted and screwed in place using a titanium screw with 25 Ncm (Figs. 28–30). As the high-performance polymer is not X-ray opaque, an uninterrupted gap of around 1 mm can be seen at the point of the implant-abutment crossover in the X-ray image (Fig. 31).

The channel where the screw entered was sealed with Teflon tape and a light-curing composite after the functional check-up. Figure 32 shows the clinical situation one year after the prosthetic restoration took place. The crown blends in with the row of teeth perfectly. The papillae are solid and pointed, closing the interdental spaces. The patient was happy about the successful and “invisible” treatment she received with implant prosthetics.

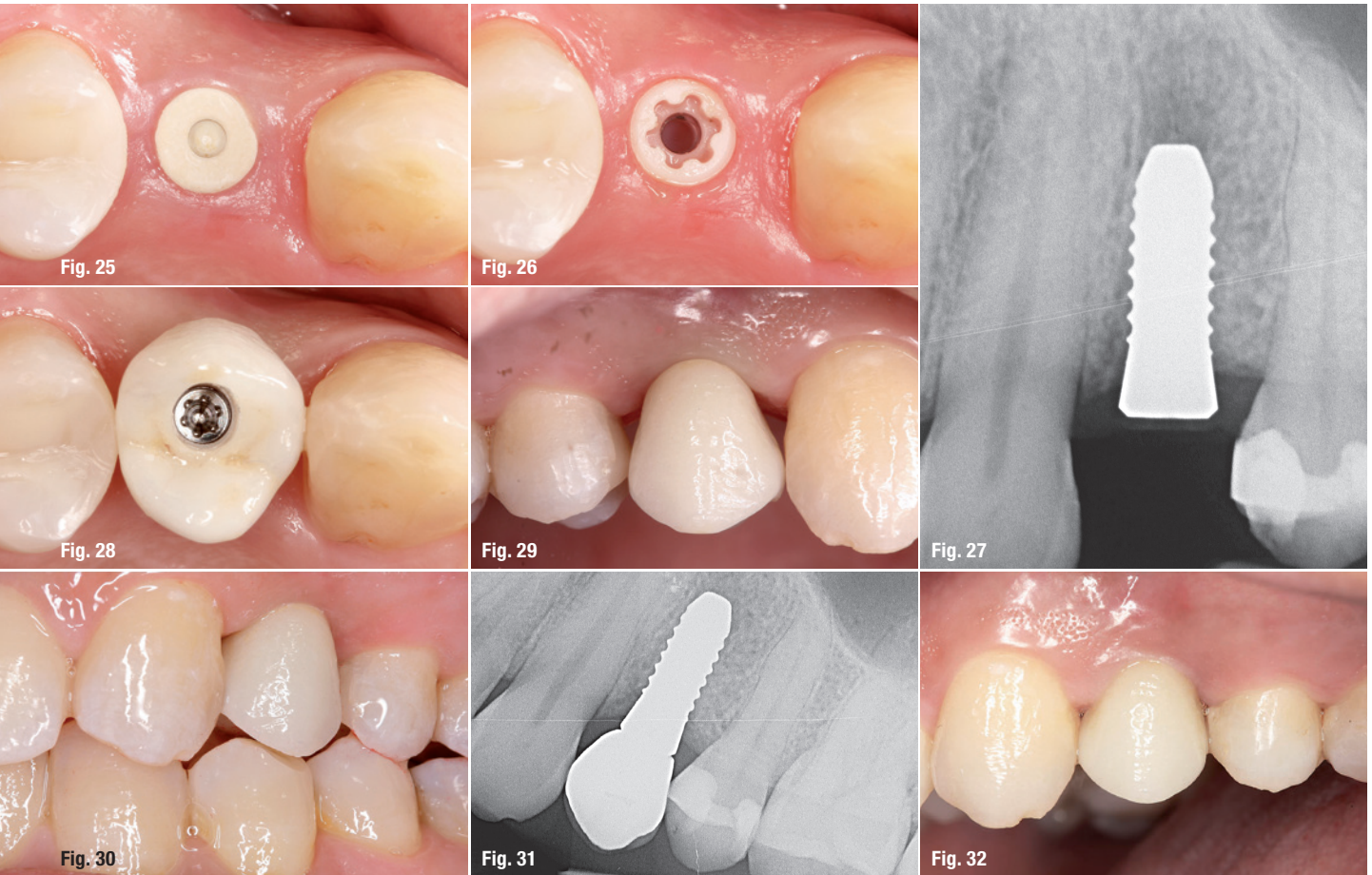Discussion

The two-part ceramic implant used in the case outlined above (CERLOG Hexalobe, CAMLOG) is an alternative to a titanium implant. It osseointegrates and is used for patients who want a metal-free, aesthetic solution. The implant can be used both supracrestally and epicrestally. In general, the primary indications for CERLOG implants are fixed single tooth crowns and three-part bridge restorations without extensions. In terms of the latest developments, there are limitations in the domain of removable treatment concepts.

CERLOG implants are produced in a ceramic injection moulding process, whereby after having been injection moulded, the implants are then subjected to a sintering



Figs. 12–15: Manual implant insertion with torque regulation. **Figs. 16–18:** For an open healing process, the implant was closed with a healing cap and the soft tissue adaptively sewn with monofilament 6-0 suture. **Figs. 19–21:** The healing cap is removed with a screw driver and an impression is made with a transfer post for the open tray technique. **Fig. 22:** Dental technicians created a master model in a laboratory. The lab analogue was attached to the impression post using a screw. **Figs. 23 & 24:** The crown was cemented to the PEKK abutment with a Multilink Hybrid Abutment.



Figs. 25–27: When the PEEK gingiva former was removed, a peri-implant gingiva free from irritation could be seen. **Figs. 28–30:** The hybrid abutment crown was inserted and screwed in place using a titanium screw with 25 Ncm. **Fig. 31:** As the high-performance polymer is not X-ray opaque, an uninterrupted gap of around 1 mm can be seen at the point of the implant-abutment crossover in the X-ray image. **Fig. 32:** The clinical situation one year after the prosthetic restoration took place.

process in a mould. This high-tech manufacturing process makes a dual surface texture possible without the surface requiring any subsequent processing. In the enossal region, it is just as coarse (1.6µm) as the approved surface (Promote, CAMLOG). In the neck region, the coarseness has a value of 0.5µm, optimal for soft tissue adaptation.

The implant system is easy to use as the abutment can be fixed with screws and the surgical procedure is easy to follow, among other aspects. The current version of the implant has been used in clinical practice with a PEKK abutment since 2013. PEKK is a high-performance polymer from the polyaryletherketone (PAEK) group. PEKK combines excellent mechanical strength with first-rate thermal properties and chemical stability.¹⁴

PEKK is mainly used as an implant material in CMF applications, such as reconstructive cranial surgery, and in the spine, such as for spinal fusion and rods for posterior lumbar interbody fusion. The ductility of the material used for the abutment simulates dental properties, as well as

having excellent sealing properties. Since the early summer, individually manufactured CAD/CAM abutments made from zirconium dioxide have been on offer for this implant system via a manufacturing service (DEDICAM). The translucent ivory-coloured zirconium dioxide implants are a similar colour to the tooth roots and as such, provide an aesthetically pleasing solution.



contact

Dr Frederic Hermann, M.Sc.
 TEAM 15 – Dental practice
 Poststr. 15
 6300 Zug, Switzerland
 info@team15.ch
 www.team15.ch





ZIRCONIA IMPLANTS

The Horizon is White



TAVDental
PRECISION. PASSION. PARTNERSHIP

www.tavdental.com
info@tavdental.com