



© Yuliya Evstratenko/Shutterstock.com

# “No Anaesthesia” endodontics in children

**Author:** Dr Imneet Madan, UAE

“Laser Popping Sound” in dentistry for children is one of the best approaches that can help us to overcome the initial fear of the unknown when it comes to first treatment appointments in children. Its uniqueness lies in the fact that the need for numbing is completely exempted. Today's children like technology playing at its best. Lasers definitely meet that perception of technology.

The routine first visit appointments are usually not a concern as children do not anticipate any intervention. Since they are not in pain, their mindset of approach is not defensive. Rather when there is no pre-biased opinion or fear, there is a pleasant sense of

adaptation that allows the smooth flow of the appointment. Any different kind of behavioural exhibit occurs only when kids are anticipating an intervention, when they had been in pain or when in general they come fatigued.

The discussion of needles is considered to be the most common subject just prior to the visit to the dentist. This discussion can become even more intense when there is already a perceived treatment need. Very young children can have the fear of the unknown, anxiety with strange and new places. The older ones develop extreme fear by talking to peers who have been to the dentist before. Some of them

might have had good and some others not so good experience. Sometimes, past unpleasant parental experience can distort the child's adaptability to the dental appointment. They enter the clinic with the pre-formed image of the dentist which is not very convincing and helpful to the child. These external experiences can lay the foundation of the child's coping ability in the dental chair.

### How can lasers help?

Since laser is not commonly available at all practices, there could be a possibility that there had been no real discussion on the use of lasers in the treatment. Another possibility of having a good experience with lasers can change the perception of the child who is in for the first time.

When laser is introduced to the parents, they are informed about details on the functioning of laser and its benefits. While explaining euphemisms to the child, the laser is shown as "Popping Light". There is a significant number of children who go awe-inspired to come back and get there teeth fixed.

The whole mindset of the child changes when they are told that treatments do not involve any needles approach.

### "No Anaesthesia"

Procedures that can be done without anaesthesia are:

- Restorations: Decays involving occlusal, labial, palatal, buccal or proximal surfaces of the teeth.
- Deep restorations on teeth with decays close to the pulp.
- Pulpotomies in primary teeth.
- Pulpectomies in primary teeth.
- Pulpectomies in primary teeth with abscess, fistula or swellings.

The term "No Anaesthesia" is a misnomer as the procedure is accomplished with few drops of anaesthesia in between, especially when endodontics is involved. The "No Anaesthesia" approach for enamel dentine restorations are the erbium laser Prep mode for restorative dentistry: MX7, 3.25 W, 25 Hz, air, water. There are two commercial settings that can be followed for the most acceptable cavity preparation:

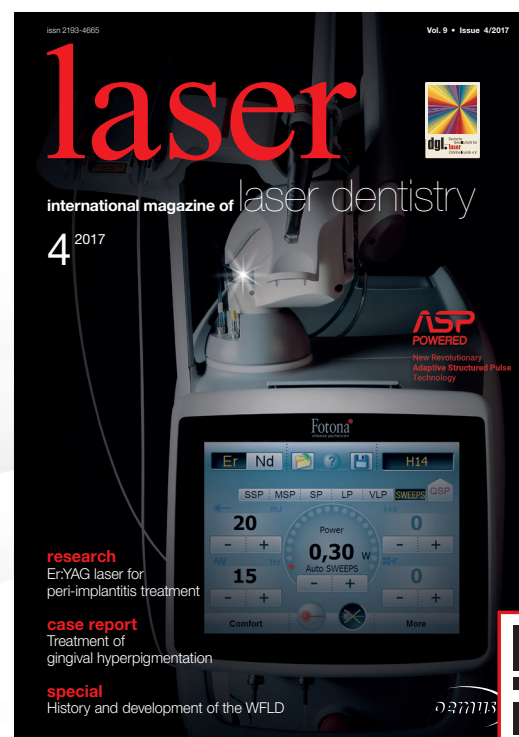
- Rapid Prep: MX7, 5 W, 20 Hz, air 80, water 50. This setting is usually used for enamel caries removal as water content is lesser. Since there is less water in the enamel, higher power is needed for appropriate absorption of laser.
- Comfort Prep: MX7, 3.75 W, 25 Hz, air 60, water 30. This setting is usually advised when we have reached the level of the dentine as the water content in the dentine is higher in comparison to enamel.

Once complete excavation of the decay has been attempted with laser, gentle hand excavation, low speed excavation is attempted. This step should be followed with Bond prep: MX7, 3.25 W, 50 Hz, air 60, water 30. Following this step, the tooth is isolated and restored with composite (Figs. 1 & 2).

# BECOME AN AUTHOR

for laser—international magazine of laser dentistry

Interdisciplinary and close to the market



www.oemus.com

## Fax to +49 341 48474-290

☐ Yes, I want to become an **author** for laser—international magazine of laser dentistry. I would like to submit an article on the following topic:

---



---

Please send back your fax form or contact Mr. **Georg Isbaner**:  
g.isbaner@oemus-media.de · Phone: +49 341 48474-123

Last Name, First Name

Street/ZIP/City

Phone/E-Mail

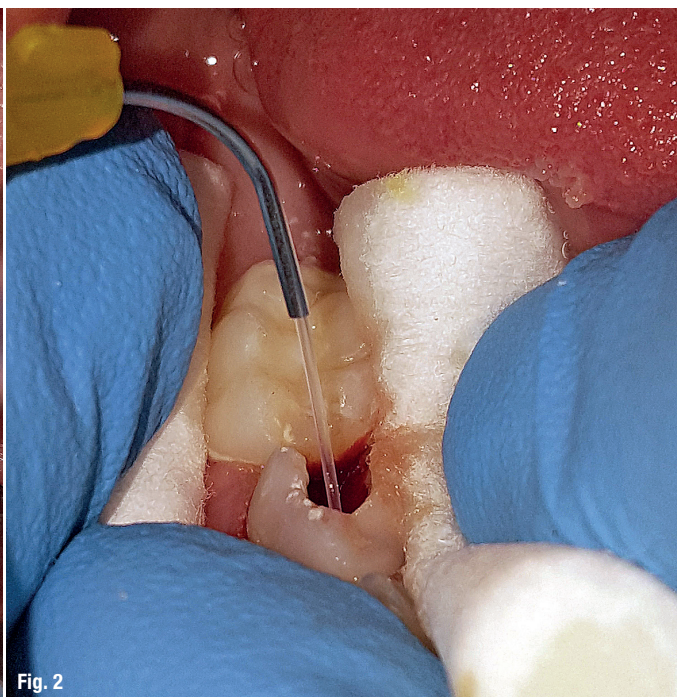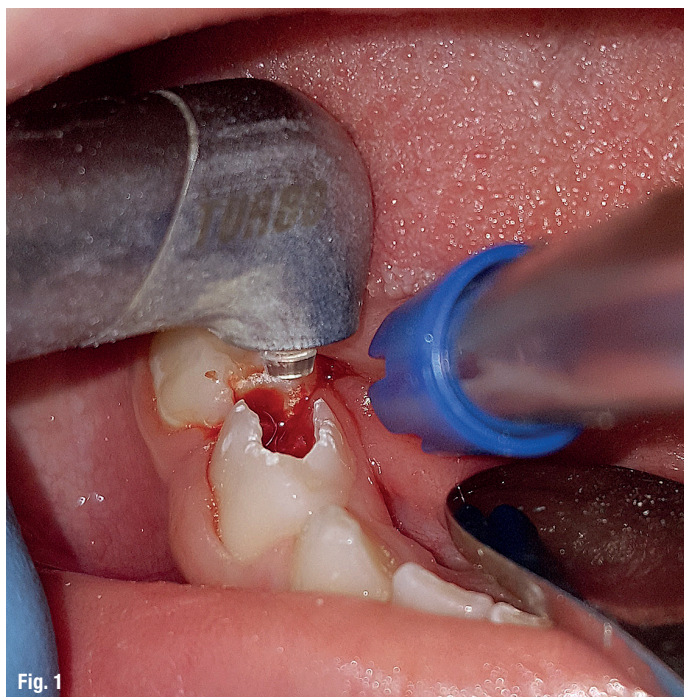
Stamp

laser 4/17

**OEMUS MEDIA AG**

Holbeinstraße 29 · 04229 Leipzig · Germany · Phone: +49 341 48474-0 · info@oemus-media.de





**Figs. 1 & 2:** The laser is a helpful tool in the dental treatment of children that can be used for various procedures.

### Pulpotomy procedure with erbium laser

When the carious decay is found deep and in close proximity to pulp, exposure of the pulp canals can happen while removing this decay. In such situations, exposed pulp needs to be treated by removing the affected coronal pulp contents. This procedure is referred to as Pulpotomy.

Deep caries are excavated with pre-adjusted rapid prep settings: MX7, 5 W, 20 Hz, air 80, water 50; and then comfort prep settings: MX7, 3.75 W, 25 Hz, air 60, water 30 are used as we approach deep into the dentinal caries. As soon as there is pin point pulp exposure, few drops of Lignospan are dropped inside the coronal pulp chamber. This step is followed by opening partial access into the coronal pulp chamber. As we go further deep into the coronal chamber, more anaesthetic intrapulpal infiltration is used followed by complete laser access opening.

After removing the coronal pulp contents, the chamber is irrigated and dried followed by diode laser sterilisation and coronal pulp filling with zinc oxide eugenol. The tooth is then filled with base Fuji IX and final restoration is done with composite or stainless steel crown.

### Pulpotomy procedure with erbium laser

Teeth that have chronic profound caries, active signs and symptoms, and radiographical signs of pulp involvement, are indicated for Pulpotomy. Pulpotomy involves the removal of both coronal and radicular pulp contents.

When the tooth is indicated for pulpectomy or root canal procedure, deep caries are excavated with pre-adjusted rapid prep settings: MX7, 5 W, 20 Hz, air 80, water 50; and then comfort prep settings: MX7, 3.75 W, 25 Hz, air 60, water 30 are used as we approach deep into the dentinal caries. As soon as there is pin point pulp exposure, few drops of Lignospan are dropped inside the coronal pulp chamber. This step is followed by opening partial access into the coronal pulp chamber.

As we go further deep into the coronal chamber, more anaesthetic intrapulpal infiltration is used followed by complete laser access opening. Once access has been done with laser, coronal pulp contents are removed. Before gaining access into radicular pulp chamber, few more drops of anaesthesia are dropped in. Complete extirpation of radicular pulp contents is done with rotary instruments.

Continuous copious irrigation is done with saline and chlorhexidine. Canal measurement is done, and as a final step before obturation, both the erbium and diode laser are used for sterilisation. Final step is zinc oxide eugenol obturation, Fuji IX base filling and composite restoration.

### Pulpectomy procedure in primary tooth with abscess or fistula

In cases where there are long standing infections or chronic irreversible pulpitis, it becomes invariable to use both diode and erbium laser sterilisation after the laser assisted access and further steps as described above.

Until the point that canals are found completely dry, obturation is deferred. Usually it takes one or two visits to complete the final step of obturation in teeth with abscess or fistula. The entire treatment is completed with intrapulpal drops of anaesthesia when required. No infiltrations or blocks are used in the entire procedure.

This procedure has been practiced as an alternate to pre-times extraction of primary teeth that has to be then replaced with a space maintainer. Most of the parents prefer this approach when compared to extraction, as they do understand that having the natural tooth as the space maintainer is indeed the best approach.

### Benefits of "No Anaesthesia" dentistry

- No risk of children having traumatic bite after the procedure is completed. The times when anaesthesia in children was a common practice, it was imperative to let the child and parents know about the numbing effect that would stay for few hours after the procedure. Cotton roll is given to bite on so that it serves as a reminder for the child.
- Despite all these precautions, children may still land up in biting their lip or cheek. Once there is a traumatic bite, there is nothing much that can be done as the traumatized tissue has to self-heal. This can be quite painful for the child, thereby defeating the entire purpose of pain free dental approach.
- Multi-quadrant dentistry can be practiced on the same day, same appointment.

- There is actual saving of chairside time, as there is no waiting period for local anaesthesia to work.
- Children can eat a few minutes after the procedure, which is not the case with dental local anaesthesia.

### Conclusion

Practicing contemporary dentistry in children with the appropriate usage of technology and the key tools, is the way forward. The benefits of the "No Anaesthesia" erbium approach far outweighs the existing alternatives. This kind of professional approach can certainly become the gold standard for dentistry in children in the very near future.

### contact

#### Dr Imneet Madan

Specialist Pediatric Dentist  
MSc Lasers Dentistry (Germany)  
MDS Pediatric Dentistry  
MBA (Hospital Management)  
Children's Dental Center, Dubai  
Villa 1020 Al Wasl Road  
Umm Suqeim 1, Dubai  
United Arab Emirates  
Tel.: +971 506823462  
imneet.madan@yahoo.com  
www.dr-michaels.com

Author details



### Kurz & bündig

Für die zahnärztliche Behandlung von Kindern wird oft eine Vollnarkose durchgeführt. Kinder fürchten den Schmerz beim Zahnarzt, den sie entweder selbst oder durch Erzählungen anderer erlebt haben. Mittels Laser sind weitgehend schmerzfreie Behandlungen ohne Narkose möglich. Ein neuer Ansatz in der laserbasierten Kinderzahnheilkunde ist „No Anaesthesia“. Hierbei wird ohne Narkose mit nur wenigen Tropfen eines Anaesthetikums gearbeitet. Folgende Prozeduren lassen sich ohne bzw. mit geringer Betäubung unter Anwendung eines Erbium-Lasers ausführen:

- Restaurationen aufgrund von Zahnfäule an okklusalen, labialen, palatinalen, bukkalen oder proximalen Zahnoberflächen.
- Tiefer gehende Restaurationen aufgrund von Karies an der Zahnpulpa.
- Pulpotomie und Pulpektomie bei Milchzähnen.
- Pulpektomie bei Milchzähnen mit Abszess, Fistel oder Schwellung.

Mittels zwei unterschiedlicher Settings im Prep-Modus lässt sich Karies an Zahnschmelz und Dentin effektiv beseitigen. Während der Behandlung werden dabei wenige Tropfen eines Anaesthetikums in das zu behandelnde Areal gegeben. Der „No Anaesthesia“-Ansatz vermindert zudem das Risiko eines traumatischen Bisses nach der Behandlung, der für das Kind sehr schmerzhaft ist und seine Abneigung gegenüber einer Zahnarztbehandlung noch verstärkt. Aufgrund der vielen Vorteile wird sich dieser Ansatz in Zukunft sicherlich zum Goldstandard in der Kinderzahnheilkunde entwickeln.