

Gingival depigmentation using diode laser

A non-ablative technique with test patch

Dr Chayanee Prakongsantikul & Assoc. Prof. Dr Sajee Sattayut, Thailand

Gingival hyperpigmentation is a condition affecting aesthetic appearance. There are many techniques for treating gingival hyperpigmentation, but still no technique available for patients to select a satisfactory gingival colour. In this case report, we present a technique of gingival depigmentation using a diode laser that provides a test patch for the patient to decide on the gingival colour.

Introduction

Nowadays, people are increasingly concerned about aesthetics. The appearance of the smile is affected by not only the teeth but also the gingivae. Much of gingival hyperpigmentation is due to normal physiological variation rather than being pathological in nature. In this case report, although it did not present any medical problems,

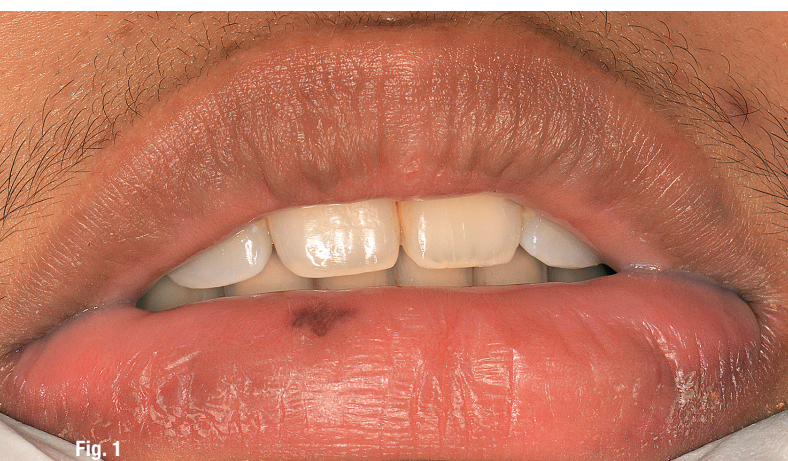

Fig. 1

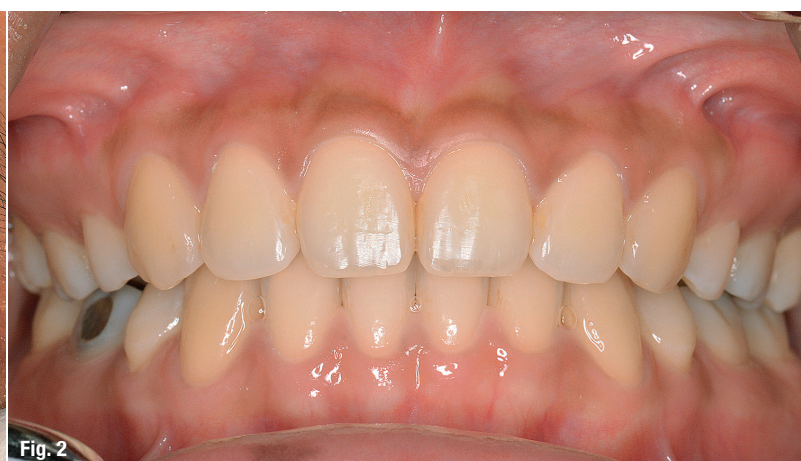

Fig. 2

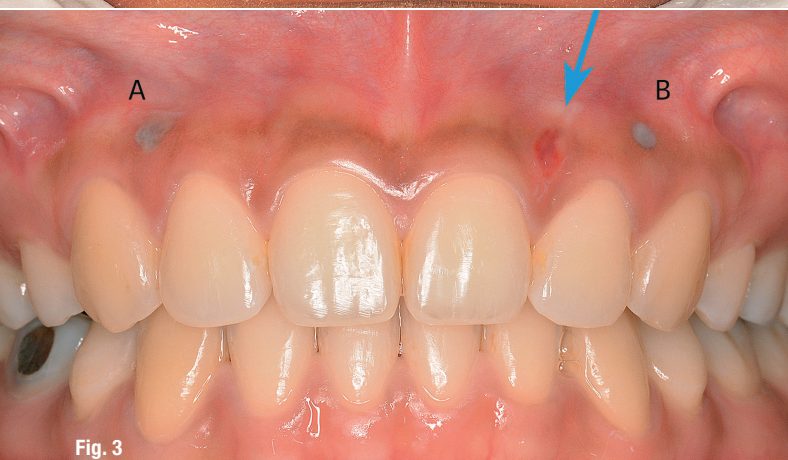

Fig. 3

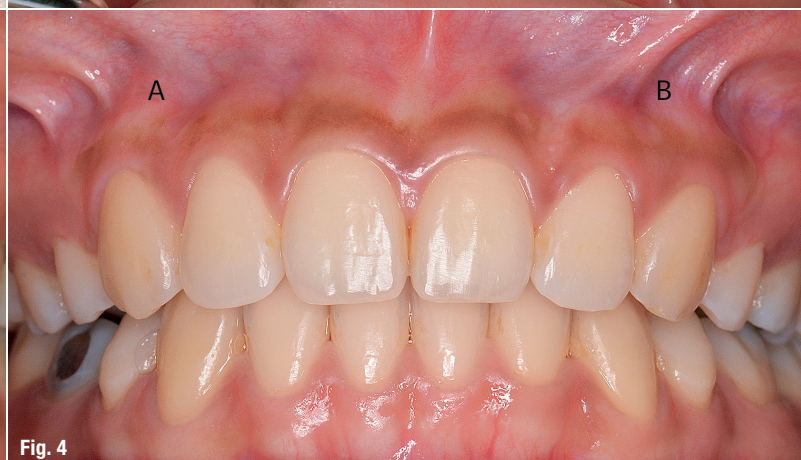

Fig. 4

Fig. 1: A melanotic macule of the lower lip. **Fig. 2:** Pre-op hyperpigmentation of the gingiva of the maxillary anterior teeth. **Fig. 3:** Test patches as indicated by A and B. The blue arrow is pointed to an incisional biopsy area. **Fig. 4:** Two weeks after laser dose testing and incisional biopsy, complete healing of the gingiva was observed. The patient was able to detect the difference in colour between the areas treated with Settings A and B.

it was an aesthetic concern for our patient and appeared as darkened gingiva.¹

There are many techniques for the treatment of gingival hyperpigmentation, such as gingivectomy using scalpel, rotary, electrosurgery, laser and chemical agents to resurface the gingiva and applying cryosurgery to eliminate melanotic cells.²⁻⁴ These abrasive techniques involve a non-favourable appearance during the healing process. Even though depigmentation using a carbon dioxide laser provides less discomfort, wound coverage using a gingival dressing is still needed.⁴ Non-abrasive techniques that use laser for gingival depigmentation are worth investigating, as well as the technique of using a tissue testing patch for fulfilling aesthetic concerns.

This case report presents a new non-abrasive technique using an 808 nm diode laser in the case of physiological hyperpigmentation of the gingiva. The laser test patches were used before treating the whole area in order to gain greater patient satisfaction regarding the gingival colour.

Case report

A 22-year-old Thai woman presented to the oral surgery clinic, faculty of dentistry at Khon Kaen University, complaining of brownish gingiva, particularly at the maxillary anterior teeth. The patient reported no underlying disease or any medicine allergy. Furthermore, she reported no history of smoking. Extraoral examination found an oral pigmented lesion at the lower lip (Fig. 1). Intraoral examination found pigmented lesions at the attached gingivae from the maxillary right canine to the maxillary left canine (Fig. 2). The patient was diagnosed with physiological pigmentation of the gingiva and a melanotic macule on the lower lip.

Incisional biopsy was conducted under local anaesthesia at the attached gingiva between the maxillary left central incisor and the lateral incision in order to determine the depth of the melanin pigment in the gingiva. Haemostasis was achieved using an 808 nm diode laser at 0.5 W for 5 seconds (Fig. 3).

Then the two test patches were undertaken at the attached gingiva (Fig. 3) between the maxillary right lateral

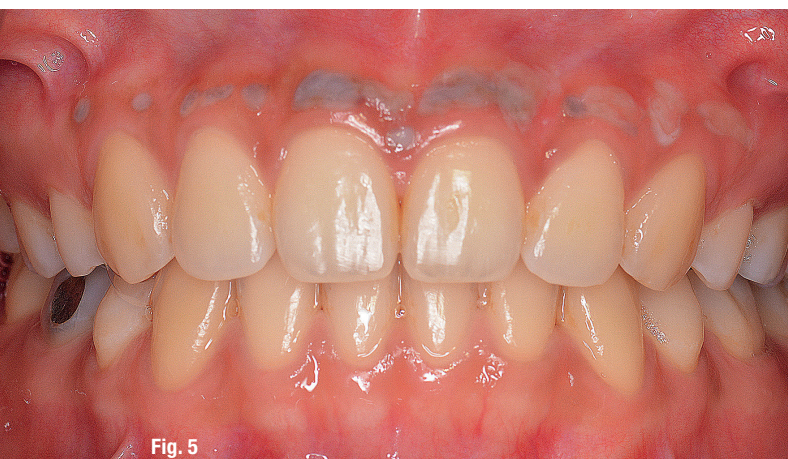

Fig. 5

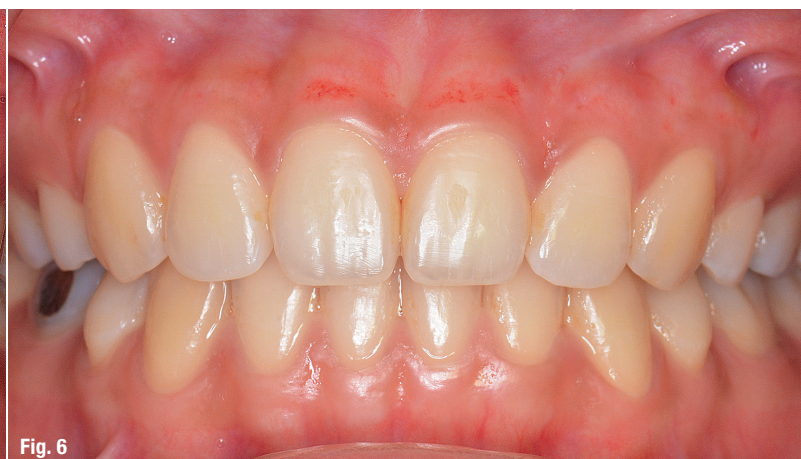

Fig. 6

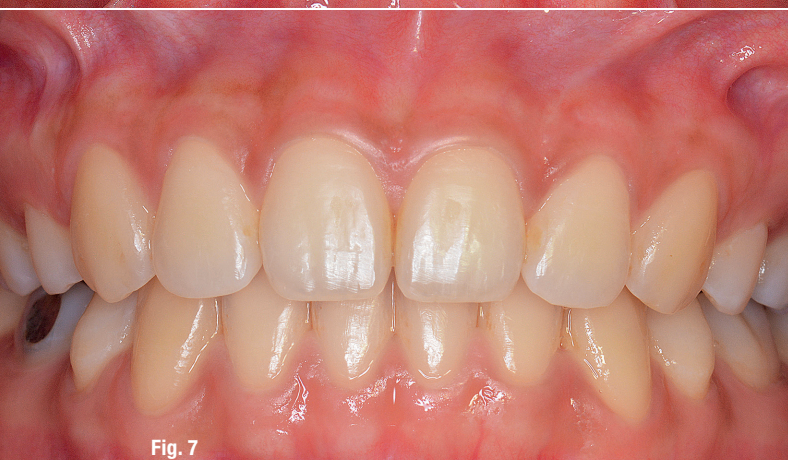

Fig. 7

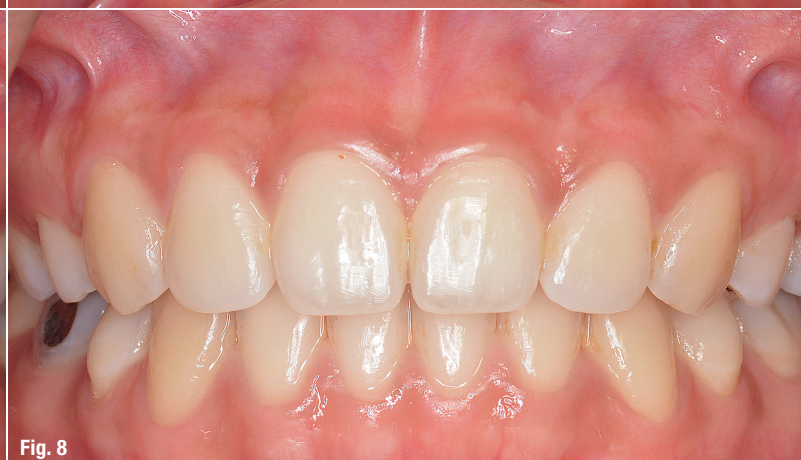

Fig. 8

Fig. 5: The immediate post-laser depigmentation photograph showed no photo-ablative effect. **Fig. 6:** After seven days, the area treated showed partial recovery with mildly reddened gingiva at the central incisors. There was no ulcerated area clinically. **Fig. 7:** After two weeks, the area treated showed complete healing of the gingiva. **Fig. 8:** After three weeks, the area treated showed uniformly normal-coloured gingiva.

incisor and canine (Setting A) and between the maxillary left lateral incisor and canine (Setting B) using an 808 nm diode laser with two settings as follows:

- Setting A: 3 W; continuous wave
- Setting B: 5 W; repeated pulse; 28 burst mode pulse per: 10 m/s; pulse width: 1 m/s burst pause.

The laser was used in a defocused mode, 3–5 mm from the gingival surface, and in circular motion until the tissue turned pale. Immediately post-laser depigmentation, the tissue showed only a photocoagulative effect without photoablation (Fig. 3).

Two weeks later, the patient was followed up. The biopsy results showed numerous melanocytes at the basal cell layer. Both laser testing sites had completely healed, with differences to the normal gingival colour. The area treated with Setting A was more erythematous than the area treated with Setting B (Fig. 4). The patient was asked to select the test patch that was her preferred gingival colour. She chose the area treated with Setting B. Then the gingival depigmentation of the maxillary anterior teeth was done according to the selected setting (Fig. 5). After the treatment, the patient was prescribed a 0.12 % chlorhexidine mouthwash to rinse daily for two weeks and 400 mg of ibuprofen as necessary.

Results


The patient felt comfortable and did not take any analgesics after the treatment. The seven-day follow-up showed some mildly reddened areas at the maxillary incisors (Fig. 6). The area that had been prepared with laser had completely healed within two weeks (Fig. 7). The colour of the treated gingiva was the same as that of the surrounding gingiva and mucosa within three weeks (Fig. 8). The patient was satisfied with the results.

Discussion

As this laser wavelength is absorbed by melanin and less absorbed by water, an 800–900 nm diode laser was used in the treatment of gingival hyperpigmentation, providing less abrasion to tissue surfaces.³ This case report has demonstrated a non-abrasive technique using a diode laser for gingival depigmentation with complete healing in only two weeks. As far as the patient's satisfaction was concerned, we presented the technique of testing laser doses that provided more predictable gingival colour particularly from the patient's perspective. This could make the results more accurate and favourable.

Conclusion

Treatment of gingival hyperpigmentation using an 808 nm diode laser with non-ablative technique and laser dose test patches as proposed in this case report is a technique that offers clinical efficacy and patient satisfaction with predictable gingival colour in the case of physiological hyperpigmentation from melanocytes at the basal layer.



contact

Assoc. Prof. Dr Sajee Sattayut

Lasers in Dentistry Research Group
Oral Surgery Department
Faculty of Dentistry
Khon Kaen University
Thailand
sajee@kku.ac.th



Kurz & bündig

Gingivale Hyperpigmentierung stellt vor allem eine ästhetische Beeinträchtigung dar. Es gibt viele Techniken zur Behandlung dieser Erkrankung, aber keine davon ermöglicht es dem Patienten, eine zufriedenstellende Farbe der Gingiva auszuwählen. Im Fallbericht präsentieren die Autoren eine nicht abrasive Technik der Gingiva-Depigmentierung unter Zuhilfenahme eines 808 nm-Diodenlasers. Die 22-jährige Patientin wurde vorstellig wegen einer bräunlichen Färbung der Gingiva, die vor allem an den Oberkieferfrontzähnen sichtbar war. Zudem wurde eine orale Pigmentläsion an der Unterlippe festgestellt. Um die Tiefe der Pigmentierung zu bestimmen, wurde eine inzisionale Biopsie unter lokaler Anästhesie durchgeführt. Zur Bestimmung der vom Patienten gewünschten Farbe wurden zwei Test-Patches mit zwei unterschiedlichen Settings durchgeführt.

Beim Follow-up zwei Wochen später waren beide Laser-Testareale vollständig ausgeheilt; das Biopsieergebnis offenbarte eine Vielzahl von Melanozyten in der Basalzellschicht. Nachdem sich die Patientin für die Farbe eines der beiden Test-Patches entschieden hatte, wurde eine gingivale Depigmentierung an den Oberkieferfrontzähnen im gewünschten Setting durchgeführt. Nach der Behandlung waren keine Analgetika notwendig. Innerhalb von zwei bis drei Wochen war das mit dem Laser behandelte Areal komplett ausgeheilt und die Farbe der behandelten Gingiva glich der des umliegenden Zahnfleisches und der Schleimhaut.



16th WORLD CONGRESS WFLD 2018

1 – 3 OCTOBER 2018
RWTH AACHEN UNIVERSITY
AACHEN, GERMANY



The 16th Congress of the
World Federation for Laser
Dentistry (WFLD)

The 27th Annual Meeting of
the German Society for Laser
Dentistry (DGL)

The 6th Annual Congress
of the World Academy for
Laser Education
in Dentistry (WALED)

This congress will integrate science and practical experience on different levels of presentation and demonstrations, like:

- High ranked international keynote speaker lectures
- On stage live patient demonstrations
- Interactive digital poster presentations
- Oral presentations combined with clinical relevant skill training
- Short presentations of latest research findings
- Clinical case presentations
- Rotating company supporting workshops, gaining continuous education certificates.

CONTACT

Headquarters WFLD 2018 Aachen
Mr. Leon Vanweersch
Vice-Organizing Chairman
Phone: +49 151 50610781
headquarters@wfl-d-aachen2018.com
www.wfl-d-aachen2018.com