

Immediate loading in heavy smokers

Dr Dr Branislav Fatori & Dr Inge Schmitz, Germany

Today, numerous implant systems and many modifications thereof are available on the market, and it may be difficult to choose the optimal implant system for each patient. Immediate loading of dental implants is indicated when there is good primary stability and an appropriate occlusal load. To achieve a satisfactory result concerning implant survival, a number of factors have to be taken into consideration, such as the type and quality of the bone, bone density, placement and location of implants, the patient's motivation and, of course, financial constraints.

In this report of two cases of heavy smokers, we investigate from clinical, morphological, biomechanical and electron microscopy aspects the suitability of a new implant system (T.A.G. Dental), using a Toronto bridge construction. The term "Toronto prosthesis" or "Toronto bridge" originates from an extrapolation of the clinical and laboratory procedures introduced by Zarb in Toronto in Canada in the 1980s. The main advantage of the Toronto bridge is that it allows the correction of implant emergence profile and that the milled abutment is sufficiently

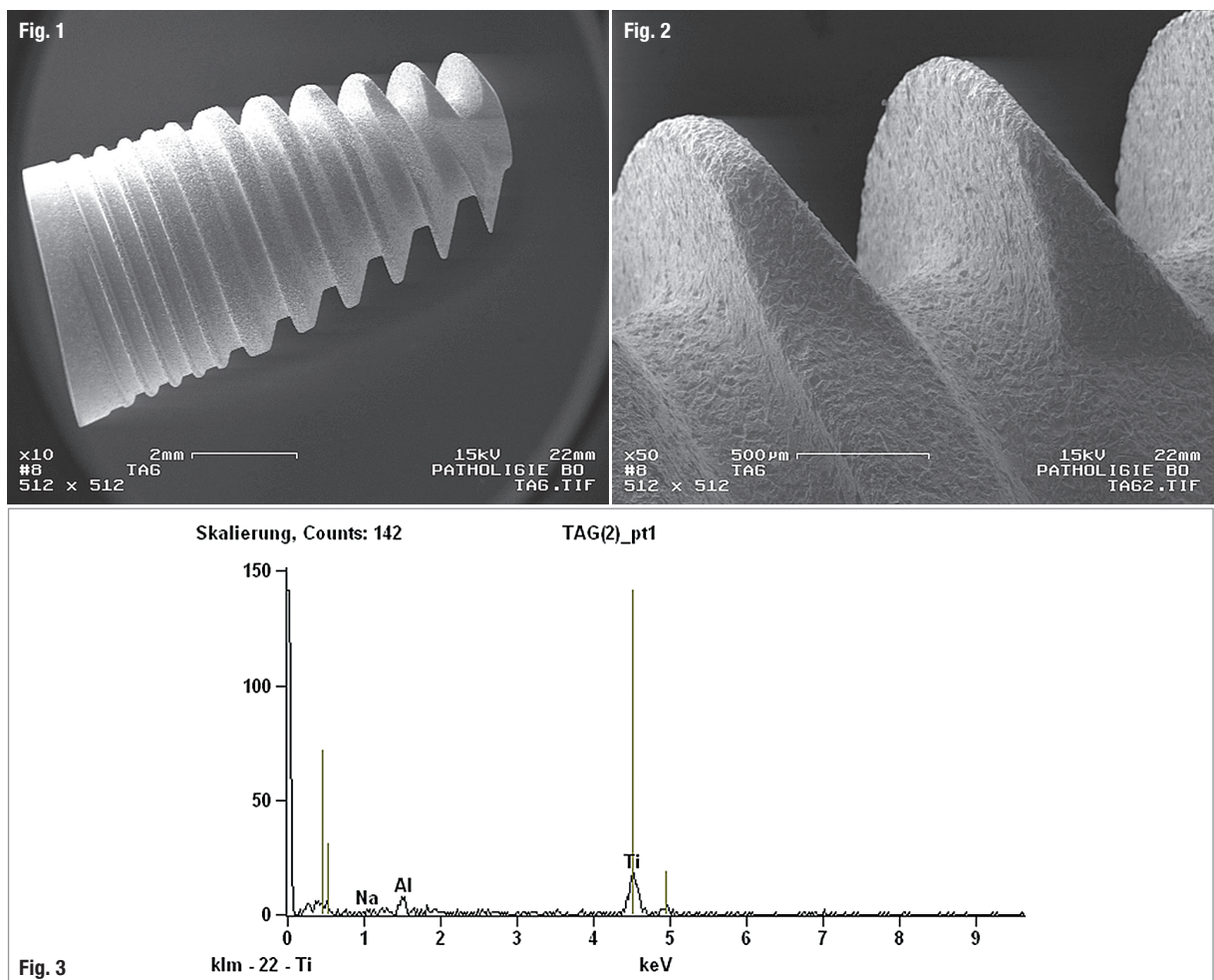


Fig. 1: SEM image, overview. Fig. 2: Detailed SEM image showing accurate design of the implant. Fig. 3: EDS of the implant surface (Case 1). Titanium (implant) and small amounts of aluminium (contaminations resulting from manufacturing processes) were detected.



Dentsply Sirona does not waive any right to its trademarks by not using the symbols or 3267114-USX1610 © 2016 Dentsply Sirona. All rights reserved.

Astra Tech Implant System®

Our world is not flat

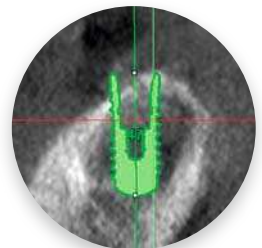
Neither is the anatomy of your implant patients

Your world is already full of clinical challenges so why work harder because of conventional thinking? Instead of augmenting sloped ridges to accommodate flat-top implants, it's time to discover a simpler solution by using an implant that follows the bone. Because sloped-ridge situations call for anatomically designed sloped implants.

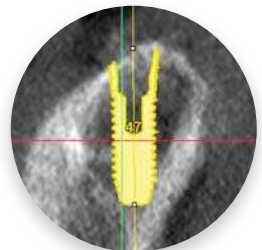
OsseoSpeed® Profile EV - It's time to challenge conventional thinking



www.profiledentalimplants.com



Conventional vs innovative approach



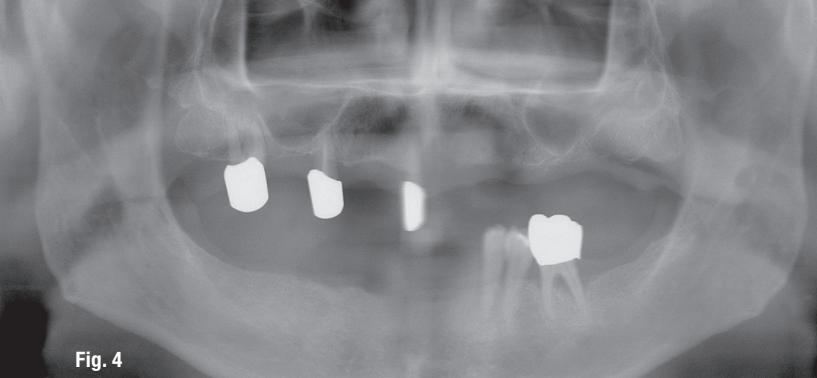


Fig. 4

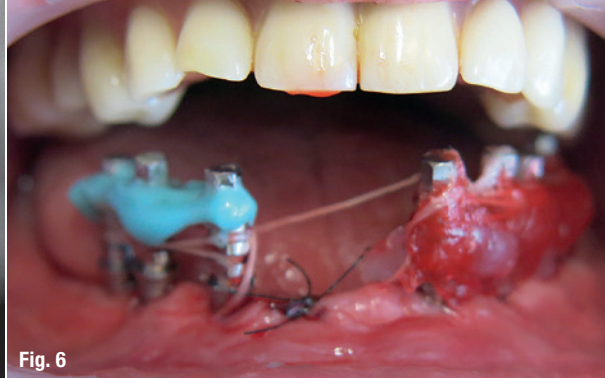


Fig. 6

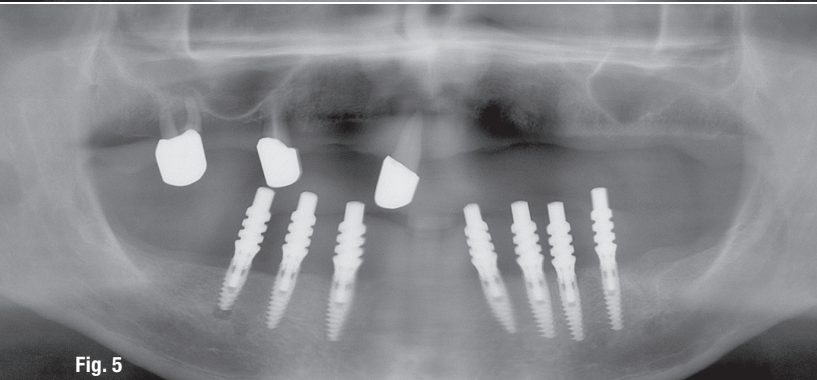


Fig. 5

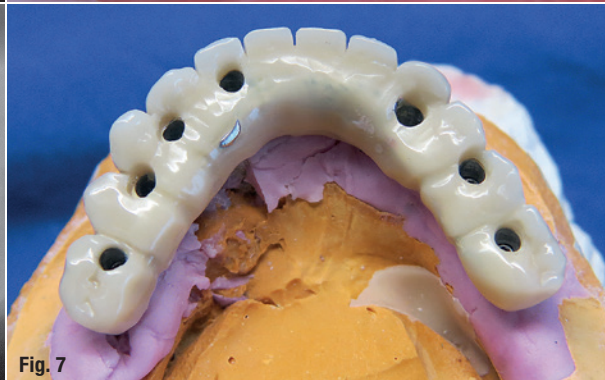

Fig. 7

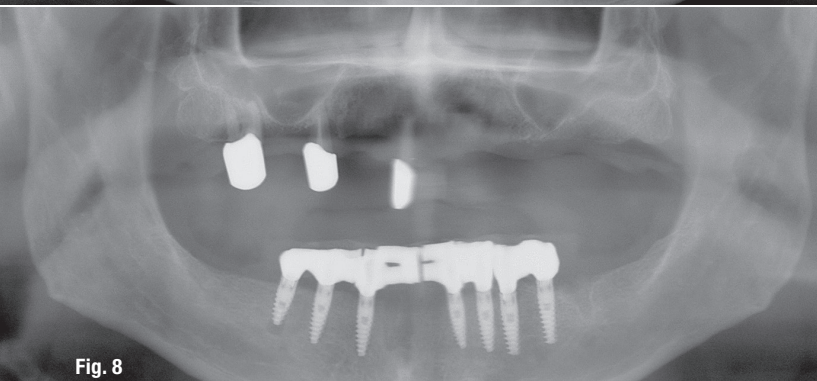


Fig. 8

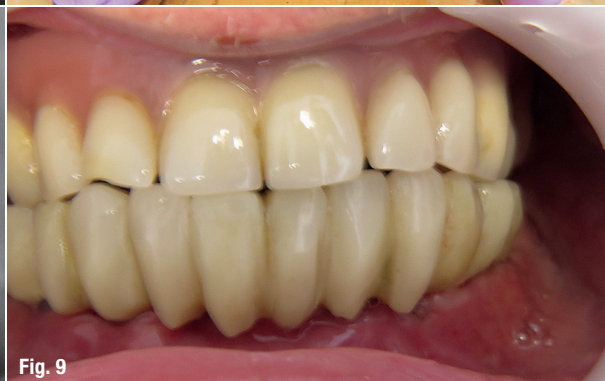

Fig. 9

Case 1 – Fig. 4: Radiograph showing situation before operation. Remaining teeth were periodontally compromised (teeth #35 and #37). **Fig. 5:** Radiograph showing in situ situation after flapless surgery had been performed. Seven implants were placed in the mandible. **Fig. 6:** Different link systems of implants were compared: using silicone (left) and patera (right). **Fig. 7:** Toronto bridge construction. Implant bridge was fixed with screws on the model. **Fig. 8:** Panoramic radiograph showing the new bridge. **Fig. 9:** Result.

tapered to ensure retention of the crown by using provisional cement.

Materials and methods

Scanning electron microscopy (SEM) investigations were done beforehand in order to evaluate the quality of the implant surfaces. An additional elemental analysis (energy-dispersive spectroscopy—EDS) was performed in order to determine whether prominent contaminations were present on the implant surfaces (Figs. 1–3).

Case reports

Four patients were treated with a new implant system (T.A.G. Dental). Two cases will be reported here in detail (Figs. 4–16). In total, 24 T.A.G. implants were inserted in four patients (maxilla and mandible). Anatomical conditions were evaluated by panoramic radiography in order to provide good information about the jaw size, bone volume and occlusal relationships. In none of the patients was augmentation necessary.

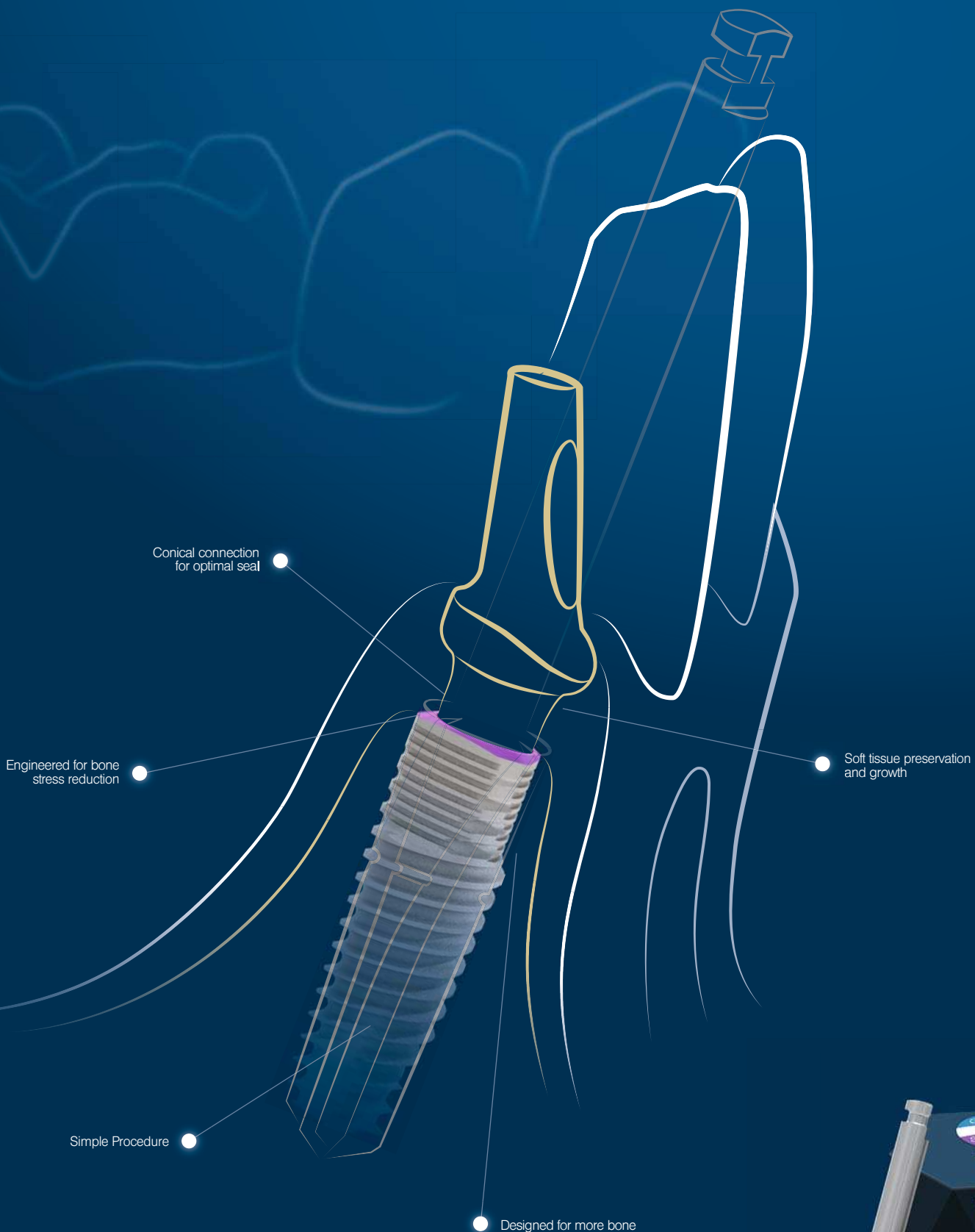
The patients were advised to quit or reduce smoking at least two weeks before implant surgery in order to allow for recovery of normal blood viscosity, because smoking is a major reason for loss of dental implants. Periodontal HELBO therapy was performed in order to remove biofilm.

Case 1

The first case was a male patient, 57 years of age and a heavy smoker (40 cigarettes per day) who reported having a great deal of stress at work. Seven implants were inserted into the mandible (two implants of 10.0 × 3.75 mm; five implants of 10 × 13 mm) with prior consensus of the patient that one implant would be removed later for histological analysis (Figs. 17 & 18).

Case 2

The second patient, also male, 37 years of age and a heavy smoker (25 cigarettes per day), presented with unsalvageable dentition. Eight implants were inserted in the mandible (six implants of 13.0 × 3.75 mm; two implants of 10.0 × 4.2 mm).



MAKE IT SIMPLE. WE KNOW HOW!

The MIS V3 Implant System was designed to offer immediate biological benefits and improved performance, while keeping surgical procedure simple. Learn more about the V3 implant and MIS at: www.mis-implants.com

mis® | **V3**

Surgical technique

Implant placement was performed under local anaesthesia (40mg of Dexamethasone, intramuscular, ratiopharm) after premedication with antibiotics. The bone cavity was extended gradually according to the intended implant diameter. After incision making, cleaning of the oral cavity was carried out and necrotic or inflammatory tissue removed. Osteotomy sites were prepared with a sequential order of drills recommended by the manufacturer. Implants were inserted in the prepared osteotomy sites with an insertion torque of 45Ncm. An adequate primary stability having been obtained, PGA RESORBA (RESORBA) was used for suturing.

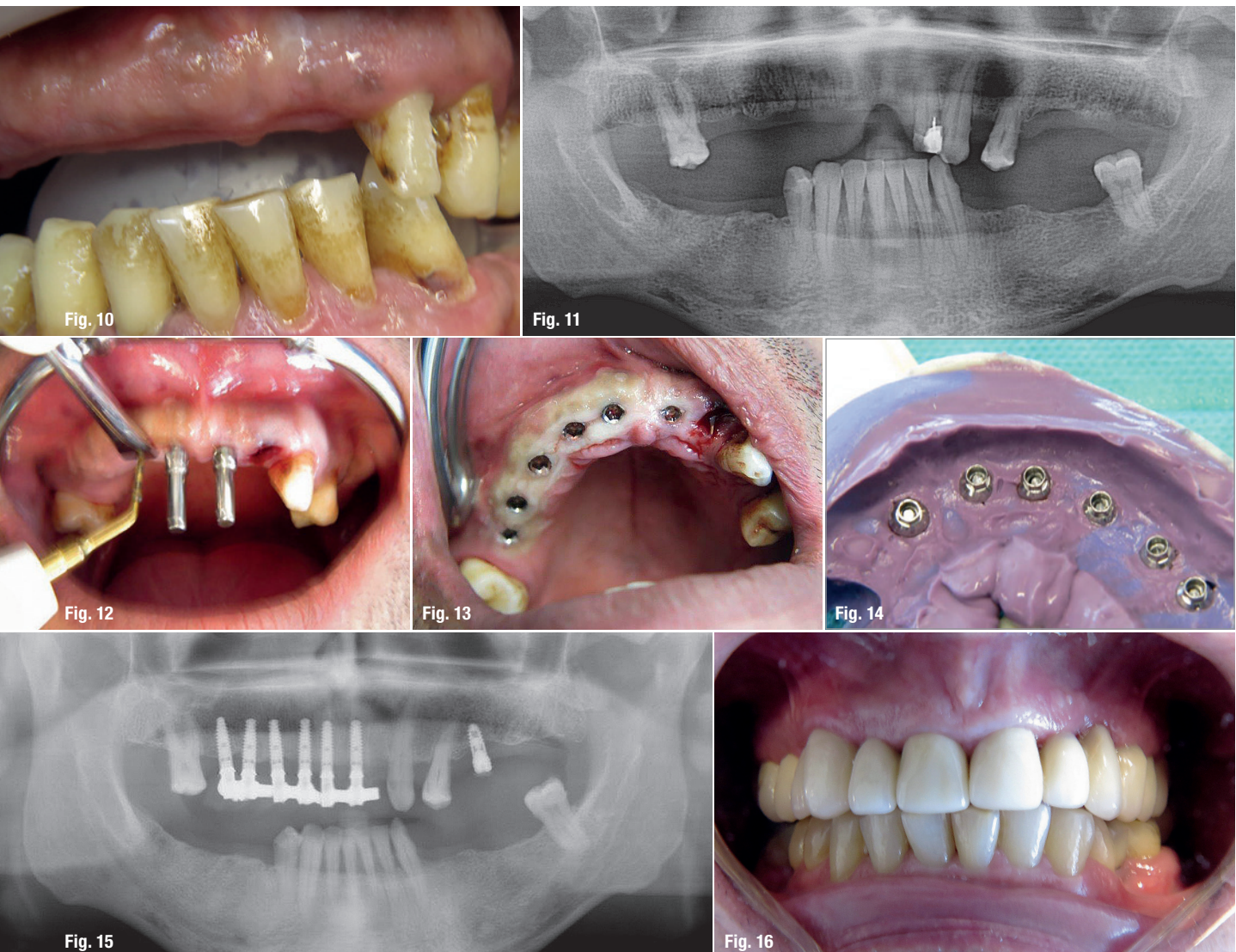Postoperative treatment

Postoperative intraoral periapical radiographs were taken and confirmed the accuracy of the implant place-

ment. Postoperative medications included antibiotics. Digital radiographic images were taken at the time of surgery, after 24 hours and one month later in order to evaluate implant success. Inflammatory processes were found in none of the patients, and all of the implants have remained stable until now. Abstention from smoking should be extended to at least eight weeks after the implantation in order to permit the healing phase of the osteoblasts to take place.

Discussion

Today, immediate implant concepts are gaining increasing popularity for replacing missing teeth. For dental implants placed at the time of extraction, high success rates have been reported. Depending on the patients' situation, immediately placed and immediately loaded



Case 2 – Fig. 10: Unsalvageable dentition before operation. All of the teeth had to be extracted. **Fig. 11:** Panoramic radiograph of the pre-op situation. **Fig. 12:** Flapless surgery. **Fig. 13:** Extraction of tooth #22. Good condition of the peri-implant gingiva. **Fig. 14:** Replica with Impregum (3M ESPE). **Fig. 15:** Radiograph of implants. **Fig. 16:** Final result.



Fig. 17

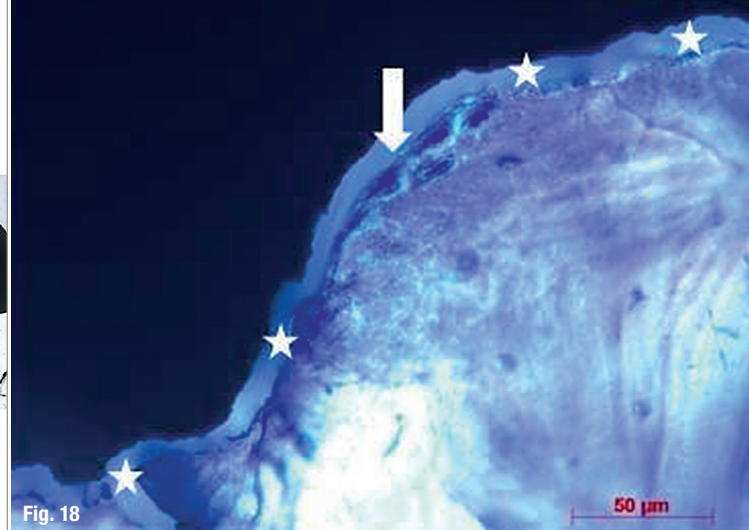


Fig. 18

Case 2 – Fig. 17: Histological analysis: good integration of implant and bone was observed. **Fig. 18:** Formation of new bone.

implants may be more predictable and successful than conventional implants. When considering immediate implant placement with an immediate loading procedure, careful patient screening and selection are required.

Smoking

The literature reports lower survival rates of dental implants in smokers. One possible mechanism that might affect osseointegration in smokers is a lowering of the blood flow rate due to increased peripheral resistance and platelet aggregation. Tobacco directly affects osteoblast function. In general, smoking is a major risk factor for implant failure. If smokers are treated with implants, good bone quality is necessary.

In the presented cases, bone quality was good and no augmentation procedures were needed. In all cases, excellent primary stability was achieved. Based on the outcomes of the present report, it can be concluded that immediate implant placement with immediate loading in heavy smokers can lead to good results if the surgeon has a great deal of experience in placing implants and the patient's bone quality is good enough.

T.A.G. implants

The surface finish of all implants is achieved mechanically and chemically by blasting with particles and acid etching, with a roughness ranging from 1.8μ to 2.2μ and morphology of the cavities from 2μ to 40μ . The micro-surface morphology increases bone-to-implant contact and results in an improvement of mechanical anchorage for better primary stability that favours cellular adhesion. Our SEM examinations confirmed the accurate surface structure of the implants used. The implant concept, such as macro-design geometry and micro-surface quality, will determine tissue reaction and influence the clinical success of the dental implant in the long term.

The macro-geometry of T.A.G. implants is designed to increase the overall functional surface area, contributing to a favourable force distribution that decreases the effective stress. The implant geometry and macro-porous surface ($mm-40\mu$) play a role in the primary stabil-

ity and long-term mechanical fixation. Parameters such as thread form, helix angle, lead number, width, depth, pitch and body shape have been the subject of intensive research regarding T.A.G. implants. Integration and optimisation of all these variables will lead to a better implant design. In the case of immediate loading, these parameters are critical.

Since the implant surface is the first component to interact with the host, surface modifications of T.A.G. implants have been extensively investigated in an attempt to increase the rate of bone healing and thereby allow practitioners to perform immediate or early loading of dental implants. The new generation of implants developed by T.A.G. Medical Products in Israel optimises the different parameters, such as geometry, topography, surface properties and surface quality, that lead to high success rates. The main advantage in using T.A.G. implants is the uniform connection design. That means that the 2.44 mm internal hexagonal connection is the same for all of the implants, ranging from 3.3 to 6.0 mm in diameter, simplifying the surgical process and eliminating the need to stock different restorative options to accommodate different implant sizes.

contact

Dr Dr Branislav Fatori

Rolandstraße 11
45128 Essen, Germany
Tel.: +49 201 82188890
info@fatori.de
www.fatori.de



Dr Inge Schmitz

Georgius Agricola Stiftung Ruhr
Institute for Pathology
Ruhr-University Bochum
Bürkle-de-la-Camp-Platz 1
44789 Bochum, Germany
Inge.Schmitz@rub.de

