

Fixed or removable? That is the question.

Dr Alessio Casucci & Alessandro Ielasi, Italy

Edentulism is considered to be a disability and a major oral health problem worldwide.^{1,2} Replacing missing teeth with a well-designed and -fabricated complete denture can satisfy the patient who has both a suitable clinical condition and adaptability. However, complete dentures do not restore function in all patients, especially in the case of the rejection of a removable solution for psychological reasons.

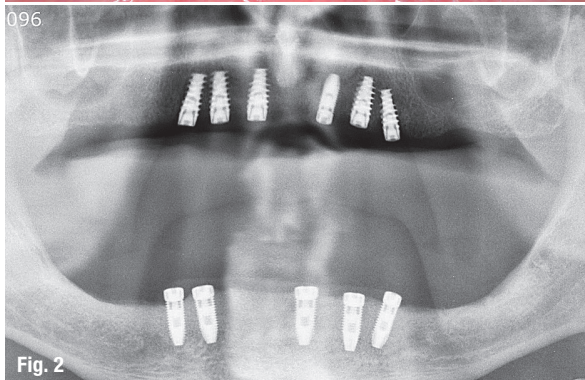
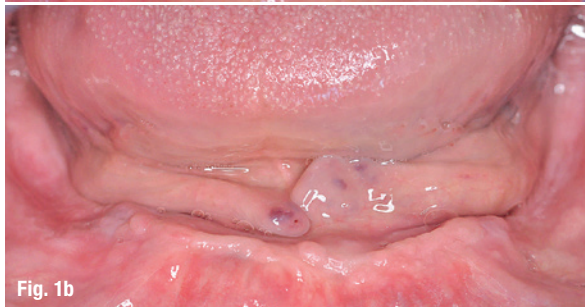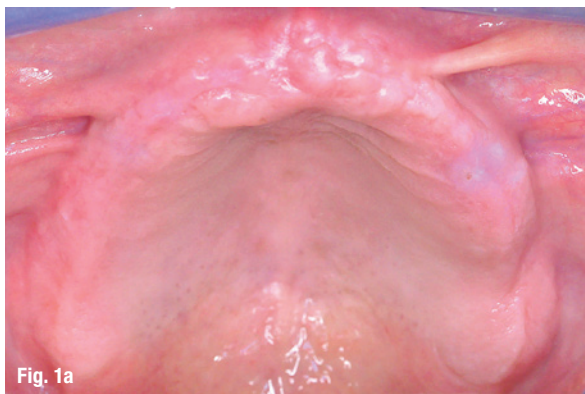
The increased awareness, survival, and success of implants and implant restorations have expanded the options for restoring the edentulous mouth from conventional dentures to implant-assisted prostheses. Furthermore, numerous studies have demonstrated that restorative approaches involving implants improve edentulous patients' masticatory function, quality of life and self-esteem.^{3,4}

Implant restorations have to be planned properly, evaluating different parameters to achieve long-term success. Bone resorption, aesthetics and phonetic parameters can be determinants in establishing a proper treatment plan. Several patient-related parameters such as hand ability, maintenance and other functional aspects, have to be considered before starting patient treatment. Scientific literature too has to be considered by the clinician in order to evaluate clinical protocols, especially for the mandible where the possible standard of care must be established. A consensus regarding this standard of care for the fully edentulous maxilla based on a critical appraisal and comparison of the cost-effectiveness of different prosthodontic solutions has not yet been achieved.⁵

For the maxilla, the literature abounds with descriptions of technical solutions, ranging from a fixed solution retained by four axial or tilted implants and upwards to a removable solution supported by two to ten splinted or free-standing implants. It has been reported that patient expectations are higher regarding treatment with fixed restorations.⁶

For some patients, a removable maxillary restoration would be the best solution providing facial scaffolding and especially for patients with a wide smile and/or high smile line covering the prosthesis-tissue junction. In addition, it is beneficial to adverse ridge relations or discrepancies and gives more latitude if the palatal contour for phonation has to be adjusted.⁷ Furthermore, it can be challenging to properly clean a fixed restoration in patients with severe maxillary resorption.⁸ It has been reported that fixed restorations result in phonetic disturbances in 42% and aesthetic problems in 37% of the treated patients.⁹

The case described in this paper reports on the treatment of an edentulous patient in whom implants were



Figs. 1a & b: Intraoral photographs. **Fig. 2:** Dental panoramic tomogram.

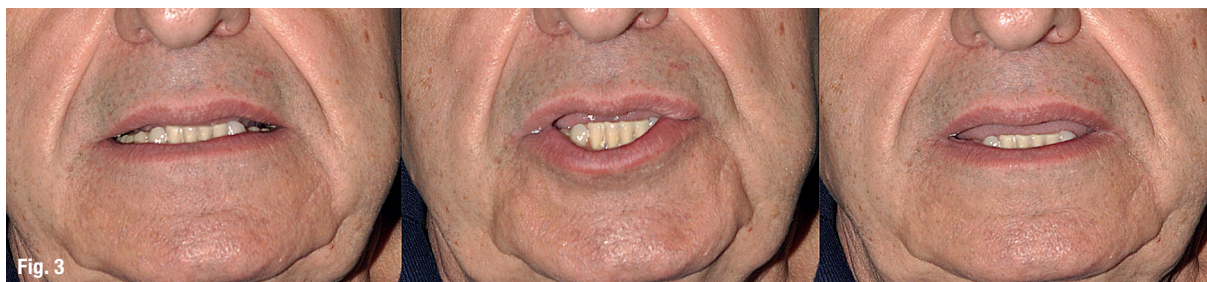

Fig. 3: Patient during speaking and smiling.

placed and prosthetic solutions were defined before the surgical procedures. The patient was rehabilitated with a fixed restoration in the mandible as established. For the maxilla, the finalisation moved from a fixed to a removable solution because of aesthetic and phonetic aspects.

Clinical case

A 63-year-old male patient edentulous in both arches was evaluated for definitive implant supported restorations.

Case history

The patient had lost his remaining teeth a few years before our visit. He had been restored with complete dentures fabricated on the basis of his repaired previous partial dentures. The patient did not report a significant medical history and occlusal or temporo-mandibular disease. At the preliminary appointment the patient communicated mainly a functional discomfort due to the instability of the mandibular denture during mastication.

He reported several problems using the mandibular denture, complaining of its instability in almost every situation (during speech, eating, etc.). The maxillary denture had low retention and the palatal extension was poorly tolerated. The previous dentist had planned to rehabilitate the patient with fixed implant restoration in both arches, but after the implant placement, the patient had had several health problems due to an ischaemic stroke and this had delayed the prosthetic finalisation. At the same time, he had been forced to move to our city because he was living with his daughter and she had changed her job.

Clinical evaluation

At the first visit the patient informed us that the implants had been placed the year before. He reported some sore spots due to the maladaptation of the bearing base to the tissue. The complete dentures were found to be unstable during static evaluation (Figs. 1a & b).

Radiographic evaluation

The dental panoramic tomogram revealed six implants in the maxilla and five implants in the mandible, and slight bone resorption was detected around the fixtures (Fig. 2).

Prosthetic evaluation

The patient's lips revealed a lack of support when wearing the complete dentures, the free-way space was more than 5 mm and it was mainly the mandibular teeth that were displayed during speaking. The maxillary teeth were not displayed even during smiling (Fig. 3). The lower third of the face was too short when the patient closed the mouth when wearing the complete dentures, revealing more than 10mm between the vertical rest position and the vertical dimension of occlusion. The occlusal plane also needed to be parallelised to the bi-pupillary and Camper's planes. The centric occlusion position was not repeatable.

Prosthetic goals

In order to improve the aesthetic, phonetic and functional aspects with definitive restorations, we decided to:

- improve the upper lip support,
- increase vertical dimension of occlusion,
- improve exposure of the maxillary teeth,
- reduce exposure of the mandibular teeth,
- improve occlusal plane parallelism to the bi-pupillary and Camper's planes,
- establish a stable and repeatable occlusal position,
- verify parameters during adaptation time.

Treatment plan

In order to manage all of the prosthetic goals that may have effected important changes in patient function and adaptation, it was decided to divide the treatment plan into different steps:

1. Restoration of all of the prosthetic parameters with new temporary complete dentures.
2. Verification of all of the parameters during patient adaptation time.
3. Fabrication of two copies of the dentures that could be used to register implant impressions and the inter-arch position in order to retain all of the data required for finalisation.
4. Construction and delivery of the definitive rehabilitation.

Clinical and laboratory procedures

Preliminary impressions

In the first appointment, two alginate impressions were taken (normal-setting alginate Neocolloid, Zhermack)

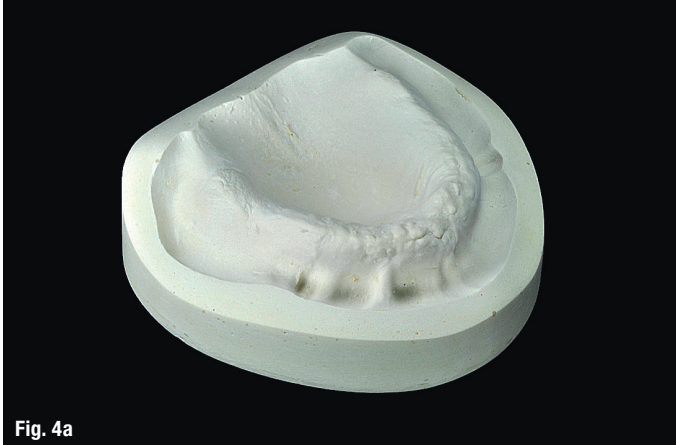

Fig. 4a

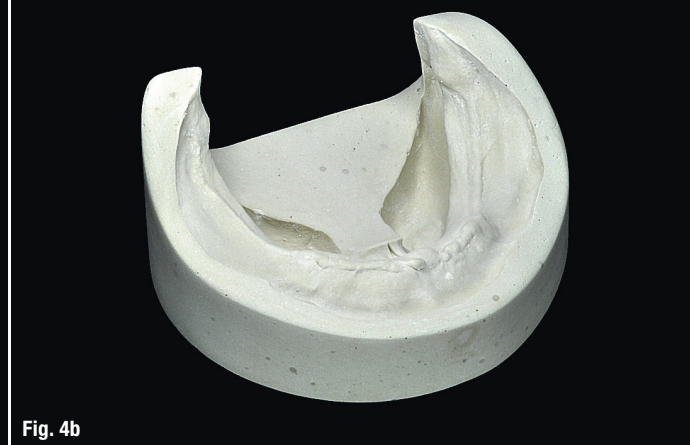

Fig. 4b



Fig. 5a

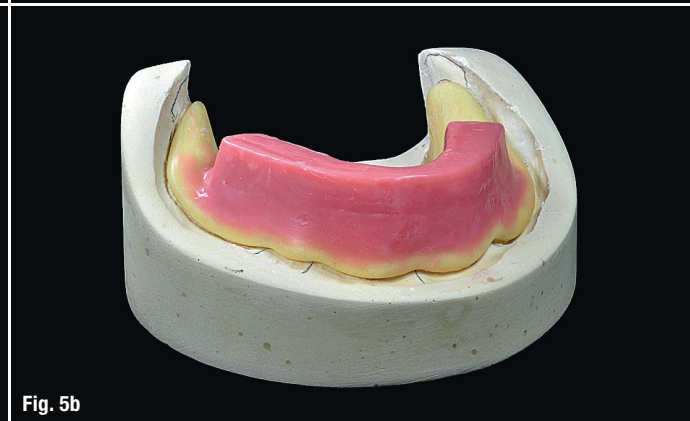

Fig. 5b

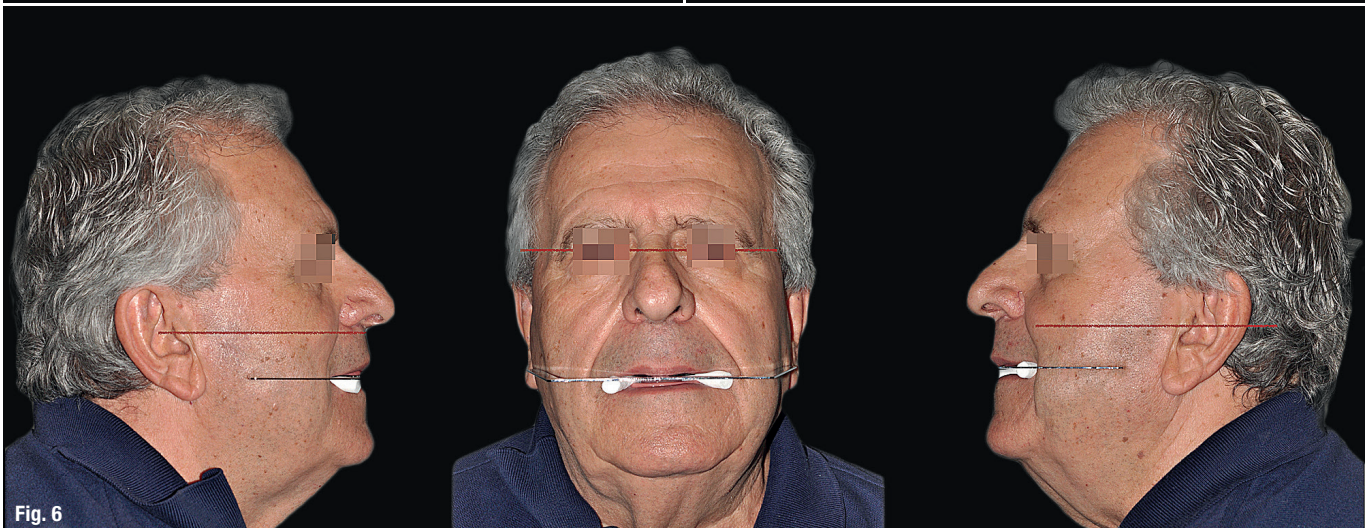


Fig. 6

Figs. 4a & b: Preliminary models. **Figs. 5a & b:** Individual trays. **Fig. 6:** Occlusal plane setting.

using Schreinemakers trays. In order to stabilise and support the impression material, a moulding wax was adapted to their surface (Cera Azzurrina Morbidissima, Zeta). The adhesive for the alginate was applied to the surface of the prepared trays (Fix Adhesive, Dentsply Sirona).

The first impressions were taken according to a two-phase technique and a high-consistency alginate was used. After removing the impression, it was prepared by removing the undercuts in order to support relining with a low-viscosity alginate. The adhesion between the alginates was promoted by drying the first material.

Preliminary models and tray construction

Preliminary models were poured using Class III plaster (Elite Model, Zhermack) according to the manufacturer's instructions (Figs. 4a & b).

Once the models had been squared and finished, the extension of the individual impression trays was drawn. Undercuts were eliminated with Tenasyle wax (Imadent) and models isolated using Separating Fluid (Ivoclar Vivadent). The trays were prepared with a self-curing resin (SR Ivolen, Ivoclar Vivadent). The trays were finished to a thickness of 2 mm, except for the borders in the sublingual areas and the retro-zygomatic areas, where they were about 3–4 mm thick.

On the basis of the trays, the wax rims were melted simulating the dental arches' volume in order to aid the clinician in taking a closed-mouth-impression. For the lower base, Tenasyle wax was used and Moyco Beauty Pink X-Hard Wax (Moyco Industries) for the upper base. For the upper wax rim, the average of distance between the vestibular sulcus and the incisal edge was set to

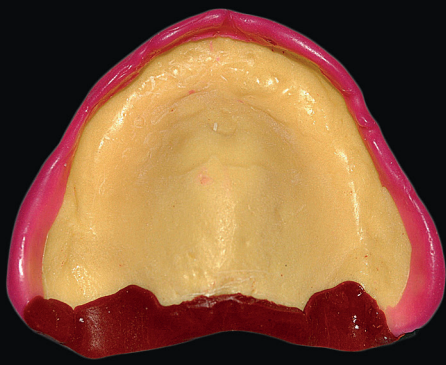

Fig. 7a

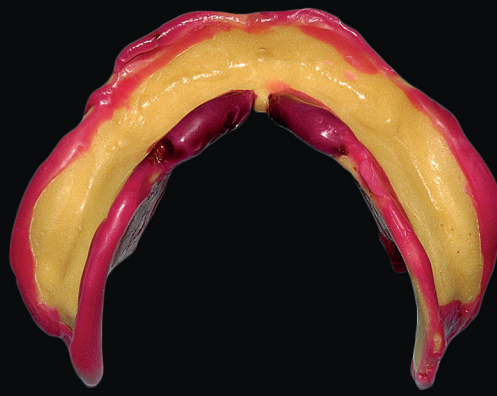

Fig. 7b

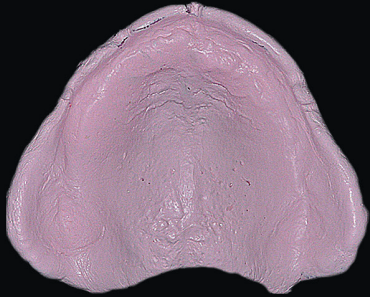


Fig. 8a

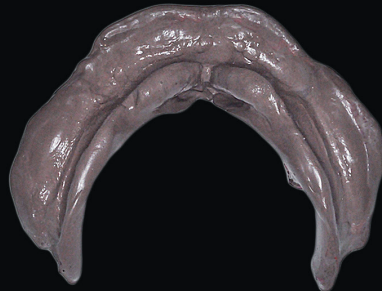

Fig. 8b

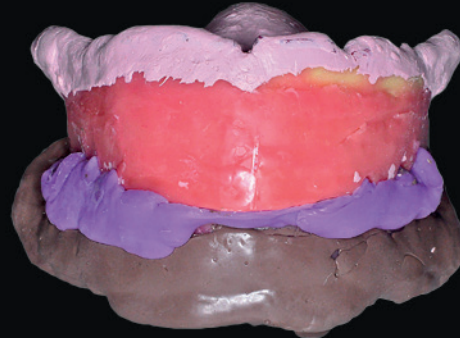

Fig. 9

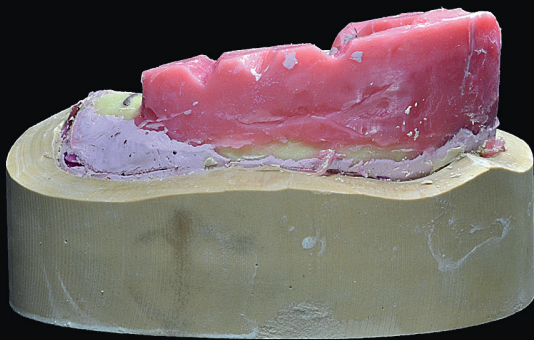


Fig. 10a

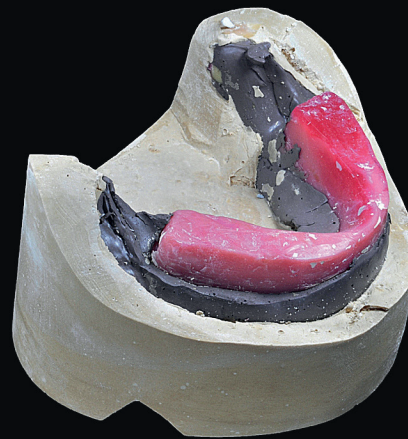

Fig. 10b

Figs. 7 & 8: Bordering and definitive impressions. **Fig. 9:** Definitive impressions and centric relation registration. **Figs. 10a & b:** Positioning models in the articulator.

22mm at the level of the central incisors and 18 mm at the molar region. The incisal edge of the upper wax rim was positioned about 8–10mm forward of the centre of the incisive papilla, with an inclination of about 20° on the sagittal plane.

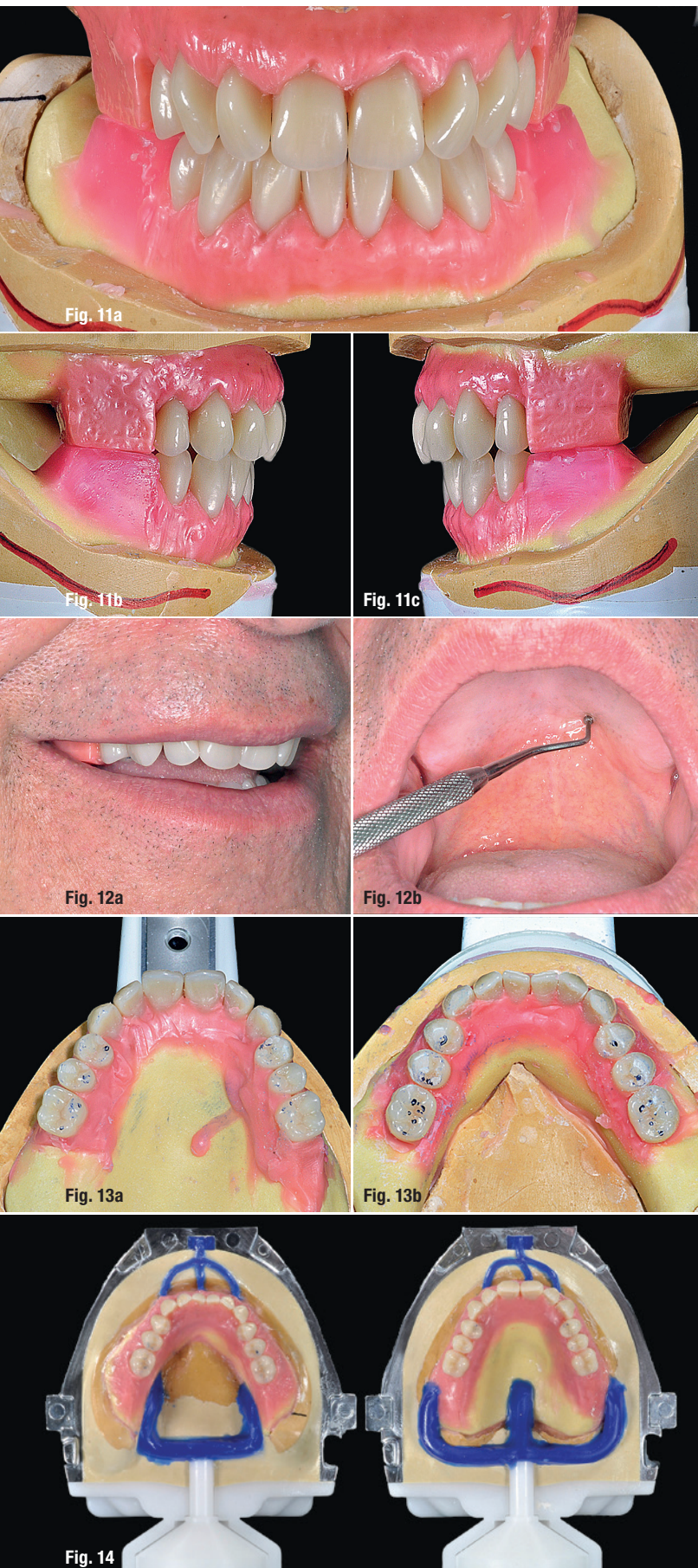
Regarding the lower jaw, the rim was prepared maintaining a distance between the labial sulcus and the incisal edge of 18mm in the anterior and posterior regions. It was positioned corresponding to the mandibular alveolar ridge and tilted about 8–10° on the sagittal plane. The rims were realised simulating an arch in accordance with the anatomical trend of the residual ridges. Moreover, they were taken to a thickness of about 2–4mm in the incisal region and about 8–10mm in the molar region. Finally, the lower wax rim was extended posteriorly to the point where the ramus of the mandible be-

gins to curve up. The posterior limit of the upper wax rim was set to the mesial limit of the maxillary tuberosity (Figs. 5a & b).

Closed-mouth definitive impressions

The stability and the adaptation of the impression trays were checked. After that, the border length and thickness were verified using a silicone-based paste (FIT CHECKER II, GC).

In the next phase, evaluating the support of the patient's lips, the rims were adapted. The upper rim was orientated parallel to the Camper's plane and the midline was recorded on it. Thus, phonetic tests were performed ("f", "v" and "s") in order to establish the position of the anterior teeth, and to allocate the space between the upper and lower planes. The vertical di-



mension of occlusion was also determined.¹⁰ Finally, the centric relation was recorded (Fig. 6).

At this point, the trays were trimmed with different thermoplastic sticks (ISO FUNCTIONAL, GC and Impression Compound, Red, Kerr Italia) in order to determine a selective pressure in the inner peripheral seal. The patient was also trained to activate the muscles of lips, cheeks and tongue to define three-dimensionally the extension of the prosthetic margin. During the trimming phase, owing to the ability to bring the rims into contact, the patient could complete swallowing movements. Furthermore, the repeatability of the centric occlusion position was verified several times using this approach.

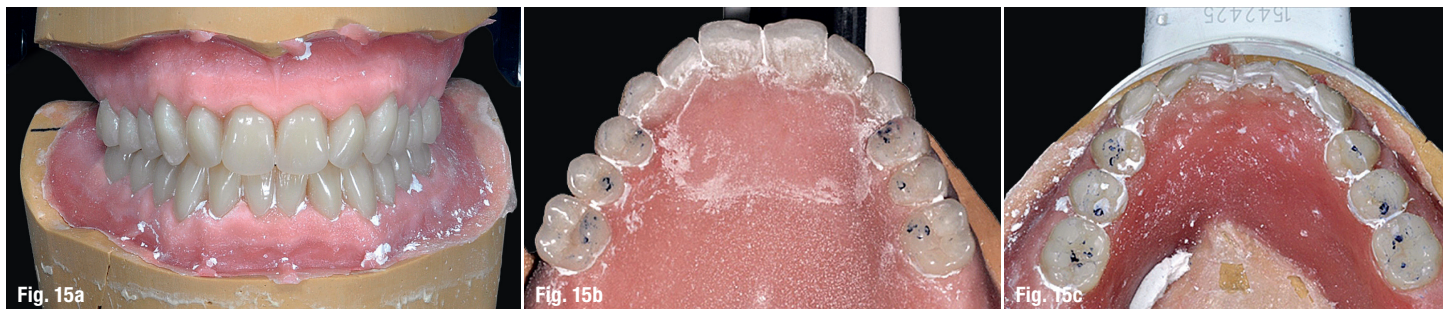
Before taking the impression, the external areas of the border were released to avoid hyperextension related to the overlap of the impression material. These procedures did not affect the areas of inner seal. The upper tray was drilled to facilitate the outflow of the impression material. The final impressions were recorded with zinc oxide paste for the upper arch (Luralite, Kerr Italia) and polysulphide material for the lower arch (Permlastic Light Bodied and Regular, Kerr Italia; Figs. 7 & 8).

Finally, the vertical dimension of occlusion and centric relation were confirmed. Thus, a face-bow transfer was also indicated (UTS 3D, Ivoclar Vivadent) set according to the Camper's plane. In order to complete information about the size and shape of the anterior teeth, the Form-Selector (Ivoclar Vivadent; Fig. 9) was used.

Functional impressions were poured with Class IV plaster (Vel-Mix Classic Die Stone, Pink, Kerr Dental Laboratory Products) maintaining the peripheral border. The plaster was mixed under vacuum with distilled water and following manufacturer's instructions. Before removing the impressions, models were mounted in the articulator (Stratos 300, Ivoclar Vivadent) using the face-bow (Figs. 10a & b).

Before removing the trays from the master models, the length and position of the rims were recorded using a silicone key. The models were then isolated using Separating Fluid and the undercuts rectified using a resilient resin (Flexacryl Soft, Lang Dental Manufacturing), being careful to avoid flow to the fornix. Once the resin was polymerised, the base was prepared using Ivolen. The anterior teeth were set using the information recorded from the rims (Figs. 11a–c).

Figs. 11a–c: Anterior tooth set-up. **Figs. 12a & b:** Aesthetic evaluation and posterior seal probing. **Figs. 13a & b:** Occlusal contacts before polymerisation. **Fig. 14:** Potsdam ditching and flasking preparation.



Figs. 15a–c: Post-polymerisation occlusal grinding.

Tooth set-up

This appointment was focused on the evaluation of the aesthetics, phonetics, vertical dimension of occlusion and repeatability of centric relation. The patient observed and accepted the set-up with a member of his family. It was decided to create two embrasures on the anterior teeth in order to reduce incisal edge convexity. The posterior seal area was evaluated by probing the compression of the tissue using a ball condenser (Figs. 12a & b).

Temporary complete denture construction

The posterior teeth were mounted using a static laser (CANDULOR). Posterior tooth contacts were obtained according to lingualised occlusion concepts and the Gerber occlusal scheme (Figs. 13a & b).¹¹

Curing and finishing the complete dentures

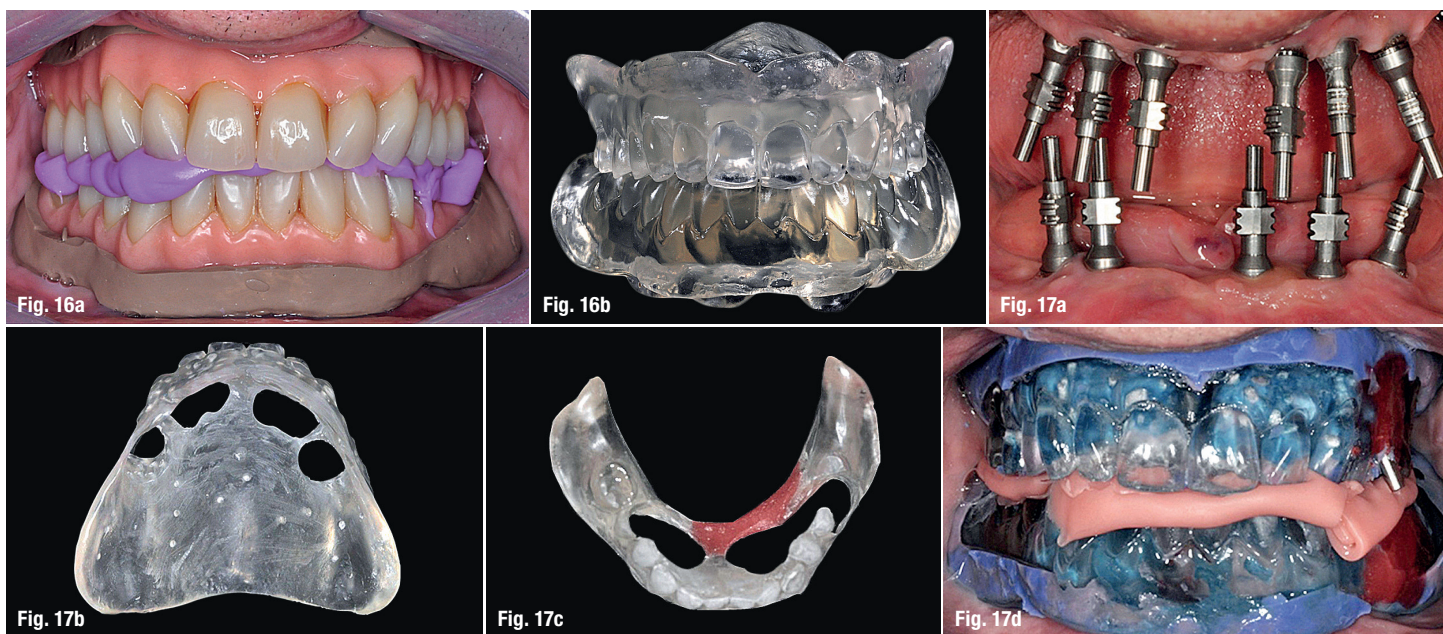
The posterior seal area was ditched on the model using the clinical information of the different levels of compression of the tissue. The prostheses were waxed for

deposit. The polymerisation was performed using the IvoBase system (Ivoclar Vivadent), a fully automatic injection system. The shrinkage of the specific PMMA resin is fully compensated for during polymerisation, thus obtaining the most accurate denture base adaptation (Fig. 14).

After polymerisation, the prostheses were replaced into the articulator and the occlusal grinding was performed in order to maintain all of the occlusal contacts that were established before polymerisation (Figs. 15a–c).

Temporary denture delivery and follow-up

Upon delivery, the prostheses were placed into the oral cavity and left to adapt for 10 to 15 minutes with the patient clenching two cotton rolls placed bilaterally between the arches. After that, the adaptation of the bases was checked with FIT CHECKER II. The patient was instructed to perform functional movements and to speak. The length and thickness of the borders were verified with the silicone-based paste and corrected when it was required.



Figs. 16a & b: Information registration and realisation of denture copies. **Figs. 17a–d:** Definitive impression registration.

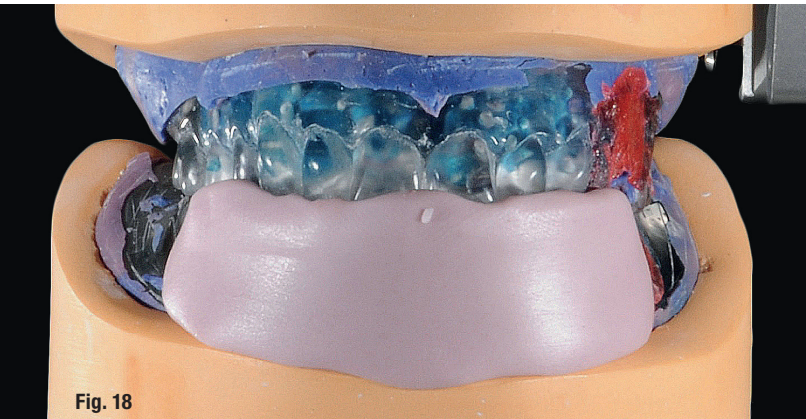


Fig. 18

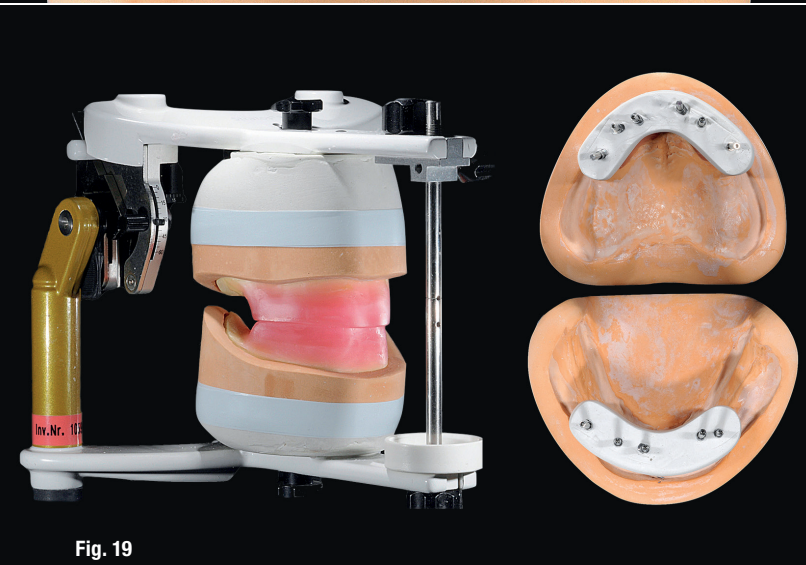


Fig. 19

Fig. 18: Silicone key recording tooth position. **Fig. 19:** Occlusal keys and pick-up stone position.

Finally, the occlusion was checked, revealing bilateral symmetrical contacts. The patient was instructed on managing and cleaning the complete dentures in the initial days. Follow-up visits were planned at 24 hours and one and two weeks after delivery. The patient reported a rapid adaptation to the new dentures, only a few points of pressure caused ulcerating lesions. Phonetics and stability were improved after the treatment. Control appointments were conducted in the weeks after delivery and excellent levels of adaptation were reported, regarding both aesthetic and phonetic aspects.

Fabrication of denture copies

The successful adaptation to the temporary dentures confirm that all the parameters (vertical dimension of occlusion, centric relation, aesthetics and phonetics) could be maintained in the definitive restoration. It was decided to fabricate copies of the temporary dentures and to use them as a closed-mouth tray. The temporary bearing bases were rebased with a polysulphide impression material (Permlastic Light). The intermaxillary position was registered using a bite registration silicone

(Occlufast, Zhermack). The copies were obtained using self-curing transparent resin (ProBase, Ivoclar Vivadent; Figs. 16a & b).

Closed-mouth implant impression registration

After the implant surgery, a multi-unit abutment was placed. At the impression appointment, pick-up copings were attached to the implant abutments. Denture copies were prepared in order to be positioned with perfect adaptation to the oral mucosa.

Finally, definitive impressions were taken with polyether material (Permadyne and Impregum, 3M ESPE). The intermaxillary position was as registered after removing all of the implant pick-up copings that could determine occlusal interferences. A face-bow was also taken before removing the maxillary impression (Figs. 17a–d). Master models were prepared using a removable soft resin to reproduce peri-implant tissue. The impressions were poured in Class IV plaster, and the obtained models were placed in the articulator using the face-bow measurements.

Before removing the impressions from the master model, a silicone key was prepared in order to record the position of the anterior teeth (Fig. 18). Two occlusal bases were prepared with wax rims in order to verify the intermaxillary position. Additionally, implant pick-up copings were splinted using stone (Elite Arti, Zhermack; Fig. 19).

Implant and inter-arch position check

The intermaxillary position was confirmed, but the upper stone key was fractured during screwing procedure. Thus, it was splinted with stone, and after repositioning the implants, replaced on the model. The implants' position was definitely confirmed (Figs. 20a–d).

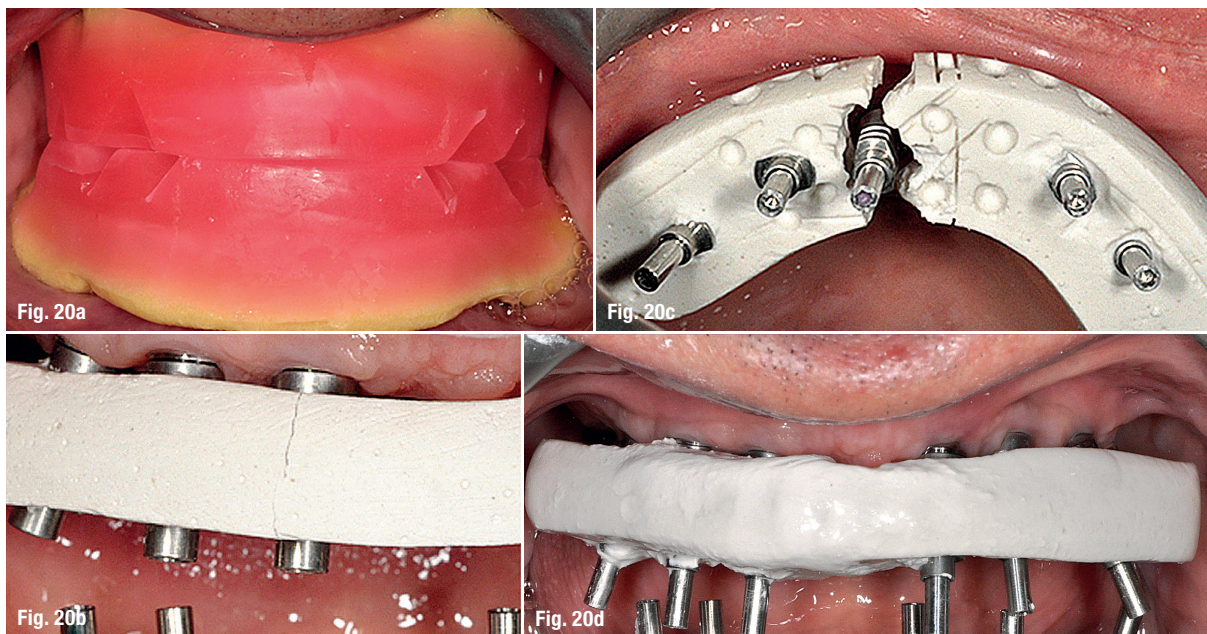
Tooth set-up

The tooth set-up was performed according to the information of the denture copies, using the silicone key. The complete set-up was evaluated with the patient and all occlusal, aesthetic and phonetic aspects confirmed. The tooth set-up approved during the patient try-in was sent to the laboratory for framework design.

Fixed or removable?

Depending on the discrepancy between the position of the clinical crown and the alveolar ridge contour in the bucco-oral dimension, compensation with the denture base of a removable reconstruction may be necessary.¹² However, for a fixed complete denture, the clinical crown should ideally be at the soft tissue level of the alveolar ridge. For this solution, minimal bone resorption and a limited inter-arch space with an optimal tooth–lip relationship are required (Fig. 21).¹³

These parameters, mainly determined by tooth position and the amount of residual alveolar bone, have to



Figs. 20a–d: Occlusal check and implant pick-up coping splinting.

be considered before planning a maxillary implant-supported restoration.¹⁴ In this case, the patient was informed before implant surgery that his dentition was to be restored with fixed restorations in both arches. However, our prosthetic evaluation determined that it was not feasible because of the horizontal distance between the teeth and implants.

The patient was informed about the advantages and disadvantages of fixed or removable prostheses. Moreover, a tooth set-up was prepared without a buccal flange in order to analyse potential problems regarding facial support, phonetics, aesthetics and hygienic access. With the patient's consent, it was decided to realise a removable solution for the maxilla and a fixed restoration for the mandible.

Clinical case finalisation

The implant overdenture was prepared maintaining the insertion path perpendicular to the occlusal plane. Two bars were fabricated in order to reduce the volume required for primary and secondary frameworks. In both bars were placed two different ball retentive systems (Rhein'83). The mesial one was mini, and the distal one of normal size. This kind of solution could guarantee enough retention for the restoration and durability of the attachment system. Moreover, owing to the number and position of the implants, complete palatal support was reduced, including the maxillary tuberosities as determinant support areas (Figs. 22a & b).

Delivery and follow-up

Definitive restorations were realised maintaining all of the prosthetic parameters of the temporary restoration.

Patient adaptation was excellent concerning the aesthetic, phonetic and hygienic parameters, despite at the beginning of treatment having been oriented to a max-

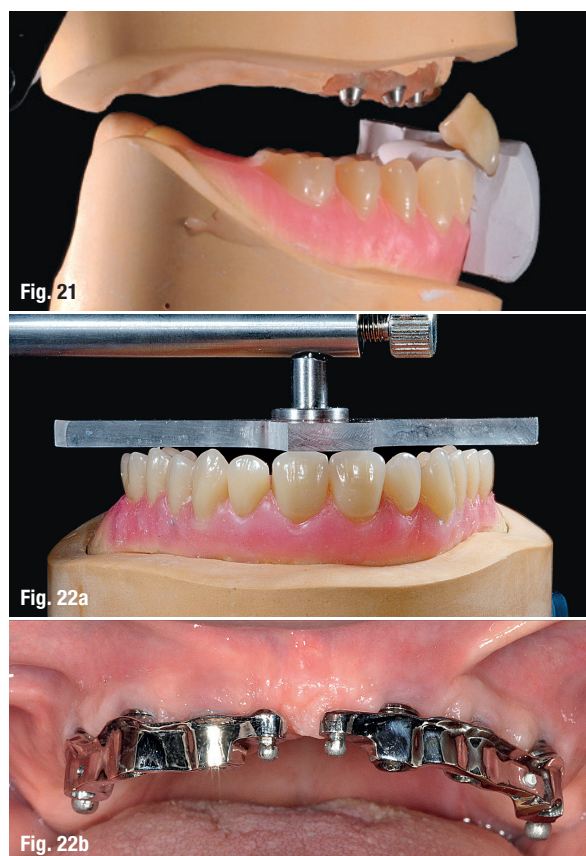


Fig. 21: Space evaluation. **Figs. 22a & b:** Implant overdenture framework fabrication and try-in.

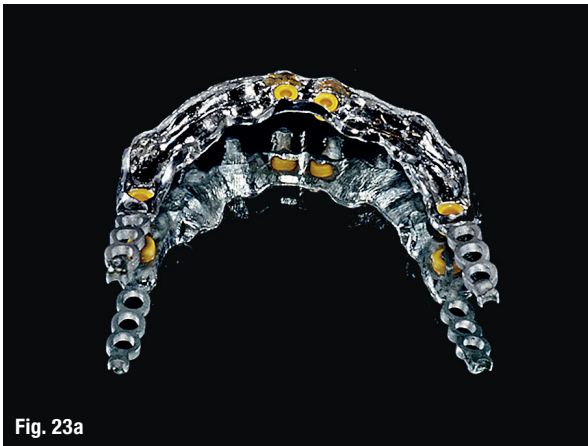

Fig. 23a

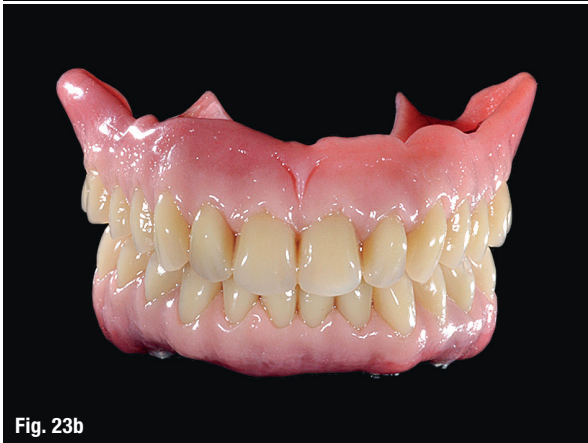

Fig. 23b

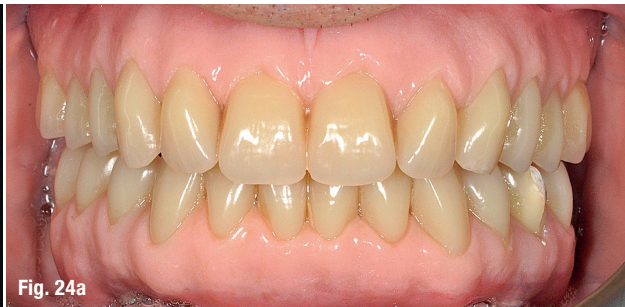

Fig. 24a

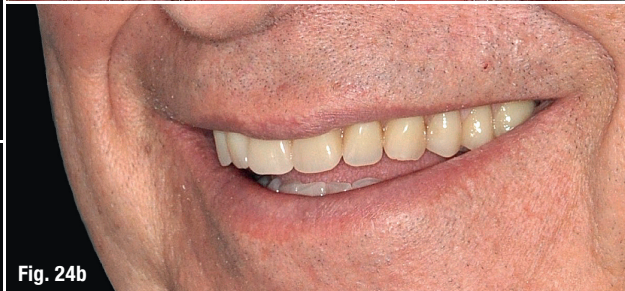

Fig. 24b

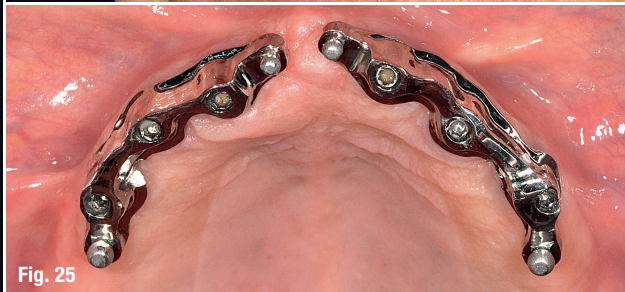


Fig. 25

Figs. 23a & b: Definitive restorations. **Figs. 24 & 25:** Three-year follow-up.

illary fixed rehabilitation (Figs. 23a & b). The prosthesis-bar-supported solution could guarantee enough retention and stability to the patient in both functional and psychological aspects. At the three-year follow-up, the tissue was healthy owing to the patient's hygiene compliance (Figs. 24 & 25).

Discussion and conclusion

While this clinical case reported good patient adaptation to the definitive restorations, modifying the initial treatment plan can be a challenge, especially when patients chose to be treated with implants because they are maladapted to removable solutions. As reported in this case, with a sufficient number of implants of adequate length, the superstructure can be purely implant-supported in construction. However, when bone is severely resorbed,¹⁵ the distance between the implants and the incisal edge position cannot be solved with a fixed restoration because of the lack of lip support or poor phonetics.

Current criteria for planning and deciding on treatment have been reported in literature and are considered a fundamental guide for establishing the treatment plan.^{16,17} This case treatment would emphasise

the importance of not promising the patient a fixed maxillary restoration until the final wax trial has been accepted.¹⁸⁻²⁰



Acknowledgements

Thanks to Marco Vannini and Rhein'83 for their support and for sharing their experience with us in solving this clinical case.

contact

Dr Alessio Casucci

Private practice
Via Bari 31
53045 Montepulciano
Italy
alessio.casucci@gmail.com

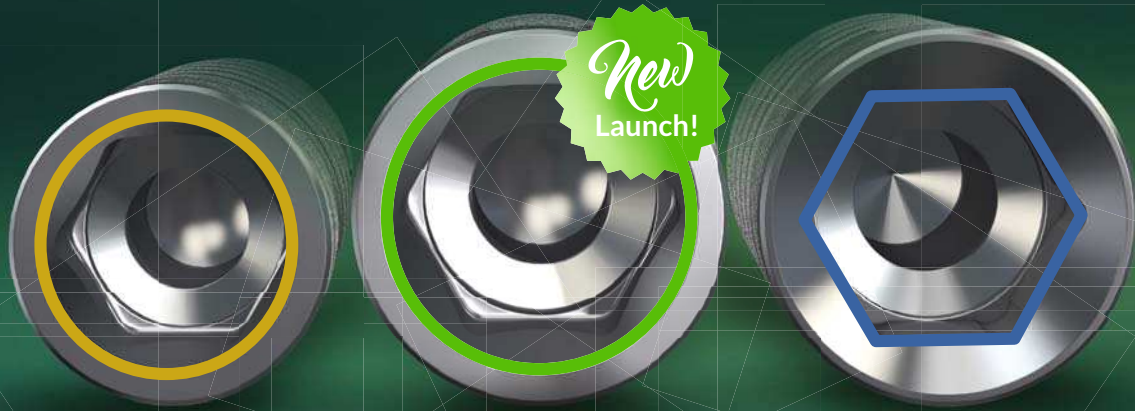

Alessandro Ielasi

Dental lab Ielasi
Snc, Via Mazzella Luigi
80077 Ischia
Italy
alessandrielasi@libero.it

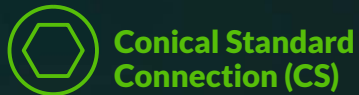


ONE **neO** MULTIPLE OPTIONS



The Complete **neO** Implant Family

With more options to choose from, the NeO family now includes 3 connections:



Each connection features a dedicated restoration line



www.alpha-bio.net/neo