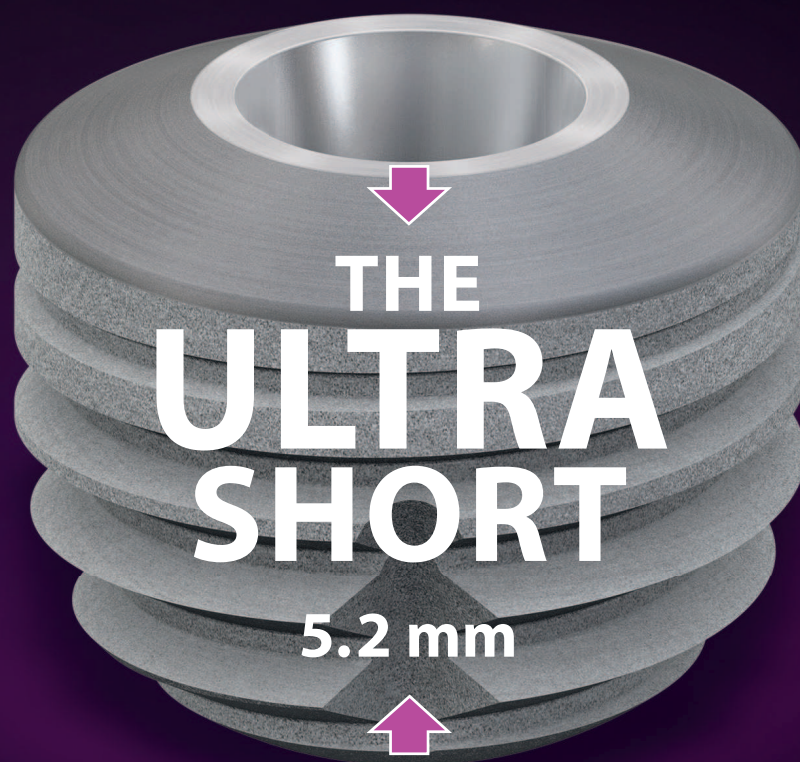

implants

international magazine of oral implantology



research

L-PRF in intraoral applications

case report

Computer-assisted implant
rehabilitation of tumour patients

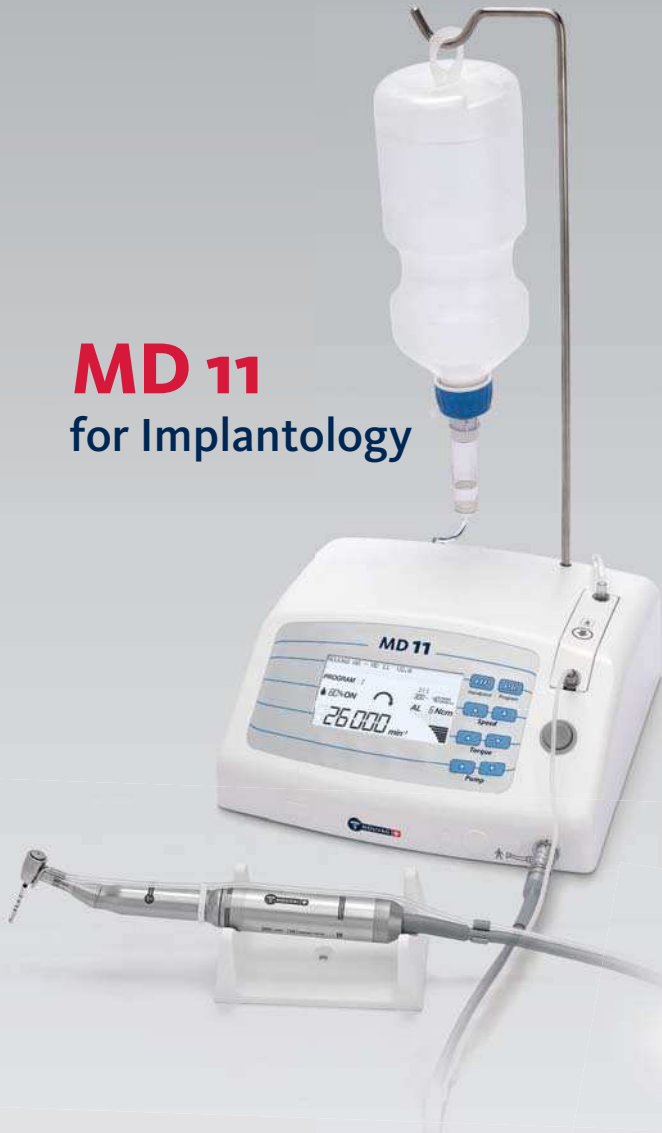events

1st Future Congress in Dental Implantology

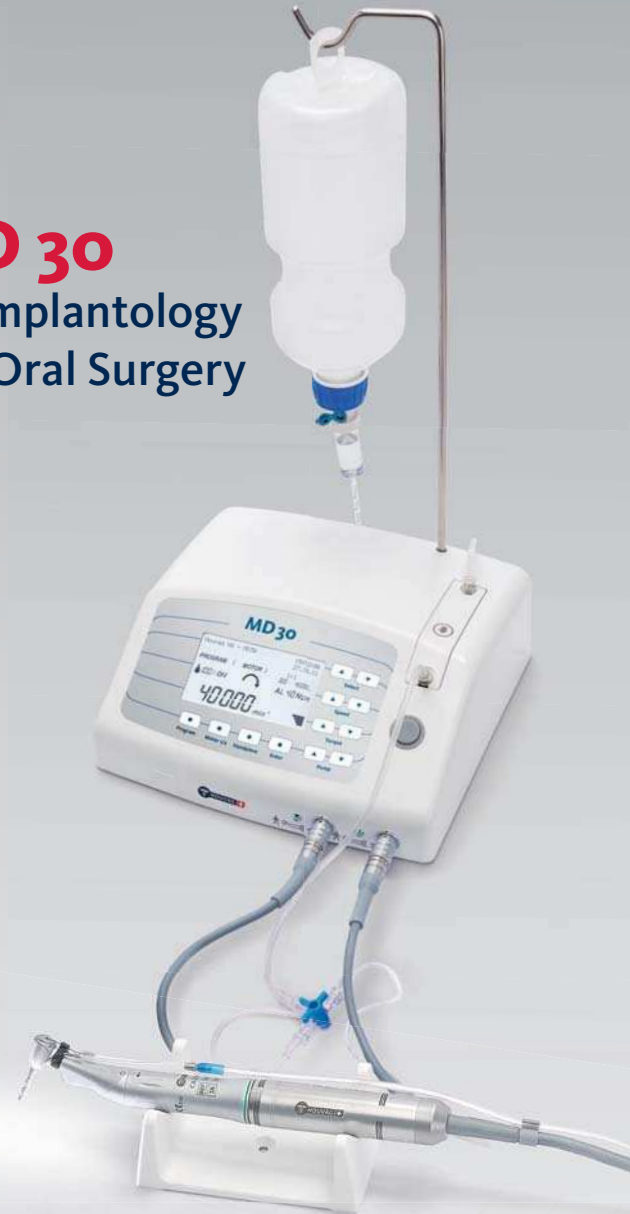

We talk implantology

MD 11
for Implantology



MD 30
for Implantology
and Oral Surgery



- **Easy** | Simple device setup
- **Strong** | Powerful and smooth motor
- **Reliable** | High quality finish



Scan me to be linked to the
Nouvag contact form. ▶



NOUVAG AG · Switzerland
info@nouvag.com · www.nouvag.com

Dr Rolf Vollmer

First Vice President and Treasurer of DGZI



How will we get **better?**— **Visions** in Implantology

Dear colleagues,

Under the premise of constant progress, the DGZI strives to stay on the pulse of current affairs for the years to come. To maintain our strong position, we intend to adapt educational structures to the most modern options and conditions. This includes curricula and training of dental technicians and congress organisation.

According to the principle “Visions in Implantology”, the DGZI’s 1st Future Congress for Dental Implantology will raise new questions, as well as try to provide answers and point out new directions through the interaction of participants, speakers and the industry. This new content claim is also reflected in an entirely new organisational concept. These modifications aim at future orientation, organisational modernity, content attractiveness and at a new mode of presenting perspectives combining viewpoints of science, practice and industry. In this way we intend to achieve a new level of interaction with practicing colleagues.

The 1st Future Congress for Dental Implantology will especially be dedicated to the question of what implantology might look like in five or maybe ten years. Ultimately, apart from addressing scientific and technological aspects, it will also focus on strategic questions with regard to the future implantological practice. The DGZI

will thus prove once more its importance and appeal also regarding the 50th anniversary of its foundation in 2020. Renowned national and international speakers, friends from international specialist societies, industry partners and of course the participants from Europe, Asia and the Arab countries will create and experience an exceptional, innovative educational event.

Save the date

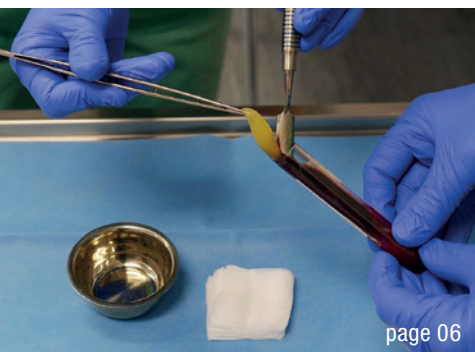
1st Future Congress for Dental Implantology
28–29 September 2018 in Düsseldorf, Germany

On behalf of our board of directors we would cordially like to invite you, already today, to the DGZI’s 1st Future Congress for Dental Implantology (48th international annual congress) on the 28 and 29 September 2018 at the Hilton Hotel Düsseldorf in Germany. Save the date, get excited and let yourself be surprised.

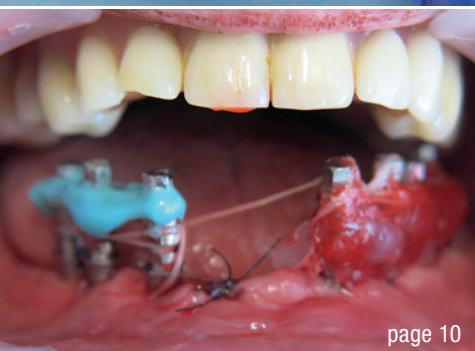
Yours,

A handwritten signature in black ink, appearing to read 'Dr Rolf Vollmer'.

Dr Rolf Vollmer



page 06



page 10



page 44

Cover image courtesy of bredent medical GmbH & Co. KG
www.bredent-medical.com



editorial

How will we get **better?**—**Visions** in Implantology 03
Dr Rolf Vollmer

research

L-PRF in different intraoral **applications** 06
Prof. Nelson R. Pinto, Dr Andy Temmerman, Ana B. Castro,
Simone Cortellini, Prof. Dr Wim Teughels & Prof. Dr Marc Quiryren

case report

Immediate loading in heavy **smokers** 10
Dr Dr Branislav Fatori & Dr Inge Schmitz

Computer-assisted **implant rehabilitation** of tumour patients 16
Ioannis Papadimitriou, Dr Petros Almagout,
Dr Erich Theo Merholz & Dr Stefan Helka

Fixed or removable? That is the **question.** 24
Dr Alessio Casucci & Alessandro Ielasi

industry

Treatment of **periodontal** and **peri-implant** inflammation 34
Dr Vincenzo Iorio-Siciliano

interview

Peri-implantitis **prevention** 40

events

Managing **aesthetic** challenges 42

Visions in Implantology 44

obituary

In memory of Prof. Dr Dr Hans L. Grafelmann 46
Dr Georg Bach

news

manufacturer **news** 36

news 48

about the publisher

imprint 50



ORAL RECONSTRUCTION
FOUNDATION



ORAL RECONSTRUCTION GLOBAL SYMPOSIUM 2018

26 - 28 APRIL 2018 | ROTTERDAM, NETHERLANDS

THE FUTURE OF THE ART
OF IMPLANT DENTISTRY

JOIN US AND
REGISTER NOW -
WE LOOK
FORWARD TO
MEETING YOU!

HIGHLIGHTS

Emphasis on clinical experience in tissue management, treatment concepts,
ceramic implants and digital workflow | Interactive case discussions
Exciting and exuberant city | Expert-guided hands-on workshops
Well-known speakers and state-of-the-art lectures | King's Day party celebration

SCIENTIFIC COMMITTEE

Dr. Edward P. Allen | Dr. Ben Derksen | Prof. Dr. Irena Sailer
Prof. Dr. Mariano Sanz | Dr. Alex Schär | Prof. Dr. Frank Schwarz

camlog

Founding Partner

Information and registration:
www.orfoundation.org/globalsymposium



L-PRF in different intraoral applications

Part I: Preparation of L-PRF

Prof. Nelson R. Pinto¹, Dr Andy Temmerman², Ana B. Castro², Simone Cortellini², Prof. Dr Wim Teughels² & Prof. Dr Marc Quirynen²

¹ Department of Periodontology and Oral Implantology, Faculty of Dentistry, Universidad de Los Andes, Santiago, Chile

² Department of Oral Health Sciences, Section of Periodontology, KU Leuven & Dentistry, University Hospitals, KU Leuven, Leuven, Belgium

Favourable wound healing has always been a major quest in dental surgery. It is a concern in healthy as well as compromised patients. In an effort to improve and accelerate healing of both hard- and soft-tissues, substitutes including growth factors and biomaterials have been traditionally employed. Membranes were also introduced to separate tissues.

Recent research clearly indicates that L-PRF (leukocyte- and platelet-rich fibrin, a second generation of platelet concentrates) significantly enhances wound healing in

both soft- and hard-tissues. Evidence now supports the assertion that this has the potential to replace the above mentioned substitutes in many situations.

Clinical procedures benefit from recent advancements with platelet concentrate protocols including, but not limited to: soft tissue healing, plastic periodontal surgery, gingiva enlargement, MRONJ, regeneration of infra-bony defects, ridge preservation, sinus augmentation, immediate implant placement and implant osseointegration itself.

An added benefit is that these platelet concentrate protocols offer significantly lower cost treatment solutions to our patients, due to the fact of their ease of use and inexpensive preparation.

Major indications for the use of L-PRF are

- Implant coating
- Wound healing
- Ridge preservation
- Immediate implant
- Floating implant
- Soft tissue R
- MRONJ
- Sinus R
- Infra-bony R

Major indications

Our basic knowledge of the biologic mechanisms of both soft- and hard-tissue healing has increased exponen-

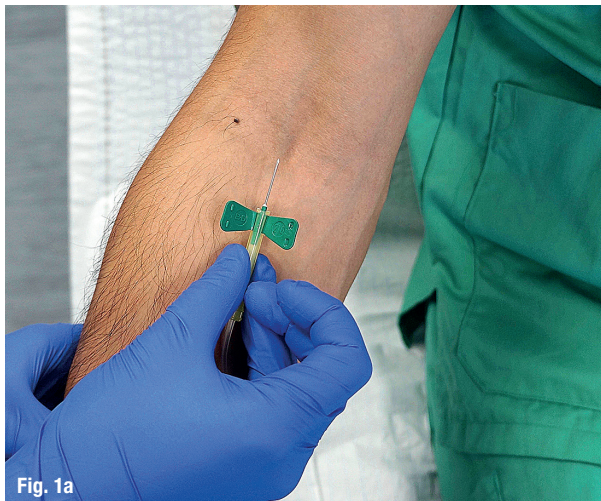

Fig. 1a

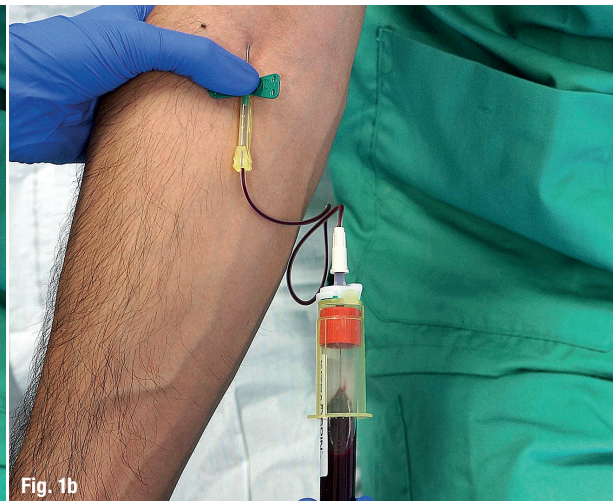

Fig. 1b

Figs. 1a & b: Venipuncture and blood collection using 21 G butterfly needle and 9 ml red cap tubes.



Fig. 2

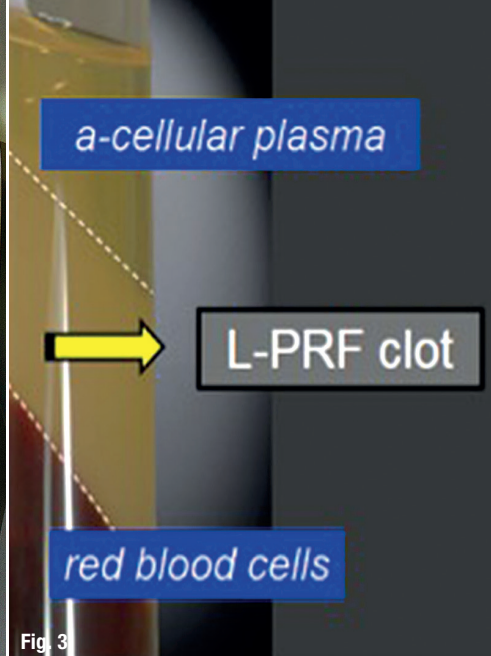


Fig. 3

Fig. 2: Centrifugation at 408 g RCF, (2,700 rpm) with IntraSpin™ centrifuge. **Fig. 3:** L-PRF clot in tube; clear separation: red blood corpuscles (RBCs) at the bottom, PPP (platelet-poor plasma) on the top, and L-PRF fibrin clot in the middle.

tially in recent years. Advancements in autologous platelet concentrate protocols, profoundly impact the way we treat patients today.

Thanks to these advancements we can now introduce a new level of treatment options to our daily practice, from periodontal procedures to regeneration of bone defects and even implant osseointegration itself.

Step by step approach for the preparation of L-PRF

Protocol for preparation of L-PRF clots

- Venipuncture: With a 21 G butterfly needle collect up to eight 9ml red cap tubes of blood (Figs. 1a & b).
- After the first two tubes of blood are collected, immediately place them into the IntraSpin™ centrifuge,

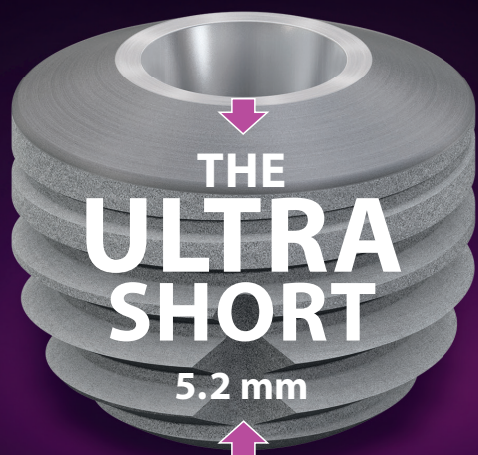AD

New options!

The ultra-short implant for optimum exploitation of the available bone



| Primary stable | Precise | Physiological



The SKY® implant system



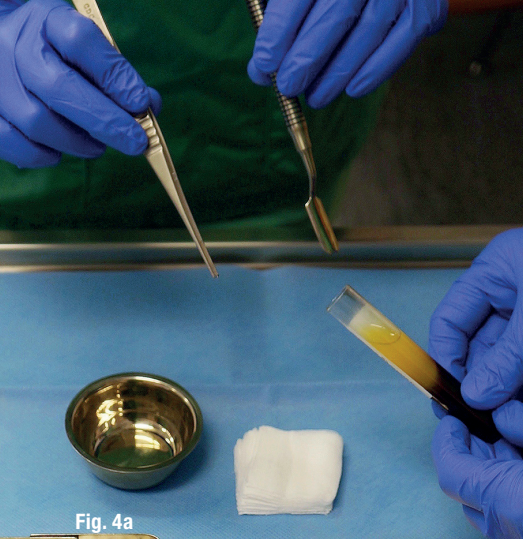


Fig. 4a

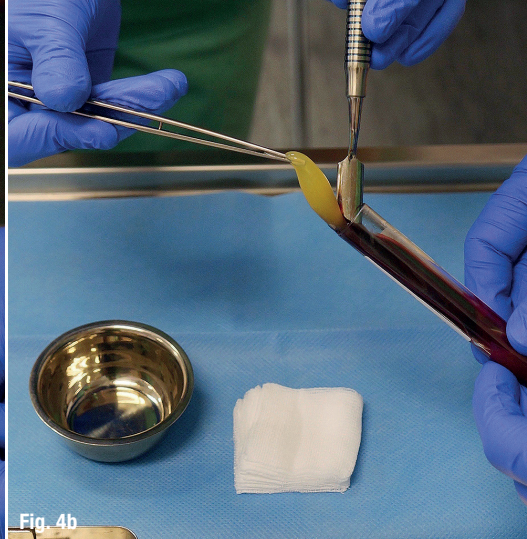


Fig. 4b

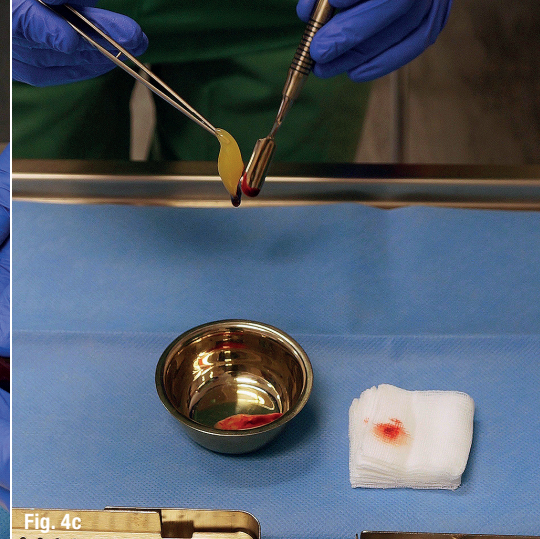


Fig. 4c




Fig. 5

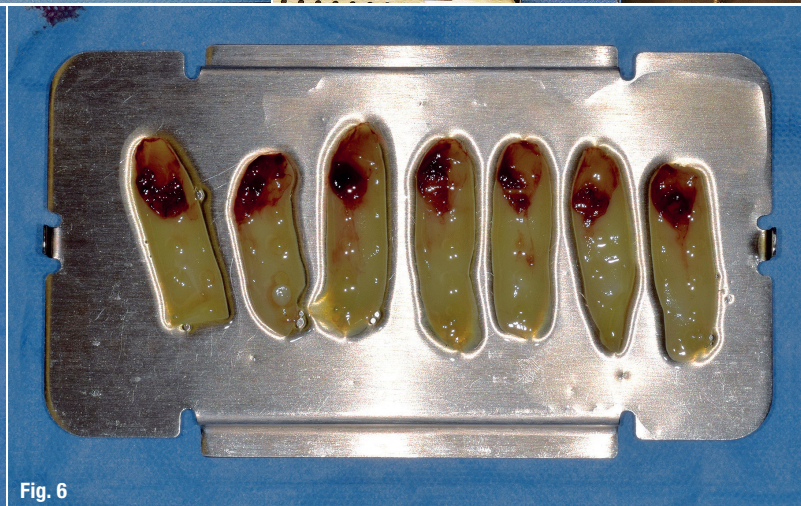

Fig. 6

Figs. 4a–c: Remove clot from tube and separate clot from red blood cells. **Fig. 5:** Specially designed kit (Xpression™ box) to compress L-PRF clots into L-PRF membranes with a consistent thickness of 1 mm. A piston and cylinder assembly (right) can be used for the creation of L-PRF plugs, suitable for filling extraction sockets. **Fig. 6:** L-PRF membranes after gentle compression: the red area of the membrane represents the face side where most leucocytes, platelets and stem cells are concentrated.

opposite to each other to ensure the centrifuge is properly balanced. Close the cover and set the timer to one minute. Press START and allow the centrifuge to run for one minute, it will then come to a full stop and the cover will pop open. While it is spinning for one minute collect the third and fourth tube of blood from patient, and repeat the procedure for the other tubes.

- Centrifugation should be at 408 g (2,700rpm using the IntraSpin™ centrifuge, for at least 12 minutes (start timing after loading the centrifuge with the last two tubes, Fig. 2).
- After 12 minutes of centrifugation (for patient taking anti-coagulant medication up to 18 minutes are recommended) L-PRF clots are ready (Fig. 3).
- Take the fibrin clots out of the tubes and separate them from the red blood cells (Figs. 4a–c).

Protocol for preparation of L-PRF membranes

- Place fibrin clots in Xpression™ box for gentle compression by gravity (e.g. with light metal plate, Fig. 5).
- Five minutes later the L-PRF membranes are ready for use (Fig. 6).
- The viability for expressed membranes is 2.5 to 3 hours, as long as they are re-hydrated with exudate.

Protocol for preparation of L-PRF plugs

- Place fibrin clots in the small white cylinder of the Xpression™ box.
- Use the piston to carefully compress the clot, until holder is level to cylinder.
- The viability for expressed plugs is 2.5 to 3 hours, as long as they are re-hydrated with exudate.

Editorial note: To be continued in implants 2/18 with application approaches for open flap debridement and ridge preservation.

For further information visit: www.ENHD2018.be

contact

Prof. Dr Marc Quiryen

University Hospitals Leuven
Periodontology & Oral Microbiology
Kapucijnenvoer 7 blok a – box 7001
3000 Leuven, Belgium
Tel.: +32 163 32483
marc.quiryen@kuleuven.be





Shortest Implants – Longest History.

Think Short!

For more than 30 years Bicon® short implants are unchanged in clinical use. Recent scientific studies confirm clinical efficacy and show the profits to local bone in many cases.

According to the 11th European Consensus Conference (EuCC) 2016 in Cologne, provided the specific treatment parameters are observed, the use of short, angulated or diameter-reduced implants in sites with reduced bone volume can be a reliable treatment option, given the risks associated with the use of standard-dimension implants in combination with augmentation procedures.

More information:

Bicon Europe Ltd.

Dietrichshöhe 2, 55491 Büchenbeuren, Germany

Phone +49 (0)6543 818200, germany@bicon.com

www.bicon.de.com



bicon[®]
DENTAL IMPLANTS

Immediate loading in heavy smokers

Dr Dr Branislav Fatori & Dr Inge Schmitz, Germany

Today, numerous implant systems and many modifications thereof are available on the market, and it may be difficult to choose the optimal implant system for each patient. Immediate loading of dental implants is indicated when there is good primary stability and an appropriate occlusal load. To achieve a satisfactory result concerning implant survival, a number of factors have to be taken into consideration, such as the type and quality of the bone, bone density, placement and location of implants, the patient's motivation and, of course, financial constraints.

In this report of two cases of heavy smokers, we investigate from clinical, morphological, biomechanical and electron microscopy aspects the suitability of a new implant system (T.A.G. Dental), using a Toronto bridge construction. The term "Toronto prosthesis" or "Toronto bridge" originates from an extrapolation of the clinical and laboratory procedures introduced by Zarb in Toronto in Canada in the 1980s. The main advantage of the Toronto bridge is that it allows the correction of implant emergence profile and that the milled abutment is sufficiently

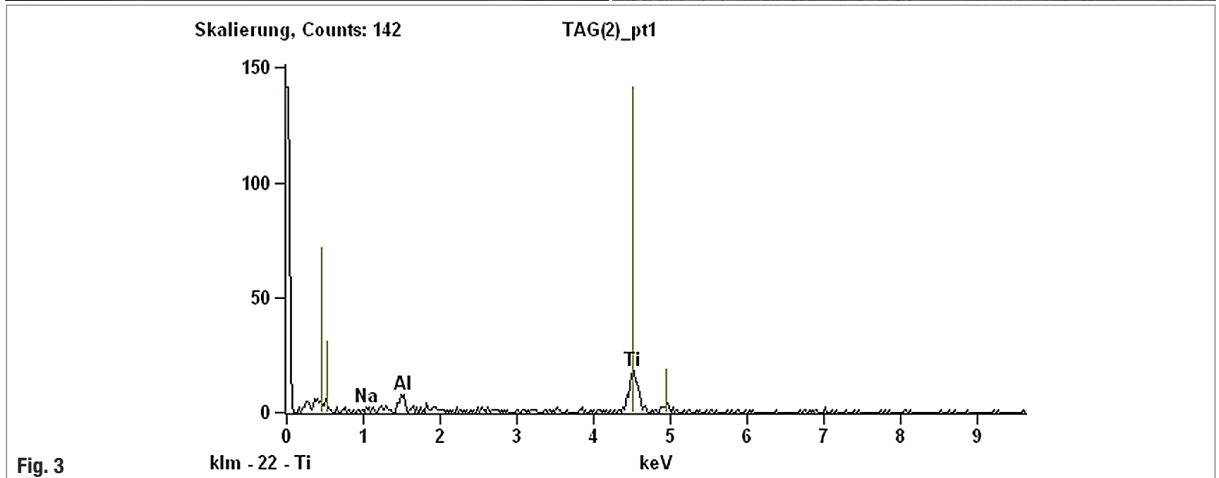




Fig. 1: SEM image, overview. Fig. 2: Detailed SEM image showing accurate design of the implant. Fig. 3: EDS of the implant surface (Case 1). Titanium (implant) and small amounts of aluminium (contaminations resulting from manufacturing processes) were detected.



Dentsply Sirona does not waive any right to its trademarks by not using the symbols or 3267114-USX1610 © 2016 Dentsply Sirona. All rights reserved.

Astra Tech Implant System®

Our world is not flat

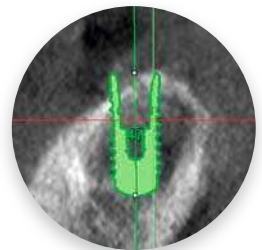
Neither is the anatomy of your implant patients

Your world is already full of clinical challenges so why work harder because of conventional thinking? Instead of augmenting sloped ridges to accommodate flat-top implants, it's time to discover a simpler solution by using an implant that follows the bone. Because sloped-ridge situations call for anatomically designed sloped implants.

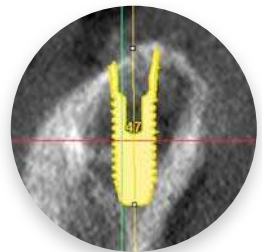
OsseoSpeed® Profile EV - It's time to challenge conventional thinking



www.profiledentalimplants.com



Conventional vs innovative approach



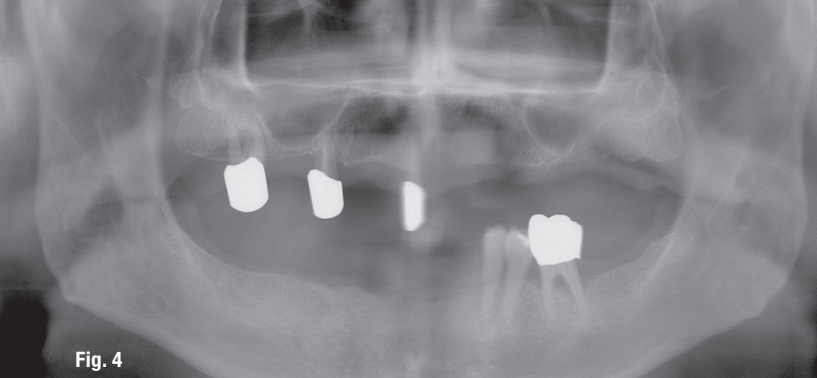


Fig. 4

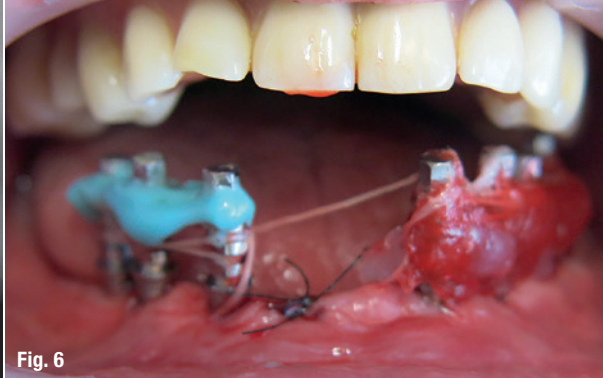


Fig. 6

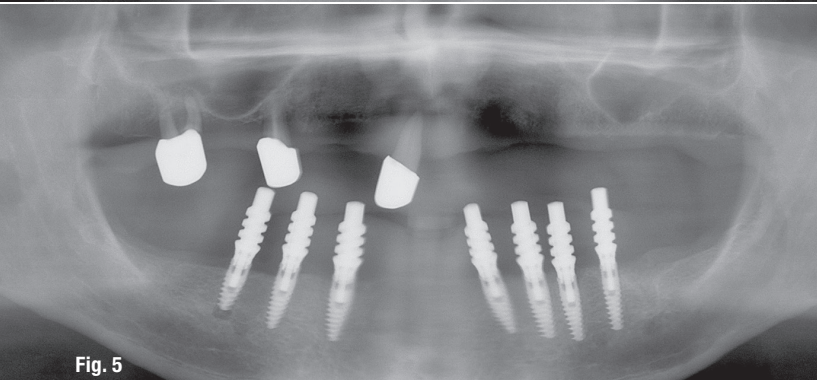


Fig. 5

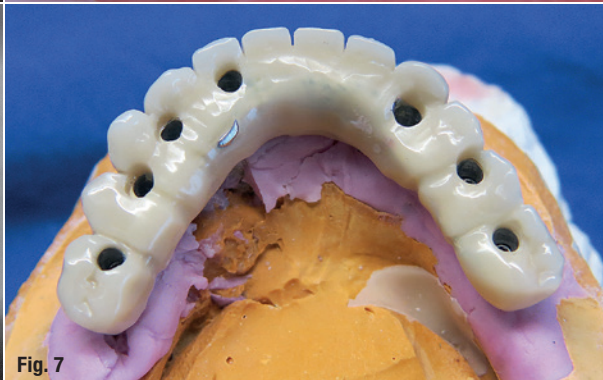

Fig. 7

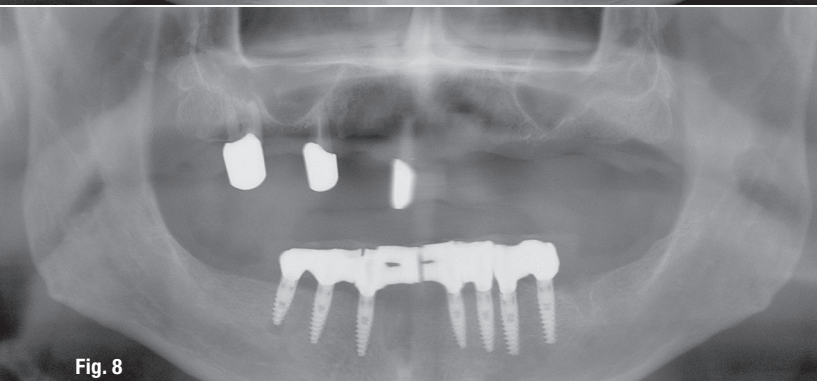


Fig. 8

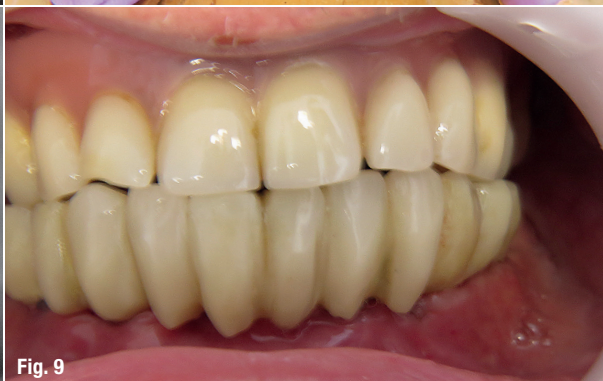

Fig. 9

Case 1 – Fig. 4: Radiograph showing situation before operation. Remaining teeth were periodontally compromised (teeth #35 and #37). **Fig. 5:** Radiograph showing in situ situation after flapless surgery had been performed. Seven implants were placed in the mandible. **Fig. 6:** Different link systems of implants were compared: using silicone (left) and patera (right). **Fig. 7:** Toronto bridge construction. Implant bridge was fixed with screws on the model. **Fig. 8:** Panoramic radiograph showing the new bridge. **Fig. 9:** Result.

tapered to ensure retention of the crown by using provisional cement.

Materials and methods

Scanning electron microscopy (SEM) investigations were done beforehand in order to evaluate the quality of the implant surfaces. An additional elemental analysis (energy-dispersive spectroscopy—EDS) was performed in order to determine whether prominent contaminations were present on the implant surfaces (Figs. 1–3).

Case reports

Four patients were treated with a new implant system (T.A.G. Dental). Two cases will be reported here in detail (Figs. 4–16). In total, 24 T.A.G. implants were inserted in four patients (maxilla and mandible). Anatomical conditions were evaluated by panoramic radiography in order to provide good information about the jaw size, bone volume and occlusal relationships. In none of the patients was augmentation necessary.

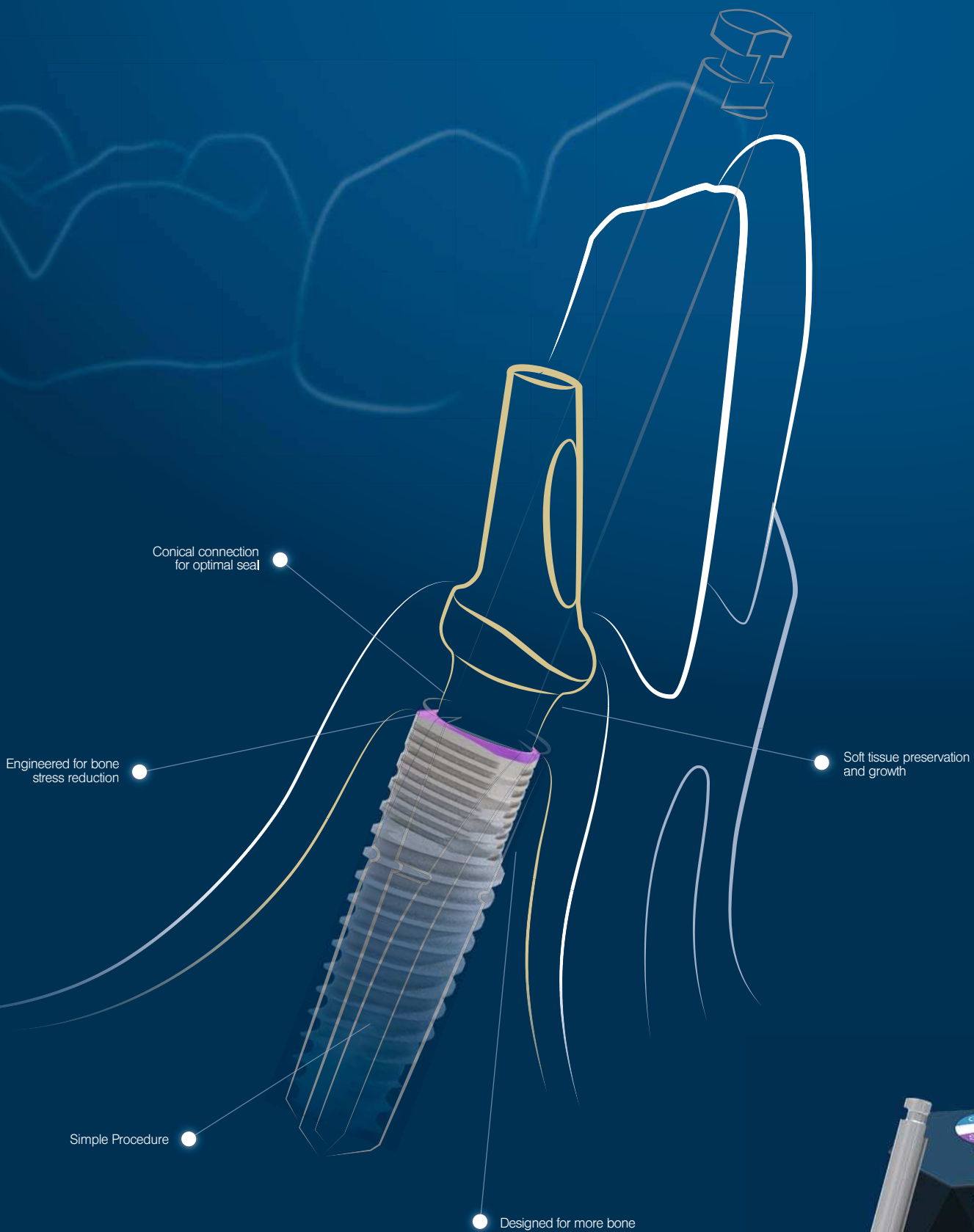
The patients were advised to quit or reduce smoking at least two weeks before implant surgery in order to allow for recovery of normal blood viscosity, because smoking is a major reason for loss of dental implants. Periodontal HELBO therapy was performed in order to remove biofilm.

Case 1

The first case was a male patient, 57 years of age and a heavy smoker (40 cigarettes per day) who reported having a great deal of stress at work. Seven implants were inserted into the mandible (two implants of 10.0 × 3.75 mm; five implants of 10 × 13 mm) with prior consensus of the patient that one implant would be removed later for histological analysis (Figs. 17 & 18).

Case 2

The second patient, also male, 37 years of age and a heavy smoker (25 cigarettes per day), presented with unsalvageable dentition. Eight implants were inserted in the mandible (six implants of 13.0 × 3.75 mm; two implants of 10.0 × 4.2 mm).



MAKE IT SIMPLE. WE KNOW HOW!

The MIS V3 Implant System was designed to offer immediate biological benefits and improved performance, while keeping surgical procedure simple. Learn more about the V3 implant and MIS at: www.mis-implants.com

mis® | **V3**

Surgical technique

Implant placement was performed under local anaesthesia (40mg of Dexamethasone, intramuscular, ratiopharm) after premedication with antibiotics. The bone cavity was extended gradually according to the intended implant diameter. After incision making, cleaning of the oral cavity was carried out and necrotic or inflammatory tissue removed. Osteotomy sites were prepared with a sequential order of drills recommended by the manufacturer. Implants were inserted in the prepared osteotomy sites with an insertion torque of 45Ncm. An adequate primary stability having been obtained, PGA RESORBA (RESORBA) was used for suturing.

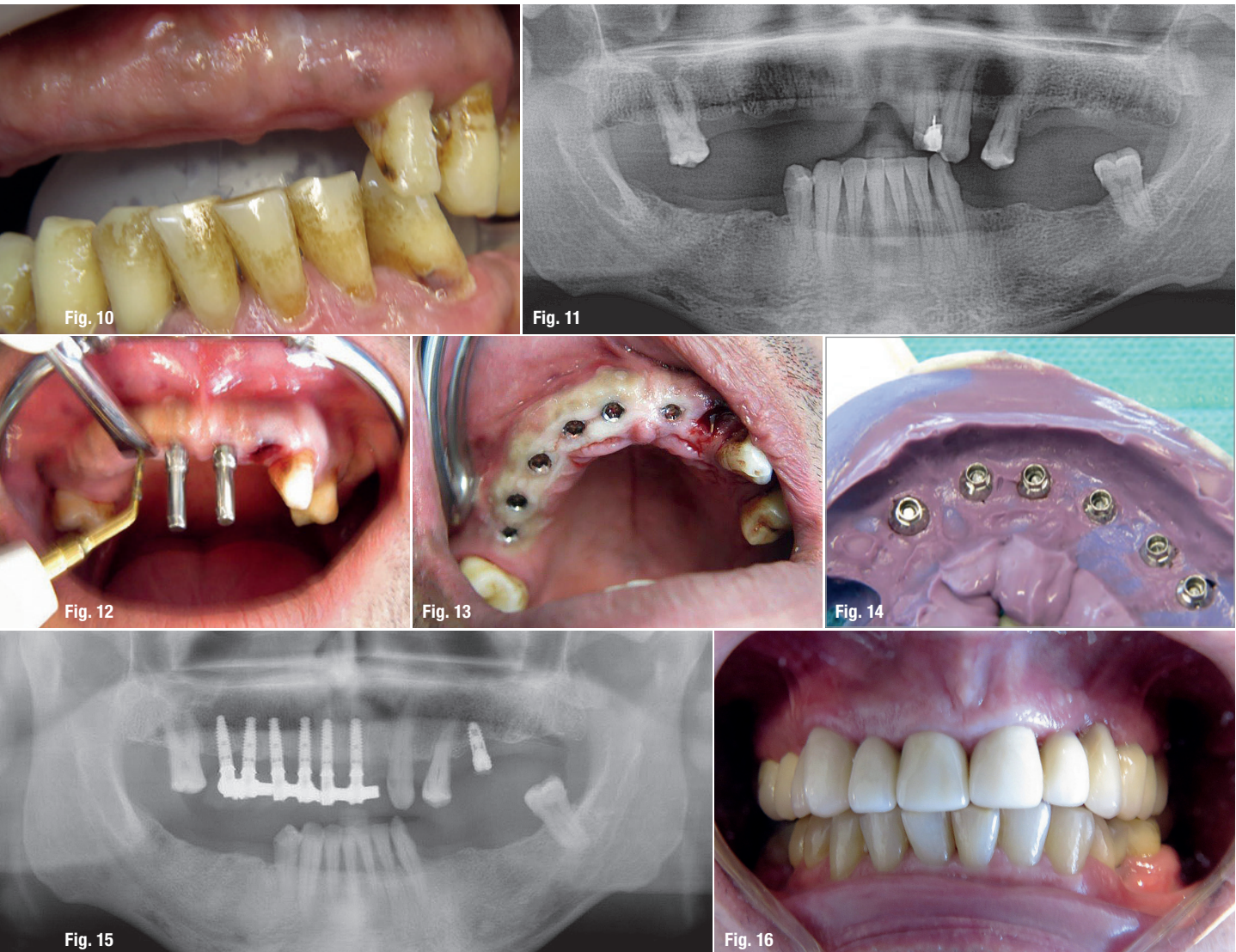
Postoperative treatment

Postoperative intraoral periapical radiographs were taken and confirmed the accuracy of the implant place-

ment. Postoperative medications included antibiotics. Digital radiographic images were taken at the time of surgery, after 24 hours and one month later in order to evaluate implant success. Inflammatory processes were found in none of the patients, and all of the implants have remained stable until now. Abstention from smoking should be extended to at least eight weeks after the implantation in order to permit the healing phase of the osteoblasts to take place.

Discussion

Today, immediate implant concepts are gaining increasing popularity for replacing missing teeth. For dental implants placed at the time of extraction, high success rates have been reported. Depending on the patients' situation, immediately placed and immediately loaded



Case 2 – Fig. 10: Unsalvageable dentition before operation. All of the teeth had to be extracted. **Fig. 11:** Panoramic radiograph of the pre-op situation. **Fig. 12:** Flapless surgery. **Fig. 13:** Extraction of tooth #22. Good condition of the peri-implant gingiva. **Fig. 14:** Replica with Impregum (3M ESPE). **Fig. 15:** Radiograph of implants. **Fig. 16:** Final result.



Fig. 17

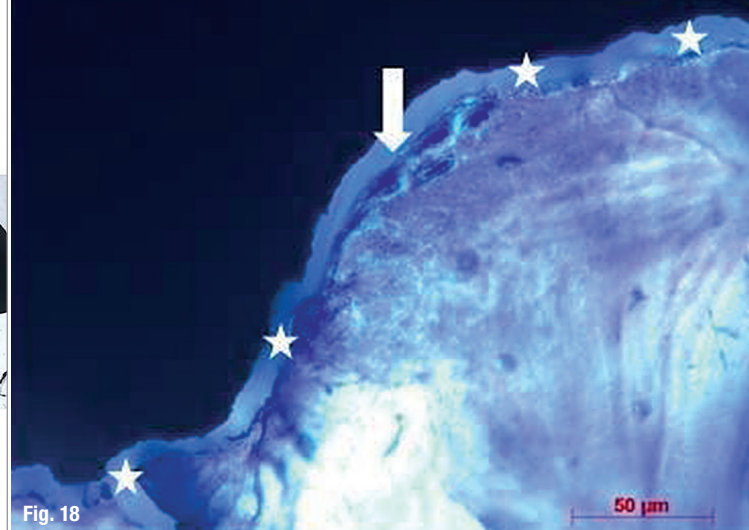


Fig. 18

Case 2 – Fig. 17: Histological analysis: good integration of implant and bone was observed. **Fig. 18:** Formation of new bone.

implants may be more predictable and successful than conventional implants. When considering immediate implant placement with an immediate loading procedure, careful patient screening and selection are required.

Smoking

The literature reports lower survival rates of dental implants in smokers. One possible mechanism that might affect osseointegration in smokers is a lowering of the blood flow rate due to increased peripheral resistance and platelet aggregation. Tobacco directly affects osteoblast function. In general, smoking is a major risk factor for implant failure. If smokers are treated with implants, good bone quality is necessary.

In the presented cases, bone quality was good and no augmentation procedures were needed. In all cases, excellent primary stability was achieved. Based on the outcomes of the present report, it can be concluded that immediate implant placement with immediate loading in heavy smokers can lead to good results if the surgeon has a great deal of experience in placing implants and the patient's bone quality is good enough.

T.A.G. implants

The surface finish of all implants is achieved mechanically and chemically by blasting with particles and acid etching, with a roughness ranging from 1.8μ to 2.2μ and morphology of the cavities from 2μ to 40μ . The micro-surface morphology increases bone-to-implant contact and results in an improvement of mechanical anchorage for better primary stability that favours cellular adhesion. Our SEM examinations confirmed the accurate surface structure of the implants used. The implant concept, such as macro-design geometry and micro-surface quality, will determine tissue reaction and influence the clinical success of the dental implant in the long term.

The macro-geometry of T.A.G. implants is designed to increase the overall functional surface area, contributing to a favourable force distribution that decreases the effective stress. The implant geometry and macro-porous surface ($mm-40\mu$) play a role in the primary stabil-

ity and long-term mechanical fixation. Parameters such as thread form, helix angle, lead number, width, depth, pitch and body shape have been the subject of intensive research regarding T.A.G. implants. Integration and optimisation of all these variables will lead to a better implant design. In the case of immediate loading, these parameters are critical.

Since the implant surface is the first component to interact with the host, surface modifications of T.A.G. implants have been extensively investigated in an attempt to increase the rate of bone healing and thereby allow practitioners to perform immediate or early loading of dental implants. The new generation of implants developed by T.A.G. Medical Products in Israel optimises the different parameters, such as geometry, topography, surface properties and surface quality, that lead to high success rates. The main advantage in using T.A.G. implants is the uniform connection design. That means that the 2.44 mm internal hexagonal connection is the same for all of the implants, ranging from 3.3 to 6.0 mm in diameter, simplifying the surgical process and eliminating the need to stock different restorative options to accommodate different implant sizes.

contact

Dr Dr Branislav Fatori

Rolandstraße 11
45128 Essen, Germany
Tel.: +49 201 82188890
info@fatori.de
www.fatori.de



Dr Inge Schmitz

Georgius Agricola Stiftung Ruhr
Institute for Pathology
Ruhr-University Bochum
Bürkle-de-la-Camp-Platz 1
44789 Bochum, Germany
Inge.Schmitz@rub.de



Computer-assisted implant rehabilitation of tumour patients

Ioannis Papadimitriou, Dr Petros Almagout, Dr Erich Theo Merholz & Dr Stefan Helka, Germany & Greece

Implantology has become a fundamental, if not routine, component of oral rehabilitation and the most reliable procedure in the discipline's attempt to realise restitutio ad integrum. In modern dentistry, implant-supported restorations are considered to be the usual and best care options. However, particularly in patients with malignancies of the oral cavity, there are fundamental changes to the anatomy of the oral cavity due to the extensive surgical procedures and adjuvant radiotherapy. In the post-irradiated jaw, a purely mucosa-supported prosthesis is not indicated owing to xerostomia and the necrosis risk of irradiated bone. The only practical way to prevent load on the mucosa is the insertion of dental implants and the subsequent incorporation of an implant-supported fixed denture.^{1,2}

Traditionally, determining implant position, size, number, direction and placement depended on the pre-operative diagnostic imaging, which was limited to 2-D radiographs and guiding templates. Three-dimensional imaging and navigational aids offer the treating implantologist enhanced certainty and additional options, especially in high-risk cases, such as patients with extreme alveolar ridge atrophy or patients with malignancies of

the oral cavity. With 3-D imaging, implant prosthetic dentistry has taken a major step forward. The dentist can plan the surgical procedure virtually in combination with 3-D planning programs.⁵⁻⁷ This has been made possible mainly by the steady improvement of specific implant planning programs, such as CTV (computer tomography visualisation) software.

With navigated implantology, it is possible to pass through the alveolar crest, locate structures and assess the existing bone at all levels. On the basis of the available data obtained on computer, the length, inclination, diameter and ideal position of the implants can be determined.¹⁻⁴ Prerequisite for navigated implantology is the use of appropriate imaging techniques, particularly the 3-D radiographic method of cone beam computed tomography (CBCT; Table 1).⁶⁻⁸ This modern 3-D diagnostic enables detailed surgical planning of implantation, taking into account prosthetic considerations. Navigated implantology offers several advantages:⁷⁻⁹

- precisely guides the osteotomy drills, through a secure, reproducible positioning of the template, directing the surgeon on the exact location and angulation to place the implant based on the virtual treatment plan;

	Effective dose in µSv	Multiple doses of a dental panoramic tomogram	Dose as % of annual natural radiation
Dental panoramic tomogram	~6	1	0.2
GALILEOS default	29	5	1.0
ILUMA default	331	52	11.0
I-CAT	68	11	2.3
Planmeca ProMax	210	33	7.0
NewTom	39	6	1.3
CT scan	2,100	323	70.0

Table 1

Table 1: Comparison of radiation exposure of various methods and systems.

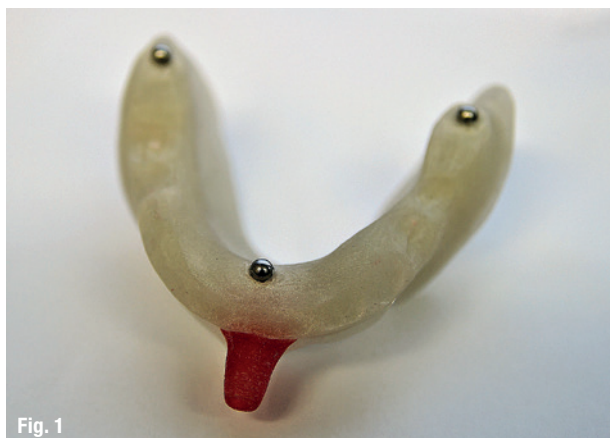

Fig. 1

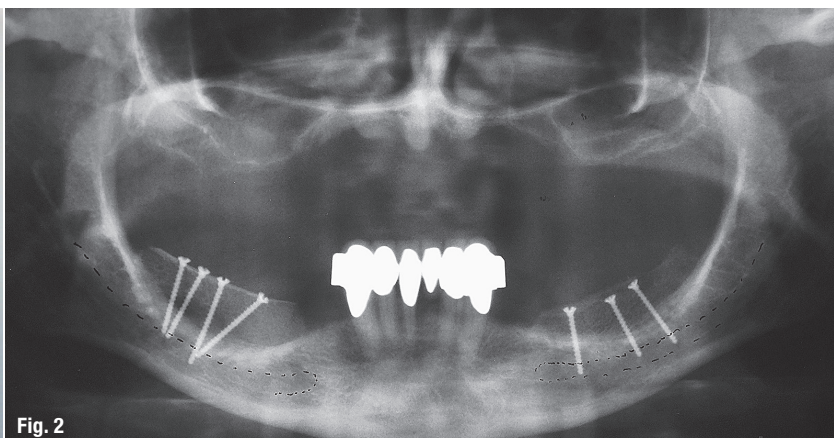


Fig. 2

Fig. 1: Radiographic template with three reference balls. **Fig. 2:** Dental panoramic tomogram after augmentation with iliac crest bone.

- allows flapless, minimally invasive surgery, avoiding unnecessary bone exposure, which entails less bleeding, less swelling, and a reduced healing time and post-operative pain;
- low-distortion and detailed radiographic analysis and an improved learning curve for the dentist, surgeon and dental technician team;
- provides greater safety for patients and dentists through 3-D planning, especially with complicated jaw conditions or low bone volume and the risk of post-operative complications is significantly reduced;
- virtual planning provides the conditions for considerably increased accuracy of implant placement and avoidance of vital structures, followed by the prosthetic restoration of masticatory function;
- the operation period is significantly shorter.

However, computer-assisted implant surgery is not free of risks. Navigated implantology also has certain drawbacks and limitations, which have to be considered as well:¹⁰⁻¹²

- problems with the template positioning in edentulous jaws and inaccurate fixation of the surgical guide, resulting in displacement during the surgery;
- fracture of the surgical guide;
- dependence between the guide system and software and usually the learning curve for the dentist, surgeon and dental technician team is complex;
- reduced mouth opening can lead to changed positioning of surgical instruments;
- the total cost of the tools needed, including the software program and surgical templates, is higher in comparison with that of traditional methods;
- intra-operative modification of implant position is not allowed.

In computer-aided implantology, the treatment procedure is very precise, but for a successful outcome and a predictable end result, backward planning is essential, since it allows the implants' alignment in the arch,

helps in treatment predictability, and promotes the maintenance of aesthetic and biomechanical principles.¹¹⁻¹³

The backward planning for a computer-aided implantation includes the following steps:

1. Impression and model fabrication.
2. Planning of prosthetic restoration.
3. Preparation of a scan template with three reference balls (aluminium, 2 mm in diameter; Fig. 1).
4. CT/CBCT scan of the patient with the inserted scan template.
5. Reading the radiographic data into the CTV system and virtual planning of the implantation.
6. Transfer of the planning data to the drilling template.
7. Guided implant placement.

Case presentation

In this section, we present two clinical cases of prosthetic rehabilitation of a patient with extreme alveolar ridge atrophy and a tumour patient with iliac crest bone grafting and computer-aided implantation using the CAMLOG Guide System. The preoperative planning, the operation phases and the patient's postoperative wound healing are described. The study was conducted in the oral and maxillofacial surgery department of St. Lukas Hospital in Solingen, Germany. The patients concerned presented for implant rehabilitation in our department after surgical resection and irradiation and before augmentation of the extreme alveolar ridge atrophy of the lower jaw with iliac crest bone. The insertion of implants was performed after obtaining CBCT scans and virtual planning of the implantation using CTV software.

Case 1

A 67-year-old female patient was referred to our department for implant rehabilitation. She was generally healthy, totally edentulous in the upper jaw and partially edentulous in the lower jaw. The initial clinical examination and the CBCT scan showed a very extensive vertical and horizontal bone defect in regions #34-37

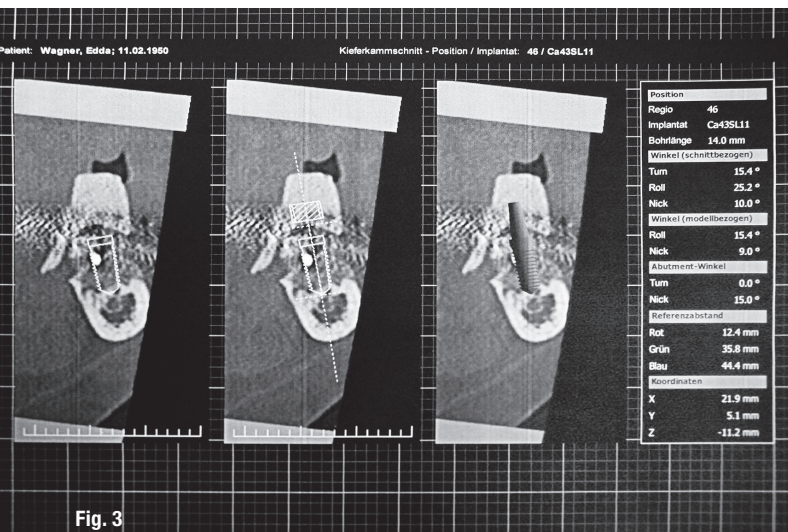


Fig. 3

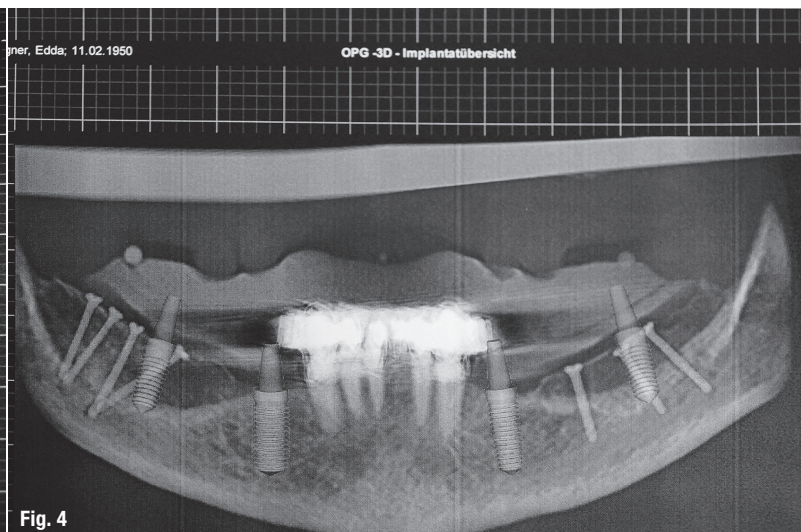


Fig. 4

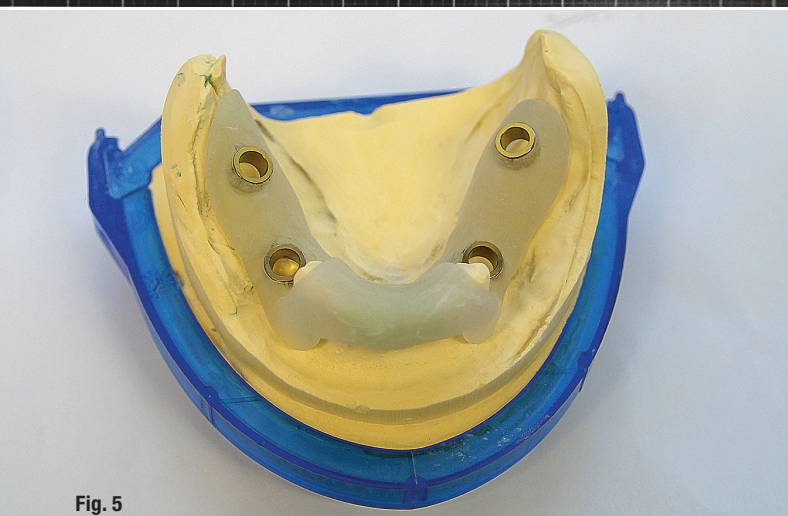

Fig. 5

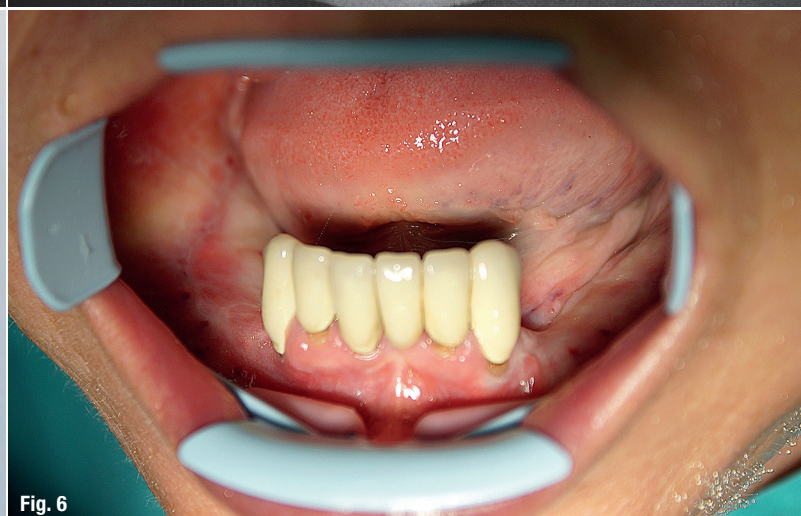

Fig. 6

Fig. 3: Sagittal section in region #46 of the planned implantation. **Fig. 4:** Virtual dental panoramic tomogram with the digitally determined 3-D implant positions. **Fig. 5:** Fully navigated drilling template for the lower jaw after CBCT planning. **Fig. 6:** Preoperative view of the mandible.

and 44–47 as consequence of progressive resorption. After the final diagnosis and planning, we discussed the possible restorative options and alternative solutions. The patient was not satisfied with her removable denture in the lower jaw and wished for a fixed denture.

In order to make treatment possible with bridge constructions on osseointegrated titanium fixtures, bone grafting was necessary in the edentulous regions of the lower jaw. The patient was explicitly informed of the possible risks and dangers from the functional and aesthetic perspective during and after the treatment period and the treatment steps were explained. Five months after the reconstruction of the alveolar jaw with iliac crest bone (Fig. 2), we were able to continue our therapy planning, which included preoperative prosthetic planning and navigated implantation.

After taking impressions, a wax set-up was produced. The aesthetic set-up in wax served for the shape speci-

fication for the preparation of the provisional restoration, the final restoration and the implant planning. The virtual planning followed. The radiographic template for CBCT imaging was prepared on a duplicate of the master model with light-curing tray material. Three radiographic balls made of aluminium were inserted into the radiographic template (Fig. 1). The use of the three balls increased the precision of the planning, because in this procedure, the ball midpoints and not edges were adjusted. A CBCT scan was performed with the patient wearing the radiographic guide. The basis for the implant planning was the data set obtained from the CBCT scan.

The minimally invasive, transgingival implantation was planned using the 3-D data set with the CTV software. Anatomical conditions had to allow the placement of at least four implants in the ideal position for prosthetic rehabilitation (Fig. 3). Once an implant had been planned, it was easy to see the vestibular and lingual cortical bone.

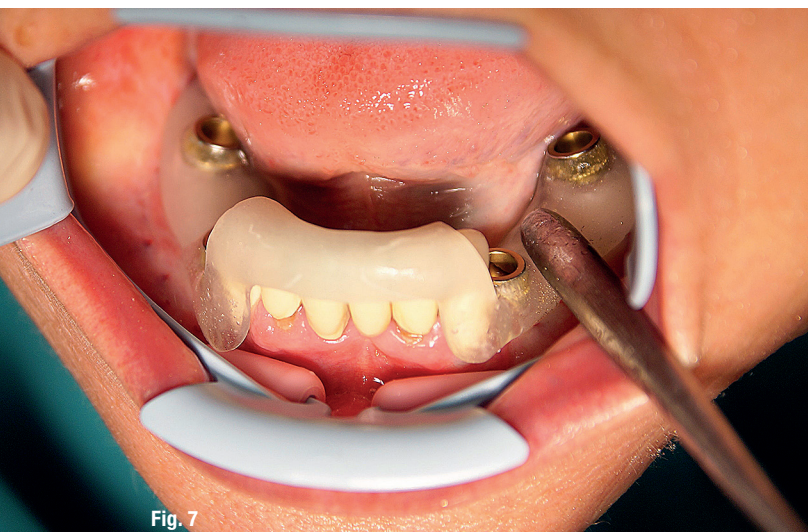


Fig. 7

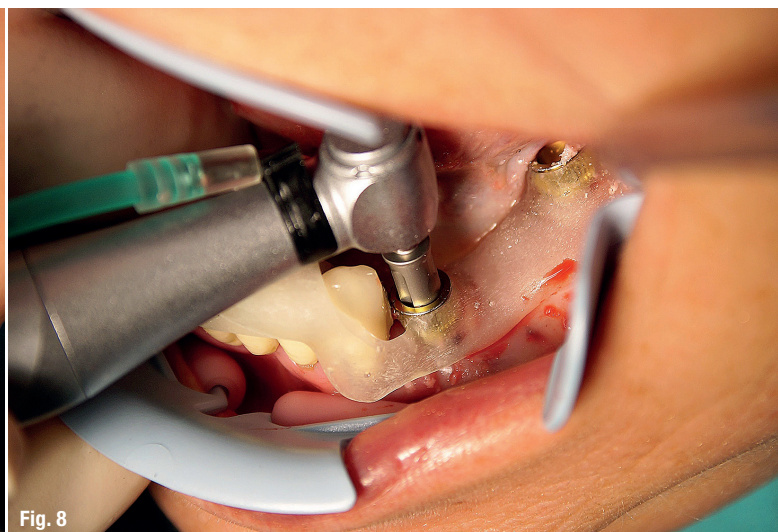

Fig. 8

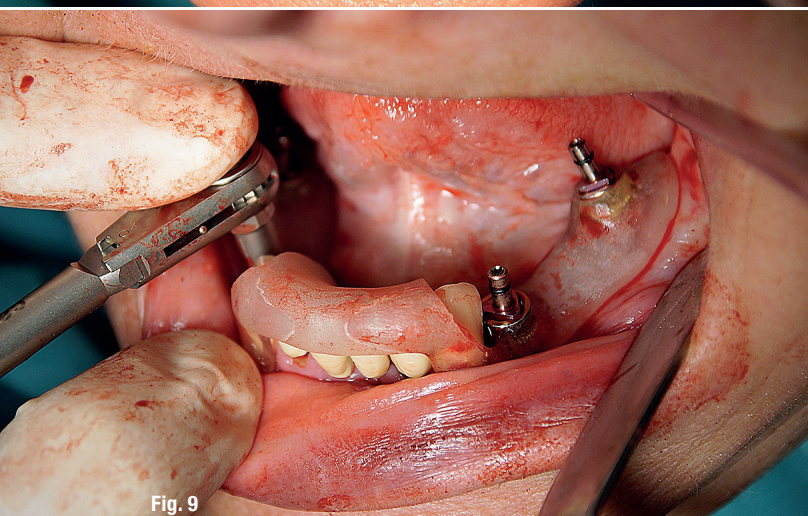


Fig. 9

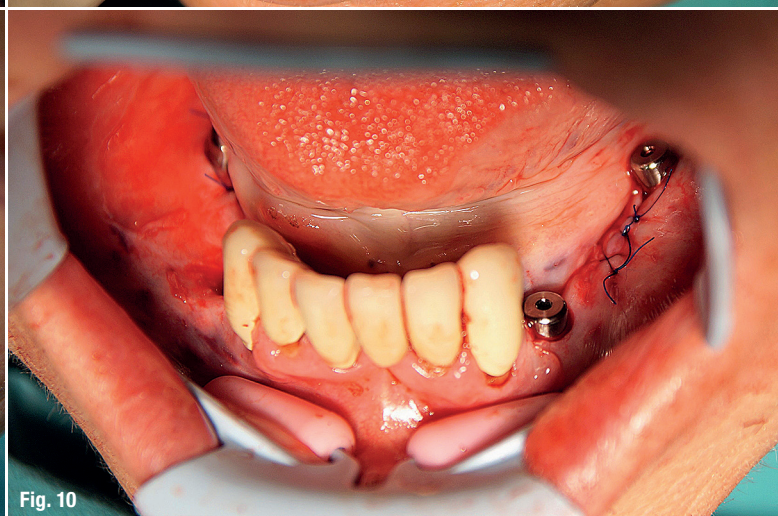


Fig. 10

Fig. 7: Insertion of the template in the lower jaw. **Fig. 8:** Guided drilling through the drilling sleeve according to the surgical protocol. **Fig. 9:** Manual insertion of the guided implants with the locked torque wrench. **Fig. 10:** All guided implants *in situ* with gingiva formers.

After bone volume analysis, implants were planned on the lingual aspect, and the implant platform virtually positioned at the level of the coronal part of the vestibular alveolar crest (Fig. 4). The main feature in the production of the surgical guide was the secure positioning and stable fixation of the drilling sleeves in the template. For the production of the drilling template, the drilling sleeves were placed on the plastic models produced by an additive process (Fig. 5).

The surgical procedure was performed under local anaesthesia with Ultracain® D-S forte 1:100,000. Cefuroxim (500mg) antibiotics were given one hour before surgery and twice a day for six days thereafter. The patient rinsed with chlorhexidine gluconate (0.2%) for one minute before the intervention (Fig. 6).

The surgical template was placed intraorally in the correct position and in relation to the opposing arch. Considerable care was taken when placing the surgical

template (Fig. 7). After correct placement and stabilisation of the surgical template, flapless implant surgery was performed in accordance with the drilling protocol for the type of implant used (Fig. 8). At the regions #34 and 44, two CAMLOG fully guided implants of 4.3mm in diameter and 13.0mm in length were inserted, and in regions #36 and 46 implants of 4.3mm in diameter and 11.0mm in length.

Moreover, two small full-thickness flaps were raised in order to remove the osteosynthesis screws used to stabilise the autogenous bone graft in the previous augmentation surgery (Fig. 9). The insertion of the implants was carried out with the standard placement head and the DRM ratchet to the maximum primary stability, with a preset insertion torque of 35–45Ncm. The gingiva formers were inserted to a torque of 20Ncm (Fig. 10) and the flaps were sutured after the implant insertion with non-resorbable sutures (Prolene 5/0). The sutures were removed after seven days. A postoperative

dental panoramic tomogram showed the inserted implants in the lower jaw and the areas of augmentation on both sides were also clearly recognisable (Fig. 11).

After the operation, the patient was instructed to cool and protect the operating area; a chlorhexidine gluconate mouthwash (0.2%) was prescribed for one minute twice a day for two weeks after surgery and painkillers, if necessary. The patient was instructed on oral hygiene. Scheduled visits after surgery were after one week, two weeks and one month. At these visits, the healing process was found to be very good and painless. The definitive prosthetic restoration was planned for four months after the implantation.

Case 2

A 75-year-old male patient was referred to our department for dental examination and for implant rehabilitation. In 2011, he had been diagnosed with squamous cell carcinoma on the right side of the tonsil. After the tumour resection and neck dissection and an adjuvant radiation therapy of up to 65 Gy, the patient was in the ambulatory tumour follow-up phase of care. This was the case

because the tumour resection was inconspicuous and without signs of recurrence. Through the previous tumour surgery, the anatomy of the oral cavity had changed fundamentally: owing to xerostomia and radiation-induced caries in 2013, all of the remaining teeth in both jaws had had to be extracted.

The first clinical examination in our department found a totally edentulous upper and lower jaw with a loss of taste and xerostomia. The dental panoramic radiograph showed about 10 per cent vertical and 15 per cent horizontal bone loss in both dimensions in the upper and lower jaw. After the final diagnosis and planning, we discussed the possible restorative options and alternative solutions. Because of the post-irradiated jaw, a purely mucosa-supported prosthesis was not indicated, and owing to the xerostomia, the maintenance of a purely mucosa-supported prosthesis was not guaranteed. Therefore, the only medically reasonable and practical solution was the insertion of dental implants, six implants in the maxilla and six in the mandible, with subsequent incorporation of an implant-supported fixed denture.

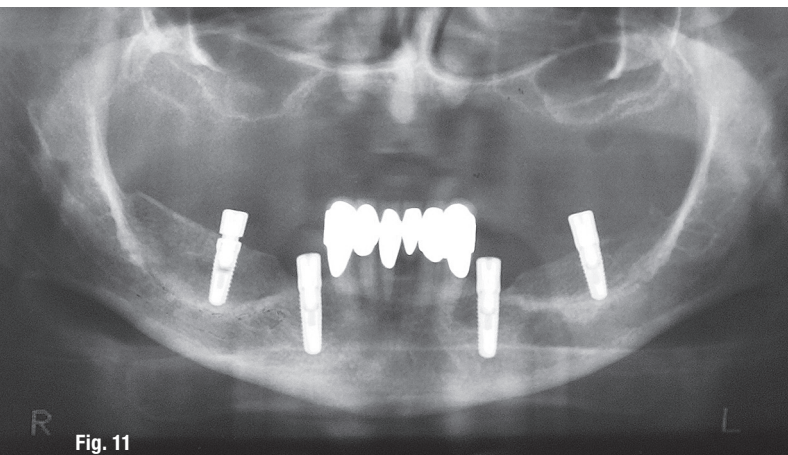


Fig. 11

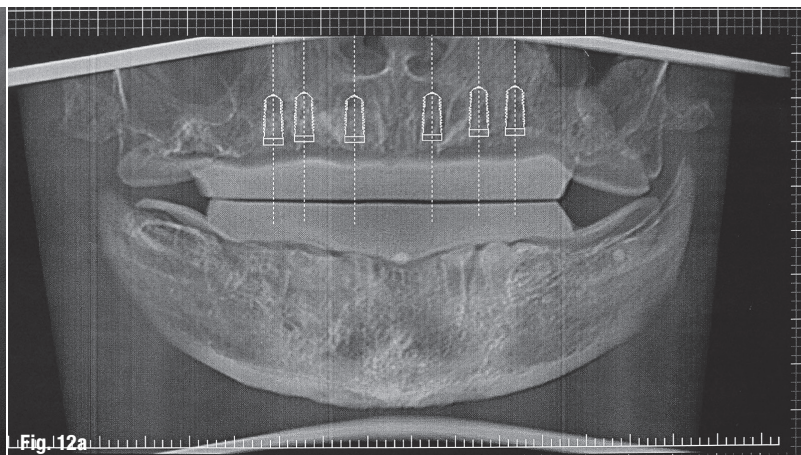


Fig. 12a

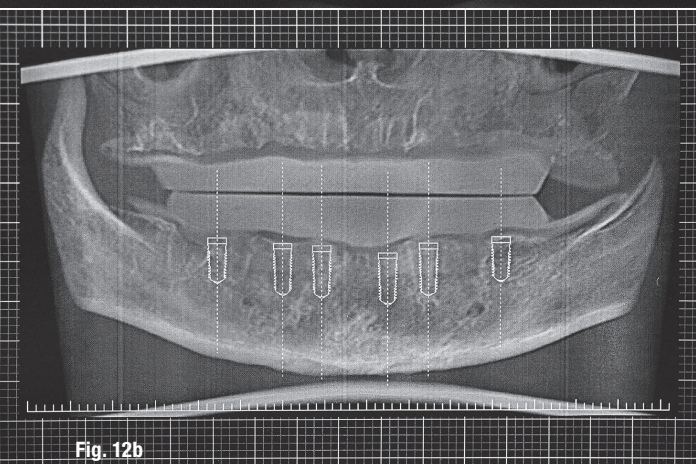


Fig. 12b

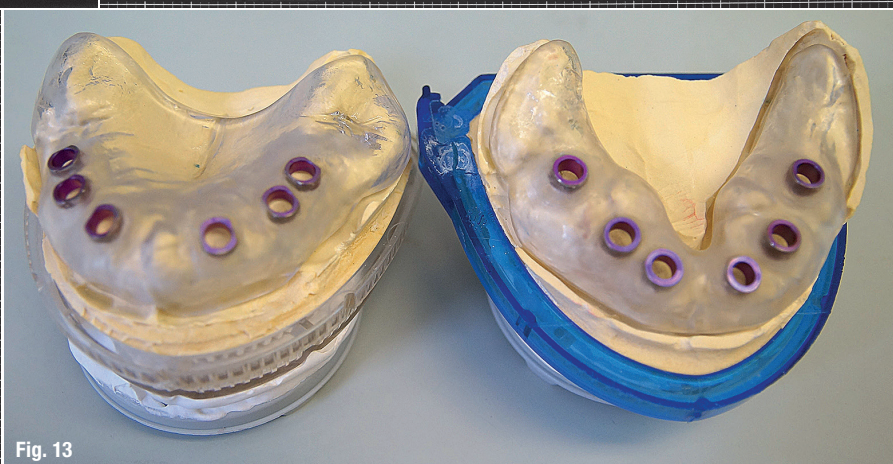

Fig. 13

Fig. 11: Dental panoramic tomogram of the patient after the surgery for control of the implants' positions. **Figs. 12a & b:** Virtual dental panoramic tomogram showing the digitally determined 3-D implant positions in the maxilla (a) and in the lower jaw (b). **Fig. 13:** Fully navigated drilling templates after CBCT planning (drilling sleeves, fully guided 4.3 mm, violet).

After taking the impressions in our department, the master models were made in the dental laboratory in a model tray socket and a wax set-up was produced and customised according to the aesthetic and functional evaluations. The patient was prepared for the computer-guided implant procedure. He underwent a CBCT with the radiographic template and the acquired DICOM images were processed with the aid of the CTV software. The planning with this software produced a report in which the coordinates of each of the three ball midpoints were determined, allowing the laboratory technician to orient and reproduce the surgical template (Figs. 12a & b). The drill guides were produced via a thermoforming technique on a duplicate model of the master model. Subsequently, the drilling sleeves were incorporated with the sleeve holders in the drilling template using the additive-produced plastic model. The transparent base of the template enabled intraoperative assessment of the template placement on the tegument through an even ischaemia due to the contact pressure during implantation (Fig. 13).

The surgical procedure was performed under local anaesthesia with Ultracain® D-S forte 1:100,000. Cefuroxim

(500mg) antibiotics were given one hour before surgery and twice a day for six days thereafter. The patient rinsed with chlorhexidine gluconate (0.2%) for one minute before the intervention. After infiltration anaesthesia in the upper and lower jaw, and bilateral nerve block anaesthesia in the lower jaw and upper palate, the surgical template was carefully inserted and stabilised correctly in the lower jaw.

In the mandible, the mucosa was punched out with a rotating punch at regions #36, 34, 32, 42, 44, and 46 (Fig. 14). After disassembling the template, the gingiva points marked with the punch were cut down and the punches removed in order to obtain a punched and prepared lower jaw (Fig. 15). Thereafter, the drilling template was used again. According to the manufacturer's instructions, cannon drills (6 mm pilot drill; 9, 11 and 13 mm form drills) were used to prepare the implant osteotomies at regions #36, 34, 32, 42, 44 and 46 (Fig. 16).

The insertion of the implants was carried out with the standard placement head and the DRM ratchet to the maximum primary stability, at about 30–35 Ncm (Fig. 17).

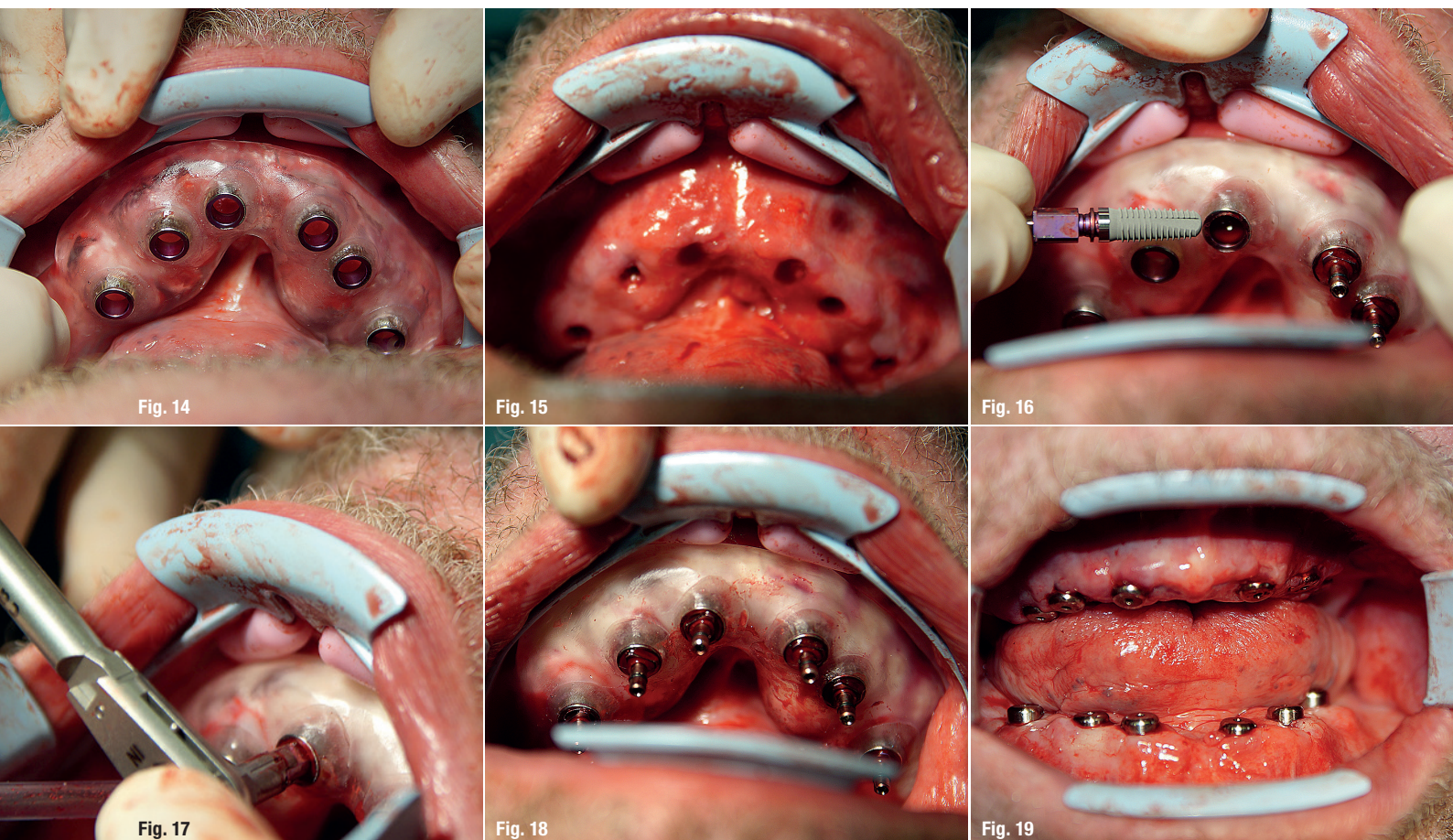


Fig. 14: Insertion of the template in the mandible. **Fig. 15:** Punched and prepared mandible. **Fig. 16:** Implant placement. **Fig. 17:** Manual insertion of the CAMLOG implant with the locked torque wrench. **Fig. 18:** All guided CAMLOG implants in the lower jaw. **Fig. 19:** Implantation result with all of the implants *in situ*.

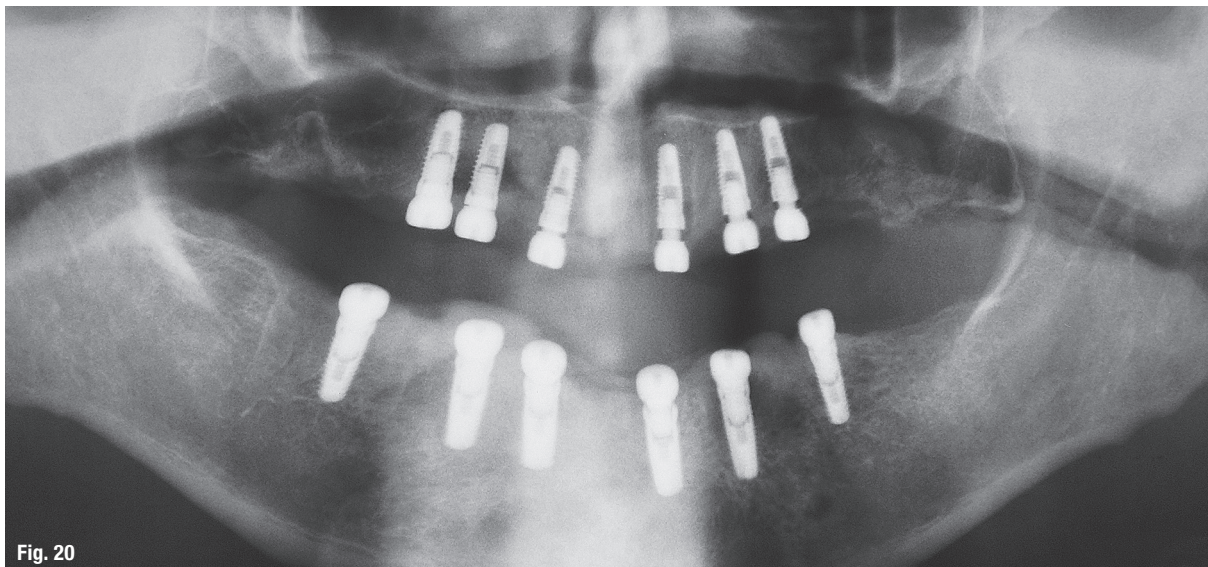


Fig. 20

Fig. 20: Dental panoramic tomogram of the patient for control of the final result.

Subsequently, the implant navigation posts and the surgical template were removed in order to insert the gingiva formers in the maxilla, which were inserted to a torque of 25Ncm (Figs. 18 & 19). The procedure in the maxilla was analogous to the operative implant bed preparation and insertion of the implants in the lower jaw, where six fully guided CAMLOG implants of 4.3mm in diameter and 11.0mm in length were inserted in regions #15, 14, 12, 22, 24 and 25. A postoperative dental panoramic tomogram showed the inserted implants in the maxilla and mandible (Fig. 20).


After the operation, the patient was instructed to cool and protect the operating area; a chlorhexidine gluconate mouthwash (0.2%) was prescribed for one minute twice a day for two weeks after surgery and painkillers, if necessary. The patient was included in our implant maintenance programme and instructed on oral hygiene. Scheduled visits after surgery were after one week, two weeks and one month. At these visits, the healing process was found to be very good and painless. The definitive prosthetic restoration was planned for five months after the implantation.

Discussion and conclusion

The advancements in the field of implantology, such as 3-D imaging, implant planning software, CAD/CAM technology, and computer-guided and navigated implant surgery, have led to the digitalisation of implant dentistry and have taken implant prosthetic dentistry a major step forward. With significant achievements accomplished in the field of digital implant dentistry, implant placement has become highly predictable, even in patients where implant surgery was previously contra-indicated.^{6,7,14}

Modern 3-D diagnostics enable detailed surgical planning of implantation, including prosthetic considerations. This achievement is mainly due to the continued improvement of implant planning programmes such as CTV software. CTV is used to display digital image data for diagnosis and precise prosthetic implant-oriented planning, with subsequent template-based implant placement.^{8,13,14}

In conclusion modern implant navigation is based on sound systematic, prosthetic and surgical knowledge. It can optimise implant treatments and safely achieve the desired result, but it can never compensate for a lack of knowledge and surgical skill of the operator.^{11,12,14}



contact

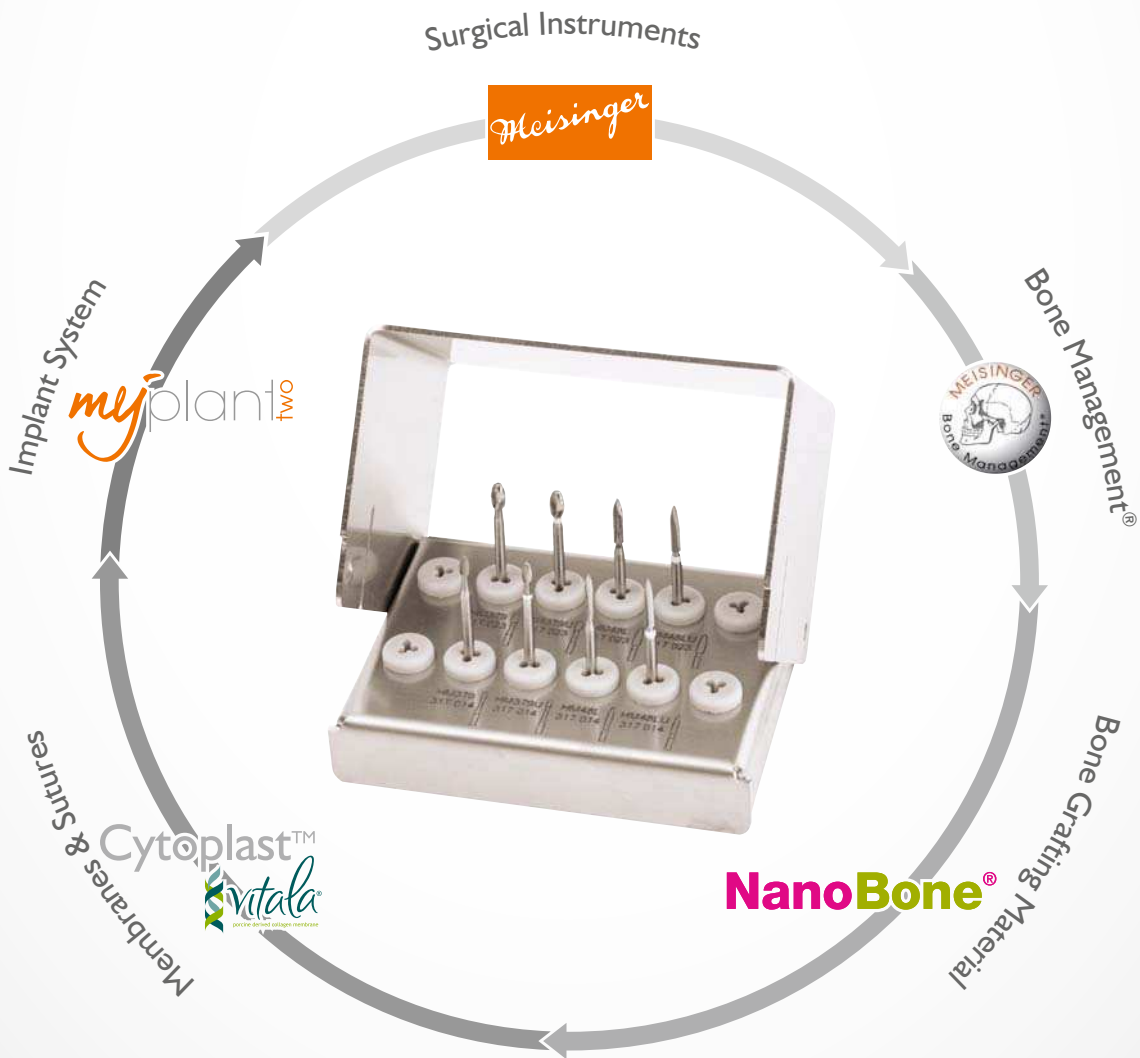
Ioannis Papadimitriou

St. Lukas Hospital
 Department of Oral and
 Maxillofacial Surgery
 Schwanenstraße 132
 42697 Solingen
 Germany
 giannis.papadimitriou_4@hotmail.com



MEISINGER

PERFECT SURGICAL SOLUTIONS



MEISINGER Periimplantitis Kit

Long Tungsten Carbide instruments for ideal peri-implantitis treatment (2575)

Fixed or removable? That is the question.

Dr Alessio Casucci & Alessandro Ielasi, Italy

Edentulism is considered to be a disability and a major oral health problem worldwide.^{1,2} Replacing missing teeth with a well-designed and -fabricated complete denture can satisfy the patient who has both a suitable clinical condition and adaptability. However, complete dentures do not restore function in all patients, especially in the case of the rejection of a removable solution for psychological reasons.

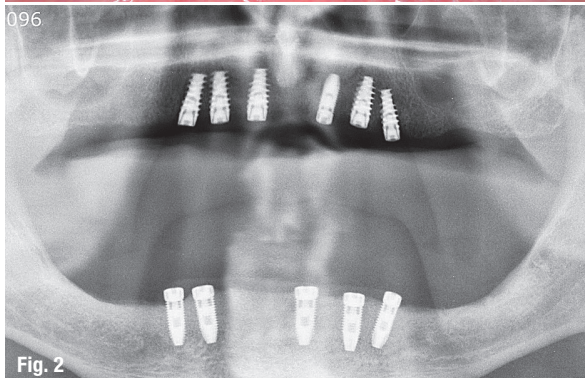
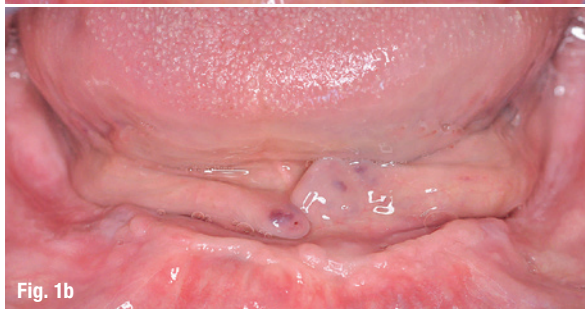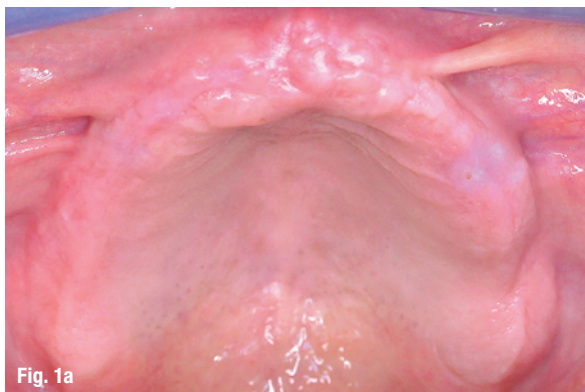
The increased awareness, survival, and success of implants and implant restorations have expanded the options for restoring the edentulous mouth from conventional dentures to implant-assisted prostheses. Furthermore, numerous studies have demonstrated that restorative approaches involving implants improve edentulous patients' masticatory function, quality of life and self-esteem.^{3,4}

Implant restorations have to be planned properly, evaluating different parameters to achieve long-term success. Bone resorption, aesthetics and phonetic parameters can be determinants in establishing a proper treatment plan. Several patient-related parameters such as hand ability, maintenance and other functional aspects, have to be considered before starting patient treatment. Scientific literature too has to be considered by the clinician in order to evaluate clinical protocols, especially for the mandible where the possible standard of care must be established. A consensus regarding this standard of care for the fully edentulous maxilla based on a critical appraisal and comparison of the cost-effectiveness of different prosthodontic solutions has not yet been achieved.⁵

For the maxilla, the literature abounds with descriptions of technical solutions, ranging from a fixed solution retained by four axial or tilted implants and upwards to a removable solution supported by two to ten splinted or free-standing implants. It has been reported that patient expectations are higher regarding treatment with fixed restorations.⁶

For some patients, a removable maxillary restoration would be the best solution providing facial scaffolding and especially for patients with a wide smile and/or high smile line covering the prosthesis-tissue junction. In addition, it is beneficial to adverse ridge relations or discrepancies and gives more latitude if the palatal contour for phonation has to be adjusted.⁷ Furthermore, it can be challenging to properly clean a fixed restoration in patients with severe maxillary resorption.⁸ It has been reported that fixed restorations result in phonetic disturbances in 42% and aesthetic problems in 37% of the treated patients.⁹

The case described in this paper reports on the treatment of an edentulous patient in whom implants were



Figs. 1a & b: Intraoral photographs. **Fig. 2:** Dental panoramic tomogram.

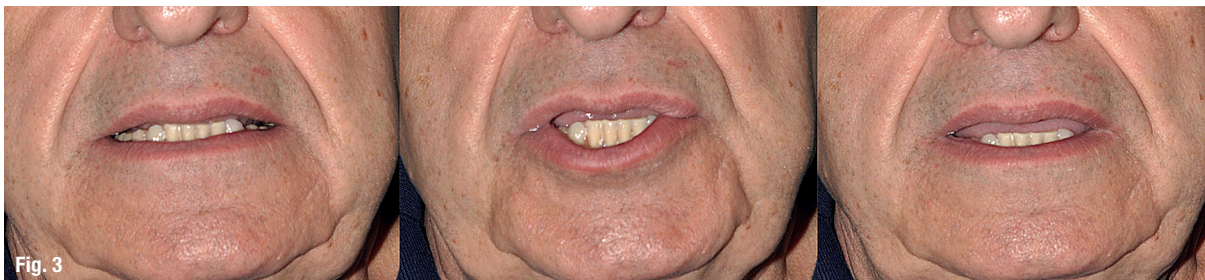

Fig. 3

Fig. 3: Patient during speaking and smiling.

placed and prosthetic solutions were defined before the surgical procedures. The patient was rehabilitated with a fixed restoration in the mandible as established. For the maxilla, the finalisation moved from a fixed to a removable solution because of aesthetic and phonetic aspects.

Clinical case

A 63-year-old male patient edentulous in both arches was evaluated for definitive implant supported restorations.

Case history

The patient had lost his remaining teeth a few years before our visit. He had been restored with complete dentures fabricated on the basis of his repaired previous partial dentures. The patient did not report a significant medical history and occlusal or temporo-mandibular disease. At the preliminary appointment the patient communicated mainly a functional discomfort due to the instability of the mandibular denture during mastication.

He reported several problems using the mandibular denture, complaining of its instability in almost every situation (during speech, eating, etc.). The maxillary denture had low retention and the palatal extension was poorly tolerated. The previous dentist had planned to rehabilitate the patient with fixed implant restoration in both arches, but after the implant placement, the patient had had several health problems due to an ischaemic stroke and this had delayed the prosthetic finalisation. At the same time, he had been forced to move to our city because he was living with his daughter and she had changed her job.

Clinical evaluation

At the first visit the patient informed us that the implants had been placed the year before. He reported some sore spots due to the maladaptation of the bearing base to the tissue. The complete dentures were found to be unstable during static evaluation (Figs. 1a & b).

Radiographic evaluation

The dental panoramic tomogram revealed six implants in the maxilla and five implants in the mandible, and slight bone resorption was detected around the fixtures (Fig. 2).

Prosthetic evaluation

The patient's lips revealed a lack of support when wearing the complete dentures, the free-way space was more than 5 mm and it was mainly the mandibular teeth that were displayed during speaking. The maxillary teeth were not displayed even during smiling (Fig. 3). The lower third of the face was too short when the patient closed the mouth when wearing the complete dentures, revealing more than 10mm between the vertical rest position and the vertical dimension of occlusion. The occlusal plane also needed to be parallelised to the bi-pupillary and Camper's planes. The centric occlusion position was not repeatable.

Prosthetic goals

In order to improve the aesthetic, phonetic and functional aspects with definitive restorations, we decided to:

- improve the upper lip support,
- increase vertical dimension of occlusion,
- improve exposure of the maxillary teeth,
- reduce exposure of the mandibular teeth,
- improve occlusal plane parallelism to the bi-pupillary and Camper's planes,
- establish a stable and repeatable occlusal position,
- verify parameters during adaptation time.

Treatment plan

In order to manage all of the prosthetic goals that may have effected important changes in patient function and adaptation, it was decided to divide the treatment plan into different steps:

1. Restoration of all of the prosthetic parameters with new temporary complete dentures.
2. Verification of all of the parameters during patient adaptation time.
3. Fabrication of two copies of the dentures that could be used to register implant impressions and the inter-arch position in order to retain all of the data required for finalisation.
4. Construction and delivery of the definitive rehabilitation.

Clinical and laboratory procedures

Preliminary impressions

In the first appointment, two alginate impressions were taken (normal-setting alginate Neocolloid, Zhermack)

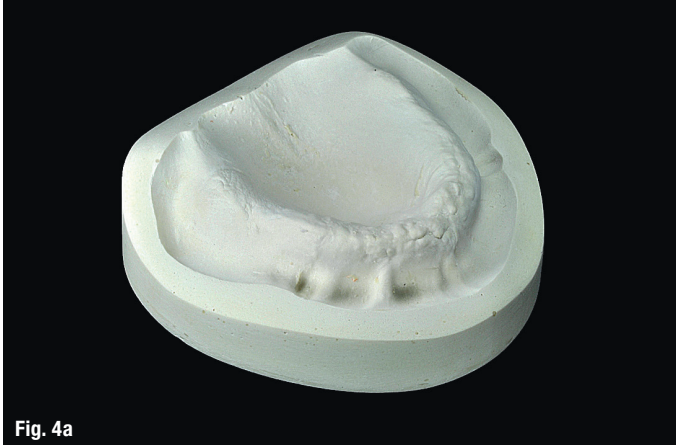

Fig. 4a

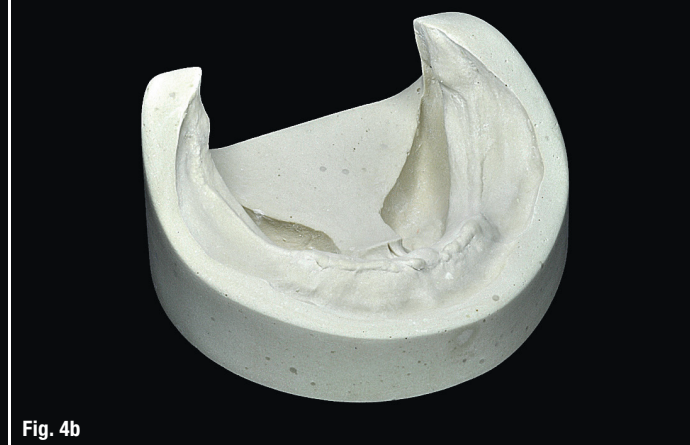

Fig. 4b



Fig. 5a

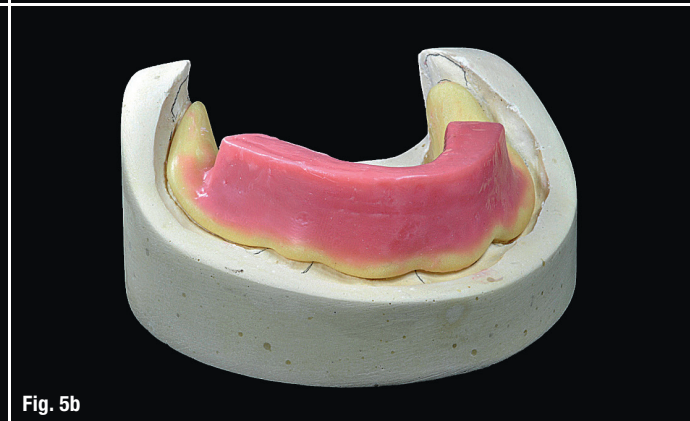

Fig. 5b

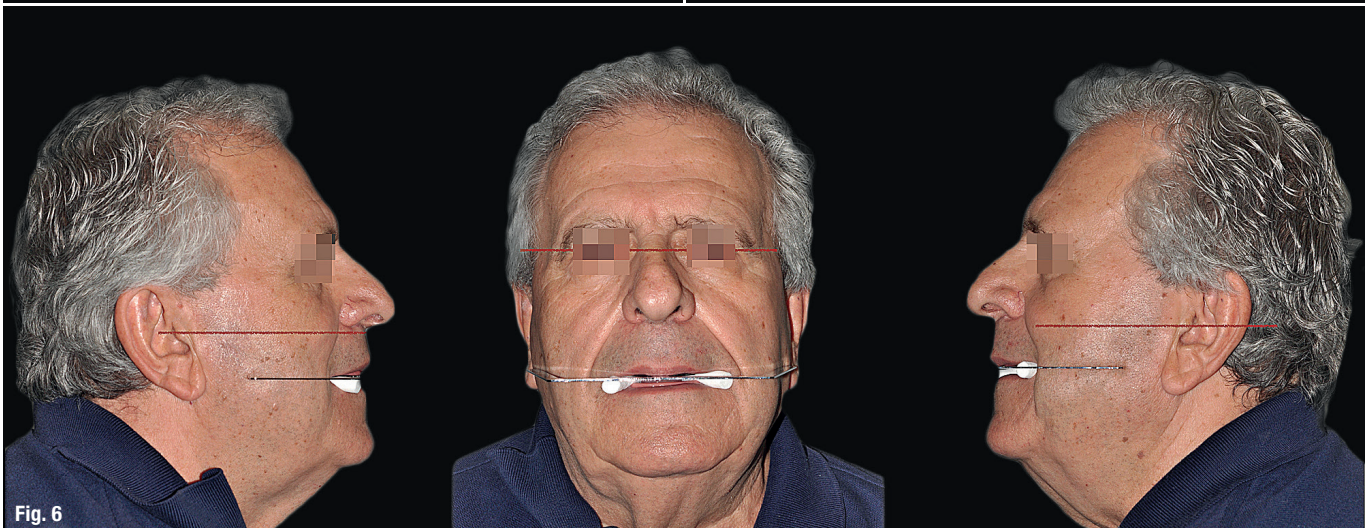

Fig. 6

Figs. 4a & b: Preliminary models. **Figs. 5a & b:** Individual trays. **Fig. 6:** Occlusal plane setting.

using Schreinemakers trays. In order to stabilise and support the impression material, a moulding wax was adapted to their surface (Cera Azzurrina Morbidissima, Zeta). The adhesive for the alginate was applied to the surface of the prepared trays (Fix Adhesive, Dentsply Sirona).

The first impressions were taken according to a two-phase technique and a high-consistency alginate was used. After removing the impression, it was prepared by removing the undercuts in order to support relining with a low-viscosity alginate. The adhesion between the alginates was promoted by drying the first material.

Preliminary models and tray construction

Preliminary models were poured using Class III plaster (Elite Model, Zhermack) according to the manufacturer's instructions (Figs. 4a & b).

Once the models had been squared and finished, the extension of the individual impression trays was drawn. Undercuts were eliminated with Tenasyle wax (Imadent) and models isolated using Separating Fluid (Ivoclar Vivadent). The trays were prepared with a self-curing resin (SR Ivolen, Ivoclar Vivadent). The trays were finished to a thickness of 2 mm, except for the borders in the sublingual areas and the retro-zygomatic areas, where they were about 3–4 mm thick.

On the basis of the trays, the wax rims were melted simulating the dental arches' volume in order to aid the clinician in taking a closed-mouth-impression. For the lower base, Tenasyle wax was used and Moyco Beauty Pink X-Hard Wax (Moyco Industries) for the upper base. For the upper wax rim, the average of distance between the vestibular sulcus and the incisal edge was set to

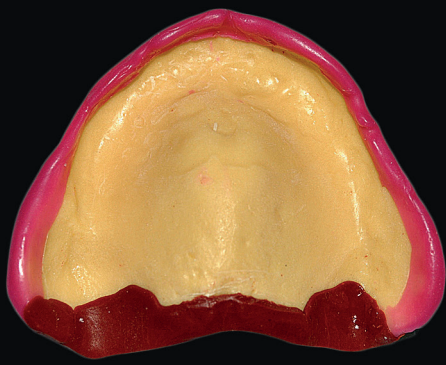


Fig. 7a

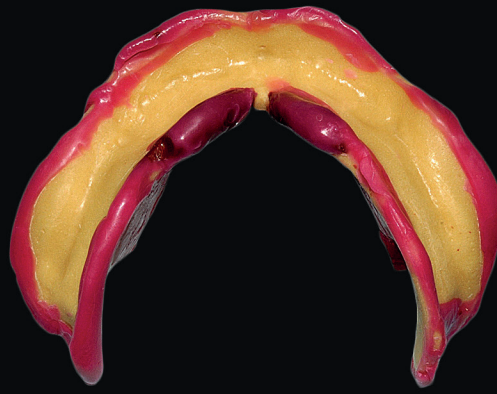

Fig. 7b

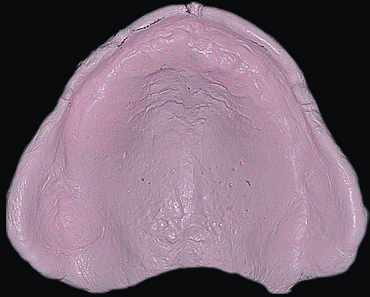


Fig. 8a

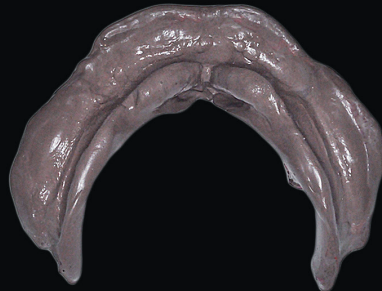

Fig. 8b

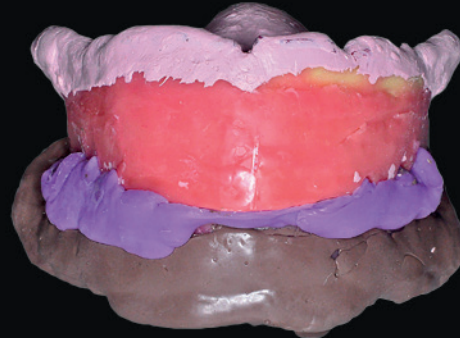

Fig. 9

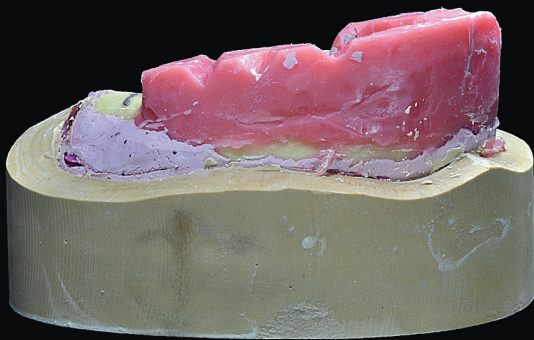


Fig. 10a

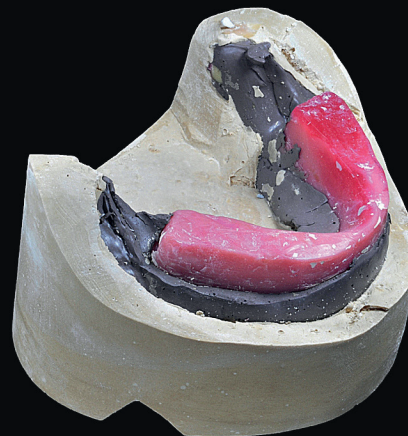

Fig. 10b

Figs. 7 & 8: Bordering and definitive impressions. **Fig. 9:** Definitive impressions and centric relation registration. **Figs. 10a & b:** Positioning models in the articulator.

22mm at the level of the central incisors and 18 mm at the molar region. The incisal edge of the upper wax rim was positioned about 8–10mm forward of the centre of the incisive papilla, with an inclination of about 20° on the sagittal plane.

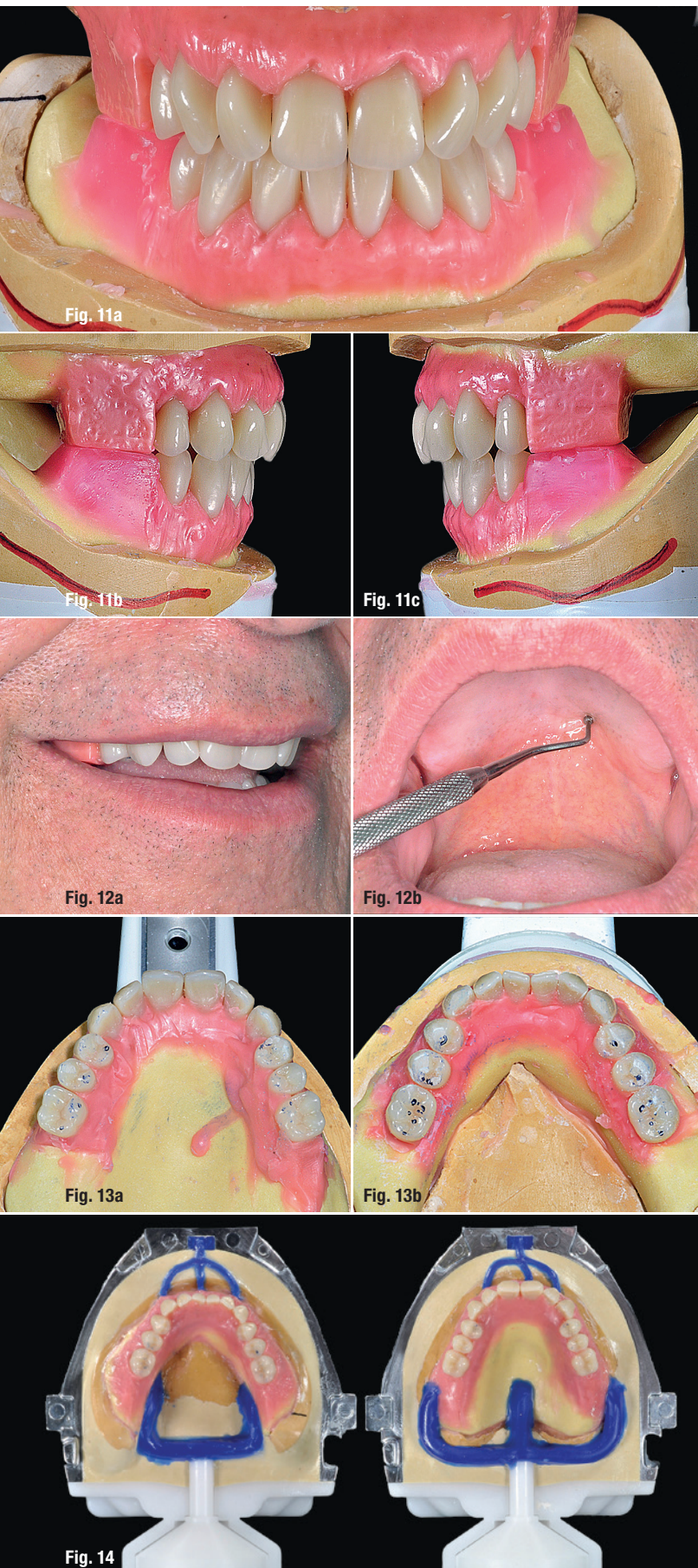
Regarding the lower jaw, the rim was prepared maintaining a distance between the labial sulcus and the incisal edge of 18mm in the anterior and posterior regions. It was positioned corresponding to the mandibular alveolar ridge and tilted about 8–10° on the sagittal plane. The rims were realised simulating an arch in accordance with the anatomical trend of the residual ridges. Moreover, they were taken to a thickness of about 2–4mm in the incisal region and about 8–10mm in the molar region. Finally, the lower wax rim was extended posteriorly to the point where the ramus of the mandible be-

gins to curve up. The posterior limit of the upper wax rim was set to the mesial limit of the maxillary tuberosity (Figs. 5a & b).

Closed-mouth definitive impressions

The stability and the adaptation of the impression trays were checked. After that, the border length and thickness were verified using a silicone-based paste (FIT CHECKER II, GC).

In the next phase, evaluating the support of the patient's lips, the rims were adapted. The upper rim was orientated parallel to the Camper's plane and the midline was recorded on it. Thus, phonetic tests were performed ("f", "v" and "s") in order to establish the position of the anterior teeth, and to allocate the space between the upper and lower planes. The vertical di-



mension of occlusion was also determined.¹⁰ Finally, the centric relation was recorded (Fig. 6).

At this point, the trays were trimmed with different thermoplastic sticks (ISO FUNCTIONAL, GC and Impression Compound, Red, Kerr Italia) in order to determine a selective pressure in the inner peripheral seal. The patient was also trained to activate the muscles of lips, cheeks and tongue to define three-dimensionally the extension of the prosthetic margin. During the trimming phase, owing to the ability to bring the rims into contact, the patient could complete swallowing movements. Furthermore, the repeatability of the centric occlusion position was verified several times using this approach.

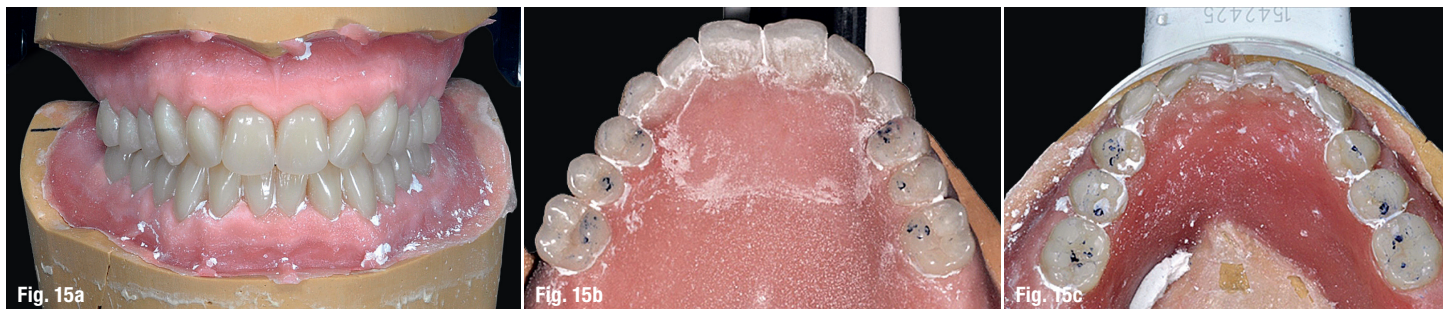Before taking the impression, the external areas of the border were released to avoid hyperextension related to the overlap of the impression material. These procedures did not affect the areas of inner seal. The upper tray was drilled to facilitate the outflow of the impression material. The final impressions were recorded with zinc oxide paste for the upper arch (Luralite, Kerr Italia) and polysulphide material for the lower arch (Permlastic Light Bodied and Regular, Kerr Italia; Figs. 7 & 8).

Finally, the vertical dimension of occlusion and centric relation were confirmed. Thus, a face-bow transfer was also indicated (UTS 3D, Ivoclar Vivadent) set according to the Camper's plane. In order to complete information about the size and shape of the anterior teeth, the Form-Selector (Ivoclar Vivadent; Fig. 9) was used.

Functional impressions were poured with Class IV plaster (Vel-Mix Classic Die Stone, Pink, Kerr Dental Laboratory Products) maintaining the peripheral border. The plaster was mixed under vacuum with distilled water and following manufacturer's instructions. Before removing the impressions, models were mounted in the articulator (Stratos 300, Ivoclar Vivadent) using the face-bow (Figs. 10a & b).

Before removing the trays from the master models, the length and position of the rims were recorded using a silicone key. The models were then isolated using Separating Fluid and the undercuts rectified using a resilient resin (Flexacryl Soft, Lang Dental Manufacturing), being careful to avoid flow to the fornix. Once the resin was polymerised, the base was prepared using Ivolen. The anterior teeth were set using the information recorded from the rims (Figs. 11a–c).

Figs. 11a–c: Anterior tooth set-up. **Figs. 12a & b:** Aesthetic evaluation and posterior seal probing. **Figs. 13a & b:** Occlusal contacts before polymerisation. **Fig. 14:** Potsdam ditching and flasking preparation.



Figs. 15a–c: Post-polymerisation occlusal grinding.

Tooth set-up

This appointment was focused on the evaluation of the aesthetics, phonetics, vertical dimension of occlusion and repeatability of centric relation. The patient observed and accepted the set-up with a member of his family. It was decided to create two embrasures on the anterior teeth in order to reduce incisal edge convexity. The posterior seal area was evaluated by probing the compression of the tissue using a ball condenser (Figs. 12a & b).

Temporary complete denture construction

The posterior teeth were mounted using a static laser (CANDULOR). Posterior tooth contacts were obtained according to lingualised occlusion concepts and the Gerber occlusal scheme (Figs. 13a & b).¹¹

Curing and finishing the complete dentures

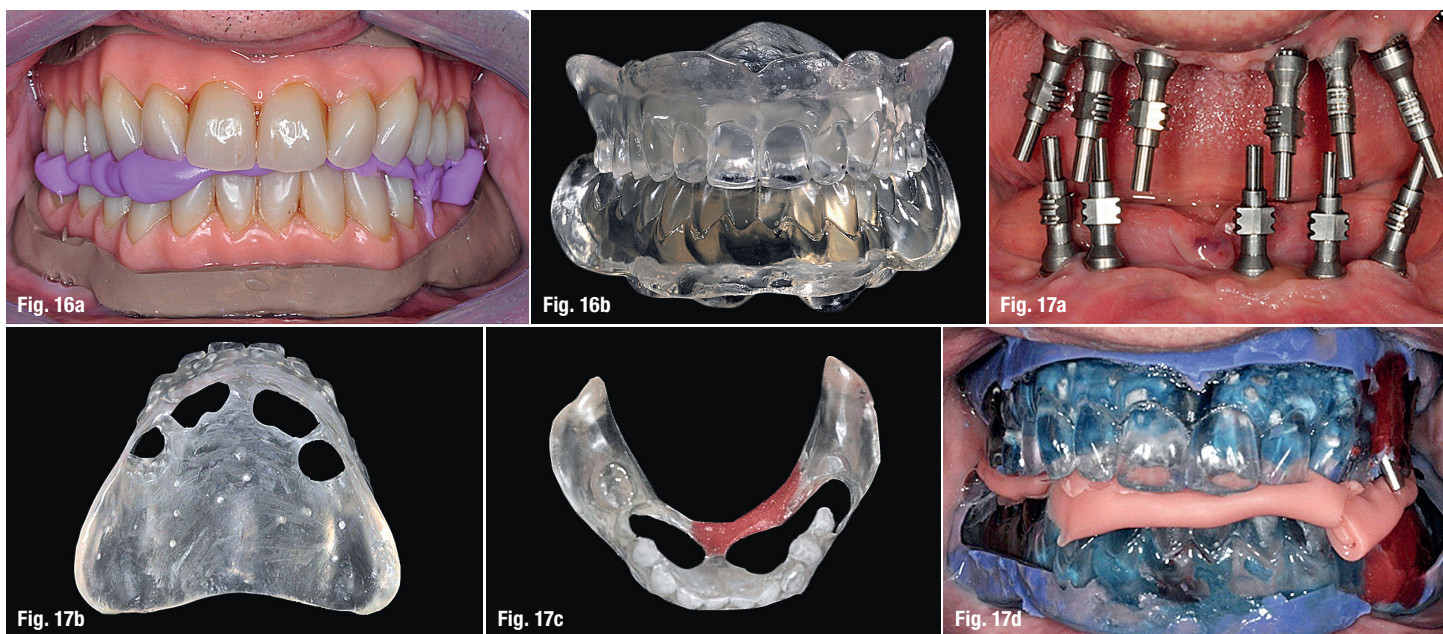
The posterior seal area was ditched on the model using the clinical information of the different levels of compression of the tissue. The prostheses were waxed for

deposit. The polymerisation was performed using the IvoBase system (Ivoclar Vivadent), a fully automatic injection system. The shrinkage of the specific PMMA resin is fully compensated for during polymerisation, thus obtaining the most accurate denture base adaptation (Fig. 14).

After polymerisation, the prostheses were replaced into the articulator and the occlusal grinding was performed in order to maintain all of the occlusal contacts that were established before polymerisation (Figs. 15a–c).

Temporary denture delivery and follow-up

Upon delivery, the prostheses were placed into the oral cavity and left to adapt for 10 to 15 minutes with the patient clenching two cotton rolls placed bilaterally between the arches. After that, the adaptation of the bases was checked with FIT CHECKER II. The patient was instructed to perform functional movements and to speak. The length and thickness of the borders were verified with the silicone-based paste and corrected when it was required.



Figs. 16a & b: Information registration and realisation of denture copies. **Figs. 17a–d:** Definitive impression registration.

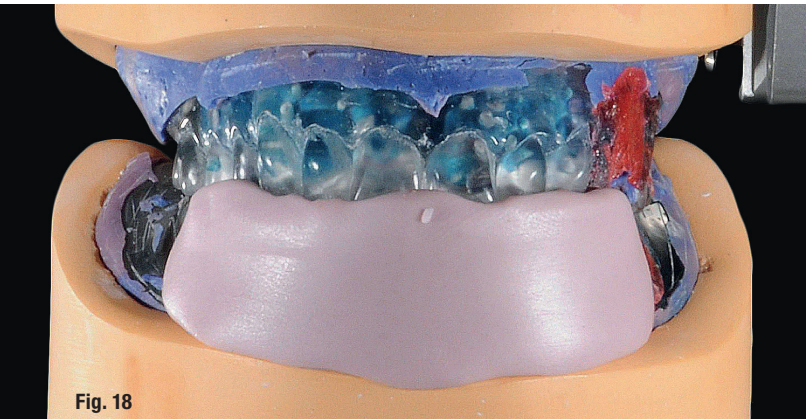


Fig. 18

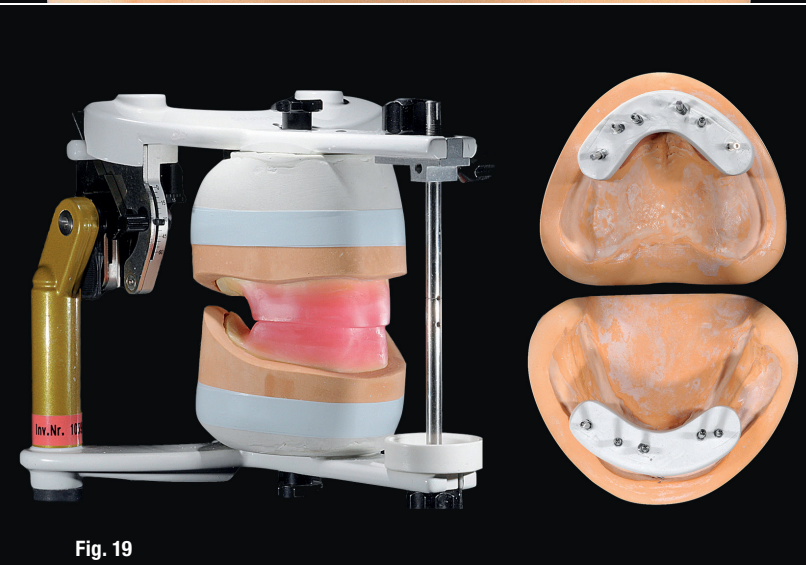


Fig. 19

Fig. 18: Silicone key recording tooth position. **Fig. 19:** Occlusal keys and pick-up stone position.

Finally, the occlusion was checked, revealing bilateral symmetrical contacts. The patient was instructed on managing and cleaning the complete dentures in the initial days. Follow-up visits were planned at 24 hours and one and two weeks after delivery. The patient reported a rapid adaptation to the new dentures, only a few points of pressure caused ulcerating lesions. Phonetics and stability were improved after the treatment. Control appointments were conducted in the weeks after delivery and excellent levels of adaptation were reported, regarding both aesthetic and phonetic aspects.

Fabrication of denture copies

The successful adaptation to the temporary dentures confirm that all the parameters (vertical dimension of occlusion, centric relation, aesthetics and phonetics) could be maintained in the definitive restoration. It was decided to fabricate copies of the temporary dentures and to use them as a closed-mouth tray. The temporary bearing bases were rebased with a polysulphide impression material (Permlastic Light). The intermaxillary position was registered using a bite registration silicone

(Occlufast, Zhermack). The copies were obtained using self-curing transparent resin (ProBase, Ivoclar Vivadent; Figs. 16a & b).

Closed-mouth implant impression registration

After the implant surgery, a multi-unit abutment was placed. At the impression appointment, pick-up copings were attached to the implant abutments. Denture copies were prepared in order to be positioned with perfect adaptation to the oral mucosa.

Finally, definitive impressions were taken with polyether material (Permadyne and Impregum, 3M ESPE). The intermaxillary position was as registered after removing all of the implant pick-up copings that could determine occlusal interferences. A face-bow was also taken before removing the maxillary impression (Figs. 17a–d). Master models were prepared using a removable soft resin to reproduce peri-implant tissue. The impressions were poured in Class IV plaster, and the obtained models were placed in the articulator using the face-bow measurements.

Before removing the impressions from the master model, a silicone key was prepared in order to record the position of the anterior teeth (Fig. 18). Two occlusal bases were prepared with wax rims in order to verify the intermaxillary position. Additionally, implant pick-up copings were splinted using stone (Elite Arti, Zhermack; Fig. 19).

Implant and inter-arch position check

The intermaxillary position was confirmed, but the upper stone key was fractured during screwing procedure. Thus, it was splinted with stone, and after repositioning the implants, replaced on the model. The implants' position was definitely confirmed (Figs. 20a–d).

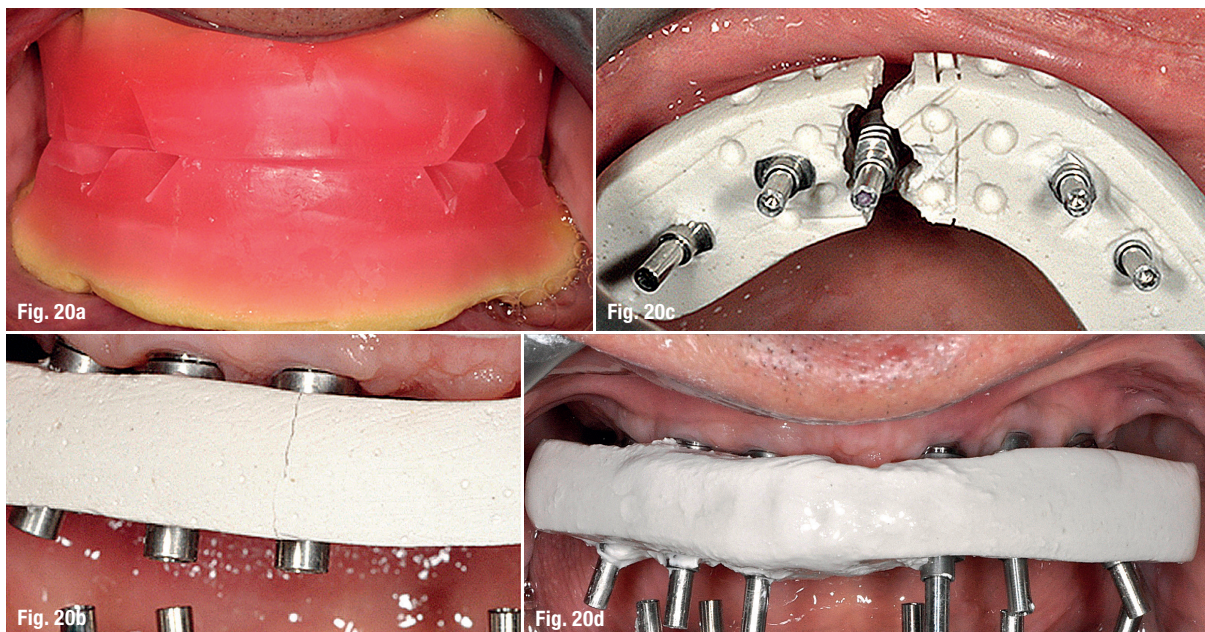
Tooth set-up

The tooth set-up was performed according to the information of the denture copies, using the silicone key. The complete set-up was evaluated with the patient and all occlusal, aesthetic and phonetic aspects confirmed. The tooth set-up approved during the patient try-in was sent to the laboratory for framework design.

Fixed or removable?

Depending on the discrepancy between the position of the clinical crown and the alveolar ridge contour in the bucco-oral dimension, compensation with the denture base of a removable reconstruction may be necessary.¹² However, for a fixed complete denture, the clinical crown should ideally be at the soft tissue level of the alveolar ridge. For this solution, minimal bone resorption and a limited inter-arch space with an optimal tooth–lip relationship are required (Fig. 21).¹³

These parameters, mainly determined by tooth position and the amount of residual alveolar bone, have to



Figs. 20a–d: Occlusal check and implant pick-up coping splinting.

be considered before planning a maxillary implant-supported restoration.¹⁴ In this case, the patient was informed before implant surgery that his dentition was to be restored with fixed restorations in both arches. However, our prosthetic evaluation determined that it was not feasible because of the horizontal distance between the teeth and implants.

The patient was informed about the advantages and disadvantages of fixed or removable prostheses. Moreover, a tooth set-up was prepared without a buccal flange in order to analyse potential problems regarding facial support, phonetics, aesthetics and hygienic access. With the patient's consent, it was decided to realise a removable solution for the maxilla and a fixed restoration for the mandible.

Clinical case finalisation

The implant overdenture was prepared maintaining the insertion path perpendicular to the occlusal plane. Two bars were fabricated in order to reduce the volume required for primary and secondary frameworks. In both bars were placed two different ball retentive systems (Rhein'83). The mesial one was mini, and the distal one of normal size. This kind of solution could guarantee enough retention for the restoration and durability of the attachment system. Moreover, owing to the number and position of the implants, complete palatal support was reduced, including the maxillary tuberosities as determinant support areas (Figs. 22a & b).

Delivery and follow-up

Definitive restorations were realised maintaining all of the prosthetic parameters of the temporary restoration.

Patient adaptation was excellent concerning the aesthetic, phonetic and hygienic parameters, despite at the beginning of treatment having been oriented to a max-

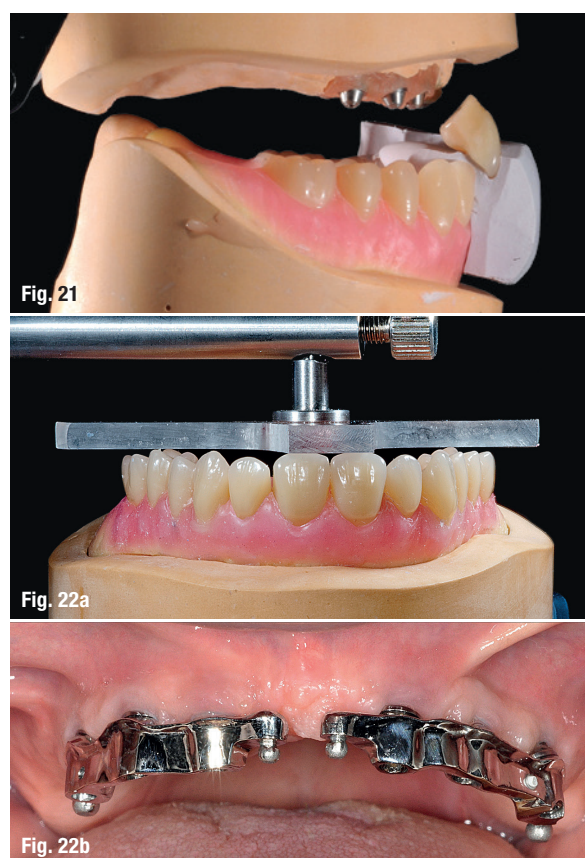


Fig. 21: Space evaluation. **Figs. 22a & b:** Implant overdenture framework fabrication and try-in.

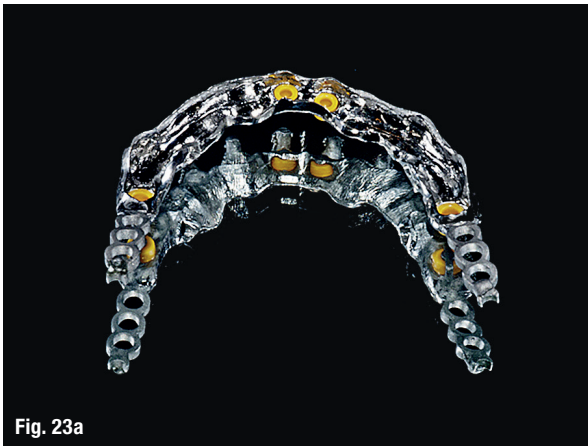

Fig. 23a

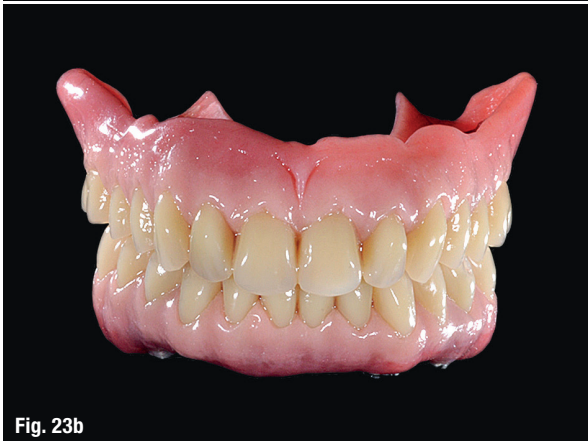

Fig. 23b

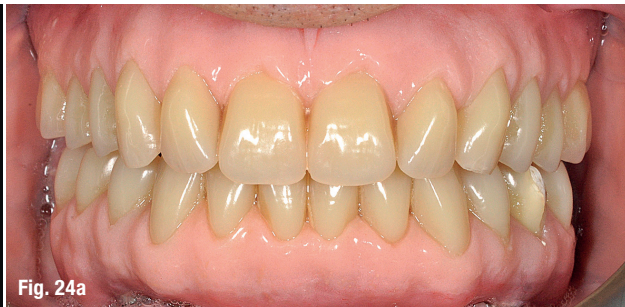

Fig. 24a

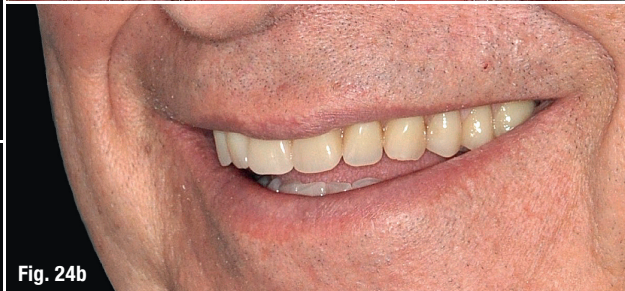

Fig. 24b

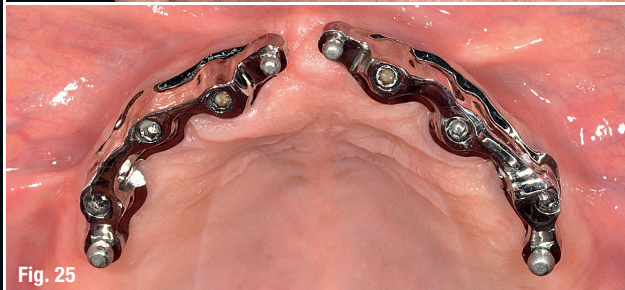


Fig. 25

Figs. 23a & b: Definitive restorations. **Figs. 24 & 25:** Three-year follow-up.

illary fixed rehabilitation (Figs. 23a & b). The prosthesis-bar-supported solution could guarantee enough retention and stability to the patient in both functional and psychological aspects. At the three-year follow-up, the tissue was healthy owing to the patient's hygiene compliance (Figs. 24 & 25).

Discussion and conclusion

While this clinical case reported good patient adaptation to the definitive restorations, modifying the initial treatment plan can be a challenge, especially when patients chose to be treated with implants because they are maladapted to removable solutions. As reported in this case, with a sufficient number of implants of adequate length, the superstructure can be purely implant-supported in construction. However, when bone is severely resorbed,¹⁵ the distance between the implants and the incisal edge position cannot be solved with a fixed restoration because of the lack of lip support or poor phonetics.

Current criteria for planning and deciding on treatment have been reported in literature and are considered a fundamental guide for establishing the treatment plan.^{16,17} This case treatment would emphasise

the importance of not promising the patient a fixed maxillary restoration until the final wax trial has been accepted.¹⁸⁻²⁰



Acknowledgements

Thanks to Marco Vannini and Rhein'83 for their support and for sharing their experience with us in solving this clinical case.

contact

Dr Alessio Casucci

Private practice
Via Bari 31
53045 Montepulciano
Italy
alessio.casucci@gmail.com

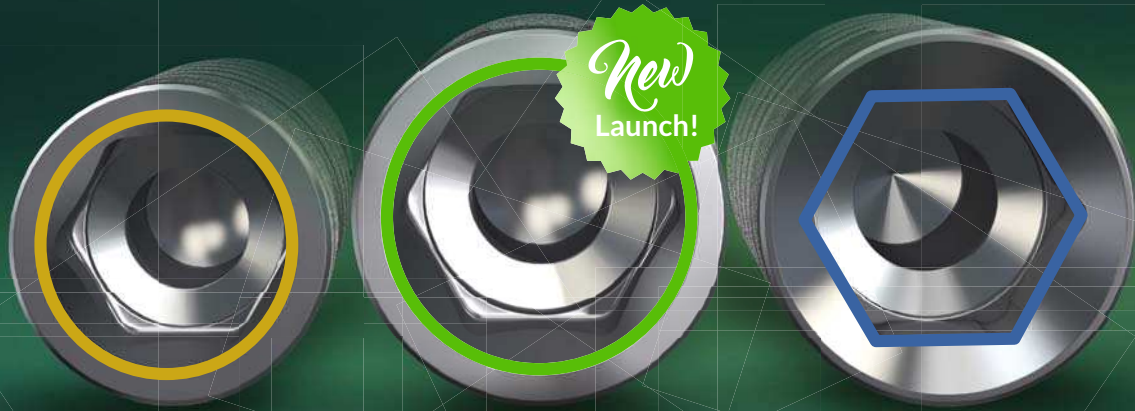

Alessandro Ielasi

Dental lab Ielasi
Snc, Via Mazzella Luigi
80077 Ischia
Italy
alessandroielasi@libero.it

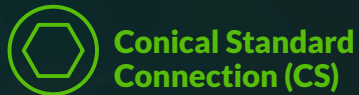

ONE **neO** MULTIPLE OPTIONS



The Complete **neO** Implant Family

With more options to choose from, the NeO family now includes 3 connections:




Each connection features a dedicated restoration line



www.alpha-bio.net/neo

Treatment of periodontal and peri-implant inflammation

Dr Vincenzo Iorio-Siciliano, Italy



The elimination of biofilm is the key factor in the treatment of periodontal and peri-implant inflammation. Periodontitis, peri-implant mucositis, and peri-implantitis represent bacterial inflammation with comparable symptoms. The clinical signs for all three are similar and include positive bleeding on probing, redness, oedematous tissue, suppuration and probing pocket depths of more than 4 mm. The cause of these similarly progressing infections is bacterial plaque, a biofilm rich of pathogenic bacteria. As a consequence, effective elimination of this biofilm is a fundamental prerequisite for the successful treatment of these diseases.

Treatment possibilities

Various methods (e.g. curettes, ultrasound, airflow) are available for the mechanical removal of biofilm. Complete elimination of the biofilm, however, is not always achievable by mechanical debridement alone.

PERISOLV® (REGEDENT) is a new antibacterial cleaning gel based on chloramines, which can be used in addition to mechanical cleaning in the treatment of periodontitis, peri-implant mucositis and peri-implantitis. The gel penetrates and softens the biofilm and, owing to its antiseptic properties, eliminates the pathogenic bacteria after only a few seconds.^{1,2}

PERISOLV® is a two-component preparation consisting of a 0.95 % sodium hypochlorite (NaOCl) and an amino acid solution. Before use, the two components are mixed. The sodium hypochlorite and the amino acids form short-lived chloramines (N-carboxy anhydride, NCA) as antibacterial and anti-inflammatory active ingredients. PERISOLV® thus has an antimicrobial effect while also softening the concretions on the tooth or implant surface. This favours a less abrasive mechanical debridement of the root surface.³

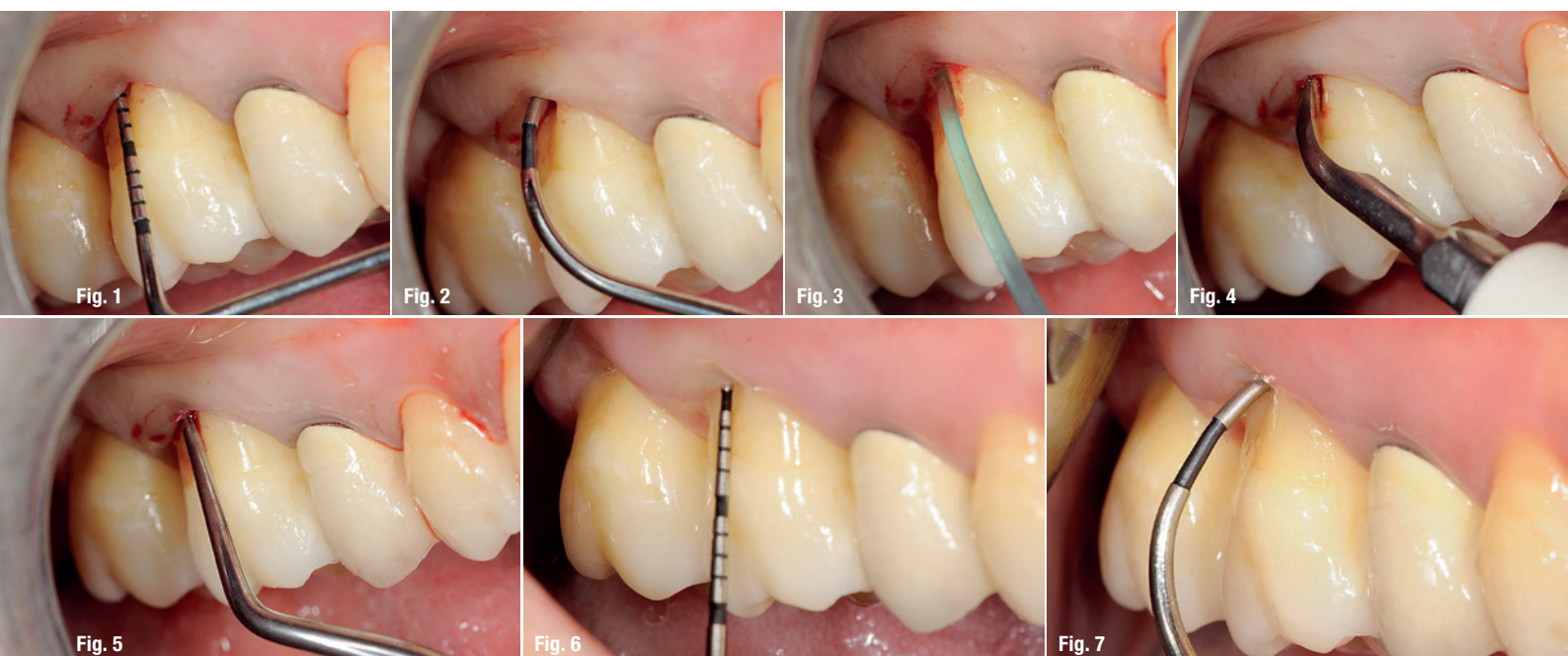


Fig. 1: A pocket depth of 5 mm with bleeding on probing was noted. **Fig. 2:** A Class II furcation defect was recorded. **Fig. 3:** PERISOLV® was applied into the furcation defect. **Fig. 4:** Subgingival scaling was performed. **Fig. 5:** Root planing was done. **Fig. 6:** A pocket depth of 4 mm at the buccal site was reported at the six-month follow-up. **Fig. 7:** The Class II furcation defect was reduced to a Class I furcation defect.

Chloramines are physiological compounds that play an essential role in the natural human immune system.⁴⁻⁶ PERISOLV[®] thus has a pronounced antimicrobial activity¹ also against bacteria in biofilms on implant surfaces.⁷ Its degranulating effect improves the efficiency of tooth root and implant surface cleaning (Figs. 1-7).⁷⁻⁹

Antimicrobial activity

The antimicrobial properties of NCA are well studied. NCA causes a significant inactivation of bacteria,¹⁰⁻¹³ fungi,^{12, 14, 15} viruses¹⁶⁻¹⁸ and protozoa¹⁹. Even when exposed to sublethal concentrations of chloramines for pathogenic bacteria, a positive effect is observed. Chlorination of the bacterial cell membrane produces a postantibiotic effect (retardation of growth). As a result, bacterial inactivation is promoted by the body's immune system.^{13, 20-22}

PERISOLV[®] shows significant antibacterial activity, which is pronounced even at rather low concentration.² It has further shown markedly higher inactivation rates than chlorhexidine and hydrogen peroxide for the periodontal pathogenic organisms *Porphyromonas gingivalis*, *Prevotella intermedia*, *Aggregatibacter actinomycetem-comitans* and *Fusobacterium nucleatum*. This superior effectiveness at low concentration is of great relevance for application in the tooth pocket. In this case, especially in periodontally infected pockets, a high sulcular fluid rate prevails, and this can cause rapid dilution of topically applied antiseptics/antibiotics.²³

An *in vitro* study at the University of Bern in Switzerland has shown that the specific composition of the preparation increases the inactivation efficacy on an established biofilm compared with standard disinfectants.¹ In this study, the antimicrobial activity of PERISOLV[®], its components and chlorhexidine was investigated on bacterial strains associated with periodontal disease. The effect of the antiseptics on individual bacteria and on an established biofilm consisting of six kinds of bacteria was examined. PERISOLV[®] showed a greater inactivation rate on the biofilm than the chlorhexidine solution did (Figs. 8-11).

The activity of PERISOLV[®] was found to be different for Gram-positive and Gram-negative bacteria. Gram-negative bacteria were inactivated even at a low PERISOLV[®]

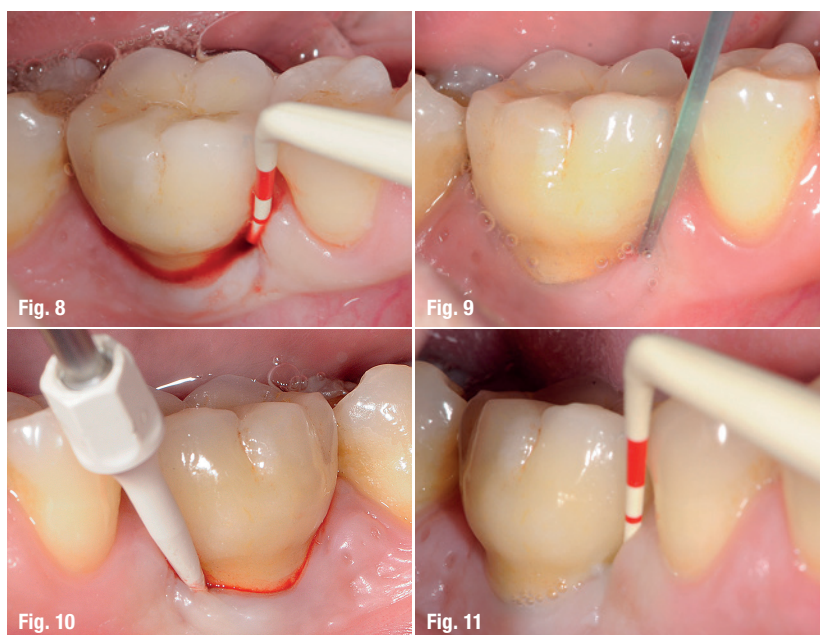

Fig. 8: Clinical situation of the peri-implant mucositis site. Implant with probing depth ≤ 5 mm and bleeding on probing. **Fig. 9:** Application of PERISOLV[®] before the non-surgical therapy. **Fig. 10:** After an exposure time of 30 seconds, the biofilm was removed non-surgically using an ultrasonic device with a PEEK tip. **Fig. 11:** Situation six months after therapy. Probing depth of ≤ 4 mm and no bleeding on probing.

concentration. This selective inhibition could benefit Gram-positive bacteria, which have a greater association with periodontal health.²⁴ For example, if these bacteria are eliminated, their physiological role in the regulation of blood pressure could be disturbed.²⁵

Conclusion

The adjuvant use of PERISOLV[®] for the decontamination of inflamed periodontal and peri-implant sites is indicated because the slightly alkaline gel softens the extracellular matrix of the biofilm (proteins and polysaccharides), allowing better penetration by the chloramines, which effectively eliminate pathogens. In addition, the immediate inactivation effect of PERISOLV[®] could prevent bacteria from entering the blood stream during mechanical treatment.

All figures: © Vincenzo Iorio-Siciliano

about

Dr Vincenzo Iorio-Siciliano is a professor of periodontology at the University of Catanzaro, Italy, adjunct professor of periodontology and implantology at the University Federico II in Naples, Italy and also works as visiting scientist at the department of periodontology at the University of Bern, Switzerland.

contact

REGEDENT AG
Zollikerstr. 144
8008 Zurich, Switzerland
Tel.: +41 44 7003777
info@regedent.com
www.regedent.com



© mihaulija/Shutterstock.com

CAMLOG

Oral Reconstruction Global Symposium

The Oral Reconstruction Foundation drives progress in implant dentistry and related areas, for the benefit of the patients. Education and training are the Foundation's utmost priorities and are realised through the organisation of high-quality events. With the Oral Reconstruction Global Symposium 2018, formerly International CAMLOG Congress, the foundation intends to build on its successes this April.

In Rotterdam, implant dentistry topics will be presented and discussed in theory and practice through practical workshops, scientific lectures, as well as podium and audience discussions. Under the theme "The Future of the Art of Implant Dentistry", a diversity of

education and training will be offered thanks to the combination of instructive workshops, an informative scientific programme with top-class speakers, an innovative event concept, and a high-end evening event for networking with opinion leaders and colleagues.

Register now for the Oral Reconstruction Global Symposium 2018: www.orfoundation.org/globalsymposium

Oral Reconstruction Foundation
Margarethenstr. 38
4053 Basel, Switzerland
www.orfoundation.org

Hager & Meisinger

Long carbide instruments for peri-implantitis treatments

Newly introduced in Spring 2017, Meisinger offers a new Periimplantitis Kit, a comprehensive range of perfectly matched carbide finishing burs for the treatment of ignited implant sites. The handler can choose from eight high-grade tungsten carbide finishing burs in egg and flame shape for every individual patient case. Both shapes come in two different sizes (diameter: 1.4 and 2.3mm) and each in standard and extra fine toothings. All finishers in the set have an extra-long FG



shank with a total length of 32 mm which specifically allows the treatment of difficult to access, deep implants. Due to different shapes and sizes of the instruments, the Periimplantitis Kit provides an ideal intraoral treatment of titanium and manages clean and smooth surfaces.

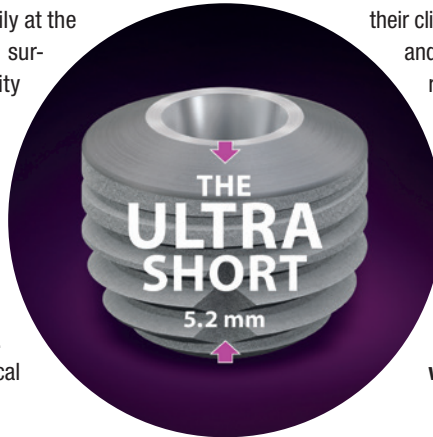
Hager & Meisinger GmbH
Hansemanstraße 10
41468 Neuss, Germany
www.meisinger.de

bredent medical

New ultra-short implant

With the new copaSKY, an ultra-short implant with a length of 5.2mm and a diameter of 4.0, 5.0 or 6.0 mm, bredent medical is expanding its SKY implant family at the start of 2018. Thread design and special surface finish guarantee high primary stability and rapid osseointegration.

copaSKY offers a good solution for short, wide alveolar ridges with reduced bone volume. The available bone is used optimally thus avoiding time-consuming augmentations. The conical parallel-walled connection on the implant is reversible and can be calculated in terms of height. Restoration in patients with physiological



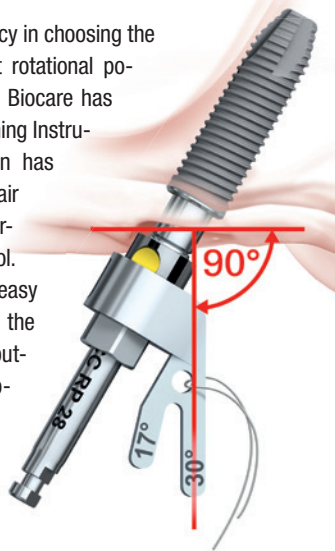
high-performance polymers, such as BioHPP, is particularly recommended. Dentists can easily integrate the indication into their clinical workflows thanks to the proven surgical and prosthetic protocol. Only a special drill set is required for the ultra-short implant. The prosthetics portfolio is clearly arranged, almost reduced. Nevertheless, all requirements can be met. This generates a reliable process and low costs for the practice.

bredent medical GmbH & Co. KG
Weißenhörner Straße 2
89250 Senden, Germany
www.bredent-medical.com

Nobel Biocare

Increased efficiency in Multi-unit Abutment treatments

For ease, speed and efficiency in choosing the correct Multi-unit Abutment rotational position and angulation, Nobel Biocare has designed the Multi-unit Aligning Instrument. This latest innovation has been designed to reduce chair time by indicating three different angulations using one tool. The instrument makes it easy to identify the angulation of the most-suitable Multi-unit Abutment and the rotational position of the implant, helping to optimise the final abutment position and prosthetic design. This is further helped by easy-to-see laser-etched markings. Clinicians can easily identify the screw-hole trajectory to avoid facially protruding screws and optimise prosthesis design. The instrument is particularly beneficial for the All-on-4® treatment concept procedure, both for improving the speed and efficiency of experienced clinicians, and in supporting new clinicians in making the correct choice of Multi-unit Abutment and determining the desired rotational position of the implant.



Nobel Biocare Services AG
P.O. Box
8058 Zurich-Airport, Switzerland
www.nobelbiocare.com

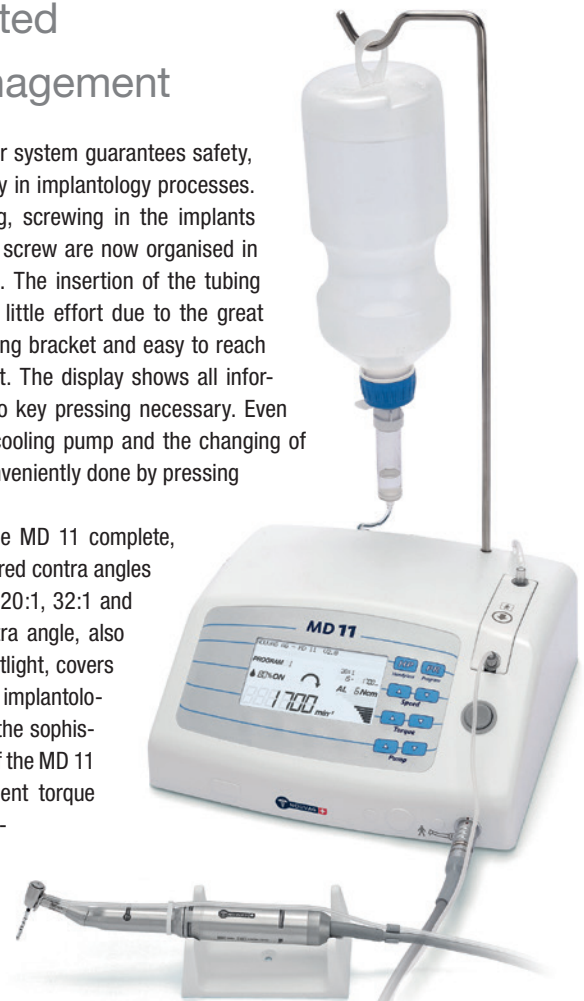Nouvag

Sophisticated motor management

Nouvag's MD 11 motor system guarantees safety, precision and reliability in implantology processes. Drilling, thread cutting, screwing in the implants and placing the cover screw are now organised in separate programmes. The insertion of the tubing set is done with very little effort due to the great visibility of the mounting bracket and easy to reach notches in the bracket. The display shows all information at a glance, no key pressing necessary. Even the activation of the cooling pump and the changing of the pump speed is conveniently done by pressing switches on the pedal.

To make the set of the MD 11 complete, Nouvag offers all required contra angles such as the 1:1, 16:1, 20:1, 32:1 and a 70:1. The 20:1 contra angle, also available with LED spotlight, covers the largest field of the implantologists tasks, thanks to the sophisticated motor control of the MD 11 which provides sufficient torque from the lowest possible speed of 15rpm to the highest speed of 1,700 rpm.

Nouvag AG
St. Gallerstr. 23-25
9403 Goldach, Switzerland
www.nouvag.com



Bicon

Time-proven design

The Bicon SHORT® Implant is an example of a time-proven geometric design that successfully transfers the occlusal forces on its prosthesis to its surrounding bone by appropriately integrating the following features: a bacterially-sealed, 1.5 degree locking taper abutment to implant connection and a subcrestally placed, sloping shouldered implant with a plateaued tapered root form body. Additionally, these integrated features compensate for the implant's ankylosed nature by successfully transforming occlusal forces to acceptable strains within the bone, provide for healthy and gingivally aesthetic peri-implant tissues, as well as for the



callus formation of cortical like bone with central vascular systems. The entirety of this design offers the patient and clinician alike the ability to place an implant in edentulous sites where there is minimal bone height.

Bicon Europe Ltd.
Hauptstraße 1
55491 Büchenbeuren
Germany
www.bicon.com

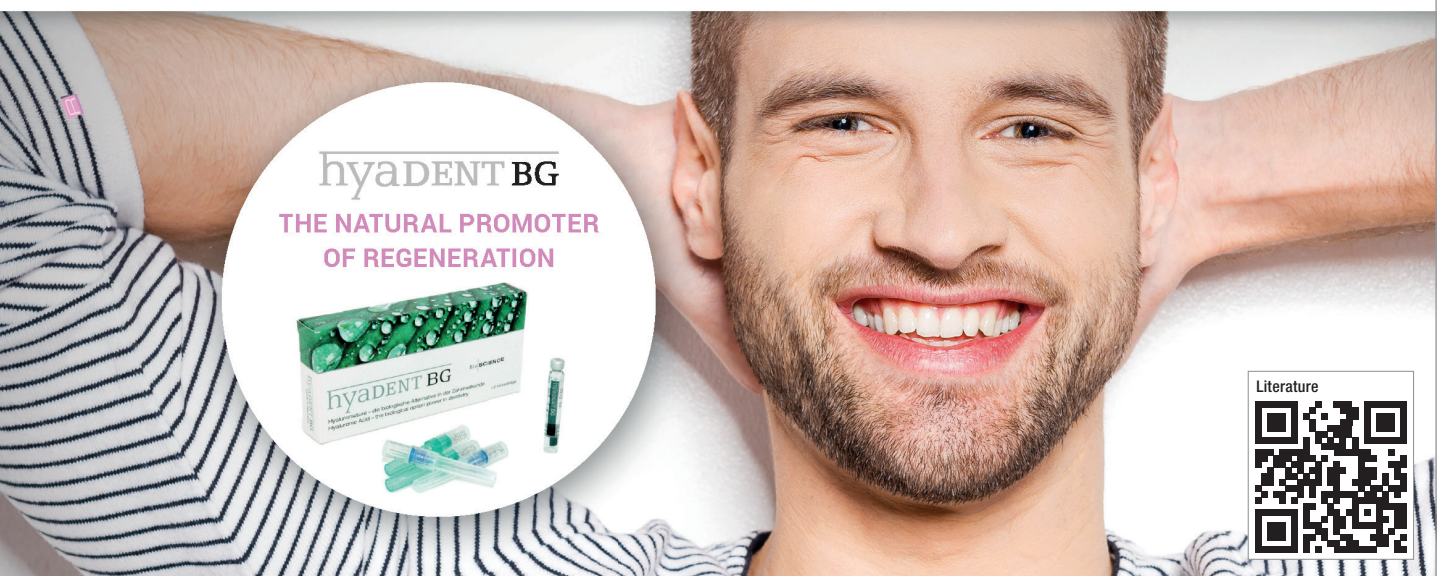REGEDENT

Natural promoter of regeneration

HYADENT BG, a highly concentrated and cross-linked hyaluronic acid gel, is specifically designed for the application in the dental field. Hyaluronic acid (HA), as one of the main components of the extracellular matrix is naturally present in the human body.¹⁻³ Studies have shown that prolonged presence of HA during the healing process promotes healing by regeneration rather than reparation.^{4,5} Besides accelerating the healing of soft tissue and bone,⁶⁻⁸ the bacteriostatic properties of HA also protect the wound.⁹ HYADENT BG remains present throughout the various phases of the healing process due to its slow degradation pattern (several weeks).¹⁰ In addition, it aids the surgical

periodontal treatment after application to the root surface and soft tissue. This leads to faster wound closure, substantial pocket reduction and enhanced attachment.¹¹⁻¹³ When mixed with bone substitution material of any origin the product forms an easily manageable putty, which may additionally lead to accelerated bone formation.^{14,15}

REGEDENT AG
Zollikerstr. 144
8008 Zurich, Switzerland
www.regedent.com



29 & 30 June 2018, Berlin

International Congress on Ankylos 2018



Dentsply Sirona

International congress in Berlin

On 29 and 30 June 2018, Dentsply Sirona Implants will be welcoming the global implant dentistry community in Berlin, Germany, following the principle "Trust experience. Discover excellence." The international congress will be focused on the Ankylos Implant System, whose TissueCare concept delivers long-term hard- and soft-tissue stability, high performance and lasting aesthetic results. Together with the scientific chairman Dr Paul Weigl from the University of Frankfurt am Main, Germany, Dentsply Sirona Implants will present an interesting programme with internationally renowned speakers and exciting topics—including

complete digital workflows of the field of implantology and further solutions of the comprehensive company portfolio. For the detailed congress programme and additional information visit www.ankyloscongress.com.

**Dentsply Sirona –
The Dental Solutions Company™
Sirona Straße 1
5071 Wals/Salzburg, Austria
www.dentsplysirona.com/implants**

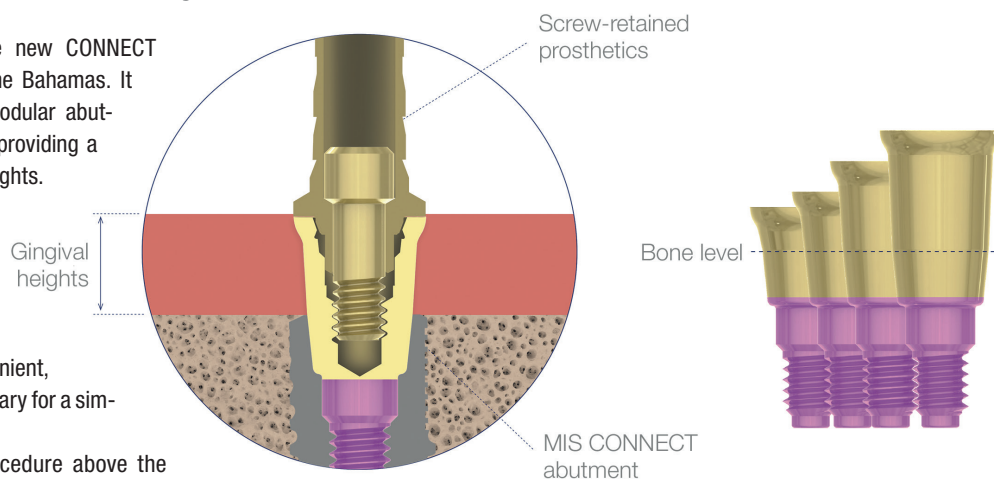
MIS

Introducing a new abutment system

This past February, MIS introduced the new CONNECT system at the 4th Global Conference in the Bahamas. It features an intra-gingival, narrow and modular abutment and is designed with a low profile, providing a tissue-level solution for various gingival heights.

Because of its versatility the system may be applied in multiple or single-unit restorations, for both digital and traditional procedures. It can also be used for provisional or final prosthetic restorations. It is easy to handle and convenient, and is supplied sterile with the tools necessary for a simple procedure.

The CONNECT enables a prosthetic procedure above the connective tissue level. It allows for a broader range of screw-retained prosthetics in the aesthetic zone and may be used in one- or two-stage procedures. The system supports long-term biological stability by increasing the distance from the bone. Additionally, in CAD/CAM restoration planning, the abutment may be scanned and incorporated into a partially or fully digitally-guided procedure.



**MIS Implants Technologies GmbH
Simeons carré 2
32423 Minden, Germany
www.mis-implants.com**

Infection Control Early Detection of Peri-implantitis

University of Sydney
University of Western Australia
Perth Periodontal Specialists



Peri-implantitis prevention

Source: Dental Tribune International

In addition to maintaining a specialist periodontics practice in West Perth, Australia, and serving as the Editor-in-Chief of the *Clinical Oral Implants Research* journal, Periodontist and implant specialist Dr Lisa Heitz-Mayfield holds several academic positions, including that of adjunct professor at the University of Western Australia and the University of Notre Dame Australia.

Dr Heitz-Mayfield has emphasised the importance of preventive strategies and early diagnosis regarding peri-implant disease, and found time for an interview on the topic which she also addressed at the 26th Annual Scientific Meeting of the European Association for Osseointegration (EAO), held in October in Madrid in Spain.

What were some of the key messages of your presentation during the EAO meeting?

In brief, my presentation focused on diagnosis and treatment planning for implant procedures in relation to the high prevalence of peri-implantitis. I emphasised the importance of achieving infection control prior to implant placement—this involves conducting a comprehensive examination of the patient to determine whether there are any problems, such as periodontal disease or any other intraoral infections.

I highlighted the need, particularly for a periodontal patient, to have been fully treated beforehand so that he or she doesn't have active periodontal disease when any implants are placed. The patient should have already gone through the entire process of infection control and should ideally be in a supportive periodontal therapy

programme with good compliance and maintenance before receiving an implant.

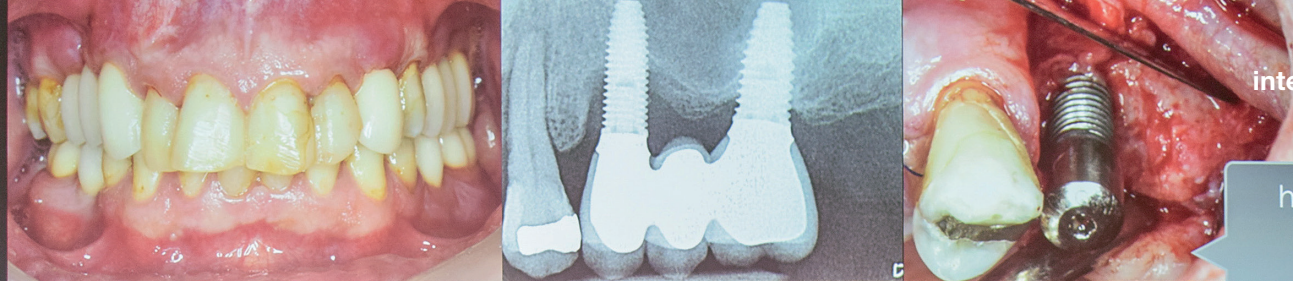
What is involved in this infection control?

Firstly, one needs to eliminate any deep periodontal pockets. We have good evidence today that supports the idea that the presence of residual periodontal disease is a risk factor for patients developing peri-implantitis at a later date. Infection control also means that patients must have really good oral hygiene. They must have low full-mouth plaque scores, which again is strongly supported by evidence that suggests patients with poor plaque control are at a much greater risk of developing peri-implantitis.

Of course, once one has achieved good infection control, one then needs to ensure that there will be good access for cleaning the implant site once the prosthesis has been placed. This will allow the patient to continue infection minimisation practices at home. If one designs a prosthesis that is inaccessible through the patient's cleaning habits, it is simply more likely that he or she will contract an infection later on.

As a practising periodontist, how have you implemented a preventive approach to infection control?

Having good infection control before placing implants is crucial, as it is the best way to prevent these infections occurring later on. When I am planning for implant procedures, I make sure that I start with a good foundation where any infection has been dealt with and that the patient has displayed good compliance and is likely to con-



heavy smoker
FIFO worker
married
bruxer



Figs. 1 & 2: Dr Lisa Heitz-Mayfield at the 26th EAO Meeting in October 2017, highlighting the importance of infection control. Photos: © DTI

tinue to do so. That is the key to prevention: to make sure that the patient has a healthy oral cavity with little plaque and no periodontal disease before one starts.

A preventive approach requires several elements to work effectively: regular monitoring and supportive periodontal therapy with professional biofilm control, a healthy and regular at-home oral hygiene routine, and controlling for other risk factors, such as smoking and uncontrolled diabetes. By managing these potential issues, dental professionals and patients can work together to help prevent the recurrence of periodontal disease and occurrence of peri-implantitis.

How important is it to properly motivate a patient to engage in these preventive measures and understand what the role of a good oral hygiene routine is?

It is extremely important. Again, it is key that, right at the beginning of the treatment planning phase, patients are informed of the risk of complications if they do not maintain good oral hygiene supplemented with regular professional care. Recent literature shows that patients with implants must receive check-ups and supportive care at least twice a year. For patients who have lost their teeth owing to periodontal disease, we know that they are at a higher risk of having similar problems around their implants. These patients then really need to understand and be informed of the importance of good oral hygiene and regular preventive, supportive care prior to engaging in the rather costly business of getting an implant.

What role does regular professional prophylaxis play in preventing peri-implantitis?

It comes back to the responsibilities of dental professionals: they need to identify early signs of inflammation, such as peri-implant mucositis, which is an inflammation of the soft tissue, and treat that before it develops into peri-implantitis and initiates bone loss. Evidence shows that management of peri-implant mucositis is a prerequisite for the primary prevention of peri-implantitis.

Removing the harmful biofilm from the exposed surface of an implant with peri-implantitis, though, can be very challenging. There is a different morphology to it, along with a modified surface that is often rough and tends to harbour the biofilm in a way that it is very difficult to remove. However, as with periodontal disease, it's much easier to manage and treat peri-implant disease before it becomes too severe. The best way to prevent it is through early detection of the signs of inflammation so that treatment that reverses this process can take place.

From a prophylactic point of view, the periodontally healthy patient is the best patient. Do you agree?

Of course. It is really important that patients have good periodontal health so that they do not have deep periodontal pockets and reservoirs of bacteria that could lead to colonisation of biofilm around the implants. Patients need to come for check-ups on a regular basis so that the early signs of disease can be identified and dealt with. In addition, we should remember that, sometimes, things can go wrong around implants; for example, if a patient has a screw-retained restoration and there is a mechanical problem or technical issue, such as a loosened screw, then a problem with bacterial accumulation may arise and peri-implantitis may develop. Though periodontal health is important, regular check-ups of the prosthesis and the patient's overall oral health are also crucial in preventing not just peri-implantitis but other intraoral issues as well.

Thank you very much for the interview.

contact

Dr Lisa Heitz-Mayfield
University of Western Australia
University of Sydney
Perth Periodontal Specialist
Perth, Australia
heitz.mayfield@inet.net.au

Managing **aesthetic** challenges

Europe & Latin America International Congress



Fig. 1

Fig. 1: Alpha-Bio Tec's CEO Yuval Grimberg highlighting the company core values at the international congress in Madrid.

Alpha-Bio Tec's International Congress for the company's European and Latin American customer network took place in Madrid, Spain, from 10 to 11 November 2017.

The congress, which was tailored for global dental professionals and hosted 14 international keynote speakers from 12 countries, offered delegates from more than 30 different nations exclusive experiences regarding the latest strategies and methods in aesthetic implant treatments. It was an opportunity for Alpha-Bio Tec dental professionals to share their knowledge and expertise on some of the current key challenges in dentistry and implantology.

750 participants from all over the world attended the congress, which focused on one of the most important topics facing dental implantology today—the management of aesthetic challenges in implant treatment strategies, illustrating the importance of aesthetics in addition to biological compatibility and product quality.

The congress also showcased the company's innovative NeO implant system, the AlphaUniverse Multi Unit, and the graft products. Also presented was the line of digital enablers products, including the market-winning CAD/CAM and guided surgery tool kit.

"Beyond giving our customers the platform to share knowledge and experiences on the crucial challenges facing implantologists around the world, this congress brought forward our core principles of customer value, quality, simplantology, implant expertise and our excellent Training & Education programme, which manifested itself through a line of 14 leading international speakers demonstrating professionalism at its best," stated Shani Biran, Alpha-Bio Tec Head of Marketing.

The congress thus demonstrated Alpha-Bio Tec's abilities to reach high professionalism and aimed at highlighting the company's values of excellence and service.

Join Alpha-Bio Tec at the 2018 regional congresses:

- Monte-Carlo, Monaco: 18–19 October 2018
- Cartagena, Colombia: 23–24 November 2018

contact

Alpha-Bio Tec
 4 Hatnufa St. P.O. Box 3936
 Kiryat Arye, Petah Tikva
 49510 Israel
www.alpha-bio.net

SUBSCRIBE NOW!

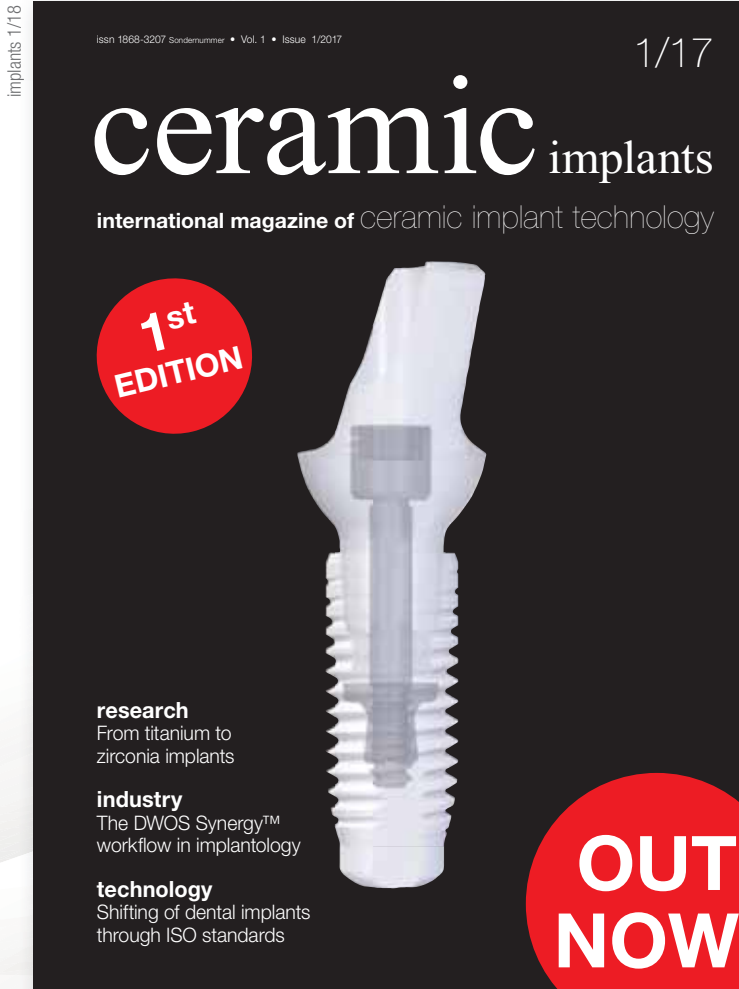ceramic implants—international magazine of ceramic implant technology

Interdisciplinary, transparent & market orientated

ONLINE
SUBSCRIPTION HERE



www.oemus-shop.de



stay updated:

research

From titanium to zirconia implants

industry

The DWOS Synergy™ workflow in implantology

technology

Shifting of dental implants through ISO standards

Fax: **+49 341 48474-290**

I would like to subscribe for the following journals:

- ceramic implants—international magazine of ceramic implant technology 2 issues p.a. € 30*
- implants—international magazine of oral implantology 4 issues p.a. € 44*

Terms & Conditions: The subscription may be cancelled in written form without due justification within 14 days of order by contacting OEMUS MEDIA AG, Holbeinstraße 29, 04229 Leipzig, Germany. Dispatching notification in good time will suffice. The subscription is automatically extended by another twelve months if it is not cancelled in written form 6 weeks prior to the end of the reference period.

* All prices include VAT, shipping and handling (within Germany).

Last Name, First Name

Company

Street

ZIP/City/Country

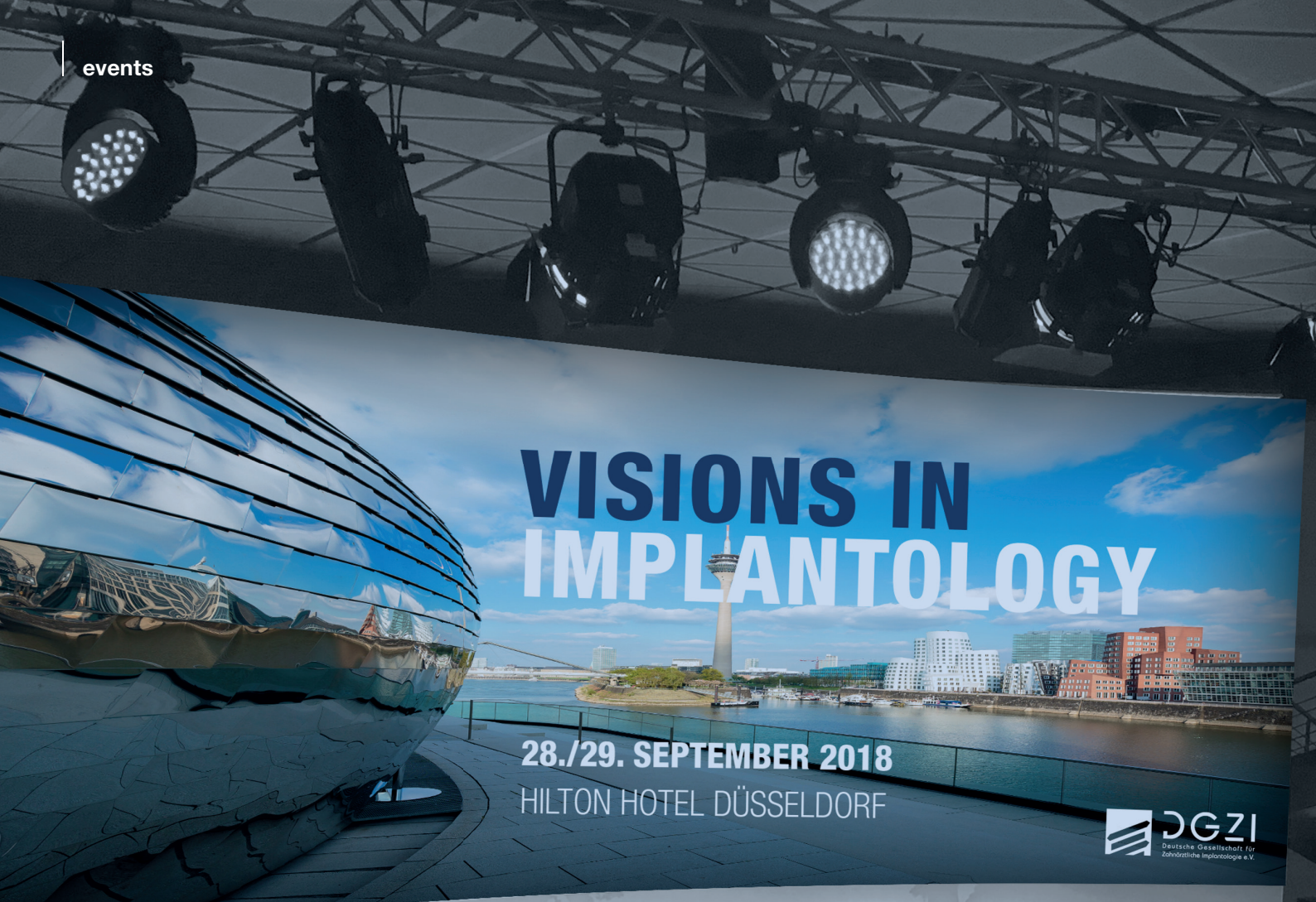E-Mail

Signature

Credit Card Number

Expiration Date

Security Code



VISIONS IN IMPLANTOLOGY

28./29. SEPTEMBER 2018
HILTON HOTEL DÜSSELDORF



Visions in Implantology

1st Future Congress in Dental Implantology

At its 48th International Annual Congress, the German Association of Dental Implantology (DGZI) is launching a completely new concept. In terms of content as well as in terms of the process and structure of the congress, new territory is being explored. The participants can expect an exciting, versatile and practical implantology event.

The DGZI is one of the most traditional European dental implantology societies. Right from the start, it has provided decisive impulses without which modern implant dentistry as one of the absolute trend disciplines of modern dentistry would not be conceivable today. Implantology was based on the established dentists. Today, this medical field undergoes a development in the interplay of practitioners, universities and industry, which was almost unimaginable. In this context, it is important for the DGZI to stay up to date and constantly face the new challenges of a rapidly developing training landscape. Thus, not only the competition has become stronger, but also the members of the DGZI, the participants in the DGZI congresses and curricula meanwhile set different premises. Efficiency, practical utility and a varied scientific programme are more and more in the spotlight today. Among other things for these reasons, the DGZI organises its annual congresses after a completely new concept in terms of content and organisation starting with the 48th International Annual Congress in 2018.

Under the motto "Visions in Implantology", the 1st Future Congress for Dental Implantology of the DGZI will raise new questions, and try to provide answers in the interaction between participants, speakers and the industry, and to point out new ways. This new content claim is also reflected in a completely new organisational concept. Specifically, this means that on the one hand the fragmentation in various podiums, workshops and side programmes will be repealed, and on the other hand, the profile of the congress as an event for practitioners will be sharpened. With the division into a so-called industrial day on Friday with strategy lectures, video transmission of live operations and table clinics as well as a pure science day on Saturday, the informational needs of the established implantologist in particular shall be better taken into account.

Explicitly, the industry is becoming more important through the table clinics and an exhibition concept, which will also be a spatially integral part of the programme.

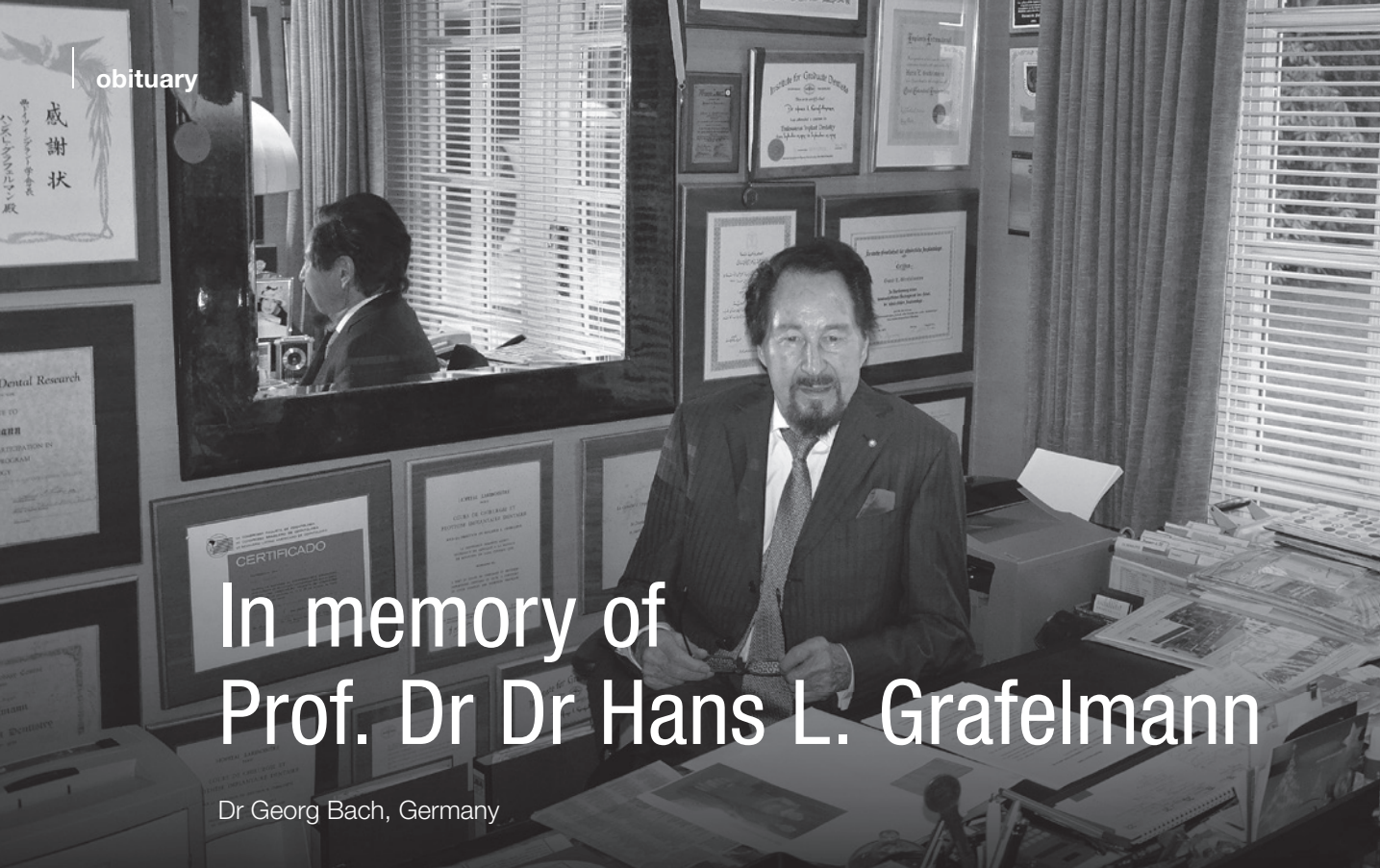Modern tools such as the future podium, innovative presentation techniques, a web-based digital poster presentation or even interactive solutions will raise the profile of the congress more in the direction of a congress fair. This is also reflected in a new catering concept with flying service. The gaps between the lecture programme, live surgeries and table clinics are thus increasingly dissolved and participants, speakers and industry are given more room to communicate.

The scientific lecture programme, the panel discussions, the transmission of live surgeries as well as the table clinics will take place on both days completely in the main podium, which also is an exhibition area. Except for the table clinics, all parts of the programme will be translated simultaneously (German/English) on both days of the congress. This will also increase the attractiveness of the congress for international participants. Renowned speakers from Germany and abroad, representatives of friendly international professional societies, industry partners and of course the participants from Europe, the USA, Asia and the Arab countries will create and experience an outstanding, innovative training event.

The goals of this modification are future orientation, organisational modernity, content attractiveness and a new way of presenting perspectives in order to reach a new level of interaction from the different perspectives of science, practice and industry. The 1st Future Congress in Dental Implantology will in particular address the question of what implantology will look like in five or maybe ten years. Ultimately, apart from scientific and technological aspects, it is also about strategic questions with regard to the implantological practice of the future. The DGZI will once again prove its importance and attraction, also in view of the 50th anniversary of its foundation, which is due to happen in 2020.

contact

OEMUS MEDIA AG
 Holbeinstraße 29
 04229 Leipzig, Germany
 Tel.: +49 341 48474-308
 kontakt@oemus-media.de
 www.oemus.com



In memory of Prof. Dr Hans L. Grafelmann

Dr Georg Bach, Germany

“Anyone who has visions should see a doctor!”—who doesn’t know this possibly a little overly used quote of the former German chancellor Helmut Schmidt. Hans L. Grafelmann did not see a doctor but rather worked unimpressed and resolutely on realising his visions. Thus when the above stated sentence was spoken during the parliamentary elections in 1980, one of Grafelmann’s visions was already having an anniversary: The German Association of Dental Implantology (DGZI) was celebrating its first decade of existence.

In order to reach such an anniversary, it really needed visions and more importantly visionaries. Hans L. Grafelmann was one of these visionaries. The dentist from Bremen was one of the first in Germany to adopt the idea of oral implantology, until then mainly originating from North America, and he was further one of the first practitioners inserting the implants available at that time. Thus our colleague Grafelmann was right from the start part of German implantology.

How important this subject was to him can be measured in terms of the solutions he aimed at finding for practical application problems, like, e.g. general availability of implant products and further by how dear uniting the former implantological elites was to him—resulting in the birth of the DGZI. One might smile to oneself about such problems today, but they visualise in which diaspora Hans L. Grafelmann and his colleagues were moving at the time. In our current days of implantological expert societies with thousands of members, of implantology being taught in universities everywhere and funds of several millions available for oral implantol-

ogy research one cannot honour Grafelmann’s pioneering achievements enough. This should be especially regarded while keeping in mind how in those days he and his allies were confronted with much animosity. It was definitely not in Grafelmann’s genes to give way in such situations, instead he consequently developed his DGZI further and enjoyed watching “his child” flourish. His incredible strength in networking and his communicative, humorous personality being especially beneficial. Hans L. Grafelmann stayed connected to our association his whole life and even after retiring from the operative business he was always interested in its developments.

Needless to say that such achievements as I am describing here, did not stay unnoticed, especially by those intensively involved in implantology. Strong symbols of this appreciation were the various honours and doctor’s degrees he received. They are too numerous to list them all here, but I am entirely sure that Hans L. Grafelmann would not have cared, as for such he was of much too humble and unpretentious personality.

How much we would have liked to have our honorary president on stage for our 50th anniversary. It goes without saying that we will be organising this anniversary congress in Bremen, Germany, to return to the founding location of our association and also to the home of our honorary president. How much we would have liked to receive his advice and to have him by our side for many more years.

Unfortunately, we now how to say goodbye to Hans L. Grafelmann. On behalf of the DGZI family I would like to say a last “Thank you!”.

Senior Premium Partner
otmedical[®]

Premium Partner
camlog

Premium Partner
straumann
simply doing more

Premium Partner
ACTEON
Germany

VISIONS IN IMPLANTOLOGY

1ST FUTURE CONGRESS
FOR DENTAL IMPLANTOLOGY

28 + 29 SEPTEMBER 2018

NEW
SAVE THE
DATE

48TH DGZI INTERNATIONAL ANNUAL CONGRESS
HILTON HOTEL DÜSSELDORF, GERMANY

WWW.OEMUS.COM

OEMUS MEDIA AG · Holbeinstraße 29 · 04229 Leipzig, Germany · Tel.: +49 341 48474-308 · Fax: +49 341 48474-290 · event@oemus-media.de

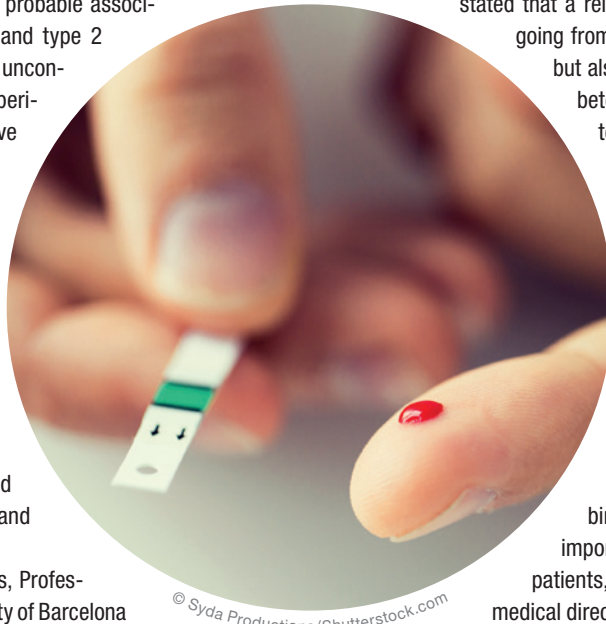DGZI
Deutsche Gesellschaft für
Zahnärztliche Implantologie e.V.

Periodontal treatment achieves

Improved control of type 2 diabetes

Several studies have indicated a probable association between poor oral health and type 2 diabetes, and it was found that if uncontrolled it leads to gingivitis and periodontitis. Spanish researchers have now discovered further evidence for the connection between periodontitis and type 2 diabetes. Their recent study “Benefits of non-surgical periodontal treatment in patients with type 2 diabetes mellitus and chronic periodontitis (...)” showed that control of type 2 diabetes improved notably after the patient underwent scaling and root planing using ultrasound and curettage.

Head of the study Dr Miguel Viñas, Professor of Microbiology at the University of Barcelona



stated that a relation does not only exist between going from diabetes to periodontal diseases, but also from periodontal disease to diabetes. 90 patients with type 2 diabetes participated in the research and were randomly assigned to either the treatment or the control group. Treatment group participants received oral hygiene instructions and underwent scaling and root treatment. “The main conclusion of the study is that non-surgical treatment of periodontitis improves the glycaemic status and the levels of glycated haemoglobin, and therefore proves the great importance of oral health in diabetic patients,” summarised Prof. José López, medical director of the university’s dental clinic.

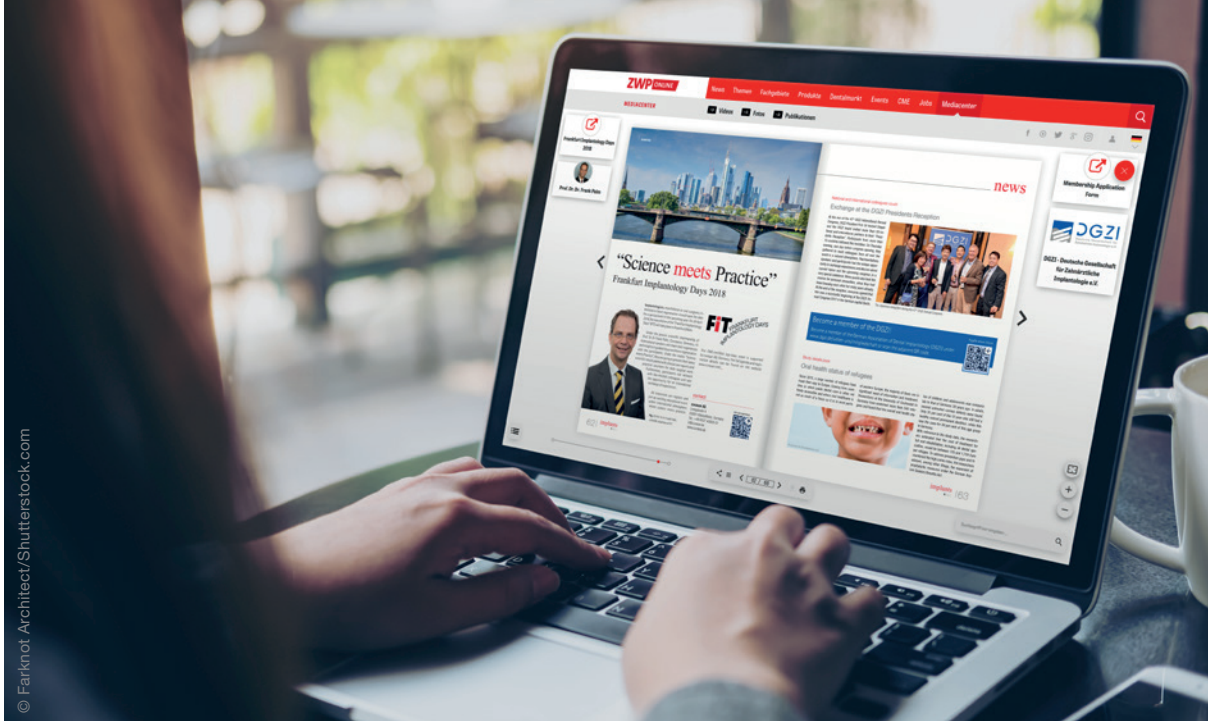Only small adjustments needed to

Better treatment of autistic children

Treatment of autistic children can be challenging even for experienced clinicians. According to research of the Plymouth University Peninsula Schools of Medicine and Dentistry, key factors for a less stressful visit to the dental practice were how confident parents behaved and how good the communication between parents and treatment staff was. Supported by the National Institute for Health Research Collaboration for Leadership in Applied Health Research and Care South West Peninsula, the research was conducted in partnership with the Peninsula Cerebra Research Unit (PenCRU) and members of the PenCRU Family Faculty, a group of parents of disabled children. Based on interviews with parents of autistic children, the study found

that they particularly reacted to negative feelings and the attitudes of those around them in the treatment room. In addition, it was found that parents should feel confident to advocate for their child’s individual needs, as well as help dental professionals understand the small changes they could incorporate to make a big difference. If the children were given a say about small things involved in their treatment, e.g. the colour of mouthwash or brightness of the lights, their experience was significantly better. Furthermore, clear referral pathways to specialist dental services will be needed to avoid any delay and distress for families whose children are not yet able to cope with conventional dental settings.





implants now also available in

Newly improved e-paper player

implants—international magazine of oral implantology can now be read online in a freshly improved e-paper design. The new version was launched at the beginning of 2018—the e-paper player having been completely refurbished—and is now offering readers an even more user-friendly experience with new features and an even clearer navigation structure. The entire print portfolio of the OEMUS MEDIA publishing house is available online through the improved player.

The interactive content menu assures an easy orientation within the entire issue proving a comfortable navigation already at the first click. Additional multimedia information—like videos, photo

galleries, literature references and product information—is now accessible through a slim flyout menu located above the e-paper, thus the reader is not redirected to a new tab, but at a glance gets a clear overview. Author and company profiles on ZWP online have been optically improved and are highlighted through the new design. The innovative e-paper player is, hence, corresponding to the extended communicative and technical possibilities of the dynamic developments in dental online media.



Source: OEMUS MEDIA AG

Stem cells might

Accelerate implant healing

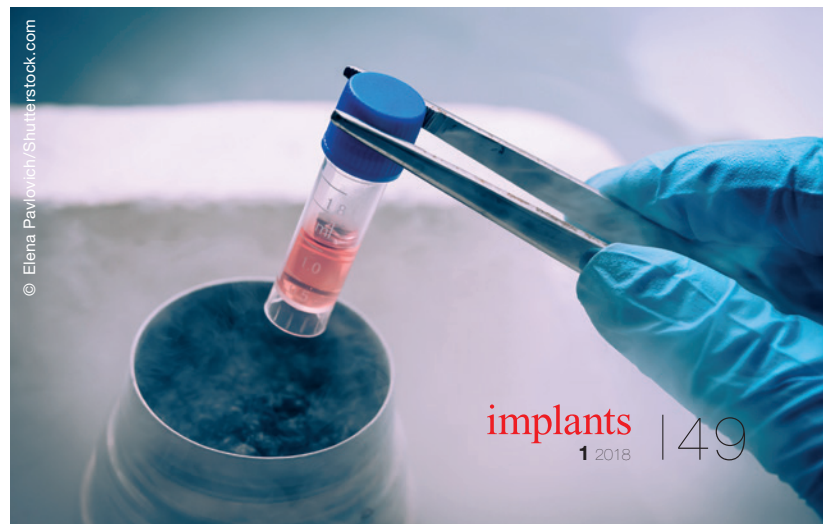Scientists from Northern Germany are currently working on an interdisciplinary approach for a new implant technology. The research project funded by the Ministry of Economic Affairs of the German state of Mecklenburg-Western Pomerania combines project partners from both science and economy, including the Institute of ImplantTechnology and Biomaterials, an Associated Institute of Rostock University.

In order to properly load implants into the jaw, it is often necessary to stimulate bone regeneration or use bone replacement material. The healing process of the latter has so far been more complicated and time-consuming. The project team is therefore researching the possibilities of colonising the bone material with stem cells of the patient. The stem cells' potential of stimulating bone growth and regeneration shall thus improve the healing process.

The main goal of the scientific research cooperation is to develop a procedure for the even colonisation of bone material with stem cells. The researchers have thus developed a so-called bio reactor in order to manage this process under specifically defined environ-

mental conditions. The development of such a reactor prototype has been a milestone in the research project. The first stem cell colonisation experiments have already shown promising results. If and to what extent the colonised material can reduce the implant healing time will be further researched until the end of 2019.

Source: Rostock University



Congresses, courses and symposia



Oral Reconstruction Global Symposium 2018

26–28 April 2018

Venue: Rotterdam, Netherlands
symposium2018.orfoundation.org



EuroPerio9

20–23 June 2018

Venue: Amsterdam, Netherlands
www.efp.org/europerio9



4th Annual Meeting of ISMI

22–23 June 2018

Venue: Hamburg, Germany
www.ismi.me



International Congress on Ankylosis 2018

29–30 June 2018

Venue: Berlin, Germany
www.ankyloscongress.com



Visions in Implantology— 1st Future Congress in Dental Implantology

28–29 September 2018

Venue: Düsseldorf, Germany
www.dgzi-jahreskongress.de

implants

international magazine of oral implantology



Deutsche Gesellschaft für
Zahnärztliche Implantologie e.V.



Imprint

Publisher

Torsten R. Oemus
oemus@oemus-media.de

CEO

Ingolf Döbbecke
doebbecke@oemus-media.de

Members of the Board

Jürgen Isbaner
isbaner@oemus-media.de

Lutz V. Hiller
hiller@oemus-media.de

Chief Editorial Manager

Dr Torsten Hartmann
(V. i. S. d. P.)
hartmann@dentalnet.de

Editorial Council

Dr Rolf Vollmer
info.vollmer@t-online.de

Dr Georg Bach
doc.bach@t-online.de

Dr Suheil Boutros
SMBoutros@aol.com

Editorial Office

Georg Isbaner
g.isbaner@oemus-media.de

Katharina Rühling
k.ruehling@oemus-media.de

Executive Producer

Gernot Meyer
meyer@oemus-media.de

Product Manager

Timo Krause
t.krause@oemus-media.de

Art Director

Alexander Jahn
a.jahn@oemus-media.de

Designer

Sandra Ehner
s.ehner@oemus-media.de

Theresa Weise

t.weise@oemus-media.de

Customer Service

Marius Mezger
m.mezger@oemus-media.de

Published by

OEMUS MEDIA AG
Holbeinstraße 29
04229 Leipzig, Germany
Tel.: +49 341 48474-0
Fax: +49 341 48474-290
kontakt@oemus-media.de

Printed by

Silber Druck oHG
Am Waldstrauch 1
34266 Niestetal, Germany

implants

international magazine of oral
implantology is published in cooperation
with the German Association of Dental
Implantology (DGZI).

DGZI

DGZI Central Office
Paulusstraße 1
40237 Düsseldorf, Germany
Tel.: +49 211 16970-77
Fax: +49 211 16970-66
office@dgzi-info.de

www.dgzi.de

www.oemus.com

www.implants.de

Copyright Regulations

implants international magazine of oral implantology is published by OEMUS MEDIA AG and will appear in 2018 with one issue every quarter. The magazine and all articles and illustrations therein are protected by copyright. Any utilisation without the prior consent of editor and publisher is inadmissible and liable to prosecution. This applies in particular to duplicate copies, translations, microfilms, and storage and processing in electronic systems. Reproductions, including extracts, may only be made with the permission of the publisher. Given no statement to the contrary, any submissions to the editorial department are understood to be in agreement with a full or partial publishing of said submission. The editorial department reserves the right to check all submitted articles for formal errors and factual authority, and to make amendments if necessary. No responsibility shall be taken for unsolicited books and manuscripts. Articles bearing symbols other than that of the editorial department, or which are distinguished by the name of the author, represent the opinion of the aforementioned, and do not have to comply with the views of OEMUS MEDIA AG. Responsibility for such articles shall be borne by the author. Responsibility for advertisements and other specially labeled items shall not be borne by the editorial department. Likewise, no responsibility shall be assumed for information published about associations, companies and commercial markets. All cases of consequential liability arising from inaccurate or faulty representation are excluded. General terms and conditions apply, legal venue is Leipzig, Germany.

SUBSCRIBE NOW!

implants—international magazine of oral implantology

Interdisciplinary, transparent & market orientated

ONLINE
SUBSCRIPTION HERE



www.oemus-shop.de




stay updated:

research
L-PRF in intraoral applications

case report
**Computer-assisted implant
rehabilitation of tumour patients**

industry
1st Future Congress in Dental Implantology



Fax: **+49 341 48474-290**

I would like to subscribe for the following journals:

implants—international magazine of oral implantology 4 issues p.a. € 44*

laser—international magazine of laser dentistry 4 issues p.a. € 44*

Terms & Conditions: The subscription may be cancelled in written form without due justification within 14 days of order by contacting OEMUS MEDIA AG, Holbeinstraße 29, 04229 Leipzig, Germany. Dispatching notification in good time will suffice. The subscription is automatically extended by another twelve months if it is not cancelled in written form 6 weeks prior to the end of the reference period.

* All prices include VAT, shipping and handling (within Germany).

Last Name, First Name

Company

Street

ZIP/City/Country

E-Mail

Signature

Credit Card Number

Expiration Date

Security Code



Redefine possibilities

Trefoil™ – the next full-arch revolution

The new Trefoil system makes definitive teeth possible in just one day.*

Discover groundbreaking engineering, created with the needs of the many in mind, that enables passive fit with a pre-manufactured bar and unique adjustable fixation mechanism.

nobelbiocare.com/trefoil



*Depending on clinician preference and close cooperation with the laboratory.
GMT 53206. Disclaimer of liability: This product is part of an overall concept and may only be used in conjunction with the associated original products according to the instructions and recommendation of Nobel Biocare. Non-recommended use of products made by third parties in conjunction with Nobel Biocare products will void any warranty or other obligation, express or implied, of Nobel Biocare. The user of Nobel Biocare products has the duty to determine whether or not any product is suitable for the particular patient and circumstances. Nobel Biocare disclaims any liability, express or implied, and shall have no responsibility for any direct, indirect, punitive or other damages, arising out of or in connection with any errors in professional judgment or practice in the use of Nobel Biocare products. The user is also obliged to study the latest developments in regard to this Nobel Biocare product and its applications regularly. In cases of doubt, the user has to contact Nobel Biocare. Since the utilization of this product is under the control of the user, it is his/her responsibility. Nobel Biocare does not assume any liability whatsoever for damage arising thereof. Please note that some products detailed in this Instructions for Use may not be regulatory cleared, released or licensed for sale in all markets. As such, provided patient criteria are met and adequate primary stability is achieved, Nobel Biocare implants allow a fixed provisional restoration to be loaded on the day of surgery.