

Analogous therapy for guided regeneration of lamellar bone tissue

Dr Karl Ulrich Volz, Prof. Dr Dr Ralf Smeets, Dr Martin Chares, Dr Stefan König MSc., Dr Dominik Nischwitz, Dr Alexander Neubauer, Sabine Hutfilz, ZÄ Clara Esquinazi & ZA Paul Kilanowski, Germany & Switzerland

Regarding bone formation, the regeneration of lost bone substance follows indisputable biological laws. The creation of cavities through so-called space makers in combination with the building of a blood clot within, has been a well-known procedure for guided bone regeneration for a long time. Due to growth factors in platelet-derived alphagranula there is a fast incrementation of blood vessels in the blood clot, followed by a fast bone regeneration through callus formation.¹⁻³ Herewith, the osseoinductive characteristics of the periosteum or the Schneiderian membrane can have a positive impact in addition. This form of bone formation leads to a histologically highly vascularised Havers' bone morphology in the long term and is functionally superior to regenerated bone, formed by bone substitution materials, especially regarding the response behaviour by induced pressure.

The new SDS sinus implant of the series "bone growing implants" supports the so-called form of callus bone formation^{4,5} with its specific macro geometry based on the tent pole/sunshade principle, creating a stable and voluminous cavity (bio container) kept open over the necessary time scale, so that by waiving bone substitution material new biological bone of highest quality can be generated.

Objective

The aim of our work has been to develop a reliable surgical procedure without secondary materials for augmentation, which creates suitable bone in the sinus maxillaris evaluated quantitatively and qualitatively in which dental implants can be anchored with high predictability. Besides a significant reduction of surgical risk as well as postoperative complications, and thus surgical stress for the patient, a substantial cost saving can be achieved for the patient.

Material and method

Modified zirconium dioxide implants of SDS Swiss Dental Solutions AG, Switzerland, have been used. On the apical end



they show a disc-like and preferably wide plateau for extensive and risk limited support concerning perforations of the Schneiderian membrane. Simultaneously, there should be created a peri-implant cavity kept open over the required time for creating a bioactive container. In it an entirely autologous and blood clot initiated bone formation should take place, which should

lead to Havers' bone morphology in the long term (Fig. 1).

Biological Principles

Systemic conditions

General ability of the organism to form new bone must be enhanced prior implant insertion. For this purpose, patients were instructed to set their LDL (Low Density Lipoprotein) below 1,2g/l and their vitamin D3 level (25-OH-Cholecalciferol) at greater than 70ng/ml by following a certain diet and by the intake of a specific vitamin and mineral nutrients mix (BASIC IMMUNE, SWISS BIOHEALTH AG). According to the study of Choukroun et al. (2014), the risk of infection reduces and the bone formation accelerates.⁶

Local conditions 1

Improvement of the extracellular matrix by creating a stable cavity formed by the osseous floor of the sinus and the Schneiderian membrane. Palma et al. (2006) showed that new bone is formed in contact to the Schneiderian membrane on a regular basis, also in mere blood clot areas proving the osteoinductive quality of the maxillary sinus membrane.⁷

Local conditions 2

Continuity of the circulation in the newly formed bone. Mammoto et al. (2009) postulate that the long-term maintenance of regenerated bone depends in particular on the maintenance of the bone's blood circulation.⁸



Fig. 1: The two-piece SDS ceramic implant shows a disc-like bulge with soft roundings on the apical end, not only widely supporting the membrane at reduced risk, but also creating a cavity to the thread.

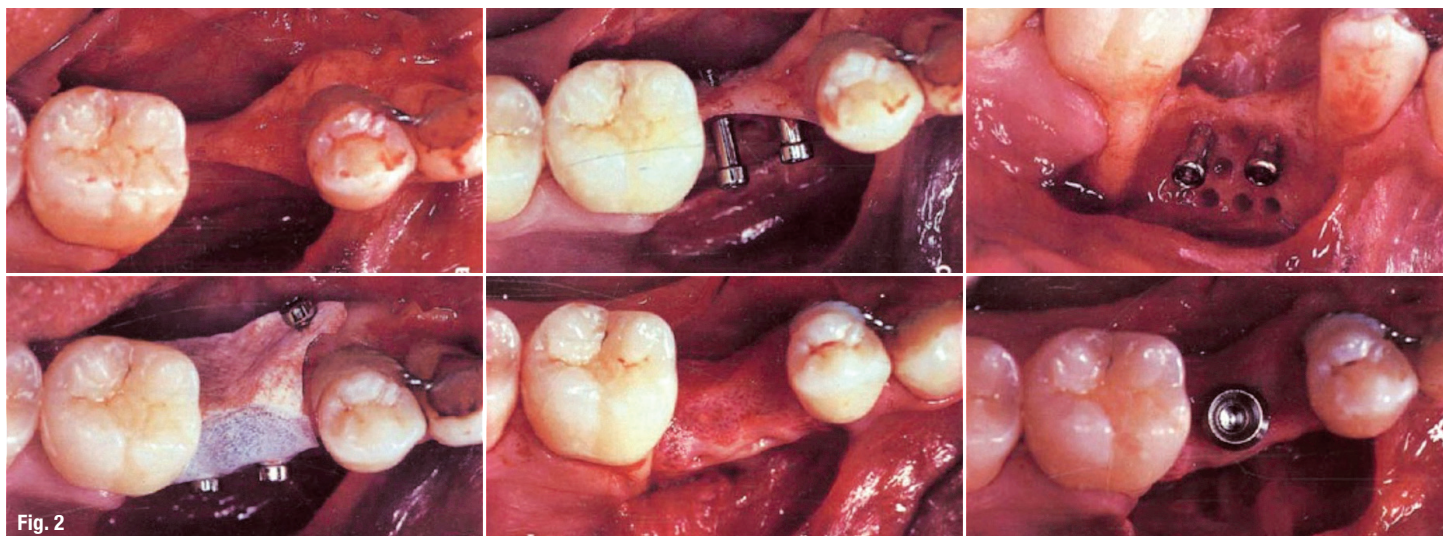


Fig. 2: The tent pole/sunshade principle has been demonstrated impressively in the publication of Hämmerle et al. (2000).⁹

The avoidance of secondary materials for bone replacement increases the amount and extent of a highly vascularised Havers' bone morphology, which develops from an initial vascularisation within an autologous blood clot with subsequent ingrowth of cortical bone transforming to lamellar bone.³

Tent pole/sunshade principle

In 1998, Hämmerle et al. (2000) already have shown that high volumina of new bone could be created by the so-called Memfix® system, without the need of bone block or granular bone graft material.⁹ The periosteum has been kept at a distance through a tent pole (Memfix® screw). In addition, GORE-TEX® membranes have been placed and fixed on one or more tent poles to protect and seal the cavity (Fig. 2).

The significance of the periosteum for bone regeneration is now undisputed. Srouji et al. (2009) noted, that the Schneiderian membrane is periosteum, which produces all necessary humoral and cellular factors needed for bone regeneration, like bone morphogenetic protein 2, only with the presence of a blood clot and without the existence of calcified structures.¹⁰

Further studies show, that the periosteum is an outstanding source for bone forming progenitor cells. Forget et al. (2011) point out the periosteum's ability of local angiogenesis.¹¹ Marolt et al. (2015) show the existence of bone forming stem cells in the periosteum,¹² You-Kyong et al. (2016) conclude:¹³ "Thus, periosteum-derived cells can be expected to be a good source for bone regeneration."

We also know today that no artificial membranes are necessary. The sealed and cavity stable cover of the periosteum or Schneiderian membrane is sufficient to effec-

tively protect the cavity. This waiver then again lowers the risk of infection or a dehiscence and reduces the cost of intervention. The additional insertion of PRF membranes stabilises the blood clot in the cavity and supports the bone and tissue regeneration (Fig. 3).¹⁴⁻¹⁶

According to the idea of Choukroun and Simonpieri, which is a further development of the root disc protocol of Randelzhofer et al. (2016),¹⁷ we fixed zirconia discs on top of SDS ceramic implants when facing extended defects. Complete bone regeneration in the defect could be achieved with the use of A-PRF (Fig. 4). Asymmetric bulges on ceramic implants (SDS balcony implant) also lead to a full bone regeneration by sealing the adjacent socket and due to the sunshade effect (Fig. 5).

Literature research

Various groups have done intensive research on generating new bone in the maxillary sinus without bone substitution material:

1. Palma et al. (2006) have shown, that new bone is regularly formed by being in contact with the Schneiderian membrane in mere blood clot areas and thus showing the osteoinductive potential of the membrane ("New bone is frequently deposited in contact with the Schneiderian membrane in coagulum-alone sites, indicating the osteoinductive potential of the membrane.").⁷
2. Cricchio et al. (2009) have installed absorbable space makers and could show, that, almost exclusively in the combination of simultaneous implant placement, it was possible to generate bone along the implant surface ("Histologically there were only minor or no signs of bone formation in the sites with a space-making device only. Sites with simultaneous implant placement showed bone formation along the implant surface.").¹⁸

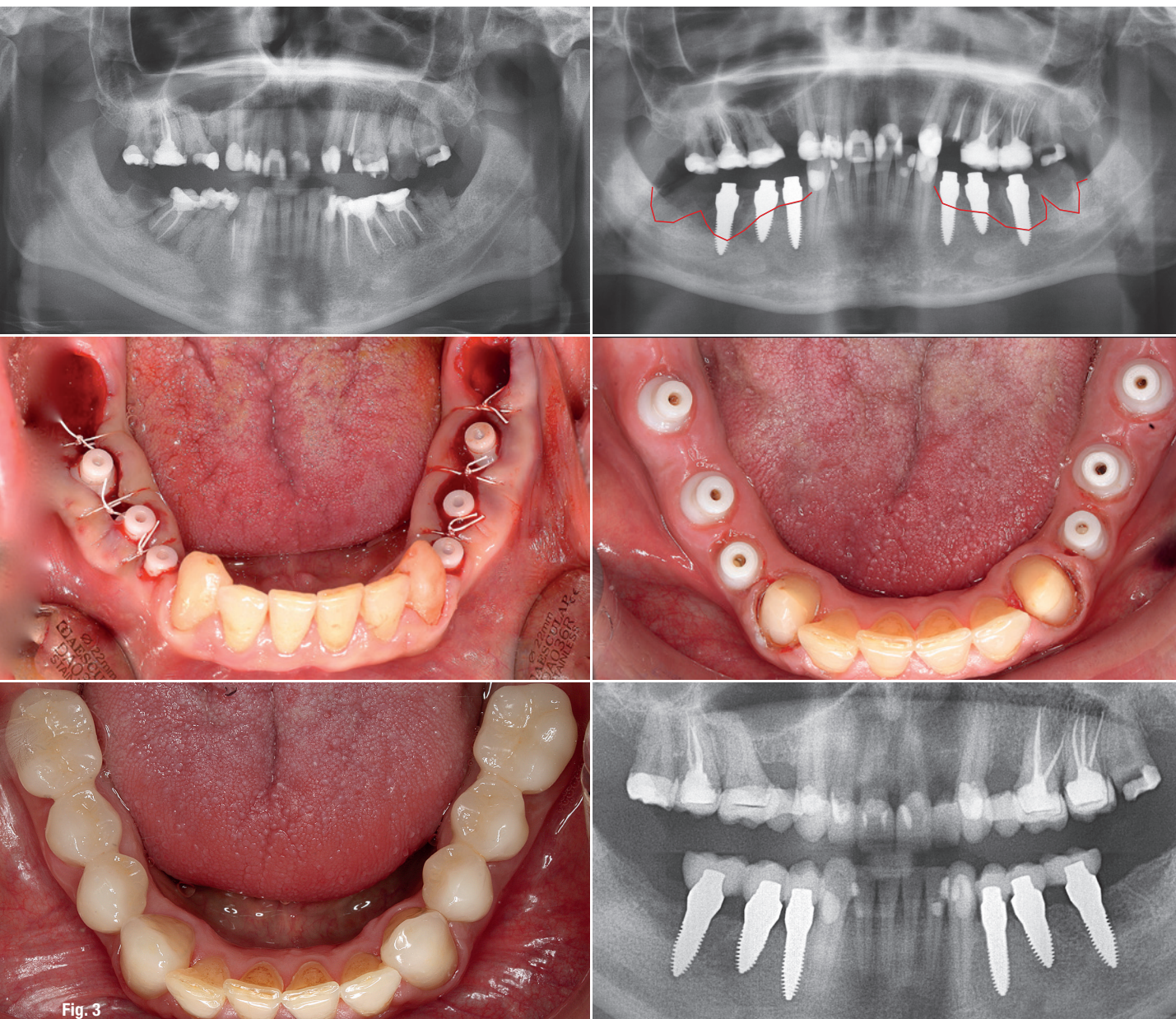


Fig. 3: During a surgery with immediate implant placement, the implants were placed at the desired level of the regenerated bone. The unharmed periosteum as well as the attached gingiva were fixed over the tulip formed widening (“sunshade principle”) of the SDS ceramic implant, which results in a stable cavity. The panoramic X-ray shows the final restoration with e.max crowns after only 2.5 months postoperatively with complete bone regeneration at the desired level.

3. Junger et al. (2015) have found out that “bone formation after sinus membrane elevation with or without additional bone grafts starts at the sinus floor and sprouts into the elevated space along the implant surface”.¹⁹
4. Cricchio et al. (2011) have proven that “when the sinus membrane was elevated, bone formation was a constant finding”.²⁰ Therefore, “an ideal space-making device should be stable and elevate the membrane to ensure a maintained connection between the membrane and the secluded space”.
5. Sohn et al. (2008) have shown the capacity of new bone formation in the maxillary sinus after elevating the Schneiderian membrane and simultaneous insertion of

implants into the resulting cavity without using any additional bone substitute.²¹ “New bone formation without additional bone graft in the maxillary sinuses revealed from the clinical, radiographic, and histologic results...”

Summarising the aforementioned studies, it can be concluded that an optimal one stage result can be achieved by a bone substitute free insertion of an implant, whose design is able to lift the Schneiderian membrane without perforating it, as well as to create a voluminous and stable cavity. Additionally, this cavity must be kept stable and sealed against the oral cavity. This led to the development of the sinus implant.

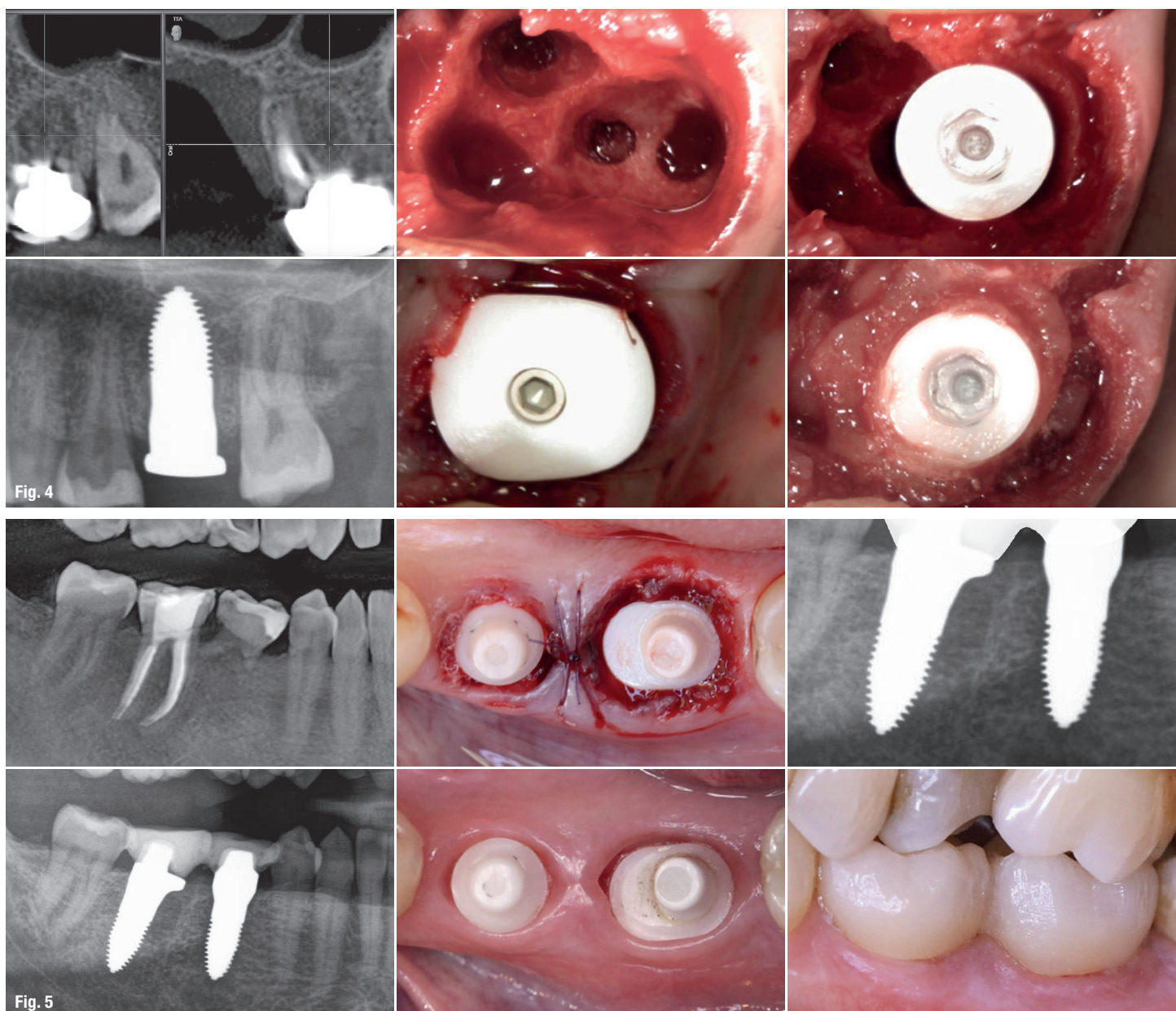


Fig. 4: After an internal sinus lift, the implant was stabilised only in the compacta of the maxillary sinus floor. The cavity was filled with A-PRF and the socket was sealed with a disc abutment in the sense of a sunshade. The defect has fully recovered after four months. **Fig. 5:** Implant placed in the distal socket of region #46, covering the medial socket after being filled with A-PRF. Complete regeneration of the hard- and soft-tissue.

Surgical protocol

Preparation of the immune system by adjuvant systemic therapy (adjusting the LDL and D3 levels, see above) and highly dosed vitamin C infusion as well as single shots of 600mg Sobelin and 8mg Dexametasone i.v. on three consecutive days (-1, day of surgery, +1). The surgery can be performed in local anaesthesia only.

- Incision on the maxillary crest with gingival margin cut at the neighbouring teeth to avoid a vertical incision.
- Avoidance of incision of the periosteum with the brushing technique by Choukroun et al. (2016) to achieve

tension and movement free coverage in combination with apical mattress sutures.²²

- Thinning out the vestibular bone in the area of the window with the help of the safescraper (Safescraper® TWIST, straight) and simultaneous gain of cortical chips.
- Usage of piezo surgery (Piezotome Solo F 57 500, Kit "Extern Sinuslift" F 87 319 Bone Surgery BS1) to remove the bone window without perforating the Schneiderian membrane.
- Elevation of the Schneiderian membrane far to the medial, dorsal and palatal side. This ensures the blood supply for the cavity^{23,24} and secures the sinus implant,

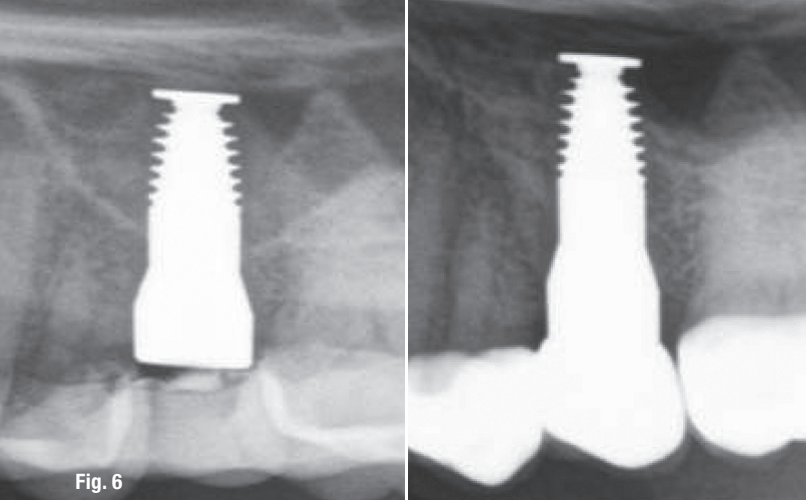


Fig. 6

Fig. 6: Result after six months postoperatively. One can observe, that there could be gained enough satisfactory bone quantitatively and qualitatively.

because there shall not be any tension on the membrane with expulsive forces on the sinus implant.

- Reinforcement of the membrane with one layer of A-PRF, insertion of the sinus implant and placement of the bony lid of the vestibular window on top of the disc of the sinus implant to enlarge the "shadow effect". Filling the cavity with more A-PRF membranes and cortical chips from the Safescraper.

- Closure of the window with cortical chips, covering with one or two A-PRF membranes and saliva proof and tension free wound closure. This is achieved by a two-layer suturing technique (apical mattress sutures and single button or continuous sutures) with a monofil, atraumatic suture material, preferably PGC25 (Atramat®). PGC25 shows the lowest bacterial adherence rate and therefore significantly minimises the incidence of stitch canal infection, which is a possible secondary complication.^{25,26}

Results

The slight radiopacity due to the cortical chips and the A-PRF show, that the cavity space was attained and the bony lid placed on top of the disc of the sinus implant (Fig. 6). Figure 7 shows an extensive treatment using SDS ceramic implants and three sinus implants on both sides. The results of the bone formation after four and eight months show a perfect situation regarding hard- and soft-tissue around the implant (Fig. 8).

Fig. 7: Insufficiently pre-treated maxillary situs, after inserting eight more implants in the maxillary, sinus lift on both sides, bone formation in the front.

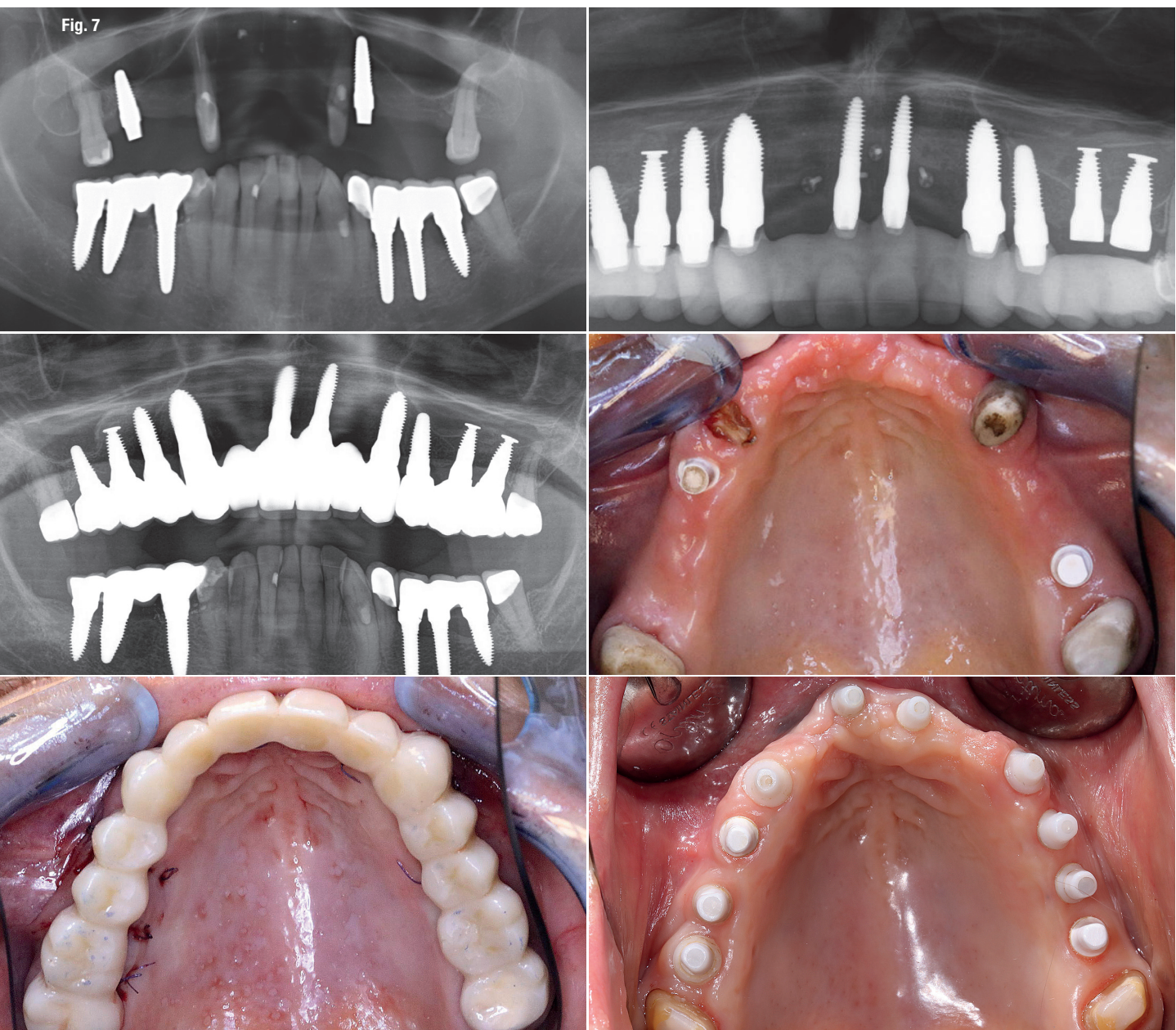


Fig. 8: Significant bone formation already after four months and continuous improvement after another four months.

Conclusion

The external and internal maxillary floor elevation using secondary materials for augmentation is a standard surgical procedure in oral implantology. However, complications such as infections or dehiscences up to total loss are still a regular problem. Unfortunately, in most cases “restitutio ad integrum” cannot be expected. The maxillary sinus floor mucosa as well as the soft tissue are mostly permanently compromised. On the one hand, the presented therapy concept allows for a minimally invasive and atraumatic surgical procedure, which only uses autologous materials.

On the other hand, only highly biologically compatible, metal-free implant materials are inserted. The complication-free processes and the outstanding results up to date in regard to the clinical, radiological as well as the bone and soft tissue situation are very positive. This presents a promising alternative for the practitioner. In case of complication, the worst that could happen in this treatment concept, is falling back to the original condition.

It is now necessary to confirm these results sustainably in regard to patient quantity and observation period within long-term studies.

Prof. Dr Dr Ralf Smeets
Author details



Dr Martin Chares
Author details



Dr Stefan König
Author details



Dr Dominik Nischwitz
Author details



Dr Alexander Neubauer
Author details



Sabine Hutfilz
Author details



contact

Dr Karl Ulrich Volz

Biological Medical & Dental Clinic
SWISS BIOHEALTH AG
Brückenstr. 15
8280 Kreuzlingen, Switzerland
dental@swiss-biohealth.com
www.swiss-biohealth.com

Author details

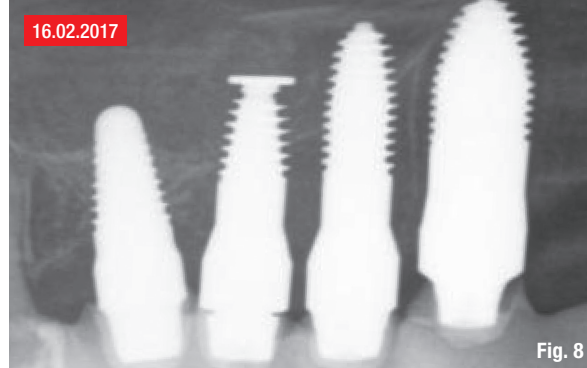

Fig. 8

