

# Erbium laser in ankyloglossia therapy

Dr Adam J. Wolniewicz, Poland

**Ankyloglossia is one of the reasons** for problems in breastfeeding, and it causes malocclusion and speech disorders. Ankyloglossia is a congenital abnormality of the oral cavity caused by a lingual fraenum that is too short and thus limits the tongue's movement. It is not always recognised by doctors and speech therapists, causing controversy in both professions. However, if properly diagnosed in childhood and then subjected to fraenotomy, the abovementioned problems can be resolved or further treatment enabled. One of the ways of performing fraenotomy is using an erbium laser.

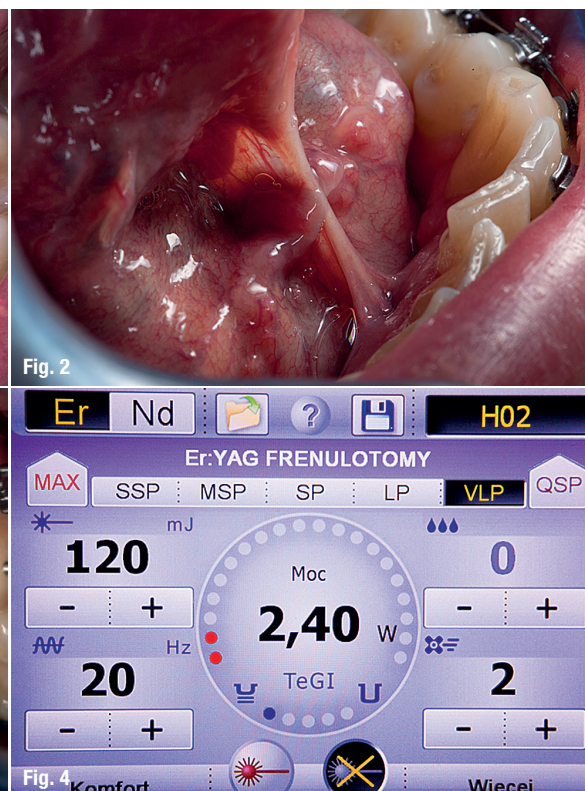
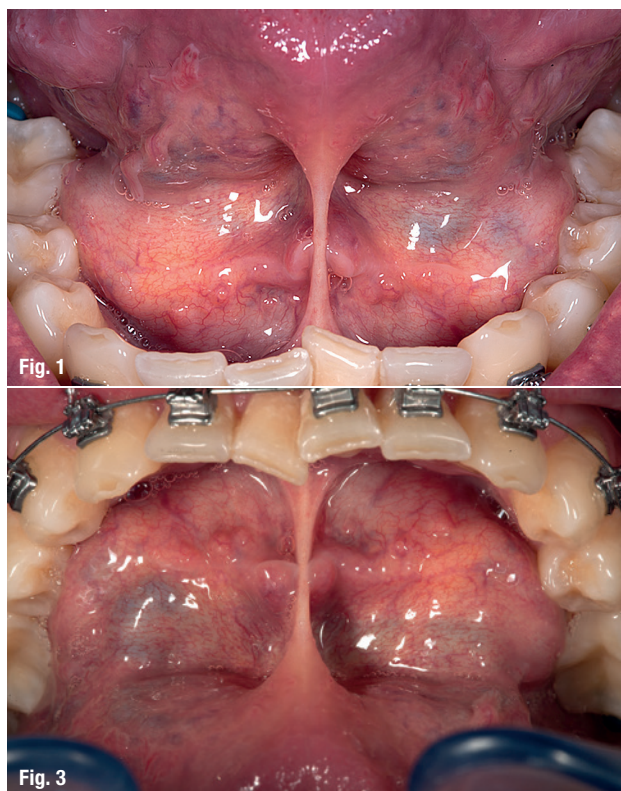
## Anatomy

Lingual fraena are composed of loose connective tissue with numerous elastic fibres surrounded by mucosa. In the fetus, they are responsible for the proper direction of

growth of many structures in the oral cavity. After birth, their importance decreases, but if they are improperly shaped, attached or too short, they may affect further orthopaedic, maxillary and functional development.

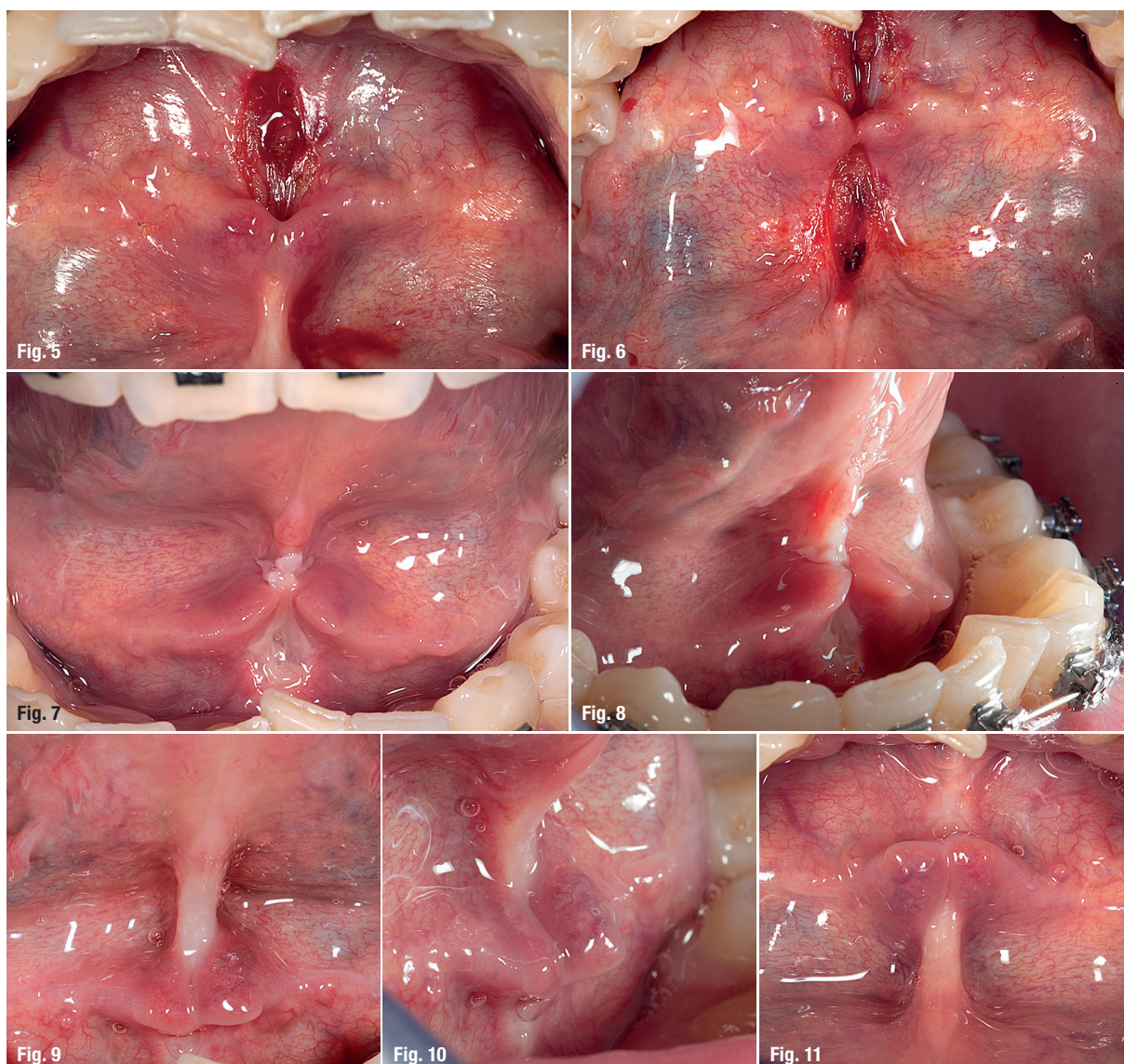


The lingual fraenum joins the inferior part of the tongue with the floor of the mouth and is visible when the tongue is raised towards the palate. If the lingual fraenum is structured properly and elastic, it does not affect the tongue's effectiveness during suckling, moving food, swallowing, speaking and breathing. If it is short, tight and wide, tongue mobility may be affected, especially when the lingual fraenum spreads from the apex of the tongue to the marginal gingiva of the mandibular incisors lingually.



Case 1 – Figs. 1–3: Situation before fraenotomy. Fig. 4: Laser parameters.





**Case 1 – Figs. 5 & 6:** Condition on the day of fraenotomy. **Figs. 7 & 8:** Condition six days after fraenotomy. **Figs. 9–11:** Condition three weeks after the procedure.

## Occurrence rate of ankyloglossia

In the world literature, the frequency of ankyloglossia occurrence is estimated at 3–4 %; yet, English and American sources report about 10 up to 16 %. However, it is generally said that speech disorders caused by the abnormal structure of the lingual fraenum occur much more often.

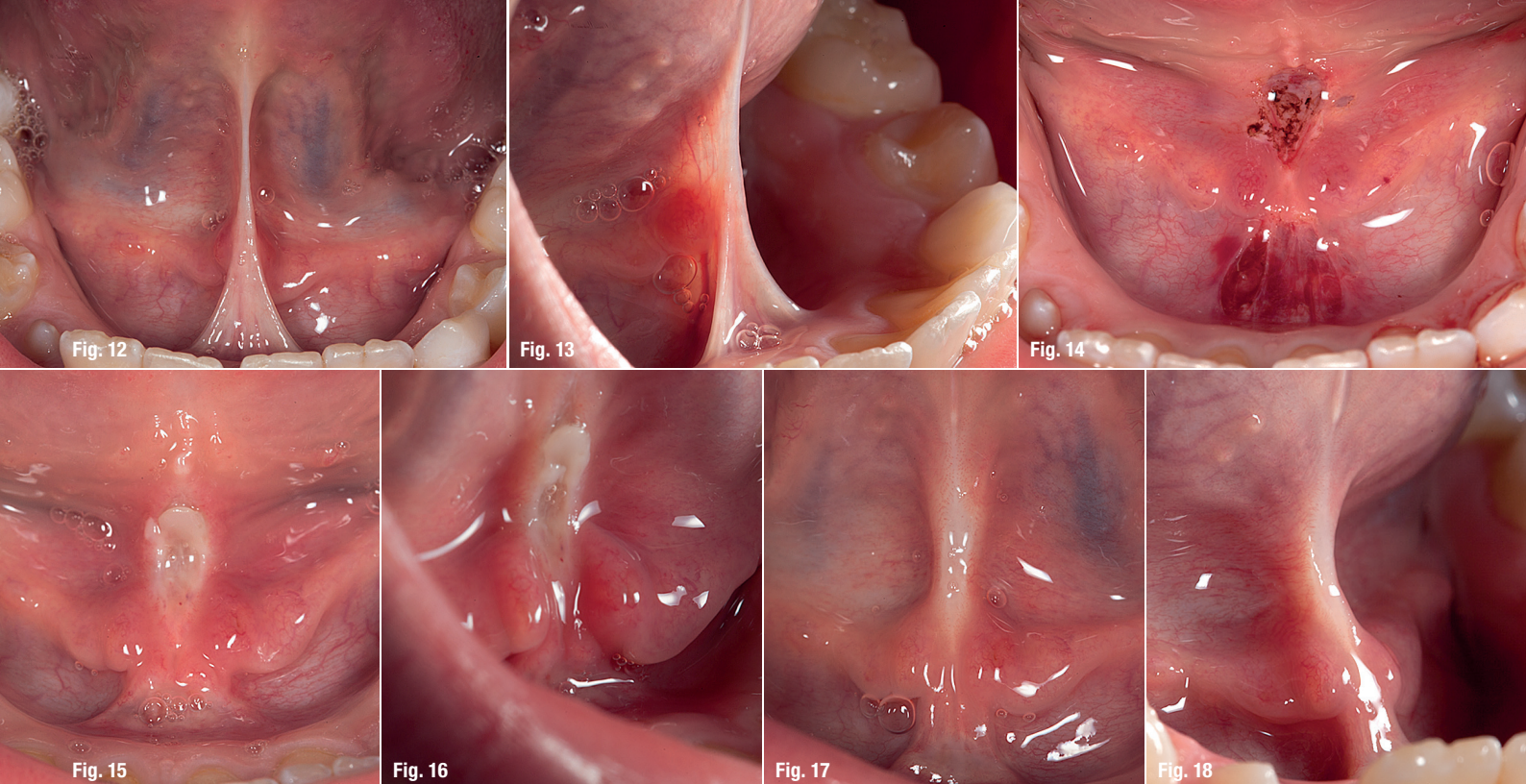
## Diagnosis

Despite the fact that this condition seems to be well understood, there are difficulties in diagnosing a short lingual fraenum because different criteria and methods are used. Some speech therapists and doctors use a very simple assessment method via examination of the degree to which the tongue can be moved forward and into a heart shape.<sup>1</sup> Other specialists, including Ostapiuk, differentiate the mobility of the tongue according to five movements.<sup>2</sup>

Some assume that there is the possibility of extending the lingual fraenum, whereas Pluta-Wojciechowska says that there is no research proving the effectiveness of extending the lingual fraenum through massage and exercise.<sup>3</sup> In her research, Ostapiuk clearly shows that, in the case of ankyloglossia, effectiveness of speech therapy cannot be achieved without surgical intervention.<sup>2</sup>

In a wide study, Fernando proved that untreated ankyloglossia has many consequences for infants, children and adults, ranging from problems with suckling to interpersonal problems caused by speech disorders.<sup>4</sup> A short lingual fraenum limits tongue mobility and prevents its proper peristaltic movements during suckling. Naturally, it is not the only cause of feeding problems and proper diagnosis is required. However, in the case of a lack of proper body weight gain in an infant, fraenotomy should be taken into consideration.





**Case 2 – Figs. 12 & 13:** Patient condition before fraenotomy. **Fig. 14:** Condition on the day of fraenotomy. **Figs. 15 & 16:** Condition six days after fraenotomy. **Figs. 17 & 18:** Condition four weeks after fraenotomy.

Among children, ankyloglossia leads to improper growth of the maxilla and mandible, which results in malocclusion. A lingual fraenum that is too short or improperly formed keeps the tongue at the floor of the mouth, preventing the natural process of maxillary widening. A maxilla that is too narrow, in turn, limits the efficient development and protrusion of the mandible, which is the most common cause of Angle Class II malocclusion.

Recognition of the problem before the baby growth spurts, which is before ten months of age, and performing of fraenotomy together with orthodontic treatment and speech therapy constitutes the efficient method of preventing the defect affecting the dentition and phonetics.

## Fraenotomy

A solution, as well as a method of prevention, can be fraenotomy, entailing the cutting and releasing of the lingual fraenum, in contrast to fraenectomy, which is the surgical removal of the fraenum. Fraenotomy can be performed with scissors, a scalpel, cautery or a laser. Depending on the age and condition of the patient, the procedure can be performed under general, local, topical or no anaesthesia at all.

Among infants, fraenotomy is performed mainly by paediatric surgeons and is applied owing to lactation problems, especially in the first days of life, in the hospital. Among older children, however, this procedure is performed mainly at the request of speech therapists and orthodontists. Among adults, it is conducted to correct a prosthetic base or to prevent periodontitis.

## Laser application in soft-tissue surgery

As mentioned, one of the tools used to perform the cutting of the lingual fraenum is a laser. In soft-tissue surgery, many types of lasers are applied: diode, Nd:YAG, carbon dioxide, Er,Cr:YSGG and Er:YAG lasers. They emit various wavelengths and, depending on the work parameters chosen, they can affect tissue in different ways. Particularly useful lasers for soft-tissue preparation seem to be the so-called hard lasers, such as carbon dioxide and Er:YAG, because their main feature is a short penetration depth. This means that the energy they emit is absorbed only by the surface and does not cause thermal damage to the deeper-lying tissue.

## Case presentation

In my daily practice, I use the LightWalker ATS laser (Fotona). It combines two radiation sources in one appliance: Er:YAG with a 2,940nm wavelength and Nd:YAG with a 1,064nm wavelength. Owing to this configuration, this device allows one to perform many advanced procedures and work on both the hard and soft tissue.

In fraenotomy procedures, the following parameters are used for the Er:YAG laser: VLP 120mJ, 20Hz (output power 2.40W), water: 0, air: 2. The contra-angle handpiece used most often is the H02. Sometimes, in the case of intensive bleeding, the Nd:YAG laser is also used in order to stop bleeding. Then, the parameters are: VLP, 4W and 20Hz.

### Case 1

A 34-year-old male was referred by the orthodontist for fraenotomy as a part of the orthodontic treatment plan



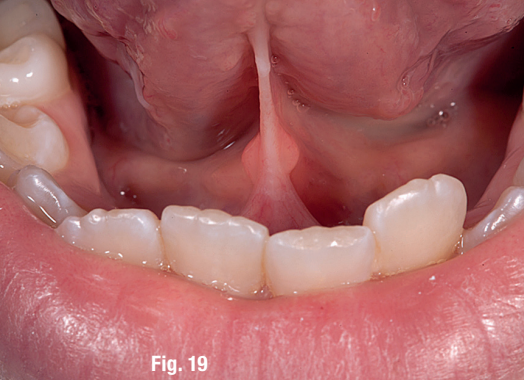

Fig. 19

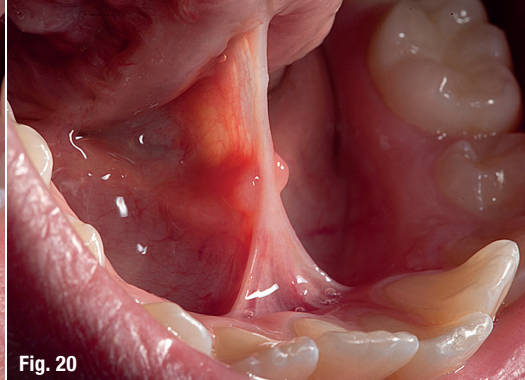


Fig. 20

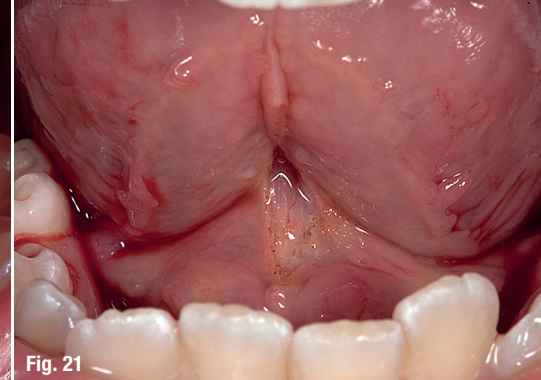


Fig. 21

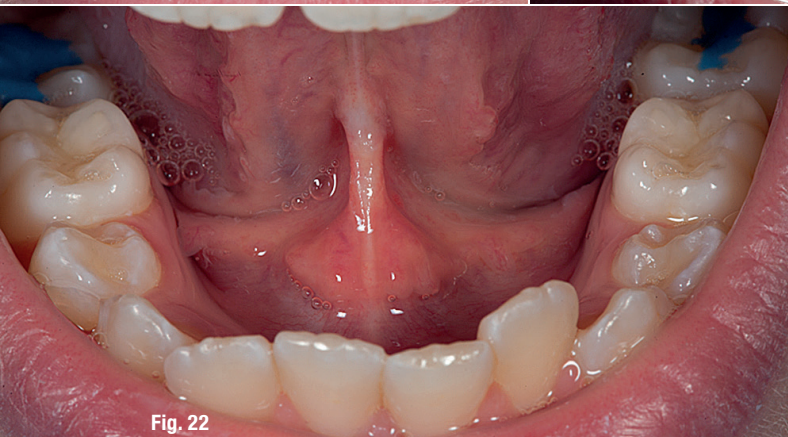


Fig. 22

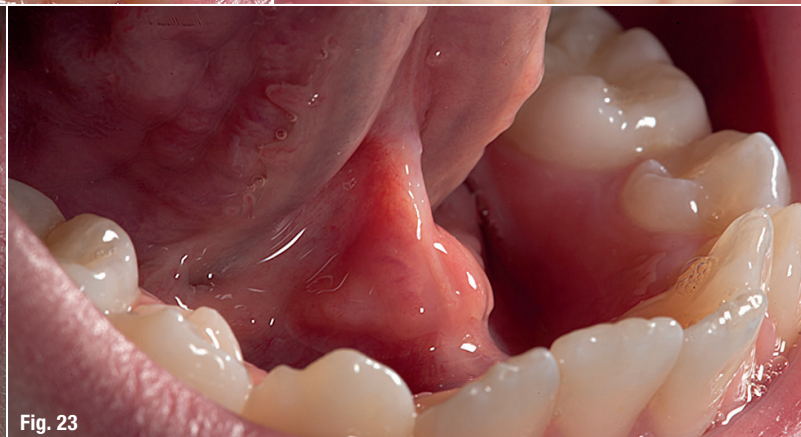

Fig. 23

**Case 3 – Figs. 19 & 20:** Patient condition before the procedure. **Fig. 21:** Condition on the day of the procedure. **Figs. 22 & 23:** Condition 11 days after fraenotomy.

(Figs. 1–3). Fraenotomy was performed under local infiltration anaesthesia with 4% Ubistesin forte (3M ESPE) using the Er:YAG laser (Figs. 4–11).

#### Case 2

A 10-year-old male patient undergoing speech therapy was referred by the orthodontist for fraenotomy (Figs. 12 & 13). The procedure was performed under local infiltration anaesthesia with 4% Ubistesin forte using the Er:YAG laser. Clot formation was performed with the Nd:YAG laser (Figs. 14–18).

#### Case 3

An 11-year-old female patient undergoing speech therapy was referred by the orthodontist for fraenotomy (Figs. 19 & 20). Fraenotomy was performed under local infiltration anaesthesia with 4% Ubistesin forte using the Er:YAG laser (Figs. 21–23).

## Conclusion

Ankyloglossia certainly has a great impact, ranging from infancy to adulthood. Fraenotomy performed with an Er:YAG laser, in particular, is a simple and uncomplicated procedure that allows the avoidance of many unnecessary consequences resulting from the abnormal structure of the lingual frenum.

## contact

### Dr Adam J. Wolniewicz

Diplomate PSI/ICOI  
Member of PTSL, PASE, PSI/ICOI  
Orłowska Dental Clinic  
Orłowska 61, 81-001 Gdynia, Poland  
[www.wolniewicz.eu](http://www.wolniewicz.eu)

Author details



## Kurz & bündig

Die Auswirkungen einer Ankyloglossie reichen von der Kindheit bis ins Erwachsenenalter. Ankyloglossie gilt als eine der Ursachen für Probleme beim Stillen und kann Sprachstörungen und Malokklusion bei Säuglingen und Kindern auslösen. Es handelt sich dabei um eine genetische Fehlbildung der Mundhöhle, welche durch ein verkürztes Zungenbändchen bedingt wird. Das fehlgebildete *Frenulum linguale* limitiert aufgrund seiner eingeschränkten Länge die Bewegungsoptionen der Zunge. Die unterschiedlichen angewandten Untersuchungskriterien und -methoden resultieren für Sprachtherapeuten und Ärzte häufig in Diagnoseschwierigkeiten. Wird Ankyloglossie jedoch frühzeitig in der Kindheit erkannt und mit einer Frenotomie behandelt, können die oben genannten Probleme verhindert werden. Mit einer folgenden kieferorthopädischen Behandlung und Sprachtherapie werden spätere Gebiss- und Phonetikdefekte weiterführend abgewendet. Eine mit einem Er:YAG-Laser vorgenommene Frenotomie stellt eine besonders einfache und unkomplizierte Behandlungsmethode dar, welche viele unnötige Beeinträchtigungen resultierend aus der anormalen Struktur des Zungenbändchens verhindern kann. Der Autor stellt drei Fallbeispiele mit detaillierter Fotodokumentation aus seiner eigenen Praxis vor, bei welchen er den LightWalker ATS Laser (Fotona) verwendete.