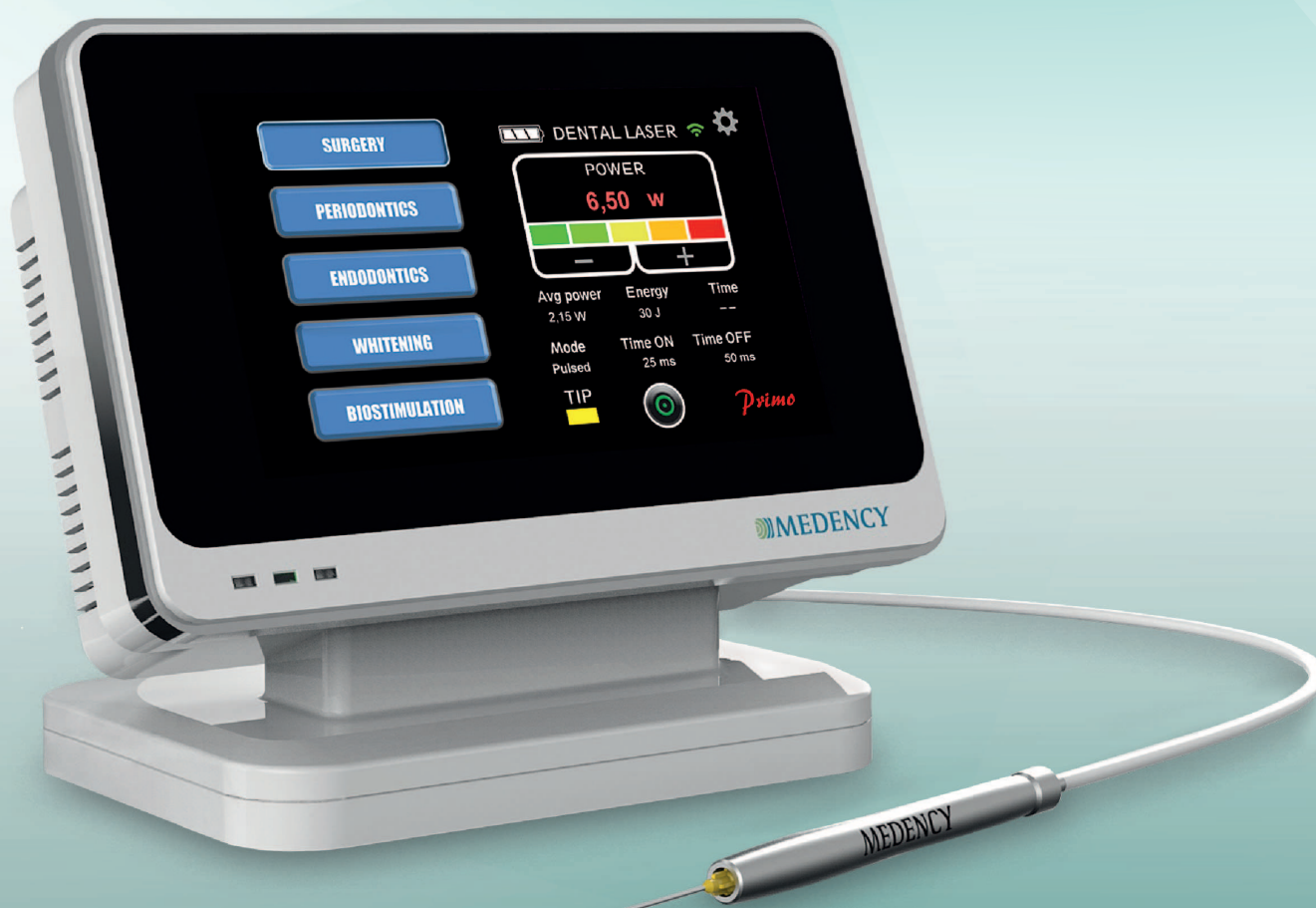

laser

international magazine of laser dentistry



case report

Peripheral giant cell granuloma surgery

industry

Erbium laser in ankyloglossia therapy

events

WFLD's Pearl Anniversary World Congress 2018



The universe at your fingertips.

● LightWalker

The highest technology dental laser system

Supreme clinical results:

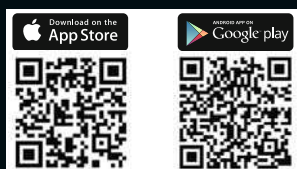- TwinLight® Perio Treatments
- TwinLight® Endo Treatments
- No-sutures soft-tissue surgery
- Patient-friendly conservative dentistry
- Pre-sets for over 40 applications


Unmatched simplicity of use:

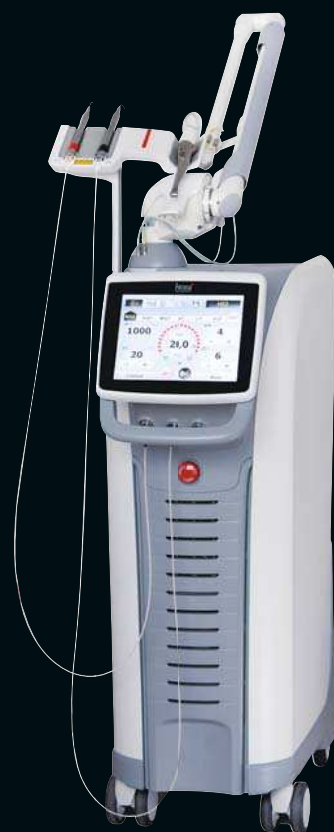- Balanced and weightless OPTOflex® arm
- Nd:YAG handpiece detection system
- Quantum Square Pulse technology for fast minimally invasive treatments
- X-Runner™ - the first digitally controlled Er:YAG dental laser handpiece

Journey into a new dental experience with speed, precision and great results.

Visit www.fotona.com today!



 Fotona App



Prof. Adam Stabholz

Former Dean of the Faculty of Dental Medicine,
Hebrew University Hadassah, Israel



From Maiman's 1st laser to the Laser World Congress 2018

Dear colleagues and friends,

One hundred years ago Albert Einstein envisioned that under the right conditions a special kind of light could be created—a light that nobody has ever seen before. It would be a single colour, it would not scatter and it would be intense.

Almost sixty years ago, in 1960, Theodore Maiman presented the first laser device on earth. Maiman identified five potential uses for the laser, among them concentrating light for industry, chemistry and medicine. The search for new devices and technologies for dental procedures has always been challenging and in the last four decades much experience and knowledge have been gained. Pioneering research in the mid-sixties paved the way for the use of lasers in dental medicine and the development of pulsed technology with CO₂ wavelengths in the eighties made lasers popular in this medical area. In 1990, the first laser designed specifically for general dentistry, the dLase 300 Nd:YAG, was introduced and in 1997, following the FDA approval of the Er:YAG laser for caries removal, cavity preparations and modification of dentine and enamel, a new era in laser dentistry began.

With the rapid development of laser technology, new lasers with a wide range of characteristics are now available and are being used for soft-tissue procedures, caries diagnosis and removal, curing composites, tooth bleaching, paediatric dentistry, endodontics, periodontics, preventive and implant dentistry, control of bleeding in vascular lesions and Low Level Laser Therapy.

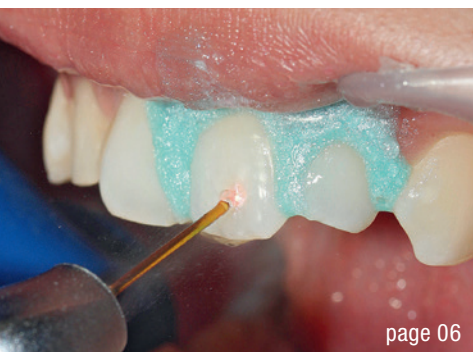The WFLD congress in Aachen from 1 to 3 October 2018 will mark the 30th anniversary of the WFLD/

ISLD and will provide a perfect stage for friends and colleagues to get together, to exchange knowledge based on latest research, to learn about the newest developments in laser dentistry and how to implement this knowledge in the various disciplines mentioned above. It will be a perfect time as well for building new friendships and planning new collaborations for the future. Do not miss this unique opportunity to be part of the largest scientific laser in dentistry meeting ever—organised in the beautiful city of Aachen, Germany, known as the cathedral city of Europe. It is located on the border to Belgium and the Netherlands and is a city that lives and breathes Europe. When not attending one of the lecture halls, where the world's most renowned speakers will be presenting, or participating at one of the workshops or learning at the posters session, a visit to the Aachen Cathedral is a must. It is certainly both a local landmark and a monument of Europe's illustrious past.

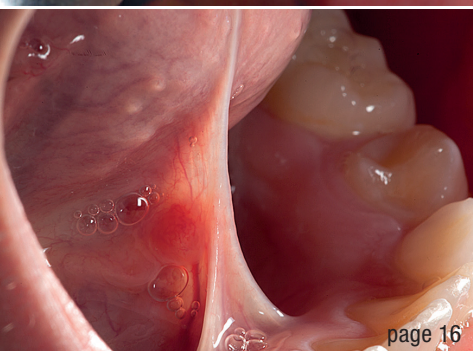
The preparations for the world congress are in full swing and a tremendous effort is made to ensure its success. Our thanks and our deepest appreciation go to the wonderful team headed by Prof. Dr Norbert Gutknecht, Prof. Dr Lynn Powell, Leon Vanweersch, Dr Dimitris Strakas, Dr Stefan Grümer, the DGL local organising team and to all members on the international organising committees.

I look forward to meeting you all in Aachen at this outstanding high-level international scientific event jointly organised by WFLD, DGL and WALED. On 1 October 2018 all roads will lead to Aachen.

All the best and see you soon in Aachen,
Prof. Adam Stabholz



page 06



page 16



page 30

Cover image courtesy of MEDENCY Srl
www.medency.com
Original Background:
© Thaiview/Shutterstock.com



editorial

- From Maiman's 1st laser to the Laser World Congress 2018 03
Prof. Adam Stabholz

case report

- Minimally invasive dentistry with Er,Cr:YSGG 06
Drs Christina Karanasiou & Dimitris Strakas
Peripheral giant cell granuloma surgery with diode laser 10
Drs Maziar Mir, Masoud Mojahedi, Jan Tunér & Masoud Shabani

industry

- Erbium laser in ankyloglossia therapy 16
Dr Adam J. Wolniewicz

practice management

- Successful communication in your daily practice 20
Dr Anna Maria Yiannikos
Six Sigma in the management of laser-assisted dental practices 22
Dr Imneet Madan

interview

- Technology, innovation and passion 26
Timo Krause

events

- "The Future of Dentistry is Here" 28
Dr Diana Constantinescu
WFLD's Pearl Anniversary World Congress 2018 30
Dr Dimitris Strakas & Leon Vanweersch

news

- manufacturer news 32
news international 33

DGL

- DGL-Jahreskongress in Aachen am 2. und 3. Oktober 2018 36
Prof. Dr. Norbert Gutknecht
news germany 38

about the publisher

- imprint 42



Master of Science (M.Sc.) in Laser in Dentistry

Next Start: **15th October 2018** | Aachen, Germany | 4 semesters



Become part of the International Dental Elite

- Create new economic potential for your practice
- Two year career-accompanying postgraduate programme at the University of Excellence RWTH Aachen
- Combination of lectures, skill training sessions, live ops, tutorials, and practical workshops
- Internationally accepted and accredited by the German Government, the European Union, the Washington Accord and the Bologna Process
- Science-based and practice-orientated on highest national and international level
- Increased patient satisfaction: minimal contact reduced vibration and pain

**RWTH INTERNATIONAL
ACADEMY
AACHEN UNIVERSITY**

RWTH International Academy
Kackertstraße 10 | 52072 Aachen | Germany
phone +49 241 80 23543 | fax +49 241 80 92525
info@academy.rwth-aachen.de
www.academy.rwth-aachen.de

AALZ

Aachen Dental Laser Center

AALZ GmbH
Pauwelsstraße 17 | 52074 Aachen | Germany
phone +49 241 47 57 13 10 | fax +49 241 47 57 13 29
info@aalz.de
www.aalz.de



PROFESSIONAL EDUCATION PROGRAMMES

Your contact for more information: Leon Vanweersch • vanweersch@aalz.de - www.aalz.de

Minimally invasive dentistry with Er,Cr:YSGG

Drs Christina Karanasiou & Dimitris Strakas, Greece

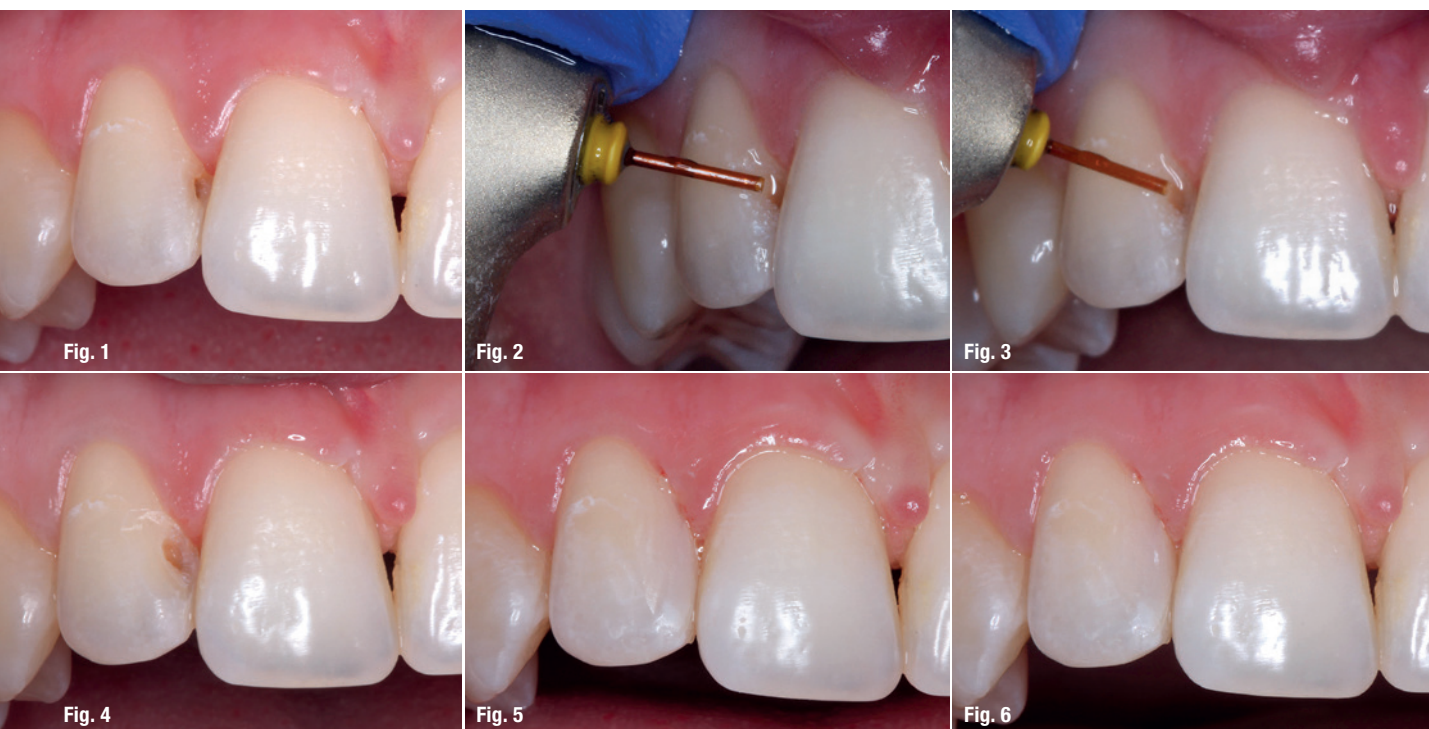
Introduction

The concept of minimally invasive dentistry can be defined as the maximal preservation of healthy dental structures, involving the minimal removal of carious lesions for example. Modern dentistry and its minimally invasive concepts are supported by the development of innovative materials and cutting-edge techniques.

Lasers have been widely used in many fields of dentistry and several wavelengths have been investigated as substitutes for a high-speed handpiece. Conventional cavity preparation refers to the removal of infected hard tissue using rotary instruments. However, dental hard-tissue ablation for cavity preparation by means of irradiation with the erbium family of lasers has attracted many researchers, and we can affirmatively state today that the procedure is safe and can be performed without anaesthesia in the ma-

jority of cases, and the resulting prepared cavity is free of a smear layer. Moreover, noise and vibration caused by dental burs are contributing factors to the development of dental fear. The use of laser ablation for tooth preparation has made it possible to avoid these discomforts, thus making the procedure a life-changing experience for patients. With lasers, the minimal removal of healthy tooth substance in operative dentistry can be achieved.

The erbium family of lasers (located in the mid-infrared region of the electromagnetic spectrum) was introduced in dentistry for cavity preparation owing to the wavelength's high absorption in water and hydroxyapatite (hydroxyl radical). Enamel removal occurs by explosive thermomechanical ablation. Light is rapidly absorbed in water molecules leading to a micro-explosion which consequently results in enamel, dentine and carious tissue removal due to strong subsurface pressure.



Case 1 – **Fig. 1:** Initial situation: dental caries of the right maxillary lateral incisor. **Figs. 2 & 3:** Caries removal by Er,Cr:YSGG laser. **Fig. 4:** Area after laser treatment. **Fig. 5:** Restorative procedure performed freehand with composite resin. **Fig. 6:** Final polishing with medium-fine and superfine oxide discs.

Pulp chamber temperature rise during cavity preparation with Er,Cr:YSGG laser irradiation has been reported by several studies to be lower than with a conventional method using a bur, suggesting that this system has no adverse thermal effect.

The Er,Cr:YSGG laser (2,780nm) has been studied in dental hard tissue, especially for cavity preparation in clinical situations, and it has proven to be ideal for minimally invasive ablation of carious lesions without any side effects.

Case 1

A 25-year-old female patient came to the postgraduate dental clinic of the Department of Operative Dentistry at the Aristotle University of Thessaloniki, Greece. The patient's major complaint was sensitivity and pain at her right maxillary lateral incisor when exposed to cold water. After taking the medical and dental anamnesis, clinical and radiographic examination were performed. They revealed dental caries affecting the right maxillary lateral incisor (Fig. 1).

Therefore, a fast and minimally invasive method for caries removal was decided on. An Er,Cr:YSGG laser (2,780nm, Waterlase MD Turbo, Biolase) was used for

this purpose (Figs. 2 & 3). For the procedure, the gold handpiece of the device and a Z-type glass tip of 500µm in diameter (MZ5) were used. The laser parameters utilised for this case were as follows: average output power of 6W, pulse duration of 140µs (H-Mode), pulse repetition rate of 20Hz (300mJ per pulse, 153J/cm² energy density) and under water spray (air: 60%, water: 80%). All margins received etch modification with the same laser device (Fig. 4). The power settings for bond preparation were as follows: MZ6 tip, average output power of 4.5W, pulse repetition rate of 50Hz and H-Mode.

After drying the tooth with an air blower, the cavity was treated with an adhesive system in accordance with the manufacturer's instructions (Single Bond Universal Adhesive, 3M ESPE). The restorative procedure was performed freehand with composite resin (Fig. 5). In order to achieve the final two colour shades, A2 for dentine and A1 for enamel (Clearfil Majesty ES-2 A2D and Clearfil Majesty ES-2 A1E, Kuraray Noritake Dental) were used. Final polishing was performed with medium-fine and superfine oxide discs (Sof-Lex, 3M ESPE; Fig. 6).

The laser treatment was performed with no local anaesthesia. The patient reported no sensitivity at any stage of the procedure.

AD

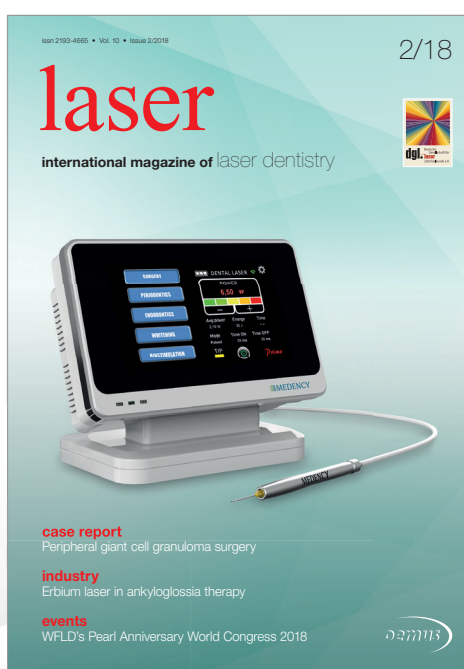
BECOME AN AUTHOR

for laser—international magazine of laser dentistry

Interdisciplinary and close to the market



www.oemus.com



Become part of a successful network and benefit from a wide reach and high level of awareness

Your benefits:

- author's profile at ZWP online
- specimen copies
- offprints
- speaking engagement*

Please contact Mr. Georg Isbaner:
g.isbaner@oemus-media.de
Phone: +49 341 48474-123

*according to the required profile



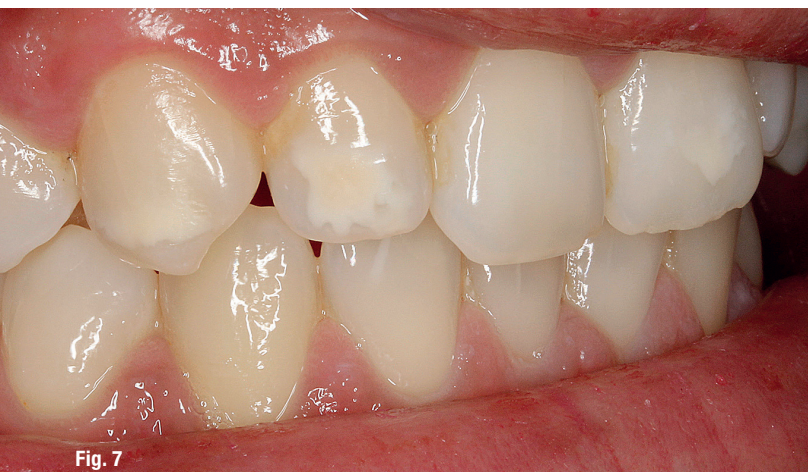

Fig. 7

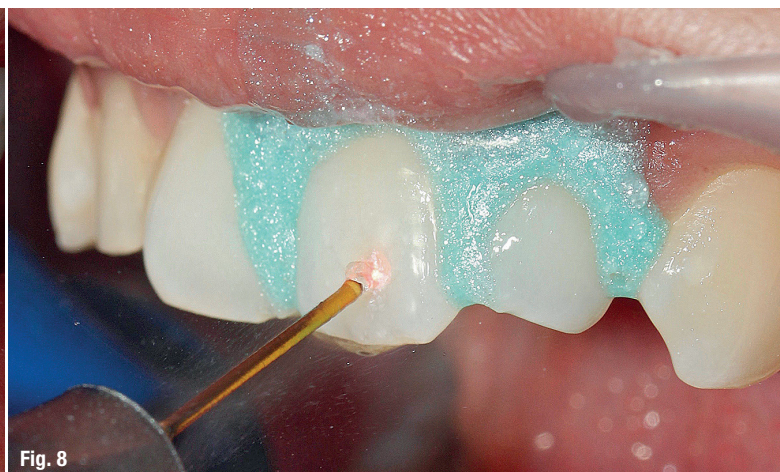

Fig. 8

Case 2 – Fig. 7: Initial situation: enamel hypomineralisation spots on anterior teeth. **Fig. 8:** Laser treatment with the gold handpiece and a Z-type glass tip (MZ6).

Case 2

A 27-year-old female patient presented with the main complaint of white spots on her anterior teeth. The patient required a minimally invasive solution to improving her smile. A thorough medical and dental history were taken prior to the clinical examination (Fig. 7).

According to the patient's clinical examination, the white spots were non-carious and were associated with enamel hypomineralisation. The aetiology of hypomineralised enamel can be genetic, acquired or idiopathic. General factors include infections during the critical age of two to three years—especially upper respiratory tract infections that require treatment with antibiotics in combination with corticosteroids—and nutritional deficiencies of vitamins A, C and D, calcium and phosphorus. Local factors include dentoalveolar infections or trauma of primary predecessors, surgical operations, and infections due to environmental factors, such as dioxins, which may be present even in breast milk.

When enamel hypomineralisation is observed in the anterior teeth, aesthetic problems arise, affecting not only the psychological state but also the social behaviour of the patient. Minimal intervention is an ideal approach in managing such white spots. The patient's expectations are vital to the decision-making process.

For this case, an Er,Cr:YSGG laser (2,780nm, Waterlase iPlus, Biolase) was used. For the procedure, the gold handpiece of the device and a Z-type glass tip of 600 µm in diameter (MZ6) were used. The laser parameters utilised for this case were as follows: average output power of 3.25W, pulse duration of 60 µs (H-Mode), pulse repetition rate of 20Hz (163 mJ per pulse, 58 J/cm² energy density) and under water spray (air: 60%, water: 70%; Fig. 8). All margins received etch modification with the same laser device. The power settings for bond preparation were as follows: MZ6 tip, average output power of 4.5W, pulse repetition rate of 50Hz and H-Mode (Fig. 9).

After drying the tooth with an air blower, the cavity was treated with an adhesive system in accordance with the manufacturer's instructions (Bond Force II, Tokuyama Dental; Fig. 10). The restorative procedure was performed freehand with composite resin. In order to

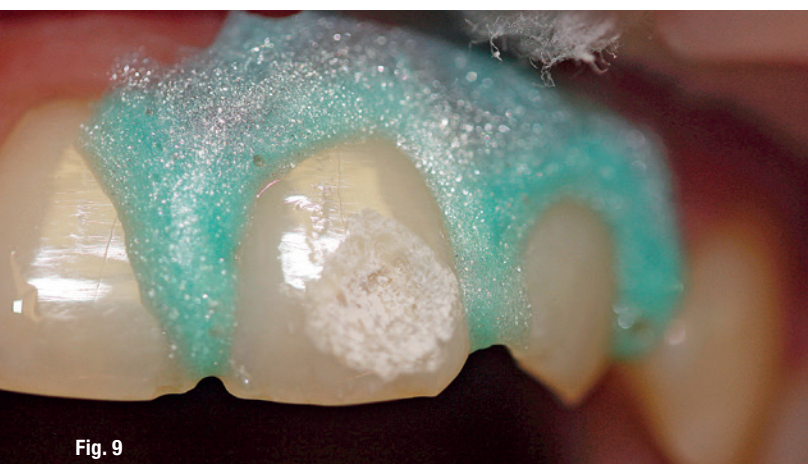

Fig. 9

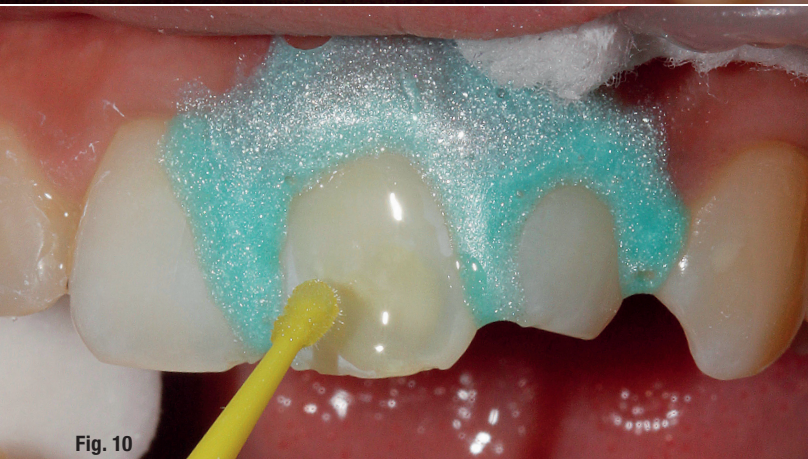

Fig. 10

Case 2 – Fig. 9: Bond preparation. **Fig. 10:** Cavity treated with adhesive system.

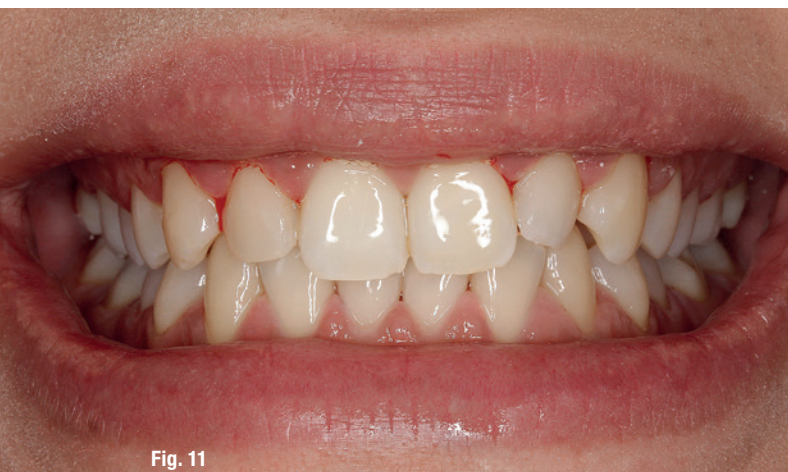

Fig. 11

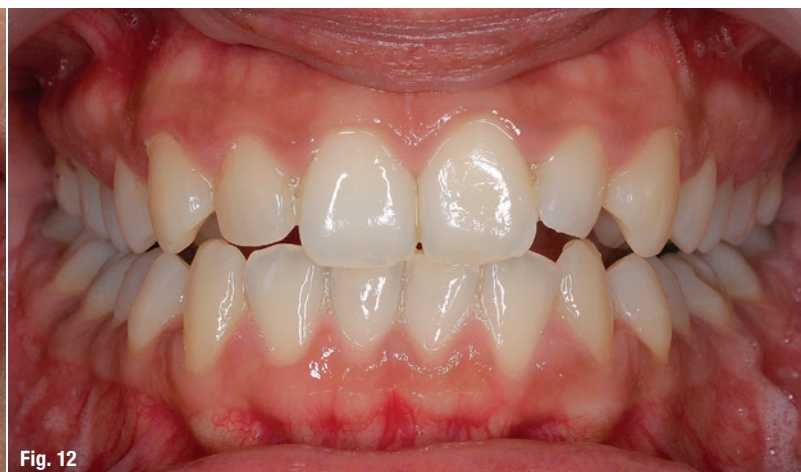

Fig. 12

Case 2 – Fig. 11: Final polishing with medium-fine and superfine oxide discs. **Fig. 12:** Final situation after rehydration of the teeth.

achieve the final two colour shades, A2 for dentine and A2E for enamel (IPS Empress Direct, Ivoclar Vivadent) were used. Final polishing was performed with medium-fine and superfine oxide discs (Sof-Lex; Fig. 11).

The laser treatment was performed with no local anaesthesia. The patient reported no sensitivity at any stage of the procedure. The final result after rehydration of the teeth can be seen in Figure 12.

Discussion

As dental technology continues to develop, new, innovative methods will continue to replace those that were once thought to be the peak. Lasers are now widely used in minimally invasive treatment in routine clinical procedures. According to the literature, treatments performed with Er,Cr:YSGG laser can be considered efficient and

viable in clinical practice, without damage to the pulp or periodontal tissue, and with great acceptance by patients owing to decreased vibration and noise, reduction of pain sensitivity and, in some cases, no need for the application of local anaesthesia.

contact

Dr Dimitris Strakas

DDS, M.Sc., PhD
Aristotle University of Thessaloniki
Spiridi 28
38221 Volos, Greece
dstrakas@dent.auth.gr

Author details



Kurz & bündig

Moderne Zahnheilkunde und minimalinvasive Konzepte werden besonders durch die Verfügbarkeit innovativer Materialien und hochmoderner Technologien unterstützt. Laser werden heute häufig für minimalinvasive Behandlungen vorrangig bei medizinischen Routineeingriffen wie bspw. im Fall von Kavitäten verwendet. Studien zufolge, gelten mit dem Er,Cr:YSGG-Laser durchgeführte Behandlungen als effizient und erfolgreich in der klinischen Praxis ohne die Zahnpulpa oder das parodontale Gewebe zu beschädigen. Aufgrund der gesenkten Vibration und Lärmbelastung sowie reduzierter Schmerzempfindlichkeit und in manchen Fällen sogar keiner Notwendigkeit einer Lokalanästhesie, findet diese Behandlungsmethode bei Patienten hohe Akzeptanz.

Die Autoren stellen zwei Fallbeispiele und Behandlungsabläufe ihrer Arbeit für die Abteilung für Zahnchirurgie der Aristoteles Universität in Thessaloniki, Griechenland, unter Verwendung des Er,Cr:YSGG-Lasers vor. Im ersten Fall wurde erfolgreich eine Kavität am rechten oberen lateralen Schneidezahn behandelt, während im zweiten Fall durch Molaren-Inzisiven-Hypomineralisation verursachte ästhetische Beeinträchtigungen in Form von weißen Arealen an den Inzisiven entfernt wurden. In beiden Fällen war keine Lokalanästhesie erforderlich, beide Patienten berichteten über keinerlei Schmerzempfindlichkeit während der Behandlung. Die je Fall verwendete Laserausstattung sowie die jeweiligen Einstellungsparameter werden detailliert wiedergegeben. Zudem sind auch die folgenden restaurativen Prozesse dargestellt und bildlich dokumentiert. Dank des Einsatzes der Er,Cr:YSGG-Laser konnten für beide Patienten mit nur minimalinvasiven Eingriffen die Beschwerden eliminiert und zufriedenstellende Ergebnisse erzielt werden.

Peripheral giant cell granuloma surgery with diode laser

Dr Maziar Mir, Germany; Dr Masoud Mojahedi, Germany; Dr Jan Tunér, Sweden & Dr Masoud Shabani, Iran

Laser surgery has many benefits, such as maintenance of a sterile condition, reduction of bleeding, good possible estimation of cutting depth, precision of cutting, often no need for suturing or bandages, pain reduction, minimally invasive procedure that reduces patient stress, promotion of wound healing and less scarring. Many cases have been reported in the literature regarding the removal of oral exophytic lesions and pain control for aphthous ulcers by laser. In the following, we will present a case of treatment of a peripheral giant cell granuloma (PGCG) and multiple aphthous ulcers in one patient.

Introduction

A PGCG originates from the periodontal ligament or the periosteum.¹ The lesion is more common in the lower jaw than in the upper jaw and is also more common in females than in males.²⁻⁴ Any region of the jaw can be affected by this kind of lesion,^{4,5} and mobility and displacement of the adjacent teeth can occur.⁶ Generally, the lesion size varies from about 0.1 cm to 3 cm.^{5,7}

The aetiology is unknown, but local irritating factors, such as an ill-fitting prosthesis, poor restorations, dental plaque, calculus, chronic infection and lack of nutrients, may have a role in the aetiology. The lesion may be seen in cases of hyperparathyroidism and after periodontal surgery.⁸⁻¹¹ The presence of S-100-positive cells, which are evidence of Langerhans cells or their precursors, and the presence of fibroblasts, endothelial cells and myofibroblasts points towards a reactive nature of the PGCG.¹²⁻¹⁴

Excision by scalpel, electrocautery or laser, and the elimination of any local irritating factors must be considered in the treatment of such lesions. The recurrence rate for lesions ranges from 5 to 11 %.^{5,15}

A recurrent aphthous ulcer (aphthous stomatitis) is a common lesion in the mouth and affects ten per cent of the population. The lesions, based on their morphology, can be classified as minor (3–10 mm in size), major (> 10 mm) and herpetiform. The exact cause of



many aphthous ulcers is unknown, but possible aetiological factors include stress, lack of sleep, citrus fruits, trauma, immune system reactions, and deficiency of vitamin B12, iron or folic acid. They also occur in relation with some systemic diseases, such as HIV, Behçet's syndrome, Crohn's disease and other autoimmune diseases.¹⁶⁻¹⁸

Nowadays, diode lasers are efficiently used for treatment of oral soft-tissue lesions.^{19,20}

Case presentation

A 45-year-old male patient with complaints of a mass with a duration of ten months and ulcers at the tongue that had been there for one day was referred for treatment. The mass was not painful, but bled during eating or sometimes even spontaneously. The ulcers were painful.

Medical history

The patient's medical history showed no systemic medical problems, no allergic reaction, no medications or recreational drugs and no history of past surgical procedures; thus, the patient did not have to be referred for medical consultation.

Clinical and radiographic findings

Oral and maxillofacial examination of the patient revealed no temporomandibular joint dysfunction or myofascial disturbances, but poor oral hygiene and an old denture lacking stability and retention.

An exophytic lesion was diagnosed at the ridge of the lower jaw. The lesion was partially firm and red to pink and bled during examination; no pain occurred on probing and the lesion was completely movable. The radiographic examination showed some retained roots in the lower jaw and there was no destructive effect such as bone resorption. There were multiple ulcers at the right side of the tongue. The ulcers were painful and the patient had not been using any medication for pain relief (Figs. 1 & 2).

The case was provisionally diagnosed as denture epulis and multiple aphthous ulcers, and we decided to

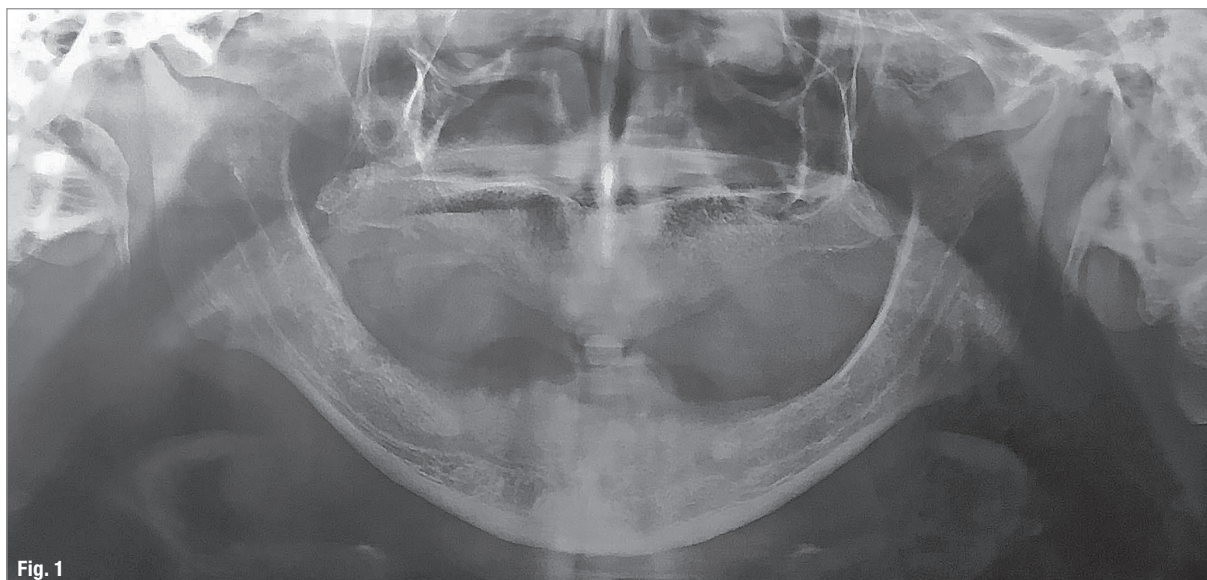


Fig. 1

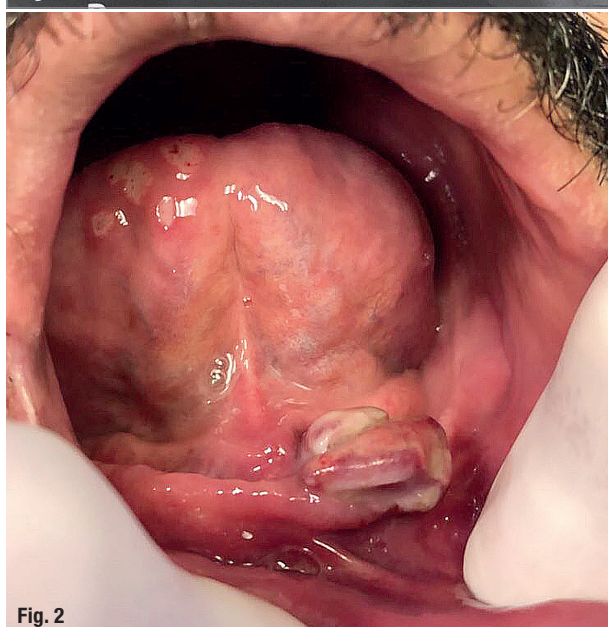


Fig. 2

Patient Name: Sex: male Report No: P-G- 311
 Clinician: Dr. Shabani Age: 45 yrs Date: 1396/10/14

SURGICAL PATHOLOGY REPORT

Specimen : gingival lesion
 Clinical data:
 Operation note:

GROSS DESCRIPTION: Specimen is received in formalin, labeled as gum lesion, consist of a cream colored soft tissue with hemorrhagic areas on its surface 14x10 mm in diameter and 2 mm thickness.

SOS: 1/1 E: 50%

MICROSCOPY: Sections show a lesion with numerous osteoclast like giant cells and a cellular highly vascularized stroma.

Gingival lesion, lesion excision
 Peripheral giant cell granuloma (giant cell epulis)

Fig. 3

Fig. 1: Initial radiographic image. Fig. 2: Before treatment: PGCG and aphthous ulcers. Fig. 3: Histological report.

perform a laser-based excisional biopsy of the exophytic lesion and ulcer photocoagulation by diode laser.

Treatment delivery sequence

After completion of the patient consent form, the surgical area was anaesthetised by infiltration with 2% lidocaine with 1:100,000 adrenaline (1.8ml) and then a retraction suture was placed within the lesion. The aphthous ulcer irradiation did not require local anaesthesia for the photocoagulation process.

The pre-operative procedures were as follows:

- defining of the controlled area and proper placing of the laser warning signs to secure the operating room,
- checking the safety of the patient's glasses and eye protection of the patient's guardian and the assistant,

- review of the patient's information (examination sheet, radiograph, consent form, etc.), and
- proper calibration of the laser system: fibre cleaving, beam aiming and initiation of the fibre with articulating paper and test-firing of the laser for the excisional biopsy, but a non-initiated fibre for the ulcer photocoagulation.

The excisional biopsy of the lesion was started with initiated fibre and the incision was performed with the tissue under tension and with tip-to-tissue contact so that the lesion was separated in the proper way. At the beginning of the surgery, we used a 980nm diode laser, 400µ fibre, 2W output power, continuous wave (CW) and contact mode for an irradiation time of 320 seconds.

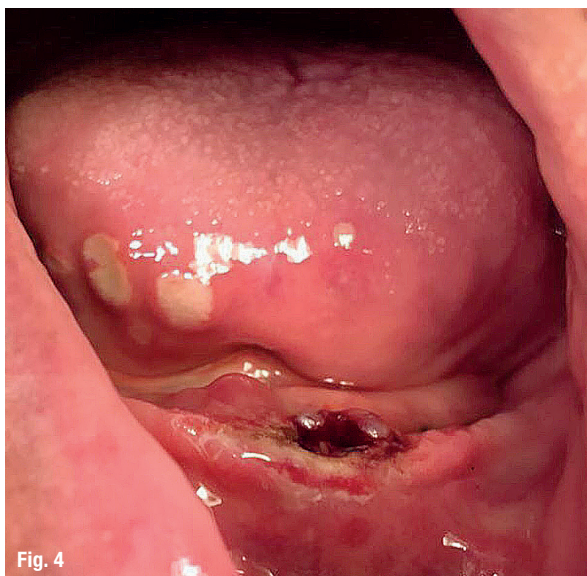


Fig. 4

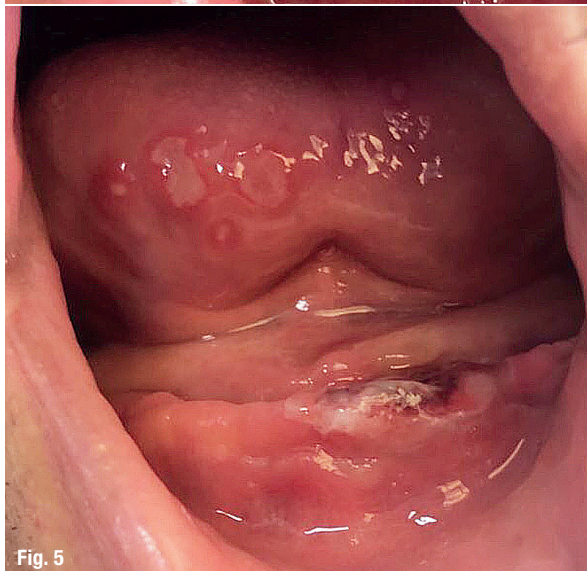


Fig. 5

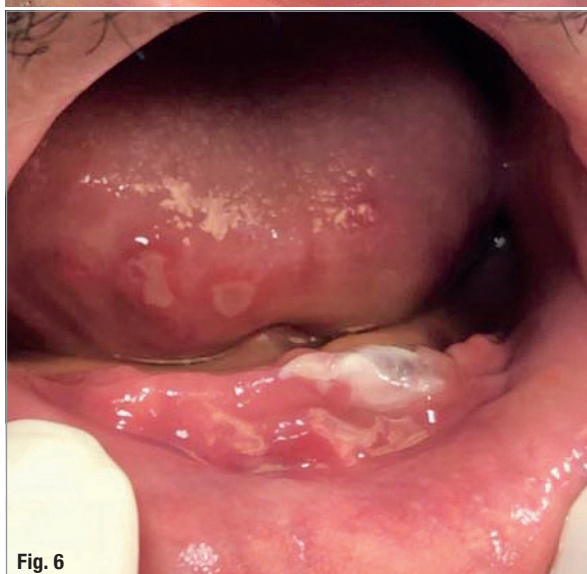


Fig. 6

Fig. 4: Immediately after PGCG surgery and aphthous ulcer photocoagulation. **Fig. 5:** One day after treatment: healing was proceeding well. **Fig. 6:** One week after PGCG surgery and aphthous ulcer photocoagulation.

After removal of the exophytic lesion in order to perform the photocoagulation process for the aphthous ulcers, we changed the laser setting to 400 μ fibre, non-initiated, 0.6W, CW, non-contact mode and an irradiation time of 30 seconds per ulcer at 18J and worked in a circular way from a distance of 6mm to the ulcer in defocused mode, advancing towards the lesion (2–3mm away), covering the entire surface of the ulcer area.

After the ulcer irradiation, a pain/feeling test was done by rubbing the lesion with the finger. For one of the lesions, we needed to increase the output power to 0.7W (21 J) for the second irradiation and then to 0.8W output power (24J) for the third irradiation to achieve full pain control.

During the treatment, high-volume suction was used to evacuate the vapour plume and objectionable odours at the site of operation. The laser-tissue interaction was respected in order to prevent any unsuitable reaction and consequent damage to the surrounding tissue through the progression of the tissue vaporisation at the base of the lesion and the patient's reflexes. A moistened gauze was used for prevention of unwanted thermal damage to the adjacent tissue for the removal of the exophytic lesion.

Removal of carbonised tissue was done using a micro-applicator brush soaked in a 3% hydrogen peroxide solution. The biopsy was sent in for laboratory examination (Fig. 3).

Post-procedural education

The patient was advised on keeping the area clean, avoiding food and liquids that might cause pain or irritation to the sensitive tissue, and taking over-the-counter analgesics as needed. The laser setting was registered in the patient's file for both stages of gross lesion removal and aphthous ulcer photocoagulation.

Final result and follow-up

Excellent laser excisional biopsy was observed with no bleeding, no char and no pain from the aphthous ulcers. The patient did not experience any discomfort and was satisfied (Fig. 4).

The first visit after laser excisional biopsy was one day after the procedure. Healing was as expected, with the healing progressing well and no swelling or pain from the surgery or the aphthous lesion areas (Fig. 5). After one week, the patient revisited and no problem in the healing process was evident (Fig. 6). Finally, after the one-month follow-up, a successful treatment outcome was observed (Figs. 7 & 8).

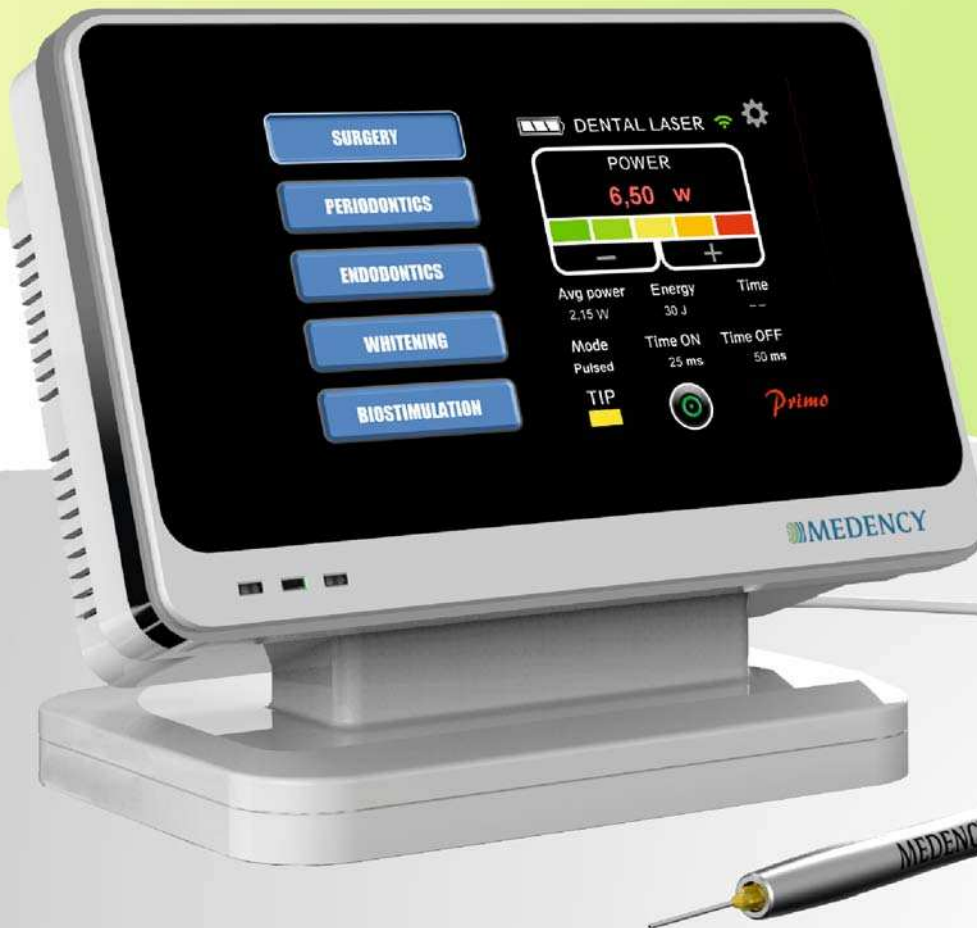
Discussion

In comparison with conventional excisional biopsy procedures (scalpel and suturing), laser-assisted excisional

EXCEED YOUR EXPECTATIONS

MEDENCY
TECHNOLOGY | INNOVATION | PASSION

The most innovative Dental Laser technology for your practice



PRIMO



Cosmetics



Therapy



Periodontics



Surgery



Implantology

One-touch
TECHNOLOGY

Stress-free software, fully automatic parameter selection offers the ideal way to boost productivity.

+35 pre-set
TREATMENT

Versatile, fast and accurate selection of protocols from a large variety of programs.

5-Top
FAVORITES

Every functional aspect of Primo has been developed with end users in mind. Most useful programs at your finger touch.

Active Time
ASSIST

Designed to help users to improve patient's care by stopping the laser output to potentially avoid tissue overheating.

Multi-function
HANDPIECES

The ergonomic lightweight handpiece gives the user a total control of movements. Wide selection of optical tips, whitening arch biostimulation and cosmetic tools.

Master-mode
FOR EXPERTS

Advanced software-enabled mode allows experienced users to achieve outstanding performance and to generate new protocols.



medency.com



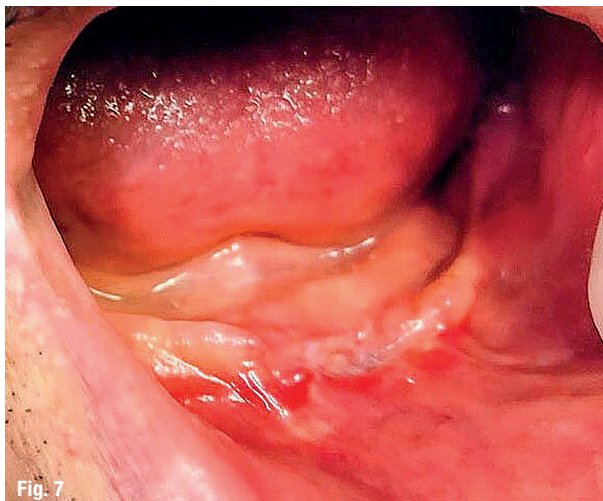

Fig. 7

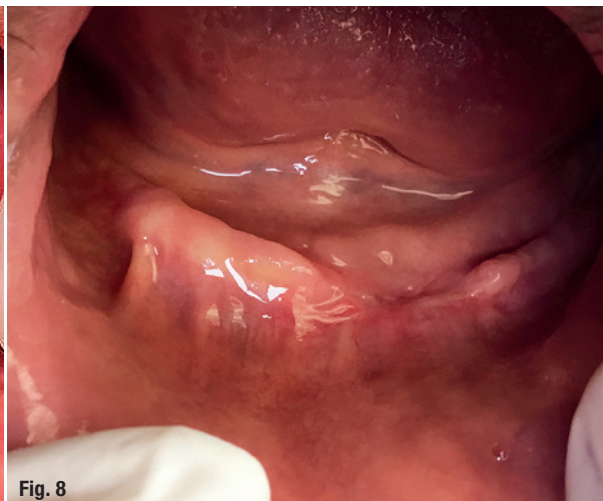

Fig. 8

Fig. 7: Situation one month after PGCG surgery and aphthous ulcer photocoagulation. **Fig. 8:** Final situation two months after treatment.

biopsy can be performed very quickly, with no bleeding, less or no pain, less or no oedema, and little or no need for analgesics.

Because of the size of the lesion in this case, the procedure is traditionally classified as an advanced laser procedure. Full removal of the lesion is very difficult and a recurrent lesion may occur owing to insufficient extension of the surgical area. In laser surgery, a larger extension into the surrounding tissue leads to an efficient removal of the lesion.

Aphthous ulcer photocoagulation was done successfully and pain reduction occurred very rapidly; thus, the patient did not need to use any medication for aphthous ulcer pain control.

Conclusion

The 980nm diode laser is a powerful tool for the removal of a PGCG as well as for the pain relief for aphthous ulcers.

contact

Dr Masoud Shabani

Department of Community Dentistry
School of Dentistry
Ardabil University of Medical Sciences
Ardabil, Iran
m.shabani@arums.ac.ir

Author details



Kurz & bündig

Die Nutzung von Lasern zur Entfernung von oralen exophytischen Läsionen und zur Schmerzkontrolle bei aphthöser Stomatitis wurde bereits in vielen Fällen dokumentiert. Die Laserchirurgie bietet zahlreiche Vorteile, wie die Wahrung steriler Bedingungen, Blutungsreduktion, eine sehr gute Einschätzung der Schnitttiefe, präzises Schneiden, meist keine Notwendigkeit von Nähten oder Verbänden, Schmerzreduzierung, weniger Stress für den Patienten dank minimalinvasiver Prozesse, Förderung der Wundheilung und verringerte Narbenbildung. Heute werden Diodenlaser erfolgreich für die Behandlung von Weichgewebsläsionen eingesetzt.

In dem hier dargestellten Patientenfall behandelten die Autoren ein bereits seit zehn Monaten vorhandenes peripheres Riesenzellgranulom (PGCG) sowie multiple aphthöse Ulzerationen, welche etwa einen Tag vor Vorstellung des 45-jährigen Patienten an der Zunge aufgetreten waren. Während sich das PGCG als nicht schmerzempfindlich erwies, jedoch spontan bei Berührung oder beim Essen blutete, verursachten die Ulzerationen Schmerzen, welche bisher jedoch nicht medikamentös behandelt wurden. Als Ursache für die Beschwerden wurden unzureichende Mundhygiene sowie ein schlecht sitzendes Gebiss diagnostiziert.

Für die Behandlung beider Weichgewebserkrankungen erwies sich der 980 nm-Diodenlaser als erfolgreiches Werkzeug. Das PGCG wurde durch eine großflächige, laserbasierte Exzisionsbiopsie entfernt. Aufgrund der Größe der exophytischen Läsion handelte es sich bei diesem Eingriff bereits um eine fortgeschrittene Laserbehandlung. Für die aphthösen Ulzerationen konnte mittels Photokoagulation eine rapide Schmerzlinderung erzielt werden.



16th WORLD CONGRESS WFLD 2018

1 – 3 OCTOBER 2018
RWTH AACHEN UNIVERSITY
AACHEN, GERMANY



The 16th Congress of the
World Federation for Laser
Dentistry (WFLD)

The 27th Annual Meeting of
the German Society for Laser
Dentistry (DGL)

The 6th Annual Congress
of the World Academy for
Laser Education
in Dentistry (WALED)

This congress will integrate science and practical experience on different levels of presentation and demonstrations, like:

- High ranked international keynote speaker lectures
- On stage live patient demonstrations
- Interactive digital poster presentations
- Oral presentations combined with clinical relevant skill training
- Short presentations of latest research findings
- Clinical case presentations
- Rotating company supporting workshops, gaining continuous education certificates.

CONTACT

Headquarters WFLD 2018 Aachen
Mr. Leon Vanweersch
Vice-Organizing Chairman
Phone: +49 151 50610781
headquarters@wfl-d-aachen2018.com
www.wfl-d-aachen2018.com

Erbium laser in ankyloglossia therapy


Dr Adam J. Wolniewicz, Poland

Ankyloglossia is one of the reasons for problems in breastfeeding, and it causes malocclusion and speech disorders. Ankyloglossia is a congenital abnormality of the oral cavity caused by a lingual fraenum that is too short and thus limits the tongue's movement. It is not always recognised by doctors and speech therapists, causing controversy in both professions. However, if properly diagnosed in childhood and then subjected to frenotomy, the abovementioned problems can be resolved or further treatment enabled. One of the ways of performing frenotomy is using an erbium laser.

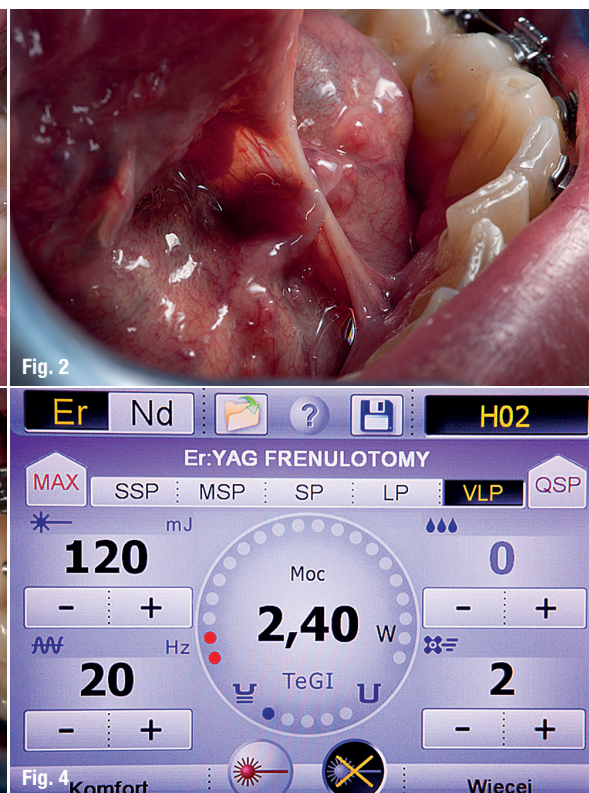
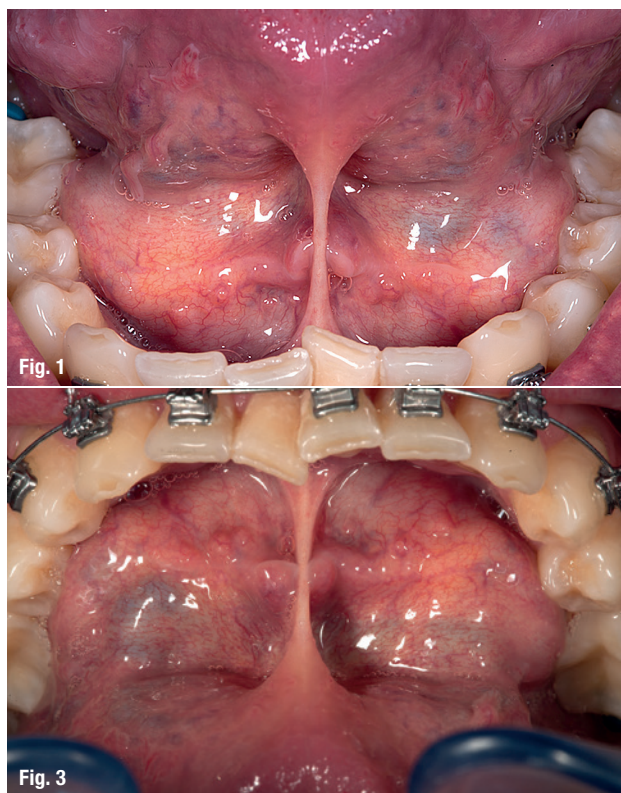
Anatomy

Lingual fraena are composed of loose connective tissue with numerous elastic fibres surrounded by mucosa. In the fetus, they are responsible for the proper direction of

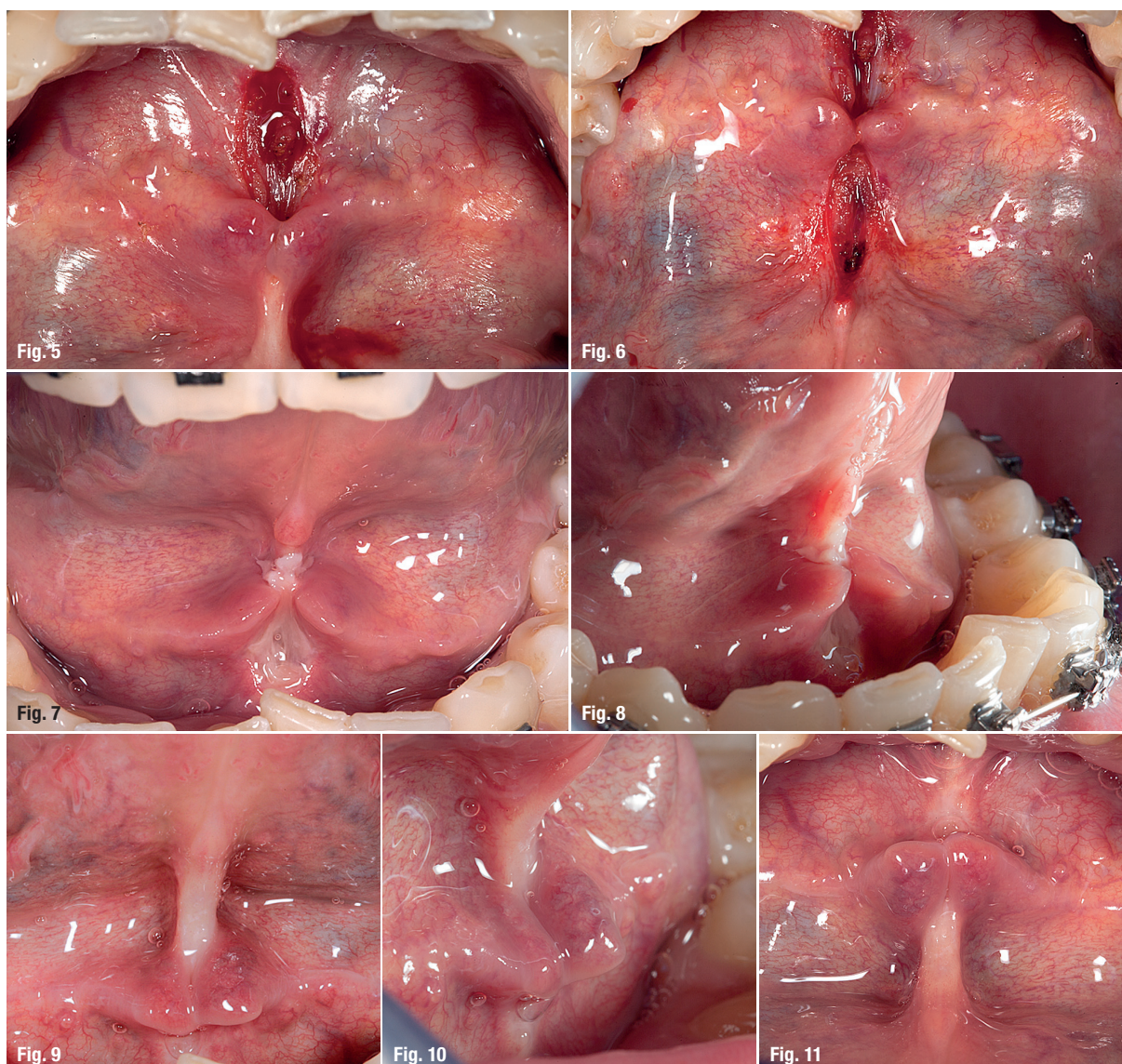
growth of many structures in the oral cavity. After birth, their importance decreases, but if they are improperly shaped, attached or too short, they may affect further orthopaedic, maxillary and functional development.



The lingual fraenum joins the inferior part of the tongue with the floor of the mouth and is visible when the tongue is raised towards the palate. If the lingual fraenum is structured properly and elastic, it does not affect the tongue's effectiveness during suckling, moving food, swallowing, speaking and breathing. If it is short, tight and wide, tongue mobility may be affected, especially when the lingual fraenum spreads from the apex of the tongue to the marginal gingiva of the mandibular incisors lingually.



Case 1 – Figs. 1–3: Situation before frenotomy. Fig. 4: Laser parameters.



Case 1 – Figs. 5 & 6: Condition on the day of fraenotomy. **Figs. 7 & 8:** Condition six days after fraenotomy. **Figs. 9–11:** Condition three weeks after the procedure.

Occurrence rate of ankyloglossia

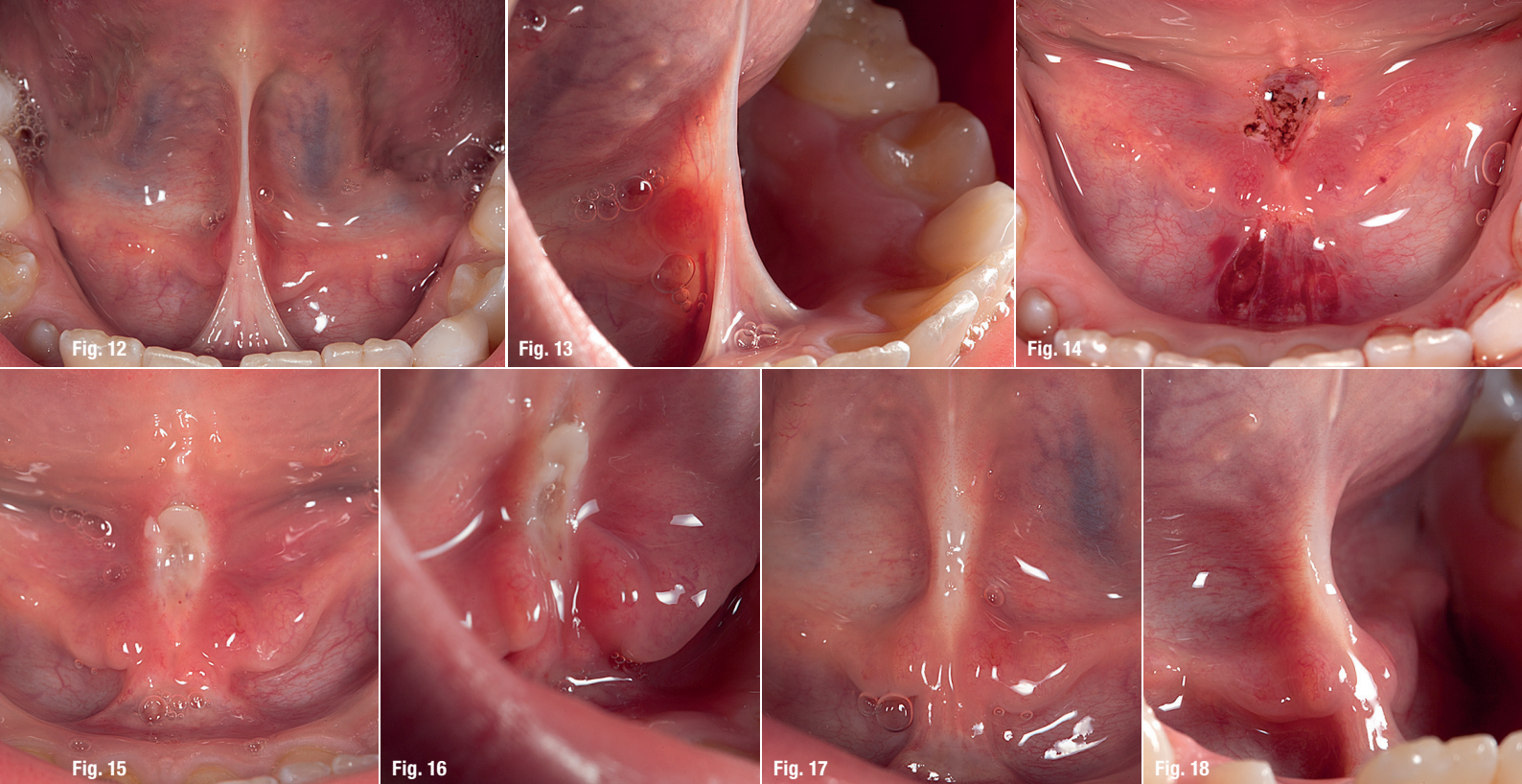
In the world literature, the frequency of ankyloglossia occurrence is estimated at 3–4 %; yet, English and American sources report about 10 up to 16 %. However, it is generally said that speech disorders caused by the abnormal structure of the lingual fraenum occur much more often.

Diagnosis

Despite the fact that this condition seems to be well understood, there are difficulties in diagnosing a short lingual fraenum because different criteria and methods are used. Some speech therapists and doctors use a very simple assessment method via examination of the degree to which the tongue can be moved forward and into a heart shape.¹ Other specialists, including Ostapiuk, differentiate the mobility of the tongue according to five movements.²

Some assume that there is the possibility of extending the lingual fraenum, whereas Pluta-Wojciechowska says that there is no research proving the effectiveness of extending the lingual fraenum through massage and exercise.³ In her research, Ostapiuk clearly shows that, in the case of ankyloglossia, effectiveness of speech therapy cannot be achieved without surgical intervention.²

In a wide study, Fernando proved that untreated ankyloglossia has many consequences for infants, children and adults, ranging from problems with suckling to interpersonal problems caused by speech disorders.⁴ A short lingual fraenum limits tongue mobility and prevents its proper peristaltic movements during suckling. Naturally, it is not the only cause of feeding problems and proper diagnosis is required. However, in the case of a lack of proper body weight gain in an infant, fraenotomy should be taken into consideration.



Case 2 – Figs. 12 & 13: Patient condition before fraenotomy. **Fig. 14:** Condition on the day of fraenotomy. **Figs. 15 & 16:** Condition six days after fraenotomy. **Figs. 17 & 18:** Condition four weeks after fraenotomy.

Among children, ankyloglossia leads to improper growth of the maxilla and mandible, which results in malocclusion. A lingual fraenum that is too short or improperly formed keeps the tongue at the floor of the mouth, preventing the natural process of maxillary widening. A maxilla that is too narrow, in turn, limits the efficient development and protrusion of the mandible, which is the most common cause of Angle Class II malocclusion.

Recognition of the problem before the baby growth spurts, which is before ten months of age, and performing of fraenotomy together with orthodontic treatment and speech therapy constitutes the efficient method of preventing the defect affecting the dentition and phonetics.

Fraenotomy

A solution, as well as a method of prevention, can be fraenotomy, entailing the cutting and releasing of the lingual fraenum, in contrast to fraenectomy, which is the surgical removal of the fraenum. Fraenotomy can be performed with scissors, a scalpel, cautery or a laser. Depending on the age and condition of the patient, the procedure can be performed under general, local, topical or no anaesthesia at all.

Among infants, fraenotomy is performed mainly by paediatric surgeons and is applied owing to lactation problems, especially in the first days of life, in the hospital. Among older children, however, this procedure is performed mainly at the request of speech therapists and orthodontists. Among adults, it is conducted to correct a prosthetic base or to prevent periodontitis.

Laser application in soft-tissue surgery

As mentioned, one of the tools used to perform the cutting of the lingual fraenum is a laser. In soft-tissue surgery, many types of lasers are applied: diode, Nd:YAG, carbon dioxide, Er,Cr:YSGG and Er:YAG lasers. They emit various wavelengths and, depending on the work parameters chosen, they can affect tissue in different ways. Particularly useful lasers for soft-tissue preparation seem to be the so-called hard lasers, such as carbon dioxide and Er:YAG, because their main feature is a short penetration depth. This means that the energy they emit is absorbed only by the surface and does not cause thermal damage to the deeper-lying tissue.

Case presentation

In my daily practice, I use the LightWalker ATS laser (Fotona). It combines two radiation sources in one appliance: Er:YAG with a 2,940nm wavelength and Nd:YAG with a 1,064nm wavelength. Owing to this configuration, this device allows one to perform many advanced procedures and work on both the hard and soft tissue.

In fraenotomy procedures, the following parameters are used for the Er:YAG laser: VLP 120mJ, 20Hz (output power 2.40W), water: 0, air: 2. The contra-angle handpiece used most often is the H02. Sometimes, in the case of intensive bleeding, the Nd:YAG laser is also used in order to stop bleeding. Then, the parameters are: VLP, 4W and 20Hz.

Case 1

A 34-year-old male was referred by the orthodontist for fraenotomy as a part of the orthodontic treatment plan

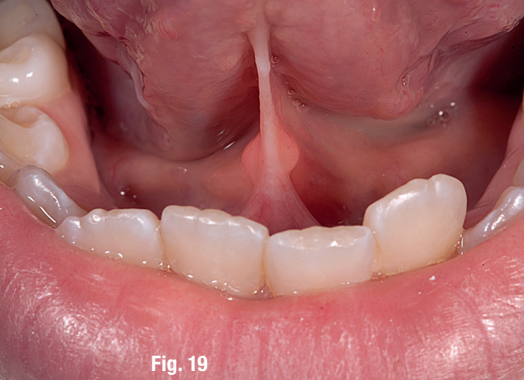

Fig. 19

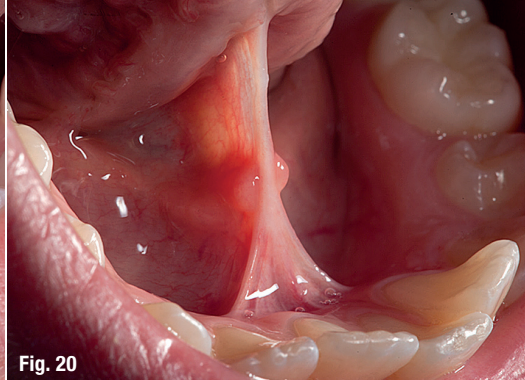


Fig. 20

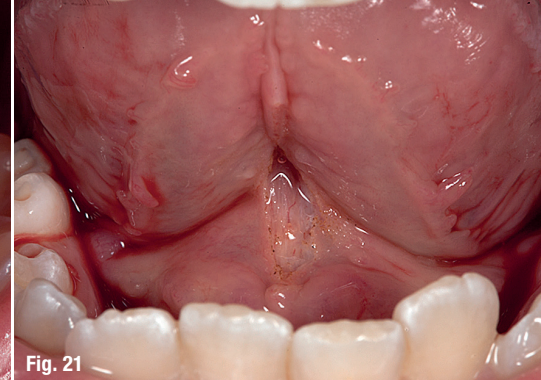


Fig. 21

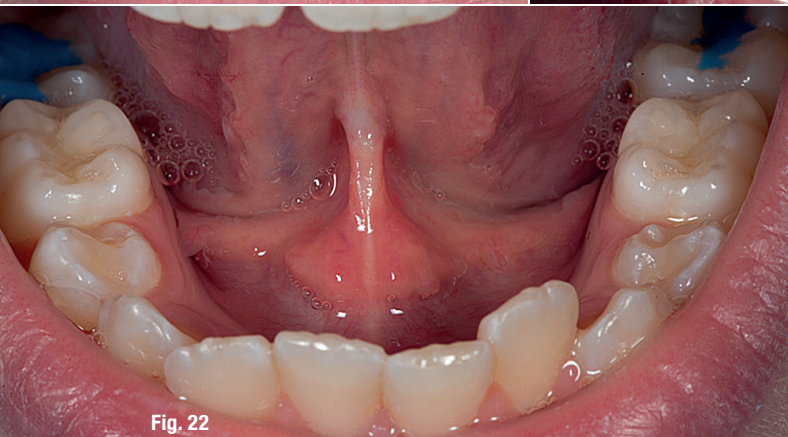


Fig. 22

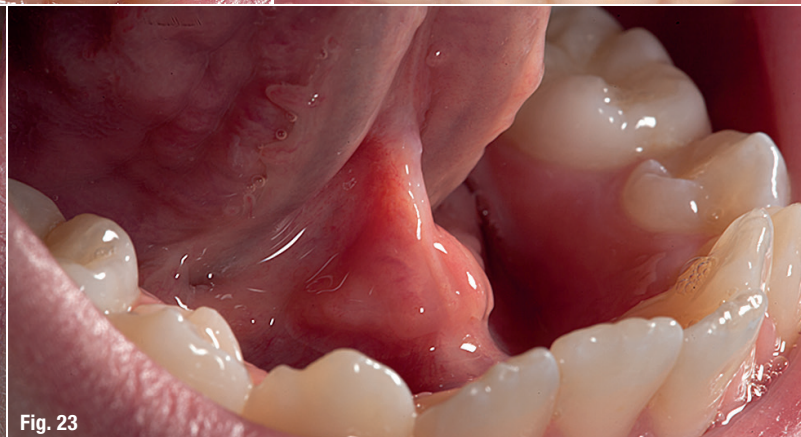

Fig. 23

Case 3 – Figs. 19 & 20: Patient condition before the procedure. **Fig. 21:** Condition on the day of the procedure. **Figs. 22 & 23:** Condition 11 days after fraenotomy.

(Figs. 1–3). Fraenotomy was performed under local infiltration anaesthesia with 4% Ubistesin forte (3M ESPE) using the Er:YAG laser (Figs. 4–11).

Case 2

A 10-year-old male patient undergoing speech therapy was referred by the orthodontist for fraenotomy (Figs. 12 & 13). The procedure was performed under local infiltration anaesthesia with 4% Ubistesin forte using the Er:YAG laser. Clot formation was performed with the Nd:YAG laser (Figs. 14–18).

Case 3

An 11-year-old female patient undergoing speech therapy was referred by the orthodontist for fraenotomy (Figs. 19 & 20). Fraenotomy was performed under local infiltration anaesthesia with 4% Ubistesin forte using the Er:YAG laser (Figs. 21–23).

Conclusion

Ankyloglossia certainly has a great impact, ranging from infancy to adulthood. Fraenotomy performed with an Er:YAG laser, in particular, is a simple and uncomplicated procedure that allows the avoidance of many unnecessary consequences resulting from the abnormal structure of the lingual frenum.

contact

Dr Adam J. Wolniewicz

Diplomate PSI/ICOI
Member of PTSL, PASE, PSI/ICOI
Orłowska Dental Clinic
Orłowska 61, 81-001 Gdynia, Poland
www.wolniewicz.eu

Author details



Kurz & bündig

Die Auswirkungen einer Ankyloglossie reichen von der Kindheit bis ins Erwachsenenalter. Ankyloglossie gilt als eine der Ursachen für Probleme beim Stillen und kann Sprachstörungen und Malokklusion bei Säuglingen und Kindern auslösen. Es handelt sich dabei um eine genetische Fehlbildung der Mundhöhle, welche durch ein verkürztes Zungenbändchen bedingt wird. Das fehlgebildete *Frenulum linguale* limitiert aufgrund seiner eingeschränkten Länge die Bewegungsoptionen der Zunge. Die unterschiedlichen angewandten Untersuchungskriterien und -methoden resultieren für Sprachtherapeuten und Ärzte häufig in Diagnoseschwierigkeiten. Wird Ankyloglossie jedoch frühzeitig in der Kindheit erkannt und mit einer Frenotomie behandelt, können die oben genannten Probleme verhindert werden. Mit einer folgenden kieferorthopädischen Behandlung und Sprachtherapie werden spätere Gebiss- und Phonetikdefekte weiterführend abgewendet. Eine mit einem Er:YAG-Laser vorgenommene Frenotomie stellt eine besonders einfache und unkomplizierte Behandlungsmethode dar, welche viele unnötige Beeinträchtigungen resultierend aus der anormalen Struktur des Zungenbändchens verhindern kann. Der Autor stellt drei Fallbeispiele mit detaillierter Fotodokumentation aus seiner eigenen Praxis vor, bei welchen er den LightWalker ATS Laser (Fotona) verwendete.

Successful communication in your daily practice

Part VI: Economic crisis

Dr Anna Maria Yiannikos, Germany & Cyprus



Hi! I am Dr Anna Maria Yiannikos and I am very happy to share the 6th part of this new loved series filled with communication protocols with you. This series includes the most popular and challenging scenarios that might occur in your dental practice and presents successful ways of how to deal with them—so your patients will always leave your practice feeling satisfied and thinking: “My dentist is THE BEST!”

Each article of this series will teach you a new, easy to use specialised protocol, which can easily be customised and adapted to your own dental clinic's requirements and needs right from day one.

Let's start with today's challenging topic which is... how to deal with economic crisis. If we have a look on how patients and their habits change during a depressed economic period, you will notice that your patients will:

- reduce their spending,
- set stricter priorities, and
- feel anxiety and anger regarding the near future.

But, they will still spend their money... Your goal thus is, to encourage them to have their treatments done, to offer them different services, to promote your services with a unique attitude and last but not least to maintain or even increase your income.

5 effective ideas

Yes, you can still increase your income. Are you wondering how? Discover five effective ideas on how to do so immediately.

1. Make the appropriate changes without having a panic attack

If these changes include reducing the prices of your treatments, which one will you choose?

Will you reduce the price of

© maxicam/Shutterstock.com

fillings or crowns? Make the right choice based on price elasticity rules. The right answer is, to decrease the price of crowns, otherwise your revenues will reduce enormously. Do not reduce the salaries of your talented employees, but let the unproductive ones or the one who you feel is an obstacle for you and your clinic go.

2. Introduce special services

Increase the value of your treatment by introducing special package services, for example, offer laser cavity preparation with no extra charge or combine dental cleaning with fluoridation without any additional cost for the fluoridation.

3. Extend credit periods

Offer layaway plans or extend the credit periods and ask your suppliers for the same for yourself. However, remember to negotiate profitably!

4. Challenge penny-wise behaviour

If you realise, for example, that the patient could afford to have the crown done, but chooses to postpone it due to fear of the future, explain in detail what the consequences and the costs of postponing the treatment will be. Highlight the fact that the tooth might break and the cost would be tripled when treating it then instead of now.

5. Continue educating your patients

Share your knowledge with your patients through your YouTube videos or by giving VIP seminars. What is your ultimate goal? It is, to emphasise the quality and the differentiation of your services, and to clearly show that you are THE expert and that the treatments you offer your patients are so special and valuable that they need to have them, now!

Are you ready?

This is very useful insight, don't you think? I am sure that you are looking forward to the next issue of laser magazine, where I will present the 7th part of this unique new series of communication concepts to you, teaching you how to offer VIP services for your distinguished patients. You want these patients to choose you, so, I will share 5 revolutionary tips with you that will guarantee you this delicious outcome.

Until then, remember that you are not only the dentist of your clinic, but also the manager and the leader. For further questions and requests for more information and guidance, keep in touch by sending me an e-mail to dba@yiannikosdental.com or via our website www.dbamastership.com. I am looking forward to our next trip of business growth and educational development!



Author details

contact



Dr Anna Maria Yiannikos

Adjunct Faculty Member of AALZ
at RWTH Aachen
University Campus, Germany
DDS, LSO, MSc, MBA
dba@yiannikosdental.com
www.dbamastership.com

Kurz & bündig

Im sechsten Teil ihrer Serie „Erfolgreiche Kommunikation im Praxisalltag“ widmet sich Dr. Anna Maria Yiannikos fünf effektiven Ideen, um Praxiserträge in Zeiten finanzieller Krisen konstant zu halten oder sogar zu steigern. Wichtig ist es dabei, zunächst nicht in Panik zu verfallen, sondern kosteneffektiv zu denken. Das heißt, nicht etwa den Lohn der besten Mitarbeiter zu senken, sondern stattdessen die Kosten für beispielsweise Kronen den Regeln der Preiselastizität entsprechend zu reduzieren.

Idee zwei betont die Möglichkeit, besondere Zusatzleistungen, wie z.B. eine laserbasierte Kavitätenvorbereitung, kostenfrei in eine bestimmte Behandlung zu integrieren, um diese attraktiver zu gestalten. Zusätzlich können Sie Patienten mit verlängerten Zahlungsperioden entgegenkommen. Es ist jedoch wichtig, dabei die eigenen Zahlungsverpflichtungen nicht außer Acht zu lassen und weiterhin gewinnbringend zu agieren.

Idee vier und fünf konzentrieren sich vor allem auf die Patientenbildung und eine öffentlichkeitswirksame Kommunikation. Das bedeutet zum einen, Patienten zu Behandlungen zum gegenwärtigen Zeitpunkt zu ermutigen und zu verdeutlichen, welche Extrakosten entstehen würden, sollten diese weiter verschoben werden. Zum anderen ist es stets wichtig, die Qualität des eigenen Angebots zu kommunizieren und sich von Mitbewerbern zu differenzieren, sodass die Patienten erkennen, Sie sind der Experte und Ihre Leistungen sind jeden Cent wert.



Six Sigma in the management of laser-assisted dental practices

Dr Imneet Madan, UAE

Every organisation has to have a source of income in order to stay in business. Thus, dentistry is facing the same challenge as businesses in the manufacturing industry are. This challenge is being profitable at what the company is doing. Without a proper focus on the financial aspects, which are, indeed, the key performance indicator, the management of the organisation will drift to trivial, unproductive issues.

The Six Sigma principles

Commitment

Persistence and diligence are the two underlying keys for the success of any business idea. Knowledge gained must be shared among those that are involved in the application. This is the reason the Six Sigma philosophy says that there is no “I” in the “team”. It is always about “we” moving ahead together.

When the master black belt executes the project, the rest of the team needs to be incorporated in order to understand and pursue the same principles and objectives. Six Sigma brings in a breakthrough change that then needs to be incorporated as a lasting strategy in order to gain long-term results. At least two years of commitment are documented to be essential in order to see the development of work. The most common cause of organisations failing at Six Sigma application is a lack of commitment to true process improvement.

The entire team that is on board for Six Sigma must be trained to carry out the implementation of the tools learnt, the process charters and the improvement strategies—even after the project is over. Commitment to Six Sigma needs to be long term in order to see the continual improvement.

Unique selling proposition (USP)

The USP of Six Sigma is: “Do the right thing first the very first time.” Anything else is considered to be a waste and a non-value-added service that does not improve the financial inputs of the organisation. According to lean principles, any form of waste, or “*muda*” (Japanese for “futility”) should be eliminated from the service or manufacturing company in order to generate revenue from the existing resources.

In dental practice, *muda* may include the following:

- retreatment of cases with no extra payment;
- improper use of material and dental supplies;
- front desk staff not scheduling recalls or poor appointment scheduling systems;
- improper use of existing data from patients;
- lack of team spirit, which lowers interteam referrals;
- referring patients outside the practice brings the market value of the clinic down, especially if it is a multi-specialty practice; and
- inadequate use of the marketing team.

Muda in all of these situations can be extensive, as a great deal is spent on building up the patient base of the practice. Reverting the order of this and then taking steps to rebuild is a classic example of *muda* in dental practice. *Muda* should be avoided at all times in order to improve the financial inputs of the company.

Philosophy

The key philosophy of Six Sigma is that each company whether it is manufacturing cars or healthy teeth, can be considered a process. A process has two components: input and output. If inputs are controlled, outputs are controlled automatically. This is generally expressed as the $y = f(x)$ concept. According to Six Sigma, any process can be defined, measured, analysed, improved and controlled (DMAIC).

Set of tools

Six Sigma works with multiple sets of tools. A few of them applicable to dental practice are control charts, failure mode and effect analysis, and process mapping.

Methodology

DMAIC defines the steps that the Six Sigma practitioner has to follow in the organisation. It starts with identifying the problem and ends with implementation of long-lasting solutions.

Metrics

Six Sigma quality performances mean 3.4 defects per million opportunities, accounting for a 1.5 sigma shift in the mean. The idea is to reduce the variation in the process.

Implementation of the Six Sigma principles in laser-assisted dental practices

The DMAIC model of Six Sigma needs time and resources for implementation. Parallel support from all the units in the organisation is essential for the accomplishment of the Six Sigma project, in terms of having the information technology group supply the data and the financial unit give data in the form of cost of quality analysis.

The DMAIC model can be applied to the dental clinic as follows:

Define

There can be no solution if the problem is not known. The most pivotal part of Six Sigma is defining the problem in a specific manner. It involves the proper study of the whys and hows of the problem. In a dental practice, one of the key concerns can be the flow of patients. There is a certain amount of focus on establishing an inflow of new patients, but there can be a substantial amount of market that can be created with the existing data. When it comes to controlling the outflow of cash from the office, inventory control can also be looked into. Specific concerns can only be addressed if the problem has been well defined.

Measure

As Robin Sharma, the author of the multiple award-winning book *The Monk who Sold his Ferrari*, stated, "What

gets measured gets improved". In order to measure the defined problem, the practice needs to look into specific and relevant data. Six Sigma focuses on collecting the required data with check sheets, Pareto charts, histograms, scatter diagrams and many other tools. The collected data can be helpful in establishing the amount of variation. In the measure phase, a current baseline is set up for the purpose of later reference.

Analyse

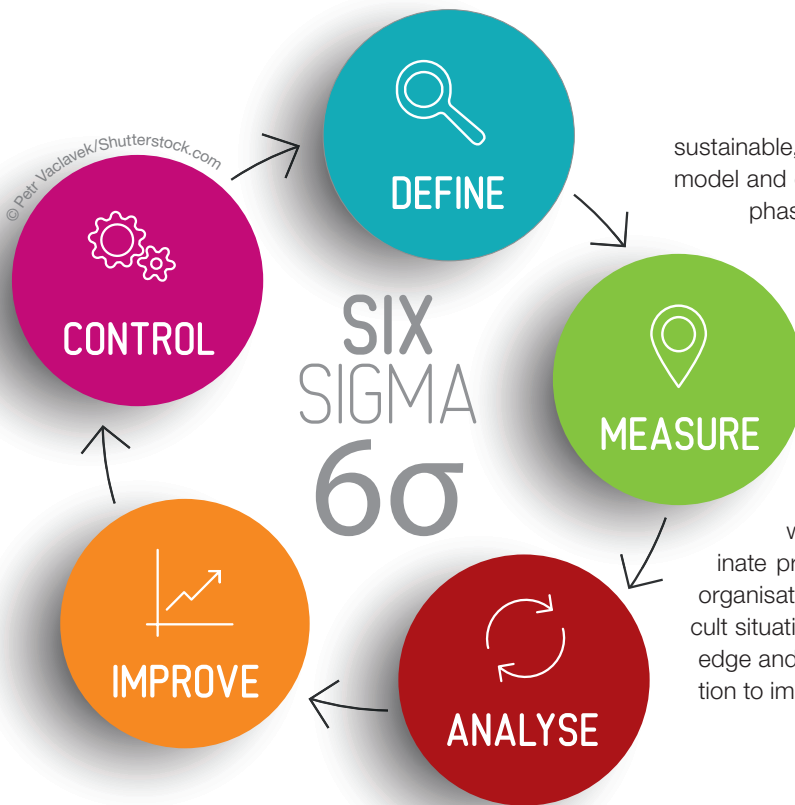Analysis of the data, either with experimental measures or with audits, helps to rule out the root of the existing problem. Once a definitive, measurable figure can be given to the problem, it becomes easy to work towards the solution.

Improve

The improve phase of the problem requires the conduction of failure mode and effect analysis (FMEA). FMEA is the road map to figuring out all the possible modes of failure and then working backwards in order to avoid them or find solutions in case they still occur.

FMEA is a very helpful tool, as it allows a 360° evaluation of the possible failures in the project. Once the problems that could potentially occur become evident, the idea is to have the exit strategy or solutions already in advance. These backward steps from the possible failures prepare the team to execute the project better.





sustainable, the organisation must follow the DMAIC model and celebrate the success at the end. Once one phase has been completed, it is good to start all over again for continual improvement, and this is then conducted with a plan-do-study-act cycle.

Conclusion

Any organisation that has an improvement-based corporate culture will imbibe the DMAIC philosophy of Six Sigma and will be consistently able to improve and eliminate problems. If, however, on the other hand, an organisation becomes trapped in the pitfalls of difficult situations or mired in bureaucracy, it could lose its edge and reduce its overall effectiveness and motivation to improve.

Control

Once the Six Sigma steps have been brought forward and executed, it is absolutely important that the entire team participates and keeps the measures taken in place. Many organisations execute Six Sigma, but the problems return, as the system itself does not generate Six Sigma unless the people who operate the system have completely adopted it. There must always be a dynamic control plan, including a mistake proofing approach, process behaviour charts and updating of lessons learnt.

Six Sigma road map

The Six Sigma journey is a breakthrough and not a continual improvement. In order to make the system

contact

Dr Imneet Madan

Specialist Pediatric Dentist
MSc Lasers Dentistry (Germany)
MDS Pediatric Dentistry
MBA Hospital Management
Children's Dental Center, Dubai
Villa 1020 Al Wasl Road
Umm Suqeim 1, Dubai
United Arab Emirates
Tel.: +971 506823462
imneet.madan@yahoo.com
www.drmichaels.com



Kurz & bündig

Six Sigma als Managementsystem dient der kontinuierlichen Prozessverbesserung und Qualitätssteigerung. Die Philosophie des Six Sigma sieht jedes Unternehmen, ob Industrie oder Dienstleister, als Prozess, welcher definiert, gemessen, analysiert, verbessert und kontrolliert (defined, measured, analysed, improved, controlled = DMAIC) werden kann. Jedes erfolgsorientierte Unternehmen kann von dieser DMAIC-Methode profitieren. Die Autorin stellt die sechs wichtigsten Prinzipien des Verfahrens dar und erläutert im Folgenden, wie diese sowie die DMAIC-Methode in der zahnärztlichen Praxis Anwendung finden können. Ein bleibendes Engagement ist entscheidend, mindestens zwei Jahre sollten für die erfolgreiche Implementierung angedacht sein und die Strategie dauerhaft inkorporiert werden, um langfristige Ergebnisse zu erzielen. Dinge von Beginn an richtig zu machen, gilt als USP des Six Sigma; so sollen keine Ressourcen für sogenanntes „muda“ (japanisch für „sinnlose Tätigkeit“) verschwendet werden.

Ziele der Prozessoptimierungen sind eine kontinuierliche Verbesserung und Eliminierung von Problemen. Dabei ist es besonders wichtig, dass alle Teammitglieder über den gleichen Wissensstand verfügen und gemeinsam in die gewünschte Richtung arbeiten. Austausch und gegenseitige Unterstützung zwischen allen Unternehmenseinheiten sind dabei unerlässlich. Um die Qualität langfristig zu steigern, müssen Erfolge zwar gefeiert, optimierte Prozesse jedoch auch stets erneut der DMAIC-Methode unterzogen werden.

Technology, **innovation** and passion

Laser devices bring improvement to the daily practice

Timo Krause, Germany

MEDENCY is a dynamic and innovative dental equipment and technology company privately owned and based in Vicenza, Italy. Since its founding, CEO Alessandro Boschi has driven the company forward through his unique passion and profound experiences in the field of laser dentistry. Prior to MEDENCY, Boschi had taken up

many important leadership roles in various dental businesses over the past 15 years, forming an in-depth understanding of business as a dedicated team effort. Hence, MEDENCY presents an utterly talented team with global expertise in the field of dentistry and, in particular, dental lasers. The overall objective and ultimate mission



TECHNOLOGY

INNOVATION

PASSION

is to provide a combination of cutting-edge products and services like tailor-made educational courses as well as a high-level of customer exchange, while drawing on a wide network of academic partners. *laser* had the opportunity to speak with Alessandro Boschi about his ideas and thoughts regarding laser dentistry and the benefits of utilising lasers in daily practice.

Mr. Boschi, what makes MEDENCY a leading force in the field of dental lasers?

Technology, innovation and passion are the main features of MEDENCY. We are creating solutions to make comfort more widely available without compromising quality—that is our major challenge. All our products arise from the highest dedication to research and development. We are therefore setting the highest standards in manufacturing our medical devices, dental lasers, and electronic systems. We are extremely proud of the fact that our medical devices and their applications are employed by professionals and specialists in their respective fields worldwide. We think, first and foremost, of others, and take a sincere interest in all points of view. Freedom of ideas is, in our understanding, an absolute prerequisite for innovation.

What are the challenges dentists face today in their daily practice?

The rapidly growing demand for high quality and professional treatment is a big and driving factor for dentists all over the world. Hence, whatever their specialty may be, they have to acknowledge those needs and demands, act on them and even foresee trends and developments. Therefore, the dental industry's focus must be on these constant and fast developments. Dentists have to leave their comfort zone behind, learn about new technologies and techniques in order to provide patients with the best and most up-to-date solutions available on the market.

Alessandro Boschi, CEO of MEDENCY
at the ADF 2017 in Paris, France.

The PRIMO dental laser device is one of your key products on the market. What are the major advantages and benefits for users?

Lasers have several uses for dental surgery, periodontics, endodontics, implantology, cosmetics, and further therapy. PRIMO combines state-of-the-art diode laser technology with the innovation and experiences MEDENCY has gained in the dental industry. Thanks to its intuitive interface and the easily accessible wide touch screen, the device is very easy to use. This small portable unit comes with variable tips and hand pieces for multiple treatment procedures. Currently, new models are being finalised in the last stages of development. Among them is a new device that shall help implantologists fight the new "tsunami" of the dental field—called peri-implantitis. Furthermore, in the near future, we are going to launch a unit specifically for hygienists as an adjunct device for scaling and root planing.

In your opinion, how have lasers changed the dental market so far, and what are your future plans?

Laser is one of the newest developments in dentistry, and has stimulated growth in the medical and dental equipment market. Particularly in dental surgery, laser offers numerous benefits, rendering treatment more effective for the dentist and less painful for the patient, accelerating treatment options and leading to significantly improved patient outcomes. I am convinced that dental lasers will be utilised more and more in dental practices. Therefore, we will continue our efforts to show, how lasers make the practice life easier for dentists and their teams. Our aim is to inform dentists of all the benefits arising from using lasers in their daily routine. Furthermore, we will increase our current full support of academic and university programmes aimed at studying new instruments and possible fields and indications of use.

contact

MEDENCY Srl

Piazza della Libertà 49
36077 Altavilla – Vicenza, Italy
Tel.: +39 0444 371462
info@medency.com
www.medency.com



“The Future of Dentistry is Here”

Dr Diana Constantinescu, Romania

From 23 to 25 March 2018, the Romanian Association of Minimally Invasive Dentistry (ARSMI) hosted the first edition of the “The Future of Dentistry is Here” Symposium in Brasov, Romania. The two-day symposium was thus set in Transylvania—Dracula’s country (Fig. 1). More than 150 clinicians from Bulgaria, Hungary, Germany, Spain, Iraq, the Netherlands, Greece and Romania, among others, attended the programme concentrating on dental specialties with lasers.

Our special thanks goes to Prof. Dr Norbert Gutknecht (Germany) for his participation and his support in making this event happen. He is a wonderful source of scientific information and a great inspiration to all of us. We also owe special thanks to all the speakers for their great lectures and for managing to cover 360 degrees of laser dentistry. Not only did all the doctors find useful information in each lecture, it was also a true pleasure listening to them.

The first day of the symposium started with a short opening ceremony held by Prof. Gutknecht. In the first lecture, Dr Dimitris Strakas (Greece) presented the topic “The Dracula’s smile project: The truth behind the myth of laser bleaching”. Dr Strakas shared insights on the bleaching mechanism and techniques using both diode and Er,Cr:YSGG laser.

Prof. Gutknecht dedicated the following session to “Lasers in endodontics—facts or fiction?” (Fig. 2). He spoke about the promising capacity of lasers in achieving the decontamination of the endodontic system. It was a great lecture that held everyone on the edge of their seats. After lunch, Prof. Gutknecht further presented on “Peri-implantitis: The tsunami in modern dentistry” and how it can be approached with the aid of lasers. Again, the decontamination effects that laser light has on both tissue and the implant surface and the minimally invasive techniques were in the spotlight.

The following lecture was given by Dr Monika Masilionyte (Lithuania) on “Saving compromised teeth: 940nm diode laser assisted endodontic treatment”. In the afternoon Dr Codruta Ciurescu (Romania), one of the first to achieve the Romanian Master of Science in Laser Dentistry spoke about “Laser periodontics” as a particular approach achieving remarkable results. Further Dr George Mihai (Romania) reported on “The benefit of the laser treatment in edentulous abscission of gum hyperplasia” with a case presentation.

The scientific programme of the day ended with Dr Alida Moise (Romania) presenting on “Conscious sedation in dentistry”. Dr Moise spoke about the nitrous oxide sedation in the dental office covering sedation mecha-



Fig. 2



Fig. 3



Fig. 4



Fig. 5

Fig. 1: Impression of the symposium venue: Bran Castle near Brasov, Romania—Dracula's castle. **Fig. 2:** Prof. Gutknecht presenting on "Lasers in endodontics—facts or fiction?". **Figs. 3 & 4:** Conference participants gaining further practical experience during the workshop sessions. **Fig. 5:** Closing party with wonderful people, good wine and great music.

nisms and techniques, the indication for this type of sedation and the legal aspects of performing it. In the evening everyone enjoyed a well-deserved cocktail party.

The second day of the symposium was characterised by further scientific insights of the invited experts. Dr Moise started the day, this time presenting on "Allergies, accidents, incidents, resuscitation". The next speaker was Dr Pierre Bruet (France) who reported on "Soft- and hard-tissue management after extraction" sharing his vast experience in the classical approach of surgery and implantology with the audience.

The following presentation was held by Dr Gilles Chaumanet (France), who spoke about "Predictable implantology using the new minimally invasive techniques strategy and dual wavelength procedure". Dr Chaumanet described surgical techniques as well as the applications and the benefits of combining the 940 nm diode laser and Er,Cr:YSGG in implantology.

After the lunch break Dr Youssef Sedky (Egypt) concentrated on the topic "940nm diode laser: My magic wand in orthodontics". Dr Sedky highlighted how orthodontic treatments can be accelerated by using the bio-stimulation effect of the 940nm diode laser and also emphasised the soft-tissue surgical applications of this laser.

Laser pain therapy specialist Dr Maria Pilar Martin (Spain) concluded this day of conferences with two presentations. The first one was called "LLLT in dentistry", in which Dr Martin spoke about the benefits of light for the human body and how to integrate this bio-stimulating effect of lasers in treatment. The second lecture focused on

"Lip repositioning and dermatology with laser". Here, Dr Martin explained her multidisciplinary approach on solving aesthetic pathologies, facial asymmetries, postural problems, gummy smile and rejuvenation treatments. She demonstrated that lasers can be very effective and at the same time minimally invasive in these types of treatment—summarising how the proper use of lasers can lead to life-changing results for the patients.

In addition to the scientific lectures, the practical aspect of the treatments was also not neglected. Workshop sessions on laser application skills and implantology were offered during the first and the second day of the symposium (Figs. 3 & 4). The last day of the conference ended with a gala dinner. It was a great party that had all the right ingredients: wonderful people, good wine and great music (Fig. 5).

Needless to say that the first edition of the "The Future of Dentistry is Here" Symposium was a success, a true learning experience and a nice occasion to meet great doctors from around the world. Once again, we congratulate all the speakers, we thank all the doctors that joined us and we are looking forward to doing it all again next year.

contact

Cristina Toader

ARSMI

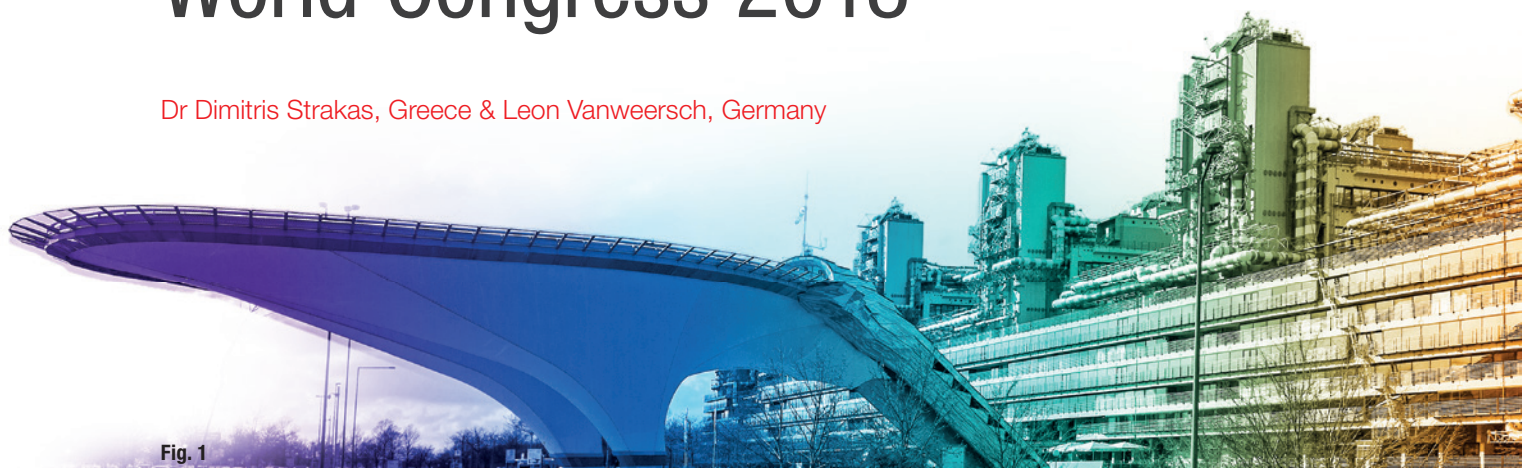Bd. Corneliu Coposu Nr. 7

030602 Bucharest, Romania

cristina@laser-stomatologic.ro

WFLD's Pearl Anniversary World Congress 2018

Dr Dimitris Strakas, Greece & Leon Vanweersch, Germany



Our laser scientific world will once more be uniting for the most well-known event of its kind—the 16th dental laser congress of the World Federation for Laser Dentistry. WFLD, formerly known as International Society for Laser Dentistry (ISLD), was established back in 1988. The scope was always the same: to serve as a non-profit medium for the exchange, advancement and dissemination of scientific knowledge on the use of lasers for treatment and research in the oral and dental environment.

Starting with the first world congress that was held in Tokyo, Japan, it became evident that this society would have a bright future. These highly scientific events have been recurring every two years since and have become the meeting point for the global laser family. The cities Tokyo (Japan, 1988), Paris (France, 1990), Salt Lake City (USA, 1992), Singapore (1994), Jerusalem (Israel, 1996), Hawaii (USA, 1998), Brussels (Belgium, 2000), Yokohama (Japan, 2002), São Paulo (Brazil, 2004), Berlin (Germany, 2006), Hong Kong (China, 2008), Dubai (UAE, 2010), Barcelona (Spain, 2012), Paris (France, 2014) and Nagoya (Japan, 2016) have been the 15 stops that this federation has offered to the world of laser science so far.

But this year—2018—the venue is of even greater value for two reasons. Firstly, the 16th World Congress will be celebrated as the WFLD's pearl anniversary as we will be completing 30 years since its foundation in 1988. Moreover, the event will be held in the city of Aachen, Germany, which is not only at the heart of Europe, but its university, RWTH Aachen University, is also considered to be one of the most respected and prominent academic names in laser science.

From 1 to 3 October 2018, the 30th anniversary of WFLD will be held at the RWTH Aachen University Hospital, under the wings of WFLD, DGL and WALED. It is our goal to achieve the highest attendance of all times for this milestone event—also gaining confidence and momentum from last year's very successful WFLD European Congress in Thessaloniki, Greece.

The organising chairman, Prof. Dr Norbert Gutknecht, stated: "It is my intention to make this congress a turning point in the set-up and structure of executing such congresses. This congress will integrate science and practical experience on different levels through presentations and demonstrations like high-ranked international keynote speakers, on stage live patient demonstrations, interactive digital poster presentations, oral presentations combined with clinically relevant skill training, short presentations of latest research findings, outstanding clinical case presentations, rotating company-supported workshops, and last but not least the option of gaining continuous education certificates. I also cordially invite all dental laser companies to seize this opportunity to present and demonstrate their products during this special anniversary world congress!"

The programme set-up and the evaluation of a large number (over 200 so far) of abstract submissions is a huge task for the scientific committee. The whole procedure is led by the scientific committee chairman Prof. Dr Lynn Powell, who stated: "Thank you all for the so far great number of submissions. We have extended the deadline to 14 May 2018. You can still submit an abstract for presentation to share your research results, clinical experience, new techniques and your knowledge with



Preliminary
Programme





**16TH WORLD CONGRESS
WFLD 2018
AACHEN**
THREE DECADES
OF LASER INNOVATION
1-3 OCTOBER

16th World Congress WFLD 2018

Check out the detailed Preliminary Congress Programme
by scanning the QR above.

Fig. 1: Venue of the 16th WFLD congress: the RWTH Aachen University Hospital. **Fig. 2:** Evaluation of abstract submissions by Prof. Dr Norbert Gutknecht, Prof. Dr Lynn Powell and Dr Dimitris Strakas (from left).

others. Everyone is welcome to attend and participate no matter what organisation you belong to, or whether a laser user or not. I look forward to greeting you in a warm, friendly, sharing environment in Aachen, Germany, this October."

Visit our official website www.wfld-aachen2018.com for online abstract submissions, secure online registrations via credit card or bank transfer, scientific and social programme details, hotel accommodation options and all related information about the beautiful city of Aachen. Last but not least we would like to thank all our current sponsors for supporting this event. We are proud of having the leaders of the laser device market on our side.

We are looking forward to meeting you all in Aachen, Germany, this October and welcome you to be part of this epic scientific event.

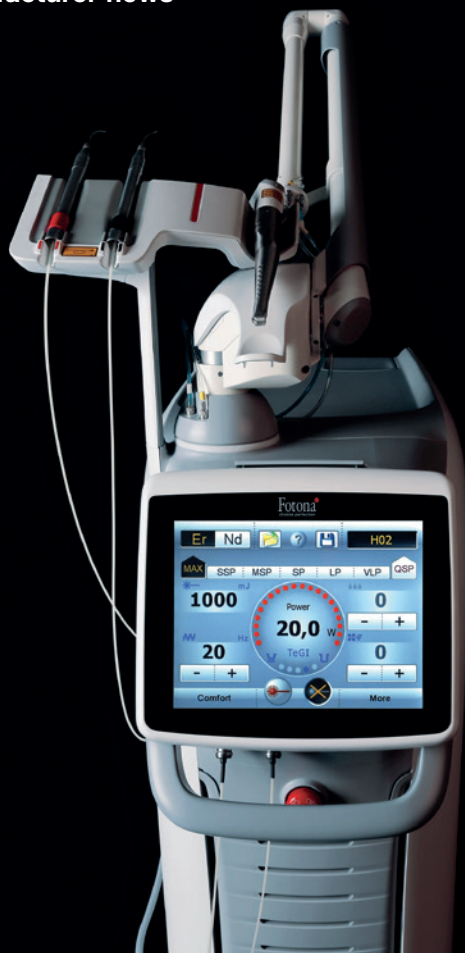contact

World Federation for Laser Dentistry

Aachen University Hospital
Pauwelsstraße 30
52074 Aachen, Germany
membership@wfldlaser.com

Fig. 2





Fotona

Dual wavelength laser system

Following its launch at IDS in March 2011, Fotona's dual wavelength (Er:YAG and Nd:YAG) LightWalker laser system quickly earned widespread industry appreciation and highly respected technology and innovation awards. Today, it is a preferred laser system of dental perfectionists and forward-thinking professionals who wish to upgrade their dental experience with new treatment possibilities that only the latest technology can offer. Owing to Fotona's advanced R&D capabilities which regularly introduce new features, software updates and usability improvements that further enhance the system's comprehensive feature set, it remains one of the most leading edge and reliable laser systems on the market. With the most state-of-the-art design, engineering and patented technologies, offering a wide range of highly effective TwinLight® hard- and soft-tissue treatments, aiming at providing the most extensive list of applications of any dental laser made today, LightWalker will continue to set standards for cutting-edge laser technology in years to come.

Fotona d.o.o.
Stegne 7
1000 Ljubljana, Slovenia
www.fotona.com

MEDENCY

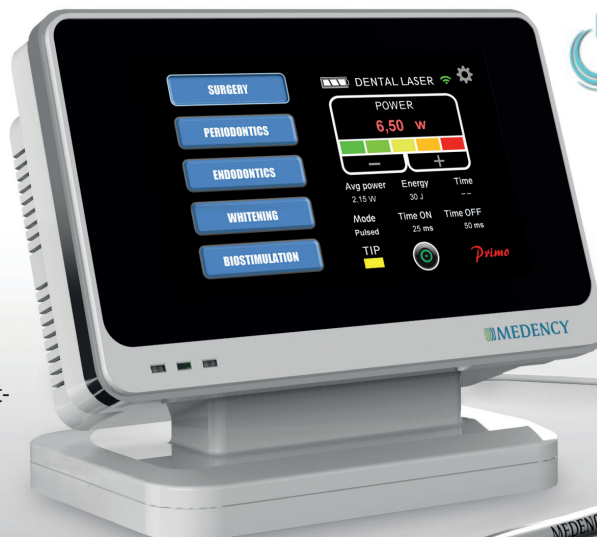State-of-the-art diode laser technology

The Italian company MEDENCY has been built upon profound global expertise in the dental market and dental lasers in particular. "Our flagship product PRIMO combines state-of-the-art diode laser technology with innovation and the experience of MEDENCY in the dental industry. PRIMO provides a variety of applications and is thus a viable alternative to conventional surgical methods like electrocautery and the scalpel. Owing to its intuitive interface, the device is easy to use," stated the company's general manager, Alessandro Boschi.

All products are designed, engineered and manufactured in Italy—with passion and commitment. "Our overall mission is to deliver a combination of cutting-edge products, services and interaction with customers drawing on a wide network of academic partners," said Boschi. The company supports its partners with tailor-made educational courses in different countries in order to gain practical

experience in the use of the system in daily practice. Using dental laser technology has never been so easy.

MEDENCY Srl
Piazza della Libertà 49
36077 Altavilla – Vicenza, Italy
www.medency.com



PRIMO

Health labels might prevent

Consumption of sugary drinks

Cigarette packets are labelled with warnings and graphic images to deter people from smoking. In a new study, researchers from Australia's Deakin University have investigated whether a similar labelling approach could dissuade people from buying sugary drinks. They found that young adults were less likely to purchase sugar-sweetened beverages that had health labels.

To investigate the possible effects of adding a health label to sugary drinks, an online experiment to examine the drink choices of almost 1,000 Australians of a diverse range of socio-economic status and education levels aged between 18 and 35 was conducted. Participants were asked to imagine that they were entering a shop or cafe or approaching a vending machine to purchase a drink, and should then choose between one of 15 bottles, with both sugary and non-sweetened options available. The drinks had either no label (control group) or one of four labels on sugary drinks: graphic warnings, text warnings, sugar information (including the number of teaspoons of added sugar) or a Health Star Rating—the national front-of-pack labelling system used in Australia and New Zealand. According to the results, participants were far less likely to select a sugary drink when a front-of-pack label was displayed, regardless



© monticello/Shutterstock.com

of their level of education, age or socio-economic background. "Our findings highlight the potential of front-of-pack health labels, particularly graphic images and Health Star Ratings, to change consumer behaviour, reduce purchases of sugar-sweetened drinks, and help people to make healthier choices," said Prof. Anna Peeters, Director of the Institute for Healthcare Transformation at Deakin University.

Source: DTI

Kangaroo ancestors identified by

Fossil molars

Kangaroos are icons of Australia's unique living fauna whose earliest ancestry has yet to be discovered. However, using archaeological findings that were unveiled in Australia approximately 30 years ago, researchers from Uppsala University in Sweden recently identified the most distant ancestor of today's kangaroos with the help of new technology.


In the early 1980s, palaeontologists excavated a few enigmatic molars around a dry salt lake in northern South Australia. The rare specimens were recognised as belonging to an ancient kangaroo ancestor and stored in a museum collection for more than three decades until modern computer-based analysis enabled scientists

to confirm the significance of the discovery. The kangaroo ancestor was named *Palaeopotorous priscus*, which is Latin for "ancient rat-kangaroo".

"Our results showed that *Palaeopotorous* was most similar to living rat-kangaroos, as well as some other extinct kangaroo relatives. Using information from fossils, and the DNA of living species, we were able to further determine that at around 24 million years old, *Palaeopotorous* is not just primitive, but likely represents the most distant forerunner of all known kangaroos, rat-kangaroos and their more ancient ancestors," said lead author

Dr Wendy den Boer, recent doctoral student at the university and current staff member of the Swedish Museum of Natural History.

Source: DTI



© Wiktoria Matynia/Shutterstock.com

Laser-supported treatment shall improve

Peri-implantitis therapy

Scientists of the University of Greifswald are currently working on developing a plasma-supported method that can be used for the cleaning of infected implants. Implants, just like teeth, have to be properly maintained, regularly checked and professionally cleaned in order to prevent health issues like peri-implantitis. This disease, if untreated, can lead to tissue infection, bone reduction and ultimately implant loss. A three-year project funded by the Federal Ministry of Education and Research to explore new approaches for proper cleaning of infected implants was thus initiated. In a cooperation between scientists from Greifswald and two medical technology companies the PeriPLas project is aiming at establishing a basis for a safe and effective method for curing peri-implantitis that can eventually be used in daily clinical practice. The advantages of efficient therapy methods like mechanical cleaning with abrasive systems, treatment with a diode laser and with an atmospheric-pressure plasma jet shall be analysed and most

promisingly combined. "Mechanical cleaning is necessary to remove the biofilm. The reduction of living microorganisms can be supported with the diode laser. Cold plasma can eliminate remaining bacteria and activate the implant surface in order to favour osseointegration [...]," stated project manager Dr Lukasz Jablonowski. A large clinical pilot study at the end of the project is intended to test the efficiency and safety of such a combined treatment.

Source: University of Greifswald

Lack of guidance may delay

Child's first trip to dentist

Parents should start taking their child for regular dental check-ups as soon as the first tooth appears. What seems like a logical step to secure a child's oral is, however, not evident to all parents as a poll on children's health conducted by the University of Michigan C.S. Mott Children's Hospital demonstrated. It was found that without a doctor's or dentist's guidance some parents do not follow the updated national recommendations for early dental care to start around age 1, when the primary teeth emerge. One in six parents who did not receive such advice believed they should delay dentist visits until age 4 or later. "Parents hear clear guidelines on when they should begin well-child visits for their child's health and often schedule the first visit before they even bring their baby home from the hospital. Parents get much less guidance, however, on when to start taking their child to the dentist [...]. This lack of guidance may mean many parents delay the start of dental visits past the recommended age," said poll co-director Sarah Clark.

The nationally representative poll was based on responses from 790 parents with at least one child under 5. 60 per cent of the parents reported that their child had had a dental visit. Among the remaining 40 per cent common reasons for not going to the dentist were that the child was not old enough, and the child would be scared of the dentist.

Source: DTI

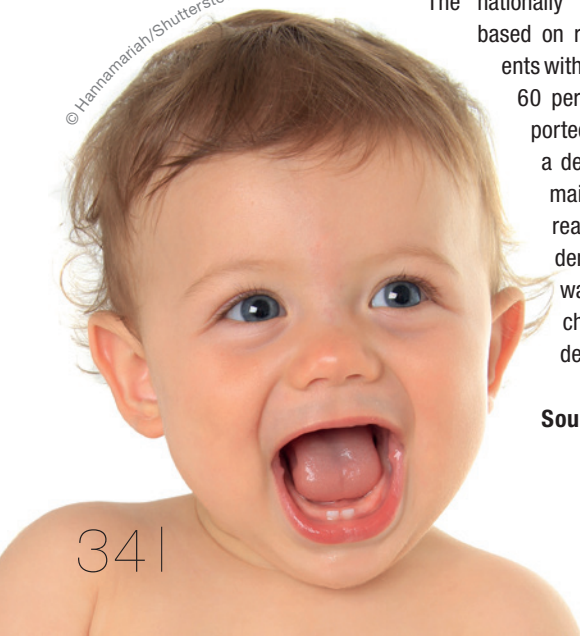Periodontal treatment improved

Control of type 2 diabetes



Spanish researchers have now discovered further evidence for the connection between periodontitis and type 2 diabetes. Their study "Benefits of non-surgical periodontal treatment in patients with type 2 diabetes mellitus and chronic periodontitis (...)" showed that control of type 2 diabetes improved notably after the patient underwent scaling and root planing using ultrasound and curettage. Head of the study Dr Miguel Viñas, Professor of Microbiology at the University of Barcelona stated that a relation does not only exist between going from diabetes to periodontal diseases, but also from periodontal disease to diabetes. 90 patients with type 2 diabetes participated and were randomly assigned to either the treatment or the control group. Treatment group participants received oral hygiene instructions, scaling and root treatment. "The main conclusion of the study is that nonsurgical treatment of periodontitis improves the glycaemic status and the levels of glycated haemoglobin, and therefore proves the great importance of oral health in diabetic patients," summarised Prof. José López, medical director of the university's dental clinic.

© Hannamariah/Shutterstock.com

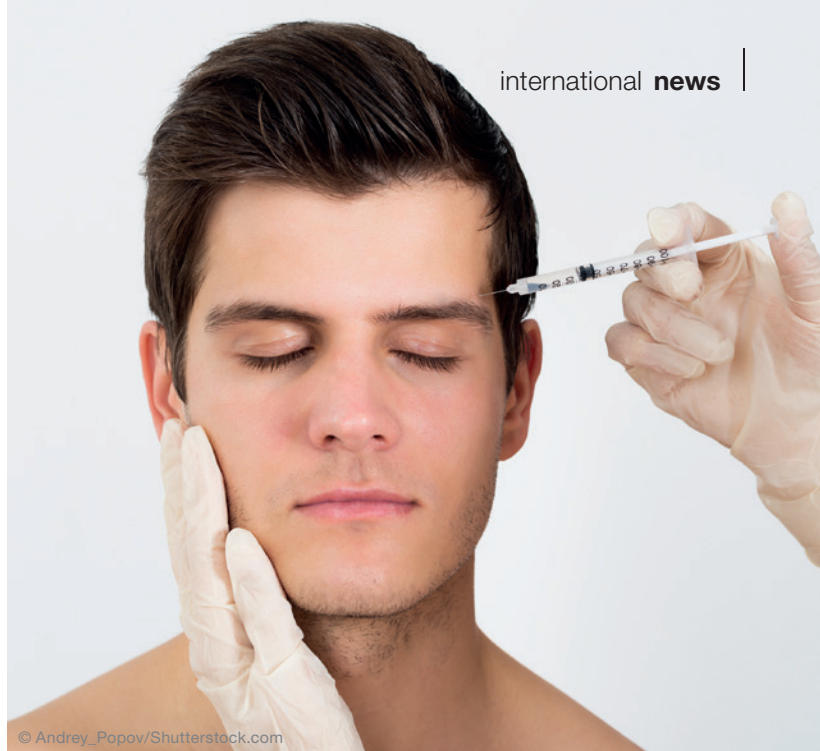

Botulinum toxin injection promises

Improvement of sleep bruxism

A new pilot study currently investigated the positive effects of onabotulinum toxin-A (BoNT-A) as a possible treatment for bruxism. The study titled "Onabotulinum toxin-A injections for sleep bruxism: A double-blind, placebo-controlled study" focused on determining the safety and efficacy of such a treatment. 22 patients, between 18 and 85 years of age, with clinically diagnosed sleep bruxism, confirmed by polysomnography, participated. 13 participants were injected with 200 BoNT-A units (60 into each masseter and 40 into each temporal muscle) and the remaining patients with the placebo. After the four- and eight-week check-ups, participants who were given the placebo injection recorded no improvement to their bruxism condition. However, those who were injected with BoNT-A reported a positive effect with minimised tooth grinding and clenching, as well as a reduction of the associated pain.

Head researcher Dr William Ondo specified that, owing to the muscle relaxation effect of the botulinum toxin, the movements causing the condition are reduced. According to the researchers



© Andrey_Popov/Shutterstock.com

from the Houston Methodist Neurological Institute, this indicates BoNT-A being an effective and safe way to improve sleep bruxism; however, a large multicentre trial to confirm the initial findings is recommended.

Join DGL!

Register now at www.qr.oemus.com/6152 or scan the QR on the right and become a member of the German Association of Laser Dentistry (DGL).

Application form

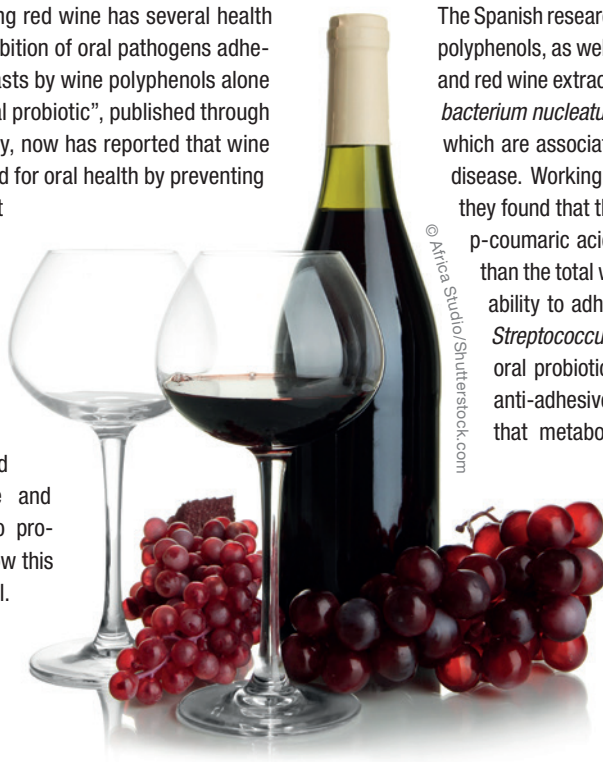


Wine polyphenols may

Prevent caries and periodontal disease

Evidence suggests that drinking red wine has several health benefits. The study titled "Inhibition of oral pathogens adhesion to human gingival fibroblasts by wine polyphenols alone and in combination with an oral probiotic", published through the American Chemical Society, now has reported that wine polyphenols might also be good for oral health by preventing the adhesion of bacteria that could cause periodontitis and other diseases.

Study author Dr M. Victoria Moreno-Arribas, Director of the Instituto de Investigación en Ciencias de la Alimentación, Madrid, Spain, and her colleagues aimed to investigate whether wine and grape polyphenols would also protect teeth and gingivae, and how this could work on a molecular level.



© Africa Studio/Shutterstock.com

The Spanish researchers studied the effect of two red wine polyphenols, as well as commercially available grape seed and red wine extracts, on *Porphyromonas gingivalis*, *Fusobacterium nucleatum* and *Streptococcus mutans* bacteria, which are associated with dental caries and periodontal disease. Working with cells that model gingival tissue, they found that the two wine polyphenols—caffeic and p-coumaric acids—in isolation were generally better than the total wine extracts at reducing the bacteria's ability to adhere to the cells. When combined with *Streptococcus dentisani*, which is believed to be an oral probiotic, the polyphenols had an even better anti-adhesive capacity. The research also showed that metabolites, formed when digestion of the polyphenols begins in the mouth, might be responsible for some of these effects.

Source: DTI

Prof. Dr. Norbert Gutknecht

Präsident der Deutschen Gesellschaft
für Laserzahnheilkunde e.V. (DGL)



DGL-Jahreskongress in Aachen am 2. und 3. Oktober 2018

Liebe DGL-Mitglieder, liebe Laserfreunde,

bevor Sie das offizielle DGL-Kongressprogramm auf unserer Webseite unter www.dgl-online.de abrufen können, darf ich Ihnen schon vorab zwei ganz wichtige Informationen unseren bevorstehenden Jahreskongress betreffend, zukommen lassen.

Wie auf unserem letzten Kongress von Herrn Priv.-Doz. Dr. Rene Franzen vorgetragen, wird aufgrund der neu herausgegebenen Lasersicherheitsleitlinien gefordert, dass die Inhaber der Qualifikation zum Laserschutzbeauftragten nach BGV B2 einen aktuellen Kurs absolvieren, welcher der aktualisierten Verordnung OStrV genügt. Dies hat den Hintergrund, den gestiegenen Anforderungen an die gesetzlichen Grundlagen gerecht zu werden. Hier wollen wir Sie als DGL bestmöglich unterstützen und bieten Ihnen daher, wie bereits im letzten Jahr mit großer positiver Resonanz angekündigt, diesen Workshop auf dem vor uns liegenden Jahreskongress für unsere Mitglieder an.

Insbesondere, wenn Sie Ihre Laserschutz-Qualifikation vor 2010 erworben haben, empfehlen wir Ihnen dringend, an diesem Workshop teilzunehmen. Der Workshop schließt mit einer obligatorisch gewordenen Prüfung ab und geht auch auf das schwierige Thema der Gefährdungsbeurteilung ein.

Bei erfolgreicher Teilnahme am Workshop wird ein Zertifikat erworben, das den Sachkundenachweis nach OStrV darstellt. Normalerweise werden für diese Kurse allein ca. 400€ erhoben. Als DGL-Mitglied dürfen wir Ihnen jedoch die überaus positive Ankündigung machen, dass dieser Kurs in den Kongressgebühren von 290€

inkl. MwSt. enthalten ist. Für Nichtmitglieder der DGL entstehen Kongressgebühren in Höhe von 350€ inkl. MwSt.

Darüber hinaus ist in diesen Kongressgebühren auch das Galadinner im Schloss Rahe in Aachen sowie die Bewirtung in den Kongresspausen (Getränke, Kaffee, Kuchen, Snacks und Mittagessen durch einen Catering-Service) an beiden Tagen inkludiert. Diese überaus positive mitgliederfreundliche Preisgestaltung war uns nur deshalb möglich, weil wir unseren deutschsprachigen DGL-Jahreskongress in den gleichzeitig und am gleichen Ort stattfindenden Jubiläumskongress der WFLD (ehemals ISLD) integrieren konnten.

Wie der ein oder andere von Ihnen möglicherweise schon vernommen oder gelesen hat, wird unser DGL-Kongress speziell auf anwendungsbezogene Indikationen der unterschiedlichen Laserwellenlängen in der Praxis ausgerichtet sein. Deshalb haben wir für Sie vortragsbezogene Workshops und Live-Demonstrationen von Behandlungen vorbereitet. Ein großes Schwerpunktthema unseres Kongresses wird die Anwendung von Lasern in den verschiedensten Bereichen der Implantologie sein. Auch dazu werden spezielle Workshops und klinische Demonstrationen angeboten. Alle namhaften Laserhersteller werden auf unserer Kongressausstellung und in den Workshops vertreten sein.

Wir haben auch an Ihre Zahnmedizinischen Fachangestellten (ZMF) gedacht. Daher haben wir einen halbtägigen Workshop am 3. Oktober ins Leben gerufen, der nicht nur Ihren ZMF einen Einblick in die sichere Handhabung von Lasergeräten geben soll, sondern auch einen Überblick über gesicherte Laserindikationen bietet und im dritten Teil des Workshops spezielle Anregungen



zum Marketing von Laserleistungen gegenüber Patienten vermittelt. Die Absolventinnen und Absolventen erhalten nach erfolgreicher Teilnahme ein entsprechendes Zertifikat. Der Preis für diesen Workshop inklusive Kongressbesuch an diesem Tag beträgt 90 € inkl. MwSt.

Ich bin sicher, dass Sie von der Vielfalt unseres Kongressangebotes nicht nur überzeugt, sondern auch begeistert sind und sich in den nächsten Tagen mit einem Klick zu diesem außerordentlichen Event anmelden werden.

Wenn die Farben der Natur unser DGL-Logo widerspiegeln, würde ich mich freuen, Sie hier in Aachen begrüßen zu dürfen.

Ihr,

Prof. Dr. Norbert Gutknecht

Einladung zur DGL-Mitgliederversammlung

Mittwoch, 3.10.2018, 12.00 – 13.00 Uhr
Aachen – Universitätsklinikum

Tagesordnung:

- TOP 1** Genehmigung der Tagesordnung
- TOP 2** Bericht des DGL-Vorstandes
- TOP 3** Bericht des DGL-Kassenprüfers
- TOP 4** Wahl Nominierungsausschuss
- TOP 5** DGL-Kongress 2019
- TOP 6** DGL-Kongress 2020: 6.-7.11.2020 in Bremen
- TOP 7** Anträge zur Mitgliederversammlung
- TOP 8** Verschiedenes



Kieferorthopädische Behandlungen

Laser statt Schmerzmittel?

Kieferorthopädische Behandlungen, beispielsweise bei einem Bogenwechsel im Rahmen von Multibandbehandlungen, können Patienten unangenehme Schmerzen bereiten. Mitunter werden bei kieferchirurgisch-kieferorthopädischen Kombinationstherapien oder bei Fällen mit skelettaler Verankerung Schmerzmittel angewendet, allerdings treten dabei zum Teil Nebenwirkungen und Allergien auf. Ersten Hinweisen zufolge, können sich NSAID (non-steroidal anti-inflammatory drugs) wie Ibuprofen zudem – wenn auch minimal – negativ auf die Zahnbewegung auswirken. So hat das Hemmen der Prostaglandinesynthese, der Botenstoffe bei der Schmerzentstehung, Einfluss auf die Knochenresorption. Eine potenzielle Alternative zur medikamentösen Schmerzbehandlung stellt die Low-Level-Laser-Therapie (LLLT) dar, deren Wirksamkeit bereits in verschiedenen Studien analysiert wurde. Alle Untersuchungen zeigten, dass LLLT zur Schmerzlinderung bei kieferorthopädischen Behandlungen beiträgt. Forschern der Universidade Luterana do Brasil gelang es, mit einer AlGaAs-Diode schmerzlindernde Effekte zu evaluieren. Eine chilenische Studie der Universidad de La Frontera konnte des Weiteren die Reduzierung von Spontan- und Kauschmerzen nach 24 und 72 Stunden nachweisen.

Weniger eindeutig fielen die Ergebnisse einer Analyse verschiedener medikamentfreier Methoden aus, die von Cochrane Oral Health

veröffentlicht wurden. Bei der Behandlung von 118 Patienten mit LLLT wurde zwar eine Reduzierung der Schmerzen festgestellt, die Resultate waren jedoch sehr schwach ausgeprägt. Lasertyp, Wellenlänge und Intensität der Behandlung sind wichtige Einflussfaktoren auf die Wirksamkeit der LLLT. Es bedarf daher weiterer Untersuchungen, bevor sich LLLT als alternative Methode etablieren kann.

Quelle: ZWP online



27. DGL-Jahreskongress

Scannen Sie den nebenstehenden QR-Code für Details zum vorläufigen Programm des DGL-Jahreskongress am 2. & 3. Oktober 2018 im Universitätsklinikum Aachen.

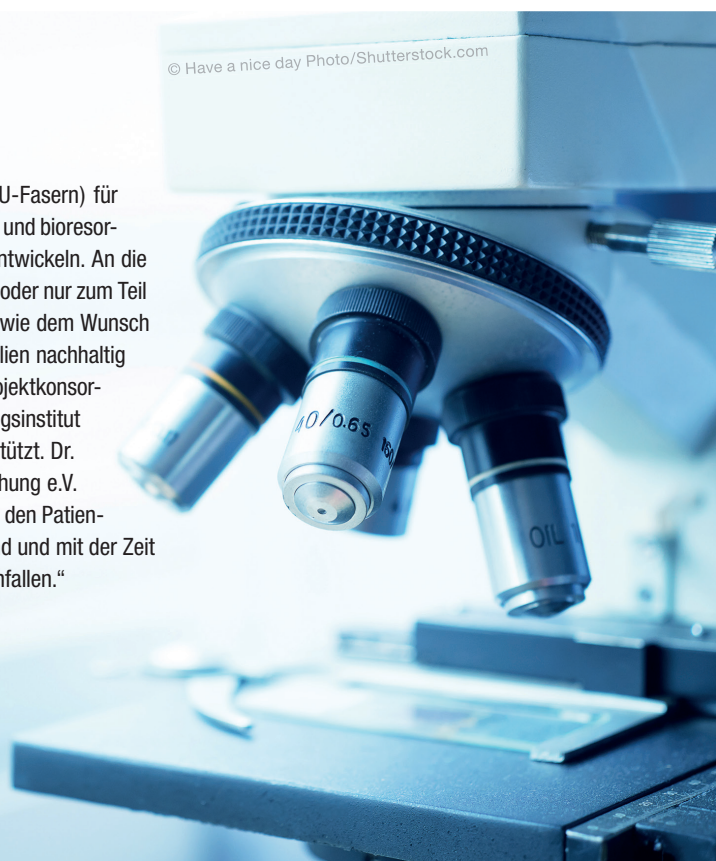


Forschungsprojekt

Neuartige biobasierte Fasern

Das Projekt „Herstellung von biobasierten Polyester-Urethan-Fasern (PEU-Fasern) für medizinische Anwendungen“ hat zum Ziel, ein biobasiertes, biokompatibles und bioresorbierbares chirurgisches Nahtmaterial für medizinische Anwendungen zu entwickeln. An die Fasern werden Anforderungen gestellt, die mit bisherigen Materialien nicht oder nur zum Teil erreicht werden. Vor dem Hintergrund effizienter Ressourcenschonung, sowie dem Wunsch erdölbasierte Roh- und Werkstoffe durch regenerative biobasierte Materialien nachhaltig zu ersetzen, rücken diese immer mehr in den Fokus der Forschung. Das Projektkonsortium vereint Kompetenzen aus mehreren Unternehmen und einem Forschungsinstitut und wird durch das Netzwerkmanagement der IBB Netzwerk GmbH unterstützt. Dr. Rüdiger Strubl vom Thüringischen Institut für Textil- und Kunststoff-Forschung e.V. erklärt: „Im Projekt entwickeln wir neuartige Fasern aus Biopolymeren, die den Patienten den Vorteil bieten, dass sie für die Menschen besonders verträglich sind und mit der Zeit vom Körper abgebaut werden, ohne dass dabei toxische Nebenprodukte anfallen.“

Quelle: IBB Netzwerk GmbH





16th WORLD CONGRESS WFLD 2018

1. – 3. Oktober 2018,
RWTH Aachen,
Aachen



The 16th Congress of the
World Federation for Laser
Dentistry (WFLD)

The 27th Annual Meeting of
the German Society for Laser
Dentistry (DGL)

The 6th Annual Congress
of the World Academy for
Laser Education
in Dentistry (WALED)

Dieser Kongress verbindet Wissenschaft und Praxis auf
diversen Präsentations- und Demonstrationsebenen durch:

- Hochwertige Vorträge internationaler Keynote-Referenten
- Live-Demonstrationen am Patienten
- Interaktive digitale Posterpräsentationen
- Vorträge in Kombination mit klinisch relevanten Fähigkeiten
- Kurzpräsentationen aktueller wissenschaftlicher Ergebnisse
- Klinische Fallpräsentationen
- Rotierende, firmenunterstützte Workshops zum Erwerb von Weiterbildungszertifikaten

Kontakt

WFLD 2018 Hauptsitz Aachen
Herr Leon Vanweersch
Stellvertretender Vorsitzender
des Organisationskomitees
Telefon: +49 151 50610781
headquarters@wfl-d-aachen2018.com
www.wfl-d-aachen2018.com

S3-Leitlinie

„Zahnärztliche Chirurgie unter oraler Antikoagulation“



© Iryna Imago/Shutterstock.com

Erstmals ist nach den Regularien der AWMF (Arbeitsgemeinschaft der Wissenschaftlichen Medizinischen Fachgesellschaften) eine S3-Leitlinie zu der präoperativen Vorbereitung, den intraoperativen Kautelen und der postoperativen Nachbetreuung von Patienten unter oraler Antikoagulation/Thrombozytenaggregationshemmung entwickelt worden.

Federführend durch die Deutsche Gesellschaft für Zahn-, Mund- und Kieferheilkunde (DGZMK) und die Deutsche Gesellschaft für Mund-, Kiefer- und Gesichtschirurgie e.V. (DGMKG) wurden in Zusammenarbeit mit 13 weiteren beteiligten Fachgesellschaften und Organisationen evidenzbasierte, breit konsenterte konkrete Handlungsempfehlungen vorgelegt, die Behandler und Patient dabei unterstützen sollen, in der operativen Zahnheilkunde sowie der Mund-, Kiefer- und Gesichtschirurgie unerwünschte Blutungsereignisse zu vermeiden und die Komplikationsraten zu verringern.

Quelle: DGZMK

Neue Volkskrankheit: Kreidezähne

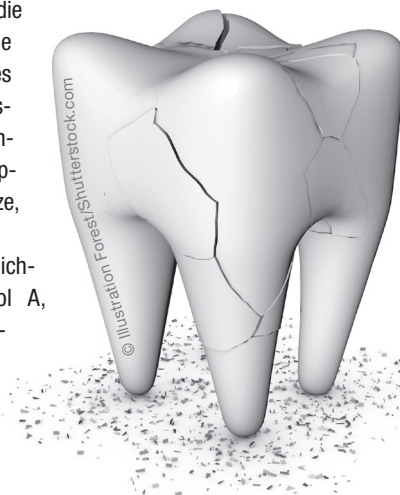
MIH überholt Karies

1987 wurde die Molaren-Inzisiven-Hypomineralisation (MIH) erstmals wissenschaftlich beschrieben, heute lässt sich bereits von einer neuen Volkskrankheit sprechen: im Durchschnitt leiden 10 bis 15 Prozent der Kinder an MIH, bei den 12-jährigen sind es laut der 5. Deutschen Mundgesundheitsstudie sogar über 30 Prozent. MIH verursacht eine systemisch bedingte Strukturanomalie des Zahnschmelzes, die auf eine Mineralisationsstörung zurückzuführen ist. Diese sogenannten „Kreidezähne“ sind äußerst schmerzempfindlich und reagieren sehr sensibel auf Hitze, Kälte und Zähneputzen.

Als potenzielle Ursachen gelten u.a. Weichmacher aus Kunststoffen wie Bisphenol A, Probleme in der Schwangerschaft und Infektionskrankheiten. Diskutiert wird ein multifaktorielles Geschehen, dennoch gilt die präzise Ätiologie weiterhin als ungeklärt. Da die Schmelzentwick-

lung der ersten Molaren und der Inzisivi zwischen dem achten Schwangerschaftsmonat und dem vierten Lebensjahr erfolgt, muss die Störung in dieser Zeitspanne stattfinden.

Häufig weisen die bleibenden Frontzähne und zunehmend auch die zweiten Milchmolaren bei MIH Fehlstrukturierungen auf. Die milde Form zeigt eher weißgelbe oder gelbbraune, unregelmäßige Opazitäten, während bei der schweren Form abgesplitterte oder fehlende Schmelz- und/oder Dentinareale unterschiedlichen Ausmaßes auftreten. Die raue Zahnoberfläche und schlechte Substanz begünstigen die Kariesanfälligkeit. Eine besonders intensive Prophylaxe beispielsweise durch Fluoridierungsmaßnahmen ist daher notwendig, um die Zähne ein Leben lang zu erhalten.



© Illustration Forest/Shutterstock.com

Quelle: DGZMK

Werden Sie DGL-Mitglied!

Registrieren Sie sich jetzt unter www.qr.oemus.com/6153 oder scannen Sie den nebenstehenden QR-Code und werden Sie Teil der Deutschen Gesellschaft für Laserzahnheilkunde e.V.

Aufnahmeantrag



Bitte ausgefüllt an E-Mail:
sekretariat@dgl-online.de
especk@ukaachen.de
oder Fax: 0241 803388164
per Post: Uniklinik Aachen

Deutsche Gesellschaft für Laserzahnheilkunde e.V.
Abt. für ZPP/ DGL
Frau Eva Speck
Pauwelsstraße 30
52074 Aachen

27. DGL-Jahreskongress

2. und 3. Oktober 2018 im Universitätsklinikum Aachen



**16th WORLD CONGRESS
WFLD 2018**

1 – 3 OCTOBER 2018
RWTH AACHEN UNIVERSITY
AACHEN, GERMANY

**RWTHAACHEN
UNIVERSITY**



The 16th Congress of the
World Federation for Laser
Dentistry (WFLD)



The 27th Annual Meeting of
the German Society for Laser
Dentistry (DGL)



The 6th Annual Congress
of the World Academy for
Laser Education
in Dentistry (WALEED)



- ☐ Hiermit melde ich mich verbindlich zum 27. Jahreskongress der DGL im Universitätsklinikum Aachen an (inkl. Galadinner und Catering).

DGL-Mitglied 290,- € inkl. 19 % MwSt.

Name: _____

Straße/Nr.: _____

Vorname: _____

PLZ/Ort: _____

Unterschrift: _____

Datum: _____

Status: ☐ DGL-Mitglied 290,- €

☐ Nichtmitglied 350,- €

Ich nehme am aktualisierten Lasersicherheitsworkshop gemäß der neuen Verordnung OStrV teil: ja ☐ nein ☐

Meine ZMF nimmt am Laserworkshop zum Preis von 90,- € inkl. MwSt teil: ja ☐ nein ☐

Name ZMF: _____

**Die Bestätigung Ihrer Anmeldung erfolgt nach dem Eingang Ihrer Kongressgebühren auf das Konto der DGL/
WFLD: Sparkasse Aachen, IBAN: DE54 3905 0000 1073 0886 90, BIC: AACSD33**

Allgemeine Bedingungen

Anmeldeschluss ist der **31. Juli 2018**. Anmeldungen nach diesem Zeitpunkt können nur noch vor Ort bearbeitet werden (bis zur max. Teilnehmerzahl). Nach Zugang der Anmeldung ist diese für den Teilnehmer verbindlich. Bei Stornierung der Teilnahme bis zum 30.06.2018 wird ein Betrag von 50,- € p. P. als Bearbeitungsgebühr einbehalten. Nach diesem Zeitpunkt erfolgt **keine Rückerstattung**. Die Gestaltung und Durchführung des wissenschaftlichen Programms obliegt der Deutschen Gesellschaft für Laserzahnheilkunde e.V. Für die Durchführung der Workshops während der Dentalausstellung übernimmt die Deutsche Gesellschaft für Laserzahnheilkunde e.V. keine Verantwortung.

Bankverbindung: Sparkasse Aachen, IBAN: DE54 3905 0000 1073 0886 90, BIC: AACSD33

laser

international magazine of laser dentistry



Imprint

Publisher

Torsten R. Oemus
oemus@oemus-media.de

CEO

Ingolf Döbbecke
doebbecke@oemus-media.de

Members of the Board

Jürgen Isbaner
isbaner@oemus-media.de

Lutz V. Hiller
hiller@oemus-media.de

Editor in Chief

Norbert Gutknecht
ngutknecht@ukaachen.de

Coeditors in Chief

Adam Stabholz
Matthias Frentzen

Editorial Managers

Dimitris Strakas
Leon Vanweersch

Regional Editors

Georgi Tomov
Europe

Marina Polonsky
North America

Marcia Martins Marques
South America

Youssef Sedky
Middle East & Africa

Ambrose Chan
Asia & Pacific

Senior Editors

Aslihan Üsümez
Josep Arnabat
Kosmas Tolidis
Andreas Braun
Rene Franzen
Lynn Powell

Editorial Board

Peter Steen Hansen, Aisha Sultan, Ahmed A Hassan,
Antonis Kallis, Dimitris Strakas, Kenneth Luk,
Reza Fekrazad, Sharonit Sahar-Helft,
Lajos Gaspar, Paolo Vescovi, Ilay Maden,
Jaana Sippus, Hideaki Suda, Ki-Suk Kim,
Miguel Martins, Aslihan Üsümez,
Enrique Trevino, José Correia de Campos,
Saleh Ghabban, Stephen Hsu, Antoni Espana Tost,
Josep Arnabat, Alaa Sultan, Evgeniy Mironov,
Ahmed Abdullah, Boris Gaspirc,
Peter Fahlstedt, Alireza Fallah,
Michel Vock, Anna Maria Yiannikos,
Ryan Seto, Joyce Fong, Iris Brader,
Masoud Mojahedi, Gerd Volland,
Gabriele Schindler, Ralf Borchers,
Stefan Grümer, Detlef Klotz, Jörg Meister,
Rene Franzen, Andreas Braun, Siegfried Jänicke,
Olaf Oberhofer, Thorsten Kleinert

Editorial Office

Georg Isbaner
g.isbaner@oemus-media.de

Katharina Rühling
k.ruehling@oemus-media.de

Product Manager

Timo Krause
t.krause@oemus-media.de

Executive Producer

Gernot Meyer
meyer@oemus-media.de

Art Director

Alexander Jahn
a.jahn@oemus-media.de

Designer

Sandra Ehnert
s.ehnert@oemus-media.de

Theresa Weise

t.weise@oemus-media.de

Customer Service

Marius Mezger
m.mezger@oemus-media.de

Published by

OEMUS MEDIA AG
Holbeinstraße 29
04229 Leipzig, Germany
Tel.: +49 341 48474-0
Fax: +49 341 48474-290
kontakt@oemus-media.de

Printed by

Silber Druck oHG
Am Waldstrauch 1
34266 Niestetal, Germany

laser international magazine of laser dentistry
is published in cooperation with the World
Federation for Laser Dentistry (WFLD).

WFLD Headquarters

University of Aachen Medical Faculty
Clinic of Conservative Dentistry
Pauwelsstraße 30
52074 Aachen, Germany
Tel.: +49 241 808964
Fax: +49 241 803389644
ngutknecht@ukaachen.de
www.wfld-org.info

www.laser-magazine.com • www.oemus.com



Copyright Regulations

laser international magazine of laser dentistry is published by OEMUS MEDIA AG and will appear with one issue every quarter in 2018. The magazine and all articles and illustrations therein are protected by copyright. Any utilisation without the prior consent of editor and publisher is inadmissible and liable to prosecution. This applies in particular to duplicate copies, translations, microfilms, and storage and processing in electronic systems. Reproductions, including extracts, may only be made with the permission of the publisher. Given no statement to the contrary, any submissions to the editorial department are understood to be in agreement with a full or partial publishing of said submission. The editorial department reserves the right to check all submitted articles for formal errors and factual authority, and to make amendments if necessary. No responsibility shall be taken for unsolicited books and manuscripts. Articles bearing symbols other than that of the editorial department, or which are distinguished by the name of the author, represent the opinion of the aforementioned, and do not have to comply with the views of OEMUS MEDIA AG. Responsibility for such articles shall be borne by the author. Responsibility for advertisements and other specially labeled items shall not be borne by the editorial department. Likewise, no responsibility shall be assumed for information published about associations, companies and commercial markets. All cases of consequential liability arising from inaccurate or faulty representation are excluded. General terms and conditions apply, legal venue is Leipzig, Germany.

SUBSCRIBE NOW!

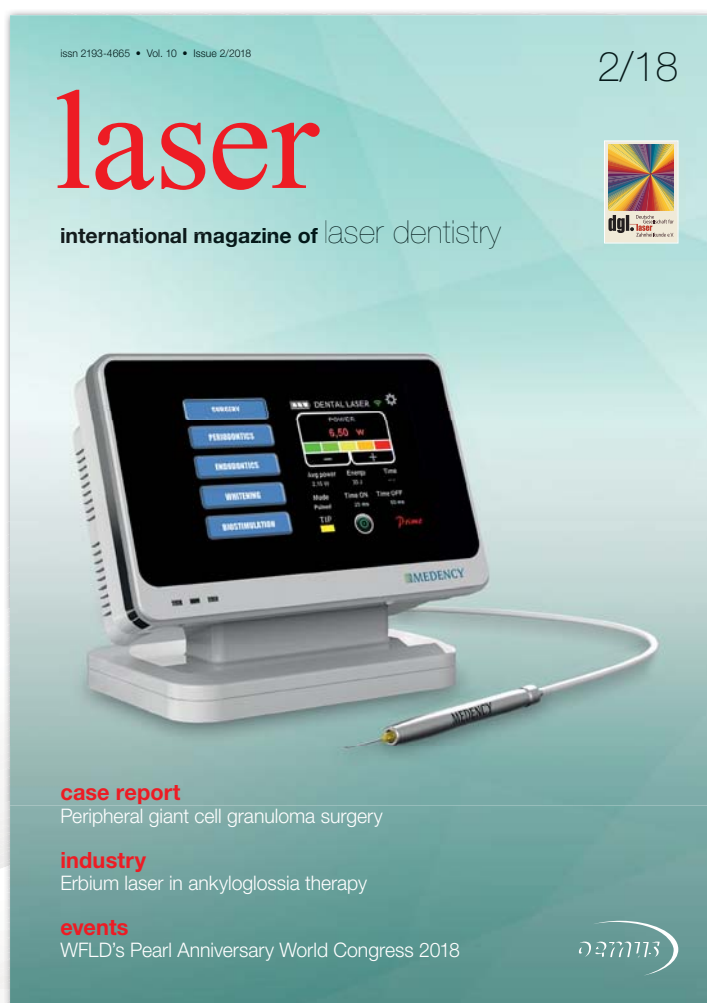laser—international magazine of laser dentistry

Interdisciplinary, transparent & market orientated

ONLINE
SUBSCRIPTION HERE



www.oemus-shop.de



stay updated:

case report

Peripheral giant cell granuloma surgery

industry

Erbium laser in ankyloglossia therapy

events

WFLD's Pearl Anniversary World Congress 2018



Fax: **+49 341 48474-290**

I would like to subscribe for the following journals:

- ☐ laser—international magazine of laser dentistry 4 issues p.a. € 44*
- ☐ implants—international magazine of oral implantology 4 issues p.a. € 44*
- ☐ ceramic implants—international magazine of ceramic implant technology 2 issues p.a. € 30*

Terms & Conditions: The subscription may be cancelled in written form without due justification within 14 days of order by contacting OEMUS MEDIA AG, Holbeinstraße 29, 04229 Leipzig, Germany. Dispatching notification in good time will suffice. The subscription is automatically extended by another twelve months if it is not cancelled in written form 6 weeks prior to the end of the reference period.

* All prices include VAT, shipping and handling (within Germany).

Last Name/First Name

Company

Street

ZIP/City/Country

E-Mail

Signature

Credit Card Number

Expiration Date

Security Code

OEMUS MEDIA AG

Holbeinstraße 29 · 04229 Leipzig · Germany · Phone: +49 341 48474-201 · grasse@oemus-media.de

