

# Periapical implant lesion and retrograde peri-implantitis

## Two conditions supported by little research

Dr Nikolaos Papagiannoulis, Germany

### Introduction

Dental implants are established as a standard treatment in dentistry. More implants are placed every year and dentists are encountering new findings, often pathological, that are little described and researched in the literature. The more implants placed, the greater the variety of novel clinical and radiographic findings for which no treatment protocols exist. The association of peri-implantitis, implant failure and other pathologies with numerous unknown factors is steadily increasing.

### Definition of terms

In general, the term “periapical implant lesion” (PIL) describes radiographic findings around the apex of an implant. It refers to a variety of occurrences with no association with the rest of peri-implant tissue or adjacent teeth. Clinical examination or patient complaints may not always indicate pathological findings, and if they do, the definition of the term overlaps with that of “retrograde peri-implantitis” (RPI). RPI has a similar definition, but is accompanied by complaints and usually clinical findings (Figs. 1–3).

### Diagnosis

RPI is manifested through radiographic findings and various clinical ones. In the case of RPI there is retrograde

infiltration of pathological microorganisms that nest at the apex of the implant. Often this infiltration comes from an adjacent tooth; it is, however, not the only reason for RPI. Other reasons relate to the operation protocol, prostheses and implant planning. In most cases, a combination of more than one factor leads to this diagnosis. Lateral defects, implant mobility or postoperative inflammation regarding the rest of the implant body or peri-implant tissue are excluded from this definition.

Both PIL and RPI are often incidental radiographic findings made, after implant placement until years after prosthetic restoration. If accompanied by clinical findings like positive percussion, occlusion complaints or pain syndromes, we distinguish two points of time: (a) during the first six weeks after insertion; and (b) four to eight weeks after loading. Pain complaints long after loading are in most cases an indication of cross-contamination from the adjacent teeth.

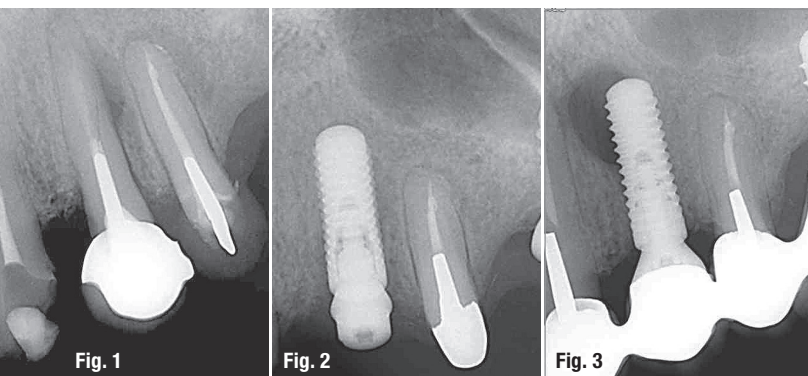
The reasons for RPI can easily be established. The reasons for PIL are various and a combination of more than one, and often no clear reason can be determined. In cases of PIL we search for the reason through the exclusion principle. The differential diagnosis is in both cases difficult and often lacks evidence. Since there is no protocol for diagnosis, we rely on empirical observation.

### Reasons for periapical implant lesion and retrograde peri-implantitis

We can distinguish between established and potential reasons for such lesions.

Established reasons are the following:

1. Contamination of the implant surface;
2. overheating of the bone during operation;
3. apical perforation of the buccal plate;
4. existing apical perforation of the buccal plate;
5. apical fracture of the bone (after external sinus, block augmentation, two stages of guided bone regeneration);
6. endodontic pathology of the adjacent teeth (distance to adjacent tooth less than 1 mm);



Figs. 1–3: Radiographs depicting cases of retrograde peri-implantitis.

Concave Abutment  
Engineered for Favorable  
Esthetic Outcome

Platform Switching  
Designed to Facilitate Bone  
Preservation and Growth

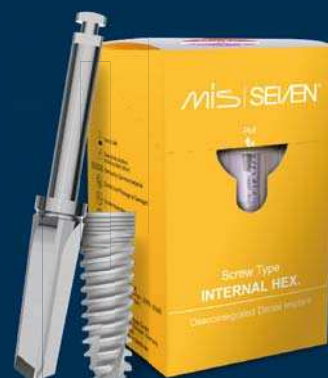Unique Thread Designed  
for High Primary Stability

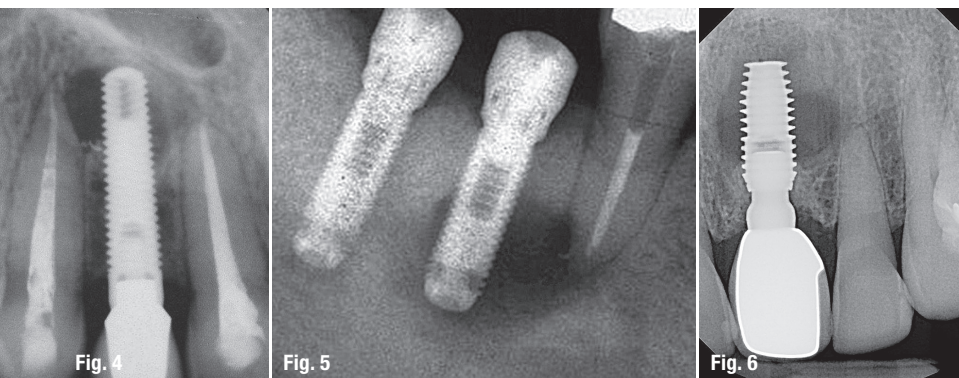
Domed Apex for  
Safe Insertion

## PROVEN SUCCESS MEETS ENHANCED STABILITY. **MAKE IT SIMPLE**

The biological stability and predictable esthetics of the SEVEN, combined with the extensive research and development process have given the SEVEN a potential advantage in soft tissue preservation and growth as well as an array of restorative benefits. Learn more about the SEVEN implant system and MIS at: [www.mis-implants.com](http://www.mis-implants.com)

**MIS**  
**SEVEN**®





**Fig. 4:** Mild lesion: less than 25 % of the implant length. **Fig. 5:** Moderate lesion: 25–50 % of the implant length. **Fig. 6:** Advanced lesion: more than 50 % of the implant length.

## Radiographic classification of retrograde peri-implantitis

In this classification, the lesion is evaluated in relation to the implant length (coronoapical direction). The spread of the lesion beyond the implant apex is not measured. The lesion is classified as follows:

- Class 1: lesion less than 25 % of the implant length (mild lesion; Fig. 4).
- Class 2: lesion 25–50 % of the implant length (moderate lesion; Fig. 5).
- Class 3: lesion longer than 50 % of the implant length (advanced lesion; Fig. 6).

7. immediate implant placement after tooth loss due to endodontic pathology; and
8. inadequate blood perfusion at the implant site.

Potential reasons may be the following:

1. Insufficient bone quality;
2. prosthetic overload;
3. endodontic pathology of the adjacent teeth (distance of 2–4 mm);
4. late implant placement with a pathology caused by perforation due to tooth extraction;
5. endodontically treated adjacent teeth showing a newly developed pathology (distance to implant of more than 2 mm);
6. residual or granulation tissue at an edentulous site; and
7. pseudo-lesion (caused by drilling deeper than actual implant length).

## Classification of periapical implant lesion/retrograde peri-implantitis according to lesion activity

### Active retrograde peri-implantitis/periapical implant lesion

The radiographic findings correlate with the patient symptoms and the clinical findings. The patient has a pain syndrome, there is inflammatory reaction at the tissue (like swelling), apical pressure point, positive percussion, etc. Often the translucent area around the implant apex is not round and seems to spread apically to the bone.

### Inactive retrograde peri-implantitis/periapical implant lesion

The radiographic findings do not correlate with the clinical findings and the patient has no symptoms. Radiographically, a translucent region at the implant apex is observed which can even be exceeding 50 % of the implant length.

RPI or PIL should not be misinterpreted in cases lacking osseointegration or with implant mobility during the healing phase or after loading.

This classification considers only two diameters of the lesion. Further information about 3-D defects, adjacent teeth, distance to adjacent teeth or implants, as well as implantation time, clinical findings, symptoms and prostheses, is interesting and these are important factors for the evaluation of such lesions.<sup>1</sup>

## Prevalence

The information provided in the literature is inconsistent. The prevalence of implants affected by PIL and RPI is 2.7 % in the lower jaw and 1.6 % in the upper in some studies.<sup>2</sup> Others give 8.2 to 13.6 % when implants are placed next to teeth that have undergone difficult endodontic therapy or in sites where teeth were extracted after endodontic complications.<sup>2</sup>

In our practice, we studied the last 650 implants that were inserted. There were three true cases of RPI or PIL lesions (two of these cases are presented in this article), resulting in a prevalence of 0.46 %. The three implants affected represented 10 % of all failed implants.

## Treatment

Experience has shown that the sooner such lesions are treated, the higher the possibility for healing. Since there is no treatment protocol, our efforts are empirical and often based on oral surgery. An inactive RPI should not necessarily be treated, but controlled through periods of regular recall. For active lesions, we suggest the following four-stage methodology.

### Stage 1

In the case of Class 1 and 2 lesions, antibiotic therapy should be administered. Some clinicians regard amoxicillin with clavulanic acid as appropriate.<sup>3</sup> We believe the initial antibiotic could also be clindamycin if there is no perforation of the lesion buccally owing to the established higher bone penetration of this antibiotic. If adjacent teeth show endodontic inflammation or other pathologies



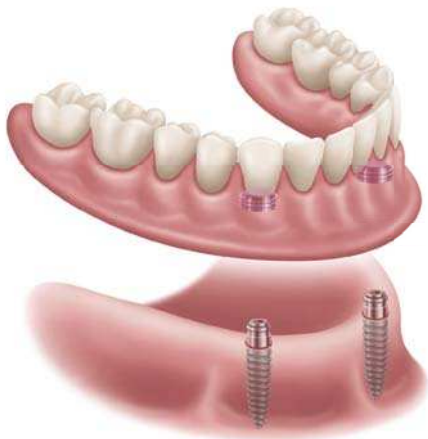
# FULL-ARCH IMPLANT SOLUTIONS AHEAD

REMOVABLE

FIXED

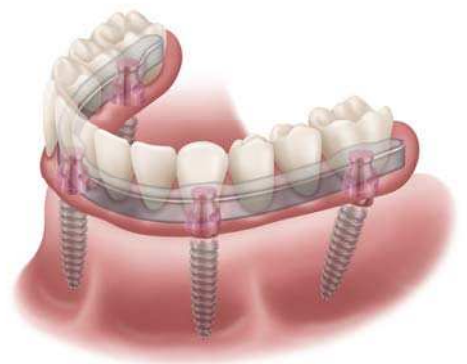


## LOCATOR R-Tx®



Patient **REMOVABLE**  
Prosthesis

## LOCATOR F-Tx®



**FIXED** Prosthesis -  
Clinician Removable

**TWO PATHS.  
ONE DESTINATION.**



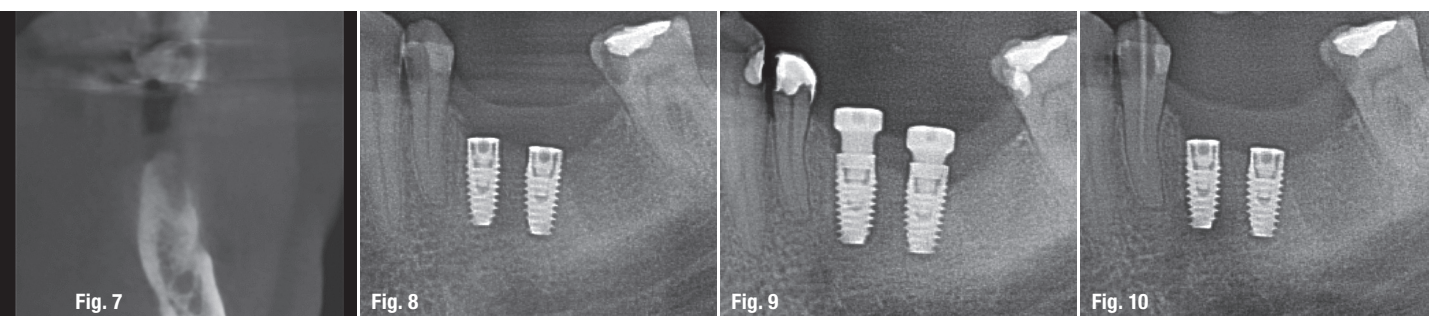
**LOCATOR R-Tx®** - Fourth generation patient **REMOVABLE** overdenture Attachment System predicated on the award-winning and market-leading LOCATOR® design. **BETTER. SIMPLER. STRONGER.**



**LOCATOR F-Tx®** - Novel **FIXED** full-arch Attachment System based on a PEEK snap-fit connection. **NO SCREWS. NO CEMENT. NO COMPROMISES.**

No matter which road you and your patients take, there is only one destination - **Zest Dental Solutions** - the pioneer and leader in full-arch implant solutions since 1977.

Visit [WWW.ZESTDENT.COM](http://WWW.ZESTDENT.COM) or call 800-262-2310.



**Fig. 7:** Pre-operative situation. **Figs. 8 & 9:** Control radiographs of two implants placed in regions #35 and 36 on the day of implantation. **Fig. 10:** Situation in regions #34 to 36: seven days after endodontic treatment. The patient was free of complaints.

(iatrogenic reasons, poor planning), they should be treated immediately. Thus, some studies have reported cases in which no bacteria were found on the surface of the explanted implant after occurrence of RPI.<sup>2,4</sup>

### Stage 2

If the lesion persists, established empirically from the oral surgery, the apex should be exposed. If the lesion is of Class 1 or 2 and the implant is stable, loaded or not, it should not be removed immediately. Surgical intervention from the lateral side should be performed if osseointegration has already occurred. Resection of the implant apex, depending on the extent of the lesion, can reduce the survival rate of the implant. The surgical procedure can be standard, rinsing with an antibacterial solution, application of local anaesthetic, curettage, administration of anti-inflammatory medicaments, drainage, etc. At the same time, we provide the patient with systemic antibiotic treatment accompanied by low-dose glyocorticosteroids or mefenamic acid. Some authors advise augmentation of the defect and flap closure; we believe this decision is not mandatory, but depends on the findings at the implant apex.

### Stage 3

If clinical symptoms and patient complaints disappear, we advise augmentation of the surgical access and coverage with a membrane. At this point, Mohamed et al. report expecting a higher success rate when resection of the implant apex is performed; however, in their study, they evaluated only loaded implants and the augmentation was performed with xenografts.<sup>5</sup> Resection of the implant apex can be an assistive step for Class 3 lesions to reduce the lesion when the thread design is not favourable for decontamination. Nevertheless, this procedure is of high risk for implant stability and removal of debris from the cavity. If at this stage of the therapy, the patient still has complaints, the implant should be removed.

### Stage 4

As long as the apical translucency is no longer evident and the patient has no complaints, implantation can be

performed. If primary stability cannot be achieved, guided bone regeneration should be performed. If symptoms or complaints cannot be controlled or the risk is high, one should wait for full bone healing, approximately six months, and plan for late implant placement. Delayed immediate implant placement seems to make no sense at this stage. A treatment protocol is provided by Kishnani et al.<sup>6</sup>

In general, the treatment of RPI or PIL relies on our experience and depends on the radiographic and clinical findings. Evident perforation of the buccal plate, compromised blood perfusion at the implant site and reduced primary stability describe a totally different situation with a different treatment protocol. Also, an association with the Epstein-Barr virus is a matter of current discussion.

### Treatment success rate

Studies report success rates of 46 per cent over four years.<sup>7</sup> Resection of the apex in cases of high primary stability and a lack of complaints seems to improve the success rate. The existing data is not sufficient to draw specific conclusions or evaluate treatment therapies. The reported success rates have also not been confirmed and do not differentiate between classification, symptoms or findings for the treatment applied. All data at this time is very limited.

### Case presentation

The cases in this article concern both PIL and RPI lesions. In the first case, the diagnosis was RPI due to inflammation of the adjacent tooth. The second case was diagnosed as PIL without evident cause, but contamination via the adjacent tooth was suspected. Both cases were late implantations without the need for bone augmentation, had entailed submerged healing, re-entry after four months and fixed prostheses. Both sites had been edentulous for nine to 15 months. At the time of implant placement, no pathological findings were made. Both cases were guided; the planning was assisted with cone beam computed tomography (CBCT). All preliminary and intraoperative planning and control aim at pre-



venting bone perforation (buccally or lingually).

Both patients reported no complaints directly after surgery. The RPI patient reported the first complaints six weeks postoperatively, while the PIL patient showed the first symptoms five and a half months after implantation and one and a half months after loading of the implant. Both patients underwent endodontic treatment of one adjacent tooth, since they showed symptoms also at these teeth. For the RPI patient, conservative treatment of the adjacent tooth was planned some days after implant placement (poor planning), but complaints had occurred earlier.

#### Case 1 (retrograde peri-implantitis)

This patient received two implants, in regions #35 and 36 (Figs. 7–9). The implant in region #35 was placed 2 mm from the adjacent tooth and 2 mm from the alveolar nerve loop. The insertion torque was 55 Ncm. Tooth #34 had been conservatively insufficiently treated and the treatment was planned to be performed by the referring dentist after implant placement.

One week after implant placement, the patient complained about pain at regions #34 to 36. The clinical examination found positive percussion of tooth #34, no apical pressure point and no pathological findings in the region of the implants. The radiographic examination showed a translucency at the apex of the implant in region #35 and this evoked suspicion regarding the adjacent tooth #34. Endodontic treatment was performed immediately and the patient additionally received systemic antibiotic therapy. Seven days after the complaints had resolved, percussion was slightly positive. After two weeks, no clinical findings were evident, either at the tooth or at the surgical site (Fig. 10).

At the time of re-entry, four months postoperatively, the implants showed osseointegration and the implant stability quotient (ISQ) was 72 mesiodistally and 75 buccolingually. Further treatment was performed as planned. The endodontic treatment was finalised af-

ter loading of the implant. After loading, at the time of obturation of tooth #34, the superstructure was removed and implant stability checked again. The ISQ value showed 74 mesiodistally and 76 buccolingually.

#### Case 2 (periapical implant lesion)

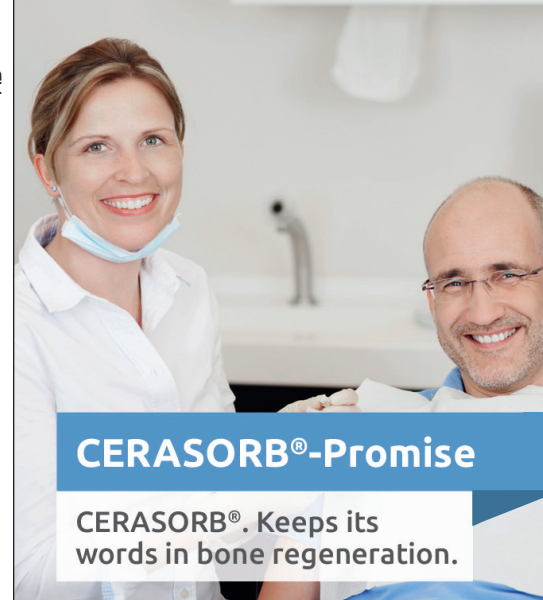This patient received a single implant in region #36. The adjacent teeth, #35 and #37, showed no pathological findings. Tooth #37 had a sufficient resin filling placed occlusally and buccally. Primary stability was very good, the insertion torque was 50 Ncm and the bone density D2–D3. The ISQ value at insertion was 70. Re-entry and prosthetic treatment were performed as planned. The patient received a screw-retained crown.

Six weeks after loading, the patient reported mild pain upon biting. Clinically and radiographically, no pathological findings were made. The occlusion and approximal contact were checked again. The crown was removed for control of the peri-implant soft tissue. The implant was then loaded again (Fig. 11).

Eight weeks after initial loading, the patient reported classic pulpitis complaints at the implant site: positive percussion and apical pressure point. The radiographic control now showed a lesion at the implant apex, diagnosed as PIL. The implant underwent surgical treatment, with a lateral approach at the implant apex and local antibacterial rinsing. The patient received systemic antibiotic treatment with amoxicillin and clavulanic acid, and the wound was drained. The crown was removed and a healing abutment inserted. The ISQ was 72 mesiodistally and 74 buccolingually at this point (Figs. 12 & 13).

Ten weeks after initial loading, the patient reported occlusal complaints at tooth #37 and the clinical finding was irreversible pulpitis. Tooth #37 received an endodontic treatment. Additionally, antibiotic therapy with clindamycin was administered (Fig. 14).

Twelve weeks after initial loading, the patient reported no complaints at tooth



#### CERASORB® M

- + big and microporous surface increases osteoconductivity
- + shortened duration of resorption by fast penetration with body own bone supporting structure



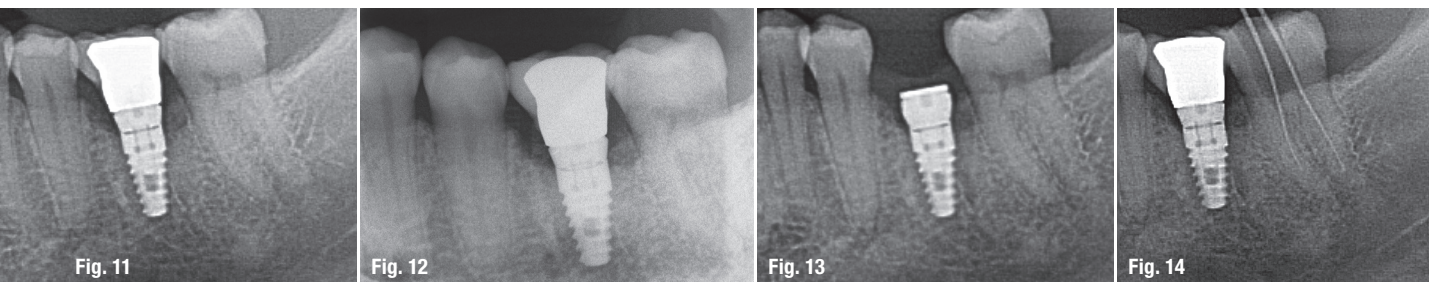
#### CERASORB® Foam

- + easy handling thanks to defect-adapted modelling and comfortable positioning

#### CERASORB® – Always First Choice.

Manufacturer:  
**curasan AG**  
 Lindigstrasse 4  
 63801 Kleinostheim  
 Germany  
[cerasorb@curasan.de](mailto:cerasorb@curasan.de)  
[www.curasan.de](http://www.curasan.de)

**curasan**  
 Regenerative Medicine



**Fig. 11:** Radiographic control six weeks after loading. **Figs. 12 & 13:** Radiographic findings eight weeks after loading. The prosthesis was removed and a surgical procedure performed at the implant apex. **Fig. 14:** Ten weeks after initial loading, endodontic treatment of the adjacent tooth was performed owing to clinical findings.

#37. There were, however, ongoing complaints regarding the implant region and this led to the removal of the implant 16 weeks after initial loading. The reverse torque for implant removal was over 200 Ncm, a trephine bur was not needed. Probing the implant osteotomy showed no soft-tissue infiltration whatsoever nor a bony defect. After explantation, the complaints were resolved within the first week. The symptoms at the implant had appeared many months after implant placement, thus excluding intraoperative cross-contamination, overheating of the bone, bone perforation or trauma of anatomical structures.

## Discussion

The most common reasons for RPI are cross-contamination by the adjacent teeth, and scar or granulation tissue at the implant site. The first main reason for RPI can easily be avoided. As shown in the first case, poor planning or insufficient clinical and radiographic examination can lead to such iatrogenically induced lesions. The second main reason is often preoperatively or intraoperatively difficult to determine. Especially old defects, with extraction of more than six months prior, show no conspicuities during the drilling protocol and probing before implant placement.

Both cases are not easy to treat. Adjacent teeth must be controlled critically before proceeding to surgery. Osteotomies should be probed for perforations, soft-tissue infiltration or other pathological findings that may increase operative risk. Another issue that has to be considered, for which we still have very poor data, is the host response after tooth extraction due to periodontal problems, even in late implantation cases.

Possible causes of RPI should be eliminated preoperatively or taken care of intraoperatively. These may be the following:

1. Overheating due to a faulty drilling protocol or its application;
2. bone necrosis through excess pressure from the implant due to a poor osteotomy, insertion torque, bone expansion technique, etc.;


3. contamination of the implant surface during insertion or of the osteotomy through saliva or surgical instruments; and
4. apical perforation buccally or lingually.

Furthermore, a detailed patient medical record and clinical examination should be undertaken to determine a differential diagnosis to avoid complications (viral infection, human pathogenic viruses, etc.).

The diagnosis of such lesions results in higher implant survival rates if made early and the extent of the lesion is small. Clinical cases are poorly documented so far and there is no consensus regarding treatment protocol. It is important to incorporate the possibility of RPI and PIL in the patient consent form and to discuss the necessity of conservative and periodontal treatment before adopting a surgical approach.

The survival rate of implants is continuously improving and their indication increasing. The interaction with other biological body systems and diseases forces us to face new challenges with very limited understanding of the processes taking place.

Literature



## contact

**Dr Nikolaos Papagiannoulis**

Dental Esthetics  
Hans-Böckler-Straße 2a  
69115 Heidelberg, Germany  
info@dentalesthetics.de  
www.dentalesthetics.de

Author details

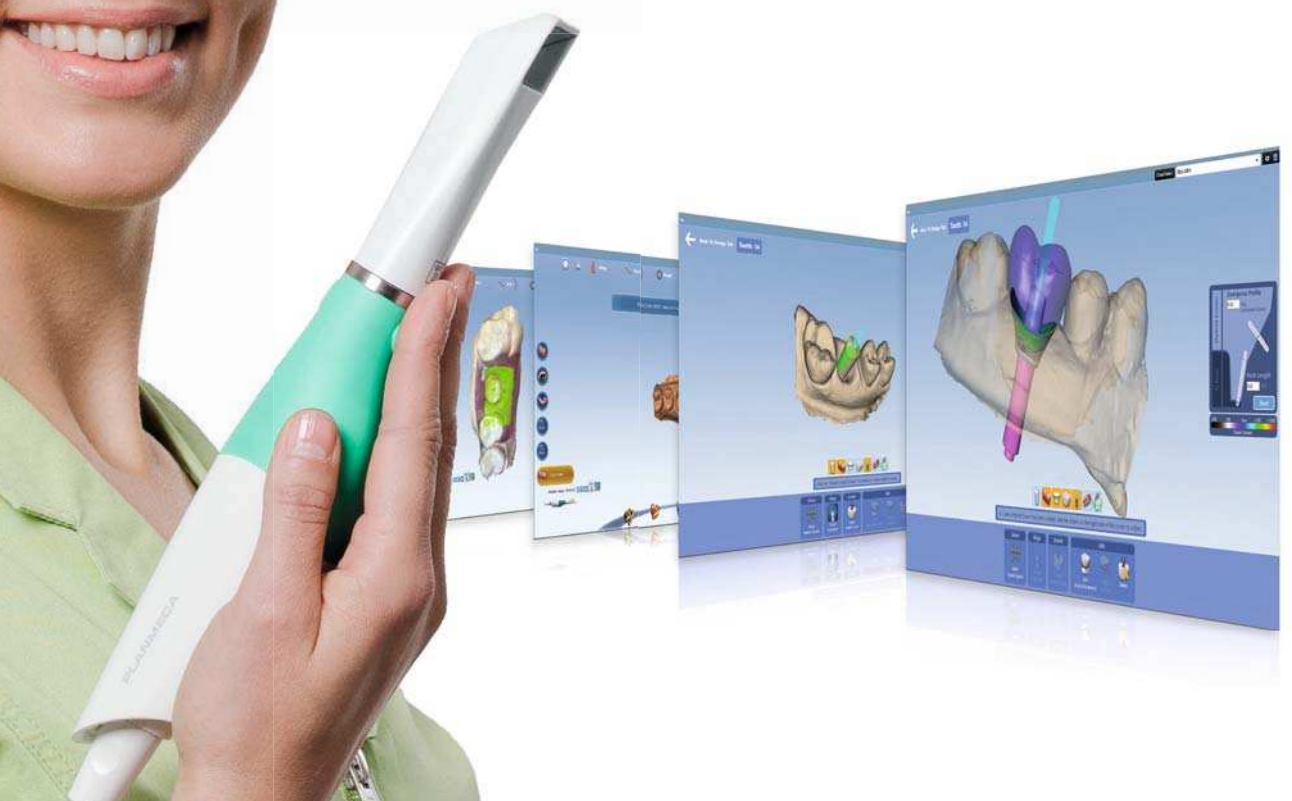



Planmeca Emerald™

# Elevate your scanning experience

**Planmeca Emerald™** is a small, lightweight and exceedingly fast intraoral scanner with superior accuracy. It is the perfect tool for smooth and efficient chairside workflows. Taking digital impressions has never been as easy!



- Highly accurate quadrant and full arch scanning
- Small and lightweight design
- Impeccable infection control
- Support for a wide range of indications

Find more info and your local dealer!  
[www.planmeca.com](http://www.planmeca.com)



## PLANMECA

Planmeca Oy, Asentajankatu 6, 00880 Helsinki, Finland. Tel. +358 20 7795 500, fax +358 20 7795 555, [sales@planmeca.com](mailto:sales@planmeca.com), [www.planmeca.com](http://www.planmeca.com)