

# Diode laser-assisted **vital pulp therapy** in pulp polyp treatment

Dr Maziar Mir, Germany; Dr Masoud Mojahedi, Germany; Dr Jan Tunér, Sweden & Dr Masoud Shabani, Iran

A **pulp polyp or hyperplastic pulpitis** is inflammation of the exposed dental pulp owing to an open cavitated carious lesion, tooth fracture after trauma or long-standing fractured restoration.<sup>1</sup> Type I hypersensitivity reactions may also have a role in pathogenesis of pulp polyps because of the higher concentration of histamine, immunoglobulin E and interleukin in primary or permanent teeth.<sup>2</sup> Removal of the polyp, pulpectomy and root canal therapy are considered for treatment of this disease.<sup>1,3</sup>

Internal root resorption and a periapical lesion (apical periodontitis) can often be seen in a tooth affected by a pulp polyp. The former indicates chronic inflammation with odontoclastic activity, and the latter expresses severely inflamed pulps, for example irreversible pulpitis or an infected root canal system.<sup>4,5</sup> A pulp polyp is referred to as asymptomatic irreversible pulpitis.

Recently, vital pulp therapy (VPT) has proven to be a successful treatment for molars with irreversible pulpitis associated with apical periodontitis. Based on many effective diode laser properties, diode laser-assisted VPT has shown to be a powerful method for VPT.<sup>6-9</sup>


This article aims to present successful results obtained by diode laser-assisted VPT in a case of pulp polyp disease, applied in permanent mandibular molars using calcium-enriched mixture (CEM) cement. One tooth also showed internal root resorption and periapical periodontitis and the other was not.

## Case presentation

A 17-year-old male patient with complaints of deep caries and an exophytic mass at a right mandibular permanent molar was referred to us for treatment (Figs. 1a & b).

## Medical history

The patient's medical history showed no systemic medical problems, no allergic reaction, no use of medications or recreational drugs and no history of past surgical procedures. Thus, the patient did not need to be referred for medical consultation.



## Dental history

Oral and maxillofacial examination of the patient revealed no temporomandibular joint disorder or myofascial disturbances, no functional or parafunctional habits, a Class I occlusion and poor oral hygiene.

## Clinical findings

In the oral examination process, the exophytic mass was found to interfere with eating and occlusion, causing intermittent pain and simultaneous bleeding.

## Diagnosis

The radiographic examination showed internal root resorption at the middle third and a periapical lesion at the end of the mesial root of the first molar, as well as large dental carious lesions in the first and second right molars of the mandible (Fig. 2). The patient was thus diagnosed with a pulp polyp.

## Laser-assisted VPT in the treatment of a pulp polyp

After the patient had completed the consent form, the operation area was anaesthetised through blocking of the inferior mandibular alveolar nerve with 2% lidocaine (1:80,000 adrenaline; 1.8 ml; Darou Pakhsh Pharmaceutical).

In the next step, the controlled area was defined and laser warning signs were properly placed in order to secure the operating room. The eye protection of the patient, the patient's guardian and the assistant were checked.

After reviewing the patient's information (examination sheet and radiograph, consent form, etc.), mouth rinsing was done with a 0.2% chlorhexidine oral rinse (Shahre Daru Laboratories) for about one minute.

The pulp polyp was removed with a high-power diode laser (Gigaa Laser) and the canal orifices were cleaned with a cotton pellet soaked in normal saline for five minutes, followed by low-level diode laser irradiation.

The laser parameters applied for the pulp polyp removal were as follows: wavelength of 980 nm, power of 1.2 W, fibre of 400 µm, initiated fibre, continuous wave and con-

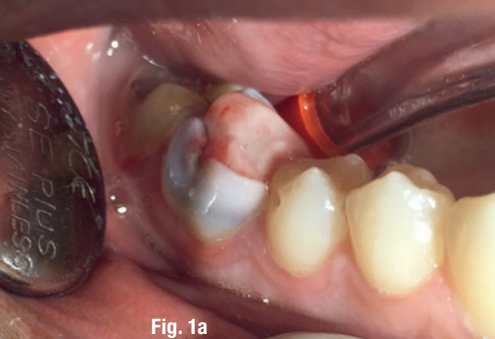

Fig. 1a

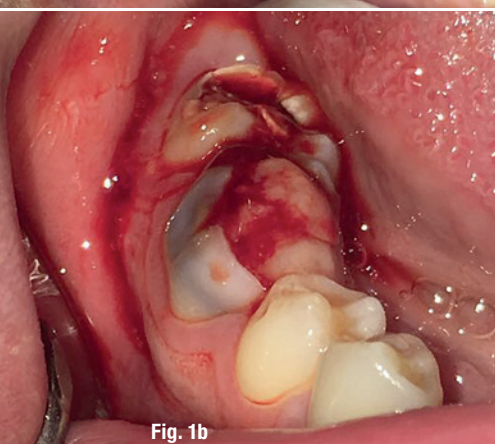


Fig. 1b

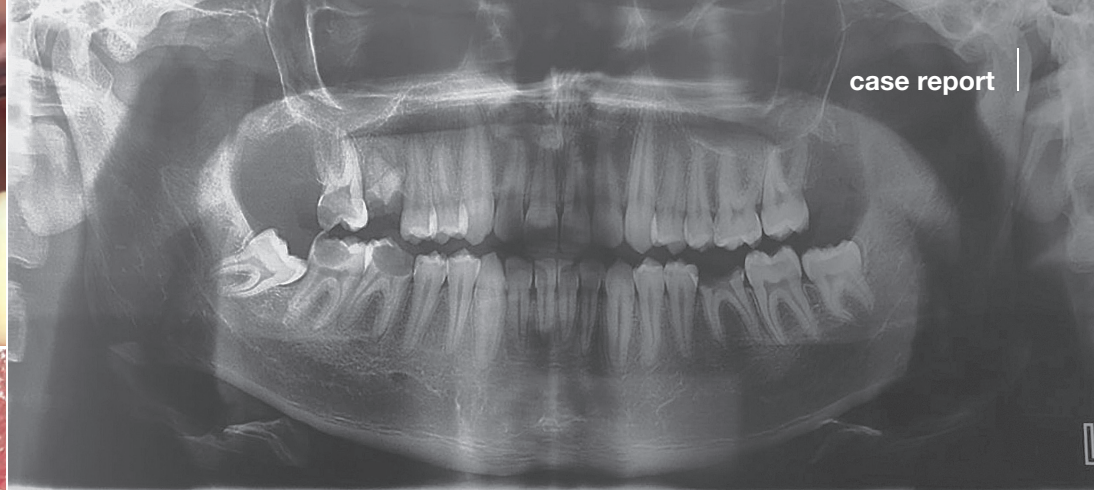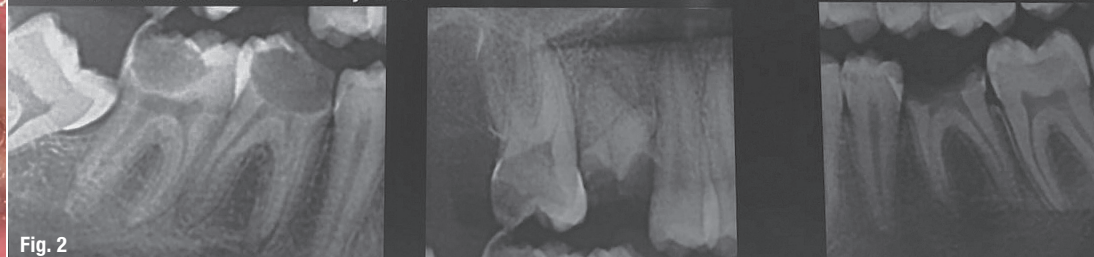/17 76.0kV 15.0mA 16.1s 265.3mGy×cm<sup>2</sup>

Fig. 2

**Figs. 1a & b:** Clinical appearance of the pulp polyp disease in the first and second right molars of the mandible. **Fig. 2:** Radiographic examination showing large cavities in the first and second right molars, a radiolucent lesion in the periapical area and internal root resorption of the first molar mesial root.

tact mode. After completing this procedure, Low Level Laser Therapy (LLLT) was performed (Figs. 3a & b). The laser parameters for bio-modulation intentions were the following: wavelength of 980nm, output power of 300mW, irradiation time of 10s and energy of 3J. The size of the laser aperture was 7mm<sup>2</sup> and irradiation was performed in a rotational mode at a distance of 5mm. The area of the canal orifice was 13mm<sup>2</sup>.

After this procedure, the CEM cement dressing was placed (Fig. 4a). The CEM cement dressing was done on a base of 2mm of CEM cement paste (Biunique Dent) prepared according to the manufacturer's instructions using a sterile plastic instrument. A dry sterile cotton pellet was used to achieve better adaptation of the CEM cement to the cavity wall at the exposure site.

Interim restorative treatment with a glass ionomer cement (Fuji IX, GC Europe) was applied according to the manufacturer's instructions without finger pressure after CEM cement placement (Fig. 4b). We decided to place the permanent filling after one month.

#### Post-procedural education

The patient was advised to respect oral hygiene according to the Caries Management by Risk Assessment requirements, and the next visit was scheduled for two days after the VPT procedure.

#### Final result

Excellent pulp polyp removal was achieved and the VPT was carried out with no bleeding, carbonisation or char. The patient did not experience any discomfort and was satisfied with the result. Radiographic examination was performed in order to monitor the result

of the laser-assisted pulpotomy based on radiographic changes (Fig. 5).

#### Follow-up

The first visit after treatment was scheduled for two days after the procedure. No pain was experienced and the second LLLT was performed with the same setting, but in contact mode at the coronal part, the mid-root part and the apical part of each root of the two affected molars in order to promote the healing process. The next visit was again scheduled for two days later in order to perform the third LLLT.

Finally, at the follow-up appointment at seven months, a successful treatment outcome was observed clinically and the patient experienced no pain. The good results were also evident in the radiographic examination (Fig. 6). A successful treatment outcome could be observed, the periapical radiolucency had disappeared and the internal root resorption of the mesial root of the first molar had stopped.

#### Discussion

Diode lasers are used extensively in many dental practices.<sup>10</sup> Laser-tissue interaction with a high-power diode laser is based on photothermal effects and in LLLT is not photothermal, but works based on a photochemical mechanism.<sup>11,12</sup> Since LLLT is dose-dependent,<sup>13</sup> the laser parameters have to be respected carefully.<sup>14,15</sup> The precise molecular mechanisms for LLLT are not entirely clear, but its clinical effects on pain control, inflammation reduction and wound healing are well investigated.<sup>16-18</sup> Gupta et al. reported that laser pulpotomy with high-power diode lasers showed better clinical and radiographic

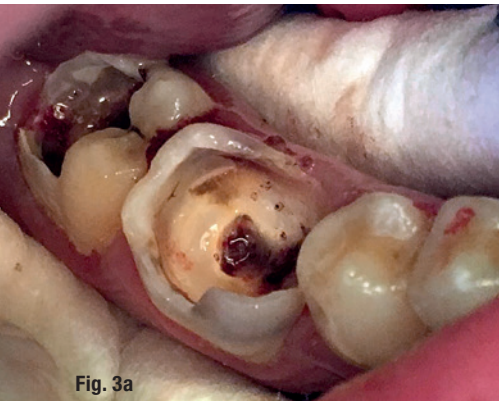


Fig. 3a

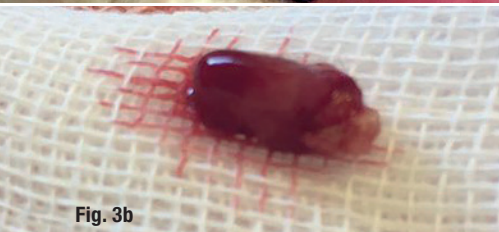


Fig. 3b

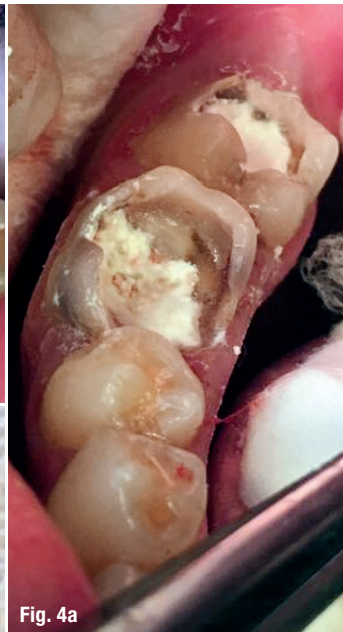

Fig. 4a

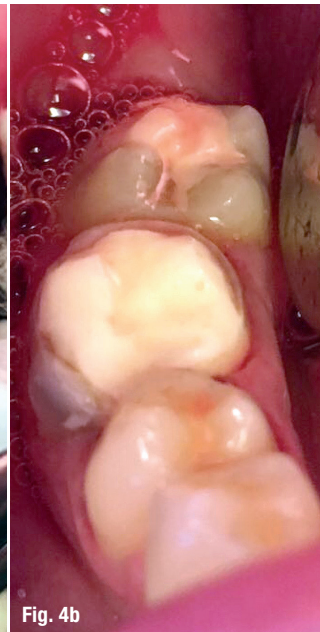


Fig. 4b

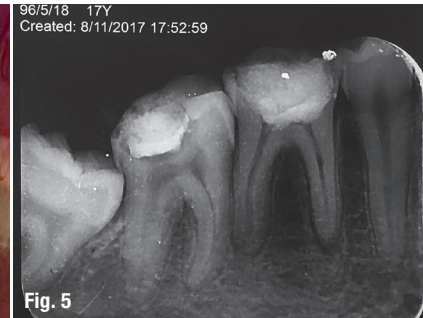


Fig. 5

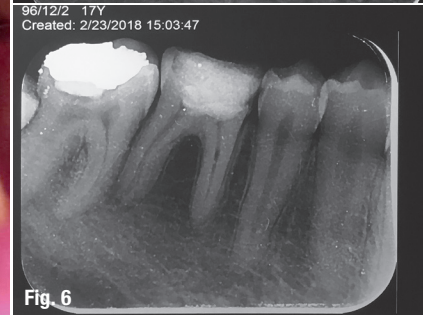


Fig. 6

**Figs. 3a & b:** Situation immediately after pulp polyp removal and achievement of good coagulation with the diode laser and subsequent LLLT. **Figs. 4a & b:** Situation immediately after CEM cement placement and interim restorative treatment with a glass ionomer cement. **Fig. 5:** Radiographic examination immediately after VPT of the teeth affected by the pulp polyp disease. **Fig. 6:** Radiographic examination at approximately seven months after VPT: successful situation after treatment.

results in human primary molars than did electrosurgery and ferric sulphate pulpotomy in order to achieve good coagulation.<sup>19</sup> Uloopi et al. have applied low-level diode lasers in pulpotomy and they noted that Low Level Laser Therapy can be considered for pulpotomy in primary teeth, its success being comparable to mineral trioxide aggregate pulpotomy technique.<sup>20</sup>

### Conclusion

It is clear that the aim of diode laser application in pulpotomy can be very different. In this case, a high-power diode laser was applied for pulp polyp removal and good coagu-

lation, and LLLT was used to promote the healing process. Based on the laser protocol applied in this study, diode lasers can be successfully used for VPT of pulp polyps.

### contact

**Dr Masoud Shabani**  
 Department of Community Dentistry  
 School of Dentistry  
 Ardabil University of Medical Sciences  
 Ardabil, Iran  
 m.shabani@arums.ac.ir



### Kurz & bündig

Ein Pulpapolyp wird auch als asymptomatische irreversible Entzündung der Zahnpulpa bezeichnet. Eine derzeit als erfolgreich angesehene Behandlung von Molaren, welche von einer derartigen Pulpitis in Verbindung mit apikaler Paradontitis betroffen sind, ist die Vitale Pulpatherapie (VPT). Aufgrund der vielen fördernden Eigenschaften von Diodenlasern, hat sich der Einsatz eines entsprechenden Lasers, als besonders effektive Methode zur Vitalen Pulpatherapie erwiesen.

Die Autoren spezifizieren in ihren Ausführungen die Behandlungserfolge einer in diesem Sinne vorgenommenen laserbasierten VPT eines Pulpapolypen. Im dargestellten Fall eines 17-jährigen Patienten wurde diese Methode zur Behandlung bleibender Unterkiefermolaren mit massiven Kavitäten angewandt. Ein Zahn zeigte zudem eine interne Wurzelresorption und periapikale Paradontitis auf.

Zur Entfernung des Pulpapolypen wurde ein 980 nm-Diodenlaser genutzt und CEM-Zement platziert. Im Anschluss folgte eine mehrphasige Low-Level-Laser-Therapie (LLLT), um den Heilungsprozess zu beschleunigen. Die verwendeten Laserparameter werden detailliert wiedergegeben. Basierend auf dem im Zuge dieser Fallstudie angewandten Laserprotokoll kann der Einsatz eines Diodenlasers als erfolgreich in der VPT von Pulpapolypen bestätigt werden.



# M.Sc. Lasers in Dentistry

Specialist in dental laser therapies

Next Start: **23<sup>rd</sup> September 2019** | Aachen, Germany | 4 semesters

Aachen Dental Laser Center - AALZ  
Pauwelsstraße 17 | 52074 Aachen | Germany  
phone +49241 47 57 13 10 | fax +49 241 47 57 13 29  
info@aalz.de  
www.aalz.de

RWTH International Academy  
Kackertstraße 10 | 52072 Aachen | Germany  
phone +49 241 80 23543 | fax +49 241 80 92525  
info@academy.rwth-aachen.de  
www.academy.rwth-aachen.de



Aachen Dental Laser Center

**INTERNATIONAL  
ACADEMY**

**RWTHAACHEN  
UNIVERSITY**

**PROFESSIONAL EDUCATION PROGRAMMES**

Your contact for more information: Leon Vanweersch • vanweersch@aalz.de - www.aalz.de