

Dual-wavelength laser in aesthetic and prosthetic dentistry

A minimally invasive approach

Dr Bogdan Crisan, Dr Liana Crisan, Dr Mihaela Baciut, Prof. Grigore Baciut, Dr Simion Bran, Dr Horatiu Rotar, Dr Adrian Petrutu, Dr Darius Tomina, Dr Cristina Dinu & Dr Cristian Dinu, Romania

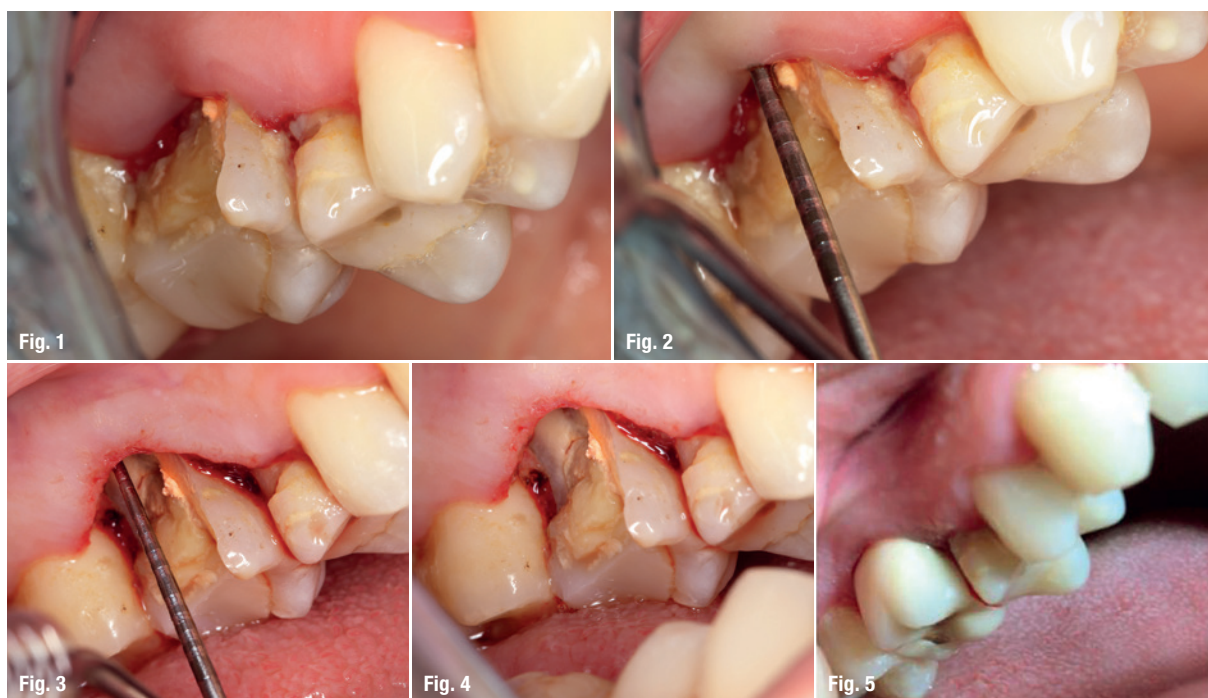
Introduction

In recent decades, lasers have been developed to be a very useful tool in everyday dental practice. Laser systems have found increasing application in more and more areas of dentistry. Aesthetic and prosthetic dentistry, in particular, are two fields of dentistry in which laser light has been found useful. Crown lengthening, removal of gingival pigmentation, tooth whitening, debonding of ceramic crowns or veneers, sulcular conditioning and minimal preparation of the tooth structure are just some of the dental procedures in which a laser can be used with success.¹⁻⁷

Minimally invasive dentistry (MID) was defined as a philosophy of professional care that is concerned with

first occurrence, the earliest possible resolution of disease at a micro level, followed by a minimally invasive treatment approach to repair irreversible damage caused by such disease.⁸ MID is a concept that was initially applied in conservative dentistry. This concept has been further developed in other areas of dentistry in recent years. MID reaches the treatment objective using the least invasive surgical approach with the removal of a minimal amount of healthy tissue.⁹ A minimally invasive approach is used today by many dental practitioners in all dental procedures.

The laser is a minimally invasive tool for the requirements of a MID approach. Today multiple laser wavelengths with different absorption in tissue can be used for maximum results with minimal side effects. Lasers



Case 1 – Fig. 1: Initial situation: hypertrophic and bleeding gingiva. **Fig. 2:** Clinical examination found a probing depth of 6 mm. **Fig. 3:** Situation after removal of the hypertrophic tissue with Er:YAG laser. **Fig. 4:** Area after Nd:YAG laser treatment. **Fig. 5:** Two months later with ceramic reconstruction *in situ*.

have been widely used in many fields of dentistry, and several wavelengths have been investigated as substitutes for a high- or low-speed handpiece, scalpel or various invasive instruments.¹⁰ The lasers of the erbium family with wavelengths in the mid-infrared region of the electromagnetic spectrum were introduced in dentistry especially for hard-tissue removal owing to their high absorption by water and hydroxyapatite molecules. The Er:YAG laser with a wavelength of 2,940nm, which corresponds to the absorption peak of water, is indicated for hard dental tissue and bone ablation. The ablative action is also due to a combination of photothermal and photoacoustic effects caused by micro-explosions of water against the target tissue.¹¹ In contrast with erbium lasers, the Nd:YAG laser with a wavelength of 1,064nm is poorly absorbed by water and selectively absorbed by haemoglobin and hyperpigmented tissue.¹² In this context, the Nd:YAG laser has been found to be valuable for treatment of benign, vascular and pre-malignant lesions of the oral mucosa.¹³

The purpose of this article is to demonstrate the usefulness of a dual-wavelength Er:YAG and Nd:YAG laser (Light-Walker, Fotona, Slovenia) in aesthetic and prosthetic dentistry, following the concept of MID in three clinical cases.

Case presentation

Case 1

A 35-year-old male patient was referred to our private clinic for surgical intervention in order to remove the hypertrophic gingiva around tooth #16 (Fig. 1). The patient's major complaint was a fracture of the buccal wall of the first molar with pain and bleeding on probing.

During clinical examination we found a 6mm depth on probing in the buccal area (Fig. 2). Therefore, we decided to perform a minimally invasive gingivectomy. The LightWalker Er:YAG (2,940nm) and Nd:YAG (1,064nm) laser system was used for this approach. For the removal of the hypertrophic gingiva, a contact handpiece for the Er:YAG laser

(H14-N) with a cylindrical tip (8.0mm in length; 1.3mm in diameter) was used. The laser parameters utilised for this case were as follows: average output power of 1.2W, pulse duration of 500µs (Long Pulse [LP] mode), pulse repetition rate of 10Hz (120mJ per pulse) and under water spray (water: 1; air: 2). The hypertrophic tissue was removed layer by layer until the fractured margins of the crown were visible (Fig. 3).

Haemostasis was established and final removal of the bleeding tissue was performed with a laser fibre (300µm in diameter) attached to the R21-C3 handpiece of the Nd:YAG laser. The laser parameters used for this procedure were as follows: average output power of 4W, pulse duration of 250µs (Short Pulse [SP] mode) and pulse repetition rate of 50Hz.

After this minimally invasive procedure, we obtained a clean and visible area, required for achieving an optimal crown reconstruction (Fig. 4). The laser procedure was performed under local anaesthesia (articaine and 1:100,000 adrenaline). The patient reported no pain at any stage of the procedure and no discomfort after laser treatment. Two months later, the patient received a prosthetic restoration with a ceramic onlay produced by CAD/CAM (Fig. 5).

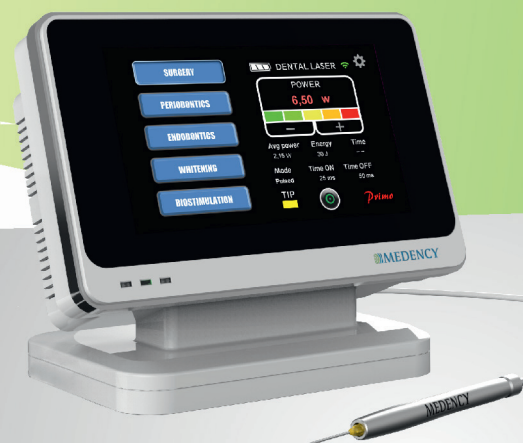Case 2

A 68-year-old female patient presented to our department because of a lesion that had developed on the left upper lip. It had grown in size lately and bothered her in terms of appearance. The patient required a minimally invasive solution to remove the lesion and to improve her appearance.

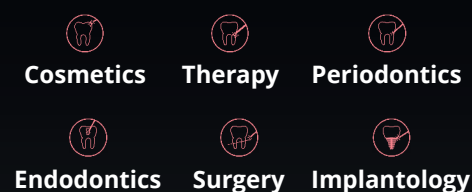A thorough medical and dental history were taken prior to the clinical examination. After the clinical and dental examination, we suspected the presence of a vascular disease, because the lesion disappeared upon digital pressure and the colour was red-blue (Fig. 6). We recommended a colour Doppler ultrasonographic examination to confirm the diagnosis. The examination revealed a vascular lesion localised under the oral

EXCEED YOUR EXPECTATIONS

The most innovative Dental Laser technology for your practice



PRIMO



One-touch TECHNOLOGY +35 pre-set TREATMENT 5-Top FAVORITES

Stress-free software, fully automatic parameter selection offers the ideal way to boost productivity. Versatile, fast and accurate selection of protocols from a large variety of programs. Every functional aspect of Primo has been developed with end users in mind. Most useful programs at your finger touch.

Active Time ASSIST Multi-function HANDPIECES Master-mode FOR EXPERTS

Designed to help users to improve patient's care by stopping the laser output to potentially avoid tissue overheating. The ergonomic lightweight handpiece gives the user a total control of movements. Wide selection of optical tips, whitening arch biostimulation and cosmetic tools. Advanced software-enabled mode allows experienced users to achieve outstanding performance and to generate new protocols.



medency.com



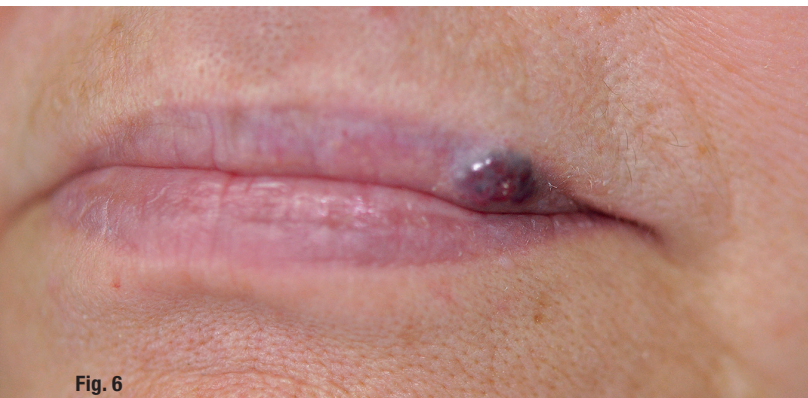

Fig. 6

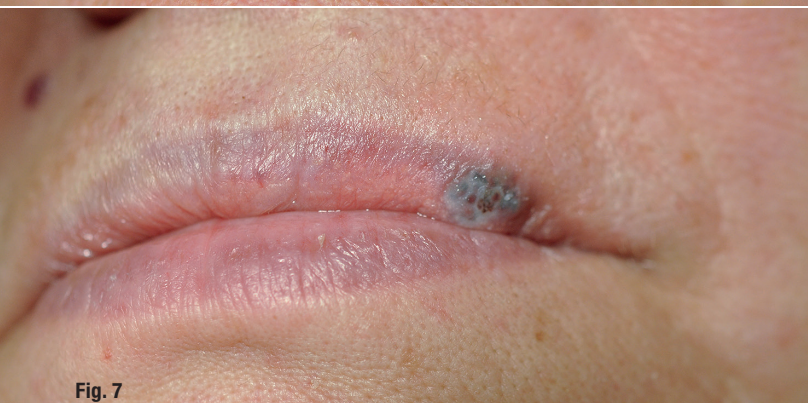

Fig. 7

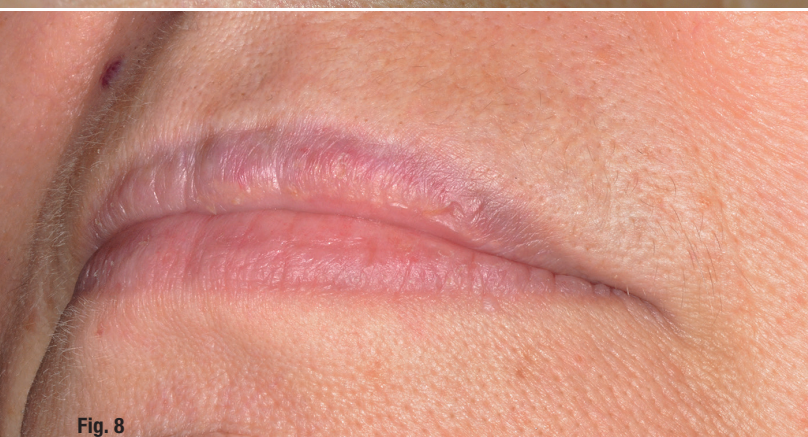

Fig. 8

Case 2 – Fig. 6: Clinical view of the venous malformation. **Fig. 7:** After Nd:YAG laser treatment. **Fig. 8:** Situation at the six-week follow-up.

mucosa with a venous vascular signal (a venous malformation).

Photocoagulation with a laser wavelength that has good absorption in haemoglobin was performed under local anaesthesia (articaine and 1:100,000 adrenaline), using the Nd:YAG laser (1,064 nm, LightWalker) in a non-contact mode, through a glass plate and under continuous cooling with ice cubes. For the procedure, the R21-C3 handpiece and a laser fibre (300 µm in diameter) were used. The laser parameters in this case were as follows: average output power of 5W, pulse duration of 250 µs (SP mode) and pulse repetition rate of 100Hz.

Immediately after laser therapy, we obtained bleaching by sclerosis and a decrease of the vascular lesion (Fig. 7). Postoperatively, we recommended anti-inflammatory treatment with ibuprofen (400 mg b.d.) and the local application of Cicaderm cream (Ivatherm). The patient reported no pain after the laser procedure, only a reduced oedema for two to three days.

At the follow-up appointment six weeks later, very good healing of the treated area without any recurrence or revascularisation and a good aesthetic result were evident (Fig. 8).

Case 3

A 36-year-old female patient presented to the private practice with an aesthetic complaint. The patient was unhappy with the shape and colour of the porcelain veneers on her maxillary anterior teeth and with the level and appearance of the gingiva (Fig. 9). The patient required a minimally invasive solution to improve her smile.

The laser-assisted removal of veneers is a fast and minimally invasive method. For debonding the porcelain veneers, an Er:YAG laser (2,940nm, LightWalker) with a non-contact handpiece (H02-N) was used. The laser parameters for this procedure were as follows: average output power of 6W, pulse duration of 100 µs (Micro Short Pulse [MSP] mode), pulse repetition rate of 30 Hz (200 mJ per pulse) and under water spray (water: 3; air: 3). The veneers (IPS e.max lithium disilicate, Ivoclar Vivadent) were removed one by one without any fracturing, because only the bonding adhesive absorbed the laser irradiation (Fig. 11). The laser treatment was performed without local anaesthetic. The patient reported no sensitivity at any stage of the procedure.

Immediately after the procedure for removal of the porcelain veneers, the patient received temporary composite veneers. Two weeks later, we realised a recontouring of the gingiva around these provisional veneers (Fig. 12). For aesthetic gingival recontouring, a dual-wavelength laser (Er:YAG/Nd:YAG, LightWalker) was used. The Er:YAG laser parameters for reshaping the gingiva were as follows: average output power of 1.2W, pulse duration of 500 µs (LP mode), pulse repetition rate of 10Hz (120mJ per pulse) and under water spray (water: 1; air: 2). A contact handpiece (H14-N) for the Er:YAG laser with a conical tip (16.0mm in length; 0.6mm end diameter) was used.

The finishing of the shape was performed and haemostasis was established with a laser fibre (300 µm in diameter) attached to the R21-C3 handpiece of the Nd:YAG laser. The laser parameters used for this procedure were as follows: average output power of 3.5W, pulse duration of 250 µs (SP mode) and pulse repetition

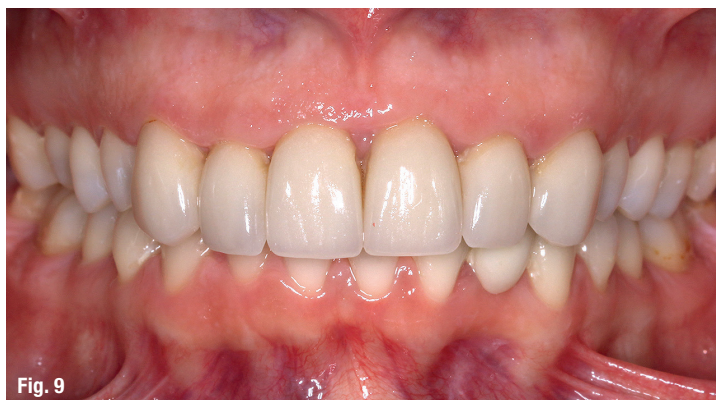

Fig. 9

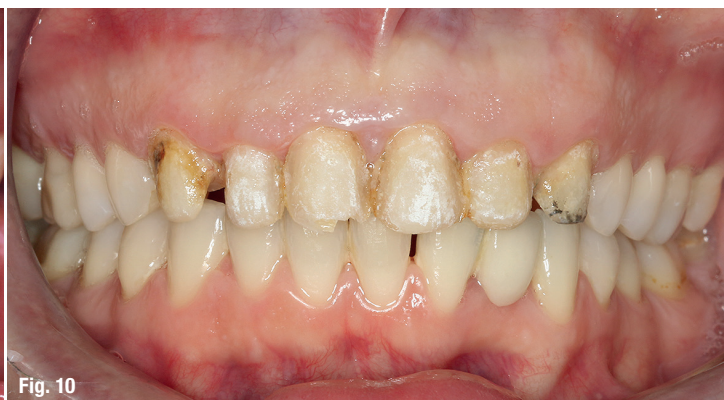

Fig. 10

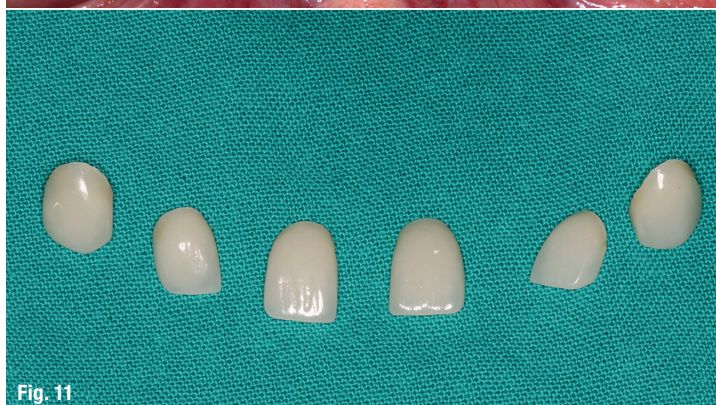

Fig. 11

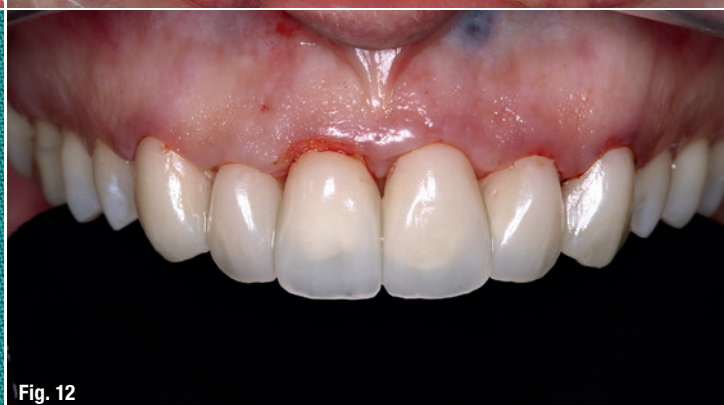

Fig. 12

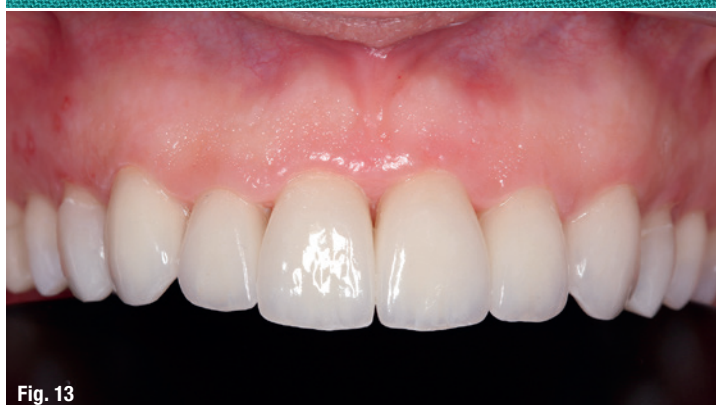

Fig. 13

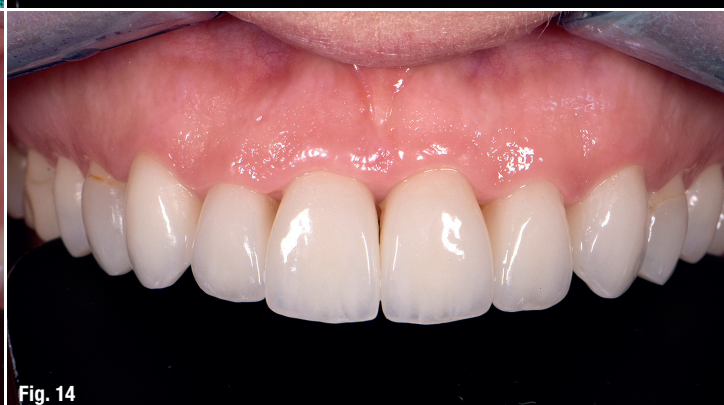

Fig. 14

Case 3 – Fig. 9: Initial situation: shape and colour of the veneers and level of the gingiva. **Fig. 10:** Clinical view immediately after removal of the veneers. **Fig. 11:** Ceramic veneers removed. **Fig. 12:** Immediately after gingival recontouring. **Fig. 13:** Final restoration with ceramic veneers. **Fig. 14:** Situation at the two-year follow-up.

rate of 40Hz. Four weeks after gingival healing, the final restoration was achieved with IPS e.max lithium disilicate veneers (Fig. 13).

At the follow-up appointment two years later, the patient was still satisfied with the aesthetic appearance achieved (Fig. 14).

Discussion

In the development of MID, it is important to use innovative materials, new and improved clinical techniques, and the latest equipment and systems in order to preserve the natural tissue. Using a creative and minimally

invasive approach to dentistry helps us provide our patients with new levels of excellence in care.¹⁴

Low- and high-power lasers have been adopted as useful tools in minimally invasive dentistry owing to their clinical benefits. Successful aesthetic treatments involve not only restorative procedures, but also the presence of healthy surrounding tissue.¹⁵ Lasers are now widely used for minimally invasive treatment in routine clinical procedures. The dual-wavelength laser can be used in various aesthetic and prosthetic procedures, as has been described in the clinical cases presented in this article. Er:YAG and Nd:YAG lasers have become more popular owing to their dual hard- and soft-tissue applications.

In the first case, the removal of the hypertrophic gingiva would conventionally have been performed with a scalpel or a round diamond bur, resulting in a bleeding surface and additional patient discomfort. In contrast, the use of a dual laser for this procedure resulted in a bloodless environment that healed quickly and uneventfully, while facilitating subsequent restorative procedures. Additionally, lasers offer superior control of the gingival sculpting process and should be part of aesthetic crown lengthening.¹


According to the literature, laser therapy for treatment of vascular anomalies has improved significantly over the last three decades to treat haemangiomas, capillary malformations and venous malformations of the head and neck.¹⁶ In the second case, the Nd:YAG laser was effective in treating the mucosal venous malformation. Laser therapy, sclerotherapy, surgical excision, or a combination of these treatment modalities may be necessary for disease control. In our case, laser photocoagulation was the optimal minimally invasive treatment, achieving a good result in a short period.

The results of Oztoprak et al. showed that the Er:YAG laser is effective in reducing the shear bond strengths of porcelain laminate veneers from very high values to a level that allows their easy removal from the teeth.¹⁷ Er:YAG lasers are clinically indicated for the removal of composite fillings. Laser absorption occurs in the organic components of the resin. The ablative mechanism involved is an explosive vaporisation followed by a hydrodynamic ejection. The Er:YAG laser can thus successfully be used to efficiently debond all-ceramic full-contour crowns from natural teeth.⁴ In our last clinical case, the dual-wavelength laser successfully demonstrated this efficacy in debonding all-ceramic veneers with a minimal effect on the healthy tissue.

Conclusion

As a conclusion to our clinical case presentations, it can be said that the dual-wavelength laser (Er:YAG laser and Nd:YAG laser) represents a very useful tool in aesthetic and prosthetic treatment in accordance with the concepts of minimally invasive dentistry.

Literature




contact

Dr Bogdan Crisan

Iuliu Hatieganu University of Medicine and Pharmacy Cluj-Napoca
Department of Implantology and Maxillofacial Surgery
Cardinal Iuliu Hossu St. No. 37
400029 Cluj-Napoca, Romania

Med Artis Dent Private Clinic
Strada Voltaire 16
400130 Cluj-Napoca, Romania
bbcrisan@yahoo.com
www.medartisdent.ro

Author details



Kurz & bündig

Laser haben sich besonders in der ästhetischen und prothetischen Zahnheilkunde als effektives Instrument erwiesen und werden in diesen Bereichen speziell im Sinne der minimalinvasiven Zahnmedizin (MID: minimally invasive dentistry) bevorzugt eingesetzt. Ziel des minimalinvasiven Ansatzes ist es dabei, maximale Resultate bei minimalen Nebeneffekten zu erreichen.

Anhand von drei Fallbeispielen stellen die Autoren den Einsatz der Dual-Wellenlängen-Methode mit dem LightWalker von Fotona als Alternative zu invasiven Instrumenten vor. So konnte zum Beispiel im ersten Fall die hypertrophe Gingiva mit dem dualen Laser blutungs-frei entfernt und somit eine schnelle Heilung erreicht werden. In der Folge wurden dadurch auch die restaurativen Prozesse erleichtert. Im dritten Fall konnten die Autoren zudem die Effizienz des Einsatzes des Dual-Wellenlängen-Lasers im schonenden Entfernen von Keramikveneers mit minimalen Auswirkungen auf das umliegende gesunde Gewebe nachweisen. Die einzelnen Behandlungsstufen und genutzten Laserparameter werden für jeden der drei Fälle spezifiziert.

Die kombinierte Anwendung der Er:YAG- und Nd:YAG-Laser in Form des LightWalker erwies sich in den drei dargestellten Fallbeispielen als erfolgreich und wird von den Autoren daher als effektive Methode für den Einsatz in der minimalinvasiven Zahnmedizin speziell in der Behandlung von ästhetischen und prothetischen Fällen empfohlen.

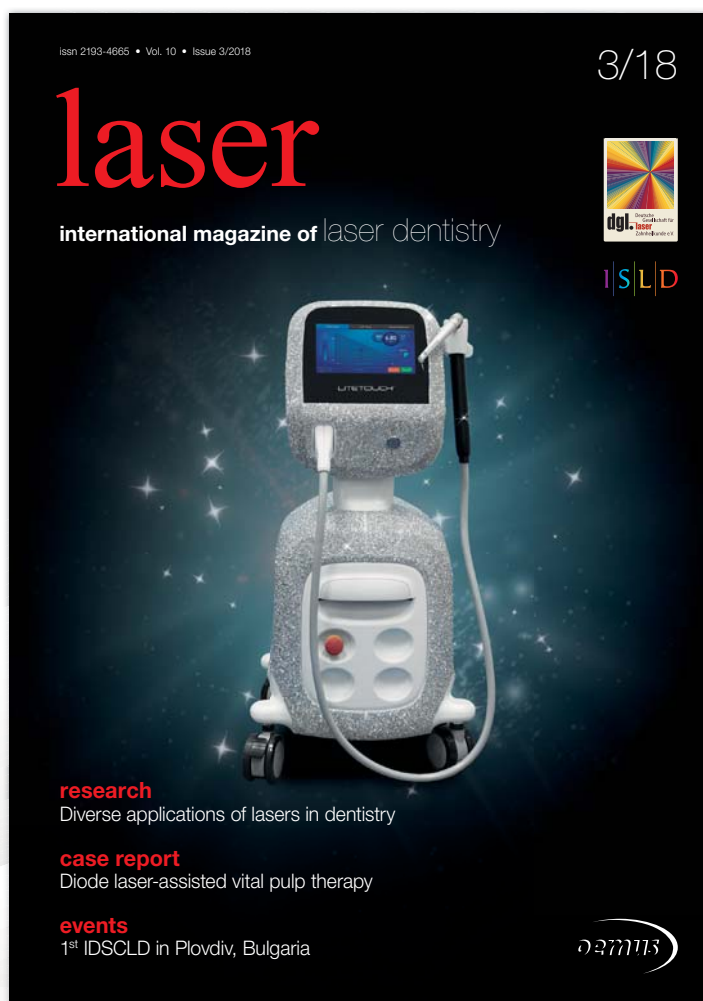
BECOME AN AUTHOR

for laser—international magazine of laser dentistry

Interdisciplinary and close to the market



www.oemus.com



Become part of a successful network and benefit from a wide reach and high level of awareness

Your benefits:

- author's profile at ZWP online
- specimen copies
- offprints
- speaking engagement*



*according to the required profile

Fax to **+49 341 48474-290**

☐ Yes, I want to become an **author** for laser—international magazine of laser dentistry. I would like to submit an article on the following topic:

Please send back your fax form
or contact Mr. **Georg Isbaner**:
g.isbaner@oemus-media.de · Phone: +49 341 48474-123

Last Name, First Name

Street/ZIP/City

Phone/E-Mail

Stamp

laser 3/18