

Modern technologies in the treatment of periodontal disease

Synergistic benefits

Dr Carmine Prisco, Italy

A private healthcare activity follows the same principles that are applicable to any professional activity that interacts with a heterogeneous public. In fact, also for a dental office, knowledge and reputation are fundamental assets for a successful professional activity and need to act in synergy and are mutually reinforcing.¹ The graph shows how investing in technology is crucial for the optimisation of a dentist's activity (Fig. 1).

Hence, the digital transformation and the technological evolution of dental surgery represent an exceptional opportunity today for the general dentist to develop his or her activity.

Offering patients suitable therapies represents the ethical principle on which all medical, and thus dental, activities are based, guaranteeing patients predictable results, reduced treatment times, greater comfort, minimal invasiveness and better care. These are the guiding principles of technologically supported dentistry completely oriented towards patients' needs, well-being and comfort.

Standard laser-assisted full-mouth disinfection protocol

To show how modern technologies available to all dental surgeries can support the dental care by improving treatment protocols, periodontal disease and, in particular, a specific treatment, denominated laser-assisted full-mouth disinfection (LAFMD), are considered in this article.

The standard protocol for LAFMD treatment consists of the following four phases:

First phase:

- 0.2 % chlorhexidine
- Ultrasonic scaler
- Air polishing decontamination

Second phase (periodontal pockets of 5 mm or deeper):

- Deep ultrasonic and manual scaling
- Air polishing decontamination
- Laser debridement

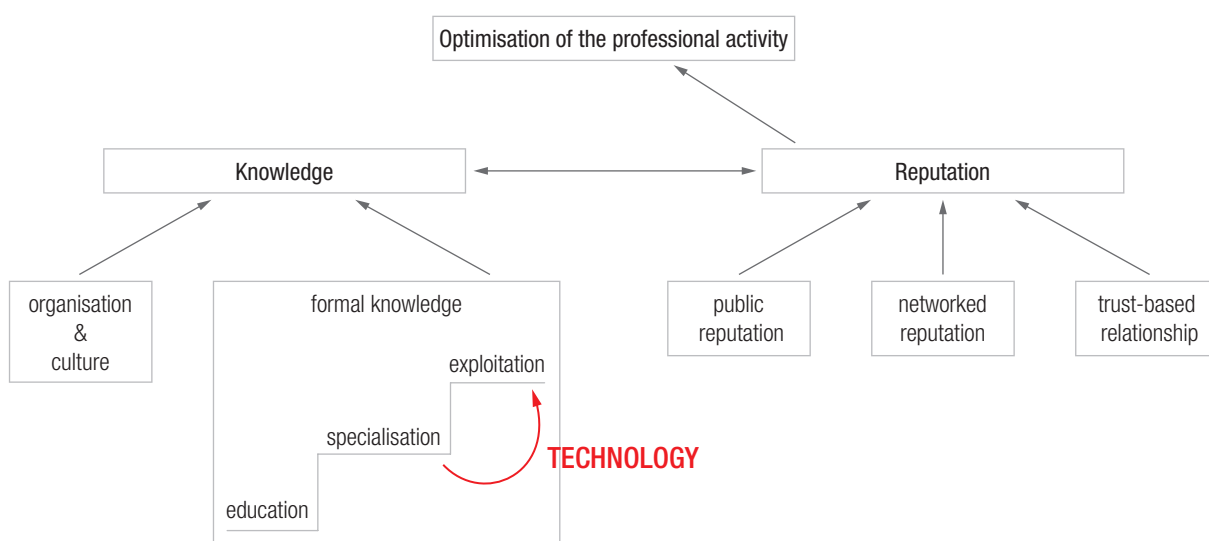


Fig. 1: Optimisation of the dentist's activity by investment in technology.



Fig. 2

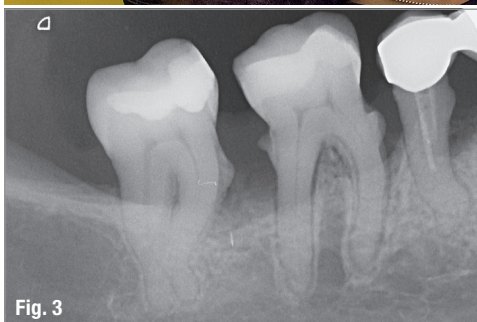

Fig. 3

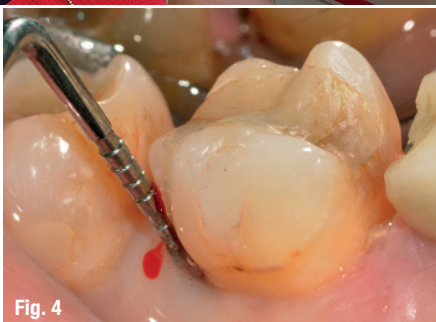

Fig. 4

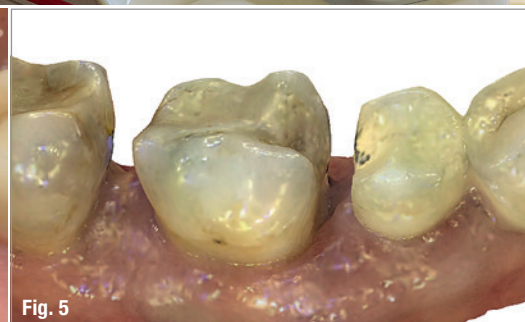

Fig. 5

Fig. 2: The patient is shown intraoral scans throughout all treatment phases. **Fig. 3:** Radiographic examination. **Fig. 4:** Periodontal probing. **Fig. 5:** 3D model shown to the patient for better understanding and motivation.

- Application of 1 % chlorhexidine gel to the pockets
- Laser analgesic treatment

Third phase:

- Photodynamic treatment
- Antibiotic treatment in the pockets
- Biostimulation

Fourth phase:

- Compliance check and follow-up

Periodontal disease is so prevalent that it is the sixth most common disease in the world. According to the data in the literature and to the 2018 classification,² considering all four stages of the disease, it is present in 70 % of the population aged between 35 and 44 years, in 90 % of 45- to 80-year-olds, and in 4 % of 18- to 34-year-olds.³

Hence, the treatment of periodontal disease constitutes an important part of the daily activity of a dental surgery. Offering effective therapeutic protocols that are affordable for the whole population thus represents a relevant social duty for the modern dentist.

It is particularly fundamental for periodontal therapy to be aimed at managing the inflammation that accompanies the disease, which has strong associations with systemic diseases such as diabetes, cardiovascular disease and other chronic illnesses.

LAFMD is a non-surgical minimally invasive protocol aimed at the treatment of the various forms of periodontitis, and it has been defined according to experimental scientific results in the literature. This protocol benefits from the use of different technologies and is performed by the dentist and the hygienist in collaboration.

The treatment is adapted according to the degree of periodontitis, and the age, and individual condition of the patient.

Application of the LAFMD protocol

When performing a periodontal treatment, it is fundamental that the patient fully complies with the dentist's instructions throughout the whole treatment plan. To achieve this goal, the intraoral scanner Condor (Biotech

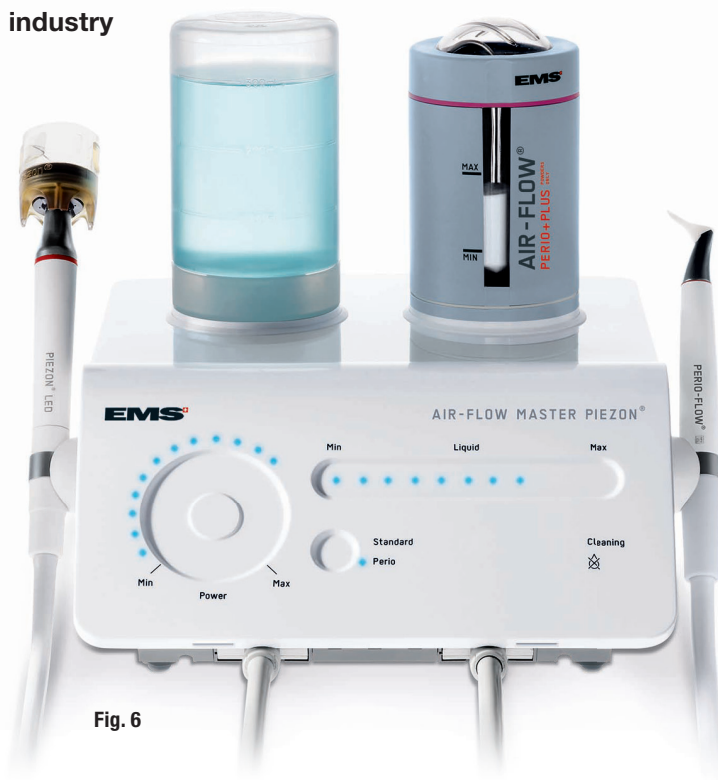

Fig. 6

Dental) should be used in every stage of the treatment to engage the patient by showing him or her 3D colour models of the mouth (Fig. 2).

Hence, during the first visit, an intraoral scan of the sectors to be treated needs to be performed systemati-

cally, contributing to the diagnosis, which involves standard methodologies such as radiographic examination (Fig. 3) and periodontal charting (Fig. 4).

Showing the patient digital 3D models (Fig. 5) of his or her mouth and discussing his or her individual situation with the patient is the most effective way to motivate and retain him or her, as the patient becomes aware of the evolution of his or her mouth throughout the treatment plan.

First phase

The first phase of the LAFMD treatment is aimed at an initial mechanical removal of the main aetiological agents of the disease: calculus and biofilm. Air polishing decontamination is added to the standard initial preparation processes involving ultrasonic scalers and pharmacological therapy.

In the practice of the author, the AIR-FLOW Master Piezon unit (EMS; Fig. 6) is used to carry out subgingival air polishing with erythritol powder (AIR-FLOW PLUS powder, EMS; mean grain size of 14µm) that contained 0.3% chlorhexidine. During the procedure, a special disposable nozzle made from thermoplastic elastomer is used (Fig. 7).

The air-powder mixture exits from the previously mentioned nozzle horizontally, while the water exits from an outlet at the tip of the nozzle and simultaneously irrigates the pocket for five seconds. After the procedure with the AIR-FLOW Master Piezon unit is completed, instrumentation with the ultrasonic scaler of the same device is performed (Fig. 8). These treatments are commonly conducted without anaesthesia.

The international literature clearly shows the improved results in controlling the aetiological factors resulting from this procedure^{4,5} and shows the ability to preserve the root cementum, as this methodology requires less use of manual curettes.⁶

Second phase

In cases of advanced disease, that is sites with periodontal pockets of 5mm depth and more, a second phase to control the disease is necessary. In such cases, the dentist can apply a 980nm diode laser of 10W, which can be used not only in surgery, but also in the treatment of periodontal disease.

In the second phase, the PRIMO diode laser (MEDENCY; Fig. 9) is a main tool of the protocol, being used with single-use fibres of 10mm in length and 400µ in thickness. The programme is set on a pulsed modality of 30 on/70 off, 2.4W and 25 seconds in order to conduct a deep debridement of the root surface and to remove the inflamed tissue inside the pocket (Figs. 10a & b).

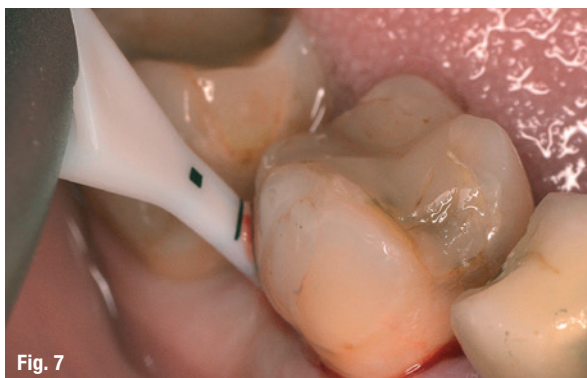

Fig. 7

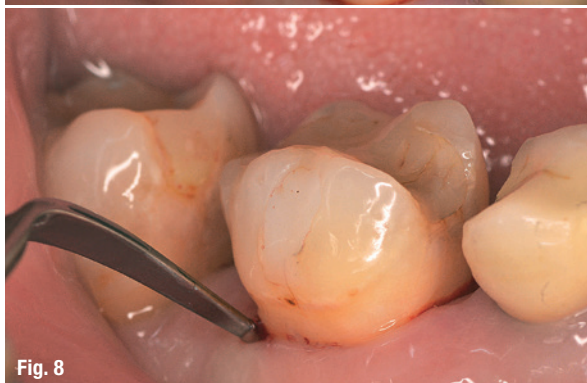

Fig. 8

Fig. 6: Subgingival air polishing performed with an AIR-FLOW Master Piezon unit. **Fig. 7:** A special disposable nozzle made from thermoplastic elastomer is used during the procedure. **Fig. 8:** Treatment with the ultrasonic scaler of the device.

The literature documents that diode lasers have a bactericidal, bacteriostatic and antitoxic function.⁷ Significantly better results in bacterial reduction are thus achieved with diode laser therapy in comparison to therapy without laser. The bleeding index improved in 96.6 % of cases treated with the laser, compared with only 66.7 % of cases treated with standard methodologies. Pocket depth is also reduced more significantly in cases treated with laser.⁷

The diode laser helps to reduce inflammation in the periodontal pockets in addition to scaling. Diode laser therapy, in combination with scaling, thus supports healing of the periodontal pockets through eliminating bacteria.

Various studies have shown that the predictability of the results obtained using a 980nm diode laser of 10W has improved.⁸ They have also shown that ultrasonic air polishing decontamination and use of a diode laser improve both the efficiency of treatment and the prognosis, stopping the progress of the disease, gaining clinical attachment and decreasing pocket depth.⁹

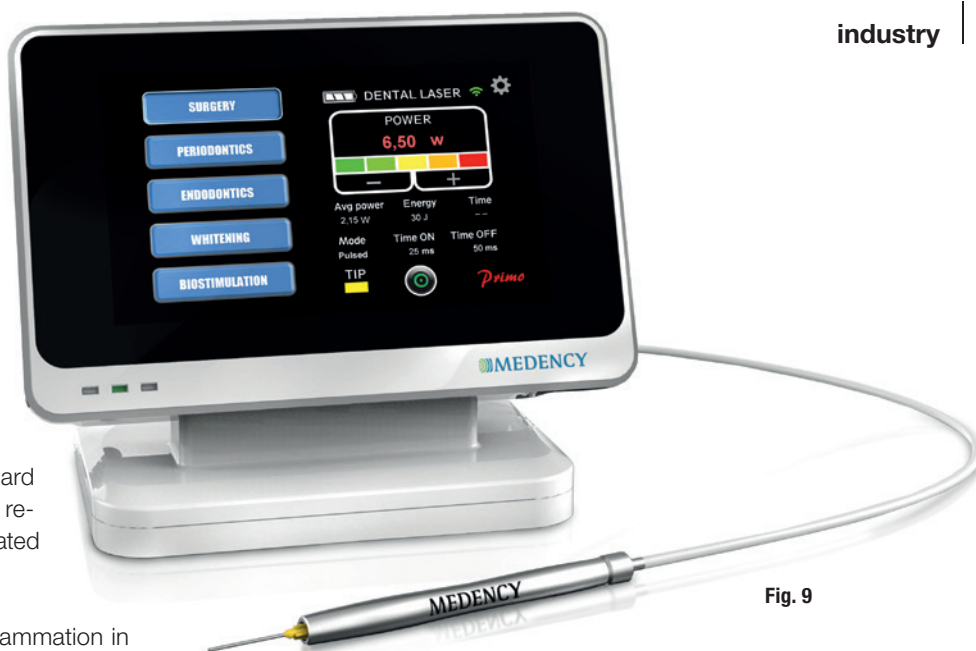


Fig. 9

In this phase, a 1 % chlorhexidine gel is used inside the periodontal pockets to extend and strengthen the effect of the 980nm laser.¹⁰ The versatility of the diode laser allows the operator to employ two preset programmes: analgesic therapy and biostimulation. These are especially practical and useful at the end of a particularly demanding therapeutic session.

A session of analgesic therapy, in particular, is usually performed after deep debridement using the dedicated

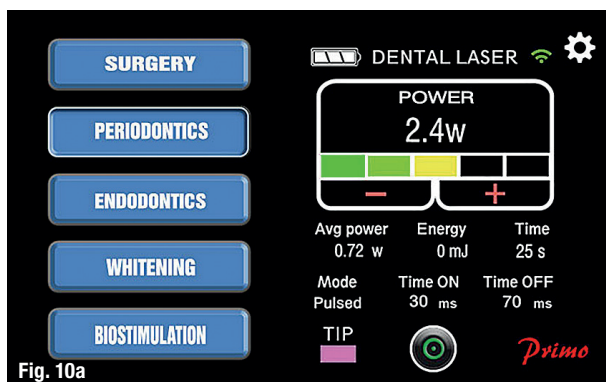


Fig. 10a

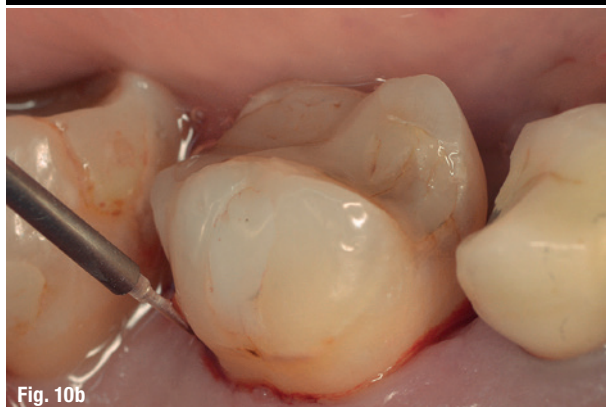

Fig. 10b

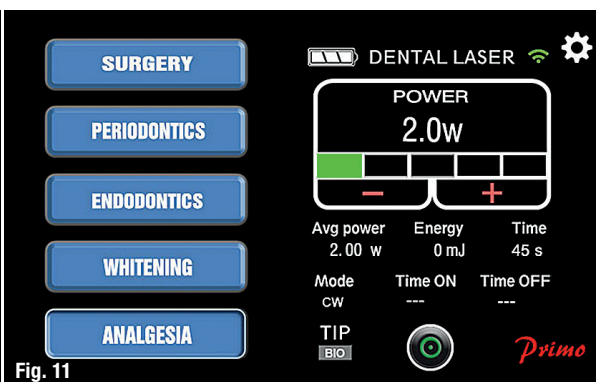


Fig. 11

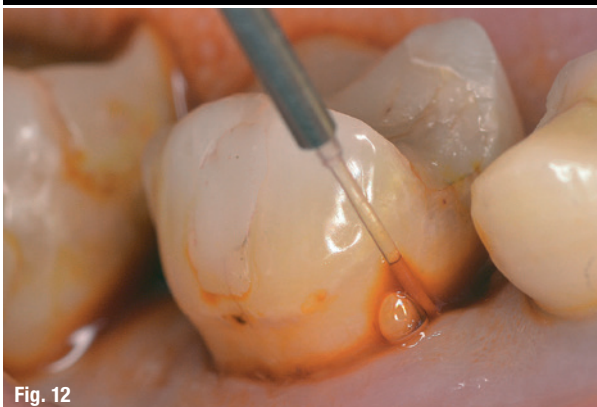

Fig. 12

Fig. 9: The PRIMO laser can be applied in the second phase for treating deep periodontal pockets. **Figs. 10a & b:** Laser settings used during debridement of the root surface and the removal of the inflamed tissue. **Fig. 11:** Laser settings applied during analgesic therapy with the PRIMO laser. **Fig. 12:** Insertion of 10% iodopovidone solution with a laser fibre.

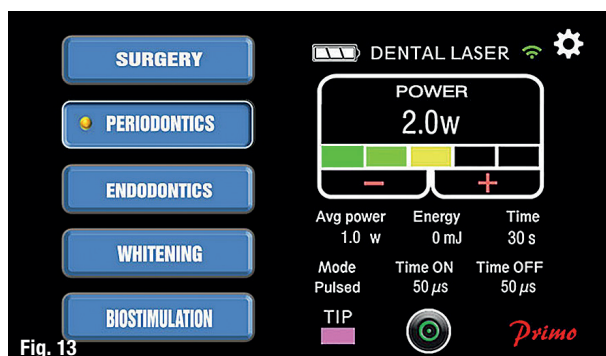


Fig. 13

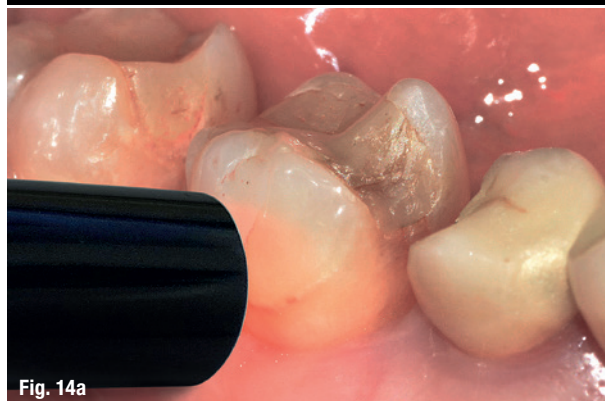


Fig. 14a

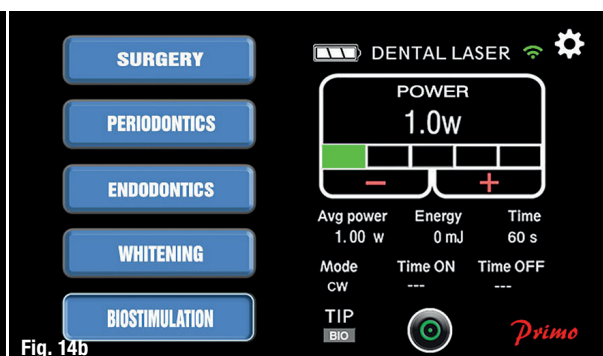


Fig. 14b

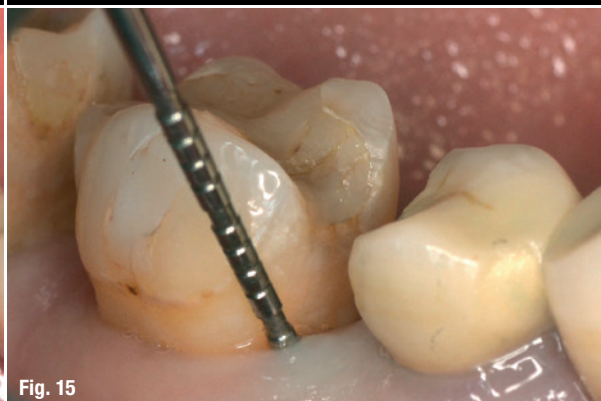

Fig. 15

Fig. 13: Laser settings used for photodynamic-photothermal therapy. **Fig. 14a:** Biostimulation using the laser. **Fig. 14b:** Laser parameters for biostimulation. **Fig. 15:** Situation at the end of the third phase: reduction of pocket depth and no inflammation.

handpiece of the PRIMO laser in continuous mode for 60 seconds at a power of 2W (Fig. 11).

Third phase

The third phase is aimed at controlling the activity of the bacteria present in the periodontal pockets. The results of experimental research have demonstrated the inability of surgical scaling and root planing to obtain a total mechanical removal of the aetiological factors. Resorting to systemic antibiotic therapies does, however, not meet unanimous approval of dentists. Hence, photodynamic therapy has recently evolved by applying past knowledge to laser technology.¹¹

Therefore, photodynamic-photothermal therapy, having a bactericidal effect, is associated with the suitable topical antibiotic medications. A 10% iodopovidone solution is conveyed inside the pocket before inserting the fibre of the PRIMO laser (Fig. 12), employing a pulsed modality of 50 on/50 off for 30 seconds per pocket at a power of 2W (Fig. 13).^{8, 12}

The objective of using this technique is to achieve a drastic reduction of the bacterial load inside the pocket. The laser also plays a fundamental role in the regeneration of the fibroblasts and in gingival attachment. The results of some studies in the literature have demonstrated that non-surgical laser applications modulate behaviour of gingival fibroblasts, which leads to inducing growth factor mRNA expres-

sion as a consequence. These applications can be used to improve periodontal wound healing.¹³ To aid tissue healing, this procedure is completed with biostimulation executed for 60 seconds with power set to 1W using the dedicated handpiece of the laser (Figs. 14a & b). The LAFMD protocol is especially suitable in the treatment of peri-implantitis, a specific form of periodontal disease, which is increasingly occurring with the evolution of modern dentistry.

Scientific studies have demonstrated better short-term results when protocols involving diode lasers are applied for the treatment of peri-implantitis compared with protocols that do not involve them.¹⁴ Therefore, in the decontamination of sites affected by peri-implantitis, this protocol is a valid auxiliary instrument. As tests conducted six months after the protocol was performed showed a partial bacterial recolonisation,¹⁵ it should be recommended to the patient to undergo the protocol twice a year.

At this stage of the treatment, the absence of inflammation and the reduction of pocket depth in the absence of bleeding are evident results (Fig. 15). The patient can maintain these results over time by complying with the correct guidelines provided by the dentist and by receiving adequate assistance.

Fourth phase

In the fourth phase, the patient's compliance plays a particularly fundamental role in the success of the ther-

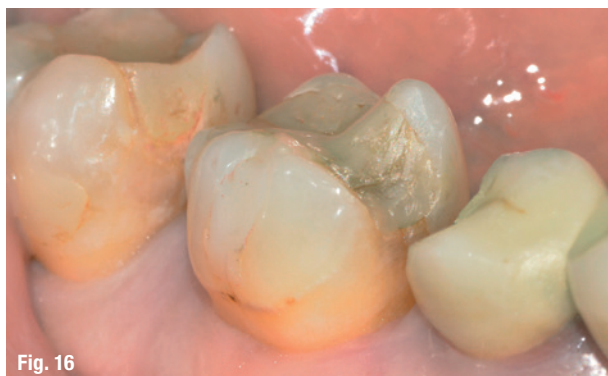

Fig. 16

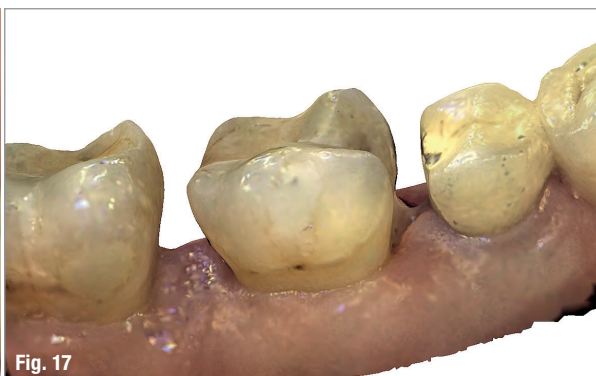


Fig. 17

Fig. 16: Final situation after treatment: stable mucosa and no bleeding. **Fig. 17:** 3D colour model of the final result used to strengthen patient motivation regarding follow-up compliance.


apy of periodontal disease. It is important to establish an individual and specific follow-up schedule for each patient to check the results over time, monitor the evolution of the disease and schedule the next follow-up sessions.

In this phase, it is fundamental to show the results achieved to the patient in order to strongly motivate him or her to maintain correct oral hygiene at home and to attend the follow-up sessions. A correctly performed LAFMD provides an immediate sensation of well-being to the patient, who experiences the absence of inflammation and bleeding, together with a new-found dental stability (Fig. 16). To support this, the 3D colour models obtained thanks to the Condor scanner are of exceptional motivational function (Fig. 17).

Conclusion

The LAFMD is a perfect example of a therapeutic protocol in which modern technology supports the dentist's

activity, allowing him or her to provide patients with minimally invasive, comfortable non-surgical treatments with predictable results. Patients are the fulcrum of the dental professional activity. Correct usage of modern technologies to adequately answer to their needs and expectations through effective and high-quality therapies is the principle on which modern dentistry is founded.



Literature

contact

Dr Carmine Prisco

Specialisation in implantology, prostheses
and laser dentistry
Dental surgery clinic
Salerno, Italy
carmineprisco@hotmail.it



Author details

Kurz & bündig

Parodontitis ist die weltweit sechst häufigste Krankheit. Dies ist der Grund dafür, dass die Behandlung von parodontalen Erkrankungen ein integraler Bestandteil der alltäglichen zahnärztlichen Praxis ist. Parodontale Therapien sollten im besten Falle immer darauf abzielen, krankheitsbegleitende Entzündungen einzudämmen. Im vorliegenden Artikel wird das nichtoperative und minimalinvasive LAFMD-Protokoll vorgestellt, mit welchem effektiv und kostengünstig verschiedenste Formen der Parodontitis behandelt werden können. Das Protokoll profitiert von dem Einsatz verschiedener Technologien und wird gemeinsam vom Zahnarzt und Hygieniker durchgeführt. Das Standardprotokoll der LAFMD-Behandlung besteht aus vier Phasen: Zunächst wird 0,2%iges Chlorhexidin verabreicht und anschließend sowohl mit einem Ultraschallscaler als auch einem Air-Polishing-System gearbeitet. Die zweite Phase definiert sich durch den Einsatz von Ultraschallscalern und manuellen Scalern, Laser Debridement, die Verabreichung von 1%igem Chlorhexidin-Gel in die zu behandelnden Zahnfleischtaschen sowie den Einsatz eines Lasers zur Schmerzlinderung. Die anschließende dritte Phase besteht dann aus einer photodynamischen Behandlung, der Verabreichung von Antibiotika und dem Einsatz von Biostimulation. Die vierte und damit letzte Phase der Therapie beinhaltet einen Compliance-Check und eine Nachsorgeuntersuchung. Das LAFMD-Protokoll ist ein Paradebeispiel für ein therapeutisches Protokoll, in welchem verschiedene moderne Technologien im Rahmen der Behandlung einer parodontalen Erkrankung zusammenfinden und miteinander harmonisieren, wodurch der Patient eine minimalinvasive, schmerzarme und nichtoperative Behandlungsalternative erfahren kann. Das LAFMD-Protokoll ist somit ganz im Sinne der modernen Zahnheilkunde, die sich anschickt, mithilfe von effektiven und hochqualitativen Behandlungsmethoden den individuellen Ansprüchen von Patienten gerecht zu werden.