

Amalgam tattoo removal with diode laser

Dr Maziar Mir, Prof. Norbert Gutknecht, Dr Masoud Mojahedi, Germany; Dr Jan Tunér, Sweden; Prof. Ramin Mosharraf, Sevda Noori & Dr Masoud Shabani, Iran

Introduction

An amalgam tattoo belongs to the group of common pigmented lesions in the oral cavity. Such tattoos are created through emergence of amalgam particles into the damaged oral mucosa during placement of amalgam fillings or a discolouring of the soft tissue close to the amalgam filling over time. Clinically, amalgam tattoos appear as bluish-black or bluish-grey lesions on the oral mucosa, most commonly on the gingival surfaces, alveolar mucosa and buccal mucosa. The incidence of amalgam tattoos has been reported as up to 8 per cent of samples surveyed.^{1,2}

The clinical appearance of the lesion and the presence of radiopaque amalgam fragments in radiographs are enough to diagnose an amalgam tattoo. If no metallic fragments can be identified in a radiograph, a biopsy of the lesion is recommended to rule out melanocytic neoplasia. Unless for aesthetic reasons, treatment of an amalgam tattoo is not necessary.^{3,4} Owing to the severity of melanoma, clinicians must differentiate between benign lesions and serious lesions, most notably melanoma. Based on the pigment origin, a bluish-black or bluish-grey pigmented lesion may be classified as an endogenous or exogenous pigmented lesion. Based on the involved areas, such lesions are further differentiated into localised and diffuse pigmentations.

Localised bluish-black or bluish-grey pigmented lesions include:

1. pigmentation due to metals like amalgam, graphite, lead (in the oral cavity, amalgam tattoos usually occur near restorations);
2. melanotic macule (small in size, mostly occurs on lips, due to increase in melanin synthesis);
3. naevus (increased proliferation of melanocytes, usually innate/congenital);
4. malignant melanoma (dark, irregular borders, asymmetrical and rapid in growth); and
5. post-inflammatory pigmentation due to healing of lesions such as lichen planus, pemphigus and pemphigoid disease.

Diffuse pigmentations include:

1. physiological pigmentation (present from birth);
2. smoker's melanosis (due to history of smoking);
3. endocrine disorders like Addison's disease/Cushing's syndrome (based on systemic signs and symptoms);
4. HIV-associated melanosis (based on ELISA test for HIV); and
5. pigmentations associated with syndromes, such as McCune–Albright and Peutz–Jeghers (requires general examination for other associated features).

All of the above-mentioned lesions have to be considered in differential diagnosis when considering the treatment of such darkly pigmented areas in the oral cavity.⁵

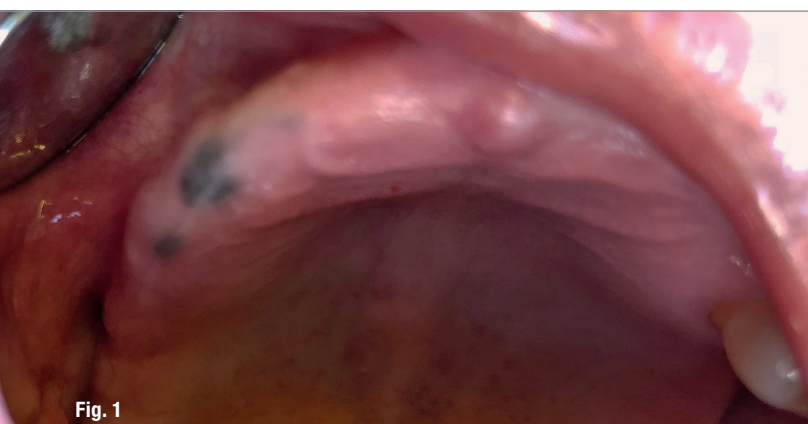


Fig. 1

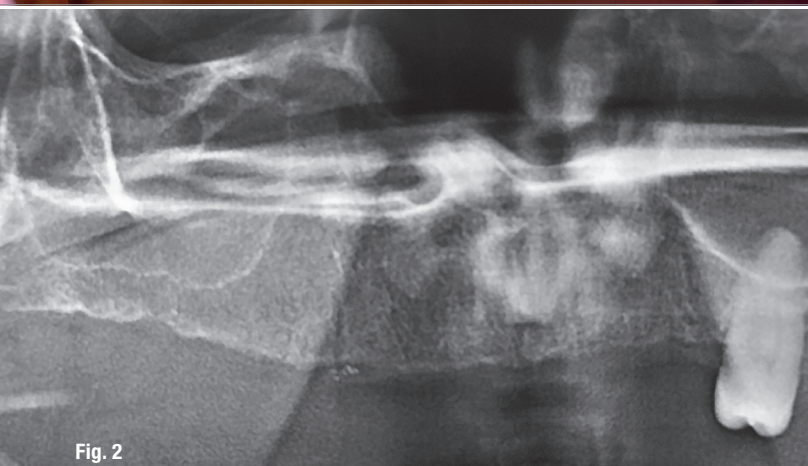

Fig. 2

Fig. 1: Clinical appearance of the amalgam tattoo at the alveolar ridge.

Fig. 2: Radiograph showing some amalgam particles at the lesion site.

Once amalgam tattoo diagnosis has been confirmed, treatment may be performed with a dental laser, surgical blade or placement of subepithelial connective tissue.^{6,7}

Case presentation

A 60-year-old female patient with a dark pigment at the edentulous alveolar ridge was referred for treatment of the lesion as a pre-prosthetic preparation procedure.

Medical history

The patient's medical history showed no systemic medical problems, no allergic reaction, no medications or recreational drugs and no history of past surgical procedures; thus, the patient did not need to be referred for medical consultation.

Dental history

Oral and maxillofacial examination of the patient revealed no temporomandibular

joint disorder or myofascial disturbances, and no functional or parafunctional habits, but poor oral hygiene and a fully edentulous maxilla.

Clinical findings

The clinical examination showed a dark pigmentation on the maxillary alveolar ridge that was firm and well demarcated and caused no pain (Fig. 1).

Radiographic examination

Radiographic examination revealed the appearance of radiopaque particles at the area of the dark pigmentation (Fig. 2).

Diagnosis

An amalgam tattoo lesion was thus diagnosed and removal by diode laser was decided on.

Amalgam tattoo removal with diode laser

After the patient had completed the consent form, the operation area was anaes-

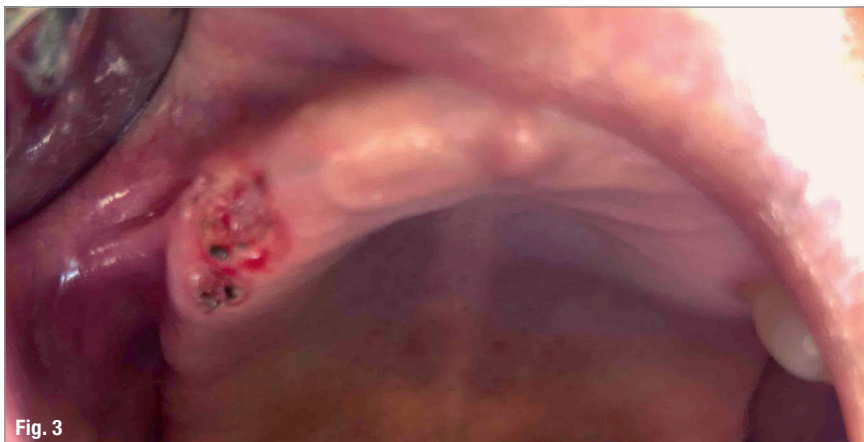


Fig. 3

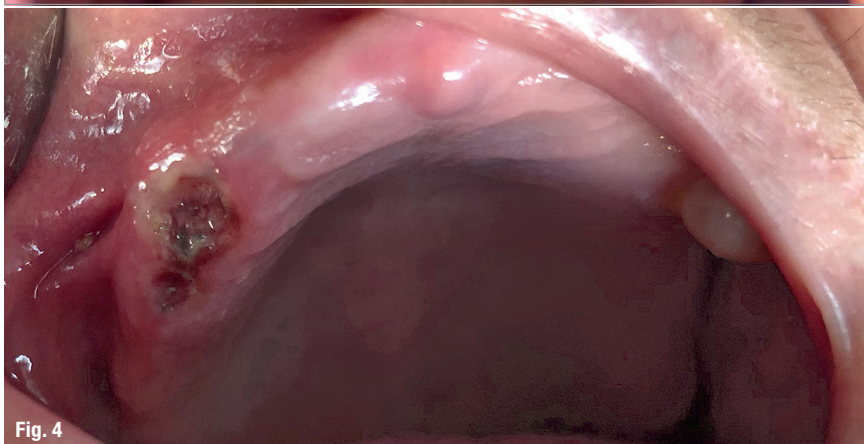


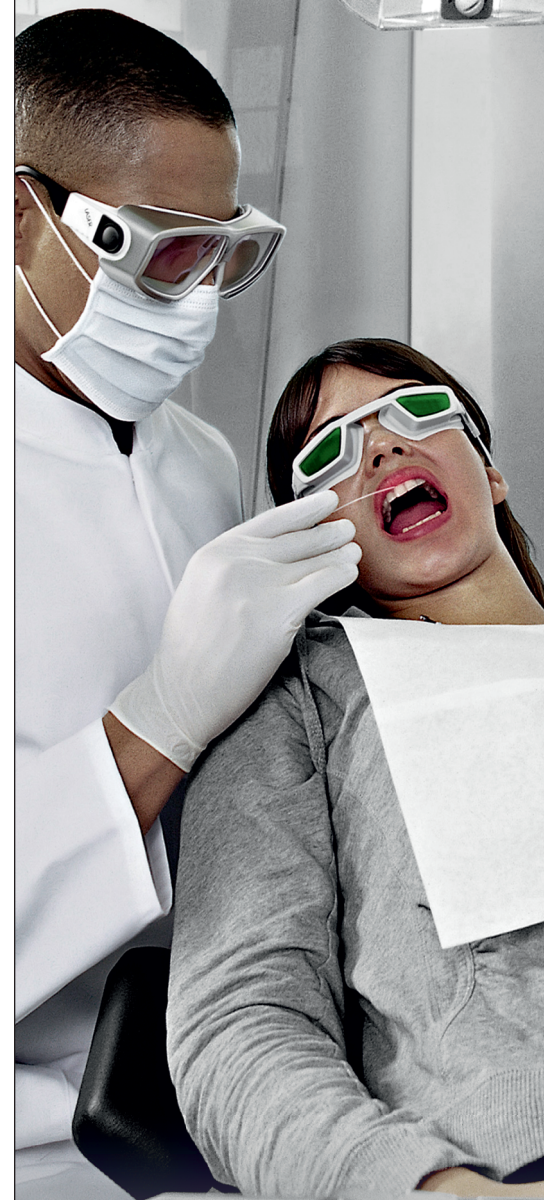
Fig. 4

Fig. 3: Situation immediately after amalgam tattoo removal. **Fig. 4:** Follow-up examination one day after amalgam tattoo removal.

laservision

shop online!

Dental Laser Protection



uvex-laservision.de

protecting people

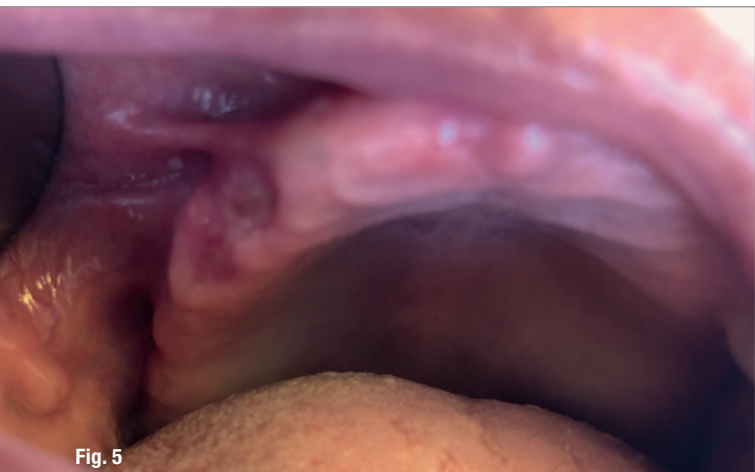

Fig. 5

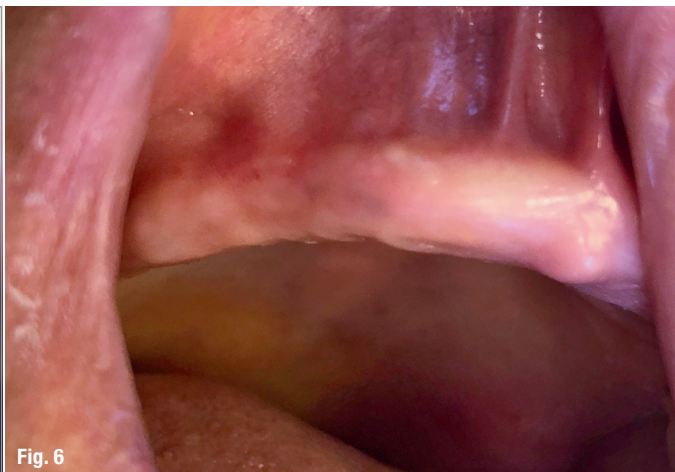

Fig. 6

Fig. 5: Situation at the one-week follow-up. **Fig. 6:** One month after amalgam tattoo removal.

thetised through infiltration with 2 % lidocaine (1:80,000 adrenaline; 1.8ml; Darou Pakhsh Pharmaceutical).

In the next step, the controlled area was defined and laser warning signs were properly displayed to secure the operating room. After the eye protection of the patient, the patient's guardian and the assistant had been checked, the patient information (examination sheet and radiograph, consent form, etc.) was reviewed.

Mouth rinsing was done with a 0.2 % chlorhexidine oral rinse (Shahre Daru Laboratories) for about one minute. Subsequently, the amalgam tattoo was removed with a high-power diode laser (Gigaa Laser). The laser parameters applied for the amalgam tattoo removal were as follows: wavelength of 980 nm, power of 1.5W, fibre of 400 μ , initiated fibre, continuous wave and contact mode. The laser settings were registered in the patient documents.

Post-procedural education

The patient was advised on keeping the area clean, avoiding food and liquids that might have caused pain or irritation of the sensitive tissue, and taking over-the-counter analgesics as needed.

Final result

Excellent amalgam tattoo removal treatment was achieved with no bleeding, carbonisation or char. The patient did not experience any discomfort and was satisfied. The amalgam particles were removed after the soft-tissue removal (Fig. 3).

Follow-up

The first visit after treatment was scheduled for one day after the procedure (Fig. 4). The healing process was found to be as expected, with healing progressing well and without any swelling or pain. The next visit was planned for one week later (Fig. 5). Finally, at the one-

month follow-up, a successful treatment could be clinically observed (Fig. 6).

Discussion

Diode lasers are used extensively in many dental practices.⁸ Laser-tissue interaction with high-power diode lasers is based on photothermal effects.⁹ Q-switched alexandrite (755 nm), diode (980 nm) and Er,Cr:YSGG (2,780 nm) lasers have been used for amalgam removal.^{10–12}

In comparison with conventional excisional biopsy procedures (scalpel and suturing), laser-assisted amalgam tattoo removal can be performed very quickly, with no bleeding, little or no pain, less or no oedema, and a reduced or no need for analgesics. Owing to the closeness of the lesion to the alveolar bone and the prevention of heat transfer to the alveolar bone, this procedure is traditionally classified as an advanced laser procedure.

Conclusion


The application of a diode laser according to the laser protocol used in this case example proved to be a successful treatment choice for amalgam tattoo removal.

contact

Dr Masoud Shabani

Department of Community Dentistry
School of Dentistry
Ardabil University of Medical Sciences
Ardabil, Iran
m.shabani@arums.ac.ir

Author details



HEILEN MIT DER KRAFT DES LICHTS

LASER EINFACH, SICHER & SANFT

A.R.C.
LASER

Fotona
choose perfection

www.henryschein-dental.de



HENRY SCHEIN DENTAL – IHR PARTNER IN DER LASERZAHNHEILKUNDE

Wir bieten Ihnen ein breites und exklusives Sortiment marktführender Lasermodele verschiedener Hersteller an.

Unsere Laserspezialisten beraten Sie gern über die vielfältigen Möglichkeiten und das für Sie individuell am besten geeignete System.

Laser ist nicht gleich Laser und genau hier liegt bei uns der Unterschied:

Sie, Ihre Patienten und Ihre gemeinsamen Bedürfnisse stehen bei uns an erster Stelle.

Bei Henry Schein profitieren Sie vom Laserausbildungskonzept!

Von der Grundlagenvermittlung über hochqualifizierte Praxistrainings und Workshops zu allen Wellenlängen bis hin zu Laseranwendertreffen.

Unsere Laser-Spezialisten in Ihrer Nähe beraten Sie gerne.

FreeTel: 0800-1400044 oder FreeFax: 08000-404444

Erfolg verbindet.

 **HENRY SCHEIN®**
DENTAL