




implants

international magazine of oral implantology

1 2010



| **case report**

Dental Implants—Treatment options for compromised clinical situations

| **case report**

Safe and effective alternatives to sinus elevation in the atrophic posterior maxilla



| **meetings**

7th Conference of the Australasian Osseointegration Society



80 Ncm

Powerful for surgery



The new Elcomed from W&H: logical and easy to use. Uncompromising in performance: with a torque of up to 80 Ncm on the rotating instrument, the surgical drive unit guarantees smooth usage, which can be completely documented at no further cost thanks to an integrated USB interface. These are just three of the many advantages of the new W&H Elcomed.

wh.com

elcomed
Captivation and precision

Dear Colleagues,



Dr Friedhelm Heinemann

The new year has just begun, and will be characterized by very special challenges. One thing is already certain—not all economic problems caused by the banking crisis will be solved in 2010. Many large-scaled problems need to be solved in respect to general economic conditions, and also in regard to health policy. Since it is a mostly privately financed treatment, even implantology, is a focal point. However, with the integration of implantological treatment in your practice's portfolio, you have already established an important basis for your existence.

Even so, implantologically active dentists must concentrate on concepts and strategies for further development of their "dental practice business" in the future. At the moment, industry is setting a new technological course, which is of crucial importance for long-term developments in dentistry in general, and implantology in particular. Through linkages in 3-D diagnosis, navigation, planning, and even CAD/CAM manufactured prostheses, opportunities are constantly growing emerging in the field of prosthetic implantology; implying a redefinition of the cooperation between dentist and dental technician.

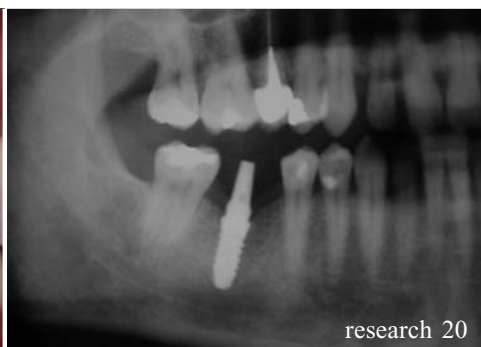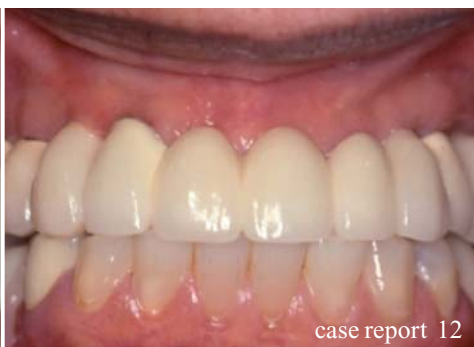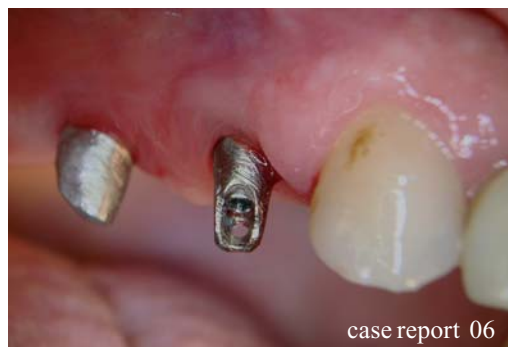The occupational image of dental technicians has been changing and extending for quite some time, due to the digital capabilities of technicians, and a growing number of dental laboratories that realize the great opportunity in their skills. In this context, dental technicians increasingly consider themselves to be digital service providers for dentists. Technicians invest in techniques and offer new cooperation platforms, which broadens and improves already established procedures. These make them into competent and professional partners for dentists, especially when it comes to finding complex restoration alternatives in implantology and implant prosthetics. In addition, technicians support dentists in diagnosis and in the course of treatment. This intensive cooperation between dentist and his local dental technician leads to high esteem, and recommendation of the patients.

One prerequisite for taking advantage of technicians' services, however, is for dentists to be in a position and willing to accept the offered service, and integrate it into everyday practice. Thus, the implantologist must face the applicabilities and the limits of planning systems, and learn to make practical use of them. Nevertheless, it is the treating dentist who is responsible to the patient, even with regard to applied digital techniques. The dentist will have to combine his operative expertise, practical skills and medical knowledge and add modern techniques to his work. This will make his work become much more complex but more interesting at the same time.

DGZI's infrastructure, with its multiple possibilities for professional training in this field is well prepared to address this emerging situation, and we will continue to expand our programs to help meet members' needs.

Yours,

Dr Friedhelm Heinemann



| editorial

03 Dear **Colleagues**
| Dr Friedhelm Heinemann

| case report

06 Safe and effective alternatives to **sinus elevation** in the atrophic posterior maxilla—Part II
| Dr Adel A. Chidiac

12 **Dental implants**—Treatment options for compromised clinical situations—Part II
| Suheil M. Boutros

16 The treatment of **toothless jaws**
| Dr Sven Rinke

| research

20 The concept of **“platform switching”** in implants dentistry—Part I
| Virgil Koszegi Stoianov

| user report

26 Cross-linked or natural collagen **membrane?**
| Dr Heike Wanner

28 **Buccal dehiscence and sinus lift cases**
| Dr Sérgio Alexandre Gehrke & Dr Giuseppe Maria Famà

| feature

32 **“Patients’ satisfaction** towards functional Reconstruction is very high”
| Daniel Zimmermann

34 **Filipino specialists back up plans for improved implant education**

34 **CEREC 25th Anniversary Celebration** in Las Vegas

| meetings

36 **7th Conference of the Australasian Osseointegration Society**
| Dr Rolf Vollmer & Dr Mazen Tamimi

38 **ITI World Symposium 2010**

40 **International events 2010/2011**

| news

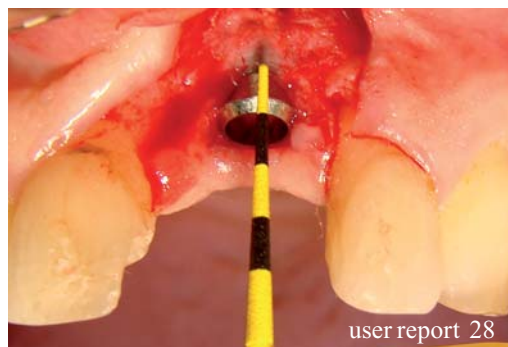
42 **Congratulations and Happy Birthday** to all DGZI-members around the world

44 **Manufacturer news**

| about the publisher

49 | submission guidelines

50 | imprint



NobelReplace™

The world's most used implant system.*

Internal tri-channel connection for accurate and secure prosthetic restorations.

TiUnite® surface and Groovy™ to enhance osseointegration.

Implant design that replicates the shape of natural tooth roots.



Color-coded system for accurate and fast component identification and ease of use.

Color-coding: step-by-step drilling protocol for predictable surgical procedures.

10 YEARS WITH
TIUNITE® SURFACE
New data confirm
long-term stability.

* Source: Millennium Research Group

Versatility, ease-of-use and predictability have made NobelReplace Tapered the most widely used implant design in the world.* NobelReplace Tapered is a general use, two-piece implant system that performs both in soft and hard bone, one- and two-stage surgical procedures, while consistently delivering

optimal initial stability. NobelReplace Tapered is a system that grows to meet the surgical and restorative needs of clinicians and their patients – from single-tooth restorations to more advanced multi-unit solutions. Whether clinicians are just starting or are experienced implant users, they will benefit from a system that

is unique in flexibility and breadth of application. Nobel Biocare is the world leader in innovative and evidence-based dental solutions. For more information, visit our website.

www.nobelbiocare.com

Safe and effective alternatives to sinus elevation in the atrophic posterior maxilla

Part II—A master thesis

Author_Dr Adel A Chidiac, Kuwait

Fig. 1 _Diagram of implant insertion in the maxilla.
 a_Conventional straight vertical position
 b_Mesio-distal angulations of the implants permitting longer implants posterior as well as better distal support of the denture.

Fig. 2 _Sagittal cross-section reconstructed perpendicular to the alveolar crest. From the 4-mm level (1), the distance to the bottom of the maxillary sinus and the nasal cavity (2) can be determined.

Fig. 3 _Presurgical radiography.

_Maxillary sinus elevation and bone augmentation are acceptable techniques that may provide sufficient bone quantity and quality for implant support in the posterior atrophic maxilla (Wallace SS et al. 2003). Yet, given the morbidity risk plus cost and time consuming effects, these techniques are to be reconsidered. Simpler and safer protocols are therefore required for the posterior maxilla where bone resorption, deficient posterior alveolar ridge, and increased pneumatization of the sinus all result in a minimal hard tissue bed thus render implant placement difficult (Frank R et al. 2005).

Part I of this publication reported about the aim of the master thesis and materials and methods. Part II follows up with the surgical techniques, dis-

cussion and conclusions avoiding a sinus lift procedure.

_Surgical techniques

Tilted implants

The standard procedure is to install the implant, totally covered with bone, in a vertical position. This requires the bone volume in the maxillary alveolar crest to be at least 10 mm vertically and 4 mm horizontally. The success rates of implant treatments as per such procedure are 95 to 99 % (Triplett RG et al. 2000). In case of less bone volume, bone grafting is one of several procedures to reach the required bone volume. An alternative, however, was presented for severely resorbed alveolar crest (CI IV, V) in which im-

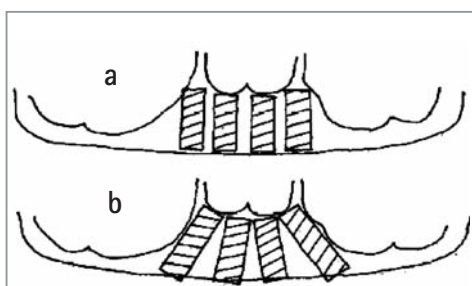


Fig. 1

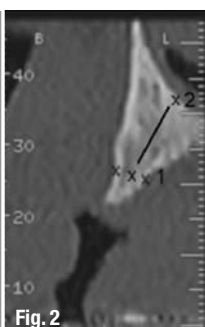


Fig. 2

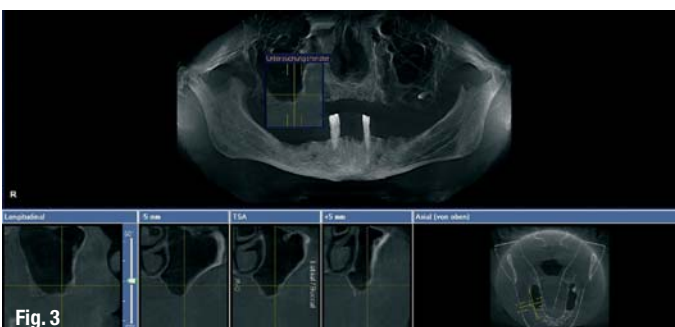


Fig. 3




Fig. 4a

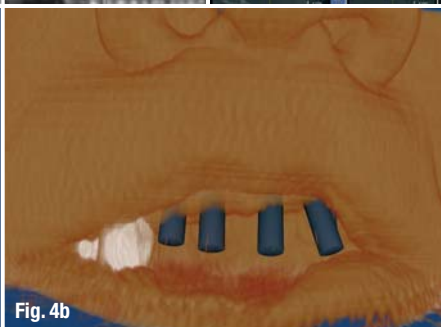


Fig. 4b

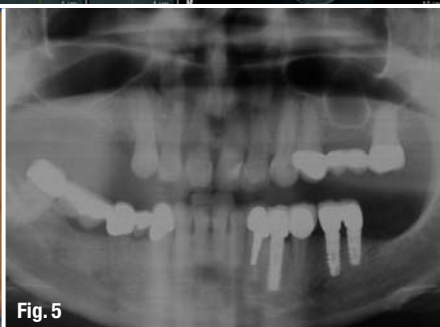


Fig. 5

plants were placed without bone grafting (Mattsson T et al. 1999). Theoretically, tilted implants in the residual crestal bone lead to (Aparicio et al. 2001):

- (a) Placement of longer implants that increases implant-to-bone contact area and implant primary stability;
- (b) Longer distance between implants that allows the elimination of cantilevers in the prosthesis thus improving load distribution;
- (c) Placement of implants in residual bone that avoids further complex techniques such as sinus lifting or bone grafting.

Clinically, the anatomy of the bone within the margins of the nasal cavity, the maxillary sinuses, and the alveolar crest margin all allow alternative mesio-distal angulations of implants. The height at the 4 mm width of an alveolar crest, being the measure to describe the available bone volume for total coverage of the implant, is often not enough for implant installation in severely resorbed maxillae.

Mesio-distal angulations of the implant thus provides better primary stability than conventional straight vertical positioning as it permits the use of a longer implant. A surgical technique was developed to make use of the maximum amount of available bone and to allow the installation of longer implants as indicated from computed tomography parasagittal reconstructions (Fig. 1; Mattsson T et al. 1999).

Mattsson et al. described a surgical technique to visualize the total amount of maxillary bone and to place posterior implants at a more than 30 degree

angle to the horizontal plane. By this technique the fixed bridge can be extended to at least the first molar position without previous bone grafting.

Presurgical examinations include a panoramic radiograph. Yet, in most cases, the extension of the maxillary sinus or the nasal cavity and the volume and density of the remaining bone are evaluated by maxillary computed tomography (Fig. 2). The estimation of bone quantity and bone quality is based on presurgical radiography and computer aided planning (Figs. 3 & 4) as well as on the resistance of bone to drilling during surgery (Kerkmanov et al. 2000).

Significantly, tilted implants can be anchored in the bone pyramid anterior to the maxillary sinus where anatomic vital structures, such as arteries or nerves, are absent. Multiunit implantation thus allows the extension of prosthetic support posteriorly and reduces cantilever arms. The results of biomechanical analyses and animal study indicate that tilting implants has no adverse effect on bone resorption (Gotfredsen K et al. 2001).

This alternative is in fact less time-consuming for the patient and the dentist; scientific investigations support the concept of immediate and early function as a modern therapeutic option (Testori T et al. 2004). Table 1 shows different degrees of angulations

Number of implants per angulation		
Inclination	15-30°	>30°
Mesiodistal	0	23
Distomesial	4	0

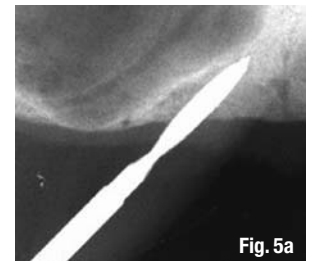


Fig. 4a_Presurgical computer aided planning (IMPLA 3D).

Fig. 4b_Presurgical soft tissue appearance (IMPLA 3D).

Fig. 5_Situation pre operation (Courtesy Dr R. & M. Vollmer).

Fig. 5a_Drilling of the titled implant site. Placing mesial axial implants before tilted ones. Intraoperative radiographs or navigation are necessary to assess the precise drilling direction.

Fig. 5b_After the pilot drilling for the titled implant osteotomes are used for enlargement and final preparation of the implant site. First the axial implant was inserted.

Fig. 5c_Tilted implant insertion following the direction of the initial hole.

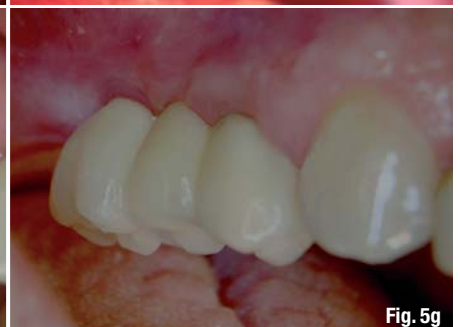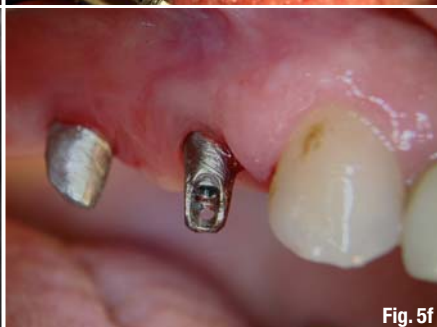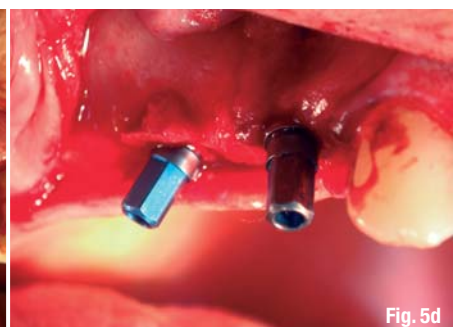
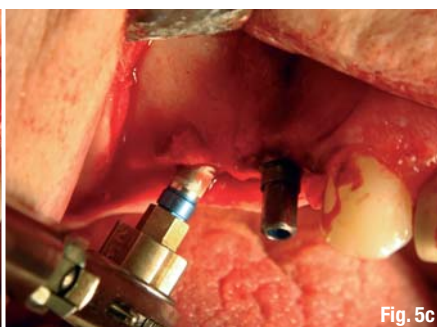
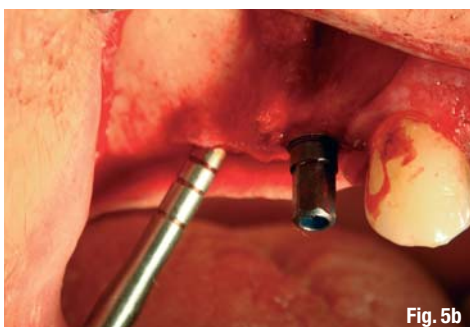
Fig. 5d_Tilted implant in site.

Fig. 5e_Radiograph after insertion.

Fig. 5f_Exposure and insertion of the abutments.

Fig. 5g_Final result.

Table 1_Degrees of angulations of tilted implants.



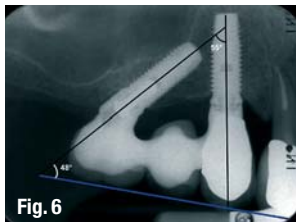


Fig. 6 Surgical placement of an axial implant following the anterior wall of the maxillary sinus is shown. The mesial axial implant will be the guide for the orientation of the tilted implant.

Fig. 7 Implant inserted in the tuberosity.

Fig. 8 Situation pre surgery with a small sinus situation.

Fig. 9 Osteotomes.

Fig. 10 Modified osteotomes (Zepf) for bone harvesting and condensing.

Fig. 11a Insertion of modified osteotomes (Zepf acc. to Vollmer and Valentin).

Fig. 11b Implants in site (IMPLA 3D, Schütz).

Fig. 11c Fixation of the angulated abutment.

of tilted implants. Figure 5 (Vollmer R et al. 2008, Candiello R et al. 2005), and Figure 6 illustrate the insertion of tilted implants (Aparicio C et al. 2001).

Tuberosity implants

Recently the maxillary tuberosity region has been increasingly utilized in preprosthetic implantation surgery especially when sinus floor elevation and bone grafting are rejected by patients due to high cost, longer healing time and increased risk of intra-operative complications. Implants, however, can be inserted in the maxillary tuberosity region as an alternative to sinus floor elevation (Fig. 7; Regeev E et al. 1995).

Osteotomy during the implantation in the maxillary tuberosity is most likely performed by an expansive and bone condensing technique with almost no bone removal like in the clinical case (Figs. 8 & 11a-e). Such osteotomy is certainly achieved in Type D IV bone acc. to the C. E. Misch classification in the tuberosity by avoiding drilling and thus reducing complications mainly hemorrhage from the palatine artery (Fernandez V. 1997).

Efficient in the maxillary tuberosity, Summers Osteotomes favor osseointegration by minimizing bone heating, dilating and compacting spongy bone, and maintaining the remaining maxillary bone (White GE 1993; Fig. 9). Summers osteotomes were modified to improve the access in the challenging areas through a double shaft design involving less pressure and less tension on the labial commissural. These modified

osteotomes allow obtaining best handling of the implant receiving site (Fig. 10; Valentin, Vollmer & Vollmer, 2002). Figures 11a-e demonstrate the final clinical case (Courtesy of Dr R. Vollmer & Dr M. Vollmer and Dr R. Valentin).

Disk implants

Disk Implant or basal osseointegrated implant can be installed where the vertical bone supply is reduced. This applies to the posterior areas of the maxilla (Ihde S et al. 2004). The insertion of the disk-design implant is laterally performed. The technique is less invasive than bone grafting and allows a tricortical or multicortical anchorage (Bocklage R. 2001).



Fig. 10

_Discussion

Short implants

Implantation in the atrophic posterior area of the maxilla is a challenge. The placement of short implants in this area is yet another alternative to sinus elevation and bone augmentation. The use of short implants (10 mm) has been a source of debate in the past decade. Some studies report higher failure rates with short implants; others report comparable results to longer implants (Buser D et al. 2000). Frequently affected by minimized bone volume, edentulous sites in the posterior maxilla prevent the placement of 10 mm implants without sinus augmentation. If shorter implants are used nevertheless, the need for more extensive sinus floor elevation is diminished and both treatment duration and morbidity are reduced (Toffler M. 2006).

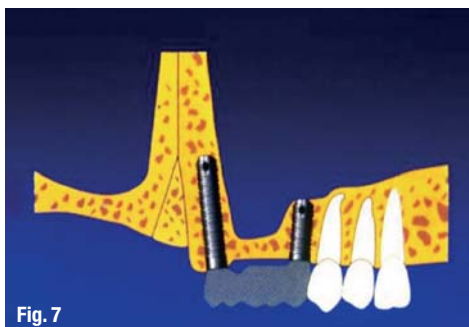


Fig. 7

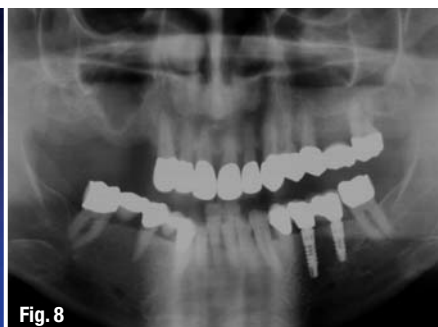

Fig. 8



Fig. 9

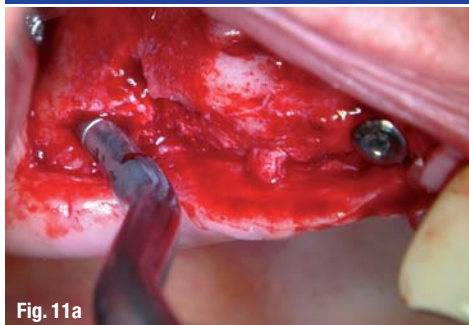


Fig. 11a

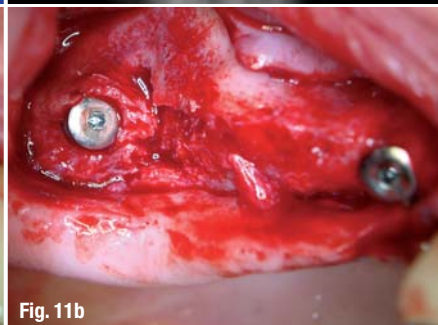


Fig. 11b

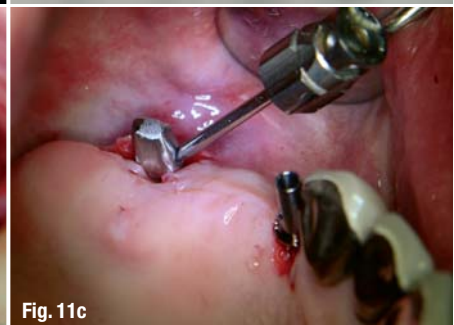

Fig. 11c

cosmetic

dentistry _ beauty & science

With the reduced amounts of bone, the use of long implants would be a difficult option. Although several studies in the literature have shown that short implants have risk factors therefore higher failure rate (Winkler S et al. 2005), the recent studies prove the good long term prognosis of short implants (Tawil G et al. 2006).

A review of the results displayed above show a range of success between 92% and 96% approximately. Failure rates were minimized by using the short implants due to several variables, including among others, change in implant design, splinting implants together, absence of cantilevers in the prosthesis, and additional methods to decrease stress to the implant interface. According to the same results, it is possible to use short implants to support fixed restorations in the atrophic posterior maxilla (Misch et al. 2006).

Implant sizes did not appear to compromise the effectiveness (Romeo E et al. 2006), and the short length was not associated with reduced survival rates (Arlin ML 2006). Researchers using finite elemental analysis (FEA) demonstrated that vertical and horizontal occlusal forces placed on implants were distributed primarily in the crestal bone rather than along the implant/bone interface. The group of Lum concludes that short implants serve as well as longer ones. Short implants show a survival rate exceeding five years and crestal bone level maintenance similar to longer implants. They can be successfully used in maxilla with limited bone length (Venuelo C et al. 2008).

Tilted implants

The results of applying the technique of using posterior tilted implants are comparable with the more resource demanding techniques applying bone grafting which often necessitates general anesthesia and hospitalization and could often lead to the following implications, including but not limited to, postoperative infection problems with the graft or maxillary sinusitis, host morbidity, lower implant success rates, and higher cost of treatment (Yerit KC et al. 2004). In fact, by tilting the posterior implants in the maxilla, the compromised bone of the sinus antrum could be circumvented with the clinical advantage of avoiding cantilever arms and using fewer implants (Calandriello R et al. 2005).

Mattsson et al. were the first to report well functioning fixed prostheses with no symptoms after treatment with the tilted implant technique (Annika R et al 2007). The success rate for the patients included in the study was 97%. Krekmanov et al also demonstrate that biomechanical measurements in tilting implants showed no negative effects on load



One issue free of charge!



Subscribe now!

*Prices include shipping and VAT

- I hereby agree to receive a free trial subscription of **cosmetic dentistry** (4 issues per year). I would like to subscribe to **cosmetic dentistry** for € 44* for German customers, € 46* for customers outside Germany, unless a written cancellation is sent within 14 days of the receipt of the trial subscription. The subscription will be renewed automatically every year until a written cancellation is sent to OEMUS MEDIA AG, Holbeinstr. 29, 04229 Leipzig, Germany, six weeks prior to the renewal date.

▶ **Reply** per Fax +49-(0) 3 41/4 84 74-2 90 to OEMUS MEDIA AG or per E-mail to grasse@oemus-media.de

IM 1/10

Last Name, First Name

Company

Street

ZIP/City/Country

E-mail

Signature

Notice of revocation: I am able to revoke the subscription within 14 days after my order by sending a written cancellation to OEMUS MEDIA AG, Holbeinstr. 29, 04229 Leipzig, Germany.

Signature

OEMUS MEDIA AG Holbeinstr. 29, 04229 Leipzig, Germany

Tel.: +49-(0) 3 41/4 84 74-0, Fax: +49-(0) 3 41/4 84 74-2 90, E-Mail: grasse@oemus-media.de



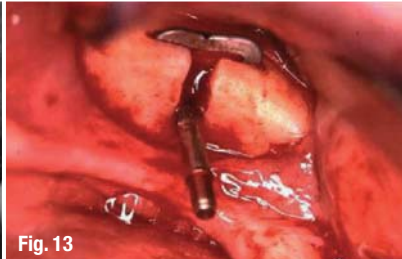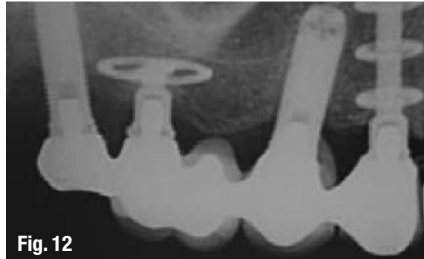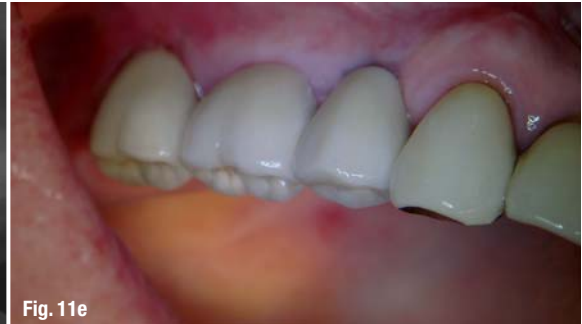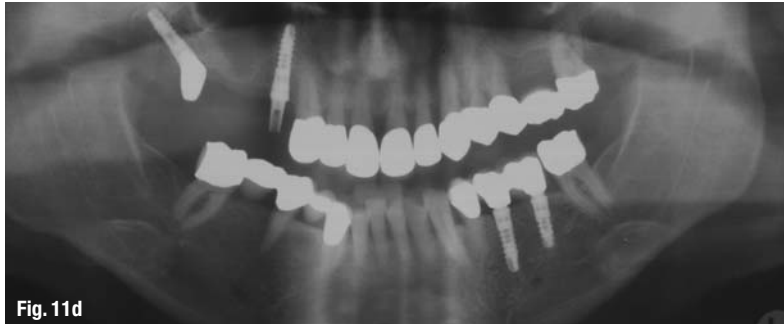


Fig. 11d_Situation post surgery. Perfect seating of the individually casted angulated abutment.

Fig. 11e_Final prosthetics.

Fig. 12_Disk Implant X-Ray.

(Martin Schweppe 2007 Wikipedia).

Fig. 13_Lateral insertion of a disk implant.

distribution in fixed prosthetic constructions. The different follow up studies prove that patients with severely resorbed maxillae can be treated successfully with conventional implant treatment (Kerkmanow L et al. 2000).

Relatively easy to be applied, the implant tilting technique decreases the treatment time compared with bone grafting and more extensive procedures such as zygoma implants. The need for other more resource demanding techniques is sometimes overestimated. However, bone augmentation may be still necessary in case bone volume is severely limited (Annika R et al. 2007).

Tuberosity implants

The few studies on implantation in the tuberosity show high percentage of success rate on condition that strict protocols and careful handling are applied to preserve the soft bone in this area (Venturelli A 1996). In combination with tilting the implants the indications for this therapy concept even increase.

Disk implants

Despite the shortage of clinical studies in the literature, the use of disk implant may be an alternative to bone augmentation in both moderately and severely resorbed posterior maxillae. The initial multicortical anchorage provided by the disk-design implant, coupled with biomechanical splinting through a rigid prosthesis, permits a one stage predictable alternative offering rapid restoration of masticatory function (Scortecchi G 1999).

_ Conclusion

The thesis highlights alternatives to sinus elevation and bone augmentation in the atrophic poste-

rior maxilla. These alternatives prove to be (a) safer than, and (b) as effective as, maxillary sinus elevation and bone augmentation techniques. The overall results show high rate of success: 90 % and above.

Short implants, tilted implants and tuberosity implants involve mainly less morbidity and less invasive surgeries. Patients are likely to be less reluctant compared to sinus elevation and bone grafting. Disk implants are worth considering despite the more invasive procedure and the shortage of high level evidence based studies. Further data, however, are required to elaborate on the safety and effectiveness of this alternative.

Recently practiced, the three dimensional implant planning software for computed tomographic (CT) scan (e.g. Schütz IMPLA-3D Navigation; Merli M et al. 2008) is becoming of benefit as it may help evaluate the exact remaining bone in the maxilla. Such planning allows the application of the most convenient implant like fshort implant, tilted implant or tuberosity implant or a combination of both. Interestingly, to avoid a sinus elevation and bone augmentation to the most possible, the examined alternatives in this thesis may be applied in sole or in either combination to rehabilitate the posterior atrophic maxilla.

I would like to thank:

Prof. Nabil Barakat , Lebanese University, Beirut, Lebanon; Dr. Mazen Tamimi, Private Practice, Amman, Jordan; Dr. Rainer Valentin, Private practice, Cologne, Germany; Dr. R. & M. Vollmer, Private practices, Wissen, Germany, for their support.

Editorial note: The literature list can be requested from the author.

_contact	implants
<p>Dr Adel Chidiac International Clinic P.O. Box 6649 Salmiya 22077 Kuwait E-Mail: adelchidiac10@hotmail.com</p>	



SIMPLY BETTER

STRAUMANN® SLActive

Straumann® SLActive – The next generation in surface technology

- Higher security and faster osseointegration for every indication
- Reduced healing times from 6–8 weeks down to 3–4 weeks
- Increased treatment predictability in critical protocols

Please contact us at **+41 (0)61 965 1111** More information on **www.straumann.com**



Straumann® SLActive
... over 1 million implants sold!

Based on the following studies: preclinical: Buser et al. (2004), Schwarz et al. (2006/2007) clinical: Zöllner et al. (2007), Oates et al. (2007) internal data on file

COMMITTED TO
SIMPLY DOING MORE
FOR DENTAL PROFESSIONALS

Dental implants—Treatment options for compromised clinical situations

Part II—The edentulous maxilla

Author_Suheil M. Boutros, USA

Abstract

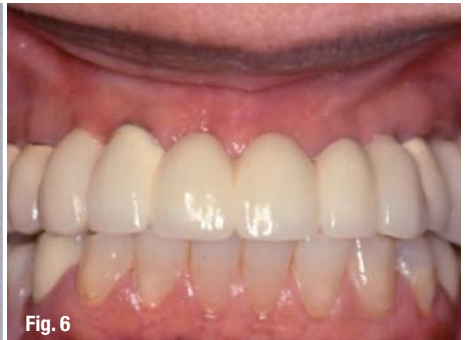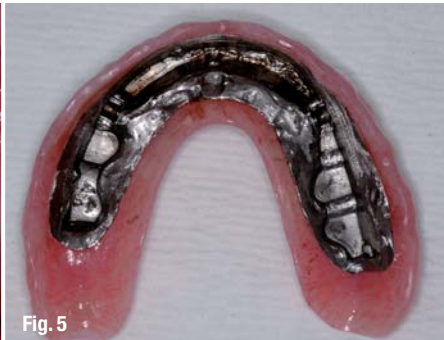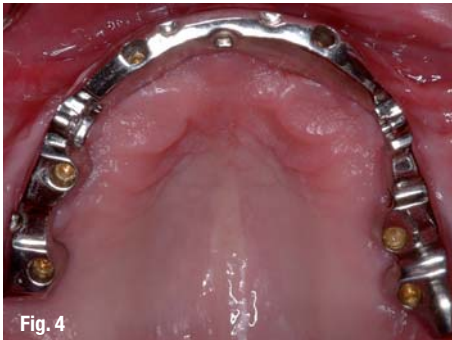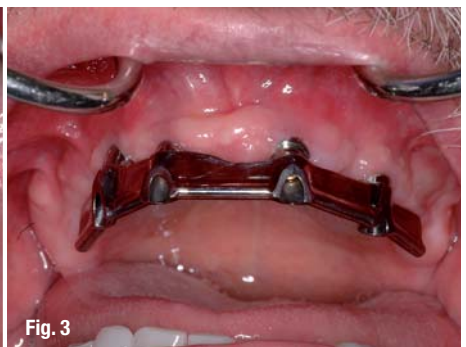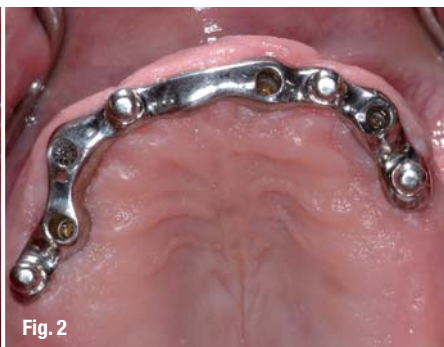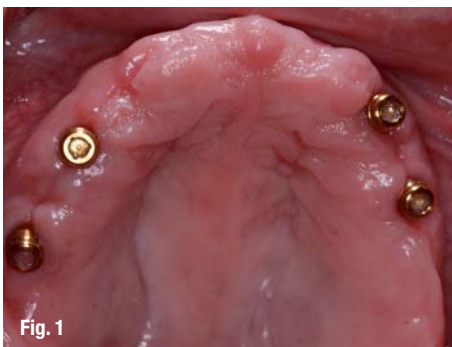Implant-supported therapy for the patient with an edentulous maxilla is dependent on several treatment planning issues. The factors that determine the choice of treatment include the following:

- _The general health of the patient.
- _The goals of the patient, such as the need for removal of the palatal portion of the prosthesis, increased stability when chewing, or the desire for a fixed prosthesis.
- _The aesthetic requirements of using acrylic to restore the soft tissue profile of the patient.

- _Availability of bone in the anterior and posterior maxilla.
- _Financial considerations.
- _Consent for bone grafting deficient sites, including considerations of bone harvest site morbidity.

Treatment planning is usually initiated at the restorative dentist's office. This includes establishing the patient's goals for the outcome he or she desires at the completion of implant therapy. Once these goals are set, the surgeon is seen and an assessment of bone availability is performed. After the amount of bone needed is determined, with

- Fig. 1 Locators supported upper overdenture.
- Fig. 2 Casted bar supporting maxillary upper removable partial denture.
- Fig. 3 Titanium-milled bar.
- Fig. 4 Spark erosion milled bar.
- Fig. 5 Overdenture with a bilateral swivel.
- Fig. 6 Full upper fixed crown and bridge.



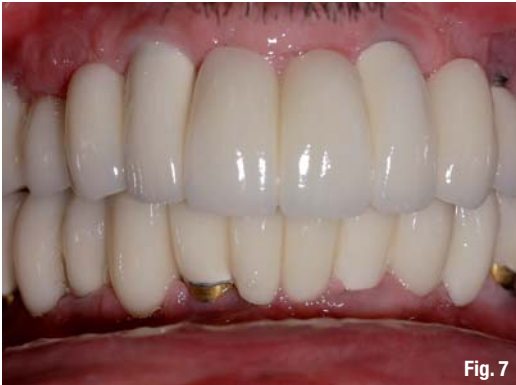

Fig. 7

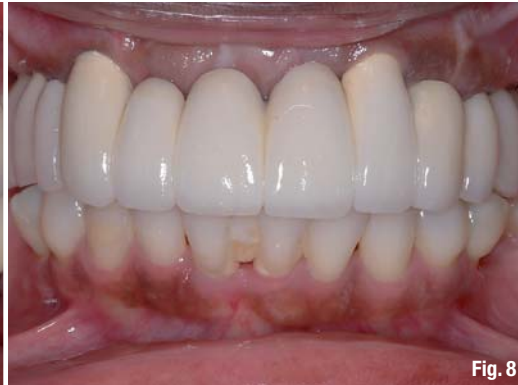

Fig. 8

Fig. 7_Upper and lower fixed crown and bridge.

Fig. 8_Upper fixed restoration.

the aid of the restorative dentist, a prosthetic plan is completed.

Parel's classification of the edentulous maxilla is useful for conceptualization of the prosthetic plan.

- 1) Class I maxilla is the patient who seems to be missing only the maxillary teeth, but has retained the alveolar bone almost to its original level.
- 2) Class II maxilla has lost the teeth and some of the alveolar bone.
- 3) Class III maxilla has lost the teeth and most of the alveolar bone to the basal level.

For the Class I, a fixed restoration, borne by implants, can be fabricated because the patient has adequate alveolar bone for support of the soft tissue and is missing only teeth. There is usually greater than 10 mm of bone height for both the anterior and posterior maxilla. For a fixed crown and bridge-type restoration, implants need to be placed within the confines of the teeth of the planned restoration.

The Class II patient is rarely aesthetically managed with a fixed crown and bridge prosthesis because they require the labial flange of the maxillary prosthesis to support the nasal-labial soft tissue.

A fixed crown and bridge, fixed/removable (spark erosion or milled prosthesis), or removable overdenture type prosthesis require at least 6–8 implants to adequately support a maxillary implant-borne prosthesis. The removable prosthesis requires placement of four implants placed into the anterior the anterior placement to support a bar, which has retentive vertical stress breaking attachments.

The prosthesis for the edentulous maxilla is usually fabricated with cross arch stabilization of the left and right implant.

_Four implants (tissue-borne prosthesis)

For an upper implant supported removable overdenture, a minimum of four implants are needed. Generally, when placing four implants for an overdenture, consideration should be given to the potential need for additional implants at a later time if the patient decides to change from a tissue-borne prosthesis to an implant-supported prosthesis. In preparation for a tissue-borne prosthesis, adequate bone should be present to allow the placement of four parallel implants that will support four Zest locators and will allow perfect draw of the overdenture (Fig. 1).

_Placement of four implants into the anterior maxilla (bar-supported removable prosthesis)

For the patient with adequate anterior vertical bone height and for whom a treatment plan has been made for anterior implants for over-denture support, four implants or more should be placed since any less will not predictably resist the forces placed on them. Two implants are contraindicated to retain a maxillary over denture. The bar can be casted (Fig. 2) or a titanium-milled structure (Fig. 3).

_Placement of six to eight implants for implant-borne and supported overdenture

If the goals of the patient are to have a denture/prosthesis that is palateless and does not depend on the tissues for support, a sufficient number of implants are required to resist the forces of mastication. In such instances, it is recommended that six to eight implants be used for an implant-supported fixed/removable prosthesis with adequate number of implants located posteriorly to support the molars. Six to eight implants in the anterior and posterior maxilla are used to support a

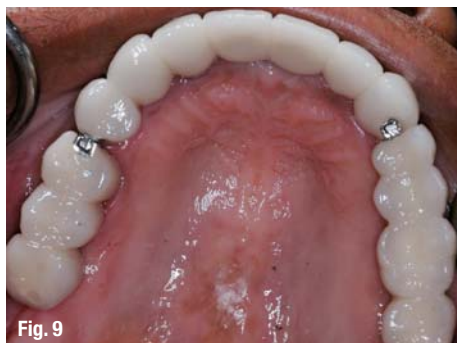

Fig. 9

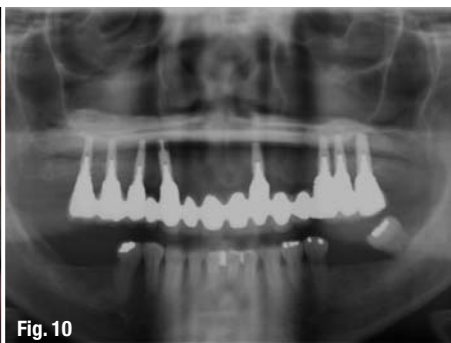

Fig. 10

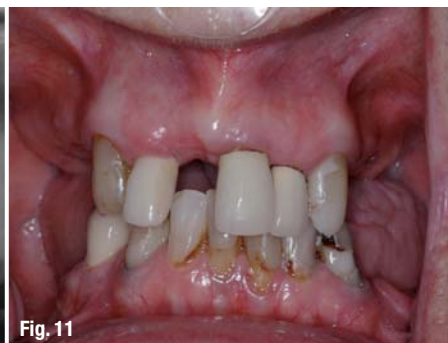

Fig. 11

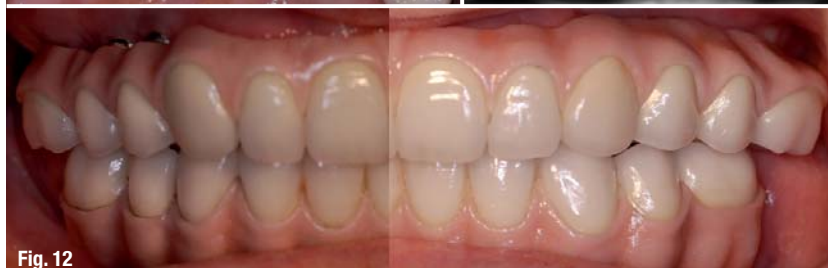

Fig. 12

Fig. 9 _Three semi-precision attachment fixed restoration.

Fig. 10 _One year follow-up.

Fig. 11 _Extremely deficient maxilla.

Fig. 12 _Final fixed restoration.

Fig. 13 _Supra-frame screw retained.

Fig. 14 _Fixed prosthesis showing great facial reconstruction.

suprastructure for a totally implant-borne restoration with tissue contact only for speech (Figs. 4 & 5).

_Fixed crown and bridge-type restoration

Six to eight implants in the anterior and posterior maxilla are used to support a suprastructure for totally implant-borne cases. Implants are placed from the canine region extending posteriorly, with a minimum number of implants placed into the incisal region. This placement pattern makes the design of the anterior portion of the prosthesis easier (Fig. 6).

_Placement of eight implants with sinus graft for a fixed crown and bridge-type restoration

These patients have had treatment planning for an implant-borne restoration (crown and bridge type), yet they had insufficient vertical bone for the placement of implants in the posterior to the ca-

nines. The sinus graft can be performed as one surgery, followed by implant placement six to eight months later (Fig. 7). Alternately, the sinus graft can be performed and the implants placed at the time of the sinus graft (Figs. 8–10).

If the soft and hard tissue is extremely deficient (Fig. 11), the lost structures can be replaced by a supra-frame that will restore the vertical dimension and the teeth can be replaced with cemented on crowns (Figs. 12–14). This type of prosthesis allows great facial reconstruction and support.

Editorial note: The literature list can be requested from the author.

_contact	implants
<p>Suheil M. Boutros DDS, MS Assistant Professor, Department of Periodontics, University of Michigan Periodontal Specialists of Grand Blanc 8185 Holly Road, Suite 19 Grand Blanc, MI 48439, USA Tel.: + 1 810 695 6444 Fax: + 1 810 695 4414 E-mail: sboutros@umich.edu</p>	

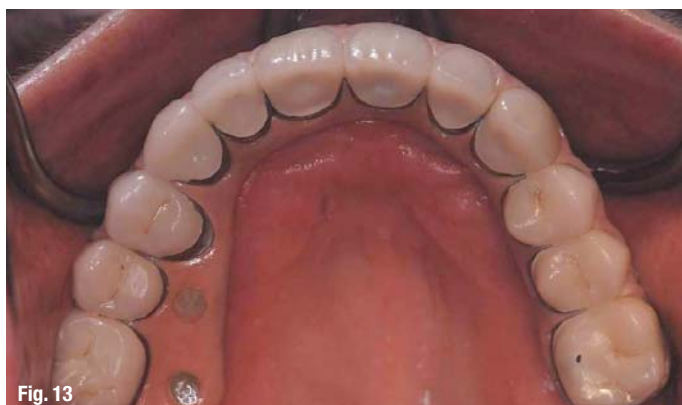

Fig. 13

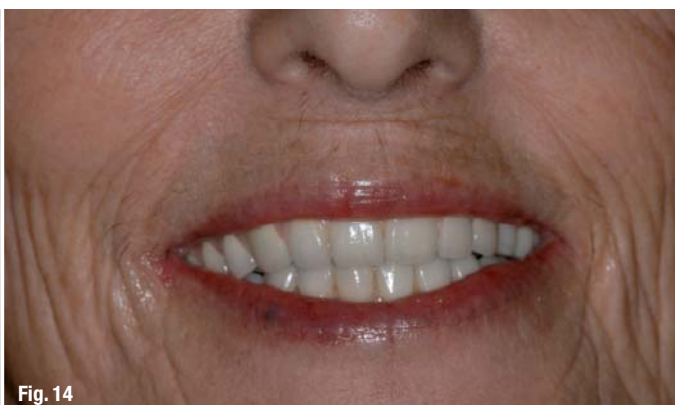

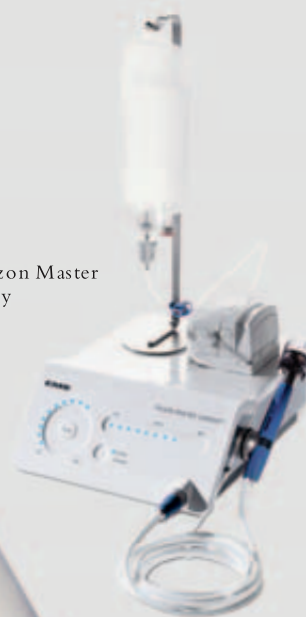Fig. 14

PIEZON-MASTER-SURGERY.COM

EMS⁺
ELECTRO MEDICAL SYSTEMS

INNOVATIVE technology, easy to operate, multiple applications, exclusive instruments, great results, extensive experience—the Original Piezon Method now also available for periodontal surgery, implantology, oral and maxillary surgery.

> Piezon Master Surgery



UNIQUE in the realm of surgery—3-touch panel for intuitive user guidance.

EXCLUSIVE design tailored to the new piezoceramic surgery hand-piece—the new Swiss Instruments Surgery.

REVOLUTIONARY in the smallest details—once you've experienced Piezon Master Surgery, you'll ask yourself: Why didn't we have this before?

PIEZON MASTER SURGERY®—
THE WORLD OF DENTAL
AND ORAL SURGERY NOW
CELEBRATES A NEW HERO

**REVOLUTION IN
YOUR HANDS**

**TOUCH
'N'
GO**

For more information,
please visit www.piezon-master-surgery.com

The treatment of toothless jaws

A case for CAD/CAM

Author_Dr Sven Rinke, Germany

Prosthetic devices can be fitted in various ways. Digital technologies have made their mark in implantology for quite a while, and they provide options for quality solutions. Classical indications for implant-prosthetic treatments include dentures for the toothless jaw. For this type of dentures, clinical studies document a high survival rate of about 85 to 90 % (Attard et al. 2004a, Attard et al. 2004b) with observation periods of up to 20 years.

According to the number of the inserted implants, various prosthetic concepts have established themselves for the fitting of supraconstructions (Zitzmann and Marinello 2002). Generally, there is either a fixed denture mounted on six to eight implants and borne by these only, or a removable denture with a reduced number of implants.

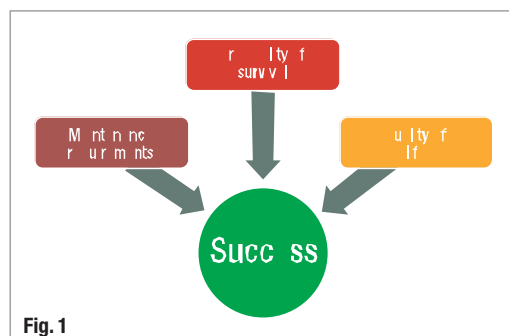
The decision process for the selection of a suitable denture depends, on the one hand, on subjective criteria (patient's expectations, financial conditions) and, on the other hand, clinical aspects (anatomic criteria, technical and clinical reliability of implants and supraconstruction). Accordingly, the success of the prosthetics depends on these factors (Fig.1):

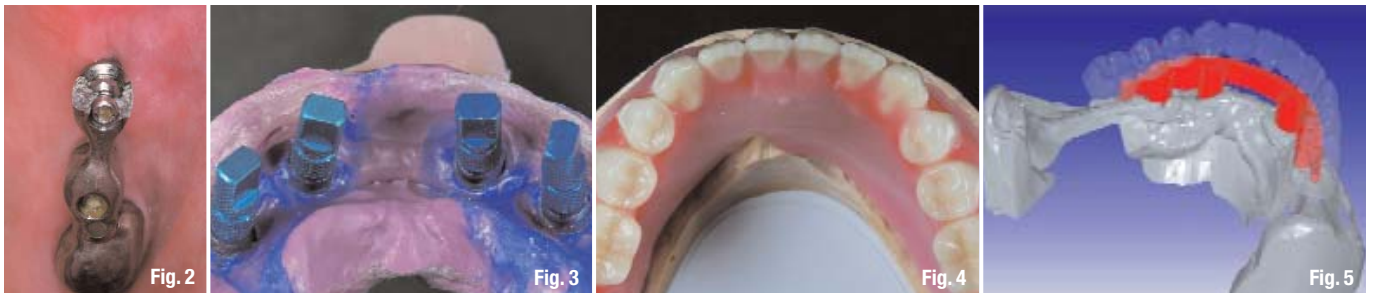- _ Subjective criteria (patient satisfaction and quality of life);
- _ Objective criteria (probability of survival); and
- _ Necessary maintenance effort during the lifetime of the denture.

Criteria for the selection of the type of denture

Fixed as well as removable implant-prosthetic dentures in the toothless jaw, as opposed to the conventional full denture, have proven to significantly increase the patients' satisfaction and to improve the ability to chew (Raghoobar et al. 2003, van der Bilt 2006). This means that already the insertion of two to four implants can lead to a clear improvement of the quality of life. Therefore, the removable implant-supported and implant-retained overdenture prosthesis is nowadays considered an effective therapy. However, there was also evidence that, in particular, the choice of fitting elements (magnets, ball-heads, bridges, telescopes) in a removable denture has an influence on patient satisfaction. A comparative crossover study has shown that, with respect to stability and retention power as well as the achievable patient satisfaction, magnets are inferior to the fitting with ball-heads (Burns et al. 1995a, Burns et al. 1995b). A comparison of ball-head elements and overdenture attachments used for the fitting of an implant-retained overdenture prosthesis did not show any differences in terms of patient satisfaction (MacEntee et al. 2005); however, there proved to be a significant difference in the rate of technical complications. Within an observation period of three years, prosthesis fitted with ball-heads required 6.7 repairs, whereas the group of bridge-fitted prosthesis required 0.8 repairs per patient only. Hence, overdenture attachments as fitting elements for removable

Fig. 1 Subjective and objective prosthetic success criterions.





supraconstructions guarantee high patient satisfaction. Thanks to their low rate of technical complications, they require less maintenance effort than alternative fitting elements (MacEntee et al. 2005), which is an important criterion for the long-term success of the prosthesis. High maintenance requirements require more practice visits and take the time of both, the patient and the care provider. Further, if there are technical complications that have led to the failure of supra construction elements, an intervention by a dental technician might be needed for the new construction or the replacement of individual components. This is also connected with further costs in order to maintain the function.

When evaluating overdenture attachment constructions as fitting means, consideration must be given to the various types and forms there are. On the one hand, there are individually shaped bar attachments, and on the other hand, there is the classic round bar, which can be manufactured either by casting or by combination of pre-fabricated elements.

The overdenture attachment sitting on four implants is a classic fitting element for a purely implant-supported coverdenture prosthesis in a toothless upper or lower jaw. A retrospective study with 51 patients compared individually shaped bar attachments and round bars for the fitting of coverdenture prostheses (Krennmair et al. 2008). 26 patients were equipped with round bars, while 25 patients received a supraconstruction with an individual bar attachment, on four implants each. After a surveillance period of five years, the survival rate of the implants was 100%. Larger technical complications, which required a renewal of the mounting elements, occurred in the round bars only, in form of fractures in the extension areas. The fractures on the extensions of the overdenture attachments, which were exposed to high mechanical stress, were due either to porosities in the cast object, or to inhomogeneities in the area of the points of attachment. Further, it was determined that low-grade complications (activation of hanks) would come up three times as often in the round bars as in the bar attachments. Basically, two causes of defects can be derived from that: Firstly, defects due to faults in the manufacturing technique (casting and joining

processes), and secondly, defect causatively connected with the design of the supra-construction.

For the fitting of attachments in the toothless upper jaw, the literature describes two versions. The fitting of attachments on four implants in the anterior segment, and the fitting of two attachments on three to four implants on the lateral segments of the toothless upper jaw (mostly after a previous sinus floor augmentation). Also for the application of attachments in the toothless upper jaw data from clinical studies have been published (Krennmair et al. 2008). Both attachment concepts featured almost identical survival rates after five years—98.4% for the attachments in the anterior segment, and 97.4% for the attachment fitting on six to eight implants in the lateral segments of the upper jaw.

In particular the fitting by bar attachments seems to be a therapy means with guaranteed success for the fitting of purely implant-supported coverdenture prosthetics in the upper and lower jaw. It excels with a low rate of technical complications and, with that, low maintenance requirements. Hence, bar attachments constitute clinically tested fitting elements for implant-retained and implant-fitted removable supraconstructions in the toothless upper and lower jaw. Clinical data for the fitting of removable supraconstructions in the toothless upper jaw are missing for magnets as well as for ball-head attachments. Also the application of so-called locators for the fitting of removable implant supraconstructions cannot be considered to be based on evidence, according to the current data provided, as no results of clinical studies have been presented by now for this fitting element.

Telescopes as fitting elements for removable supraconstructions are popular particularly in the German-speaking countries, as they are very hygienic and easy to expand. However, these advantages are opposed by the high technical requirements and costs at manufacture. Clinical studies on the suitability of double crowns as fitting elements in implant prosthetics show that they are generally suitable, and they point out the advantage of combining the natural teeth with implants for the fitting of a removable construction, as opposed to attachments.

Fig. 2 Fracture of a bar attachment construction manufactured by casting, in the area of the extension.

Fig. 3 Casting of the implants in the pick-up technique with a high-strength casting material.

Fig. 4 Tooth arrangement produced on the work model.

Fig. 5 Virtual construction of the bar attachment construction with distal attachments.

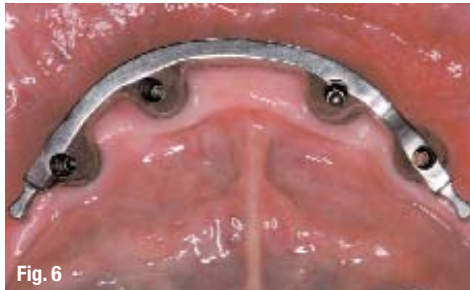

Fig. 6

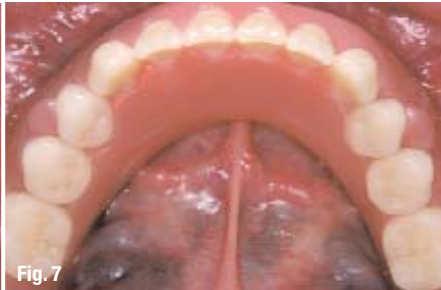

Fig. 7



Fig. 8

Fig. 6 _Compartis ISUS bar attachment made of pure titanium; the attachment could be inserted without manual after-processing.

Fig. 7 _Completed implant-retained prosthesis for the lower jaw.

Fig. 8 _Good fit with a CAD/CAM produced attachment construction made of pure titanium.

_Optimising the manufacturing technology

Despite of the high and well documented survival rates of attachment constructions, the question arises whether the strategies can be further optimised in order to avoid defects attributable to the technique. The traditional way of manufacturing attachment constructions is by casting. However, the larger the cast object, the more problems use to arise in terms of porosity and warpage which, on the one hand, increase the risk of mechanical failure and, on the other hand, impair the proper fit (Jemt et al. 1999; Fig. 2).

Relatively early, the well-known casting problems have led to the establishment of alternative techniques. The application of pre-fabricated implant components, which then were mated by means of soldering or laser welding, was one way to improve the fit; however, in particular with large constructions, this procedure has the disadvantage of very time-consuming manual post-processing. Furthermore, there is the risk that the mechanical ability to cope with pressure may be reduced in the area of the joining point.

In addition to that, from the economical point of view, it would make sense to use largely biocompatible material of sufficient mechanical strength for the manufacture, such as pure titanium or a Co-Cr alloy. However, the processing of such alternative materials does not provide a sufficiently exact fit with the current casting techniques. *In-vitro* examinations of cast implant suprastructures made of non-metallic materials showed gaps of 200 to 300 µm between the suprastructure and the implant arrangement (DeTorres et al. 2007). Compared to that, cast structures made of noble metals featured median gaps of 40 to 50 µm (Takahashi and Gunne 2003). The use of alternative materials therefore requires an alternative processing technology, and be it just to achieve the necessary precision. In the ideal case, the supraconstruction is cut from a prefabricated solid material in order to safely exclude inhomogeneities. With this thought in mind, the manufacture of supraconstructions with cutting technological means utilising the CNC process started already more than ten years ago.

In-vitro examinations with this CAM technology showed that the precision achievable in such constructions, with median gap widths between 20 and 30 µm is better than the accuracy of fit achieved with cast frames made of noble metals (Takahashi and Gunne 2003). Modern scanning and software technology allows expanding this manufacturing principle also to the area of the virtual construction. Hence, the already well-known process of CNC cutting is supplemented with the option of a purely virtual construction. Meanwhile there are several manufacturers offering this technology (e.g. Compartis ISUS of DeguDent).

_Case presentation

The manufacturing process is documented below on the example of an attachment utilising the Compartis ISUS system. After exposure of the implants, the next appointment is devoted, as usual, to making a casting with impression material which has a high final hardness and hence guarantees a secure fixing of the casting posts (e.g. Impregum, 3M ESPE, or Monopren transfer, Kettenbach Dental; Fig. 3).

In the ideal case, the casting appointment will already include the determination of the jaw relations and a casting for the model for the opposite jaw. After that, the work model is manufactured with the help of a removable gingiva mask in the area of the implants. When the first checkbite is taken, a first provisional model can be mounted straight away. Based on this working material a tooth arrangement is prepared from plastic. It is useful if the information about the colour and the shapes of the teeth is already available during this work step (Fig. 4).

The tooth arrangement can be tried on at the next appointment, and corrected if needed. So, the exact jaw relations can be determined, and sufficient information will be collected for the definitive tooth arrangement. At this appointment, also the precision of the casting should be checked with a transfer jig. For this key, the posts on the work model can be blocked with plastic and a metal reinforcement. The key must then fit onto the implants in the mouth without causing tension or shifting around. For the exact determi-

nation of the accuracy of the casting fit it makes sense to perform the so-called Scheffield test. For this test, a screw is mounted and fastened on the post on one side of the distal implant. When fastening the screw, the transfer jig must not lift off the other implants.

Further, there must not be any gaps. If the screw can be fastened without making the transfer jig move the conclusion can be drawn that the impression has exactly copied the situation in the mouth. In case that the test has a negative result a transfer defect can be assumed. In such a case, the transfer jig should be separated, and all posts should be fastened with screws, so that a new impression casting can be taken.

Once an exact impression has been secured and the tooth arrangement has been adjusted, the CAD/CAM manufacture of the supraconstruction can begin. First, the work model and the tooth arrangement are sent to a Compartis ISUS Planning Centre. There, the virtual construction of the attachment is made according to the specifications of the dentist(s) and dental technician(s). In the present case, a bar attachment construction made of titanium with distal attachments (Preci-Vertex, CEKA Germany) has been chosen. The tooth arrangement determines the space available for the supraconstruction and the alignment towards the chewing area. This information then constitutes the foundation for computer-assisted design of the supraconstruction, the CAD process. For this purpose, first, special scan posts are screwed into the implants, in order to determine the position of the implants with a first scan. Then a second scan is done with the wax arrangement, in order to determine the available space and the orientation of the supraconstruction. Then, the desired supraconstruction is designed with the help of special software. This constitutes the basis for the manufacture of the supraconstruction utilising the CNC process (Fig. 5).

Dental technicians and care providers will then receive the construction suggestion of the Compartis ISUS Planning Centre by email with the request for release or for advice of possibly required changes. As soon as the release is obtained the manufacture of the attachment begins. The Compartis ISUS system ensures, particularly by applying modern cutting machines and special cutting strategies with all the materials, a perfect quality of the surfaces which dispense with the need for manual after-processing also as far as the retaining elements are concerned (Fig. 6).

Then the dental laboratory can commence with the manufacture of the secondary construction. In the present case, first, a secondary structure was made by means of electroplating (Solaris, DeguDent), and the plastic matrix for the Preci-Vertex retaining elements was incorporated. After that, a cast tertiary

structure was made of a cobalt-chromium alloy and bonded with the galvanoplastic structure. The supraconstruction was completed using the already existing tooth arrangement. Several *in-vitro* examinations prove the excellent accuracy of fit in these CAD/CAM manufactured constructions. In a comparison of five different techniques for the manufacture of implant supraconstructions, the CAD/CAM structures showed a median accuracy of fit of 25 µm, while cast structures had median gaps of 78 µm width (Torsello et al. 2008; Fig. 7).

However, the advantage of the CAD/CAM technology is not only the highly precise manufacture of suprastructures made of pure titanium and Co-Cr alloys; there is also its applicability to a broad range of indications. Starting out from the scan data, the virtual construction allows for a wide range of variations in terms of various forms of supraconstructions, from the simple round bar to retaining element attachments or to a bridge frame for fixed constructions. With a CAD/CAM system, it is also possible to virtually incorporate active holding elements such as extra-coral retaining joints, bars and press buttons.

In summary, it can be said that the CAD/CAM technology is also ideal for the processing of alternative materials on titanium and NEM basis. It provides these advantages:

- _ High mechanical resilience thanks to homogeneous pore-free materials;
- _ Tension-free fit thanks to precise CNC manufacturing technology;
- _ Suitability for a large width of indications thanks to individual computer-assisted design.

The integration of the virtual design supplements the trusted manufacturing technology based on cutting and hence opens up possibilities of new indications for using alternative materials in implant prosthodontics.

Editorial note: Bibliographical reference is immediately available for download at www.zwp-online.info/fachgebiete/implantologie.

_contact	implants
<p>Dr med dent Sven Rinke, MSc, MSc Geleitstr. 68 63456 Hanau, Germany E-mail: rinke@ihr-laecheln.com</p>	

The concept of “platform switching” in implant dentistry

A literature review—Part I

Author_Virgil Koszegi Stoianov, Romania

Over the last decades, osseointegrated dental implants have proven to be highly predictable and largely accepted as treatment modality for the rehabilitation of partially and completely edentulous jaws.

Being considered the most aesthetical and functional alternative to missing teeth, dental implants are used as prosthetic supports and expected to withstand complex occlusal load. However, they also have to confront the effects of additional factors such as oral microflora or elevated parafunctional forces.

Introduction

Several factors such as implant design and surface, implant abutment interface or connection,

bone architecture, prosthodontic restoration type and loading conditions may have effect on bone modelling and remodelling around the implants.

The generally accepted criterion for implant success is that less than 0.2 mm of alveolar bone loss per year should occur after the first year in function.¹

What is overlooked, however, is that the implant therapy success is determined after the first year of service because most of the bone loss occurs during the first 12 months following abutment connection.²

Therefore, the 2 mm loss of crestal bone over the first year might be considered a normal characteristic of a healthily functioning implant and this change in bone height is merely due to remodelling in response to loading.

The questions that need to be redressed are whether this small amount of bone loss exerts any clinical significance and whether it can be considered acceptable.

Dental implants have two goals to fulfil: an aesthetic one and functional one. The loss of crestal bone and soft tissue may have important implications for aesthetic implant restorations, which are reliant on healthy and constant soft tissue dimensions over time. The aesthetic replacement of teeth has become an important standard for implant dentistry, leading to further research regarding the factors contributing to crestal bone loss around two stage implants (Fig. 1).

Bone adaptation under loading conditions

Bone is a tissue that changes its mass and internal architecture adapting itself to the loading con-

Fig.1_Factors affecting bone changes around titanium dental implants

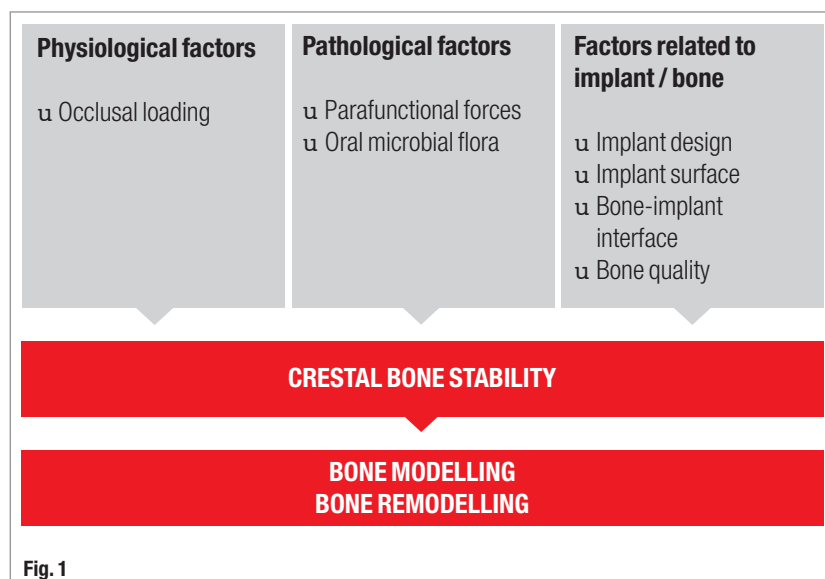


Fig. 1

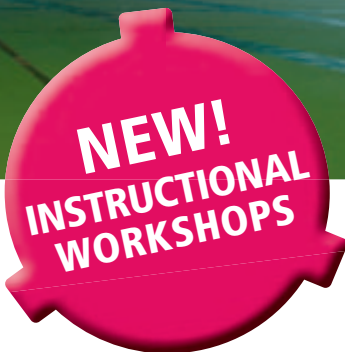


3RD INTERNATIONAL

CAMLOG CONGRESS

JUNE 10TH – 12TH, 2010

STUTT GART LIEDERHALLE



FROM SCIENCE TO INNOVATIONS AND CLINICAL ADVANCES

TOPICS

- Scientific and clinical advances, standard or platform switching restorations
- Restorative aspects and technical solutions
- Reports on current research
- Innovations in surgical site development
- Management of complications
- Meet the experts

SCIENTIFIC COMMITTEE

Prof. Dr. Jürgen Becker, Dr. Sven Marcus Beschmidt, Prof. Dr. Dr. Rolf Ewers

Prof. Dr. Dr. Dr. Robert Sader, PD Dr. Frank Schwarz, Prof. Dr. Dr. Wilfried Wagner

Under the aegis of the

 camlog foundation

More information and registration: www.camlogcongress.com

ditions. According to Wolff's law¹⁶, every change in the form and function of bone is followed by modifications in its internal architecture and external conformation. The dimensions and orientation of trabeculae are adaptable in accordance with changes in loading trajectorial vectors and, when equilibrium is found, trabecular patterning represents the average regime experienced by the bone.¹⁷

Mechanical stimuli affect bone response and exert influence on the replication and differentiation of mesenchymal cells toward the osteoblast lineage.¹⁸

Frost's theory

Frost stated that bone mass changes when absolute peak strains induced inside the bone fall either below or above the physiological window estimated between 200 and 1,500 microstrains.

Fig. 2 Frost's Mechanostat theory.

4,000 – 6,000 microstrains PATHOLOGICAL LOAD => fracture
1,500 – 4,000 microstrains OVERLOAD => bone resorption
200 – 1,500 microstrains PHYSIOLOGICAL LOAD => bone apposition

Fig. 2

The application of this theory Fig. 2 to dental implant rehabilitation explains bone resorption at the crestal level of loaded implants, a condition that may occur because of the stress shielding effect, due to both the solid metal structure of the implant and the implant design. These features can play a role on load transfer to the bone, reducing strain magnitude under the lower physiologic threshold and, thus, promoting osteoclast resorption at the crestal level.

The rigid metal structure of the implant acquires most of the occlusal stresses, transferring them deeper into the basal bone, excluding the crestal bone from the physiologic stimulation. Implants with a slim design at the crestal level, for example, demonstrate a wide bone formation, corroborating Frost's theory.

Effect of implant geometry on the marginal bone

Implant design consists of the combination of the implant body three-dimensional geometry, presence of threads, thread design, surface topography and surface treatments that may affect strain stimulation of peri-implant bone.²⁰

Finite element analysis reported that tapered implants present a better mechanical performance than cylindrical implants to avoid punching stresses.^{21,22} It has been demonstrated that threads and their location on the implant body have a role in the load transferring pressure patterns to the bone.²³

The outcome of comparative clinical research on different implant systems have reported analogous marginal bone loss per year (1–3), even if smooth surfaced implants with a conical collar have demonstrated higher bone loss than self-tapping and standard implants.^{29,30}

In this respect, marginal bone loss might be primarily related to the smoothness of the implant surface, leading to stress protection, and thus, to bone resorption (bone shielding).³¹

Effect of the implant surface on the peri-implant bone

Surface microgeography plays a primary role in facilitating biological interactions between bone precursor cells and implant.

Rough implant surfaces facilitate high osteoblast adhesion levels²⁴, and since osteoblasts are spread on implant surfaces, the roughness seems to induce osteoblasts toward synthesis and the release of biological factors affecting the tissue response at the interface. Surface roughness is a crucial factor affecting bone apposition at the interface and improving the interface resistance because of better mechanical interlocking.

However, increased bone mass around rough surfaces may also be attributed to a lower bone remodelling level during the early stages of implantation, as reported in a comparative research study between plasma sprayed and smooth surfaced implants.^{25,26}

A poor implant design like smooth machined coronal part could be related to a reduction in mechanical interlocking between implant and crestal bone, acting like a stress shield and inducing crestal bone loss.^{27,28}

The stability of the peri-implant cervical bone around the neck of the implant and the absence of resorption are the key to maintaining gingival papillae and bone in the anterior region.

According to reference literature, several changes should occur after abutment connection. Bone resorption of approximately 2 mm from the implant abutment junction³ should occur circumferentially, noticeable on the buccal plate.

Preliminary evidence suggests that anticipated

bone loss occurring around two-stage implants, following loading, or surgical stage 2, may be reduced or eliminated when implants are restored with smaller-diameter abutments on larger platforms.^{4,5}

The interface between abutment and implant, or the microgap, is subject to micro movements and bacterial seeding, and, if it lies at or below the crest of the bone, prompts osseous resorption for these reasons.

Bone preserving techniques such as platform switching have been utilized for more than ten years (Fig. 3).

The answer to these questions may be of an important support in choosing the implant system, able to switch the platform, which can face high implant–aesthetic demands.

Is the concept of platform switching a bone preserving technique and, if so, is this reproducible?

Is this concept alone able to preserve bone?

Is the platform switching concept evidence based?

Materials and methods

The aim and objectives of this review have been to examine the scientific validity of claims that platform switching concept improves implant performance, being a bone preserving technique.

These claims have been analyzed against historic background, findings and conclusions of published implant studies.

A literature search of paper published in reference journals in the English language was performed by computer using the National Library of Health.

PubMed—the government search engine for the

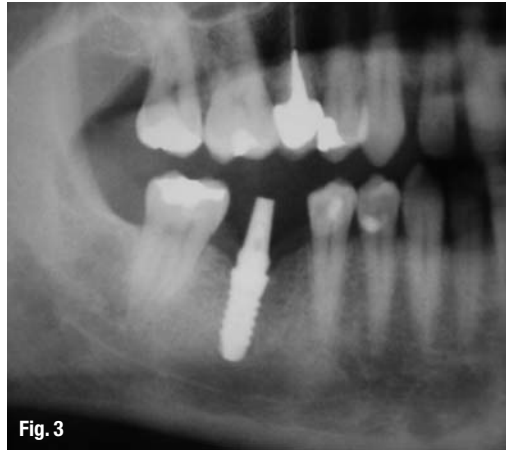


Fig. 3

Fig. 3_ The platform switching concept (X-ray courtesy Dr. R. Vollmer, G. Golecki)

National Library of Health, National Institute of Health MEDLINE database: <http://www.pubmed.gov>, has been used as the primary source of data.

Google Scholar Search engine and different Journals and books have been employed as a secondary source.

PubMed search for the key words “implant platform switching concept” ended in 10 and Google Scholar in 3,110 results for the same key words in 0.07 seconds.

These results show an ever-growing interest in this subject which is very challenging for the peer reviewed literature to keep up with.

Manual search of IJOMI—International Journal of Oral and Maxillofacial Implants with back issues from 1996 to 2009 revealed very few results.

The reference list of identified publications and textbooks were scanned.

The first selection method consisted in a relevant references selection on the basis of titles and abstracts.

The final selection method being possibly rele-

Site	Type of implants	No. of implants	Bone res. (mm) after 1 year	Bone res. (mm) after 2 years	Bone res. (mm) after 3 years	Bone res. (mm) after 4 years	Bone res. (mm) after 5 years
Maxilla PS*	3/ ext. hex	50	0,6+/-0,2	0,6+/-0,2	0,6+/-0,2	0,6+/-0,2	0,6+/-0,2
Mandible PS	3/ ext. hex.	47	0,5+/-0,2	0,5+/-0,2	0,5+/-0,2	0,5+/-0,2	0,5+/-0,2
Maxilla non PS**	3/ ext. hex.	42	0,9+/-0,3	1,0+/-0,3	1,0+/-0,3	1,1+/-0,3	1,2+/-0,3
Mandible non PS	3/ ext. hex.	43	0,8+/-0,2	0,9+/-0,3	0,9+/-0,3	1,0+/-0,3	1,0+/-0,3

PS* = Platform switched abutments (narrower)
 PS** = Same platform abutment (non-switched)

Tab. 1

vant full text publications have been reviewed for a more detailed evaluation.

Tables have been drawn up using data and findings extracted from relevant studies, further compared and analyzed in view of establishing a final conclusion.

Results

Table 1

Jomi 2009; 24:103–109
Paolo Vigolo, Andrea Givani
Platform Switched Restorations on Wide-Diameter Implants: A 5-year Clinical Prospective Study

Result: Statistically significant differences in marginal bone loss have been observed between implants with platform switching (0.6 mm; SD 0.2 mm) and implants with the same abutment platform (0.9 mm; SD 0.3 mm)

Table 2

J Oral Maxillofac Surg. 2007 Jul;65
M, Fickl S, Zuhr O, Wachtel HC
Peri-implant bone level around implants with plat-

form switched abutments: Preliminary data from a prospective study

Result: The concept of platform switching appears to limit crestal resorption and seems to preserve peri-implant bone levels. Significant differences concerning the peri-implant bone height in PS compared to non PS implants are still evident one year after final restauration.

Table 3

Jomi 2007;22:995–1000
Luigi Canullo, Giulio Rasperini
Preservation of Peri-implant Soft and Hard Tissues Using Platform Switching of Implants Placed in Immediate Extraction Sockets: A Proof-of-Concept Study with 12- to 36-months Follow-up

Result: Post-extractive immediate implants with platform switching can preserve hard and soft tissues and, therefore, may provide better aesthetic outcomes.

Table 4

Int. J Periodontics Restorative Dent. 2008 Aug
Cappiello M, Luongo R, Di Iorio D, Bugea C, Coc-

Type of implant	Baseline mean value of crestal bone height	Bone height at 1 year	Mean bone level change from baseline to 1 year
3/int hex PS	-0.09 mm+/-0.65 mm	-0.22 mm+/-0.53 mm	-0.12 mm+/-0.4 mm
3/int hex non PS	-1.73 mm+/-0.46 mm	-2.02 mm+/-0.49 mm	-0.29 mm+/-0.34 mm
P</=0.0001			

Tab. 2

No. of implants	Type of implants	Site of implantation	Mesial Mean bone loss	Distal Mean bone loss	Overall Mean bone loss
9	Defcon Implant System	Maxilla	0.57 mm (0.002–1.02)	1.01 mm (0.230–1.592)	0.78 +/- 0.36

Tab. 3

	Nr. of implants	Bone loss after 1 year	Mean bone loss
PS implants narrower healing abutment	75	0.6 mm–1.2 mm	0.95 mm+/- 0.32 mm
Non PS implants with Same diam. Ha	56	1.3 mm–2.1 mm	1.67 mm+/- 0.37 mm

Tab. 4

chetto R, Celletti R.
Evaluation of Peri-Implant Bone loss around platform-switched implants

Results: This data confirm the important role of the microgap between the implant and abutment in the remodeling of the peri-implant crestal bone. Platform switching seems to reduce peri-implant crestal bone resorption and increase long-term predictability of implant therapy.

Table 5
J Periodontol. 2001 Oct
Hermann JS ,Schoolfield JD, Schenk RK, Buser D, Cochran DL
Influence of the size of the microgap on crestal bone changes around titanium implants. A histometric evaluation of unloaded non-submerged implants in canine mandible.

Type of implant	Size of the microgap	Mean crestal bone levels after 3 months*
Laser welded A	< 10 micron	1.06 mm+/- 0.46 mm
Laser welded B	~ 50 micron	1.28 mm+/- 0.47 mm
Laser welded C	100 micron	1.17 mm+/- 0.51 mm
Abutm. with screw D	< 10 micron	1.72 mm+/- 0.49 mm
Abutm. with screw E	~ 50 micron	1.71 mm+/- 0.43 mm
Abutm. with screw F	100 micron	1.65 mm+/- 0.37 mm

Tab. 5

Results: All implants in the non-welded group had significantly increased amounts of crestal bone loss compared to the welded group. These findings demonstrate that crestal bone changes around 2-piece non-submerged titanium implants are significantly influenced by possible movements between implants and abutments, but not by the size of the microgap. Significant crestal bone loss occurs in 2-piece implant configurations even with the smallest-sized microgaps (<10 micron) in combination with possible movements between implant components.

Table 6
JOMI 2006; 21:777-784
Michael R. Norton
Multiple Single-Tooth Restorations in the Posterior Jaws: Maintenance of Marginal Bone Levels with Reference to the Implant-Abutment Microgap

Site	No. of implants (173) Astra	Mean marginal bone loss	Two stage surgical protocol	Transmucosal surgical protocol
Maxilla	80	0.56 mm	48	125
Mandible	93	0.70 mm		

Tab. 6

0.65 mm from the microgap the data of this study is in close agreement with numerous studies on the Astra Tech System.

The finding that some of the implants have demonstrated bone above the level of the microgap cast doubt on the theory of biologic width, with regard to the influence of the location of the implant-abutment microgap which requires re-evaluation.

Editorial note: The publication will be continued with Part II in the next issue.

Results: The way in which bone responds around an implant may be due to multiple factors. It is also plausible that the tight conical joint, with its high resistance to bending moments and a microgap of only 2-4 microns, contribute significantly to the maintenance of marginal bone.

With an overall mean marginal bone loss of only

_contact	implants
<p>Virgil Koszegi Stoianov Office: Str.Paciurea No. 5 300036 Timisoara, Romania Tel.: +40 356433733 Mobile: +40 723573443 E-mail: virgil.koszegi@medicis.ro</p>	

AD



Subscribe now! **One issue free of charge!**

I hereby agree to receive a free trial subscription of **laser international magazine of laser dentistry** (4 issues per year). I would like to subscribe to **laser** for € 44* for German customers, € 46* for customers outside Germany, unless a written cancellation is sent within 14 days of the receipt of the trial subscription. The subscription will be renewed automatically every year until a written cancellation is sent to OEMUS MEDIA AG, Holbeinstr. 29, 04229 Leipzig, Germany, six weeks prior to the renewal date.

► Reply per Fax +49-(0) 3 41/4 84 74-2 90 to OEMUS MEDIA AG or per E-mail to grasse@oemus-media.de

Last Name, First Name	ZIP/City/Country
Street	E-mail

Notice of revocation: I am able to revoke the subscription within 14 days after my order by sending a written cancellation to OEMUS MEDIA AG, Holbeinstr. 29, 04229 Leipzig, Germany.

Signature	<p>OEMUS MEDIA AG Holbeinstr. 29, 04229 Leipzig, Germany Tel.: +49-(0) 3 41/4 84 74-0, Fax: +49-(0) 3 41/4 84 74-2 90 E-Mail: grasse@oemus-media.de</p>
-----------	---

*Prices include shipping and VAT IM 1/10

Cross-linked or natural collagen membrane?

Fewer complications and good bone regeneration with natural structure

Author_Dr Heike Wanner, Switzerland

Recent study results show that artificial cross-linking of collagen membranes does not confer any additional benefit: bone regeneration is as good with Geistlich Bio-Gide® as compared with a cross-linked collagen membrane. The natural collagen structure of Geistlich Bio-Gide® has the additional advantage that the membrane is outstandingly bio-compatible and that it ensures secure wound healing and fewer complications.

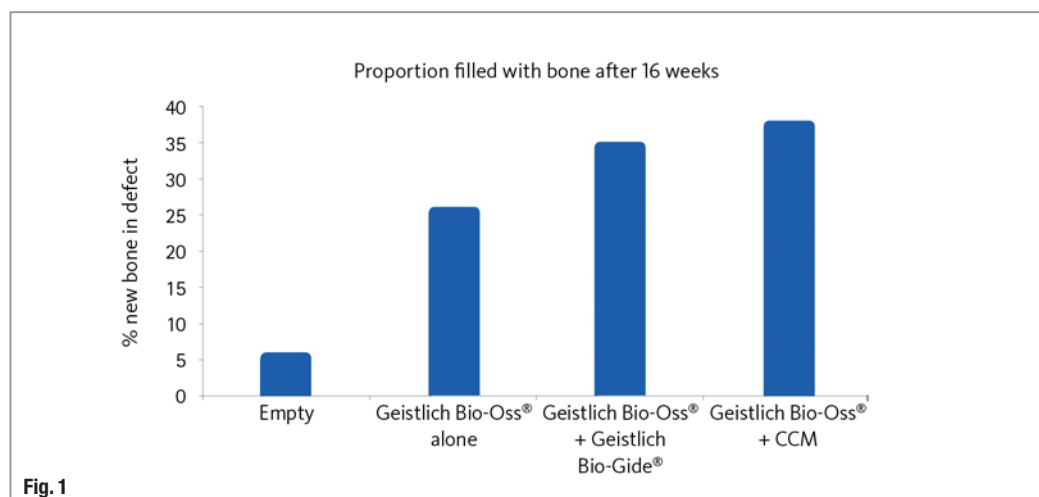
Absorbable collagen membranes are used more and more frequently in dentistry for guided bone regeneration (GBR) or for guided tissue regeneration (GTR). The great advantage of using absorbable membranes is that a second procedure to remove the membrane is not necessary, unlike in the case of non-absorbable ones. In connection with absorbable membranes, however, how long they have to be present for their barrier function to be sufficient for optimal bone regeneration is repeatedly a topic of discussion.

No additional benefit for bone regeneration through cross-linking

Artificial cross-linking of collagen is an attempt to increase the barrier function of collagen membranes. Recent results from clinical and preclinical studies have shown, however, that this is unnecessary as the barrier function of the natural non-cross-linked collagen membrane Geistlich Bio-Gide® is already sufficient to enable effective and predictable bone regeneration (Becker, Al-Nawas et al. 2009; Bornstein, Heynen et al. 2009).

In a clinical study by Becker et al. (54 patients) of the treatment of dehiscences around implants, bone regeneration was similar with an experimental cross-linked collagen membrane and with the natural non-cross-linked membrane Geistlich Bio-Gide® (Becker, Al-Nawas et al. 2009). Both collagen membranes were used in combination with Geistlich Bio-Oss®.

Fig. 1 Use of Geistlich Bio-Gide® or an experimental cross-linked collagen membrane (CCM) combination with Geistlich Bio-Oss leads to comparable bone regeneration in the pig model. The bone regeneration is better than in empty defects and defects filled only with bone material (Bornstein, Heynen et al. 2009).



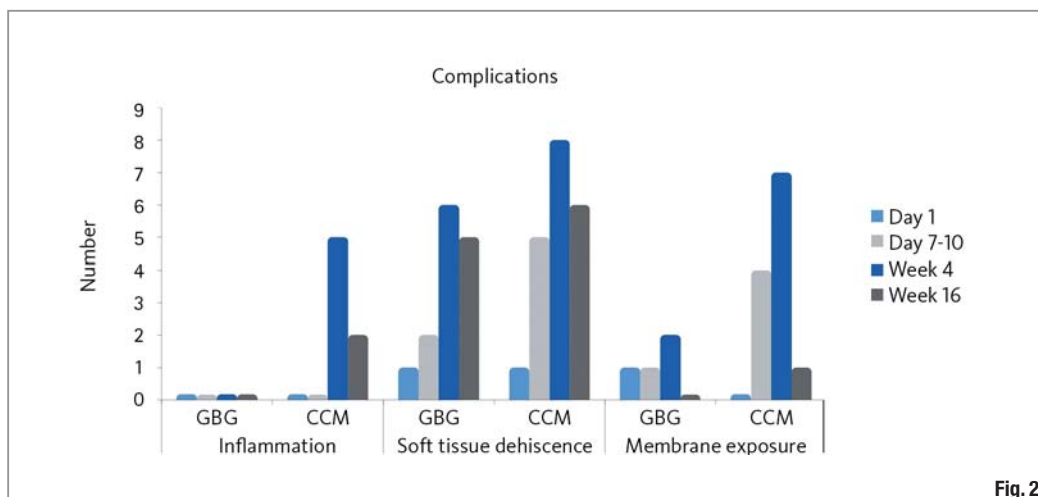


Fig. 2 Use of the natural collagen membrane Geistlich Bio-Gide® (GBG) led to fewer complications in wound healing than use of an experimental cross-linked collagen membrane (CCM). Inflammation, soft tissue dehiscence and membrane exposure occurred more often up to 16 weeks after the procedure when the cross-linked membrane was used (Becker, Al-Nawas et al. 2009).

These data agree with the results of a preclinical study in the pig model (N = 17). This showed that the proportion of newly formed bone in experimental bone defects of the skull was similar when Geistlich Bio-Gide® was used to when an experimental cross-linked collagen membrane was employed—in each case in combination with Geistlich Bio-Oss® and independent of the size of the defect (Fig. 1). Both membranes also showed significantly better bone regeneration in combination with Geistlich Bio-Oss® than when the bone substitute was used without a membrane (Bornstein, Heynen et al. 2009).

_Fewer wound dehiscences with Geistlich Bio-Gide®

Compared with the cross-linked collagen membrane, it is also apparent that the use of the natural collagen membrane Geistlich Bio-Gide® leads to better wound healing. In the clinical study by Becker et al. wound dehiscences and membrane exposures over 16 weeks were fewer with Geistlich Bio-Gide® than with an experimental cross-linked collagen membrane (Fig. 2). Whereas inflammation did not occur with Geistlich Bio-Gide® it was significantly more with the cross-linked membrane after four and 16 weeks (Becker, Al-Nawas et al. 2009).

The recent data are thus confirmed by the results of a clinical study by Tal et al. (2008), who showed that membrane exposure occurs significantly more often with the cross-linked collagen membrane Ossix® than with Geistlich Bio-Gide®. Wound dehiscences occurred about twice as often in the study when the artificially cross-linked membrane was used (Tal, Kozlovsky et al. 2008).

_Cross-linking reduces biocompatibility

The better wound healing achieved with Geistlich Bio-Gide® is based on the superior biocompatibility

of the natural membrane in comparison with collagen membranes that were artificially cross-linked. With the cross-linked membranes, vascularisation is lower and/or much slower and tissue integration is diminished (Rothamel, Schwarz et al. 2005; Schwarz, Rothamel et al. 2006). In addition, Rothamel et al. observed a foreign body reaction with different cross-linked membranes in the rat model, but not with the natural Geistlich Bio-Gide® (Rothamel, Schwarz et al. 2005). In an *in vivo* study, moreover, it was shown that the natural non-cross-linked collagen membrane promotes proliferation and adhesion of cells. After seven days, the number of osteoblast-like cells and fibroblasts of the periodontal ligament was highest in cultures with Geistlich Bio-Gide® (Rothamel, Schwarz et al. 2004).

_References

1. Becker, J., B. Al-Nawas, et al. (2009). "Use of a new cross-linked collagen membrane for the treatment of dehiscence-type defects at titanium implants: a prospective, randomized-controlled double-blinded clinical multicenter study." *Clin Oral Implants Res.* 20(7): 742–9.
2. Bornstein, M. M., G. Heynen, et al. (2009). "Effect of two bioabsorbable barrier membranes on bone regeneration of standardized defects in calvarial bone: a comparative histomorphometric study in pigs." *J Periodontol* 80(8): 1289–99.
3. Rothamel, D., F. Schwarz, et al. (2005). "Biodegradation of differently cross-linked collagen membranes: an experimental study in the rat." *Clin Oral Implants Res* 16(3): 369–78.

Editorial note: The whole literature list can be requested from the editorial office.

_contact

implants

Dr Heike Wanner

Bahnhofstrasse 40

6110 Wolhusen, Switzerland

Buccal dehiscence and sinus lift cases

Predictable bone augmentation with synthetic bone material

Authors_ Dr Sérgio Alexandre Gehrke, Brazil & Dr. Giuseppe Maria Famà¹, Italy

Introduction

The substitution of lost teeth by dental implants is being increasingly used to support prosthetic crowns or bridges. Many of these cases are associated with bone loss that requires the filling of the defects by some kind of bone substitute. The recent improvements in synthetic bone materials have led to increased predictability and explain the ever-increasing use of such materials in various bone augmentation indications.

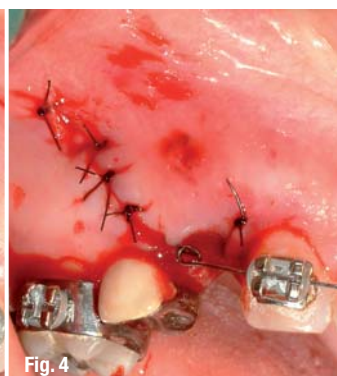
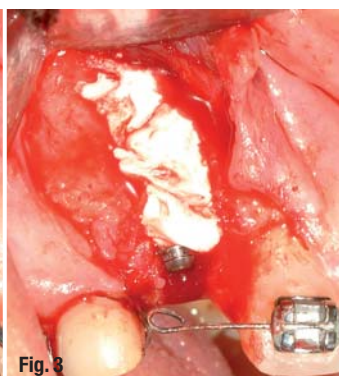
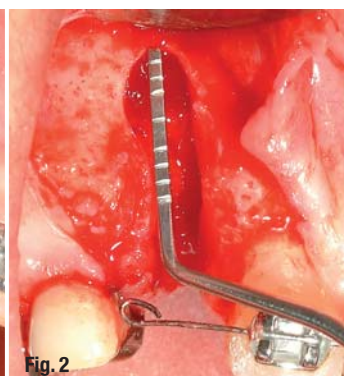
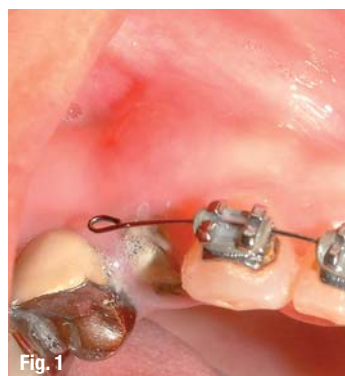Over the last years, one could observe a trend to bring products on the market that seem to be the next generation to supplement granular materials. These are the materials that have their own cohesion and are presented in the form of a paste. Some examples are easy-graft™ (Degradable Solutions, Schlieren, Switzerland), consisting of granules embedded in a sticky polymer matrix, Bond Bone™ (Augma Biomaterials, Karkur, Israel), a hardening calcium sulfate paste, Fortoss Vital (Biocomposites, Staffordshire, England), granules embedded in a hydroxyl sulfate matrix, and PDVitalOs Cement® (Produits Dentaires, Vevey, Switzerland), a hardening

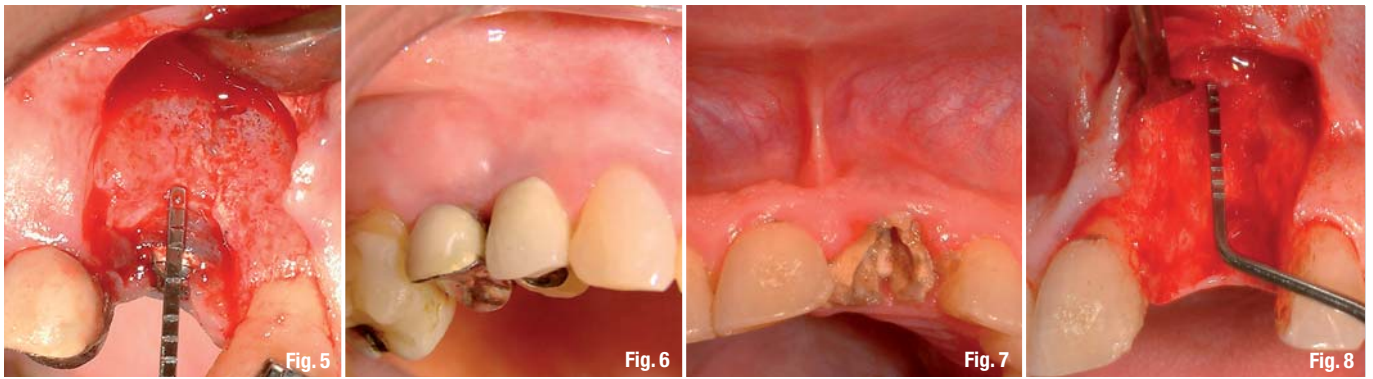
calcium phosphate (brushite) cement. We have been working with the latter material for a couple of years now. The large number of positive results obtained and the ease of use of the cement explain our great satisfaction with the product. Nevertheless, to get good results with this product requires to re-think the way of working because this material, like the pasty materials in general, cannot be placed the same way as one would place granules in a defect.

The goal of this article is to exemplify the positive results obtained with the VitalOs cement in two kinds of indications which seem to be the most adequate indications for the use of this product: immediate implantation and sinus lift in one-step. This is achieved by showing four cases, with an emphasis on how to use the product correctly.

Immediate implantation in alveolus—Cases presentation

Case 1 was a 50-year old non-smoking female patient in good health who presented with a fractured root at the level of the maxillary first right premolar. This fracture was visible on the radi-





ograph as well as clinically (Fig. 1). The facts that the fracture was old and that a fistula developed around the root resulted in a large loss of the buccal bone wall. The treatment options were presented to the patient, who signed an informed consent form. The patient presented no contra-indications to the treatment.

Case 2 was a 54-year old non-smoking male patient in good health with no contra-indication to the proposed treatment, who presented with a maxillary right central incisor following a root fracture as can be seen on the pre-operative radiograph and clinically (Fig. 7). Given the radiographic and clinical findings it seemed evident that the buccal bone wall was resorbed. The treatment options were presented to the patient, who signed an informed consent form.

_Immediate implantation in alveolus—Surgical protocol

After administration of the local anesthetics (Scandicaine 2%, Septodont), an intrasulcular incision was made around the root and a lateral one on the buccal side to provide access and allow visualization of the defect. The fractured roots were very carefully extracted to avoid increase of the bone loss. After curettage, the sites were prepared for the installation of the implant according to the manufacturer's instructions. The bone defects were measured with a periodontal probe with millimeter

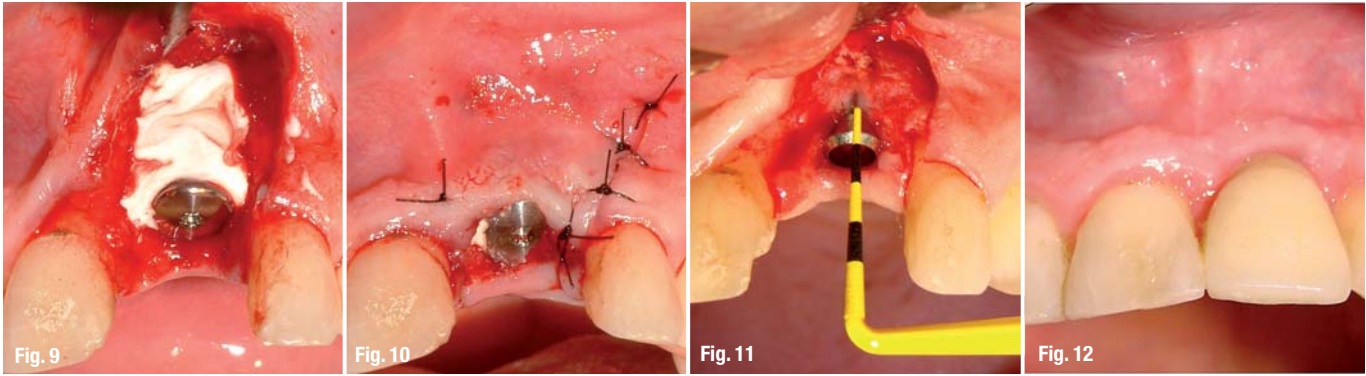
markings (Figs. 2 & 8). The implants placed were in each case a Straumann RN SP (4.1 mm diameter, 14 mm length). The implants were installed at the level of the crestal bone of the adjacent teeth.

The injection of VitalOs must always be preceded by adequate control of the bleeding with the suction canula. The cement is placed within the defect without need for over-filling (Figs. 3 & 9), unlike what is often done with other types of bone substitutes like granules. Any material put in excess is always expelled or resorbed. With VitalOs, as the cement forms a block, a large quantity or even the whole material may be expelled. When the injected quantity is in large excess, the hardened block can easily break up and large pieces may be expelled out of the site. With granular materials it is only small granules that are expelled and this is less disturbing than pieces of cement. This is the reason why we never overfill sites with VitalOs.

A suture is then made with a 5-0 nylon suturing material. No attempt is made to achieve primary suture over the implant (Figs. 4 & 10) because we observed that even when the cement remains exposed to the oral environment, the bacteriae cannot adhere onto the surface of VitalOs and therefore no infection develops. The implants with a large platform help to maintain the volume and anatomy of the gums because they act as a shape keeper for the gingiva. A post-operative radiograph is taken for each case 7 days after implantation.

Case	Initial longitudinal measurement of the defect	Initial mesio-distal distance of bone loss (at the ridge level)	Initial area of bone lack in mm ²	Longitudinal defect measurement after 3 months	% of area substituted by bone
1	12 mm	2 mm	82	2 mm	95
2	10 mm	8 mm	132	2 mm	97

Tab. 1 _Bone defect measurements (buccal dehiscence cases).



The bone loss area was also measured (with imaging software Image ProPlus 4.0). These results are presented in Table 1.

Immediate implantation in alveolus—Re-opening

The sites were re-opened three months after implant installation to install the healing abutments. Measurement of the buccal bone level was measured again with the periodontal probe (Figs. 5 & 11).

Immediate implantation in alveolus—Restorations

After gingival conditioning, impressions were taken and the prosthetic restorations were made according to manufacturer's (Straumann) instructions. The two cases were followed up after one year and the esthetic result can be seen on Figures 6 and 12. The results show that there was neither loss of tissue nor gingival retraction in the grafted areas. Therefore, the anatomy obtained after implantation was maintained one year after restoration, ensuring a stable esthetic result.

Sinus lift with simultaneous implantation—Cases presentation

Case 1 was a 47-year old non-smoking male patient in good general health with a missing maxil-

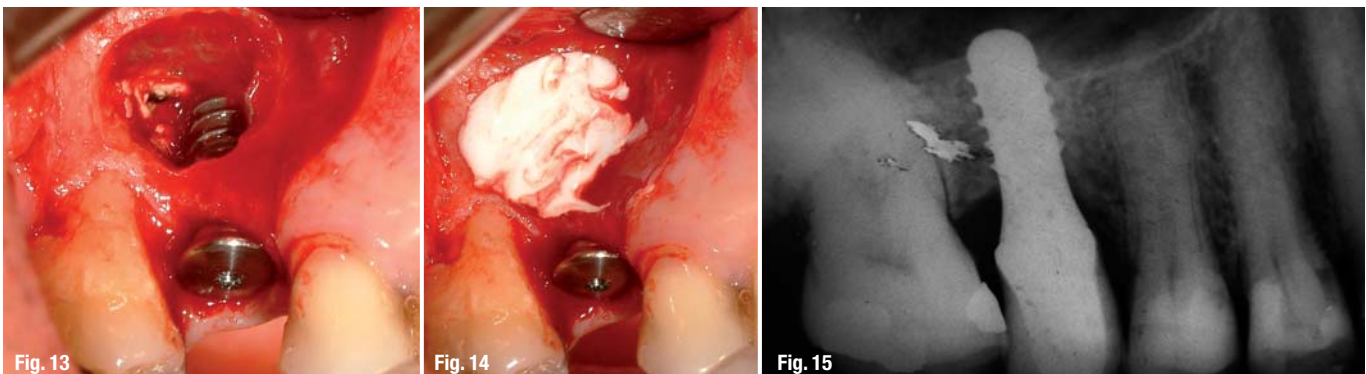
lary right second premolar and sinus pneumatization.

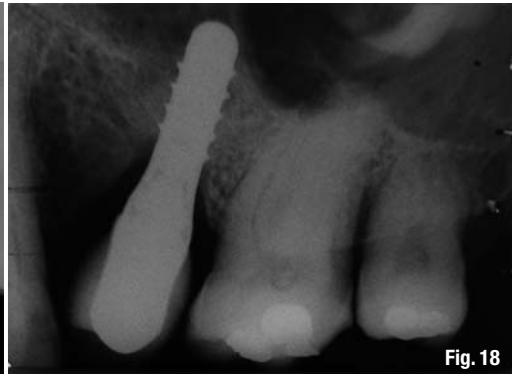
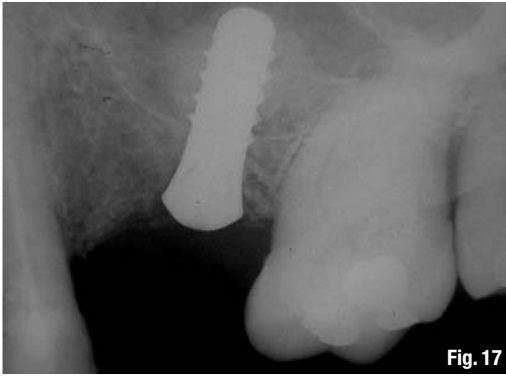
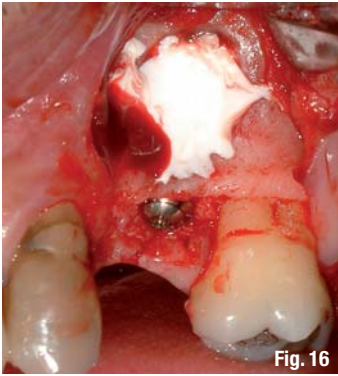Case 2 was a 48-year old non-smoking male patient in good general health with a missing maxillary left first premolar and sinus pneumatization.

In both cases, the sinus pneumatization was an indication for sinus grafting. Since the remaining bone height was larger than 3 mm it was decided to perform a sinus lifting with simultaneous implant installation. The treatment options were presented to the patients and they signed an informed consent form.

Sinus lift with simultaneous implantation—Surgical protocol

After local administration of anesthetics (Scandicaine 2%, Septodont) an intrasulcular incision was performed around the root and a lateral incision was made on the buccal side to gain access to the lateral wall of the maxillary sinus. After creation of the lateral window, the sinus membrane was carefully lifted and the site was prepared for implant installation. Then, the cement was injected against the inner (nasal) sinus cavity up to half of its width, and the implant Straumann RN SP (4.1 mm diameter, 12 mm length) was then installed (Fig. 13). Once the implant installed, the rest of the sinus cavity was filled with the cement (Figs. 14 & 16). The suture was made with 5-0 nylon simple





stitches. A post-operative radiograph was taken 7 days after surgery (Fig. 17). The distance between the sinus floor and the implant apex was measured on the radiograph. The results are shown in Table 2. The patients were recalled after one year to take a radiograph of the treated sites (Figs. 15 & 18).

_Sinus lift with simultaneous implantation—Bone gain measurement

Six months after surgery, the sites were reopened to install the healing abutments. Radiographs were taken to measure the bone gain.

that this material is suitable and very efficient as a bone substitute. This is exemplified here through the presentation of a few cases, representative of the results generally obtained with this material.

The way of delivering the product into the site greatly simplifies its placement: a dual syringe with a mixing tip. Since the product is initially in a pasty form it fills out the site to treat very uniformly and prevents the ingrowth of soft tissues once it has hardened. The sites presented here are situations which offer stability to the cement due to the geometry of the defects. For these reasons,

Case	Initial ridge height	Post-operative distance between original sinus floor and implant apex	Bone height between ridge and new sinus floor after one year
1	3 mm	9 mm	10 mm
2	4 mm	8 mm	9,5 mm

Tab. 2 Bone height measurement (sinus lift cases).

Table 2 shows the values measured post-operatively and one year later.

We already observed that the process of resorption of the cement coupled with new bone growth can be conveniently followed up radiographically (Gehrke 2009). One year after functional restoration we could see that the level of newly formed bone was maintained, without loss around the apical portion of the implants. This is a very positive finding because the loss of bone at the apical level after loading the implants is a common phenomenon when this type of sinus grafting is performed.

_Discussion

Several types of biomaterials and different techniques have been proposed for the recovery of bone tissue lost after tooth extraction or loss. The results obtained with the PD VitalOs cement show

the product is used without membrane. However, a particular attention must be paid to achieving primary stability: if the product is not tightly anchored onto the bone walls or onto an implant surface, then the blood pressure is able to expel part or all of the injected volume. To avoid this situation, it is very important to control bleeding and to choose site geometries that offer stability to the cement.

In our practice we observed the replacement of the cement by bone is generally fast, even though it depends much on the injected volume. This is a very interesting feature because patients choosing the immediate implantation treatment are willing to have the missing element replaced as quickly as possible. The same way, in the case of the maxillary sinus grafting, the cement promotes accelerated bone formation, enabling earlier placement of the restoration.

_contact implants

Dr Sérgio Alexandre Gehrke
 BioFace Institut
 Dr. Bozano, 571
 Santa Maria – RS, Brazil
 E-mail:
 Sergio.gehrke@terra.com.br

¹MD, DDS, Tutor of Periodontology and Implantology at University of Perugia

“Patients’ satisfaction towards functional Reconstruction is very high”

Author_Daniel Zimmermann, Germany

_ With increasing public awareness of the benefits of dental implants, an increasing number of patients are considering this treatment option. While current studies often focus only on clinical aspects such as osseointegration, patient responses to psychological and psychosocial changes are only infrequently addressed. Dental Tribune International Group Editor Daniel Zimmermann spoke with Dr Bo Chen from the Department of Oral Implantology (Beijing University School of Stomatology in China) about her latest study on patients' attitudes following implant placement and subsequent restoration.

_ Dr Bo, studies on patient satisfaction figures of patients who have had maxillofacial surgery with implants are very rare, even in well-developed dental markets like Europe or the US. What motivated your study in China?

Severe jawbone defects due to tumour resection present a major problem for functional restoration (mastication, swallowing and speech),

which severely influences patients' quality of life. Reconstruction of lost tissue in order to facilitate implant placement often means relatively complex maxillofacial surgeries accompanied by certain morbidities. Unlike Europe or the US, where patients suffering from head or neck tumours are mostly treated by ENT surgeons and plastic surgeons, oral and maxillofacial surgeons in China treat such tumours in addition to conducting the subsequent bone reconstruction. The sample of such patients at the Peking University School of Stomatology is quite large compared with what is available in the literature. Thus, I decided upon investigating patient satisfaction of this kind of treatment series.

_ Oral defects and edentulism can have a significant impact on people's lives. How do they generally affect the social status of people in China?

Oral defects and edentulism may lower body image significantly. People tend to limit their social activities and contact with their surroundings. They tend to be more depressed and frustrated, less tolerant of their family and irritable.

_ Are dental implants already a standard treatment option for maxillofacial surgery in China, and if not why not?

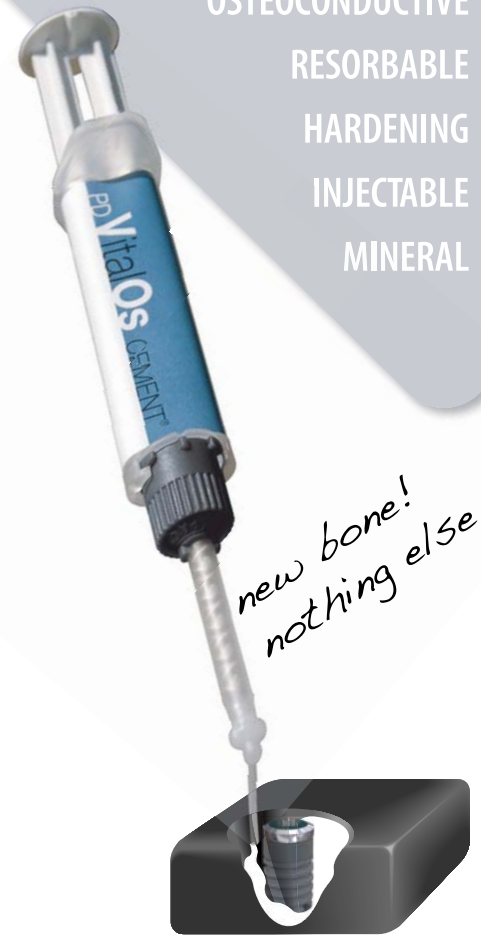Maxillofacial surgery is practised at a high standard at the Peking University School of Stomatology and is quite affordable for the patients. But dental implants are not yet a standard treatment option in China. Although the lack of public awareness and availability of competent clinicians may contribute to this, the high cost of this treatment option, which is usually not covered by insurance, may be the most significant factor.



The bone regeneration cement



OSTEOCONDUCTIVE
RESORBABLE
HARDENING
INJECTABLE
MINERAL



What measures did you use for the study and how did you implement them?

Questionnaires in the form of a visual analogue scale (VAS) of patients' treatment satisfaction were used in addition to OHIP-14 (Oral Health Impact Profile-14) in this retrospective study. Patients were invited to the clinic for these evaluations, which took 30 minutes on average. For those who could not come to the clinic, the evaluation was conducted by telephone.

In a nutshell, what was the outcome and what psychological and psychosocial changes following surgery did the patients report?

According to a number of studies on patients suffering from head or neck tumours, frequent problems regarding the patients' OHIP were reported, especially within one year after tumour resection. The retrospective study indicated that patients were satisfied with the outcome of functional reconstruction with osseointegrated implants despite the morbidity of the surgery. Their OHIP score was not significantly different to that of a healthy population, which means that they did not have more frequently reported psychological or psychosocial problems. For the majority who did not undergo functional reconstruction, the high cost of implant treatment was their most significant concern.

What conclusions did you draw from these results?

The patients' satisfaction of functional reconstruction is very high. Their quality of life has greatly improved as demonstrated by the OHIP score. For financial reasons, only about 10 per cent of the patients are undergoing functional reconstruction with implants thus far.

It is not easy to find figures on implant procedures in China. What is the estimated number of dentists placing implants and where are they located?

Indeed, it is quite difficult to find reliable figures! The estimated number of dentists placing implants on a regular basis in China may be around 300. Thus far, they are mostly located in university-affiliated dental hospitals in the large cities. Some, but not many, are in private practice.

Should implantology form part of the curriculum in dental schools?

Only a few dental schools have begun offering implantology in their curriculum within the last couple of years. In the long term, implantology should and will form part of the standard curriculum. However, we need qualified and well-trained dental professionals who would like to convey their knowledge to dental students in a responsible way.

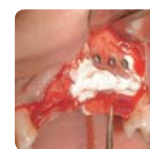Industry experts have forecasted a 30 per cent annual growth rate in the implant market in China. What prospects do you predict for the specialty from a clinical perspective?

The next decade will witness a boom in implant dentistry in China. There will be increasing demand for training and education in this field in order to guarantee standardised development. Owing to the shortage of competent clinicians, we foresee a critical period ahead of us. We certainly need to strengthen cooperation with any possible positive resources, including the industry, for training and educational programmes.

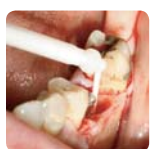
The Chinese Stomatological Association recently announced a new partnership with the International Congress of Oral Implantologists to promote implant technology can improve quality of life. Is there a need for more public awareness in the field?

There is definitely a need for more public awareness in the field. We are lagging far behind in this regard compared to Europe or the US.

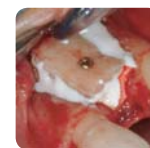Thank you very much for the interview.



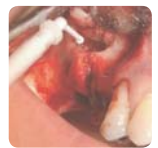bone splitting



peri-implant



onlay graft



sinus lift

Clinical cases
www.vitalos.com

Your distributor for Germany & Austria

Alexander Haid
Tel. 0049 (0)700 69 69 90 90
Fax: 0049 (0)700 69 00 90 90
info@i-dent.org
www.i-dent.org

i-DENT

intelligentes Dentalequipment

Other countries:

www.vitalos.com
Produits Dentaires SA / Switzerland



Filipino specialists back up plans for improved implant education



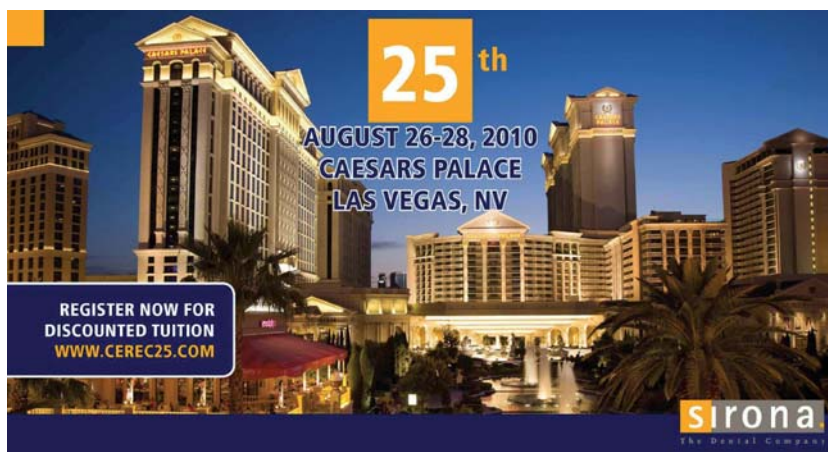_Dental implants in the Philippines are on the upswing, participants of an implantology conference in the capital Manila have agreed. They also supported plans of dental colleges and universities throughout the country to include implantology as part of their curriculum by 2011. Currently, there are an estimated 400–500 dentists placing implants in the Philippines. The conference, which was organised by the Philippine Academy of Implant Dentistry (PAID), drew almost 200 participants to Manila.

Amongst others, latest technologies and treatment methods in dental implantology were discussed including implant supported prosthetic rehabilitation and maxillofacial reconstruction. Due to the demand, representatives of the organisation have announced to organise more seminars with a higher share of foreign speakers around the country in order to advance the specialty.

"The economic prospects are very good," said Dr Carlos Buendia, President of the PAID. "With the influx of dental implant companies offering affordable implant fixtures and dental laboratories catering to dental implant prosthesis, the overall cost for the dentist has gone down."

In the last few years, more and more implant companies have entered the Philippines. Despite dental awareness programmes and dental tourism campaigns, its dental implant market is still behind other markets in the region, such as Singapore, Taiwan or Hong Kong.

CEREC 25th Anniversary Celebration in Las Vegas



_Sirona—the acknowledged dental technology leader—will stage the dental event of the year on the occasion of the CEREC Silver Jubilee. The world's leading dental CAD/CAM experts will gather in Las Vegas 26–28 August 2010 to report on the latest technological trends and celebrate 25 years of CEREC innovation. The event will feature an extensive educational program of more than 40 lectures and workshops. Approximately 3,000 dental professionals are expected to attend. Since the invention of the CEREC procedure 25 years ago and the launch of

the first CEREC system by Sirona, more than 20 million restorations have been placed. Originally a system for the fabrication of single tooth restorations, the concept has expanded to include digital impressions, integrated implant planning, and custom abutments.—Thanks to Sirona's innovative technology, these future-oriented developments in restorative dentistry have become a practical reality.


Taking part in CEREC 25 in Las Vegas offers several important benefits:

- _Central meeting place for the "Who's Who" in dental CAD/CAM and computerized dentistry
- _More than 40 lectures and workshops on the subject of CEREC
- _Attendees qualify for continuing education credits
- _Breathtaking entertainment including a performance by 5-time Emmy winning comedian and actor Dennis Miller.

The world's most spectacular dental party of 2010 —at Las Vegas' premier nightclub "Pure"—

For more information and to register for events, visit the CEREC 25 website (www.cerec25.com).

The right cap for the job



Geistlich
Bio-Oss®
NEW CAP



EASY+SAFE

Geistlich Bio-Oss® vials with optimised handling
www.geistlich-pharma.com/new-cap

LEADING REGENERATION

7th Conference of the Australasian Osseointegration Society


Author_Dr Rolf Vollmer, Germany & Dr Mazen Tamimi, Jordan



The 7th Conference of the Australasian Osseointegration Society was held from 4–7 November 2009. The Australasian Osseointegration Society (AOS) is an affiliate association of DGZI similar to the AO and AAID academies. Some DGZI members joined the congress and DGZI was represented by the 1st Vice-president and Treasurer Dr Rolf Vollmer as well as the international representative Dr Mazen Tamimi from Jordan. After flight time of around 20 hours the participants enjoyed the scientific program under the motto "staying between the flags".

In his welcome greetings the current President of AOS and AOS 2009 Chairman Saso Ivanovski emphasized: "On behalf of the Australasian Osseointegration Society, I am honoured and privileged to invite you to the AOS 7th Biennial Conference to be held at the Gold Coast, Queensland from 4–7 November 2009.

The conference is dedicated to 'Staying Between the Flags', with the aim of fostering safe clinical practice by promoting understanding of the benefits and limitations of various contemporary clinical techniques. The scientific program has been designed to address practical and highly relevant issues that concern all practitioners involved in implant dentistry, with lecture topics targeted at both the beginner and the experienced clinician. We have confirmed outstanding speakers who will contribute to an exciting three days, providing an authoritative and reliable scientific and clinical basis for the treatment of patients, as well as addressing exciting new innovations and research. Some of these internationally renowned speakers are: Prof Dr Jan Lindhe, Dr Michael Norton, Dr Ueli Grunder, Prof Joseph Kan, Dr Dietmar Weng, Dr Gabi Chaushu, Prof Niklaus Lang and Dr Richard Lazzara. Take a few extra days in conjunction with the conference and experience this wonderful loca-



tion. To kick-start the conference, we are hosting a welcome cocktail reception on Level 77 of Q1, the world's tallest residential tower, with breathtaking 360 degree views of the coast. The Gold Coast location of this conference is renowned for its sunny subtropical climate, popular surfing beaches, active nightlife and wide variety of tourist attractions. The Gold Coast is a fantastic venue all year round, but especially at the beginning of the summer when this event is to be held.

The Gold Coast is a spectacular coastal city, stretching along 70 kilometres of white sandy beaches that meet the Pacific Ocean. As a primary destination for visitors, the Gold Coast offers a myriad of entertainment opportunities

and recreational experiences. From swimming and surfing to bungee jumping and bushwalking, there are countless recreational activities on offer on the Gold Coast. The Gold Coast is Australia's major theme park capital, with major theme parks offering rides and themed attractions. Bring the family & experience all the Gold Coast has to offer!"

The 8th Biennial Conference of the Australasian Osseointegration Society will be held from 9–12 November 2011 in Adelaide Convention Center. DGZI members who are interested to participate can get more information from our office in Düsseldorf. The society president and conference president will be Davor Hribar.



ITI World Symposium 2010

30 Years of Leadership and Credibility



The International Team for Implantology (ITI), a leading academic organization dedicated to the promotion of evidence-based research and education in the field of implant dentistry, is holding the 11th ITI World Symposium from April 15 to 17, 2010 in Geneva, Switzerland. At the same time, the organization, which was founded in 1980, is celebrating its 30th anniversary. Since the first ITI World Symposium in 1998, the meeting has developed into one of the most prestigious implant dentistry events worldwide. Under the heading "30 years of leadership and credibility", a total of 104 experts from 25 countries will present on current themes and developments in the field. The following main areas will be explored at both a theoretical and practical level over the Symposium's three days:

- _ New clinical methods for diagnosis and treatment planning
- _ New and proven treatment procedures
- _ Complications in implant dentistry or dealing with reality

There will be simultaneous translation available for all the presentations in the main sessions from English into German, French, Italian, Spanish, Portuguese, Japanese, Korean, Mandarin Chinese, Russian, Turkish and Farsi. For the first time, the ITI World Symposium is complementing its main sessions with two full-day pre-Symposium courses on 14 April as well as an industry exhibition. The attractive and historic city of Geneva at the heart of Europe is the ideal location for the event. The city's excellent infrastructure in combination with the Palexpo congress center offers both exhibitors and participants excellent conditions.

About the ITI

The International Team for Implantology (ITI) unites professionals around the world from every field of implant dentistry and related tissue regeneration. As an independent academic association, it actively promotes networking and exchange among its membership. ITI Fellows and Members, who now number more than 7,000 in total, regularly share their knowledge and expertise from research and clinical practice at meetings, courses and congresses with the objective of continuously improving treatment methods and outcomes to the benefit of their patients. The ITI is active in three principal areas: research, development and education. In 30 years, the ITI has built a reputation for scientific rigor combined with concern for the welfare of patients. The organization focuses on the development of well documented treatment guidelines backed by extensive clinical testing and the compilation of long-term results. The ITI funds research as well as Scholarships for young clinicians, organizes congresses and continuing-education events and also publishes reference books such as the ITI Treatment Guide series.

_contact

implants

International Team for Implantology

ITI Center
Peter-Merian-Weg 10, 4052 Basel, Switzerland
Tel.: +41 61 270 83 83
Fax: +41 61 270 83 84
E-mail: iticenter@iticenter.ch, Web: www.iti.org

Willkommen in München am Oktoberfest!

2nd European Implant Direct Congress

September 24th - 26th 2010

2nd European Implant Direct Congress – September 24th – 26th 2010

Challenging
Conventional
Thinking in
Implant
Dentistry



Send us your best cases and
**Win trip to
Munich!**

Congress Speakers

Dr. Gerald Niznick (USA)
Dr. Ferdinando D'Avenia (Italy)
Dr. Roberto Martelli (Italy)
Dr. Pedro Peña (Spain)
Dr. Frederic Hermann (Switzerland)
Dr. Marius Steigmann (Germany)
Dr. Achim Sieper (Germany)
Dr. Roland Török (Germany)
Dr. Jan- Willem Vaartjes (Netherlands)
Dr. Marius Steigmann (Germany)

Entertaining social and cultural program

Enjoy the very popular "Oktoberfest" or BMW Drivertaining

Top participation options

5 star Package 799 Euro*
4 star Premium Package 699 Euro*
4 star Basic Package 599 Euro*
* includes accomodation from 24th to 26th, reception, entry to the congress, evening program



Register today!

www.implantdirect.eu
Tollfree Infoline 00800 4030 4030
info-eu@implantdirect.com



**Implant
Direct™**

simply smarter.

International events

2010

6th Arab-German Implantology Meeting & 2nd International Dental Congress of Oral and Dental Medicine/Cairo University

Where: Cairo, Egypt
Date: 23–26 March 2010
E-mail: drazim2001@yahoo.com
Website: www.dgzi-international.com

IDEM International Dental Exhibition and Meeting

Where: Singapore
Date: 15–18 April 2010
Website: www.idem-singapore.com

32nd Asia Pacific Dental Congress

Where: Colombo, Sri Lanka
Date: 12–16 May 2010
Website: www.apdc2010.com

4th CAD/CAM & Computerized Dentistry International Conference

Where: Dubai, UAE
Date: 13–14 May 2010
E-Mail: info@cappmea.com
Website: cappmea.com

1st Croatian-German Implantology Meeting of DGZI

Where: Hvar, Croatia
Date: 10–12 June 2010
Website: www.hvarkongres.hr

FDI Annual World Dental Congress

Where: Salvador da Bahia, Brazil
Date: 02–05 September 2010
Website: www.fdiworldental.org

40th International Congress of DGZI

Where: Berlin, Germany
Date: 01–02 October 2010
Website: www.dgzi.de

19th Annual Scientific Meeting of EAO

Where: Glasgow, Scotland
Date: 06–09 October 2010
Website: www.eao.org

AAID 59th Annual Meeting

Where: Boston, MA, USA
Date: 20–23 October 2010
Website: www.aaid.com

Greater New York Dental Meeting

Where: New York, NY, USA
Date: 26 November–01 December 2010
Website: www.gnydm.org

2011

34th International Dental Show

Where: Cologne, Germany
Date: 22–26 March 2011
E-Mail: ids@koelnmesse.de
Website: www.ids-cologne.de





1st Croatian-German implantology meeting of DGZI

Dear Colleagues,

we take great pleasure in inviting you to participate in the 1st Hvar International Dental Congress.

From 10. to 12. of June 2010., HSK - Croatian Dental Chamber in cooperation with Oral Dent company, supported by three international associations DGZI - Deutsche Gesellschaft für Zahnärztliche Implantologie e.V., IADFE - International Academy for Dental Facial Esthetics and ESCD - European Society of Cosmetic Dentistry organizes an extraordinary assembly of experts from all over the world on the island of Hvar, Croatia.

More than 40 lecturers from Europe, the United States of America and Middle East will give lectures on the island of Hvar. We organize programs for dentists, dental technicians, world Ozon Symposium, Laser Symposium, many workshops and big international exhibition. Along with the educational program, we organize luxurious entertaining social programs with numerous surprises during all three congress days.

The whole event will be held in Grand Hotel Amfora, in the town of Hvar, in the period of 10. to 12. of June 2010. It is important to mention that the Croatian Dental Chamber rated this Congress with the maximal 12 points, which ranks this Congress among the best events in Croatia in 2010.

The island of Hvar is the queen of the Croatian Dalmatian islands. It has been famous since the antique because of its important strategic and nautical position, the rich of the various historical periods, the culture and natural monuments and the literature. Thanks to the mild climate, the warm winters and pleasant summers Hvar receives many guests, scientists and travellers, who are attracted by the dense mediterranean nature, rich tradition and architecture, and nightlife.

All dental companies which are interested in participation and renting exhibition booths on this congress can find all the information on our web site www.hvarkongres.hr or can contact us directly via e-mail info@hvarkongres.hr We will be happy to provide you with detailed information.

Looking forward to welcoming you on the island of Hvar.

Sincerely Yours,

the Organizing committee

Lecturers:

Dr. David L.Hoexter - USA
 Prof.Dr. Bilal Al-Nawas - GER
 Dr. Istvan Urban - HUN
 Dr. Suheil Michael Boutros - USA
 Dr. Francesco Mintrone - ITA
 Dr. Darko Slova - CRO
 Prof. Dr. Claus Udo Fritzemeier - GER
 Dr. Mazen Tamimi - JOR
 Dr. Nadim Abou Jaoude - LBN
 Prof.Dr. Nabil Jean Barakat - LBN
 MUDr. Jiri Holahovski - CZE
 Dr. Rainer Valentin - GER
 Dr. Rolf Vollmer - GER
 Dr. Ulf Krueger Janson - GER
 Dr. Wolfgang Richter - AUT
 Dr. Luca Lorenzo Dalloca - ITA

Dr. Stefano Ardu - CHE
 Dr. Dusko Gedosev - GER
 Dr. Gregory Brambilla - ITA
 Prof. Dr. Ivica Anic - CRO
 Prof. Dr. Ivana Miletic - CRO
 Dr. Thomas Schindler - AUT
 Dr. Vanja Coric - CRO
 Dr. Fay Goldstep - CAN
 Dr. Ross W. Nash - USA
 Dr. Elliot Mechanic - CAN
 Dr. George Freedman - CAN
 Prof. Dr. Edward Lynch - GBR
 Dr. Orsolya Rigo - HUN
 Prof. Dr. Hrvoje Juric - CRO
 Prof. Dr. Bozidar Pavelic - CRO
 Dr. Zeljka Cabunac - SRB

Dr. Mark P. Collona - USA
 Dr. Zelimir Bozic - CRO
 Dr. Douglas Ness - USA
 Dr. Oscar Von Stetten - GER
 Prof. Dr. Davor Katanec - CRO

DT Lecturers:

MDT. Harald Hoer - AUT
 MDT. Roberto Iafate - IT
 CDT. Przemek Seweryniak - SWE
 DT. Jorn Trocha - GER
 MDT. Jerko Marsic - CRO
 DT. Senad Bajramagic - CRO
 DT. Leon Cebovski - CRO



HVAR 2010 CONGRESS

INTERNATIONAL DENTAL CONGRESS CROATIA

10.06.2010. - 12.06.2010.

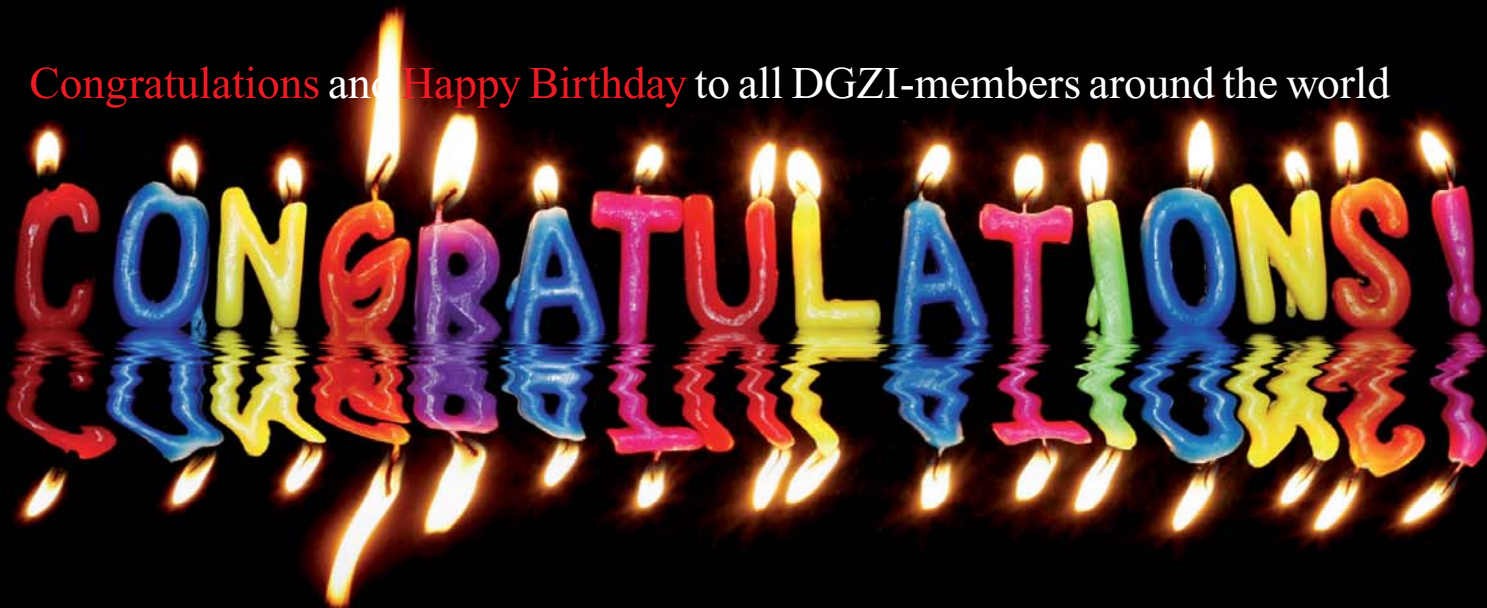

sunčani hvar hotels
 creating sunsational experiences every day



www.hvarkongres.hr

Congratulations and Happy Birthday to all DGZI-members around the world



JANUARY 2010

75th Birthday

Dr Frank LaMar (31.01.)

70th Birthday

Dr Klaus Ligensa (10.01.)

65th Birthday

Dr Peter Rick (06.01.)
Dr Jürgen Krohn (12.01.)

60th Birthday

Dr Lothar Gebert (13.01.)
Dr Aslan Mammadov (13.01.)

Dr Peter Kessler (20.01.)

Dr Wynn Zor (24.01.)
Dr Claus Hoffmann (25.01.)

55th Birthday

Dr Dieter Bauer (02.01.)
Dr Tomas Folta (04.01.)
ZA Uwe Schiminski (11.01.)
Harald Hahmann (18.01.)
Friedrich Wilhelm Birk (21.01.)
ZA Andreas Wolf (25.01.)
Dr Klaus Schwenk (29.01.)

50th Birthday

Dr Frank Wiebeck (04.01.)
ZA Markus Dehez (06.01.)
Dr Wolfgang Heer (06.01.)
Dr Sabine Sennhenn-Kirchner (11.01.)
Dr Andreas Petereit (25.01.)
Dr Georg Damen (29.01.)

45th Birthday

Dr Joachim Scholz (02.01.)
Dr Iris Beck (04.01.)
Dr Kharbouti Walid (08.01.)
Dr Martin Nemeč (08.01.)

Dr Andreas Groetz (15.01.)

Ashok Prabhakaran (17.01.)
ZA Lidia-Marianna Kubicz (29.01.)

40th Birthday

Michael Kupfer (01.01.)
ZA Jens Lührs (03.01.)
Dr Stephan Meyer (04.01.)
Dr Tamara Strauß-Matusik (08.01.)
Dr Khalil Housin (10.01.)
Dr Wolfram Hahn (21.01.)

FEBRUARY 2010

65th Birthday

Dr Gunter Müllenmeister (09.02.)
Dr Hans-Jürgen Frei (19.02.)
Dr Rolf Semmler (20.02.)

60th Birthday

Dr Klaus Op de Hipt (02.02.)
Dr Victor Rapp (02.02.)
Dr Klaus W. Schubach (05.02.)
Dr Michael Filusch (21.02.)
ZA Gerd Cyrus (26.02.)

55th Birthday

Dr Jens Wollenweber (01.02.)
Dr Ingolf G. Welsch (05.02.)
Dr Detlef Lutz (08.02.)
Dr Wolfgang Nemeč (08.02.)
Dr Fukae Masahiko (16.02.)
Dr Omar Aloum (17.02.)
Dr Gilles Chaumanet (19.02.)
Dr Thomas Springer (19.02.)

50th Birthday

Dr Lutz Pieper (04.02.)

Dr Markus Beckers (06.02.)
Dr Ulrich Hansmeier (11.02.)
Dr Volker Rick (12.02.)
Dr Detlef Bruhn (15.02.)
Dr Stephan Roth (21.02.)
Dr Ulrich Leindecker (25.02.)

45th Birthday

ZÄ Bettina Sander (01.02.)
Dr Martin Rossa (06.02.)
Dr Michael Henzler (10.02.)
Dr Ludger Schröder (10.02.)

Dr Andreas Laatz (15.02.)
Dr Dirk Droegge (12.02.)
Dr Bernward Kretschmer (21.02.)

40th Birthday

Dr Frank Jochum (01.02.)
Carsten Alfred Leitzbach (06.02.)
ZA Mario Gottschalk (15.02.)
Dr Hani Al-Kassem (25.02.)
Dr Attila Gombos (25.02.)
Dr Stefan Henkel (27.02.)
Dr Stefan Wittmann (27.02.)

MARCH 2010

75th Birthday

Dr Manutschehr Nedjat (15.03.)

65th Birthday

Dr Achim Grossehelleforth (21.03.)

60th Birthday

Dr Dirk Leusch (02.03.)
Dr Thomas Zitsch (08.03.)
Prof Dr Dr Rudolf Reich (09.03.)
Dr Rom Hortolomei (10.03.)
Gabriele Waldecker (20.03.)
Dr Michael Patzelt (22.03.)
Dr Detlev Glas (29.03.)

55th Birthday

Dr Bruno A. C. Austermann (05.03.)
Dr Hassan Al-Khansa (06.03.)
Dr Renate Pellech (06.03.)
Dr Volkmar Hartung (11.03.)
Dr Ahmad Ibrahim Rayyan (14.03.)
Dr Michael Maass (16.03.)
Dr Andree Kramer (23.03.)
Dr Bechara El Lazkani (25.03.)

50th Birthday

Dr Roger Holstein (05.03.)
ZTM Ulrich Schütte (05.03.)
Dr Hans-Joachim Lohmann (06.03.)

Dr Stefan Sommer (10.03.)
Dr Dirk Jaskolla (13.03.)
Dr Peter Fröling (16.03.)
Dr Jürgen Pipke (19.03.)
Dr Dirk Plassmann (30.03.)
Dr Mathias Peter Christian Sommer (31.03.)

45th Birthday

Dr Georg Peter (01.03.)
Dr Matthias Strugala (06.03.)
Dr Guido Heesch (14.03.)
Dr Sören Wandel (17.03.)
Dr Ramin Yachkaschi (24.03.)
Dr Ralph Dietrich (30.03.)

40th Birthday

Dr Thomas Schrage (02.03.)
Claudia Tjindra (08.03.)
Dr Jürgen Hellmer (12.03.)
Roy Riefenstahl (14.03.)
Dr Ioannis Ioannou (17.03.)
Marcus Mohr (28.03.)

40th INTERNATIONAL ANNUAL CONGRESS OF THE DGZI

Essential Oral Implantology

October 1-2, 2010, Berlin, Germany

Anniversary Conference



40 YEARS OF DGZI
1970-2010
 **DGZI**
Deutsche Gesellschaft für
Zahnärztliche Implantologie e.V.

Gold Sponsor



Silver Sponsor



Bronze Sponsor



Please fax this form to: +49-3 41/4 84 74-2 90

More information:

40th INTERNATIONAL ANNUAL CONGRESS OF THE DGZI

October 1-2, 2010, Berlin, Germany

office stamp

Manufacturer news

camlog

CAMLOG/ALTATEC underscore their long-term commitment to the Wimsheim location

The above-average success of the CAMLOG® Implant System in recent years is also a constant challenge to its manufacturer, ALTATEC GmbH in Wimsheim, Germany. By 2007, the just 3-year-old building was no longer equal to the increasing demands, making it necessary to plan an extension. With the recently commissioned buildings in Wimsheim, production area has now doubled to 15,000 sqm, and the potential for further developments has been created. Not only does ALTATEC GmbH benefit from the increased production facilities, but for CAMLOG Vertriebs GmbH, also located in Wimsheim, the new extension additionally offers the opportunity for organizational improvements. This gave rise, for example, to a spacious CAMLOG auditorium for user training and a separate area for logistical support of external CAMLOG training and continuing education events several hundred of which are held annually in Germany alone. In Wimsheim, however, not only new functional buildings were the result, but rather an architectural translation of the known CAMLOG qualities. Transparency, for example, is one of those qualities to which CAMLOG/ALTATEC attaches great importance. This sense of clarity and perspective is clearly conveyed by the building's interior characterized by the numerous sight lines and outlooks in the spirit of Le Corbusier, who said, "The view needs to roam." All construction materials used are recyclable or can at least be disposed of in an environmentally friendly manner. The entire premises including the 216 new parking places for staff and the ex-



tensive green roof areas are drained by an elaborate retention basin system, and the water is returned to the ground in a natural way. CAMLOG/ALTATEC look forward to showing the more than 100 international visitor groups annually in Wimsheim both brand-new high-tech production as well as architectural esthetics 'made in Germany'.

CAMLOG Biotechnologies AG

Margarethenstrasse 38
4053 Basel, Switzerland
E-mail: info@camlog.com
Web: www.camlog.com

W&H

The new Elcomed— Powerful for surgery

Top quality and power — the new Elcomed SA-310 from W&H has some impressive features. With just one operating stage and a total of four buttons, the user is able to adjust all the important parameters. In addition to torque, motor speed and quantity of liquid, six different programs can also be accessed from the clearly laid out display. The user is thus able to individually save the most important recurring operational procedures. In addition, the attached instruments are also preset on the display in order to guarantee optimum power transmission. The Elcomed motor not only achieves speeds of 50,000 rpm but is also the lightest and shortest motor in its class. It can be used with all surgical instruments that have an ISO connection. Together with the surgical handpieces/contra-angles from W&H, it can achieve a torque of 80 Ncm on the rotary instru-

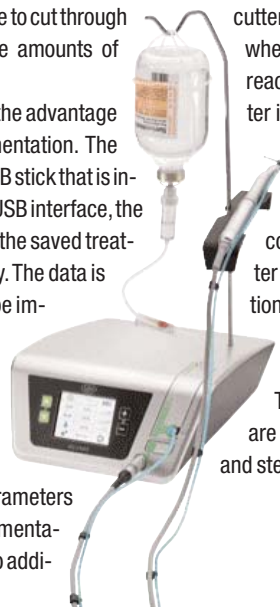
ment. This high torque guarantees an extremely high motor power. The user is able to cut through the bone without exerting large amounts of force.

The new Elcomed also features the advantage of simple and complete documentation. The data are stored directly on the USB stick that is included in the delivery. Using the USB interface, the user is therefore able to transfer the saved treatment stages to the PC very easily. The data is displayed as a csv file, ready to be imported into standard analysis programs, and as a bitmap file. The documented information contains the torque curve and the screenshot of the Elcomed display on which all the set parameters can be viewed. Complete documentation is therefore guaranteed at no additional cost.

To enable the implant to heal as quickly as possible and with the least possible stress, the

new Elcomed SA-310 has an automatic thread cutter function. The thread cuts into the bone when the foot control is activated. Upon reaching the pre-set torque, the thread cutter immediately switches to reverse operation, in order to remove any bone chips. This process can be stopped by releasing the foot control. If the foot control is activated again, the thread cutter function will restart in forward operation. In this way, compression on the bones is minimised and potential bone damage avoided.

The motor, cable and handpiece holder are naturally thermo washer disinfectable and sterilizable.



W&H Deutschland GmbH

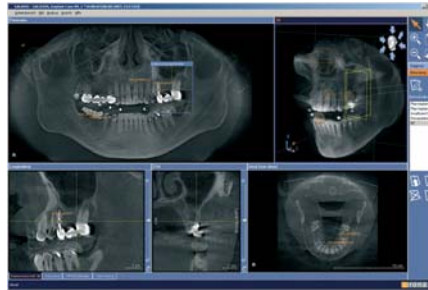Raiffeisenstraße 4
83410 Laufen, Germany
E-mail: office.de@wh.com
Web: www.wh.com

SIRONA

New X-ray software facilitates a diagnosis-oriented mode of working

The new Sirona GALAXIS 1.7 software enables dentists to adopt a diagnosis-oriented approach when working with the GALILEOS 3D X-ray system. The user has the option of inserting "bookmarks" and descriptive texts directly into the X-ray images. Previously saved images can be retrieved with a single mouse click.

The starting point when analyzing a 3-D volume is the standard panoramic view. During the navigation



process the user is able to mark any conspicuous findings by setting a so-called diagnosis point, accompanied by personal notes. These notes can either be freely worded or else composed of predefined text blocks. The notes are saved automatically together with information about the view mode, position, zoom, brightness and contrast. The X-ray images and all the patient-related information can be retrieved with a single mouse click. If required, reports can be generated automatically using REPORTER 1.0, the optional documentation software for GALILEOS.

Sirona Dental Systems GmbH

Fabrikstraße 31
64625 Bensheim, Germany
E-mail: contact@sirona.de
Web: www.sirona.com

Dr. Ihde Dental

KOS T—the implant for equipping the region of the maxillary tuberosity

In the region of the maxillary tuberosity the mucosa often is between 5 mm and 7 mm thick. This makes it difficult to work on correctly placed KOS® implants, whose neck-length is less than 3 mm. For this reason a new version of this system has been launched by Ihde Dental: KOS® T. The implant is available in the diameters 3.2 mm, 3.7 mm and 4.1 mm and in the lengths of 15 mm and 17 mm. The KOS® T implant is typically placed in a flapless procedure. Only in ex-



tremely narrow bone sites a flap is necessary. Like all KOS-implants also KOS® T provides an immediate 3-D corticalisation of the bone. Thereby an increase of minerals nearby the implant is found instantly and this allows immediate loading in most of the cases. Anchoring the implant in addition in the opposing cortical bone further increases the primary and final stability. KOS® T is supplied with a double-sandblasted, osmoactive® surface configuration. The osmoactive coating was developed by Swiss researchers and it acts like an anti-bacterial barrier: it selectively prevents bacterial growth and promotes the growth of bone building os-

teoblasts at the same time. This coating works on the osmotic principle and it is unique in the world and applied to all implants produced by Ihde Dental.

Dr. Ihde Dental GmbH

Erfurter Straße 19
85386 Eching, Germany
E-mail: info@ihde.com
Web: www.ihde-dental.de

BEGO Implant Systems

BEGO Semados® Mini-Implant

Modern, minimally-invasive dental implant technology has advanced in leaps and bounds. BEGO Implant Systems was the first dental implant manufacturer to develop high performance implants based on bionic principles and turn them into marketable items. This enables dynamic loads to be supported with implants of approx. 3 mm diameter and less which, otherwise, could only have been borne by standard implants with diameters exceeding 3.5 mm. BEGO Semados® Mini-Implants with diameters of 2.7 mm, 2.9 mm and 3.1 mm and lengths of 11.5 mm, 13 mm and 15 mm are the solution of choice for the multitudes of edentulous people in the world. In Germany alone, more than 3 million people are fully edentulous. By using BEGO Semados® Mini-Implants, BEGO clients throughout the world



can help provide many people with a "firm dentition". Multiple options are available for prosthetic restorations—a perfectly matched Wirobond® MI bar system, two different ball abutments in the height of 1.5 mm and 4 mm for different gingiva heights and tapering abutments for filling narrow anterior gaps leave nothing to be desired.

BEGO Semados® Mini-Implants are made of proven, pure grade 4 titanium and manufactured in Germany. The contoured design also makes use of the compressing thread used for BEGO Semados® RI implants. The proven TiPure^{plus} surface is highly pure and ultrahomogeneous. It possesses an above average capacity for binding proteins to ensure rapid osseointegration.

BEGO Implant Systems GmbH & Co. KG

Technologiepark Universität
Wilhelm-Herbst-Straße 1
28359 Bremen, Germany
E-mail: info@bego-implantology.com
Web: www.bego-implantology.com

AD

100% SAFETY DOCTOR - PATIENT GOAL REACHED

Since our beginnings, we have always been focused on quality and innovation toward the battle against cross-contamination and infections.

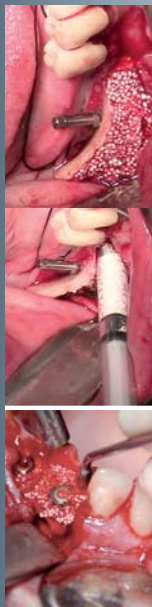In the last 20 years, we have ensured safety and protection to you and your patients, with advanced and reliable products. Tools that represent the ideal solution for who is operating in dentistry, implantology/oral surgery and general surgery.

With Omnia sure to be safe.

Surgical Line **Safety Line** **EXIT**

OMNIA
Disposable Medical Devices

OMNIA S.p.A.
Via F. Delnevo, 190 - 43036 Fidenza (PR) Italy
Tel. +39 0524 527453 - Fax +39 0524 525230
VAT. IT 01711860344 - R.E.A. PR 173685
Company capital € 200.000,00
www.omniaspa.eu



easy-graft®CRYSTAL

easy-graft® CRYSTAL

Ingenious: Simple handling and accelerated osteoconduction for long-term volume preservation.

Order your free test sample over the internet!

Degradable Solutions AG
Wagistrasse 23
CH-8952 Schlieren
Phone: +41 43 433 62 60
www.degradable.ch
dental@degradable.ch

DS
DENTAL

Nobel Biocare

Nobel Biocare appoints new Head of Global Marketing & Products

Nobel Biocare today announced that Hans Geiselhöringer has been appointed Executive Vice President Global Marketing & Products and a member of the Executive Committee (EC) as of 10 February 2010. Hans Geiselhöringer (German, 1968) is a certified dental technician. He further holds a certification in anaplastology and epithetics and graduated in technical business administration from the IHK in Germany. During his career as a dental professional Hans Geiselhöringer specialized in dental laboratory management, implantology and ceramics.

In 1998, he founded his own dental laboratory specializing in implantology, anaplastology, functional and esthetic reconstruction, and imaging technologies. Since 2008 he has been heading the company's NobelProcera business and developed it into the most comprehensive CAD/CAM offer on the market today. Hans Geiselhöringer has

published a wide range of articles about CAD/CAM dentistry, digital dentistry, prosthetics restorations and prosthetic manufacturing processes. He is a member of various international dental associations and a member of several review boards at international dental publications.

"Hans Geiselhöringer has been instrumental in advancing our NobelProcera technology and broadening our product and material offer over the last two years. Robert Gottlander, who has successfully led the marketing function over the last five years, will concentrate on our increasing number of key accounts. Both appointments support our drive to increase customer focus and to be the partner of choice in dentistry."

Nobel Biocare Holding AG

P.O. Box, 8058 Zurich Airport
Switzerland

E-Mail: info@nobelbiocare.com

Web: www.nobelbiocare.com



NSK

NSK launches new Surgical Micromotor System

'Surgic XT' series has received preferable reputation from global market as a reliable surgical micromotor system. As a successor model of its series, new Surgic XT Plus has been designed to realize the maximum safety during operation. Surgic XT Plus improves the efficiency of controlling torques delivering to the handpiece and automatically calibrates the implant micromotor and the handpiece to the rotational resistance of each individual handpiece prior to the operation (Advanced Handpiece Calibration—AHC). For taking into account of user friendliness, both optic and non-optic implant micromotors can easily be at-

tached to Surgic XT Plus just by changing the micromotor. NSK implant micromotors for Surgic XT Plus are dramatically durable and lightweight by embodying the advantages of titanium. Also, the large LCD panel clearly makes it easier for clinicians to see and check the displayed data. The display shows all parameters and status at the same time. Surgic XT Plus is the reliable surgical micromotor system from NSK offering you accurate and powerful torque with impressive power.

Key Features

- _ Wide speed range of 200 – 40,000 min⁻¹
- _ Powerful torque: 5–50 Ncm
- _ High Power: 210W
- _ Advanced Handpiece Calibration—AHC for safety during operation
- _ Large LCD panel with ease operation
- _ 8 programs can be set individually
- _ Selectable optic/non-optic brushless micromotor
- _ Excellent durable, lightweight micromotor body reduces hand fatigue and improves balance
- _ Low noise and low vibration with minimal heat generation



NSK Europe GmbH

Elly-Beinhorn-Str. 8
65760 Eschborn, Germany
E-Mail: info@nsk-europe.de
Web: www.nsk-inc.com







المؤتمر الأردني الثاني والعشرون لطب الأسنان

THE 22nd JORDANIAN DENTAL CONGRESS

٢٠١٠ / ٤ / ٢ - ٣ - ٣٠

فندق الرويال - عمان الأردن

March 30 th - April 2 nd , 2010

Le Royal Hotel , Amman - Jordan

الحديث في طب الاسنان السريري

AN UPDATE IN CLINICAL DENTISTRY

www.jda.org.jo
congress@jda.org.jo

M.I.S.

Official opening of MIS's new headquarters in Israel

MIS's relocation to its newly constructed company premises, which cover a total area of over 30,000 m², including 10,000 m² of production area, marks a further chapter in the success story of the Israeli dental company. A group of around 30 visitors from Germany, who had travelled to Israel at the invitation of MIS Germany to see the new MIS headquarters, were able to see for themselves the growing success of the company embodied by this new building. In keeping with its corporate philosophy of 'Make it Simple', the company has from its inception pursued a coordinated and demand-oriented product policy and is now represented by its product innovations in over 60 countries throughout the world. Collaborative partnerships with scientific and research institutes form



an additional strategy that has been systematically pursued by the company up to the present day, leading, for example, to the development of the 'Trio Concept': three different implants with a matching prosthesis product range on internal and external hex connections. The company has since extended its collaborative partnerships throughout the whole world. The final breakthrough came in 2004 with MIS's presentation of the SEVEN implant, which firmly established the company as one of the leading international dental companies engaged in scientific

research and development. Further innovations followed, such as MISTRAL, the M-Guide planning kit or the UNO one piece implant. As the company became more successful, training formed an increasing part of its activities, as illustrated, for example, by the foundation of the DITC (the Dental Implant Training Center) in the USA in 2005. Particular emphasis has been placed in recent years on biomaterials. What initially began with 4BONE—an in-house product range for bone augmentation—has since been supplemented by further developments including 4BONE RCM, the natural and resorbable collagen membrane. Further developments in this field are expected in the next few years as the German visitors to Israel could clearly see for themselves.

MIS Implants Technologies GmbH

Paulinenstraße 12A
32427 Minden, Germany
E-mail: service@mis-implants.de
Web: www.mis-implants.de

Straumann

Straumann launches digital solutions platform

Straumann is presenting an array of integrated computer-based technologies that have been designed to increase confidence, safety, precision and reliability in implant and restorative dentistry. Under the new umbrella brand of 'Straumann Digital Solutions', the company now offers state-of-the-art computer-guided surgery, intra-oral scanning, and CAD/CAM prosthetics to specialists, general dentists and dental laboratories in various markets around the world. With these new innovations, a complete Straumann tooth—from implant to final crown—is now available from a single provider. Straumann is the only lead-

ing manufacturer in implant, restorative and regenerative dentistry to offer all these services. The company will also present a number of new products and features that will be launched over the course of the year.

Straumann Digital Solutions offer the flexibility of open, state-of-the-art systems together with seamless connectivity to one of the world's leading implant, restoration and regenerative systems, in addition to guaranteed Straumann quality, service and network support.

Institut Straumann AG

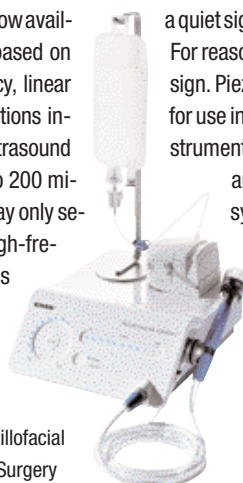
Peter Merian-Weg 12
4052 Basel, Switzerland
E-mail: info@straumann.com
Web: www.straumann.com

EMS

Precise and gentle: Bone sections using ultrasound

Piezon Master Surgery by EMS means that the Piezon method is now available in dental, oral and maxillofacial surgery. The method is based on piezoceramic ultrasound waves which produce high-frequency, linear oscillations forwards and back. According to EMS, these vibrations increase the precision and security of surgical applications. The ultrasound operation enables a micrometric section cut in an area of 60 to 200 micrometers with only a slight loss in bone mass. The ultrasound ray only selectively cuts hard tissue; soft tissue remains untouched. The high-frequency vibrations with permanent cooling also mean that there is little blood in the operating area and thermal alterations are avoided. Piezon Master Surgery can be used in parodontal, oral and maxillary surgery as well as in implantology. Specific indications are osteotomy and osteoplastics, extraction, apical root resection, cystectomy,

For dental, oral and maxillofacial surgery: Piezon Master Surgery



extraction of bone blocks, sinus lift, nerve transposition, jaw ridge division and extraction of autologous bones. According to the manufacturer's details operation using the touch board is easy and hygienic. By moving your fingers over the notches of the operating elements, the power as well as the flow rate of the isotonic solution can be regulated. The LED reacts to the moving fingers by emitting a quiet signal, even if a hand is in a glove or if an additional protective film is used. For reasons of hygiene, corners, joints and chinks have been avoided in the design. Piezon Master Surgery is offered as a basic system with five instruments for use in implantation preparation. The development of the exclusive Swiss Instruments Surgery is based on the experience of 25 years' continual research and covers various applications, according to EMS. The user has optional systems for tooth extraction, retrograde root channel preparation and procedures on bones at his disposal. All systems contain autoclavable Combitorques and a Steribox.

EMS Electro Medical Systems GmbH

Schatzbogen 86
81829 München, Germany
E-mail: info@ems-ch.de
Web: www.ems-ch.de

submission guidelines:

Please note that all the textual components of your submission must be combined into one MS Word document. Please do not submit multiple files for each of these items:

- _ the complete article;
- _ all the image (tables, charts, photographs, etc.) captions;
- _ the complete list of sources consulted; and
- _ the author or contact information (biographical sketch, mailing address, e-mail address, etc.).

In addition, images must not be embedded into the MS Word document. All images must be submitted separately, and details about such submission follow below under image requirements.

Text length

Article lengths can vary greatly—from 1,500 to 5,500 words—depending on the subject matter. Our approach is that if you need more or less words to do the topic justice, then please make the article as long or as short as necessary.

We can run an unusually long article in multiple parts, but this usually entails a topic for which each part can stand alone because it contains so much information.

In short, we do not want to limit you in terms of article length, so please use the word count above as a general guideline and if you have specific questions, please do not hesitate to contact us.

Text formatting

We also ask that you forego any special formatting beyond the use of italics and boldface. If you would like to emphasise certain words within the text, please only use italics (do not use underlining or a larger font size). Boldface is reserved for article headers. Please do not use underlining.

Please use single spacing and make sure that the text is left justified. Please do not centre text on the page. Do not indent paragraphs, rather place a blank line between paragraphs. Please do not add tab stops.

Should you require a special layout, please let the word processing programme you are using help you do this formatting automatically. Similarly, should you need to make a list, or add footnotes or endnotes, please let the word processing programme do it for you automatically. There are menus in every programme that will enable you to do so. The fact is that no matter how carefully done, errors can creep in when you try to number footnotes yourself.

Any formatting contrary to stated above will require us to remove such formatting before layout, which is very time-consuming. Please consider this when formatting your document.

Image requirements

Please number images consecutively throughout the article by using a new number for each image. If it is imperative that certain images are grouped together, then use lowercase letters to designate these in a group (for example, 2a, 2b, 2c).

Please place image references in your article wherever they are appropriate, whether in the middle or at the end of a sentence. If you do not directly refer to the image, place the reference at the end of the sentence to which it relates enclosed within brackets and before the period.

In addition, please note:

- _ We require images in TIF or JPEG format.
- _ These images must be no smaller than 6x6 cm in size at 300 DPI.
- _ These image files must be no smaller than 80 KB in size (or they will print the size of a postage stamp!).

Larger image files are always better, and those approximately the size of 1 MB are best. Thus, do not size large image files down to meet our requirements but send us the largest files available. (The larger the starting image is in terms of bytes, the more leeway the designer has for resizing the image in order to fill up more space should there be room available).

Also, please remember that images must not be embedded into the body of the article submitted. Images must be submitted separately to the textual submission.

You may submit images via e-mail, via our FTP server or post a CD containing your images directly to us (please contact us for the mailing address, as this will depend upon the country from which you will be mailing).

Please also send us a head shot of yourself that is in accordance with the requirements stated above so that it can be printed with your article.

Abstracts

An abstract of your article is not required.

Author or contact information

The author's contact information and a head shot of the author are included at the end of every article. Please note the exact information you would like to appear in this section and format it according to the requirements stated above. A short biographical sketch may precede the contact information if you provide us with the necessary information (60 words or less).

Questions?

Kristin Urban (Managing Editor)
k.urban@oemus-media.de

implants
international magazine of oral implantology



Publisher

Torsten R. Oemus
oemus@oemus-media.de

CEOs

Ingolf Döbbbecke
doebbecke@oemus-media.de

Jürgen Isbaner
isbaner@oemus-media.de

Lutz V. Hiller
hiller@oemus-media.de

Chief Editorial Manager

Dr Torsten Hartmann (V. i. S. d. P.)
hartmann@dentalnet.de

Editorial Council

Dr Friedhelm Heinemann
friedhelmheinemann@web.de

Dr Roland Hille
dr-hille@t-online.de

Prof Dr Dr Kurt Vinzenz
kurt.vinzenz@aon.at

Dr Torsten Hartmann
hartmann@dentalnet.de

Dr Suheil Boutros
SMBoutros@aol.com

Editorial Office

Kristin Urban
k.urban@oemus-media.de

Eva Kretzschmann
e.kretzschmann@oemus-media.de

Executive Producer

Gernot Meyer
meyer@oemus-media.de

Designer

Sarah Fuhrmann
s.fuhrmann@oemus-media.de

Customer Service

Marius Mezger
m.mezger@oemus-media.de

Published by

Oemus Media AG
Holbeinstraße 29
04229 Leipzig, Germany
Tel.: +49-341/4 84 74-0
Fax: +49-341/4 84 74-2 90
kontakt@oemus-media.de

Printed by

Messedruck Leipzig GmbH
An der Hebemärchte 6
04316 Leipzig, Germany

implants

international magazine of oral implantology
is published in cooperation with the German
Association of Dental Implantology (DGZI).

DGZI President

Dr Friedhelm Heinemann
DGZI Central Office
Feldstraße 80, 40479 Düsseldorf, Germany
Tel.: +49-2 11/1 69 70-77
Fax: +49-2 11/1 69 70-66
office@dgzi-info.de

www.dgzi.de
www.oemus.com

Copyright Regulations

_implants international magazine of oral implantology is published by Oemus Media AG and will appear in 2010 with one issue every quarter. The magazine and all articles and illustrations therein are protected by copyright. Any utilization without the prior consent of editor and publisher is inadmissible and liable to prosecution. This applies in particular to duplicate copies, translations, microfilms, and storage and processing in electronic systems.

Reproductions, including extracts, may only be made with the permission of the publisher. Given no statement to the contrary, any submissions to the editorial department are understood to be in agreement with a full or partial publishing of said submission. The editorial department reserves the right to check all submitted articles for formal errors and factual authority, and to make amendments if necessary. No responsibility shall be taken for unsolicited books and manuscripts. Articles bearing symbols other than that of the editorial department, or which are distinguished by the name of the author, represent the opinion of the afore-mentioned, and do not have to comply with the views of Oemus Media AG. Responsibility for such articles shall be borne by the author. Responsibility for advertisements and other specially labeled items shall not be borne by the editorial department. Likewise, no responsibility shall be assumed for information published about associations, companies and commercial markets. All cases of consequential liability arising from inaccurate or faulty representation are excluded. General terms and conditions apply, legal venue is Leipzig, Germany.

implants

international magazine of oral implantology



 **Subscribe now!**

One issue free of charge!

I hereby agree to receive a free trial subscription of **implants international magazine of oral implantology** (4 issues per year).

I would like to subscribe to **implants** for € 44* for German customers, € 46* for customers outside Germany, unless a written cancellation is sent within 14 days of the receipt of the trial subscription. The subscription will be renewed automatically every year until a written cancellation is sent to OEMUS MEDIA AG, Holbeinstr. 29, 04229 Leipzig, Germany, six weeks prior to the renewal date.

Reply per Fax +49-(0) 3 41/4 84 74-2 90 to OEMUS MEDIA AG or per E-mail to grasse@oemus-media.de

Last Name, First Name

Company

Street

ZIP/City/County

E-mail

Signature

Notice of revocation: I am able to revoke the subscription within 14 days after my order by sending a written cancellation to OEMUS MEDIA AG, Holbeinstr. 29, 04229 Leipzig, Germany.

Signature

*Prices include shipping and VAT

IM 1/10


Holbeinstr. 29, 04229 Leipzig, Germany, Tel.: +49-(0) 3 41/4 84 74-0, Fax: +49-(0) 3 41/4 84 74-2 90, E-Mail: grasse@oemus-media.de

OEMUS MEDIA AG



BEGO is an official
co-partner of the German
Olympic teams for
Vancouver 2010
London 2012

GO FOR GOLD.



Bionic Engineering Design transfer of
optimal living nature solutions
to technical products

BEGO Semados®
Mini-Implant

BEGO Semados®
S-Implant

BEGO Semados®
RI-Implant

BIONIC ENGINEERING DESIGNED IMPLANTS

BEGO Semados® patented Implants embody:

- Indication-optimised contour design
- Function-optimised implant-abutment-connection
- High purity and ultra-homogenous-surface
- Polished rim for an inflammation-free gingiva-attachment
- 100 % German design – 100 % German manufacturing
- Value for money

Are You Interested?

info@bego-implantology.com

www.adwork.de

BEGO 
Partners in Progress

www.bego-implantology.com