

# Laser-assisted frenectomy in pediatric dentistry

**Author\_** Dr Gabriele Schindler-Hultzsch, Germany

## \_Abstract

The greatest challenge in pediatric dentistry is the child's fear of pain, fear of dental treatment, fear of noise and fear of something they do not know. This is the reason why dental surgery in pediatric dentistry is a special challenge for the child, the parents and the dentist.

Dental fear, anxiety and dental behavior management problems often go together with a perceived lack of control. This leads to a lack of compliance and a high percentage of untreated and unhealed children (Klingberg 2008; Butz, Goebel 2006). Laser-assisted frenectomy offers a treatment alternative for children, providing a more convenient therapy.

## \_Introduction

Labial frenectomy is the surgical procedure of removing the frenulum. A labial frenulum is the tissue attached to the upper lip and extends into the gums between the two upper front teeth. The labial frenulum may sometimes extend and intrude into the inner, palatal side of the upper front teeth. A labial frenulum also appears at the lower teeth between the two lower

central incisors or as lingual frenulum attached to the tongue and the inner, lingual side of the two lower central incisors.

Indications for frenectomy are a diastema of the upper or lower central incisors, retraction of the gingiva, pain during tooth brushing or orthodontic problems.

Often no treatment is necessary because most of these "abnormal" frenula and diastema disappear as the permanent incisors and canines erupt (Koch, Poulsen 2009). The best time for frenectomy is shortly after the beginning of the eruption of the permanent canines.

Frenectomy can be performed conventionally by scalpel or laser-assisted with either diode lasers at wavelengths of 810 nm, 940 nm, 980 nm, Nd:YAG (1,064 nm), CO<sub>2</sub> lasers (10,600 nm) or lasers of the Erbium-group (Er:YAG 2,940 nm or Er,Cr:YSGG: 2,780 nm), (Gutknecht 2007).

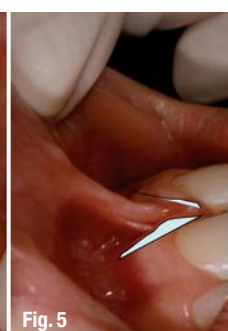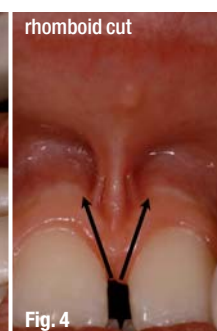
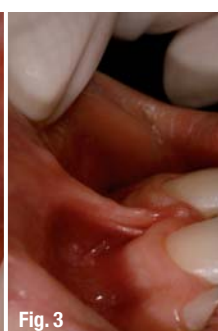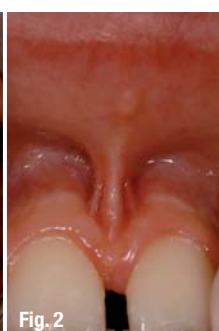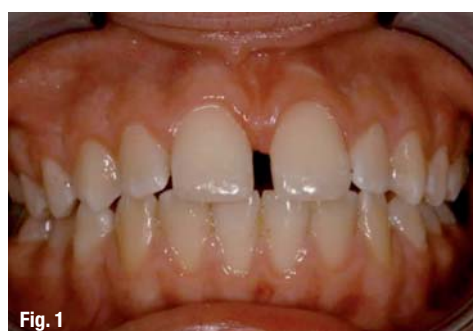## \_Clinical Procedure

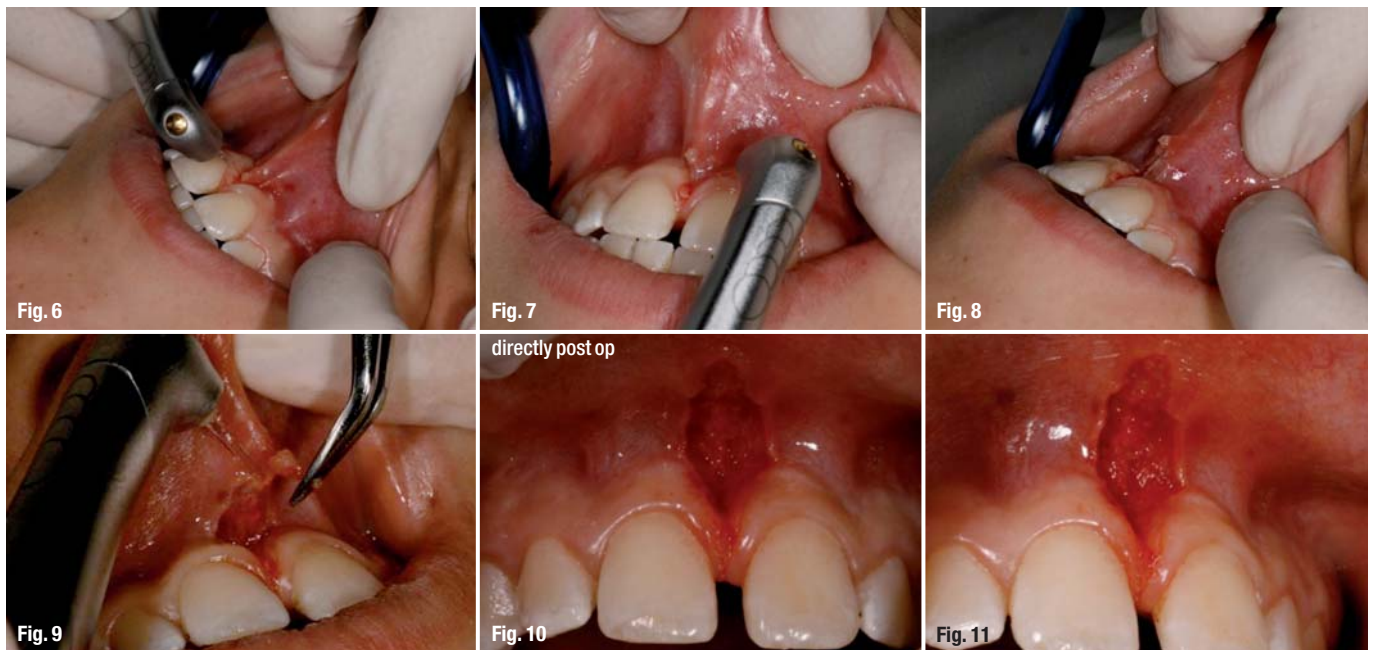
In this article laser-assisted frenectomy will be presented with the clinical procedure of the

**Fig. 1** \_Initial status – persisting diastema between the two upper central incisors.

**Figs. 2 & 3** \_Initial status front side: strong, three way labial frenulum.

**Figs. 4 & 5** \_Cutting technique.





Laserkids® concept. The Laserkids® concept (Schindler 2008) is a comprehensive guideline for laser-assisted pediatric dentistry including aspects of dental anxiety, behavioral management, desensitizing, special laser parameters and treatment procedures for pediatric dentistry from the first visit to lifetime care (Schindler, Gutknecht 2009).

In this case the general medical and dental anamnesis shows a healthy 12 year old boy who was very anxious and did not want to have surgery because of previous bad experiences. He was referred from the orthodontist for frenectomy because of the persistent gap between the two upper central incisors. The referral for frenectomy was late because canines were fully erupted. Further orthodontic treatment was considered.

The clinical findings were a strong, three way labial frenulum extending to the gap between the two upper central incisors leading to a diastema mediale with an incisal spacing of 5 mm and a cervical spacing of 4 mm. The patient showed an Angle Class I denticulation with a slight protrusion of the front teeth, a convex profile and a swallowing dysfunction.

The diagnosis was a diastema mediale between the two upper central incisors with spacing of the upper central incisors. The treatment plan was laser-assisted frenectomy because of the boy's fear of surgical treatment. The clinical procedure followed the Laserkids® concept.

The treatment procedure for the upper labial frenectomy took 8 minutes. In this case topical and

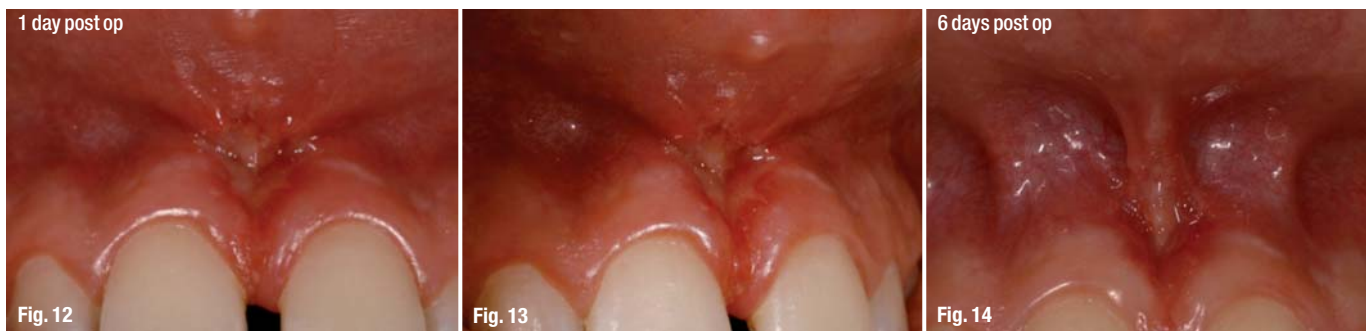local anesthesia was used because of the strong and deep, three way frenulum. In many cases only topical anesthesia is necessary. After applying Cherry GINGICAIN® GEL (Belpo Co., Inc. Camarillo, CA, USA) and waiting for 30 seconds, 1,0 ml local anesthesia Ultracain® D-S forte 1:100,000 Epinephrine (Sanofi-Aventis Deutschland GmbH, Germany) was applied buccally on the left and right side of the frenulum.

Safety goggles were put on the patient, mother, assistant and dentist while waiting for the anesthetic to work. The time was used to desensitize the child and to get acquainted. A tell-show-show-do technique was used to explain the laser beam, its function and the procedure. The laser beam was shown first on a puppet and then on the finger of the child, following the Laserkids® concept. The surgical procedure started when the child felt comfortable. The frenectomy was completed within 4:30 minutes.

For this frenectomy the Er,Cr:YSGG laser with a wavelength of 2,780 nm was used. The procedure was performed with a MC3 tip, 1,5–2 W, 30 Hz, pulse duration 700 µs, 7 % water and 11 % air, in contact mode.

The first cut was placed incisally in V-form from the right side at an angle. The second cut followed from the left at an angle with the tissue under tension to allow the edges of the fibres to be seen. The next step was an extension to a rhomboid shape, cutting fibres at depth to avoid later relapse and retraction of the tissue. The fibres and excessive tissue were removed. Almost no bleeding occurred during

**Figs. 6–9** Treatment procedure.  
**Figs. 10 & 11** Post-operative follow-up.



**Fig. 12–15** \_Post-operative follow-up.

surgery, enabling a clear view for the surgeon and making the procedure fast. No further coagulation was necessary. No sutures were required. A swab was placed for 30 seconds at the end of the laser treatment. The compliance of the patient during treatment was very good.

No painkillers and no antibiotics were prescribed. The patient's post-operative instructions were to take no milk products, no alcohol, no smoking, no caffeine and no theine for the day, and not to participate in sports that day. The lip should be left down and cooled. The teeth should be brushed as always. Repeat visits after one day, six days and four months.

Post-operative findings after one day showed no complications. No bleeding, no pain and no swelling appeared. The healing process was very fast, showing fibrine coating after one day and good vascularisation. There was slight scarring after 4 months. The spacing reduced by about 1,5 mm incisally. The patient was referred back to the orthodontist.

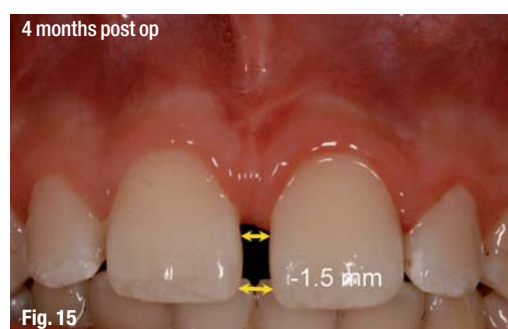## Conclusion

Laser-assisted dental surgery has benefits compared to conventional treatment methods: selective, minimally invasive, less traumatic, and less pain. There was almost no bleeding and therefore a good, clear view for the surgeon during the treatment. The bactericidal and biostimulating effect of the laser resulted in very good and rapid healing.

The advantages for this patient were obvious—less post operative pain, no swelling. In addition, no sutures were necessary and a further appointment for suture removal was not needed. The compliance and acceptance of the child was high. Laser-assisted frenectomy in pediatric dentistry following the Laserkids® clinical procedure is a gentle treatment option.

## References

1. Butz CL, Goebel C. 2006. Die Inhalationssedierung mit Sauerstoff und Stickoxid in der Kinderzahnheilkunde. Quintessenz 57, 959–963.
2. Gutknecht N. 2007. Proceedings of the 1<sup>st</sup> International Workshop of Evidence Based Dentistry on Lasers in Dentistry. Quintessence Publishing Co. Ltd.
3. Klingberg G. 2008. Dental anxiety and behavior management problems in pediatric dentistry—a review of the prevalence, measurement and aetiology. Eur Arch Paediatr Dent. Feb; 9 Suppl 1: 11–5.
4. Koch G., Poulsen, S. 2009. Pediatric Dentistry: a clinical approach. 2<sup>nd</sup> edition. Blackwell Publishing Ltd. 306–307.
5. Schindler G. 2008. The Laserkids® Concept—Treatment Concept for laser-assisted pediatric dentistry. Master's thesis RWTH Aachen University.
6. Schindler G., Gutknecht N. 2009. The Laserkids® Concept—Treatment Concept for laser-assisted pediatric dentistry. Lasers Med Sci 24:496–497.



## \_contact

laser

### Dr Gabriele Schindler-Hultzsich

MSc, DDS  
Münchenerstraße 16  
86551 Aichach, Germany  
Tel.: +49 8251 7070  
Fax: +49 8251 1820  
E-mail: schindler@laserkids.de



# The Experts Agree is #1

7 Watts for Only **\$4,995**

2.5 Watts for Only **\$2,495**



Indications for use include soft tissue surgery, endodontic and periodontic treatments, and tooth whitening.

#### Features:

- 7 Watts of power
- Pulse/continuous modes
- 8 Customizable presets
- Color touchscreen
- Adjustable aiming beam
- Multiple language menu
- 3-year warranty
- Training DVD



A Limited Edition (LE) Picasso Lite is available in pink.

AMD LASERS proudly announces that we are "tasting for a cause" in the fight against breast cancer. Through June of 2010, we have pledged to donate \$15,000 to the National Breast Cancer Foundation.



Indications for use include soft tissue surgery, endodontic and periodontic treatment.

#### Features:

- 2.5 Watts of power
- Pulse/continuous modes
- 3 Customizable presets
- Adjustable aiming beam
- 2-year warranty
- Training DVD



**Ross Nash, DDS**  
Nash Institute  
Charlotte, NC



**Glenn van As, DMD**  
International Lecturer  
N. Vancouver, Canada



**Ron Kaminer, DDS**  
International Lecturer  
Master of Laser Dentistry  
Hewlett, NY



**Larry Rosenthal, DDS**  
Director, Aesthetic Advantage  
New York, NY



**Arun K. Garg, DMD**  
International Lecturer  
Aventura, FL



**James Jesse, DDS**  
International Lecturer  
Master of Laser Dentistry  
Colton, CA



**Jim Dunn, DDS**  
Associate Professor of  
Restorative Dentistry  
Loma Linda University  
Loma Linda, CA



**George Freedman, DDS**  
International Lecturer, Author  
Toronto, Canada



**Rodrick Loud, DDS**  
Private Practitioner  
Shreveport, LA



**Fay Goldstep, DMD**  
International Lecturer  
Toronto, Canada

Visit us at  
**BOOTH #515**  
at the **Chicago Mid-Winter Show**



7405 Westfield Blvd  
Indianapolis, IN 46240 USA  
[www.amdlasers.com](http://www.amdlasers.com)

Tel: (866) 999-2635  
Tel: +1 (317) 202-9530  
Fax: +1 (678) 868-4108

