

Apical microsurgery—

Part IV: The REB and REP

Author_ Dr John J. Stropko, USA

The amount or degree of the root-end bevel (REB) is of utmost importance and should be precisely planned after considering the overall crown–root ratio, presence of posts or other obstacles, root anatomy, and periodontal status of the tooth. According to previous research, 98% of canal system ramifications occur in the apical 3 mm.¹ If the bevel is long (traditionally 25° to 45°), an excessive amount of root structure would have to be removed to include the apical 3 mm on the palatal or lingual part of the root's apical canal system (especially in roots with multiple canals).

operator to overcome while trying to visualise the true long axis of the canal system (Fig. 2); the longer the bevel, the greater the tendency for the operator to leave more of the palatal or lingual aspect of the root intact.

As it is difficult to visualise the long axis of the tooth, the resultant retro-preparation is not as likely to be within the long axis of the canal. This concept is extremely important and the primary reason for the occasional, unintentional perforation of the retro-preparation to the lingual or palatal (Figs. 3a & b). Another important consideration—with a bevel as close to 0° as possible—is that the cavo-surface marginal dimensions of the root-end preparation (REP) will be considerably decreased. Therefore, the restoration will be easier to place and have less chance of leakage.

The root anatomy is especially important when there are more than two canals in one root. This occurs most commonly in maxillary bicusps and in the mesial roots of nearly all molars. It has been shown that as many as 93% of the mesio-buccal (MB) roots of the maxillary first molars have a second canal (MB2).² However, the operator has to be constantly aware that multiple canals can occur in any root, no matter which tooth is being operated on. If there is an isthmus present, it can usually be seen with the Operating Microscope (OM) if the root has been adequately bevelled and stained with methylene blue.

The refinement of the bevel is best accomplished with a surgical length 1171 carbide tapered fissure bur (Brassler) in a 45° handpiece (SybronEndo; Fig. 4). No air exists from the working end of these handpieces, which nearly eliminates the possibility of an air embolism or air embolism beneath the flap. A standard high-speed handpiece should never be used for the above reason. On occasion, the refinement of the bevel can cause additional bleeding due to an enlargement of the crypt. The operator should address any crypt management problem due to a newly created crypt before proceeding any further. Remember that it is of utmost importance to complete one step before proceeding to the next step.

Fig. 1 Illustration of the effect that different bevel angles have on root length, including missing potential lingual anatomy.

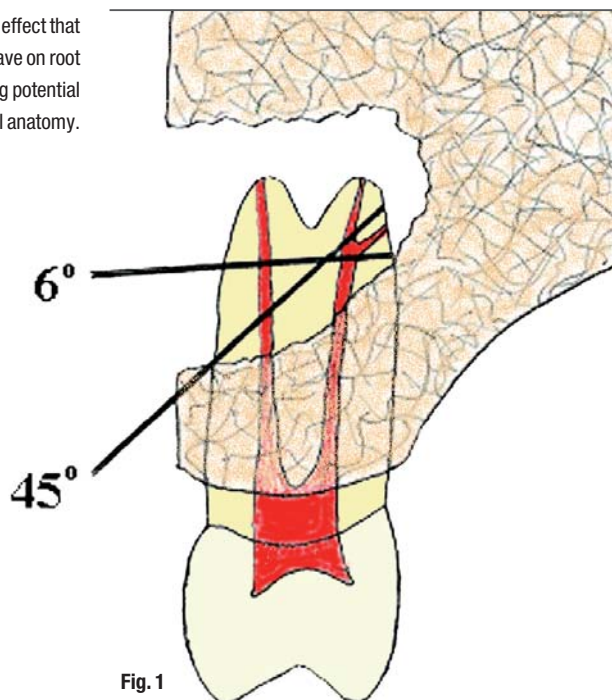


Fig. 1

If the bevel is closer to 0°, the lingual 3 mm is easier to remove; thus, more root structure can be conserved, improving the crown–root ratio. With a long bevel, there is also an increased risk of completely missing some important palatal or lingual anatomy, especially if the operator is in any measure attempting to be conservative in order to preserve the crown–root ratio as far as possible (Fig. 1). The long bevel also creates a spatial problem that is generally impossible for the

After the REB has been refined and crypt management is completely under control, the apical surface is rinsed and dried with a Stropko Irrigator. The clean and dried surface is then stained with methylene blue. It is important to allow the methylene blue to remain on the tooth for just a short period before gently rinsing and drying again, in order to enable inspection of the stained surface. Normally, a fresh, white piece of Telfa is reinserted for better lighting. If there are any fractures, isthmus tissue or accessories present, the staining will greatly enhance the operator's ability to visualise them. Also, the methylene blue will stain the periodontal ligament and enable the operator to ensure the apex has been completely resected (Figs. 5a & b). If there is an accessory canal present, the easiest solution is usually to bevel past it and re-stain; or, on occasion, the accessory can be troughed-out, leaving the bevel as is.

When two canals are present in the same root, it is necessary to prepare for an isthmus between the two canals even if the staining did not reveal one. It has been shown that in the MB roots of the maxillary first molars with two canals, the 4 mm section displayed a partial or complete isthmus 100% of the time.² This, combined with the finding that two canals in the same root in maxillary molars present clinically at least 93% of the time in the MB root of the maxillary first molar, lends importance to always preparing the isthmus area of the REB.³ Although staining does not always reveal the presence of an isthmus, it may lie just below the REB surface, only to be exposed during the remodelling of the surface of the bevelled root that normally takes place during the healing process (Fig. 6). The rule is to prepare an isthmus when there are two canals in one root.

The preparation of the REP is best accomplished using ultrasonics. For the most part, they are all dependable and have a good service record. There are multitudes of ultrasonic tips from which to choose. The newer diamond-coated and vented tips (ProUltra tips, DENTSPLY Tulsa Dental; KiS tips, Obtura/Spartan) are much more efficient and especially good at re-

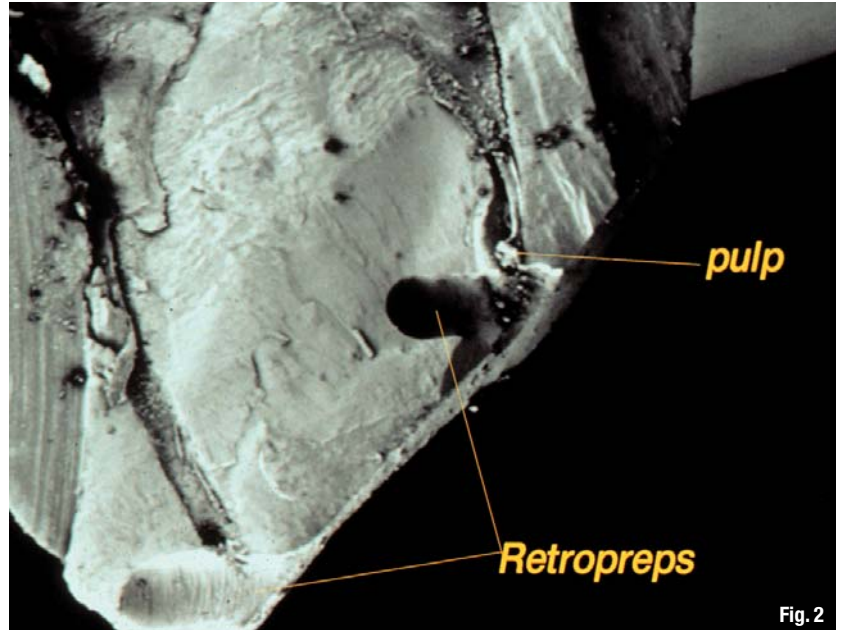


Fig. 2

moving gutta-percha. Rather than the brand of the ultrasonic unit or type of tip, the most important consideration is the manner in which the instrument is used. The tendency for the new operator is to use the ultrasonic unit in the same manner (regarding pressure) as the handpiece. The secret is to start at a low power setting and use an extremely light touch. The lighter the touch, the more efficient the action of the tip will be. The correct amount of coolant is also important. If too much spray is used, visibility and cutting efficiency will both be decreased. If too little spray is used, there will be insufficient cooling and overheating, which can lead to micro-cracks.

Fig. 2 Long bevel with round bur preparations, demonstrating angulation and orientation problems. (Courtesy: Dr Gary Carr)

Various left and right tips of various angles are necessary on occasion, but in most cases anterior tips will suffice. If the canal is large and/or filled with gutta-percha, a larger, coated tip can be used most efficiently. The key is to: 1) slow down; 2) be gentle; 3) use a light, brushing movement; and 4) carefully regulate the power setting of the ultrasonic unit. The power setting will vary greatly depending on the tip being used and nature of the preparation task.

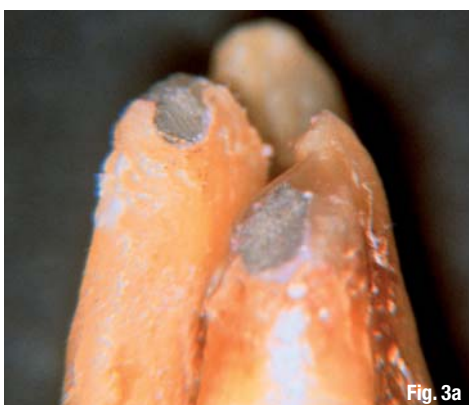

Fig. 3a

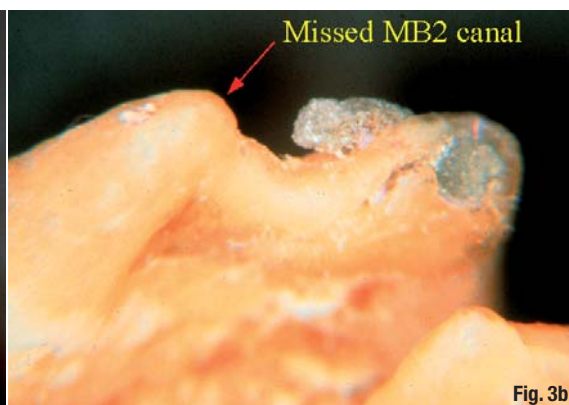
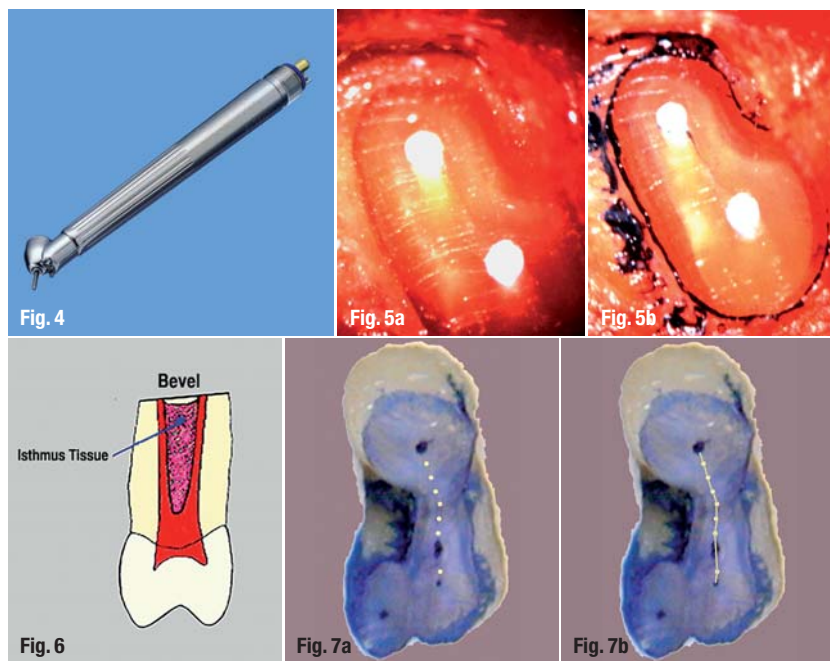


Fig. 3b

Figs. 3a & b Inadequate and acute 45° bevel clearly demonstrates the way perforations can occur and canals can be missed. The operator's view from the buccal (Fig. 3a). View of actual occurrence, as completely missed by the operator (Fig. 3b).



The needle inserted into the Stropko Irrigator is then bent to a similar angle to that of the ultrasonic tip to be used for the REP (Fig. 8). Always keep in mind that cleanliness and dryness are essential for good visibility when using the OM.

The buccal aspect of the internal wall of the REP is of particular interest. Dr Richard Rubinstein was the first to point out that often this area is not debrided, owing to the angulation of the ultrasonic tip within the canal system during the REP. If there is some gutta-percha streaming up the side of the wall and the preparation is finished, the best thing is to use a small plugger and fold the gutta-percha coronally so the wall is clean once more. It is usually futile to attempt to remove that gutta-percha with an ultrasonic tip.

The ideal REP should: 1) be within the long axis of the canal system; 2) have parallel walls; 3) be at least 3 mm in depth (including the isthmus portion of the preparation); 4) be adequately extended to include any buccal or lingual variations of the canal system; 5) be clean (free of a smear layer); and 6) be dry and ready to accept any type of root-end filling material.

After completion of the REP, it should be rinsed and dried once more with the Stropko Irrigator. The REP is re-inspected, using micro-mirrors and the varying powers of the OM and/or endoscope, in order to ensure it is clean and within the long axis of the canal system. At this time, the REP is etched with blue 35% phosphoric acid gel (Ultra-Etch, Ultradent) to remove the smear layer. After 15 to 20 seconds, the REP is thoroughly rinsed and dried with the Stropko Irrigator and re-examined with the OM. If all is satisfactory, a 20-second application of 2% chlorhexidine will help eliminate any residual organisms. After a final rinse and dry, the REP is ready for the root-end fill.

In the final two parts of this series, we will discuss *Retrofill materials and techniques* (Part V) and *Sutures, suturing technique and healing* (Part VI).

Editorial note: A complete list of references is available from the publisher.




Fig. 4 A surgical handpiece, such as Impact Air (SybronEndo), should be used to prevent the possibility of an air embolism.

Figs. 5a & b Unstained (a) and stained (b) resected root surfaces. (Images courtesy of Dr Gary Carr).

Fig. 6 An illustration of an isthmus lying just below the surface that would not be evident even after staining with methylene blue.

Fig. 7a The series of 'dots' permit easy and accurate preparation of an isthmus in a root end that is very thin.

Fig. 7b With the water spray still off, the 'dots' are connected to establish a tracking groove in order to guide a more aggressive ultrasonic tip in finishing the REP.

Fig. 8 For ergonomics, the modified tip used in the Stropko Irrigator should be bent to an angle similar to that of the ultrasonic tip that will be used during the REP.

For the preparation of an isthmus, an uncoated, fine-pointed tip (CT-1, SybronEndo) is inserted into the ultrasonic unit and used to create a precise series of multiple 'dots' on the stained or imaginary line between the two canals. For the dot technique, the ultrasonic unit is set at a low power setting but inactivated, the water spray is turned off, a CT-1 tip is placed exactly where desired, and the rheostat is tapped for just an instant. The process is repeated as many times as necessary until there is a series of 'dots' (Fig. 7a). Then, while the water spray is still off, the dots are gently connected to create the initial, shallow but precise tracking groove (Fig. 7b). The dot technique is of great value, especially when there is concavity present and the width of the bevelled root is very thin mesially to distally. The resultant groove serves as a definite guide for the completion of the isthmus portion of the REP. Then, with the water spray turned back on and the power increased slightly, a pointed, coated tip can be used more aggressively to deepen the tracking groove. In this manner, accuracy is completely controlled and there is no chance of slipping while preparing the isthmus in a very thin root. On occasion, if the walls of the preparation become too thin, further bevelling may be necessary.

Throughout the REP process, it is important to use the Stropko Irrigator to rinse and dry the REP in order to ensure it is kept within the long axis of the canals and all debris is being removed as planned. Various sizes of micro-mirrors or an endoscope can be used to periodically inspect the preparation and confirm accuracy. A pre-cut and pre-bent 25-gauge endodontic irrigating needle (Monoject, Carson Dental) works well for this purpose. The notched end is removed by rapidly bending the end third rapidly back and forth with Howe Pliers (Magnum Ortho) until it separates.

_contact	roots
<p>Dr John J. Stropko 8757 E. Double Eagle Dr. Carefree, AZ 85377 USA E-mail: topendo@aol.com</p>	

SCIENCE IS GLOBAL

NEW LEARNING EXPERIENCE



BEYOND ENDODONTICS:

ENDOEXCELLENCE, MICRO-DENTISTRY,
DENTAL TOMOGRAPHY (CBCT), BUILDUP OF ROOT
CANAL TREATED TEETH, DENTAL TRAUMATOLOGY,
PERIODONTICS & IMPLANTOLOGY

www.rootssummit2010.com

Barcelona
r o o t s
2 0 1 0
u m m i t

June 3rd, 4th & 5th

- Hands-on and lectures with 20 experts from across the world
- Meet & Interact Face-to-Face with Colleagues & Experts
- Network friendly
- Further information and registration under: www.rootssummit2010.com