

The importance of endodontics in implant treatment planning

Author_ Dr Jose M. Hoyo, USA

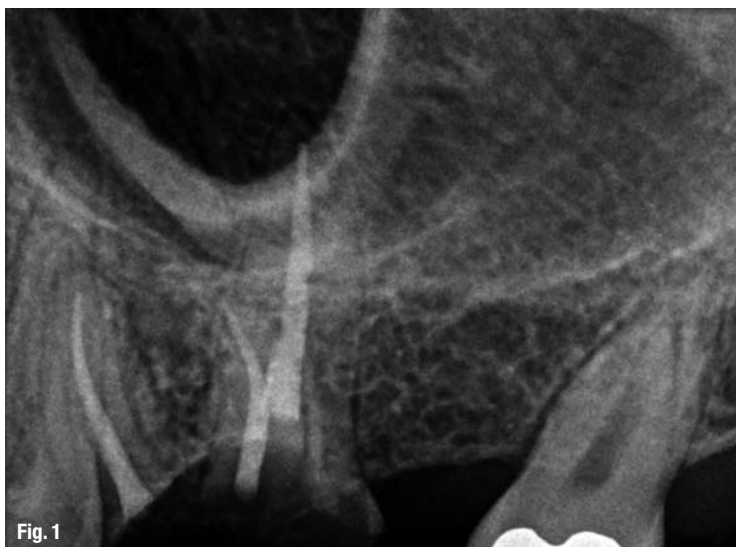

Fig. 1_Pre-op radiograph prior to extraction.

There's a new vision in dentistry that is gradually being recognised and is referred to as the endo-implant algorithm. This new approach considers the role of the endodontist as critical in considering whether a tooth can be saved or whether extraction and replacement with a dental implant is the correct treatment protocol. An endodontist is in the unique position to evaluate critical factors leading to endodontic failures in order to determine whether another endodontic procedure will lead to a predictable and successful outcome. Should the outcome not be favourable, then extraction and replacement with a dental implant would be the protocol to follow.

In considering the ideal treatment plan, it is imperative to provide the patient with all treatment options, as well as the financial cost and procedures associated with each treatment option. The patient is thus given the opportunity to make an educated decision as to the best treatment protocol for him or her. The information presented to the patient should include the endodontist's opinion regarding which treatment option is more practical and predictable.

_Case study

A patient with a non-contributory medical history was referred to my office for evaluation of the maxillary left first molar. The patient was asymptomatic, and the tooth had been endodontically treated by a general dentist approximately seven months prior to the consultation and had never been restored. Clinically, it presented extensive decay, probing depths of 3 mm all around, exposure of the obturation material to the oral cavity, and no temporary restoration. Radiographically, no peri-apical lesions were detected, and the bone levels around the tooth were adequate (Fig. 1).

In order to determine the integrity of the tooth structure, some excavation was performed using 4.5 x magnification and supplementary illumination, provided by a fibre-optic headlight, with a dental rubber dam for isolation. After the removal of some decay, a bitewing X-ray was taken (Fig. 2) and the following was determined:

- a) the floor of the pulp chamber was too shallow;
- b) it was too close to perforation and
- c) the peri-radicular dentine was insufficiently strong to support a permanent restoration.

These critical factors, in my opinion, rendered the tooth non-restorable. A cotton pellet and Cavit were placed in the access cavity and a follow-up call with the referring dentist was conducted in order to update him on the condition of his patient and to determine what recommendations should be given regarding the tooth. It was recommended to the patient that the tooth be extracted and the socket preserved through a minor grafting procedure. This would allow for an ideal amount of bone to receive a dental implant approximately four to six months later. It was also recommended that he receive some orthodontic treatment prior to the placement of the

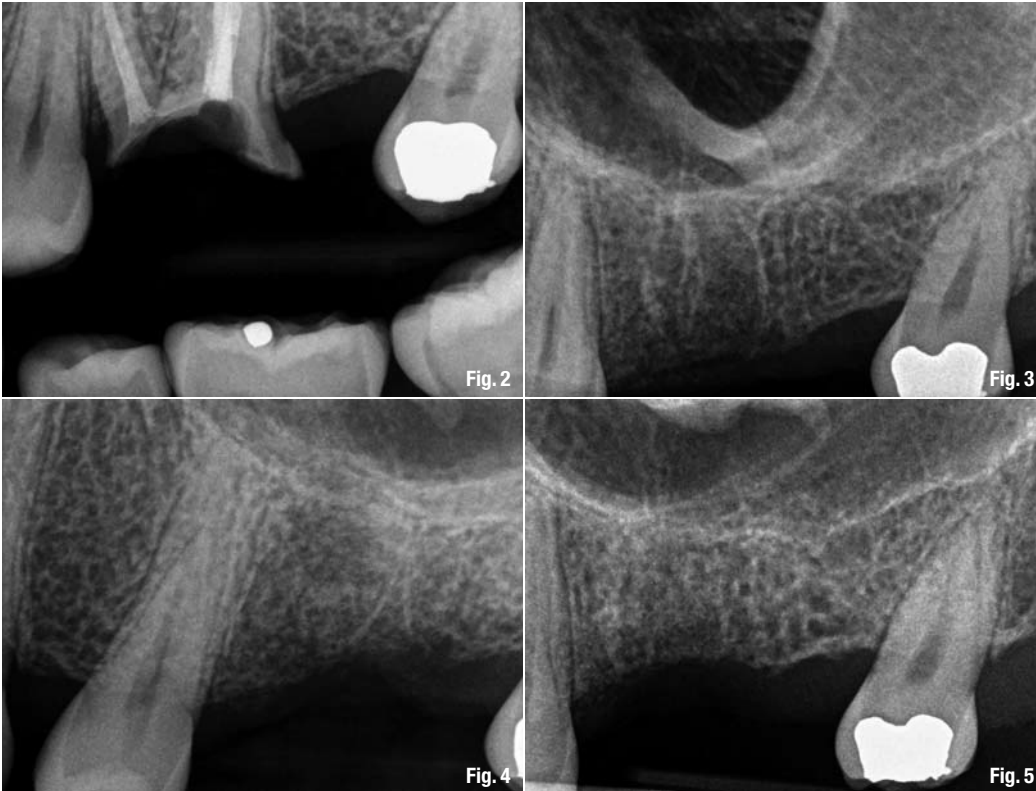


Fig. 2_ Bitewing X-ray after decay had been removed.

Fig. 3_ Grafted socket following extraction.

Fig. 4_ Peri-apical film showing healing of grafting material after four months.

Fig. 5_ Pre-op film on the day of surgery.

implant so that all the diastemas would be closed and the dentition properly aligned for this procedure.

The patient clearly understood the concept and the logistics of the orthodontic treatment recommended but expressed no interest in this approach.

_The bigger picture

It is very important in evaluating treatment using implants to consider the whole dentition and not just the space or tooth in question. It should be borne in mind that implants, unlike teeth, do not move, so if there are any misalignments in the dentition, orthodontic treatment prior to implant therapy is imperative should the patient proceed with the dental implant at a later stage. If the treatment plan is not in this sequence, the dental implant could become a challenging obstacle during the orthodontic treatment.

The patient was prescribed Amoxicillin 500mg (one every six hours, beginning two days before the next appointment) and Chlorhexidine rinses (three times a day, also beginning two days before the next appointment). The use of tartar control toothpaste was also recommended in order to avoid staining of teeth. On the day of surgery, the patient's blood pressure was 119/73 with a heart rate of 76.

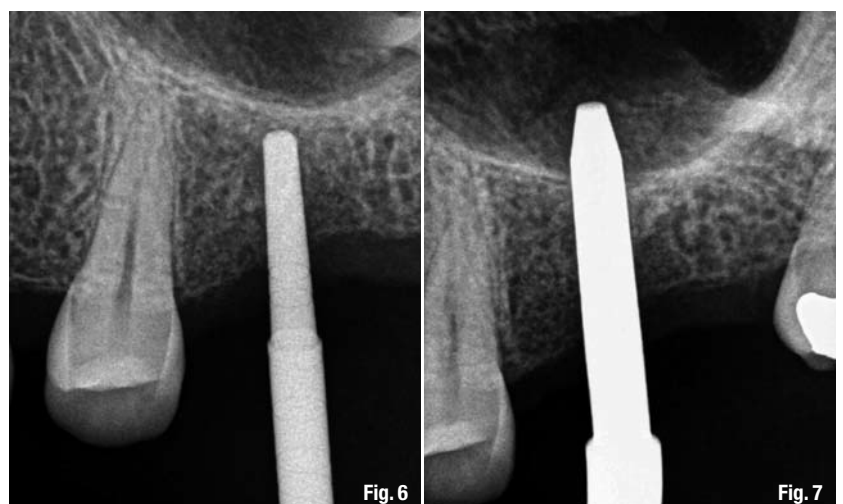Under local anaesthetic (Lidocaine 2% HCl with epinephrine 1/50,000 x 2 cpl) and using a dental rub-

ber dam, magnification loupes and supplementary illumination, the tooth was sectioned into three pieces. The rubber dam was removed, and using PDL-Evator elevators (Salvin) all three roots were extracted without any complications. Spoons were used to curette the socket in order to clean any granulation tissue and engage the cancellous bone. This crucial step results in some bleeding and thus promotes angiogenesis. The crest of the interradicular bone was engaged with the socket cupped part of a XIVE osteotome (DENTSPLY Friadent), and a sinus lift was performed using the Summer's technique.

There were no signs of a sinus perforation based on the Valsalva test. The sockets and sinus-lift area were

Fig. 6_ Guide pin in osteotomy following use of 2 mm pilot drill.

Fig. 7_ Radiograph showing XIVE osteotome in place during the osteotomy.



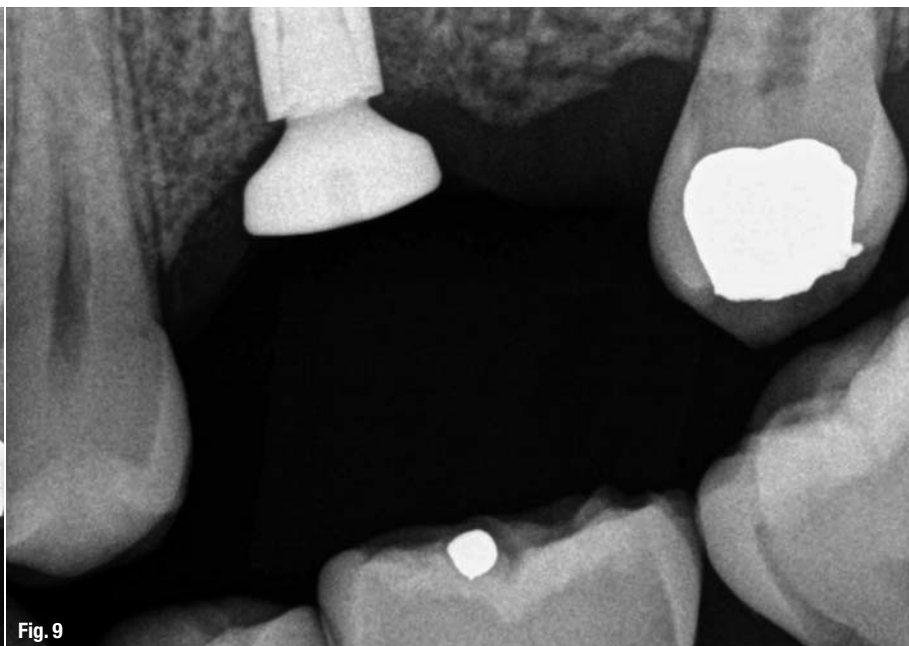
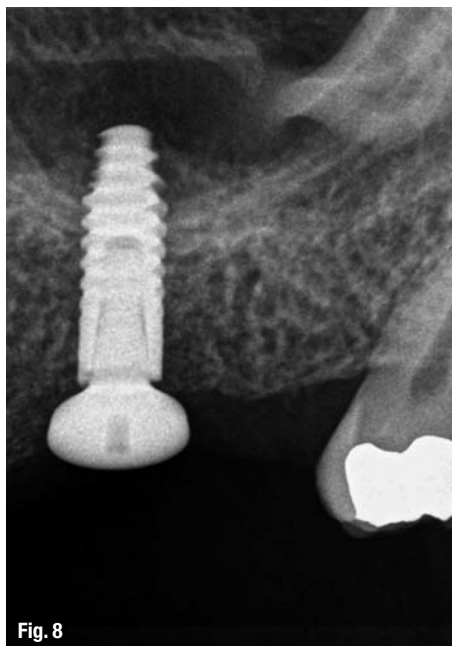


Fig. 8 Radiograph of implant with sulcus former (healing abutment); the apical portion of the implant is under the Schneiderian membrane.

Fig. 9 Bitewing X-ray showing sub-crestal placement of implant with sulcus former in place.

then grafted with a mixture of DBX and MCP using a marshmallow technique. This grafting mixture helps the site produce its own bone in terms of mineral and collagen from the DBX, and it provides a better scaffold effect from the MCP. The area was covered with a PTFE membrane, slightly tucked under the periosteum (not more than 2 mm). Sutures were done with polyglycolic acid using a criss-cross four-x-corner technique (Fig. 3).

Removing the sutures


The sutures were removed two weeks later. Two weeks after suture removal, the patient was seen again for the removal of the membrane. This was done by gently picking at the membrane with cotton pliers and exerting pull on it—there is often no need for anaesthesia. The benefit of using this allograft cocktail is that the waiting period for re-entry was approximately four to six months versus six to nine had a xenograft been used. The quantity and the quality of the bone appeared to be much better with the use of this allograft cocktail.

At the time of re-entry, the patient's blood pressure was 113/69 with a heart rate of 64 (Figs. 4 & 5). Under local anaesthetic (Lidocaine 2 per cent HCl with epinephrine 1/50,000 x 2 cpl), a tissue punch access was done using a 3.8 tissue punch XiVE drill (DENTSPLY Friadent).

The pilot drill from the ANKYLOS implant system (DENTSPLY Friadent) was then used to drill 6 mm, just short of the sinus floor (Fig. 6). A series of XiVE osteotomes, from size 2.0 up to 3.4, were used to perform a sinus lift using the Summer's technique. The osteotomy was prepared to a depth of 11 mm (Fig. 7).

A Valsalva test was performed to ensure that the sinus had not been perforated. An ANKYLOS implant A11 (3.5 mm x 11 mm) was placed and primary stability was obtained. The density of the bone perceived as D-3 during the drilling stage, likely changed to D-2 with the use of the osteotomes. The implant-transfer mount was removed, as was the cover screw that came pre-mounted inside the implant, and a 1.5 mm sulcus former (healing abutment) was placed into the implant (Figs. 8 & 9).

This case clearly demonstrates one of the reasons that endodontists are becoming increasingly involved in implant dentistry. They are able to provide a comprehensive evaluation of the tooth in question, and they are able to present the patient with the best options based on clinical assessment.

_about the author	roots
	<p>Dr Jose M. Hoyo graduated from the University of Puerto Rico School of Dentistry in 1984. He received his Certificate of Advanced Graduate Studies in Endodontics from Boston University's Henry M. Goldman School of Graduate Dentistry in 1994.</p> <p>He practices as a specialist in Endodontics and Implant dentistry in southern Massachusetts and can be contacted at drjhoyo@aol.com.</p>



DENTAL TRIBUNE STUDY CLUB C.E. SYMPOSIA AT IDEM, SINGAPORE

APRIL 16 - 18, 2010 TIMES ARE LISTED IN LOCAL SINGAPORE TIME, WHICH IS 12 HOURS AHEAD OF EST.



The Dental Tribune Study Club Symposia at IDEM offer an ambitious schedule of continuing education lectures in various dental disciplines. Each day will feature a selection of lectures led by experts in the field, providing an invaluable opportunity to learn from opinion leaders, while earning ADA CERP C.E. Credits. Find us directly on the exhibition floor at J30.

THE SYMPOSIA SESSIONS ARE FREE FOR IDEM VISITORS. WALK-INS WELCOME. THE LECTURES WILL ALSO BE BROADCAST LIVE ONLINE, FOR THOSE WHO ARE NOT ABLE TO MAKE IT TO SINGAPORE. LIVE ONLINE ATTENDANCE IS ALSO FREE.

APRIL 16

11:00 - 12:30 - AFFORDABLE SOFT TISSUE DIODE LASERS with Dr. George Freedman and Dr. Fay Goldstep

1:00 - 2:30 - DEATH OF A SALES MAN; BIRTH OF THE HELPING PROFESSIONAL with Peter Barry

3:00 - 4:30 - A MINIMALLY INVASIVE APPROACH TO PREDICTABLE DIRECT COSMETIC RESTORATIONS with Dr. Shriju Joshi

APRIL 17

11:00 - 12:30 - TOOTH WEAR AND NEW TECHNOLOGY TO MANAGE DENTIN HYPERSENSITIVITY with Dr. Fotinos Panagakos

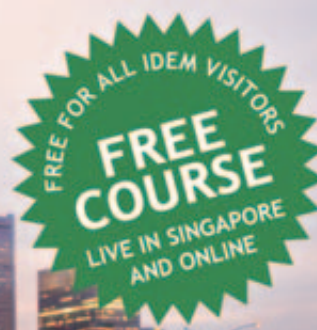1:00 - 2:30 - LASERS, RESTORATIVES AND THE DENTAL MEDICAL CONNECTION - PART I with Dr. George Freedman and Dr. Fay Goldstep

3:00 - 4:30 - EXPLORING NEW FRONTIERS IN INDIRECT AESTHETIC RESTORATION with Dr. Shriju Joshi

APRIL 18

11:00 - 12:30 - LASERS, RESTORATIVES AND THE DENTAL MEDICAL CONNECTION PART II with Dr. George Freedman and Dr. Fay Goldstep

1:00 - 2:30 - RISK OF CORONARY HEART DISEASE IN ASSOCIATION WITH PERIODONTITIS AND PERIIMPLANTITIS with Dr. Hans-Dieter John



REGISTER ON WWW.DTSTUDYCLUB.COM

Program is subject to change.



QUALIFY FOR ADA CERP C.E. CREDITS!
Dental Tribune America LLC is a recognized ADA CERP provider.