

# Managing maxillary molars

Author\_Dr Mark Dreyer, USA

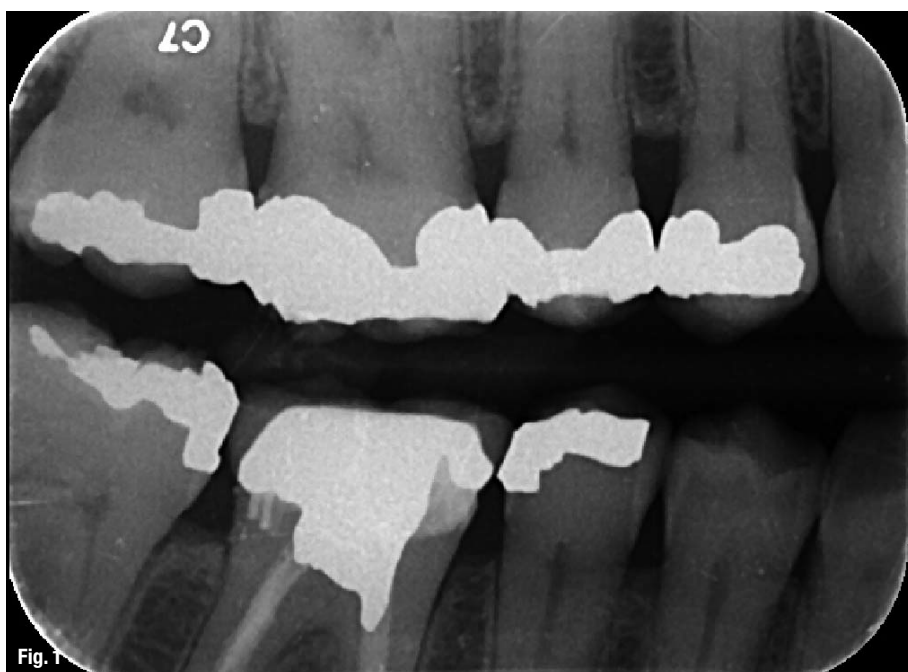


Fig. 1

**\_Maxillary first molars** are notable for their complex root-canal system morphology. The mesio-buccal (MB) roots are characterised by an irregular ovoid morphology, resulting in an isthmus or fin of pulpal tissue extending palatally to the principle MB canal. This case report presents steps taken to address this anatomy in order to maximise the disinfection and debridement of the root-canal system. Failure to address this anatomic complexity may lead to persistence or recurrence of endodontic disease.

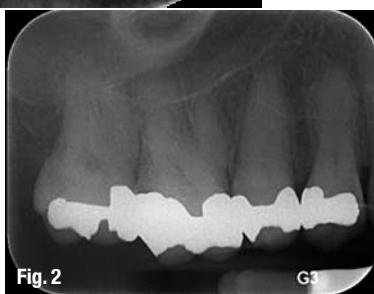

Fig. 2

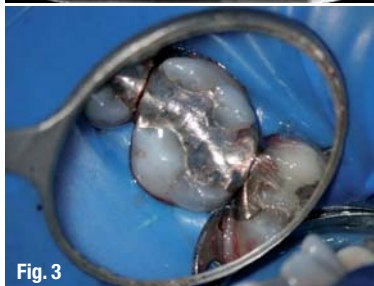
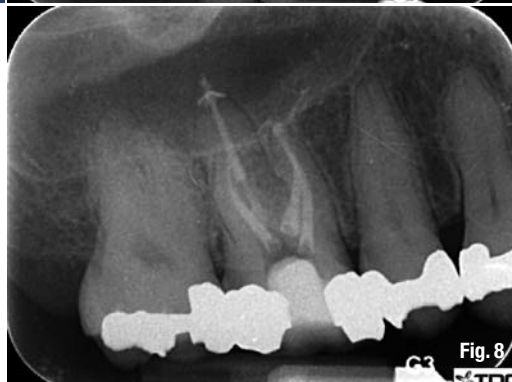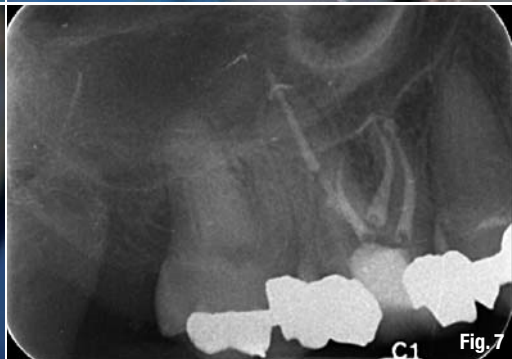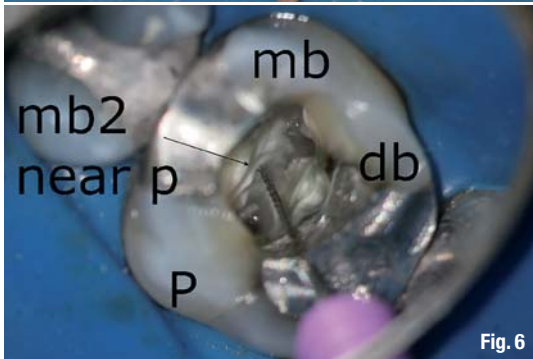
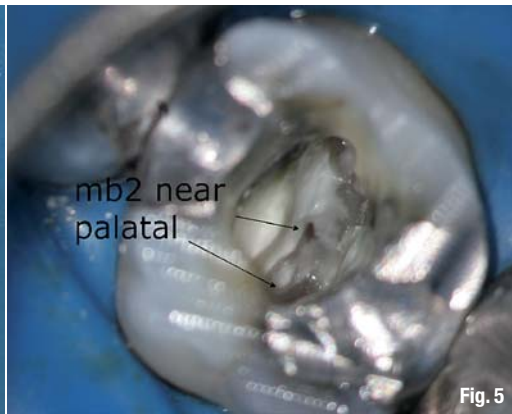


Fig. 3

## \_Endodontic evaluation

A 58-year-old female patient presented for endodontic evaluation and therapy in the upper left quadrant. Mild pain for several days was reported by the patient prior to the appointment. Medical history was non-contributory, and dental history was remarkable for multiple existing large amalgam restorations (Figs. 1–3). Clinical examination and diagnostic evaluation were performed for all posterior teeth on the right side, including cold testing, percussion, palpation, periodontal probing and bite challenge. Findings led to a pre-operative diagnosis of irreversible pulpitis in tooth #3 with normal peri-radicular tissues.

After anaesthesia and isolation with the rubber dam, entry was made into a calcified pulp chamber. Use of the dental operating microscope (OM) greatly enhances lighting and visibility, allowing for careful and deliberate clearing of reparative dentine, pulp stones and other potential impediments to canal orifices. It is important to stress that the files must not be taken into the canals prior to developing proper access form. In such cases, ledging and blockages can easily occur, needlessly compromising and complicating treatment. The palatal pulp tissue was calcified and extirpated *in toto* (Fig. 4).



**\_Ultrasonic tips**

Ultrasonic tips were used to plane the pulpal floor and increase visibility. These instruments are available from many manufacturers in a variety of sizes and shapes designed to address specific case needs. The orifice of the MB2 canal was located towards the palatal orifice in an unusual presentation (Figs. 5 & 6). This stresses the importance of continuing to examine the pulpal floor with the OM throughout the procedure, as irrigants and instrumentation constantly alter the presentation of subtle cues and clues to orifice location.

Once the orifice location had been determined, canal negotiation and instrumentation were completed. Warm vertical compaction of gutta-percha and ZOE sealer was used in this case, demonstrating the treated canal morphology (Figs. 7 & 8). The MB2 canal was addressed as a completely separate canal.

A study that examined more than 1,700 teeth, which included more than 1,000 first molars, demonstrated the presence of the MB2 canal in 93% of these teeth.<sup>1</sup> These findings are not surprising, given the morphology of the MB root in maxillary molars.

In order to better acquaint oneself with this anatomy, examine extracted teeth or consult Brown and Herbranson's *Tooth Atlas*, a rich source of 3-D imagery. The final radiographs demonstrate placement of an orifice barrier, subsequent to temporisation and referral back to the restorative dentist.

**\_A complex system**

This case report has demonstrated the complex root-canal system anatomy present in maxillary molars. Use of the OM throughout a carefully executed coronal and radicular access procedure maximises the ability to disinfect and debride these teeth.

Ultrasonic instrumentation allows for the judicious removal of dentine required to prevent iatrogenic mishaps and unnecessary weakening of the tooth. Meticulous root-canal therapy lays the foundation for successful long-term retention and restorative care for patients who present with endodontic disease.

**\_Reference**

1. Stropko J. Canal morphology of maxillary molars: Clinical observations of canal configurations. JOE, June 1999.

_contact	roots
<p><b>Dr Mark Dreyer</b> is a 1986 graduate of the University of Florida College of Dentistry. He practices as a general dentist limited to endodontics in Orlando and Kissimmee, Florida, and can be contacted at <a href="mailto:markdreyer@gmail.com">markdreyer@gmail.com</a>.</p>	