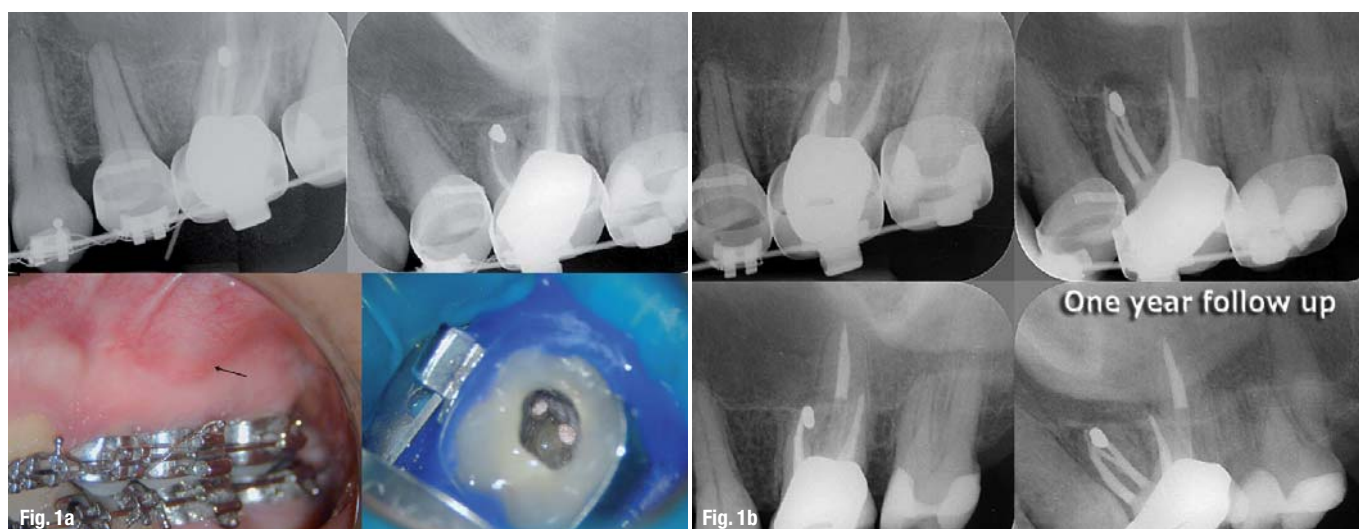


Untying the Gordian Knot: An evidence-based endo-implant algorithm (Part I)

Author_Dr Kenneth S. Serota, USA



Figs. 1a & b Previous endodontic therapy on tooth #14 had failed; the clinician chose to correct the problem with a microsurgical procedure on the mesio-buccal root. This procedure failed over time as well (sinus tract). Radiographic and clinical evidence indicate the developing apical lesion.

The root-canal system was reaccessed, the untreated canal identified, the entire system debrided, disinfected and after interim calcium hydroxide therapy, obturated. One year later, the lesion had healed. While the retrograde amalgam remained in the root end, its presumed ability to seal a complex apical terminal configuration effectively was ill considered. Everything leaks in time; re-treatment is always the first choice for resolution of an unsuccessful endodontic procedure, where possible.

Study the past, if you would divine the future.

—Confucius

The endodontic implant algorithm provides highlights in the assessment and identification of determinant factors leading to endodontic failures, in order to help in the decision-making process, whether it is adequate to implement a new endodontic approach versus extraction and replacement with dental implants.

—Confusion

_Over the years, endodontics has diminished itself by enabling the presumption that it is comprised of a narrowly defined service mix; root-canal therapy purportedly begins at the apex and ends at the orifice. Nothing could be further from the truth. It is the catalyst and precursor of a multivariate continuum, potentially the foundational pillar of all phases of any rehabilitation (Figs. 1a–c).

Early diagnosis of teeth requiring endodontic treatment, prior to the development of peri-radicular

disease, is critical for a successful treatment outcome.¹ Aesthetics, function, structure, biotics and morphology are the variables in the equation of optimal oral health. Interventional or interceptive endodontics, restorative endodontics, the re-engineering of failing therapy, transitional endodontics and surgical endodontics encompass a vast scope of therapeutic considerations prior to any decision/tipping point to replace a natural tooth.

Everything we do as dentists is transitional, with the exception of extractions. No result is everlasting, none are permanent; thus our treatment plans must reflect this reality. Artifice versus a natural state is not a panacea for successful treatment outcomes (Figs. 2a–d).

In 1992, funding from the Cochrane Collaboration was obtained for the UK Cochrane Centre based in Oxford to facilitate the preparation of systematic reviews of randomised trials of health care.² The Cochrane Systematic Review is a process that involves locating, appraising, and synthesising evidence from scientific

studies in order to provide informative empirical answers to scientific research questions.

In 1952, the enterprising son of an inventor named Ron Popeil created infomercials using 30- to 120-second television spots to sell his inexpensive array of useful products, including the Pocket Fisherman and the Veg-O-Matic food slicer. The singular goal of an infomercial was to have the viewer phone immediately and place his or her order—no waiting weeks, months or even years for the lofty marketing goals of branding to pay off. Somewhere along the way, dentistry morphed the two concepts. Nowhere is this becoming more apparent than in the debate on the endodontic implant algorithm. "We have met the enemy ... and he is us." (*The Pogo Papers*)

Scientific doctrine is the cornerstone of endodontic therapeutics. However, of late, anecdotal testimony has become the default setting for new paradigms to justify endodontic treatment modalities and an encomium to technological advances. The strength of the arch of this or any specialty's integrity and relevance must rely on a keystone of randomised clinical trials and evidence-based treatment outcomes. Expert opinions reflected through the looking glass of business models or global tours cannot replace stringently controlled clinical assessments distilled from exacting independent investigations. Science cannot be applied through a McLuhanistic rear-view mirror of technology. The two must symbiotically occupy the same space regardless of whether that is antithetical to the Pauli Exclusion Principle, one of the most accepted laws of physics: no two objects can simultaneously occupy the same space.

In December 2004, Salehrabi and Rotstein³ published an epidemiological study on endodontic treatment outcomes in a large patient population. The outcomes of initial endodontic treatment by general practitioners and endodontists participating in the Delta Dental Insurance plan on 1,462,936 teeth of 1,126,288 patients from 50 states across the US were assessed in an eight-year timeline. Subsequent to non-surgical endodontic treatment over this period 97 % of teeth were retained in the oral cavity. The combined incidence of untoward events, such as re-treatments, apical surgeries and extractions, was 3 % and occurred primarily within three years from the completion of treatment. Analysis of the extracted teeth revealed 85 % had no full coronal coverage. A statistically significant difference was found between covered and uncovered teeth for all tooth groups tested, which is consistent with the findings of numerous investigations.⁴⁻⁶

The purpose of this publication is to evaluate current trends and perceptions pertaining to the standard of

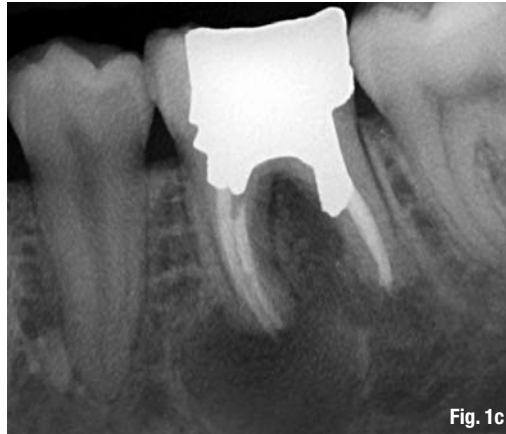

Fig. 1c—"Listening to both sides of a story will convince you that there is more to a story than both sides." (Frank Tyger). The endodontic implant algorithm ensures that philosophy does not obscure pragmatism and expediency does not denigrate adaptive capacity.

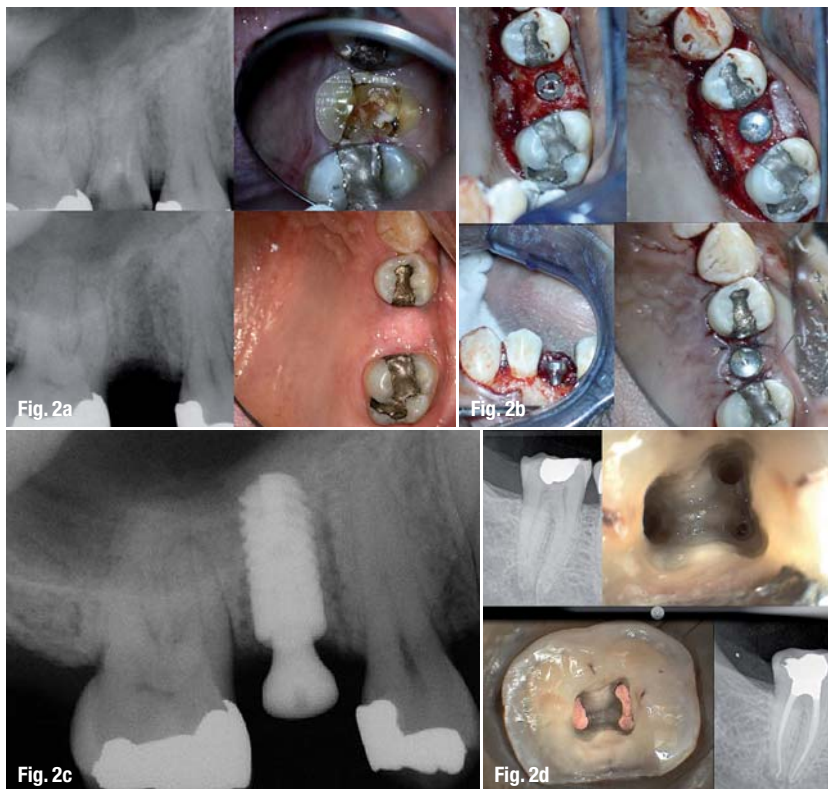
care in endodontics and provide an evidence-based consensus on their relevance and application. Part II will address the algorithm by which sacrifice of natural structures for ortho-biological replacements can be validated and the engineering principles and designs that best mimic clinical dictates.

Evolutionary paradigm shifts

Three surveys have been conducted with the membership of the American Association of Endodontists since the late 1970s. The first reflected what is now an anachronistic view of emergency procedures and the standard of care defining non-surgical therapy during that period.⁷ The second, done prior to the technological advances of the last decade of the twentieth century, was hallmarked by a dramatic decrease in leaving pulpless teeth open in emergency situations and a significant decline in the use of culturing prior to obturation.⁸

The report on the second survey indicated that the concept of *debridement and disinfection versus cleaning and shaping* was now the focus of the biological therapeutic imperative and the need for expansive microbial strategies was recognised as being of paramount importance (Fig. 3). The primary patho-physiologic vectors of pulpal disease and the myriad complexity of the root-canal system had always been understood; as the century closed, clinicians were provided with new tools and technology to expand the boundaries and limitations of endodontic treatment procedures (Figs. 4a & b).

Root-canal infections are polymicrobial, characterised predominantly by both facultative and obligate anaerobic bacteria.⁹ The necrotic pulp becomes a reservoir of pathogens; toxic consequences and their resultant infection are isolated from the patient's immune response. Eventually, the microflora and their by-products will produce a peri-radicular inflammatory response. With microbial invasion of the peri-radicular tissues, an abscess and cellulitis



Figs. 2a & b Tooth #4 was determined to be non-salvageable. It was removed, the socket stimulated to regenerate and in four month's time an ANKYLOS implant inserted, a sulcus former placed and the tissue closed over the site to allow for osseo-integration to occur.

Figs. 2c & d The choice of a natural tooth versus an ortho-biological replacement will increasingly be a powerful force in dental treatment plans. The temptation to select one or the other based on expediency versus complexity, on marketing versus science, will be the sine qua non of the standard of comprehensive care.

Fig. 3 The degree of complexity of the root-canal system has been understood for most of the past century. The failure to negotiate the labyrinthine ramifications of the root-canal system has purportedly been a function of technical limitation rather than comprehension and yet, it took until the mid-1970s to appreciate that thermo-labile condensation of an obturating material could demonstrate a greater occlusive degree of the system than any other modality.

may develop. The resultant inflammatory response will initiate a protective and/or immuno-pathogenic effect. Additionally, it may destroy surrounding tissue, resulting in the five classic signs and symptoms of inflammation: calour, dolour, rubor, tumour and penuria. Patient evaluation and the appropriate diagnosis/treatment of the source of an infection are of utmost importance.

Patients demonstrating signs and symptoms associated with severe endodontic infection (Table I) should have the root-canal system filled with calcium hydroxide and the access sealed. In the event of copious drainage, the access can be left open for no longer than 24 hours, the tooth then isolated with rubber dam, the canals irrigated and dried and calcium hydroxide inserted into the root-canal space, and the access sealed.¹⁰

The antibiotic of choice for peri-radicular abscess remains Penicillin VK; however, recent studies have reported that amoxicillin in combination with clavulanate (1 gm loading dose with 500 mg q8h for seven days) was a more effective therapeutic regimen.¹¹

Systemic antibiotic administration should be considered if there is a spreading infection that signals failure of local host responses in abating the dispersion of bacterial irritants, or if the patient's medical history indicates conditions or diseases known to reduce the host defence mechanisms or expose the patient to higher systemic risks. Antibiotic treatment

is generally not recommended for healthy patients with irreversible pulpitis or localised endodontic infections (Table II). Numerous studies with well-defined diagnosis and inclusion criteria have failed to demonstrate enhanced pain resolution beyond the placebo effect.^{12,13}

The sophistication of endodontic equipment, materials and techniques has been steadily iterated and innovated since the second survey. The microscope first introduced to otolaryngology around 1950, then to neurosurgery in the 1960s, is now the standard of care for the voyage into the microcosmic world of the root-canal system. Recursions in the micro-processing technologies of electronic foraminal locators begat unprecedented accuracy levels, improved digital radiographic sensors and software-enhanced diagnostic acumen, and ultrasonic units with a variety of tips designed specifically for use when performing both non-surgical and surgical endodontic procedures minimised damage to coronal and radicular tooth structure in the effort to locate the pathways of the pulp. The treatment outcome of non-surgical root-canal therapy currently is far more predictable than at any other period in our history.

Diagnosis

Of all the technologic innovations embraced by endodontics, digital radiography should have generated the greatest impact; however, its value remains limited in diagnosis, treatment planning, intra-operative control and outcome assessment. Flat-field sensors still require three to four parallax images of the area of interest in order to establish better perception of depth and spatial orientation of osseous or dental pathology. These 3-D information deficits, geometric distortion and the masking of areas of interest by overlying anatomy or anatomical noise are of strategic relevance to treatment planning in general and endodontics specifically (Figs. 5a & b).¹⁴

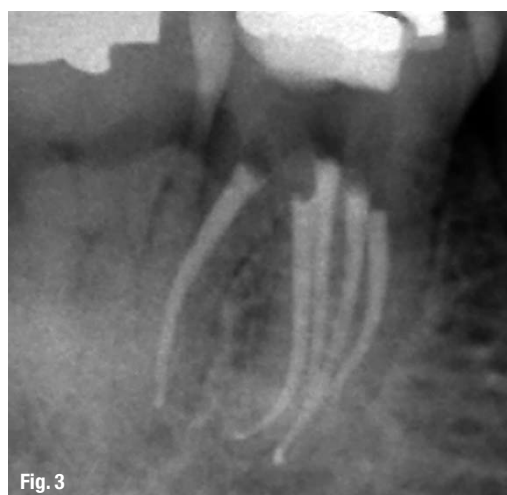


Fig. 3

Cone-beam computed tomography (CBCT) produces up to 580 individual projection images with isotropic sub-millimetre spatial resolution enhanced by advanced image receptor sensors. It is thus ideally suited for dedicated dento-maxillofacial CT scanning. When combined with application-specific software tools, CBCT can provide a complete solution for performing specific diagnostic and surgical tasks. The images can be re-sliced at any angle, producing a new set of reconstructed orthogonal images, and studies have shown that the scans accurately reflect the volume of anatomical defects. The limited volume CBCT scanners best suited for endodontics require an effective radiation dose comparable to two or three conventional peri-apical radiographs and as such are set to revolutionise endodontics (Fig. 6).^{15,16}

Three-dimensional pre-surgical assessment of the approximation of root apices to the inferior dental canal, mental foramen and maxillary sinus are essential to treatment planning. The ability of CBCT to diagnose and manage dento-alveolar trauma using multiplanar views, the determination of the root-canal anatomy and number of canals, the detection of the true nature and exact location of resorptive lesions and the discovery of the existence of vertical and horizontal fractures outweigh concerns about the degree of ionising radiation and the risks posed.¹⁷ Provided CBCT is used in situations in which the information from conventional imaging systems is inadequate, the benefits are essential for optimisation of the standard of care.

Patel reported that peri-apical disease can be detected sooner and more accurately using CBCT compared with traditional peri-apical views and that the true size, extent, nature and position of peri-apical and resorptive lesions can be accurately assessed.¹⁸ Using a new peri-apical index based on CBCT for identification of apical periodontitis, peri-apical lesions were identified in 39.5% and 60.9% of cases by radiography and by CBCT, respectively ($p < 0.01$).



Fig. 4b

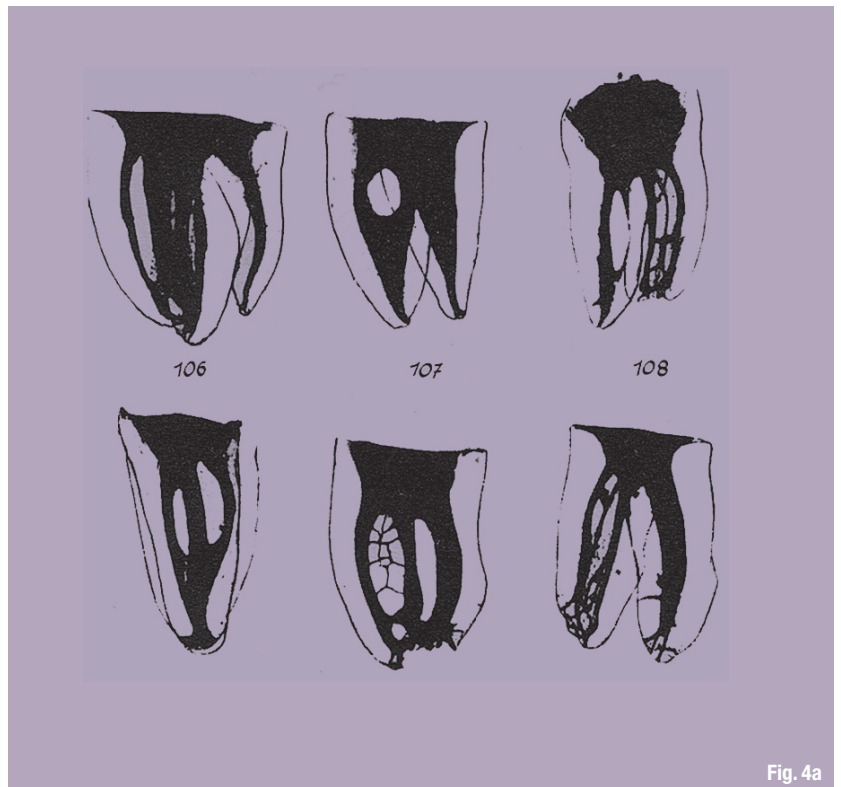


Fig. 4a

Simon et al. compared the differential diagnosis of large peri-apical lesions with traditional biopsy. The results suggested CBCT might provide a faster method to differentially diagnose a solid from a fluid-filled lesion or cavity, without invasive surgery.^{19,20} In spite of the presence of artefacts, the learning curve related to image manipulation and the cost, CBCT will invariably be the accepted standard of diagnostic care and treatment planning in endodontics in the very near future.

Fig. 4a Panel of anatomic preparations from the classic work by Walter Hess (*The Anatomy of the root canals of teeth of the permanent dentition*, London, 1925).

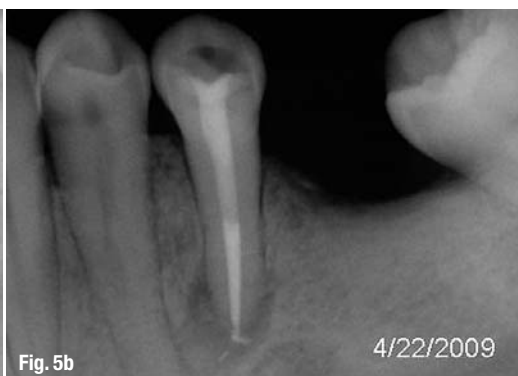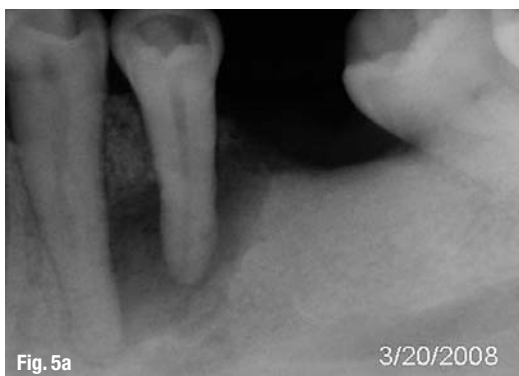Access

An improperly designed access cavity will hamper facilitation of optimal root-canal therapy. If the orientation, extension, angulations and depth are inaccurate, retention of the native anatomy of the root-canal space becomes precarious. The requirements of access cavity design can be achieved by conceptual and technical regression of the existing configuration to that which one would logically expect to have seen prior to the insults of restoration, function and ageing. If tertiary dentine were perceived as 'irritational dentine' or dystrophic calcification considered 'decay', the chamber outline could be used to blueprint an inlay configuration for the access design that literally replicates the virgin tooth (Fig. 7).

Removal of the existing restoration in its entirety and/or preliminary preparation of the coronal tooth structure for the subsequent full coverage restoration will identify decay, fractures, unsupported tooth structure and expose the anatomy of the underlying

Fig. 4b In order to determine the number of root canals and their different morphology, ramifications of the main root canals, location of apical foramina and transverse anastomoses, and frequency of apical deltas, 2,400 human permanent teeth were decalcified, injected with dye and cleared (Vertucci FJ, 1984).

Figs. 5a & b Flat-field sensors provide a sense of the extent of osseous pathology; however, the peri-apical radiographic image corresponds to a 2-D aspect of a 3-D structure. Peri-apical lesions confined within the cancellous bone are usually not detected. Thus, a lesion of a certain size can be detected in a region covered by a thin cortex, whereas the same size lesion cannot be detected in a region covered by thicker cortex.



root trunk periphery, which assists in discovery of the spatial orientation and morphology of the roots. The pulp chamber ceiling and pulp stones can be peeled away with a football diamond bur to identify grossly the primary orifices.

Micro-etching (Danville Materials) the floor of the chamber, perhaps the most underused of all access tools, is invaluable in the exposure of fusion lines and grooves in order to identify accessory orifices. Troughing with ultrasonic tips of any design is used solely to trace fusion lines, not affect gross removal. The use of ultrasonics to 'jackhammer' pulp stones is simply too

Schwartz and Fransman described a clinical strategy for coronal sealing of the endodontic access preparation that lists the following considerations in the protocol: use bonded materials (4th generation (three-step) resin adhesive systems are preferred because they provide a better bond than the adhesives that require fewer steps); the etch and rinse adhesives are preferred to self-etching adhesive systems, if a eugenol-containing sealer or temporary material is used; self-etching adhesives should not be used with self-cure or dual-cure restorative composites. When restoring access cavities, the best aesthetics and highest initial strength are obtained with an incremental fill technique using composite resin. A more efficient technique that provides acceptable aesthetics is to bulk fill with a glass ionomer material to within 2 to 3 mm of the cavo-surface margin, followed by two increments of light-cure composite and, if retention of a crown or bridge abutment is a concern after root-canal treatment, post placement increases retention to greater than the original state (Fig. 9).²³

Table I	Table II
Indications for adjunctive antibiotics	Conditions not requiring adjunctive antibiotics
Fever > 100°F	Pain w/o signs and symptoms of infection
Malaise	Symptomatic irreversible pulpitis
Lymphadenopathy	Acute periradicular periodontitis
Truismus	Teeth with negrotic pulps and radiolucency
Increased swelling	Teeth with a sinus tract (chronic periradicular abscess)
Cellulitis	Localised fluctuant swellings
Osteomyelitis	

_Irrigation

The complex anatomy of the root-canal space presents a daunting challenge to the clinician who must thoroughly debride and disinfect the corridors of sepsis in order to achieve a successful treatment outcome (Fig. 10). In addition, the absence of a cell-mediated defence (phagocytosis, a functional host response) in necrotic teeth means the micro-organisms residual in tubuli, cul-de-sacs and arborisations are mainly affected by the redox potential (reduction potential reflects the oxidation–reduction state of the environment— aerobic microflora can only be active at a positive E_h , whereas strict anaerobes can only be active at negative E_h values) and availability of nutrients in the various parts of the root canal.²⁴

While our knowledge of persistent bacteria, disinfecting agents and the chemical milieu of the necrotic root canal has greatly increased, more innovative basic and clinical research is required in order to

risky as one approaches the floor of the chamber, particularly if there are no water ports on the tips. Orifice lengthening and widening enables straight-line glide path to the apical third. The strategic objective is not to impede the file, stainless-steel or NiTi rotary along the axial walls with minimal dentine removal (Figs. 8a & b).

It is equally important to produce a high-quality coronal restoration at the time of sealing the root-canal system.^{21,22} Despite research supporting the effectiveness of coronal barriers and the need for immediate placement as a component of the completion phase of root-canal treatment, a universally accepted protocol does not exist.

Tables I & II Derived from Baumgartner (*Antibiotics and the Treatment of Endodontic Infections*, Summer 2006).



Think Endo cordless!



No cord. Full power. Entran sets new standards in the area of cordless endodontics and combines the highest level of ergonomics with consistent W&H quality. For root canal preparation, there are a number of features at your disposal e.g. torque control, automatic direction change and 5 preset torque levels for NiTi files. Simple to operate, so you can concentrate on the treatment. With Entran you can enjoy complete freedom of movement inside the entire mouth - even in the most inaccessible posterior molar area.

wh.com

entran

Endodontics. Cordless!

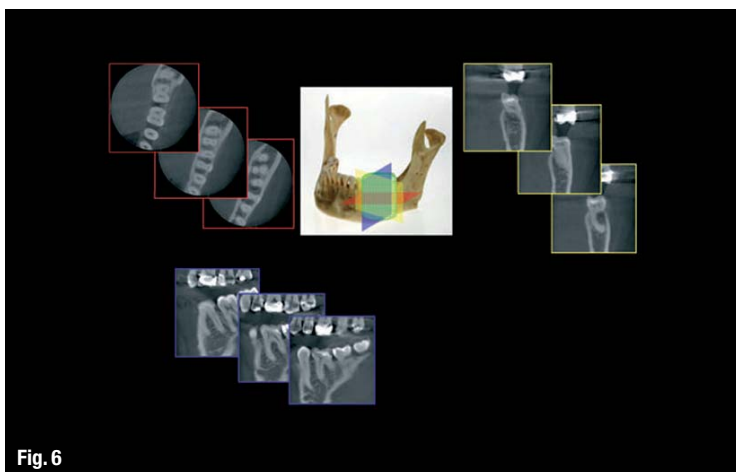


Fig. 6

Fig. 6 All CBCT units provide correlated axial, coronal and sagittal multiplanar volume reformations. Basic enhancements include zoom or magnification and visual adjustments to narrow the range of gray scale, in addition to the capability to add annotation and cursor-driven measurement.

Fig. 7 Strategic extension of the access perimeter is too often undervalued in terms of successful endodontic treatment outcomes. The shape of the chamber must be regressed to its native state to ensure that axial interference is negated as an instrument traverses the length of the root-canal space.

Fig. 8a Dystrophic calcification confounds even the most experienced clinician. The key to identification of the orifices is to regress the inner space using the continuum, cusp tip, pulp horn and canal orifice. In lieu of an ultrasonic tip, which tends to chop the stone and scatter debris, gross removal is best done with a diamond bur in a high-speed handpiece. The fine removal of residue can be done with a multi-fluted carbide bur to trace the fusion lines.

Fig. 8b Keeping the chamber wet with alcohol improves optics and highlights colour disparities.

The most important tool for orifice identification in addition to dyes is a micro-etcher. The satin finish produced highlights the disparity between the natural tooth structure of the floor and the secondary and tertiary dentine of the calcified orifice.

optimise the use of existing methods and materials and develop new ones to prevent and treat apical periodontitis.

Varying degrees of sterility of the root-canal space are achieved by mechanistic removal, the chemical reactivity and fluid dynamics of irrigants and their introduction to the canal space; however, the protocols used today cannot predictably provide sterile canals. As none of the elements of endodontic therapy (host defence system, systemic antibiotic therapy, instrumentation and irrigation, inter-appointment medicaments, permanent root filling, and coronal restoration) can alone guarantee complete disinfection, it is of utmost importance to aim for the highest possible quality at every phase of the treatment.

In the classic study by Sjogren et al., 55 single-rooted teeth with apical periodontitis were instrumented and irrigated with sodium hypochlorite and root filled. Peri-apical healing was followed-up for five years. Complete peri-apical healing occurred in 94% of cases that yielded a negative culture. In cases in which the samples were positive prior to root filling, the success rate of treatment was just 68%—a statistically significant difference. These findings emphasise the importance of eliminating bacteria from the root-canal system prior to obturation. This objective cannot be reliably achieved in a one-visit treatment of necrotic pulps because it is not possible to eradicate all infection from the root canal without the support of an inter-appointment antimicrobial dressing.²⁵

Sodium hypochlorite (NaOCl) is the most widely used irrigating solution. It is a potent antimicrobial agent and lubricant that effectively dissolves pulpal remnants and organic components of dentine, thus preventing packing infected hard and soft tissue into the apical confines. Hypochlorous acid (HClO) is the active moiety responsible for bacterial inactivation.

NaOCl is used in concentrations varying from 0.5 to 5.25%; the *in vitro* and *in vivo* studies differ significantly in terms of the effectiveness of the range of concentrations as *in vitro* experiments provide direct access to microbes, higher volumes are used and the chemical milieu complexity of the natural canal space are absent as compared to *in vivo* experimentation. Siqueira et al. found no difference (*in vitro*) between 1%, 2.5% and 5% NaOCl solutions in reducing the number of bacteria during instrumentation.²⁶ What has been demonstrated is that the tissue dissolving effects are directly related to the concentration used.²⁷

Perhaps the most misunderstood aspect of NaOCl irrigation is the need for the quantities of irrigation required due to the morphological and anatomical variations in the volumetric size of the root-canal anatomy. Siqueira et al. demonstrated that regular exchange and use of large amounts of irrigant should maintain the antibacterial effectiveness of the NaOCl solution, compensating for the effects of concentration.²⁸

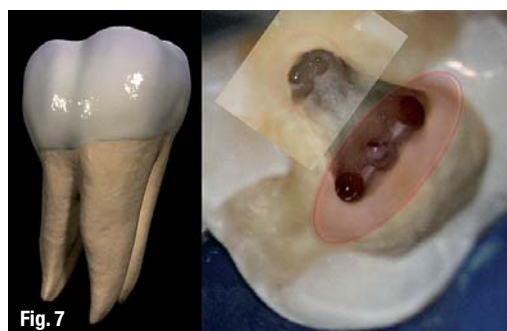

Fig. 7

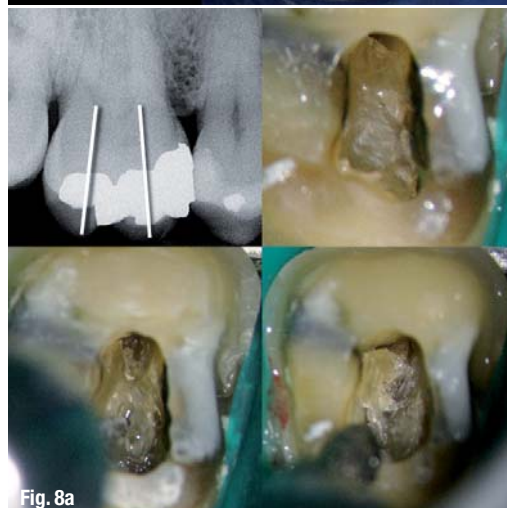

Fig. 8a

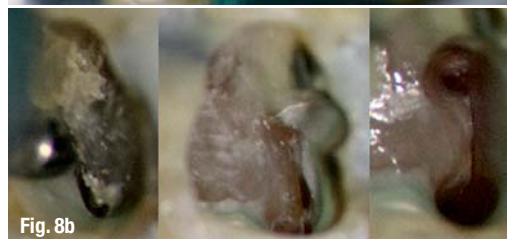

Fig. 8b

Numerous devices have appeared in the endodontic armamentarium to address this situation:

- _ EndoVac (Discus Dental): a negative pressure differential device designed to deliver high volumes of irrigation solution while using apical negative pressure through the office high-volume evacuation system;
- _ Negative Pressure Safety Irrigator (Vista Dental): device is similar to EndoVac;
- _ Rinsendo (Air Techniques): uses pressure suction technology; 65 ml of irrigant are automatically drawn from the attached syringe and aspirated into the canal (pressure created is lower than manual irrigation); and
- _ Vibringe (Bisco Canada): sonic flow technology facilitates enhanced irrigation through the myriad complexities of the root-canal system (Fig. 11).

NaOCl cannot dissolve inorganic dentine particles and thus prevent smear layer formation during instrumentation.²⁹ Chelators, such as EDTA and citric acid, are recommended as adjuvants in root-canal therapy. It is probable that biofilms are detached with the use of chelators; however, they have little if any antibacterial activity.

Several studies have demonstrated that citric acid in concentrations ranging as high as 50% were more effective at solubilisation of inorganic smear layer components and powdered dentine than EDTA. In addition, citric acid has demonstrated antibacterial effectiveness.

Technology and innovation will not negate the need for optimal preparation (debridement and disinfection) to eliminate microbial content and its impact on a necrotic root-canal system. We as a discipline need to improve; however, endodontics has shown its commitment to endless reinvention. In time, this will restructure the role of natural teeth in foundational dentistry, currently diminished by the market forces of implant-driven dentistry.

Ortho-biological replacement is not a panacea as random clinical trials increasingly show; the severity of peri-implantitis lesions demonstrates significant variability and as such no treatment modality has shown superiority. The pendulum will continue to swing as the endodontic implant algorithm becomes increasingly multivariate.

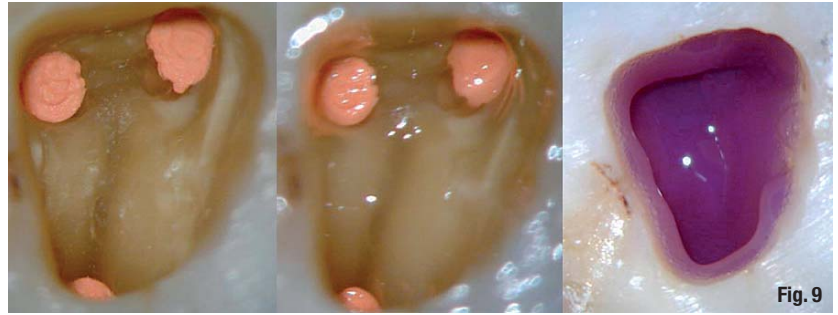


Fig. 9

Microstructural replication—obturation

Steven Covey is known for his book *The Seven Habits of Highly Effective People*. The habit most applicable to endodontics is the second one: "begin with the end in mind". The implication of this vision with regard to idealising the final shape of the root-canal system in order to ensure that the obturation represents a totality is profound. The root canal is negative space and as such recovery of its original unaffected form is the sine qua non of obturation or more descriptively, microstructural replication.

Fig. 9 Micro-etching ensures the removal of oils and debris, and the elimination of the residue in fusion lines and fissures. Routine dentine bonding is then performed. The composite selected in this instance is PermaFlo Purple (Ultradent Products, Inc.), which enables differentiation of restoration and tooth structure should re-entry be necessary.

irrigation, agitation techniques and devices

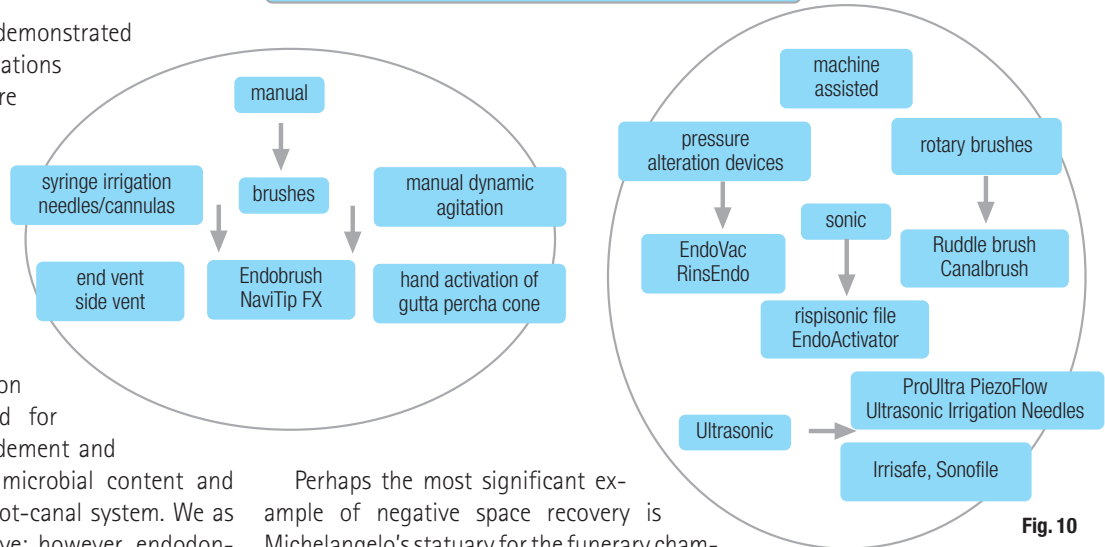


Fig. 10

Perhaps the most significant example of negative space recovery is Michelangelo's statuary for the funerary chamber of Pope Julius II. Four unfinished sculptures speak eloquently to this process: the figure was outlined on the front of the marble block and then Michelangelo worked steadily inwards from this side, in his own words "liberating the figure imprisoned in the marble". This is an exacting description of debridement and instrumentation of the root-canal space prior to root filling after a myriad of pathologic vectors have destroyed the dental pulp, and altered the morphology/topography of the system (Fig. 12). Incomplete filling of the debrided and sculpted root-canal space is one of the major causes of endodontic failure.³⁰ Until recently, *in vitro* testing (dye leakage, fluid

Fig. 10 There is a vast array of equipment on the market to optimise irrigation protocols. Radical change may well be in the offing; however, research and development on bio-active obturating materials may prove to be the defining variable in total asepsis.

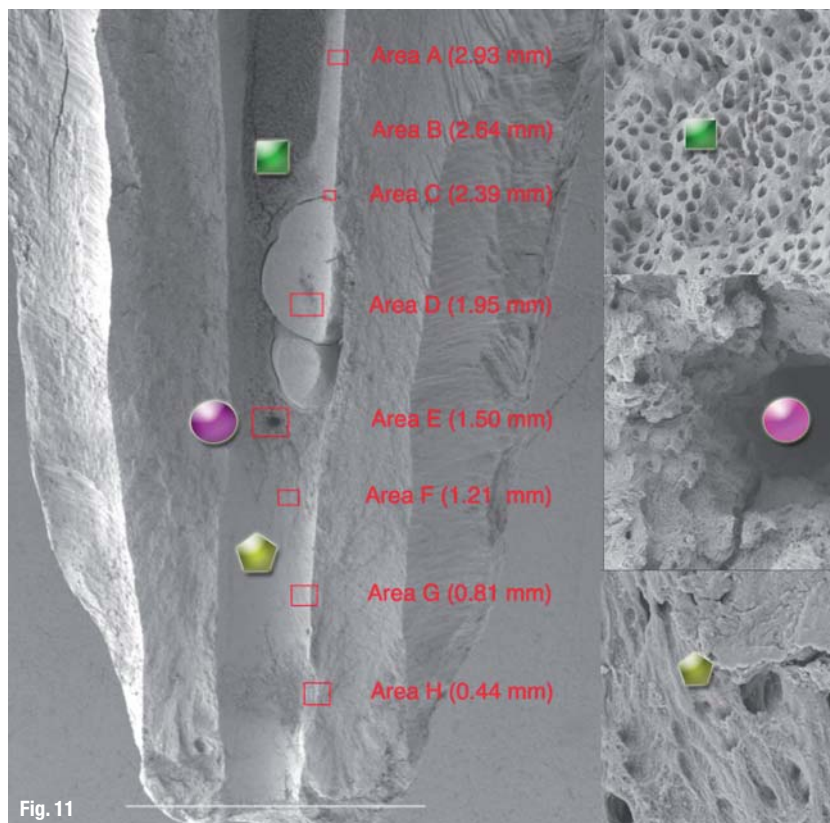


Fig. 11

Fig. 11 Numerous researchers have demonstrated that the concept of keeping the apical foramen as small as practical does not mean a size #20 or 25 file. This Schilderian concept should read *as small as the apical morphology permits* in order to ensure that the free flow of irrigant to the apical terminus enables more definitive cleaning of the apical segment of the root-canal space.

transport, bacterial penetration, glucose leakage) was used to evaluate the sealing efficacy of endodontic filling materials and techniques by assessing the degree of penetration/absorbance of these tracers.³¹⁻³³

Unfortunately, leakage studies are limited static models that do not simulate the conditions found in the oral cavity (temperature changes, dietary influences, salivary flow). Given the historic dominance of *in vitro* testing, the clinician must be cautious in extrapolating study findings to the clinical situation, regardless of manufacturer's claims.³⁴ This reliance on invalid testing protocols diminishes the monoblock assertions applied to the new generation of adhesive obturating materials proposed as the replacement material for gutta-percha.³⁵

Fig. 12 The artist/clinician recognises that negative space surrounding an object is equally important as the object itself. In the case of root-canal therapy, the positive space is alterable but must be created in balance with the encompassing negative space to ensure morphological integrity.

Gutta-percha was introduced to dentistry by Edwin Truman in 1847.³⁶ The concept of thermo-labile vertical condensation of gutta-percha was originally described by Dr J. R. Blaney in 1927.³⁷ The defining article on obturation remains Dr Schilder's classic on filling the root-canal space in three dimensions, published 40 years later.³⁸

Fig. 13 While there is no meta-analysis to elucidate this concern, the incidence of fracture of the mesial root of mandibular molars has been shown to have a significant correlation to cusp fracturing.

Logically, one cannot physically fill the root canal in two dimensions; however, one can fill the root-canal space badly in three dimensions. This does not disprove Dr Schilder's exposition, but it does demonstrate that words can easily be misconstrued and alter perspective once they become, as Kipling said, "the

most powerful drug of mankind". Ironically, Schilder's article came seven years prior to his treatise on cleaning and shaping the root-canal system, which even to this day remains the iconic standard.

The *Washington Study* by Ingle indicated that 58 % of treatment failures were due to incomplete obturation.³⁹ The corollary is obvious: teeth that are poorly obturated are invariably poorly debrided and disinfected. Procedural errors such as loss of working length, canal/apical transportation, perforations, loss of coronal seal and vertical root fractures have been proven to affect the integrity of the apical seal adversely.^{40,41}

The Toronto study that evaluated success and failure of endodontic treatment at four to six years after completion of treatment found that teeth treated with a flared canal preparation and vertical condensation of thermo-labile gutta-percha had a higher success rate when compared with step-back canal preparation and lateral compaction. Highlighting the vertical condensation of warm gutta-percha obturation technique as a factor influencing success and failure simply confirmed a perspective evident to most endodontists from years of clinical empiricism.

There is a never-ending array of obturation materials, delivery systems and sealers appearing in the marketplace. Each is hallmarked by proprietary modifications and each is heralded as the most significant iteration in obturation since the previous one; today, we practice with a sad truism—marketing inexorably directs science. However, gutta-percha in combination with a myriad of sealers and solvents remains the primary endodontic obturating material. The dominant systems remain carrier-based obturation (Thermafil, Tulsa Dental Specialties), Continuous

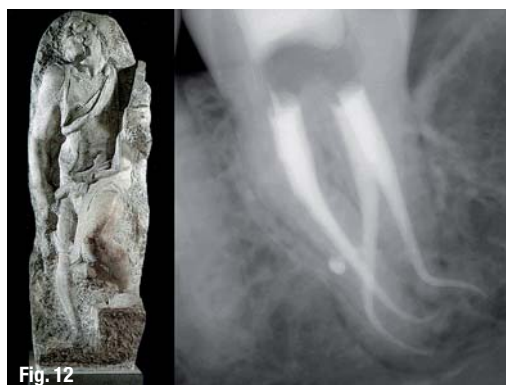

Fig. 12

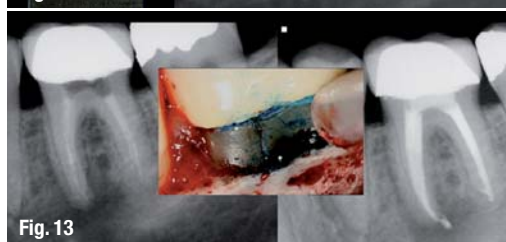


Fig. 13

EndoInnovations III

SybronEndo offers you advanced technology for safer, more efficient procedures.



REALSEAL 1 Warm-Bonded Obturator

All the components of RealSeal 1™ – sealer, filler and core – are resin-based materials that chemically bond with each other to form a *superior seal*. As an added benefit, this system's core is engineered to be easily seen on a radiograph.



TF – Faster, Safer, Stronger

TF™ is twisted, not ground – unlike other nickel titanium files – making it more durable. Endodontic files are made by grinding the flutes, weakening the metal's molecular structure which can lead to separation. Our unique manufacturing process produces a file with optimal sharpness, strength and flexibility. TF allows you to work in difficult situations faster, safer and with a stronger file.



SybronEndoEurope | Safe files, superior fills.
A DIVISION OF SYBRON DENTAL SPECIALTIES

SybronEndo Europe, Basicweg 20, 3821 BR Amersfoort, The Netherlands
tel: +31 33 4536 159 fax: +31 33 4536 153 email: Endo@SybronDental.com

SybronEndo, 1717 West Collins Avenue, Orange, CA 92867
800.346.ENDO 714.516.7979 Fax 714.516.7911 SybronEndo.com

Wave Compaction Technique (Elements Obturation, SybronEndo) and Thermoplastic Injection (Obtura III Max, Obtura Spartan).

Resilon (RealSeal, SybronEndo), a high-performance industrial polyurethane, was developed as an alternative to gutta-percha. There are scattered studies that demonstrate that Resilon exhibits less microbial leakage⁴² and higher bond strength to root-canal dentine⁴³, reduced peri-apical inflammation⁴⁴ and enhanced fracture resistance of endodontically treated teeth when compared with gutta-percha⁴⁵ (Fig. 13). Other studies have reported undesirable properties

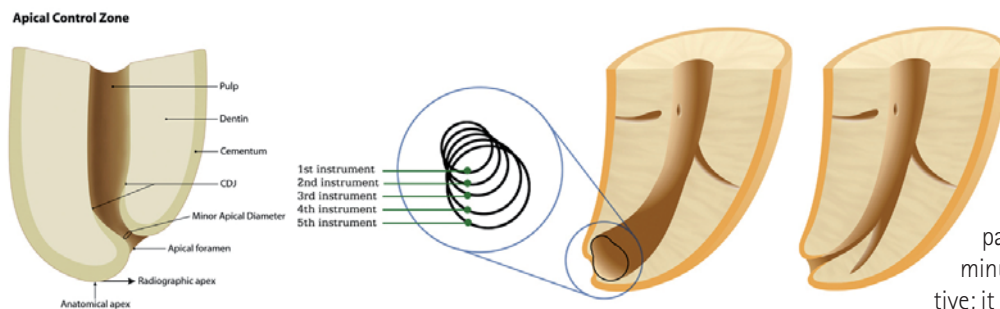


Fig. 14a

On left, the working length has two reference points, coronal and apical. Failure to maintain patency at the minor apical diameter will cause loss of the apical reference point as a result of blockage, or ellipticisation of the foramen.

associated with Resilon, including low push-out bond strength⁴⁶ and low cohesive strength plus stiffness.⁴⁷ In addition, Resilon did not achieve a complete hermetic apical seal.⁴⁸ These results indicate that a more appropriate material for root-canal obturation still needs to be developed. There is still no obturation method or material that produces a leak-proof seal. A material that is bio-inductive and promotes regeneration, a smart nano-material that can adapt to the ever-changing microenvironment of the canal system is essential, but to date, remains elusive.

All polymers demonstrate melt temperature and flow rate. Both gutta-percha and Resilon demonstrate a viscoelastic gradient that manifests as a dynamic rheological birefringence in the moulded state. Dependent upon the molecular weight of the source material (without the opacifiers, waxes and modifiers), gravimetric measurements of the time-temperature-transformation diagram of any moulding compound can be constructed. In the thermoplastic world of today, this has engendered an increase in the weight of the mass of obturating material and an improvement in the bacterial seal. This applies to carrier-based obturation techniques, Continuous Wave Compaction Technique and Obtura III obturation without cone placement.

Instrumentation

The steps required for debridement and disinfection of the root-canal space are sequential and interdependent. Aberration of any node in the process affects the others, leading to iatrogenic damage and

potentially, treatment outcome failure. The most common distortion of native anatomy is ledging; canal curvature exceeding 20 degrees was shown to produce ledging of mandibular molars 56% of the time in a cohort of undergraduate students.⁴⁹ Dentine chips pushed apically by instrumentation incorporated with fragments of pulp tissue will compact into the apical third and the foraminal area causing blockage, altering the working length due to the loss of patency (Figs. 14a & b).

Apical patency is a technique in which the minor apical diameter of the canal is maintained free of debris by recapitulation with a small file through the apical foramen.⁵⁰

The most predictable method is to use a designated patency file regularly throughout the cleaning and shaping procedure in conjunction with copious irrigation. A #0.08 K-file passively moved through the apical terminus without widening it is most effective; it will refresh the NaOCl at the terminus as the action of the file going to the point of patency produces a fluid dynamic. Regrettably, loss of working length remains a common adverse event during endodontic therapy, especially amongst less experienced clinicians. Its major cause is the formation of an apical dentine plug. Therefore, establishing apical patency is recommended even during treatment of canals with vital pulp.⁵¹

Historically, numerous techniques have been advocated for canal preparation (balanced force, anti-curvature, double-flare, modified double-flare); however, step-back⁵² and crown-down⁵³ are the most universally accepted. Experience has shown a crown-down preparation will cause fewer procedural errors (apical transportation, elbow formation, ledging, strip perforation, instrument fracture). The preliminary removal of coronal dentine (pre-enlargement—treating the apex last) minimises blockage and enables an increasing volume of irrigant penetration, thereby sustaining working length throughout the procedure.⁵⁴

The balanced-force shaping philosophy is integral to the crown-down approach. Its premise is that instruments are guided by the canal structure when rotational/anti-rotational motion (watch winding) is used. Changing the direction of rotation controls the probability that instruments will become overstressed and thus ensures that the cutting of structure occurs most efficiently.⁵⁵ Endodontists have long appreciated what the science reported, that the balanced-force hand instrumentation technique produced a cleaner apical portion of the canal than other techniques (Fig. 15).^{56,57} As discussed below, I remain committed to hand filing in order to refine

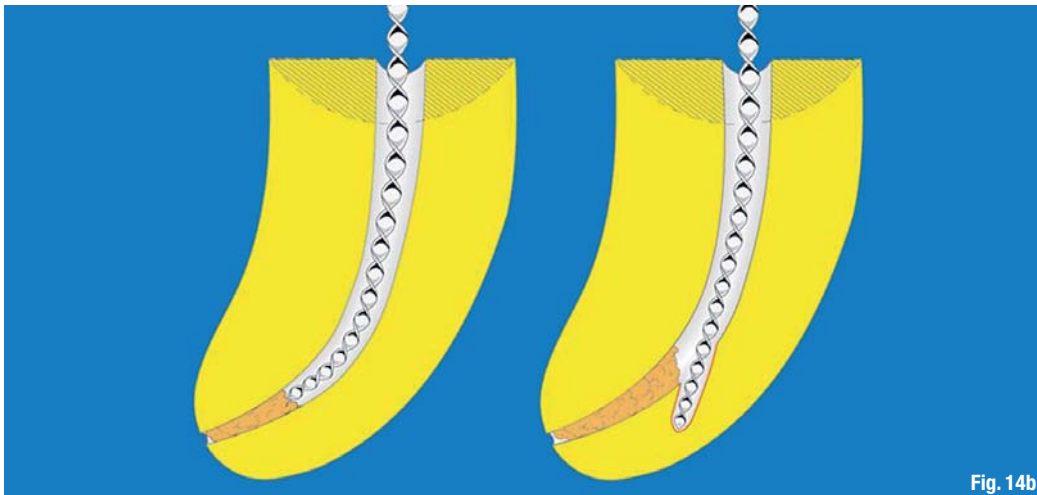


Fig. 14b The volume of irrigant necessary to prevent apical blockage is indeterminate. While NiTi rotary instrumentation has minimised this to a significant degree, a slurry of dentine mud is always a risk factor to be monitored.

apical third shaping and creating an enhanced apical control zone taper.

Two distinct phases are required for the preparation of canals with NiTi rotary files. It is essential that, no matter the protocol used, a reservoir of NaOCl be maintained and replenished repeatedly in the strategically extended access preparation. The coronal portion of the canal space is explored with small-sized K-files to establish a glide path for the rotaries to follow. The taper of NiTi files, regardless of manufacturer, induces a crown-down effect in the straight portion of the canal. After the coronal and middle third segments have been opened and repeatedly irrigated with NaOCl, a sequence of small K-files can progress apically, ultimately defining patency, confirming the topography of the accessible canal space and its degree of curvature. A second 'wave' with the NiTi rotaries is then used to effect deep shape, approximating the working length, and depending upon the configuration of the apical third, to enlarge the terminus to the gauged apical size and initiate the taper of the apical control zone.⁵⁸ This is a basic concept. It is inherent in all templated protocols that each tooth is different, and modifications to the process are always necessary as a function of the tooth morphology.

The apical control zone is defined as a matrix-like region created at the terminus of the apical third of the root-canal space. The zone demonstrates an exaggerated taper from the spatial position determined by an electronic foraminal locator to be the minor apical diameter. Whether this is linear or a point determination is a function of histopathology. The enhanced taper at the terminus creates a resistance form against the condensation pressures of obturation and acts to prevent excessive extrusion of filling material during thermo-labile vertical compaction.

All NiTi systems are modelled upon a single or multiple taper ratio per millimetre of file length. Figure 16a

demonstrates the metrics of the F1, F2, F3 finishing files of the ProTaper Universal System (my preference). These files demonstrate a common taper in the last 4mm of the file, which in the vast majority of situations corresponds to the length of the apical third of the root-canal space. As shown, the 0.07 taper of the F1 (0.20 tip), the 0.08 taper of the F2 (0.25 tip) and the 0.09 taper of the F3 (0.30 tip) produce the corresponding diametral dimension indicated each millimetre back from the apical terminus, if the crown-down protocol built into this multiple taper file system is adhered to. If the shape of the internal micro-morphology of the root complex were epidemiologically similar, then imprinting of the canal preparation would be logical. Unfortunately, such is not the case.⁵⁹

Figure 16b demonstrates that the use of hand files in the apical third can alter the preliminary shape created by the NiTi files. Hand files have a 0.02 taper (along the shaft of the file, the diameter increases by 0.02 mm per mm of length—a 0.20 file with 16mm of flutes would be measure 0.52 mm at the coronal end of the flutes). In the example shown, a #20 file is positioned at the minor apical diameter. Careful positioning of a series of file within the last millimetre can produce a 0.2 mm or 20% taper with no undue disruption of the native anatomy. Schilder's precept for shaping was to keep the apical foramen as small as practically possible. Whatever file approximates the minor apical diameter, in conjunction with hand filing, the apical control zone created will enhance the apical seal, as the rheological vectors of compaction and condensation have a greater lateral volume of displacement at the terminus.

Fig. 15 Rheology is a science that addresses the deformation and flow of matter. The biochemistry of filling material, its viscosity gradient, the lubricating effect of sealer and optimal thermal application are only as effective as the flow characteristics of the shape created and its degree of cleanliness.

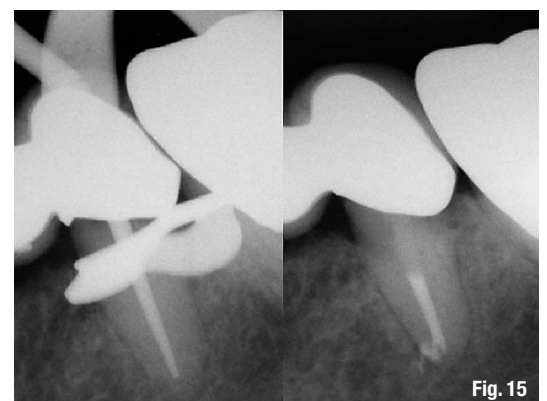
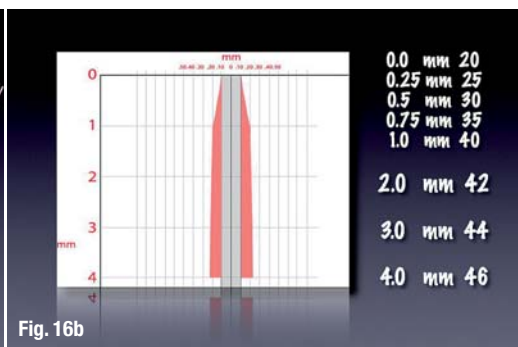
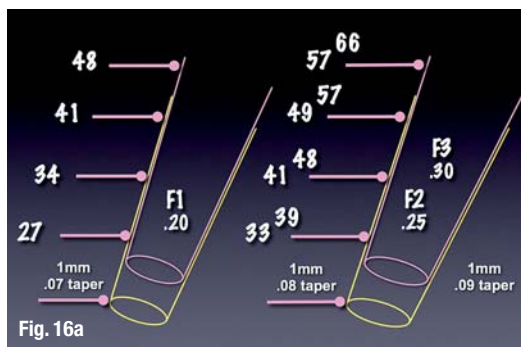


Fig. 15

Fig. 16a The ProTaper Universal System consists of two shaping files that address the planes of geometry of the coronal and middle thirds of the root-canal space. There are five finishing files that include tips sizes: 20, 25, 30, 40 and 50. Tapers range from 0.06 to 0.09 through the series.

A thorough understanding of the metrics is essential for the preparation of the myriad variations in internal micro-morphology of the root-canal space and the assurance of minimal iatrogenic impact.

Fig. 16b Modification of taper in the last millimetre of the apical terminus exaggerates the constriction or minor apical diameter. Thermo-labile vertical condensation has been shown to enhance successful endodontic outcomes. The matrix effect of the apical control zone enhances the gravimetric density of the required hermetic apical seal and enables more material to flow into the region to occlude fins, cul-de-sacs, deltas and lateral arborisations.



A risk-assessment algorithm

If the biological parameters that mandate endodontic success are adhered to, in almost all cases, treatment outcomes will be successful. The endodontic implant algorithm processes the array of contributing factors leading to endodontic failure, in order to determine whether to implement a re-engineered endodontic approach or to extract and replace the natural tooth with an osseointegrated implant. It finds the greatest common divisor amongst the degree of coronal breakdown of the involved or adjacent teeth, the quality and quantity of the bone support and tissue condition, and the engineering demands to be born by the tooth or teeth in question, and assesses the occlusal scheme and the patient's aesthetic and functional expectations of treatment.

The reasons for tooth extraction may include, but are not limited to, crown-to-root ratio, remaining root length, periodontal attachment levels, furcation


status, periodontal health of teeth adjacent to the proposed fixture site and non-restorable carious destruction. In addition, the clinician must consider questionable teeth in need of endodontic treatment, teeth requiring root amputations, hemi-sections or advanced periodontal procedures with a questionable prognosis, and pulpless teeth fractured at the gingival margin with roots shorter than 13 mm. These teeth will require endodontic treatment, crown lengthening, post/cores and crowns; however, their longevity is much in doubt with these parameters.⁶⁰

Practitioners are ethically obligated to inform patients of all reasonable treatment options. It is the patient's attitude, values and expectations that are integral to the risk assessment algorithm. Poor motivation to retain a tooth mandates extraction, not clinical intervention, whereas high motivation advocates non-surgical intervention or surgery. The process of planning, presentation and acceptance of dental treatment plans is always dominated by the duality of emotion and pragmatism associated with cost. Where it becomes specious is the side-by-side dollar comparison of restoring a natural tooth or placement of a fixed bridge etc. in contrast to ortho-biological replacement of a debilitated tooth. Far too often the comparison of purported treatment outcome percentages are based upon corporate affiliation and/or fiduciary bias, or are simply too narrow a parameter to suggest comparable alternatives. With the treatment options available to an experienced endodontist, only very few structurally sound teeth need be removed.

Benjamin Disraeli said: "Expediency is a law of nature. The camel is a wonderful animal, but the desert made the camel". The endodontic implant algorithm raises the question: Does science drive the market, or does the market drive science. "All truths are easy to understand once they are discovered; the point is to discover them," Galileo said. Time and forbearance will bear witness to the discovery of the salient and relevant truths that guide the endodontic implant algorithm.

Editorial note: Part II of this article will be published in roots 2/2010. A complete list of references is available from the publisher.

_about the author
roots



Dr Kenneth S. Serota graduated from the University of Toronto in 1973 and was awarded the George W. Switzer Memorial Key for Excellence in Prosthodontics. He received his Certificate in Endodontics and Master of Medical Sciences degree from the Harvard-Forsyth Dental Center in Boston.

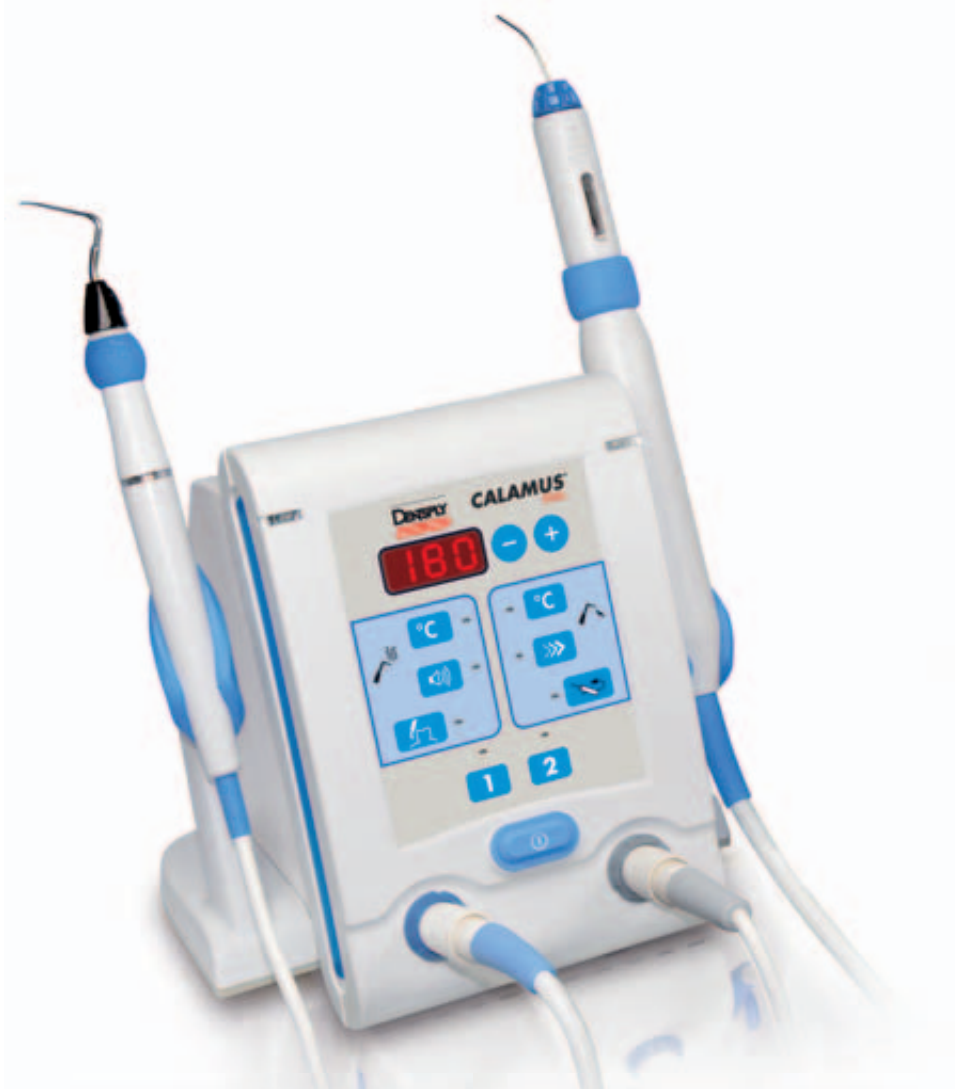A recipient of the American Association of Endodontics Memorial Research Award for his work in nuclear medicine screening procedures related to dental pathology, his passion is education, and most recently e-learning, and rich media. Dr Serota provided an interactive endodontic programme for the Ontario Dental Association from 1983 to 1997 and was awarded the ODA Award of Merit for his efforts in the provision of continuing education.

The author of more than 60 publications, Dr Serota is on the editorial board of *Endodontic Practice*, *Endo Tribune* and *Implant Tribune*. He founded ROOTS, an online educational forum for dentists from around the world who wish to learn cutting-edge endodontic therapy, and recently launched IMPLANTS (www.rximplants.com) and www.tdsonline.org in order to provide dentists with a clear understanding of the endodontic-implant algorithm in foundational dentistry.

CALAMUS[®] DUAL

DOWNPACK & BACKFILL

FAST AND TIGHTLY SEALED ROOT CANAL FILLINGS



TIME-SAVING AND LONG-LASTING 3D OBTURATION OF ROOT CANALS

Filling was never so easy!

- Obturation device for downpack and backfill

Device designed for your comfort

- Ergonomically designed handpieces with large operation angle and feather-touch activation by flexible silicone ring

Lateral or vertical obturation? Better results with Calamus[®]

- Vertical condensation is a faster method to achieve a long-lasting, tightly sealed, three dimensional root canal filling
- Reliable obturation of lateral canals as well as minimal risk of root fractures

DENTSPLY
MAILLEFER

www.dentsplymaillefer.com