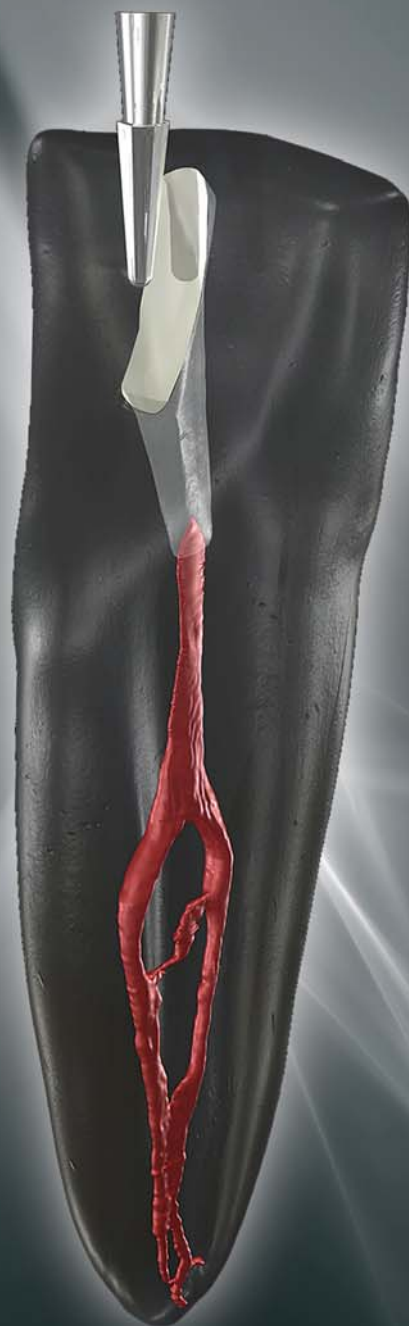

# roots

international magazine of endodontology

1 2010



| **special**

Evidence-based  
endo-implant algorithm

| **case report**

Managing maxillary molars

| **business**

Word-of-mouth 2.0



# Ultrastreaming in the root canal



for an effective cleaning

## VDW.ULTRA®

Ultrasonic device with endo-focus.  
Safe operation thanks to clear user  
guidance following endodontic  
indications:

- Passive, ultrasonic irrigation reaches all areas inaccessible to instrumentation
- Cavity preparation
- Retreatments
- Removal of metal posts and separated instruments



Want more information?  
VDW GmbH · P.O.Box 830954 · 81709 München · Germany  
info@vdw-dental.com · www.vdw-dental.com

Endo Easy Efficient®

# Dear Reader,



Dr Chris J. Lampert  
Guest Editor

The success of modern endodontic treatment can largely be attributed to the work of Dr Herbert Schilder. This is not because he pioneered 3-D obturation with warm gutta-percha, not because he defined the first mechanical and biological objectives for shaping and cleaning a root-canal system, not because he stood by his principles in the face of criticism, but because he raised the bar for endodontic success to a new level. Numerous gifted educators and clinicians have followed and furthered Dr Schilder's principles and techniques. In fact, in this edition of **roots**, two contributing authors were trained by Dr Schilder.

Historically, endodontic treatment has been considered the last option for saving a tooth prior to extraction. The option of endodontic treatment was compared to that of not having a tooth, which was an easy decision to make. Presently, dental implants are the comparative treatment against which endodontic success is measured. Many believe, and I agree, that this comparison has also raised the bar for endodontic treatment success to a new level.

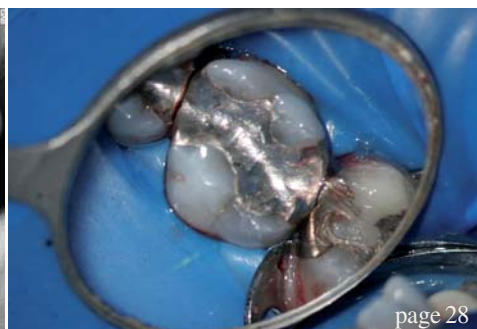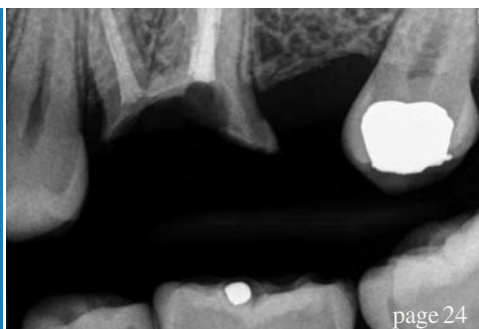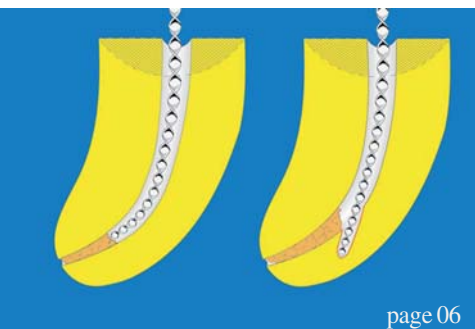
Raising the level of endodontic treatment begins with knowing when to treat a compromised case and when not to treat a hopeless case. Correctly determining this improves the success of endodontic treatment. Utilising technology such as cone-beam imaging gives clinicians diagnostic information about the aetiology of endodontic pathology that is critical to determining whether a case can be treated endodontically. Treating complicated cases with advanced micro-surgical endodontic treatment is also required to improve the success of endodontic treatment. It is essential that current and future generations of endodontic clinicians continue to practise and improve micro-surgical endodontic treatment.

I am honoured to contribute to this edition of **roots**. As you will see in the following articles, **roots** has become a premier international endodontic publication. It offers a forum for renowned clinicians and educators to share their knowledge and expertise with colleagues in all fields of dentistry. I hope you will enjoy this issue of **roots** as much as I did.

Sincerely yours,

A handwritten signature in black ink that reads "Chris Lampert". The signature is written in a cursive, flowing style.

Dr Chris J. Lampert  
Guest Editor  
Endodontist  
Portland, Oregon, USA



**| editorial**

03 **Dear Reader**  
 | Dr Chris J. Lampert, Guest Editor

**| special**

06 **Untying the Gordian Knot:**  
**An evidence-based endo-implant algorithm (Part I)**  
 | Dr Kenneth S. Serota

**| clinical report**

20 **Apical microsurgery—Part IV:**  
**The REB and REP**  
 | Dr John J. Stropko

**| case report**

24 **The importance of endodontics in**  
**implant treatment planning**  
 | Dr Jose M. Hoyó

28 **Managing maxillary molars**  
 | Dr Mark Dreyer

30 **Comprehensive evaluation of previous**  
**root canal therapy**  
 | Dr Richard E. Mounce

**| opinion**

34 **The perceptions of a David in a land of Goliaths**  
 | Dr Barry Lee Musikant

**| research**

36 **Determining working length,**  
**or how to locate the apical terminus (Part II)**  
 | Prof Vladimir Ivanovic & Dr Katarina Beljic-Ivanovic

**| instrumentation**

44 **File selection: Why geometry matters most**  
 | Dr L. Stephen Buchanan

**| industry news**

46 **Ready-to-use root-canal sealer:**  
**2Seal easymiX**  
 | VDW

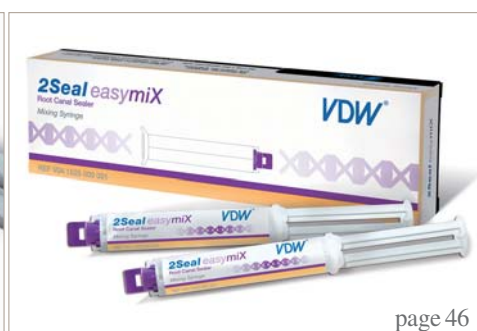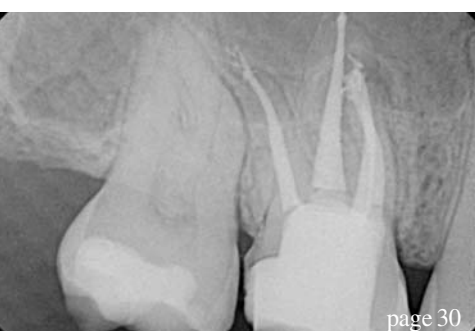
**| meetings**

48 **International Events**

**| about the publisher**

49 | submission guidelines  
 50 | imprint

Cover: CK endodontic access bur (SS White). Image courtesy of Dr Eric Herbranson and Dr David J. Clark, drclark@microscopdentistry.com.



# TOOLS TO KEEP SMILING

No less than ...  
...4 launches !

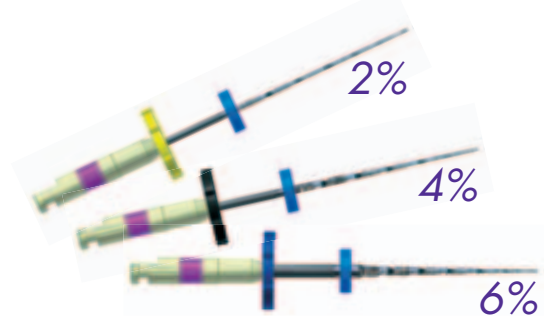
## D-RaCe

*Desobturation made easy*



## FKG RaCe ISO 10

*Mechanical Glide Path*




## Spreader 4%

*NiTi & Electro-chemical polishing*



## SMG handle

*Indicator of uses*



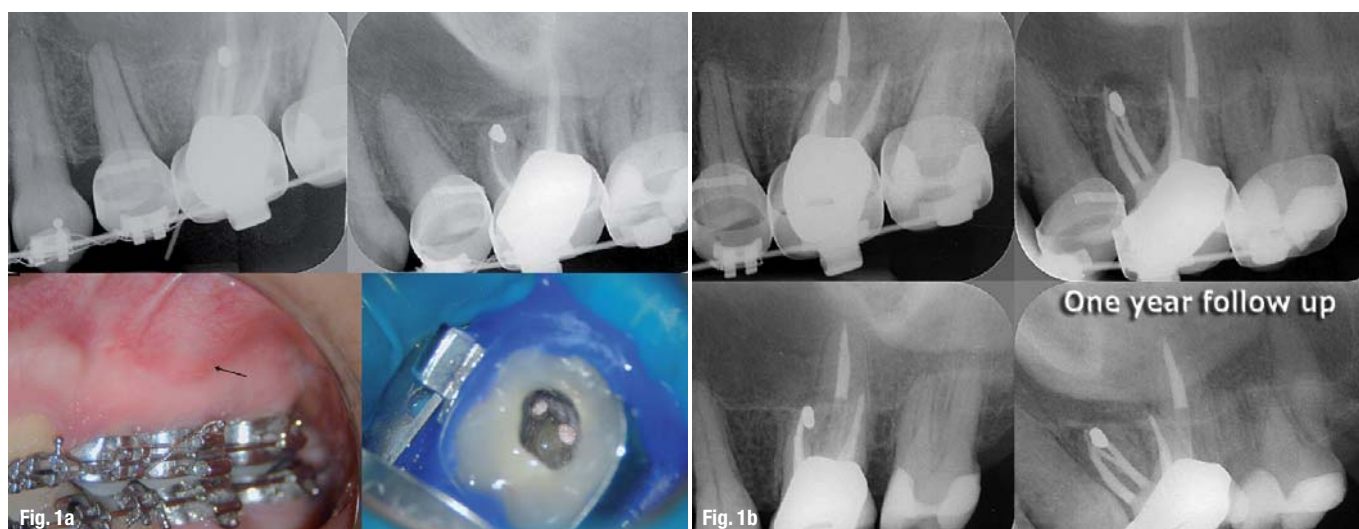
[www.fkg.ch](http://www.fkg.ch)

**FKG**  
**FKG DENTAIRE**  
Swiss Dental Products



# Untying the Gordian Knot: An evidence-based endo-implant algorithm (Part I)

Author\_Dr Kenneth S. Serota, USA



**Figs. 1a & b** Previous endodontic therapy on tooth #14 had failed; the clinician chose to correct the problem with a microsurgical procedure on the mesio-buccal root. This procedure failed over time as well (sinus tract). Radiographic and clinical evidence indicate the developing apical lesion.

The root-canal system was reaccessed, the untreated canal identified, the entire system debrided, disinfected and after interim calcium hydroxide therapy, obturated. One year later, the lesion had healed. While the retrograde amalgam remained in the root end, its presumed ability to seal a complex apical terminal configuration effectively was ill considered. Everything leaks in time; re-treatment is always the first choice for resolution of an unsuccessful endodontic procedure, where possible.

*Study the past, if you would divine the future.*

—Confucius

*The endodontic implant algorithm provides highlights in the assessment and identification of determinant factors leading to endodontic failures, in order to help in the decision-making process, whether it is adequate to implement a new endodontic approach versus extraction and replacement with dental implants.*

—Confusion

**\_Over the years**, endodontics has diminished itself by enabling the presumption that it is comprised of a narrowly defined service mix; root-canal therapy purportedly begins at the apex and ends at the orifice. Nothing could be further from the truth. It is the catalyst and precursor of a multivariate continuum, potentially the foundational pillar of all phases of any rehabilitation (Figs. 1a–c).

Early diagnosis of teeth requiring endodontic treatment, prior to the development of peri-radicular

disease, is critical for a successful treatment outcome.<sup>1</sup> Aesthetics, function, structure, biotics and morphology are the variables in the equation of optimal oral health. Interventional or interceptive endodontics, restorative endodontics, the re-engineering of failing therapy, transitional endodontics and surgical endodontics encompass a vast scope of therapeutic considerations prior to any decision/tipping point to replace a natural tooth.

Everything we do as dentists is transitional, with the exception of extractions. No result is everlasting, none are permanent; thus our treatment plans must reflect this reality. Artifice versus a natural state is not a panacea for successful treatment outcomes (Figs. 2a–d).

In 1992, funding from the Cochrane Collaboration was obtained for the UK Cochrane Centre based in Oxford to facilitate the preparation of systematic reviews of randomised trials of health care.<sup>2</sup> The Cochrane Systematic Review is a process that involves locating, appraising, and synthesising evidence from scientific

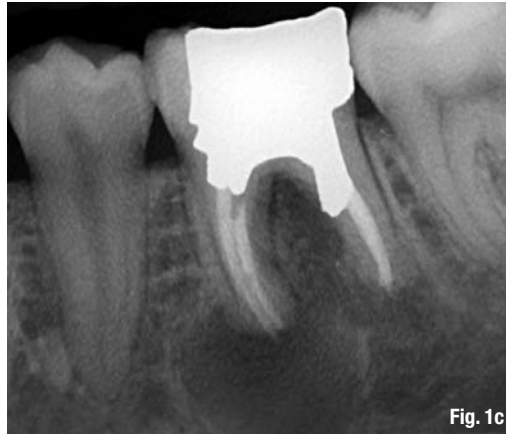studies in order to provide informative empirical answers to scientific research questions.

In 1952, the enterprising son of an inventor named Ron Popeil created infomercials using 30- to 120-second television spots to sell his inexpensive array of useful products, including the Pocket Fisherman and the Veg-O-Matic food slicer. The singular goal of an infomercial was to have the viewer phone immediately and place his or her order—no waiting weeks, months or even years for the lofty marketing goals of branding to pay off. Somewhere along the way, dentistry morphed the two concepts. Nowhere is this becoming more apparent than in the debate on the endodontic implant algorithm. "We have met the enemy ... and he is us." (*The Pogo Papers*)

Scientific doctrine is the cornerstone of endodontic therapeutics. However, of late, anecdotal testimony has become the default setting for new paradigms to justify endodontic treatment modalities and an encomium to technological advances. The strength of the arch of this or any specialty's integrity and relevance must rely on a keystone of randomised clinical trials and evidence-based treatment outcomes. Expert opinions reflected through the looking glass of business models or global tours cannot replace stringently controlled clinical assessments distilled from exacting independent investigations. Science cannot be applied through a McLuhanistic rear-view mirror of technology. The two must symbiotically occupy the same space regardless of whether that is antithetical to the Pauli Exclusion Principle, one of the most accepted laws of physics: no two objects can simultaneously occupy the same space.

In December 2004, Salehrabi and Rotstein<sup>3</sup> published an epidemiological study on endodontic treatment outcomes in a large patient population. The outcomes of initial endodontic treatment by general practitioners and endodontists participating in the Delta Dental Insurance plan on 1,462,936 teeth of 1,126,288 patients from 50 states across the US were assessed in an eight-year timeline. Subsequent to non-surgical endodontic treatment over this period 97 % of teeth were retained in the oral cavity. The combined incidence of untoward events, such as re-treatments, apical surgeries and extractions, was 3 % and occurred primarily within three years from the completion of treatment. Analysis of the extracted teeth revealed 85 % had no full coronal coverage. A statistically significant difference was found between covered and uncovered teeth for all tooth groups tested, which is consistent with the findings of numerous investigations.<sup>4-6</sup>

The purpose of this publication is to evaluate current trends and perceptions pertaining to the standard of



**Fig. 1c**—"Listening to both sides of a story will convince you that there is more to a story than both sides." (Frank Tyger). The endodontic implant algorithm ensures that philosophy does not obscure pragmatism and expediency does not denigrate adaptive capacity.

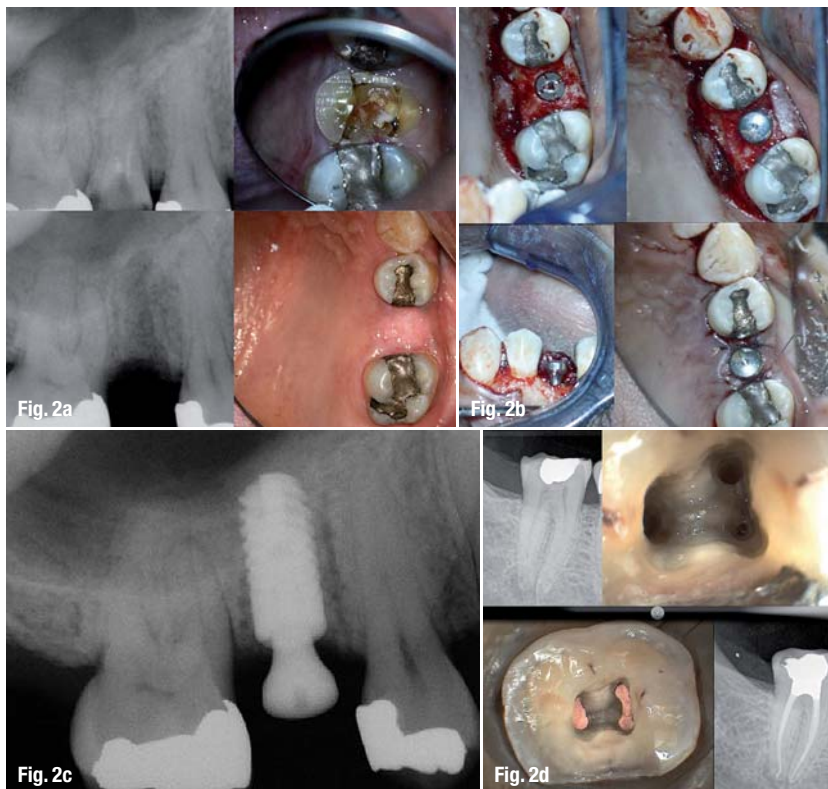
care in endodontics and provide an evidence-based consensus on their relevance and application. Part II will address the algorithm by which sacrifice of natural structures for ortho-biological replacements can be validated and the engineering principles and designs that best mimic clinical dictates.

### **Evolutionary paradigm shifts**

Three surveys have been conducted with the membership of the American Association of Endodontists since the late 1970s. The first reflected what is now an anachronistic view of emergency procedures and the standard of care defining non-surgical therapy during that period.<sup>7</sup> The second, done prior to the technological advances of the last decade of the twentieth century, was hallmarked by a dramatic decrease in leaving pulpless teeth open in emergency situations and a significant decline in the use of culturing prior to obturation.<sup>8</sup>

The report on the second survey indicated that the concept of *debridement and disinfection versus cleaning and shaping* was now the focus of the biological therapeutic imperative and the need for expansive microbial strategies was recognised as being of paramount importance (Fig. 3). The primary patho-physiologic vectors of pulpal disease and the myriad complexity of the root-canal system had always been understood; as the century closed, clinicians were provided with new tools and technology to expand the boundaries and limitations of endodontic treatment procedures (Figs. 4a & b).

Root-canal infections are polymicrobial, characterised predominantly by both facultative and obligate anaerobic bacteria.<sup>9</sup> The necrotic pulp becomes a reservoir of pathogens; toxic consequences and their resultant infection are isolated from the patient's immune response. Eventually, the microflora and their by-products will produce a peri-radicular inflammatory response. With microbial invasion of the peri-radicular tissues, an abscess and cellulitis



**Figs. 2a & b** Tooth #4 was determined to be non-salvageable. It was removed, the socket stimulated to regenerate and in four month's time an ANKYLOS implant inserted, a sulcus former placed and the tissue closed over the site to allow for osseo-integration to occur.

**Figs. 2c & d** The choice of a natural tooth versus an ortho-biological replacement will increasingly be a powerful force in dental treatment plans. The temptation to select one or the other based on expediency versus complexity, on marketing versus science, will be the sine qua non of the standard of comprehensive care.

**Fig. 3** The degree of complexity of the root-canal system has been understood for most of the past century. The failure to negotiate the labyrinthine ramifications of the root-canal system has purportedly been a function of technical limitation rather than comprehension and yet, it took until the mid-1970s to appreciate that thermo-labile condensation of an obturating material could demonstrate a greater occlusive degree of the system than any other modality.

may develop. The resultant inflammatory response will initiate a protective and/or immuno-pathogenic effect. Additionally, it may destroy surrounding tissue, resulting in the five classic signs and symptoms of inflammation: calour, dolour, rubor, tumour and penuria. Patient evaluation and the appropriate diagnosis/treatment of the source of an infection are of utmost importance.

Patients demonstrating signs and symptoms associated with severe endodontic infection (Table I) should have the root-canal system filled with calcium hydroxide and the access sealed. In the event of copious drainage, the access can be left open for no longer than 24 hours, the tooth then isolated with rubber dam, the canals irrigated and dried and calcium hydroxide inserted into the root-canal space, and the access sealed.<sup>10</sup>

The antibiotic of choice for peri-radicular abscess remains Penicillin VK; however, recent studies have reported that amoxicillin in combination with clavulanate (1 gm loading dose with 500 mg q8h for seven days) was a more effective therapeutic regimen.<sup>11</sup>

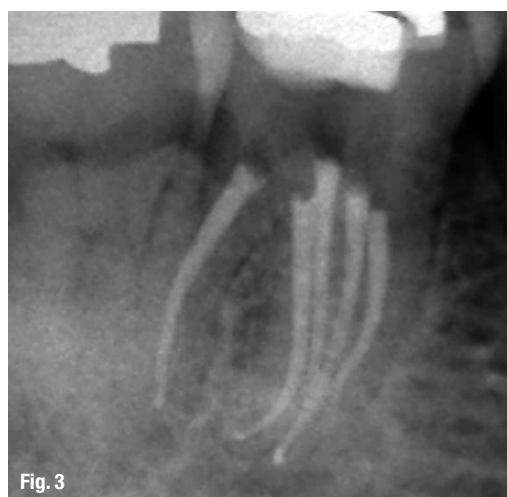
Systemic antibiotic administration should be considered if there is a spreading infection that signals failure of local host responses in abating the dispersion of bacterial irritants, or if the patient's medical history indicates conditions or diseases known to reduce the host defence mechanisms or expose the patient to higher systemic risks. Antibiotic treatment

is generally not recommended for healthy patients with irreversible pulpitis or localised endodontic infections (Table II). Numerous studies with well-defined diagnosis and inclusion criteria have failed to demonstrate enhanced pain resolution beyond the placebo effect.<sup>12,13</sup>

The sophistication of endodontic equipment, materials and techniques has been steadily iterated and innovated since the second survey. The microscope first introduced to otolaryngology around 1950, then to neurosurgery in the 1960s, is now the standard of care for the voyage into the microcosmic world of the root-canal system. Recursions in the micro-processing technologies of electronic foraminal locators begat unprecedented accuracy levels, improved digital radiographic sensors and software-enhanced diagnostic acumen, and ultrasonic units with a variety of tips designed specifically for use when performing both non-surgical and surgical endodontic procedures minimised damage to coronal and radicular tooth structure in the effort to locate the pathways of the pulp. The treatment outcome of non-surgical root-canal therapy currently is far more predictable than at any other period in our history.

### Diagnosis

Of all the technologic innovations embraced by endodontics, digital radiography should have generated the greatest impact; however, its value remains limited in diagnosis, treatment planning, intra-operative control and outcome assessment. Flat-field sensors still require three to four parallax images of the area of interest in order to establish better perception of depth and spatial orientation of osseous or dental pathology. These 3-D information deficits, geometric distortion and the masking of areas of interest by overlying anatomy or anatomical noise are of strategic relevance to treatment planning in general and endodontics specifically (Figs. 5a & b).<sup>14</sup>





Cone-beam computed tomography (CBCT) produces up to 580 individual projection images with isotropic sub-millimetre spatial resolution enhanced by advanced image receptor sensors. It is thus ideally suited for dedicated dento-maxillofacial CT scanning. When combined with application-specific software tools, CBCT can provide a complete solution for performing specific diagnostic and surgical tasks. The images can be re-sliced at any angle, producing a new set of reconstructed orthogonal images, and studies have shown that the scans accurately reflect the volume of anatomical defects. The limited volume CBCT scanners best suited for endodontics require an effective radiation dose comparable to two or three conventional peri-apical radiographs and as such are set to revolutionise endodontics (Fig. 6).<sup>15,16</sup>

Three-dimensional pre-surgical assessment of the approximation of root apices to the inferior dental canal, mental foramen and maxillary sinus are essential to treatment planning. The ability of CBCT to diagnose and manage dento-alveolar trauma using multiplanar views, the determination of the root-canal anatomy and number of canals, the detection of the true nature and exact location of resorptive lesions and the discovery of the existence of vertical and horizontal fractures outweigh concerns about the degree of ionising radiation and the risks posed.<sup>17</sup> Provided CBCT is used in situations in which the information from conventional imaging systems is inadequate, the benefits are essential for optimisation of the standard of care.

Patel reported that peri-apical disease can be detected sooner and more accurately using CBCT compared with traditional peri-apical views and that the true size, extent, nature and position of peri-apical and resorptive lesions can be accurately assessed.<sup>18</sup> Using a new peri-apical index based on CBCT for identification of apical periodontitis, peri-apical lesions were identified in 39.5% and 60.9% of cases by radiography and by CBCT, respectively ( $p < 0.01$ ).




Fig. 4b

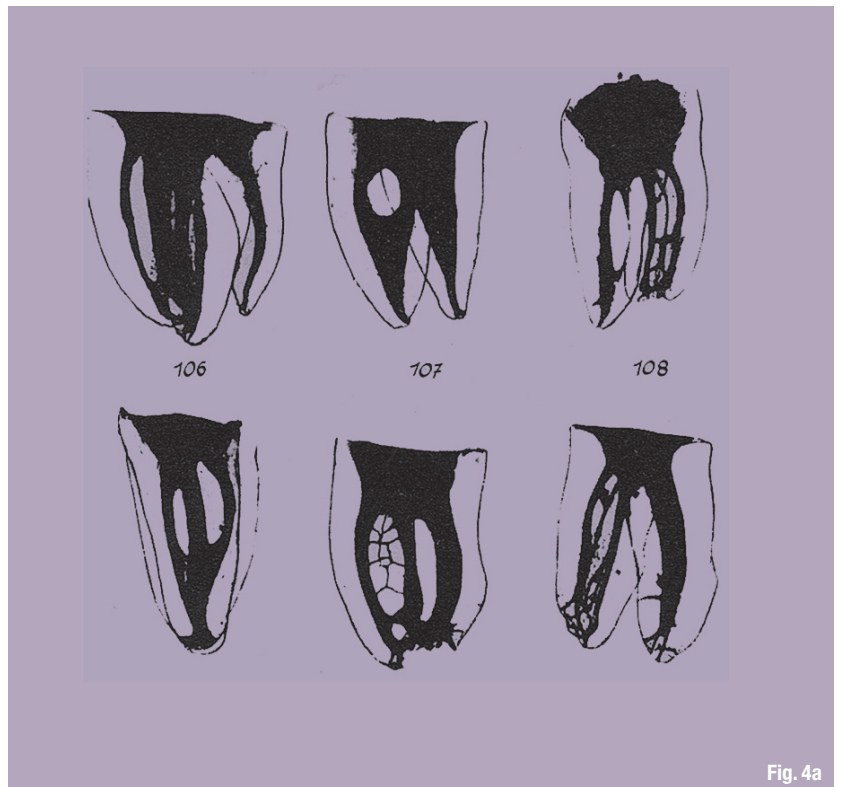


Fig. 4a

Simon et al. compared the differential diagnosis of large peri-apical lesions with traditional biopsy. The results suggested CBCT might provide a faster method to differentially diagnose a solid from a fluid-filled lesion or cavity, without invasive surgery.<sup>19,20</sup> In spite of the presence of artefacts, the learning curve related to image manipulation and the cost, CBCT will invariably be the accepted standard of diagnostic care and treatment planning in endodontics in the very near future.

**Fig. 4a** Panel of anatomic preparations from the classic work by Walter Hess (*The Anatomy of the root canals of teeth of the permanent dentition*, London, 1925).

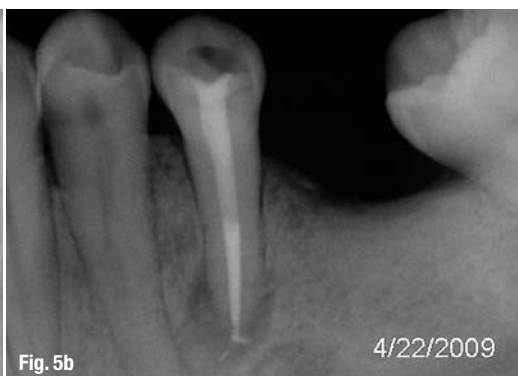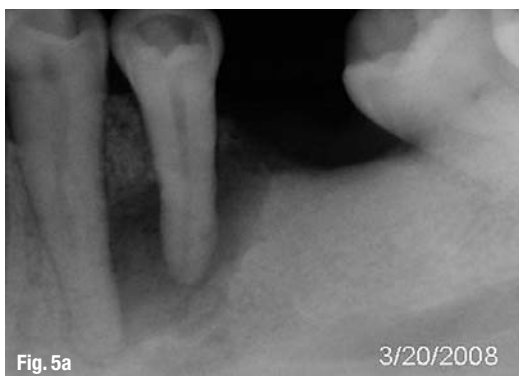## Access

An improperly designed access cavity will hamper facilitation of optimal root-canal therapy. If the orientation, extension, angulations and depth are inaccurate, retention of the native anatomy of the root-canal space becomes precarious. The requirements of access cavity design can be achieved by conceptual and technical regression of the existing configuration to that which one would logically expect to have seen prior to the insults of restoration, function and ageing. If tertiary dentine were perceived as 'irritational dentine' or dystrophic calcification considered 'decay', the chamber outline could be used to blueprint an inlay configuration for the access design that literally replicates the virgin tooth (Fig. 7).

Removal of the existing restoration in its entirety and/or preliminary preparation of the coronal tooth structure for the subsequent full coverage restoration will identify decay, fractures, unsupported tooth structure and expose the anatomy of the underlying

**Fig. 4b** In order to determine the number of root canals and their different morphology, ramifications of the main root canals, location of apical foramina and transverse anastomoses, and frequency of apical deltas, 2,400 human permanent teeth were decalcified, injected with dye and cleared (Vertucci FJ, 1984).

**Figs. 5a & b** Flat-field sensors provide a sense of the extent of osseous pathology; however, the peri-apical radiographic image corresponds to a 2-D aspect of a 3-D structure. Peri-apical lesions confined within the cancellous bone are usually not detected. Thus, a lesion of a certain size can be detected in a region covered by a thin cortex, whereas the same size lesion cannot be detected in a region covered by thicker cortex.



root trunk periphery, which assists in discovery of the spatial orientation and morphology of the roots. The pulp chamber ceiling and pulp stones can be peeled away with a football diamond bur to identify grossly the primary orifices.

Micro-etching (Danville Materials) the floor of the chamber, perhaps the most underused of all access tools, is invaluable in the exposure of fusion lines and grooves in order to identify accessory orifices. Troughing with ultrasonic tips of any design is used solely to trace fusion lines, not affect gross removal. The use of ultrasonics to 'jackhammer' pulp stones is simply too

Schwartz and Fransman described a clinical strategy for coronal sealing of the endodontic access preparation that lists the following considerations in the protocol: use bonded materials (4<sup>th</sup> generation (three-step) resin adhesive systems are preferred because they provide a better bond than the adhesives that require fewer steps); the etch and rinse adhesives are preferred to self-etching adhesive systems, if a eugenol-containing sealer or temporary material is used; self-etching adhesives should not be used with self-cure or dual-cure restorative composites. When restoring access cavities, the best aesthetics and highest initial strength are obtained with an incremental fill technique using composite resin. A more efficient technique that provides acceptable aesthetics is to bulk fill with a glass ionomer material to within 2 to 3 mm of the cavo-surface margin, followed by two increments of light-cure composite and, if retention of a crown or bridge abutment is a concern after root-canal treatment, post placement increases retention to greater than the original state (Fig. 9).<sup>23</sup>

Table I	Table II
<b>Indications for adjunctive antibiotics</b>	<b>Conditions not requiring adjunctive antibiotics</b>
Fever > 100°F	Pain w/o signs and symptoms of infection
Malaise	Symptomatic irreversible pulpitis
Lymphadenopathy	Acute periradicular periodontitis
Trismus	Teeth with necrotic pulps and radiolucency
Increased swelling	Teeth with a sinus tract (chronic periradicular abscess)
Cellulitis	Localised fluctuant swellings
Osteomyelitis	

### Irrigation

The complex anatomy of the root-canal space presents a daunting challenge to the clinician who must thoroughly debride and disinfect the corridors of sepsis in order to achieve a successful treatment outcome (Fig. 10). In addition, the absence of a cell-mediated defence (phagocytosis, a functional host response) in necrotic teeth means the micro-organisms residual in tubuli, cul-de-sacs and arborisations are mainly affected by the redox potential (reduction potential reflects the oxidation–reduction state of the environment— aerobic microflora can only be active at a positive  $E_h$ , whereas strict anaerobes can only be active at negative  $E_h$  values) and availability of nutrients in the various parts of the root canal.<sup>24</sup>

While our knowledge of persistent bacteria, disinfecting agents and the chemical milieu of the necrotic root canal has greatly increased, more innovative basic and clinical research is required in order to

risky as one approaches the floor of the chamber, particularly if there are no water ports on the tips. Orifice lengthening and widening enables straight-line glide path to the apical third. The strategic objective is not to impede the file, stainless-steel or NiTi rotary along the axial walls with minimal dentine removal (Figs. 8a & b).

It is equally important to produce a high-quality coronal restoration at the time of sealing the root-canal system.<sup>21,22</sup> Despite research supporting the effectiveness of coronal barriers and the need for immediate placement as a component of the completion phase of root-canal treatment, a universally accepted protocol does not exist.

**Tables I & II** Derived from Baumgartner (*Antibiotics and the Treatment of Endodontic Infections*, Summer 2006).



# Think Endo cordless!



No cord. Full power. Entran sets new standards in the area of cordless endodontics and combines the highest level of ergonomics with consistent W&H quality. For root canal preparation, there are a number of features at your disposal e.g. torque control, automatic direction change and 5 preset torque levels for NiTi files. Simple to operate, so you can concentrate on the treatment. With Entran you can enjoy complete freedom of movement inside the entire mouth - even in the most inaccessible posterior molar area.

[wh.com](http://wh.com)

## entran

Endodontics. Cordless!

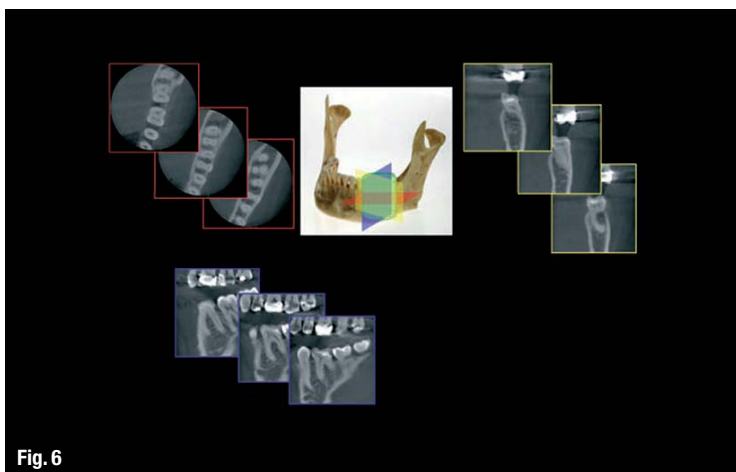


Fig. 6

**Fig. 6** All CBCT units provide correlated axial, coronal and sagittal multiplanar volume reformations. Basic enhancements include zoom or magnification and visual adjustments to narrow the range of gray scale, in addition to the capability to add annotation and cursor-driven measurement.

**Fig. 7** Strategic extension of the access perimeter is too often undervalued in terms of successful endodontic treatment outcomes. The shape of the chamber must be regressed to its native state to ensure that axial interference is negated as an instrument traverses the length of the root-canal space.

**Fig. 8a** Dystrophic calcification confounds even the most experienced clinician. The key to identification of the orifices is to regress the inner space using the continuum, cusp tip, pulp horn and canal orifice. In lieu of an ultrasonic tip, which tends to chop the stone and scatter debris, gross removal is best done with a diamond bur in a high-speed handpiece. The fine removal of residue can be done with a multi-fluted carbide bur to trace the fusion lines.

**Fig. 8b** Keeping the chamber wet with alcohol improves optics and highlights colour disparities. The most important tool for orifice identification in addition to dyes is a micro-etcher. The satin finish produced highlights the disparity between the natural tooth structure of the floor and the secondary and tertiary dentine of the calcified orifice.

optimise the use of existing methods and materials and develop new ones to prevent and treat apical periodontitis.

Varying degrees of sterility of the root-canal space are achieved by mechanistic removal, the chemical reactivity and fluid dynamics of irrigants and their introduction to the canal space; however, the protocols used today cannot predictably provide sterile canals. As none of the elements of endodontic therapy (host defence system, systemic antibiotic therapy, instrumentation and irrigation, inter-appointment medicaments, permanent root filling, and coronal restoration) can alone guarantee complete disinfection, it is of utmost importance to aim for the highest possible quality at every phase of the treatment.

In the classic study by Sjogren et al., 55 single-rooted teeth with apical periodontitis were instrumented and irrigated with sodium hypochlorite and root filled. Peri-apical healing was followed-up for five years. Complete peri-apical healing occurred in 94% of cases that yielded a negative culture. In cases in which the samples were positive prior to root filling, the success rate of treatment was just 68%—a statistically significant difference. These findings emphasise the importance of eliminating bacteria from the root-canal system prior to obturation. This objective cannot be reliably achieved in a one-visit treatment of necrotic pulps because it is not possible to eradicate all infection from the root canal without the support of an inter-appointment antimicrobial dressing.<sup>25</sup>

Sodium hypochlorite (NaOCl) is the most widely used irrigating solution. It is a potent antimicrobial agent and lubricant that effectively dissolves pulpal remnants and organic components of dentine, thus preventing packing infected hard and soft tissue into the apical confines. Hypochlorous acid (HClO) is the active moiety responsible for bacterial inactivation.

NaOCl is used in concentrations varying from 0.5 to 5.25%; the *in vitro* and *in vivo* studies differ significantly in terms of the effectiveness of the range of concentrations as *in vitro* experiments provide direct access to microbes, higher volumes are used and the chemical milieu complexity of the natural canal space are absent as compared to *in vivo* experimentation. Siqueira et al. found no difference (*in vitro*) between 1%, 2.5% and 5% NaOCl solutions in reducing the number of bacteria during instrumentation.<sup>26</sup> What has been demonstrated is that the tissue dissolving effects are directly related to the concentration used.<sup>27</sup>

Perhaps the most misunderstood aspect of NaOCl irrigation is the need for the quantities of irrigation required due to the morphological and anatomical variations in the volumetric size of the root-canal anatomy. Siqueira et al. demonstrated that regular exchange and use of large amounts of irrigant should maintain the antibacterial effectiveness of the NaOCl solution, compensating for the effects of concentration.<sup>28</sup>

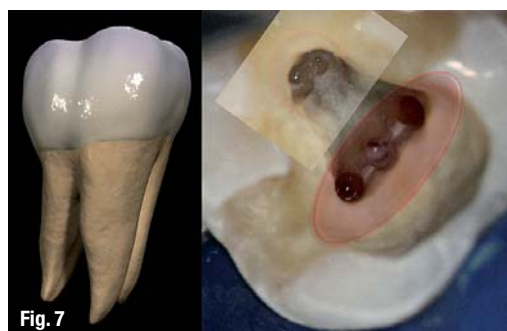

Fig. 7

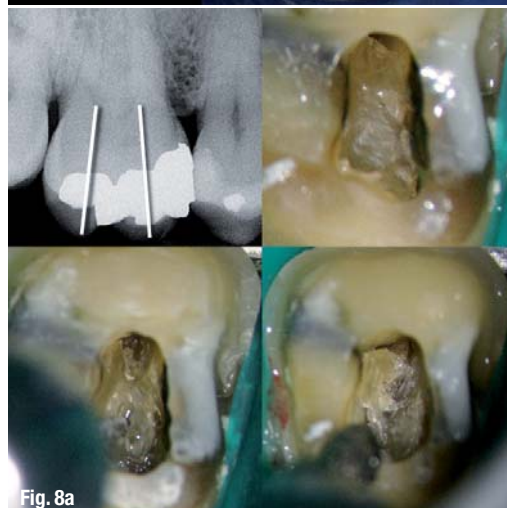

Fig. 8a

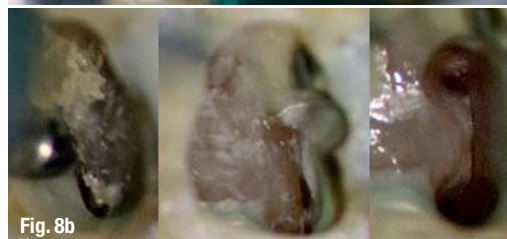

Fig. 8b

Numerous devices have appeared in the endodontic armamentarium to address this situation:

- \_ EndoVac (Discus Dental): a negative pressure differential device designed to deliver high volumes of irrigation solution while using apical negative pressure through the office high-volume evacuation system;
- \_ Negative Pressure Safety Irrigator (Vista Dental): device is similar to EndoVac;
- \_ Rinsendo (Air Techniques): uses pressure suction technology; 65 ml of irrigant are automatically drawn from the attached syringe and aspirated into the canal (pressure created is lower than manual irrigation); and
- \_ Vibringe (Bisco Canada): sonic flow technology facilitates enhanced irrigation through the myriad complexities of the root-canal system (Fig. 11).

NaOCl cannot dissolve inorganic dentine particles and thus prevent smear layer formation during instrumentation.<sup>29</sup> Chelators, such as EDTA and citric acid, are recommended as adjuvants in root-canal therapy. It is probable that biofilms are detached with the use of chelators; however, they have little if any antibacterial activity.

Several studies have demonstrated that citric acid in concentrations ranging as high as 50% were more effective at solubilisation of inorganic smear layer components and powdered dentine than EDTA. In addition, citric acid has demonstrated antibacterial effectiveness.

Technology and innovation will not negate the need for optimal preparation (debridement and disinfection) to eliminate microbial content and its impact on a necrotic root-canal system. We as a discipline need to improve; however, endodontics has shown its commitment to endless reinvention. In time, this will restructure the role of natural teeth in foundational dentistry, currently diminished by the market forces of implant-driven dentistry.

Ortho-biological replacement is not a panacea as random clinical trials increasingly show; the severity of peri-implantitis lesions demonstrates significant variability and as such no treatment modality has shown superiority. The pendulum will continue to swing as the endodontic implant algorithm becomes increasingly multivariate.

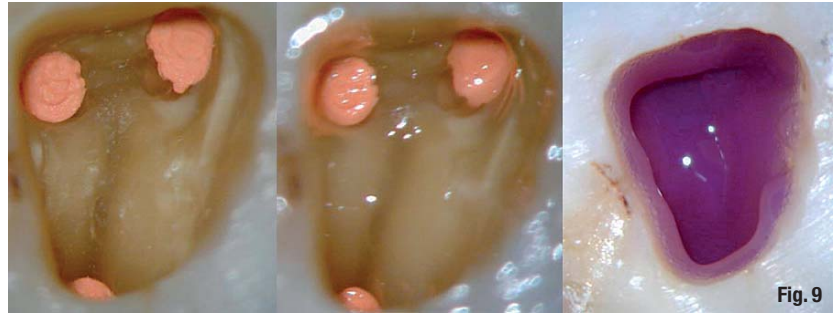


Fig. 9

**Microstructural replication—obturation**

Steven Covey is known for his book *The Seven Habits of Highly Effective People*. The habit most applicable to endodontics is the second one: "begin with the end in mind". The implication of this vision with regard to idealising the final shape of the root-canal system in order to ensure that the obturation represents a totality is profound. The root canal is negative space and as such recovery of its original unaffected form is the sine qua non of obturation or more descriptively, microstructural replication.

Fig. 9\_Micro-etching ensures the removal of oils and debris, and the elimination of the residue in fusion lines and fissures. Routine dentine bonding is then performed. The composite selected in this instance is PermaFlo Purple (Ultradent Products, Inc.), which enables differentiation of restoration and tooth structure should re-entry be necessary.

**irrigation, agitation techniques and devices**

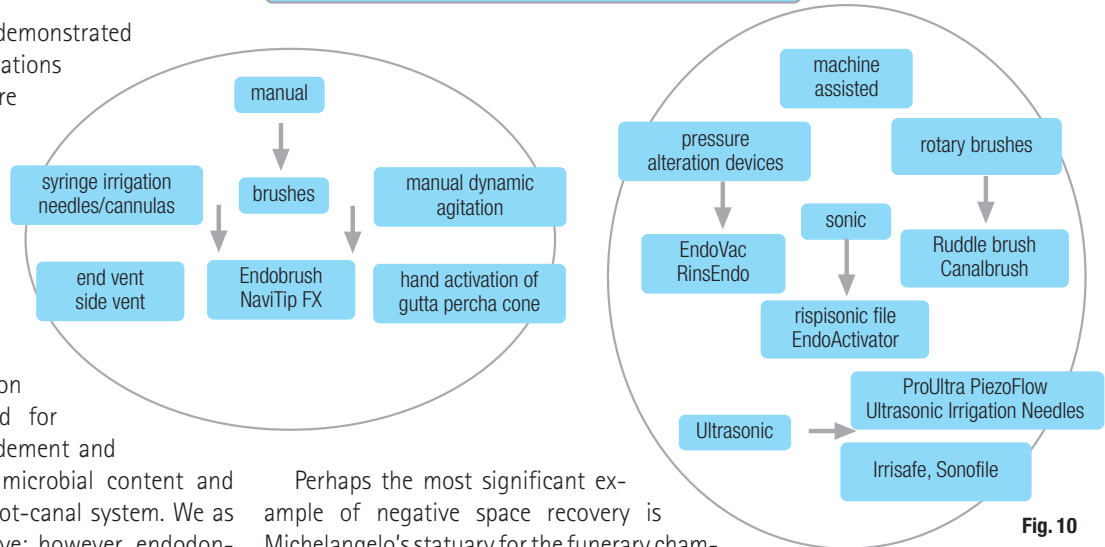


Fig. 10

Perhaps the most significant example of negative space recovery is Michelangelo's statuary for the funerary chamber of Pope Julius II. Four unfinished sculptures speak eloquently to this process: the figure was outlined on the front of the marble block and then Michelangelo worked steadily inwards from this side, in his own words "liberating the figure imprisoned in the marble". This is an exacting description of debridement and instrumentation of the root-canal space prior to root filling after a myriad of pathologic vectors have destroyed the dental pulp, and altered the morphology/topography of the system (Fig. 12). Incomplete filling of the debrided and sculpted root-canal space is one of the major causes of endodontic failure.<sup>30</sup> Until recently, *in vitro* testing (dye leakage, fluid

Fig. 10\_There is a vast array of equipment on the market to optimise irrigation protocols. Radical change may well be in the offing; however, research and development on bio-active obturating materials may prove to be the defining variable in total asepsis.

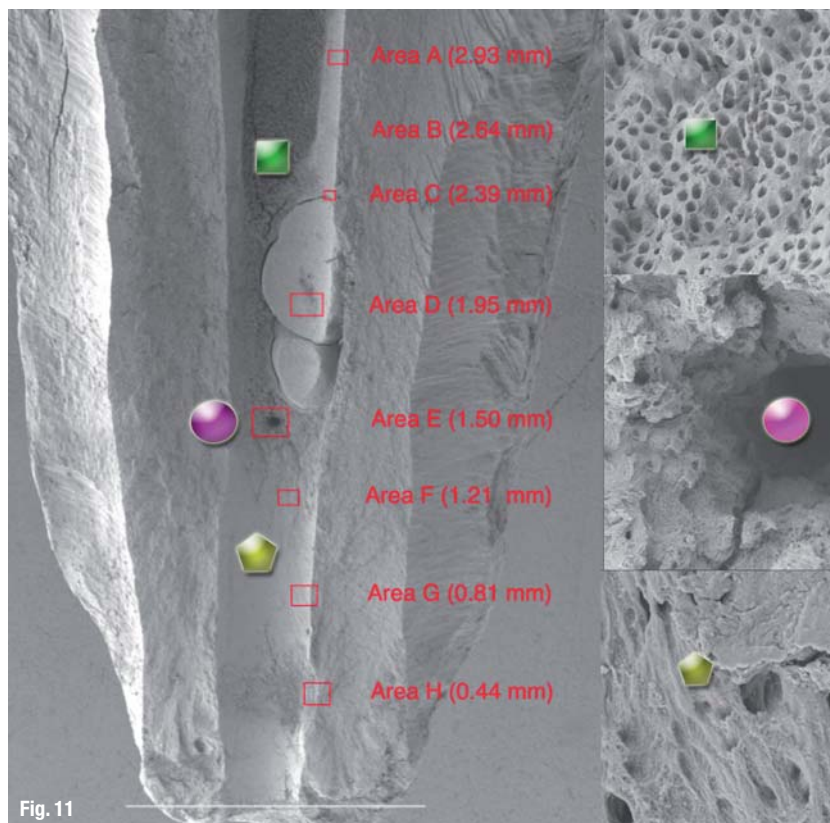


Fig. 11

**Fig. 11** Numerous researchers have demonstrated that the concept of keeping the apical foramen as small as practical does not mean a size #20 or 25 file. This Schilderian concept should read *as small as the apical morphology permits* in order to ensure that the free flow of irrigant to the apical terminus enables more definitive cleaning of the apical segment of the root-canal space.

transport, bacterial penetration, glucose leakage) was used to evaluate the sealing efficacy of endodontic filling materials and techniques by assessing the degree of penetration/absorbance of these tracers.<sup>31-33</sup>

Unfortunately, leakage studies are limited static models that do not simulate the conditions found in the oral cavity (temperature changes, dietary influences, salivary flow). Given the historic dominance of *in vitro* testing, the clinician must be cautious in extrapolating study findings to the clinical situation, regardless of manufacturer's claims.<sup>34</sup> This reliance on invalid testing protocols diminishes the monoblock assertions applied to the new generation of adhesive obturating materials proposed as the replacement material for gutta-percha.<sup>35</sup>

**Fig. 12** The artist/clinician recognises that negative space surrounding an object is equally important as the object itself. In the case of root-canal therapy, the positive space is alterable but must be created in balance with the encompassing negative space to ensure morphological integrity.

Gutta-percha was introduced to dentistry by Edwin Truman in 1847.<sup>36</sup> The concept of thermo-labile vertical condensation of gutta-percha was originally described by Dr J. R. Blaney in 1927.<sup>37</sup> The defining article on obturation remains Dr Schilder's classic on filling the root-canal space in three dimensions, published 40 years later.<sup>38</sup>

**Fig. 13** While there is no meta-analysis to elucidate this concern, the incidence of fracture of the mesial root of mandibular molars has been shown to have a significant correlation to cusp fracturing.

Logically, one cannot physically fill the root canal in two dimensions; however, one can fill the root-canal space badly in three dimensions. This does not disprove Dr Schilder's exposition, but it does demonstrate that words can easily be misconstrued and alter perspective once they become, as Kipling said, "the

most powerful drug of mankind". Ironically, Schilder's article came seven years prior to his treatise on cleaning and shaping the root-canal system, which even to this day remains the iconic standard.

The *Washington Study* by Ingle indicated that 58 % of treatment failures were due to incomplete obturation.<sup>39</sup> The corollary is obvious: teeth that are poorly obturated are invariably poorly debrided and disinfected. Procedural errors such as loss of working length, canal/apical transportation, perforations, loss of coronal seal and vertical root fractures have been proven to affect the integrity of the apical seal adversely.<sup>40,41</sup>

The Toronto study that evaluated success and failure of endodontic treatment at four to six years after completion of treatment found that teeth treated with a flared canal preparation and vertical condensation of thermo-labile gutta-percha had a higher success rate when compared with step-back canal preparation and lateral compaction. Highlighting the vertical condensation of warm gutta-percha obturation technique as a factor influencing success and failure simply confirmed a perspective evident to most endodontists from years of clinical empiricism.

There is a never-ending array of obturation materials, delivery systems and sealers appearing in the marketplace. Each is hallmarked by proprietary modifications and each is heralded as the most significant iteration in obturation since the previous one; today, we practice with a sad truism—marketing inexorably directs science. However, gutta-percha in combination with a myriad of sealers and solvents remains the primary endodontic obturating material. The dominant systems remain carrier-based obturation (Thermafil, Tulsa Dental Specialties), Continuous

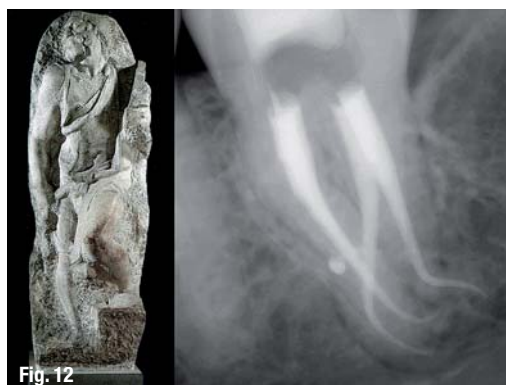

Fig. 12

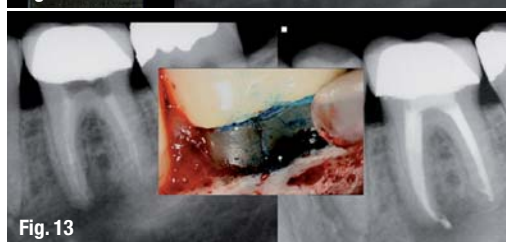

Fig. 13

# EndoInnovations III

SybronEndo offers you advanced technology for safer, more efficient procedures.




## REALSEAL 1 Warm-Bonded Obturator

All the components of RealSeal 1™ – sealer, filler and core – are resin-based materials that chemically bond with each other to form a *superior seal*. As an added benefit, this system's core is engineered to be easily seen on a radiograph.



## TF – Faster, Safer, Stronger

TF™ is twisted, not ground – unlike other nickel titanium files – making it more durable. Endodontic files are made by grinding the flutes, weakening the metal's molecular structure which can lead to separation. Our unique manufacturing process produces a file with optimal sharpness, strength and flexibility. TF allows you to work in difficult situations faster, safer and with a stronger file.



**SybronEndoEurope** | Safe files, superior fills.  
A DIVISION OF SYBRON DENTAL SPECIALTIES

SybronEndo Europe, Basicweg 20, 3821 BR Amersfoort, The Netherlands  
tel: +31 33 4536 159 fax: +31 33 4536 153 email: Endo@SybronDental.com

SybronEndo, 1717 West Collins Avenue, Orange, CA 92867  
800.346.ENDO 714.516.7979 Fax 714.516.7911 SybronEndo.com

Wave Compaction Technique (Elements Obturation, SybronEndo) and Thermoplastic Injection (Obtura III Max, Obtura Spartan).

Resilon (RealSeal, SybronEndo), a high-performance industrial polyurethane, was developed as an alternative to gutta-percha. There are scattered studies that demonstrate that Resilon exhibits less microbial leakage<sup>42</sup> and higher bond strength to root-canal dentine<sup>43</sup>, reduced peri-apical inflammation<sup>44</sup> and enhanced fracture resistance of endodontically treated teeth when compared with gutta-percha<sup>45</sup> (Fig. 13). Other studies have reported undesirable properties

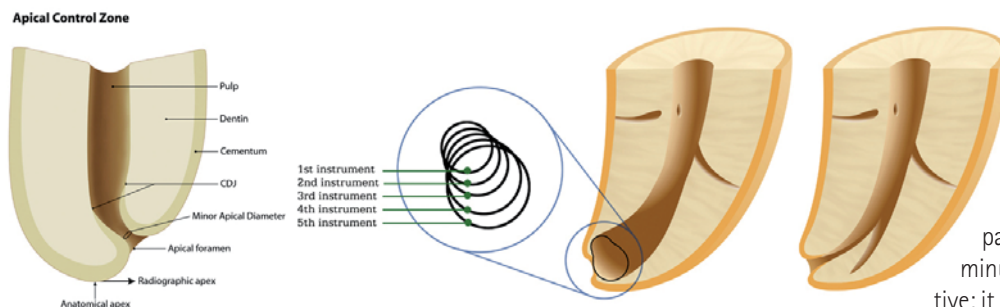


Fig. 14a

On left, the working length has two reference points, coronal and apical. Failure to maintain patency at the minor apical diameter will cause loss of the apical reference point as a result of blockage, or ellipticisation of the foramen.

associated with Resilon, including low push-out bond strength<sup>46</sup> and low cohesive strength plus stiffness.<sup>47</sup> In addition, Resilon did not achieve a complete hermetic apical seal.<sup>48</sup> These results indicate that a more appropriate material for root-canal obturation still needs to be developed. There is still no obturation method or material that produces a leak-proof seal. A material that is bio-inductive and promotes regeneration, a smart nano-material that can adapt to the ever-changing microenvironment of the canal system is essential, but to date, remains elusive.

All polymers demonstrate melt temperature and flow rate. Both gutta-percha and Resilon demonstrate a viscoelastic gradient that manifests as a dynamic rheological birefringence in the moulded state. Dependent upon the molecular weight of the source material (without the opacifiers, waxes and modifiers), gravimetric measurements of the time-temperature-transformation diagram of any moulding compound can be constructed. In the thermoplastic world of today, this has engendered an increase in the weight of the mass of obturating material and an improvement in the bacterial seal. This applies to carrier-based obturation techniques, Continuous Wave Compaction Technique and Obtura III obturation without cone placement.

### Instrumentation

The steps required for debridement and disinfection of the root-canal space are sequential and interdependent. Aberration of any node in the process affects the others, leading to iatrogenic damage and

potentially, treatment outcome failure. The most common distortion of native anatomy is ledging; canal curvature exceeding 20 degrees was shown to produce ledging of mandibular molars 56% of the time in a cohort of undergraduate students.<sup>49</sup> Dentine chips pushed apically by instrumentation incorporated with fragments of pulp tissue will compact into the apical third and the foraminal area causing blockage, altering the working length due to the loss of patency (Figs. 14a & b).

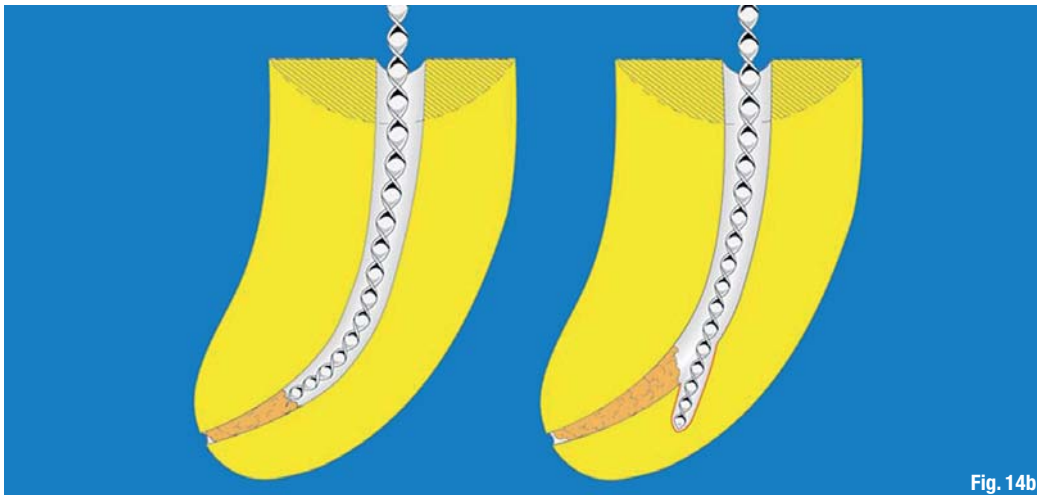
Apical patency is a technique in which the minor apical diameter of the canal is maintained free of debris by recapitulation with a small file through the apical foramen.<sup>50</sup>

The most predictable method is to use a designated patency file regularly throughout the cleaning and shaping procedure in conjunction with copious irrigation. A #0.08 K-file passively moved through the apical terminus without widening it is most effective; it will refresh the NaOCl at the terminus as the action of the file going to the point of patency produces a fluid dynamic. Regrettably, loss of working length remains a common adverse event during endodontic therapy, especially amongst less experienced clinicians. Its major cause is the formation of an apical dentine plug. Therefore, establishing apical patency is recommended even during treatment of canals with vital pulp.<sup>51</sup>

Historically, numerous techniques have been advocated for canal preparation (balanced force, anti-curvature, double-flare, modified double-flare); however, step-back<sup>52</sup> and crown-down<sup>53</sup> are the most universally accepted. Experience has shown a crown-down preparation will cause fewer procedural errors (apical transportation, elbow formation, ledging, strip perforation, instrument fracture). The preliminary removal of coronal dentine (pre-enlargement—treating the apex last) minimises blockage and enables an increasing volume of irrigant penetration, thereby sustaining working length throughout the procedure.<sup>54</sup>

The balanced-force shaping philosophy is integral to the crown-down approach. Its premise is that instruments are guided by the canal structure when rotational/anti-rotational motion (watch winding) is used. Changing the direction of rotation controls the probability that instruments will become overstressed and thus ensures that the cutting of structure occurs most efficiently.<sup>55</sup> Endodontists have long appreciated what the science reported, that the balanced-force hand instrumentation technique produced a cleaner apical portion of the canal than other techniques (Fig. 15).<sup>56,57</sup> As discussed below, I remain committed to hand filing in order to refine





**Fig. 14b** The volume of irrigant necessary to prevent apical blockage is indeterminate. While NiTi rotary instrumentation has minimised this to a significant degree, a slurry of dentine mud is always a risk factor to be monitored.

apical third shaping and creating an enhanced apical control zone taper.

Two distinct phases are required for the preparation of canals with NiTi rotary files. It is essential that, no matter the protocol used, a reservoir of NaOCl be maintained and replenished repeatedly in the strategically extended access preparation. The coronal portion of the canal space is explored with small-sized K-files to establish a glide path for the rotaries to follow. The taper of NiTi files, regardless of manufacturer, induces a crown-down effect in the straight portion of the canal. After the coronal and middle third segments have been opened and repeatedly irrigated with NaOCl, a sequence of small K-files can progress apically, ultimately defining patency, confirming the topography of the accessible canal space and its degree of curvature. A second 'wave' with the NiTi rotaries is then used to effect deep shape, approximating the working length, and depending upon the configuration of the apical third, to enlarge the terminus to the gauged apical size and initiate the taper of the apical control zone.<sup>58</sup> This is a basic concept. It is inherent in all templated protocols that each tooth is different, and modifications to the process are always necessary as a function of the tooth morphology.

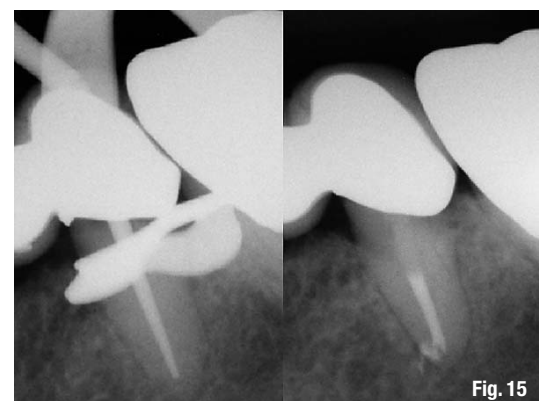
The apical control zone is defined as a matrix-like region created at the terminus of the apical third of the root-canal space. The zone demonstrates an exaggerated taper from the spatial position determined by an electronic foraminal locator to be the minor apical diameter. Whether this is linear or a point determination is a function of histopathology. The enhanced taper at the terminus creates a resistance form against the condensation pressures of obturation and acts to prevent excessive extrusion of filling material during thermo-labile vertical compaction.

All NiTi systems are modelled upon a single or multiple taper ratio per millimetre of file length. Figure 16a

demonstrates the metrics of the F1, F2, F3 finishing files of the ProTaper Universal System (my preference). These files demonstrate a common taper in the last 4mm of the file, which in the vast majority of situations corresponds to the length of the apical third of the root-canal space. As shown, the 0.07 taper of the F1 (0.20 tip), the 0.08 taper of the F2 (0.25 tip) and the 0.09 taper of the F3 (0.30 tip) produce the corresponding diametral dimension indicated each millimetre back from the apical terminus, if the crown-down protocol built into this multiple taper file system is adhered to. If the shape of the internal micro-morphology of the root complex were epidemiologically similar, then imprinting of the canal preparation would be logical. Unfortunately, such is not the case.<sup>59</sup>

Figure 16b demonstrates that the use of hand files in the apical third can alter the preliminary shape created by the NiTi files. Hand files have a 0.02 taper (along the shaft of the file, the diameter increases by 0.02 mm per mm of length—a 0.20 file with 16mm of flutes would be measure 0.52 mm at the coronal end of the flutes). In the example shown, a #20 file is positioned at the minor apical diameter. Careful positioning of a series of file within the last millimetre can produce a 0.2 mm or 20% taper with no undue disruption of the native anatomy. Schilder's precept for shaping was to keep the apical foramen as small as practically possible. Whatever file approximates the minor apical diameter, in conjunction with hand filing, the apical control zone created will enhance the apical seal, as the rheological vectors of compaction and condensation have a greater lateral volume of displacement at the terminus.

**Fig. 15** Rheology is a science that addresses the deformation and flow of matter. The biochemistry of filling material, its viscosity gradient, the lubricating effect of sealer and optimal thermal application are only as effective as the flow characteristics of the shape created and its degree of cleanliness.

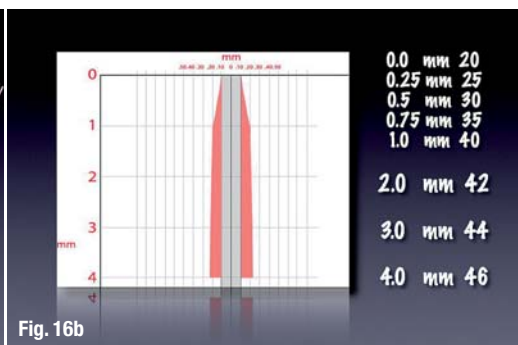
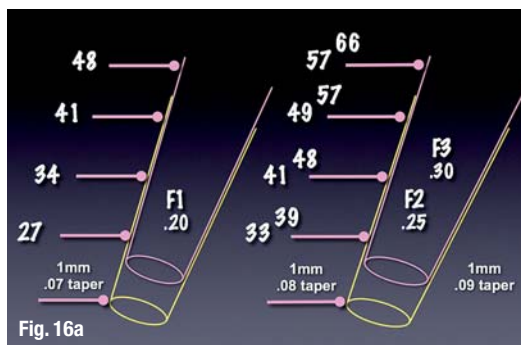


**Fig. 15**

**Fig. 16a** The ProTaper Universal System consists of two shaping files that address the planes of geometry of the coronal and middle thirds of the root-canal space. There are five finishing files that include tips sizes: 20, 25, 30, 40 and 50. Tapers range from 0.06 to 0.09 through the series.

A thorough understanding of the metrics is essential for the preparation of the myriad variations in internal micro-morphology of the root-canal space and the assurance of minimal iatrogenic impact.

**Fig. 16b** Modification of taper in the last millimetre of the apical terminus exaggerates the constriction or minor apical diameter. Thermo-labile vertical condensation has been shown to enhance successful endodontic outcomes. The matrix effect of the apical control zone enhances the gravimetric density of the required hermetic apical seal and enables more material to flow into the region to occlude fins, cul-de-sacs, deltas and lateral arborisations.



### A risk-assessment algorithm

If the biological parameters that mandate endodontic success are adhered to, in almost all cases, treatment outcomes will be successful. The endodontic implant algorithm processes the array of contributing factors leading to endodontic failure, in order to determine whether to implement a re-engineered endodontic approach or to extract and replace the natural tooth with an osseo-integrated implant. It finds the greatest common divisor amongst the degree of coronal breakdown of the involved or adjacent teeth, the quality and quantity of the bone support and tissue condition, and the engineering demands to be born by the tooth or teeth in question, and assesses the occlusal scheme and the patient's aesthetic and functional expectations of treatment.

The reasons for tooth extraction may include, but are not limited to, crown-to-root ratio, remaining root length, periodontal attachment levels, furcation


status, periodontal health of teeth adjacent to the proposed fixture site and non-restorable carious destruction. In addition, the clinician must consider questionable teeth in need of endodontic treatment, teeth requiring root amputations, hemi-sections or advanced periodontal procedures with a questionable prognosis, and pulpless teeth fractured at the gingival margin with roots shorter than 13 mm. These teeth will require endodontic treatment, crown lengthening, post/cores and crowns; however, their longevity is much in doubt with these parameters.<sup>60</sup>

Practitioners are ethically obligated to inform patients of all reasonable treatment options. It is the patient's attitude, values and expectations that are integral to the risk assessment algorithm. Poor motivation to retain a tooth mandates extraction, not clinical intervention, whereas high motivation advocates non-surgical intervention or surgery. The process of planning, presentation and acceptance of dental treatment plans is always dominated by the duality of emotion and pragmatism associated with cost. Where it becomes specious is the side-by-side dollar comparison of restoring a natural tooth or placement of a fixed bridge etc. in contrast to ortho-biological replacement of a debilitated tooth. Far too often the comparison of purported treatment outcome percentages are based upon corporate affiliation and/or fiduciary bias, or are simply too narrow a parameter to suggest comparable alternatives. With the treatment options available to an experienced endodontist, only very few structurally sound teeth need be removed.

Benjamin Disraeli said: "Expediency is a law of nature. The camel is a wonderful animal, but the desert made the camel". The endodontic implant algorithm raises the question: Does science drive the market, or does the market drive science. "All truths are easy to understand once they are discovered; the point is to discover them," Galileo said. Time and forbearance will bear witness to the discovery of the salient and relevant truths that guide the endodontic implant algorithm.

*Editorial note: Part II of this article will be published in roots 2/2010. A complete list of references is available from the publisher.*

\_about the author
roots



**Dr Kenneth S. Serota** graduated from the University of Toronto in 1973 and was awarded the George W. Switzer Memorial Key for Excellence in Prosthodontics. He received his Certificate in Endodontics and Master of Medical Sciences degree from the Harvard-Forsyth Dental Center in Boston.

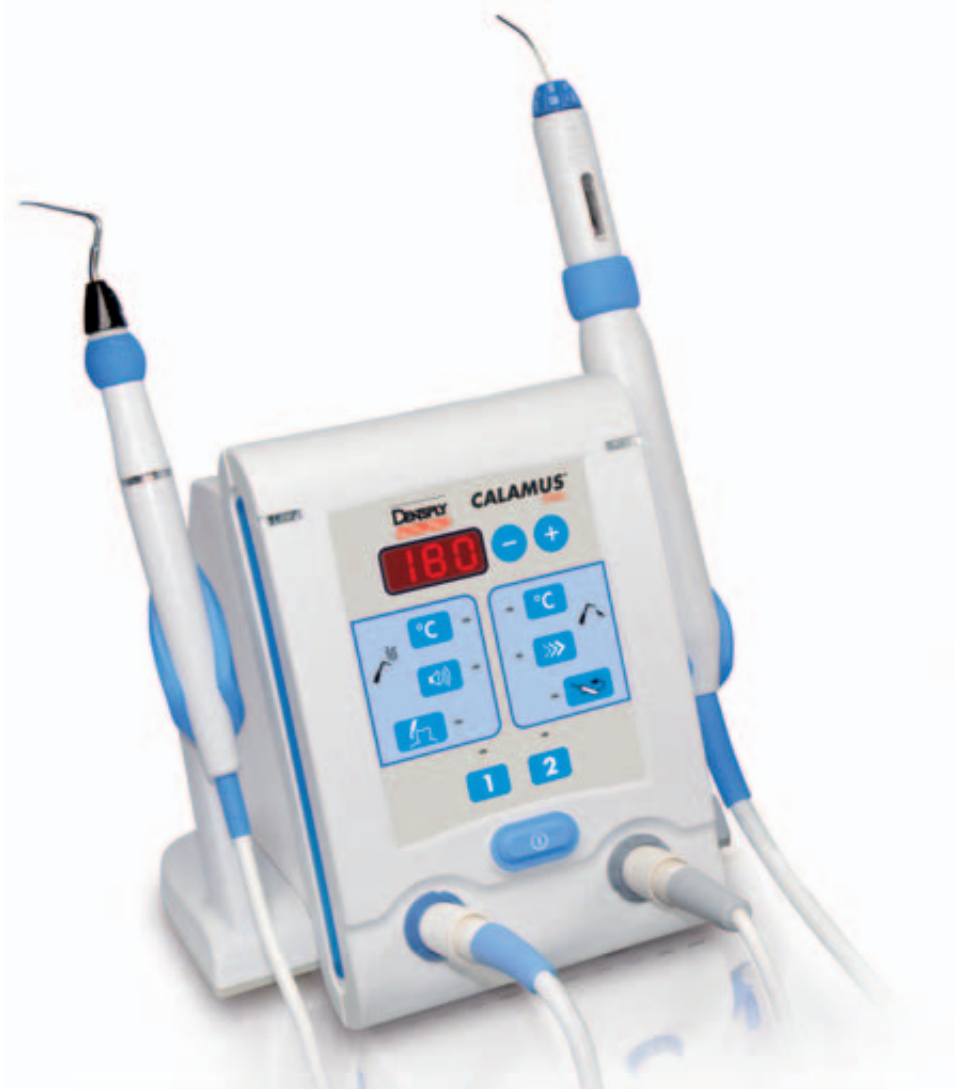A recipient of the American Association of Endodontics Memorial Research Award for his work in nuclear medicine screening procedures related to dental pathology, his passion is education, and most recently e-learning, and rich media. Dr Serota provided an interactive endodontic programme for the Ontario Dental Association from 1983 to 1997 and was awarded the ODA Award of Merit for his efforts in the provision of continuing education.

The author of more than 60 publications, Dr Serota is on the editorial board of *Endodontic Practice*, *Endo Tribune* and *Implant Tribune*. He founded ROOTS, an online educational forum for dentists from around the world who wish to learn cutting-edge endodontic therapy, and recently launched IMPLANTS ([www.rximplants.com](http://www.rximplants.com)) and [www.tdsonline.org](http://www.tdsonline.org) in order to provide dentists with a clear understanding of the endodontic-implant algorithm in foundational dentistry.

# CALAMUS<sup>®</sup> DUAL

DOWNPACK & BACKFILL

FAST AND TIGHTLY SEALED ROOT CANAL FILLINGS



## TIME-SAVING AND LONG-LASTING 3D OBTURATION OF ROOT CANALS

Filling was never so easy!

- Obturation device for downpack and backfill

Device designed for your comfort

- Ergonomically designed handpieces with large operation angle and feather-touch activation by flexible silicone ring

Lateral or vertical obturation? Better results with Calamus<sup>®</sup>

- Vertical condensation is a faster method to achieve a long-lasting, tightly sealed, three dimensional root canal filling
- Reliable obturation of lateral canals as well as minimal risk of root fractures

**DENTSPLY**  
**MAILLEFER**

[www.dentsplymaillefer.com](http://www.dentsplymaillefer.com)

# Apical microsurgery— Part IV: The REB and REP

Author\_ Dr John J. Stropko, USA

The amount or degree of the root-end bevel (REB) is of utmost importance and should be precisely planned after considering the overall crown–root ratio, presence of posts or other obstacles, root anatomy, and periodontal status of the tooth. According to previous research, 98% of canal system ramifications occur in the apical 3 mm.<sup>1</sup> If the bevel is long (traditionally 25° to 45°), an excessive amount of root structure would have to be removed to include the apical 3 mm on the palatal or lingual part of the root's apical canal system (especially in roots with multiple canals).

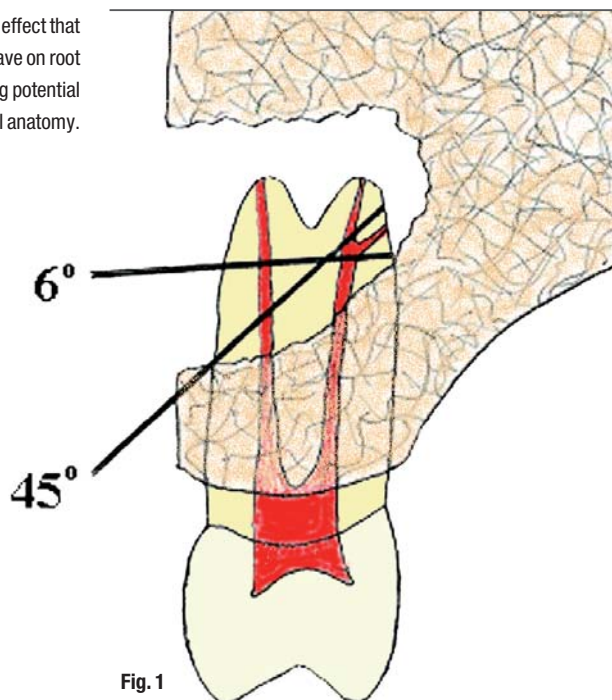
operator to overcome while trying to visualise the true long axis of the canal system (Fig. 2); the longer the bevel, the greater the tendency for the operator to leave more of the palatal or lingual aspect of the root intact.

As it is difficult to visualise the long axis of the tooth, the resultant retro-preparation is not as likely to be within the long axis of the canal. This concept is extremely important and the primary reason for the occasional, unintentional perforation of the retro-preparation to the lingual or palatal (Figs. 3a & b). Another important consideration—with a bevel as close to 0° as possible—is that the cavo-surface marginal dimensions of the root-end preparation (REP) will be considerably decreased. Therefore, the restoration will be easier to place and have less chance of leakage.

The root anatomy is especially important when there are more than two canals in one root. This occurs most commonly in maxillary bicusps and in the mesial roots of nearly all molars. It has been shown that as many as 93% of the mesio-buccal (MB) roots of the maxillary first molars have a second canal (MB2).<sup>2</sup> However, the operator has to be constantly aware that multiple canals can occur in any root, no matter which tooth is being operated on. If there is an isthmus present, it can usually be seen with the Operating Microscope (OM) if the root has been adequately bevelled and stained with methylene blue.

The refinement of the bevel is best accomplished with a surgical length 1171 carbide tapered fissure bur (Brassler) in a 45° handpiece (SybronEndo; Fig. 4). No air exists from the working end of these handpieces, which nearly eliminates the possibility of an air embolism or air embolism beneath the flap. A standard high-speed handpiece should never be used for the above reason. On occasion, the refinement of the bevel can cause additional bleeding due to an enlargement of the crypt. The operator should address any crypt management problem due to a newly created crypt before proceeding any further. Remember that it is of utmost importance to complete one step before proceeding to the next step.

Fig. 1 Illustration of the effect that different bevel angles have on root length, including missing potential lingual anatomy.



If the bevel is closer to 0°, the lingual 3 mm is easier to remove; thus, more root structure can be conserved, improving the crown–root ratio. With a long bevel, there is also an increased risk of completely missing some important palatal or lingual anatomy, especially if the operator is in any measure attempting to be conservative in order to preserve the crown–root ratio as far as possible (Fig. 1). The long bevel also creates a spatial problem that is generally impossible for the

After the REB has been refined and crypt management is completely under control, the apical surface is rinsed and dried with a Stropko Irrigator. The clean and dried surface is then stained with methylene blue. It is important to allow the methylene blue to remain on the tooth for just a short period before gently rinsing and drying again, in order to enable inspection of the stained surface. Normally, a fresh, white piece of Telfa is reinserted for better lighting. If there are any fractures, isthmus tissue or accessories present, the staining will greatly enhance the operator's ability to visualise them. Also, the methylene blue will stain the periodontal ligament and enable the operator to ensure the apex has been completely resected (Figs. 5a & b). If there is an accessory canal present, the easiest solution is usually to bevel past it and re-stain; or, on occasion, the accessory can be troughed-out, leaving the bevel as is.

When two canals are present in the same root, it is necessary to prepare for an isthmus between the two canals even if the staining did not reveal one. It has been shown that in the MB roots of the maxillary first molars with two canals, the 4 mm section displayed a partial or complete isthmus 100% of the time.<sup>2</sup> This, combined with the finding that two canals in the same root in maxillary molars present clinically at least 93% of the time in the MB root of the maxillary first molar, lends importance to always preparing the isthmus area of the REB.<sup>3</sup> Although staining does not always reveal the presence of an isthmus, it may lie just below the REB surface, only to be exposed during the remodelling of the surface of the bevelled root that normally takes place during the healing process (Fig. 6). The rule is to prepare an isthmus when there are two canals in one root.

The preparation of the REP is best accomplished using ultrasonics. For the most part, they are all dependable and have a good service record. There are multitudes of ultrasonic tips from which to choose. The newer diamond-coated and vented tips (ProUltra tips, DENTSPLY Tulsa Dental; KiS tips, Obtura/Spartan) are much more efficient and especially good at re-

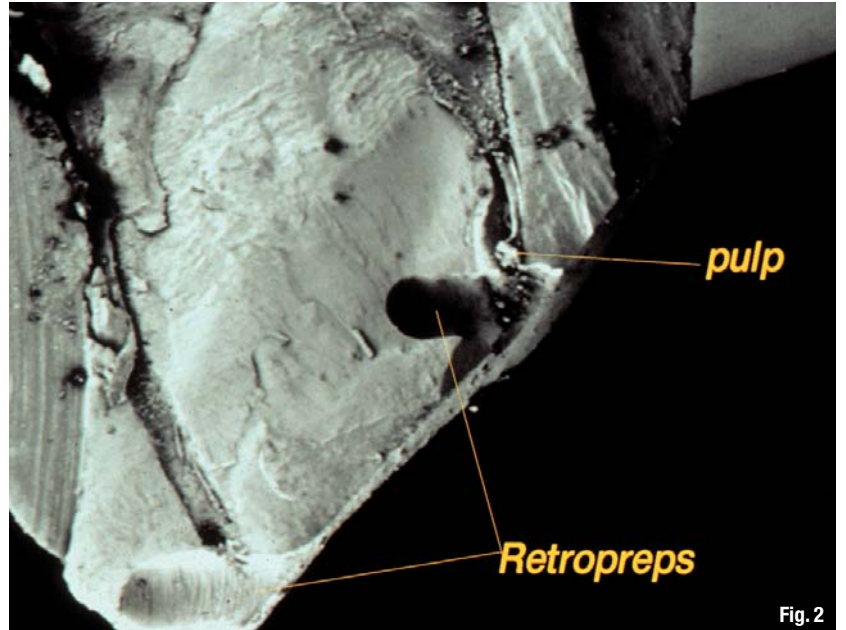


Fig. 2

moving gutta-percha. Rather than the brand of the ultrasonic unit or type of tip, the most important consideration is the manner in which the instrument is used. The tendency for the new operator is to use the ultrasonic unit in the same manner (regarding pressure) as the handpiece. The secret is to start at a low power setting and use an extremely light touch. The lighter the touch, the more efficient the action of the tip will be. The correct amount of coolant is also important. If too much spray is used, visibility and cutting efficiency will both be decreased. If too little spray is used, there will be insufficient cooling and overheating, which can lead to micro-cracks.

**Fig. 2** Long bevel with round bur preparations, demonstrating angulation and orientation problems. (Courtesy: Dr Gary Carr)

Various left and right tips of various angles are necessary on occasion, but in most cases anterior tips will suffice. If the canal is large and/or filled with gutta-percha, a larger, coated tip can be used most efficiently. The key is to: 1) slow down; 2) be gentle; 3) use a light, brushing movement; and 4) carefully regulate the power setting of the ultrasonic unit. The power setting will vary greatly depending on the tip being used and nature of the preparation task.

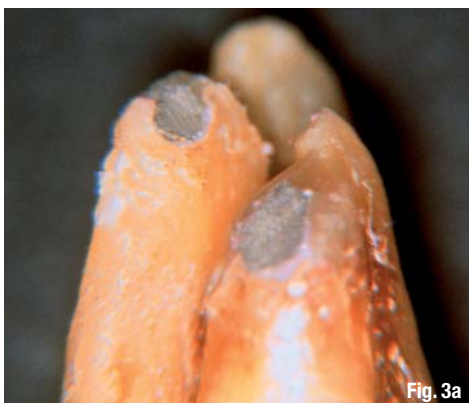

Fig. 3a

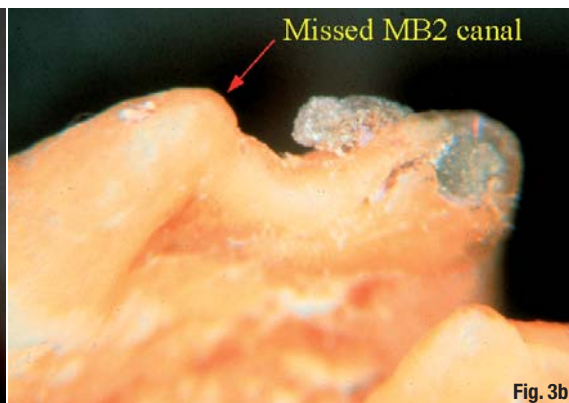
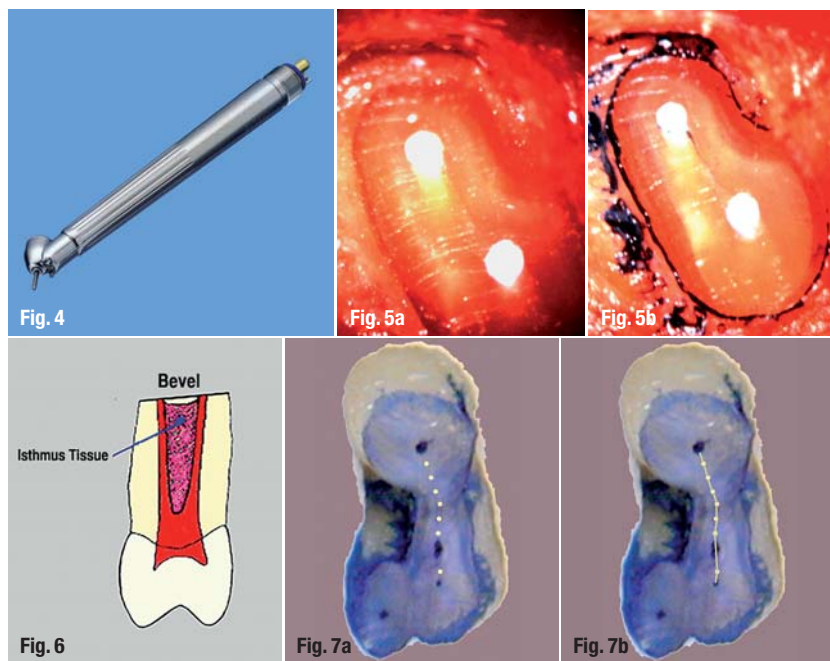


Fig. 3b

**Figs. 3a & b** Inadequate and acute 45° bevel clearly demonstrates the way perforations can occur and canals can be missed. The operator's view from the buccal (Fig. 3a). View of actual occurrence, as completely missed by the operator (Fig. 3b).



The needle inserted into the Stropko Irrigator is then bent to a similar angle to that of the ultrasonic tip to be used for the REP (Fig. 8). Always keep in mind that cleanliness and dryness are essential for good visibility when using the OM.


The buccal aspect of the internal wall of the REP is of particular interest. Dr Richard Rubinstein was the first to point out that often this area is not debrided, owing to the angulation of the ultrasonic tip within the canal system during the REP. If there is some gutta-percha streaming up the side of the wall and the preparation is finished, the best thing is to use a small plugger and fold the gutta-percha coronally so the wall is clean once more. It is usually futile to attempt to remove that gutta-percha with an ultrasonic tip.

The ideal REP should: 1) be within the long axis of the canal system; 2) have parallel walls; 3) be at least 3 mm in depth (including the isthmus portion of the preparation); 4) be adequately extended to include any buccal or lingual variations of the canal system; 5) be clean (free of a smear layer); and 6) be dry and ready to accept any type of root-end filling material.

After completion of the REP, it should be rinsed and dried once more with the Stropko Irrigator. The REP is re-inspected, using micro-mirrors and the varying powers of the OM and/or endoscope, in order to ensure it is clean and within the long axis of the canal system. At this time, the REP is etched with blue 35% phosphoric acid gel (Ultra-Etch, Ultradent) to remove the smear layer. After 15 to 20 seconds, the REP is thoroughly rinsed and dried with the Stropko Irrigator and re-examined with the OM. If all is satisfactory, a 20-second application of 2% chlorhexidine will help eliminate any residual organisms. After a final rinse and dry, the REP is ready for the root-end fill.

In the final two parts of this series, we will discuss *Retrofill materials and techniques* (Part V) and *Sutures, suturing technique and healing* (Part VI).

*Editorial note: A complete list of references is available from the publisher.*



**Fig. 4** A surgical handpiece, such as Impact Air (SybronEndo), should be used to prevent the possibility of an air embolism.

**Figs. 5a & b** Unstained (a) and stained (b) resected root surfaces. (Images courtesy of Dr Gary Carr).

**Fig. 6** An illustration of an isthmus lying just below the surface that would not be evident even after staining with methylene blue.

**Fig. 7a** The series of 'dots' permit easy and accurate preparation of an isthmus in a root end that is very thin.

**Fig. 7b** With the water spray still off, the 'dots' are connected to establish a tracking groove in order to guide a more aggressive ultrasonic tip in finishing the REP.

**Fig. 8** For ergonomics, the modified tip used in the Stropko Irrigator should be bent to an angle similar to that of the ultrasonic tip that will be used during the REP.

For the preparation of an isthmus, an uncoated, fine-pointed tip (CT-1, SybronEndo) is inserted into the ultrasonic unit and used to create a precise series of multiple 'dots' on the stained or imaginary line between the two canals. For the dot technique, the ultrasonic unit is set at a low power setting but inactivated, the water spray is turned off, a CT-1 tip is placed exactly where desired, and the rheostat is tapped for just an instant. The process is repeated as many times as necessary until there is a series of 'dots' (Fig. 7a). Then, while the water spray is still off, the dots are gently connected to create the initial, shallow but precise tracking groove (Fig. 7b). The dot technique is of great value, especially when there is concavity present and the width of the bevelled root is very thin mesially to distally. The resultant groove serves as a definite guide for the completion of the isthmus portion of the REP. Then, with the water spray turned back on and the power increased slightly, a pointed, coated tip can be used more aggressively to deepen the tracking groove. In this manner, accuracy is completely controlled and there is no chance of slipping while preparing the isthmus in a very thin root. On occasion, if the walls of the preparation become too thin, further bevelling may be necessary.

Throughout the REP process, it is important to use the Stropko Irrigator to rinse and dry the REP in order to ensure it is kept within the long axis of the canals and all debris is being removed as planned. Various sizes of micro-mirrors or an endoscope can be used to periodically inspect the preparation and confirm accuracy. A pre-cut and pre-bent 25-gauge endodontic irrigating needle (Monoject, Carson Dental) works well for this purpose. The notched end is removed by rapidly bending the end third rapidly back and forth with Howe Pliers (Magnum Ortho) until it separates.

_contact	roots
<p><b>Dr John J. Stropko</b>                  8757 E. Double Eagle Dr.                  Carefree, AZ 85377                  USA                  E-mail: topendo@aol.com</p>	

# SCIENCE IS GLOBAL

## NEW LEARNING EXPERIENCE



### BEYOND ENDODONTICS:

ENDOEXCELLENCE, MICRO-DENTISTRY,  
DENTAL TOMOGRAPHY (CBCT), BUILDUP OF ROOT  
CANAL TREATED TEETH, DENTAL TRAUMATOLOGY,  
PERIODONTICS & IMPLANTOLOGY

[www.rootssummit2010.com](http://www.rootssummit2010.com)

**Barcelona**  
**Endodontics**  
**Summit 2010**

**June 3rd, 4th & 5th**

- Hands-on and lectures with 20 experts from across the world
- Meet & Interact Face-to-Face with Colleagues & Experts
- Network friendly
- Further information and registration under: [www.rootssummit2010.com](http://www.rootssummit2010.com)

# The importance of endodontics in implant treatment planning

Author\_ Dr Jose M. Hoyo, USA

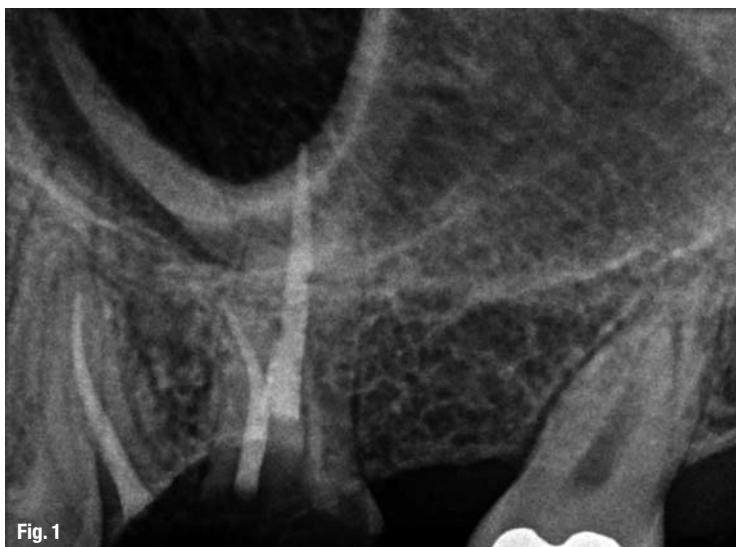

Fig. 1

Fig. 1\_Pre-op radiograph prior to extraction.

There's a new vision in dentistry that is gradually being recognised and is referred to as the endo-implant algorithm. This new approach considers the role of the endodontist as critical in considering whether a tooth can be saved or whether extraction and replacement with a dental implant is the correct treatment protocol. An endodontist is in the unique position to evaluate critical factors leading to endodontic failures in order to determine whether another endodontic procedure will lead to a predictable and successful outcome. Should the outcome not be favourable, then extraction and replacement with a dental implant would be the protocol to follow.

In considering the ideal treatment plan, it is imperative to provide the patient with all treatment options, as well as the financial cost and procedures associated with each treatment option. The patient is thus given the opportunity to make an educated decision as to the best treatment protocol for him or her. The information presented to the patient should include the endodontist's opinion regarding which treatment option is more practical and predictable.

## \_Case study

A patient with a non-contributory medical history was referred to my office for evaluation of the maxillary left first molar. The patient was asymptomatic, and the tooth had been endodontically treated by a general dentist approximately seven months prior to the consultation and had never been restored. Clinically, it presented extensive decay, probing depths of 3 mm all around, exposure of the obturation material to the oral cavity, and no temporary restoration. Radiographically, no peri-apical lesions were detected, and the bone levels around the tooth were adequate (Fig. 1).

In order to determine the integrity of the tooth structure, some excavation was performed using 4.5 x magnification and supplementary illumination, provided by a fibre-optic headlight, with a dental rubber dam for isolation. After the removal of some decay, a bitewing X-ray was taken (Fig. 2) and the following was determined:

- the floor of the pulp chamber was too shallow;
- it was too close to perforation and
- the peri-radicular dentine was insufficiently strong to support a permanent restoration.

These critical factors, in my opinion, rendered the tooth non-restorable. A cotton pellet and Cavit were placed in the access cavity and a follow-up call with the referring dentist was conducted in order to update him on the condition of his patient and to determine what recommendations should be given regarding the tooth. It was recommended to the patient that the tooth be extracted and the socket preserved through a minor grafting procedure. This would allow for an ideal amount of bone to receive a dental implant approximately four to six months later. It was also recommended that he receive some orthodontic treatment prior to the placement of the



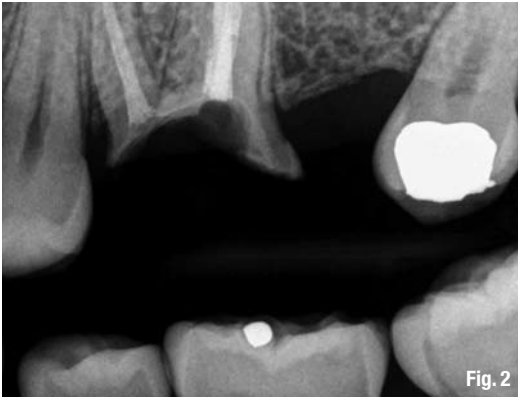

Fig. 2

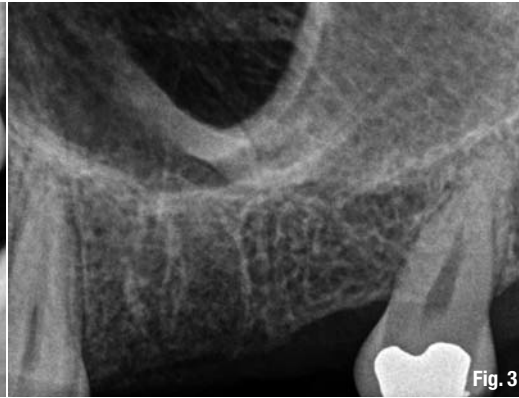


Fig. 3

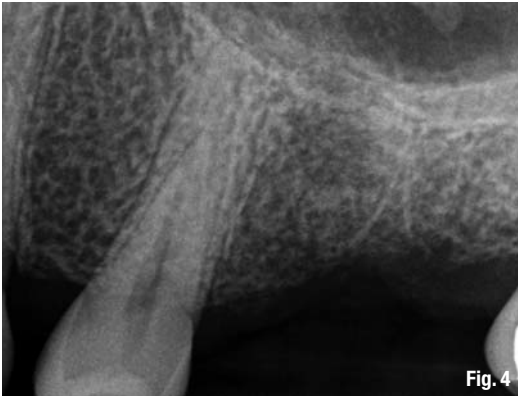


Fig. 4

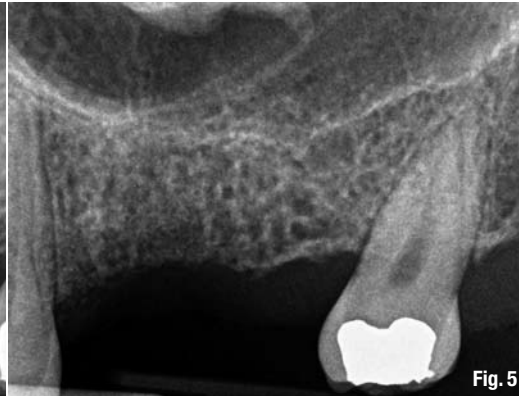

Fig. 5

**Fig. 2**\_ Bitewing X-ray after decay had been removed.

**Fig. 3**\_ Grafted socket following extraction.

**Fig. 4**\_ Peri-apical film showing healing of grafting material after four months.

**Fig. 5**\_ Pre-op film on the day of surgery.

implant so that all the diastemas would be closed and the dentition properly aligned for this procedure.

The patient clearly understood the concept and the logistics of the orthodontic treatment recommended but expressed no interest in this approach.

### The bigger picture

It is very important in evaluating treatment using implants to consider the whole dentition and not just the space or tooth in question. It should be borne in mind that implants, unlike teeth, do not move, so if there are any misalignments in the dentition, orthodontic treatment prior to implant therapy is imperative should the patient proceed with the dental implant at a later stage. If the treatment plan is not in this sequence, the dental implant could become a challenging obstacle during the orthodontic treatment.

The patient was prescribed Amoxicillin 500mg (one every six hours, beginning two days before the next appointment) and Chlorhexidine rinses (three times a day, also beginning two days before the next appointment). The use of tartar control toothpaste was also recommended in order to avoid staining of teeth. On the day of surgery, the patient's blood pressure was 119/73 with a heart rate of 76.

Under local anaesthetic (Lidocaine 2% HCl with epinephrine 1/50,000 x 2 cpl) and using a dental rub-

ber dam, magnification loupes and supplementary illumination, the tooth was sectioned into three pieces. The rubber dam was removed, and using PDL-Evator elevators (Salvin) all three roots were extracted without any complications. Spoons were used to curette the socket in order to clean any granulation tissue and engage the cancellous bone. This crucial step results in some bleeding and thus promotes angiogenesis. The crest of the interradicular bone was engaged with the socket cupped part of a XIVE osteotome (DENTSPLY Friadent), and a sinus lift was performed using the Summer's technique.

There were no signs of a sinus perforation based on the Valsalva test. The sockets and sinus-lift area were

**Fig. 6**\_ Guide pin in osteotomy following use of 2 mm pilot drill.

**Fig. 7**\_ Radiograph showing XIVE osteotome in place during the osteotomy.

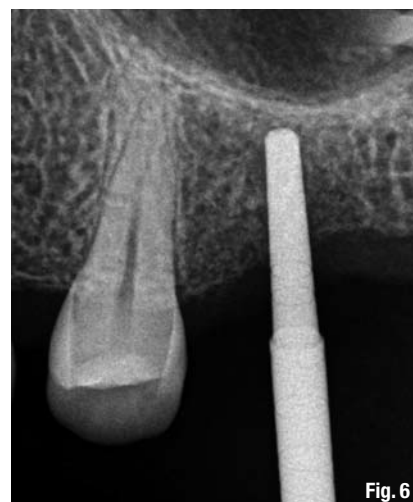
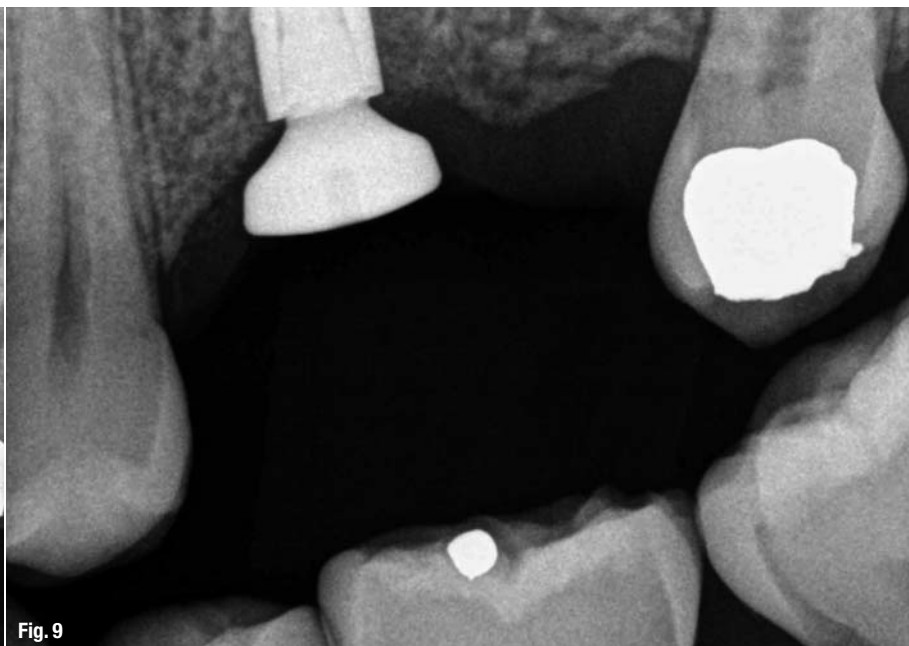
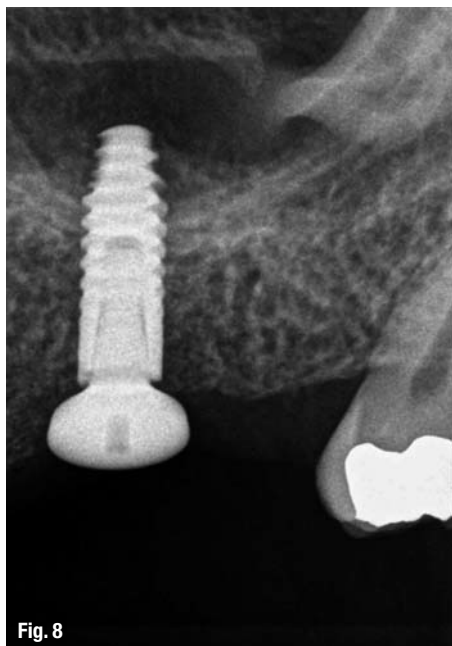


Fig. 6

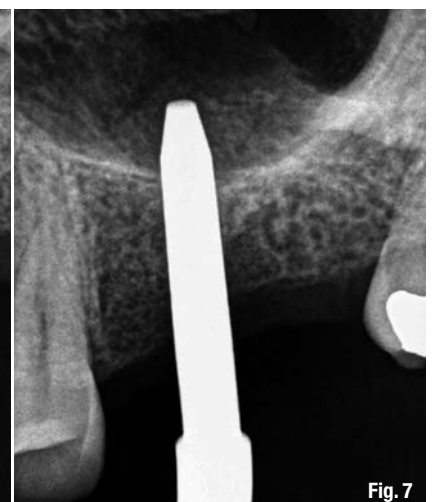

Fig. 7



**Fig. 8** Radiograph of implant with sulcus former (healing abutment); the apical portion of the implant is under the Schneiderian membrane.

**Fig. 9** Bitewing X-ray showing sub-crestal placement of implant with sulcus former in place.

then grafted with a mixture of DBX and MCP using a marshmallow technique. This grafting mixture helps the site produce its own bone in terms of mineral and collagen from the DBX, and it provides a better scaffold effect from the MCP. The area was covered with a PTFE membrane, slightly tucked under the periosteum (not more than 2 mm). Sutures were done with polyglycolic acid using a criss-cross four-x-corner technique (Fig. 3).

### Removing the sutures


The sutures were removed two weeks later. Two weeks after suture removal, the patient was seen again for the removal of the membrane. This was done by gently picking at the membrane with cotton pliers and exerting pull on it—there is often no need for anaesthesia. The benefit of using this allograft cocktail is that the waiting period for re-entry was approximately four to six months versus six to nine had a xenograft been used. The quantity and the quality of the bone appeared to be much better with the use of this allograft cocktail.

At the time of re-entry, the patient's blood pressure was 113/69 with a heart rate of 64 (Figs. 4 & 5). Under local anaesthetic (Lidocaine 2 per cent HCl with epinephrine 1/50,000 x 2 cpl), a tissue punch access was done using a 3.8 tissue punch XiVE drill (DENTSPLY Friadent).

The pilot drill from the ANKYLOS implant system (DENTSPLY Friadent) was then used to drill 6 mm, just short of the sinus floor (Fig. 6). A series of XiVE osteotomes, from size 2.0 up to 3.4, were used to perform a sinus lift using the Summer's technique. The osteotomy was prepared to a depth of 11 mm (Fig. 7).

A Valsalva test was performed to ensure that the sinus had not been perforated. An ANKYLOS implant A11 (3.5 mm x 11 mm) was placed and primary stability was obtained. The density of the bone perceived as D-3 during the drilling stage, likely changed to D-2 with the use of the osteotomes. The implant-transfer mount was removed, as was the cover screw that came pre-mounted inside the implant, and a 1.5 mm sulcus former (healing abutment) was placed into the implant (Figs. 8 & 9).

This case clearly demonstrates one of the reasons that endodontists are becoming increasingly involved in implant dentistry. They are able to provide a comprehensive evaluation of the tooth in question, and they are able to present the patient with the best options based on clinical assessment.

_about the author	roots
	<p><b>Dr Jose M. Hoyo</b> graduated from the University of Puerto Rico School of Dentistry in 1984. He received his Certificate of Advanced Graduate Studies in Endodontics from Boston University's Henry M. Goldman School of Graduate Dentistry in 1994.</p> <p>He practices as a specialist in Endodontics and Implant dentistry in southern Massachusetts and can be contacted at <a href="mailto:drjhoyo@aol.com">drjhoyo@aol.com</a>.</p>



# DENTAL TRIBUNE STUDY CLUB C.E. SYMPOSIA AT IDEM, SINGAPORE

APRIL 16 - 18, 2010 TIMES ARE LISTED IN LOCAL SINGAPORE TIME, WHICH IS 12 HOURS AHEAD OF EST.



The Dental Tribune Study Club Symposia at IDEM offer an ambitious schedule of continuing education lectures in various dental disciplines. Each day will feature a selection of lectures led by experts in the field, providing an invaluable opportunity to learn from opinion leaders, while earning ADA CERP C.E. Credits. Find us directly on the exhibition floor at J30.

**THE SYMPOSIA SESSIONS ARE FREE FOR IDEM VISITORS. WALK-INS WELCOME. THE LECTURES WILL ALSO BE BROADCAST LIVE ONLINE, FOR THOSE WHO ARE NOT ABLE TO MAKE IT TO SINGAPORE. LIVE ONLINE ATTENDANCE IS ALSO FREE.**

## APRIL 16

**11:00 - 12:30 - AFFORDABLE SOFT TISSUE DIODE LASERS**  
with Dr. George Freedman and Dr. Fay Goldstep

**1:00 - 2:30 - DEATH OF A SALES MAN; BIRTH OF THE HELPING PROFESSIONAL**  
with Peter Barry

**3:00 - 4:30 - A MINIMALLY INVASIVE APPROACH TO PREDICTABLE DIRECT COSMETIC RESTORATIONS**  
with Dr. Shriju Joshi

## APRIL 17

**11:00 - 12:30 - TOOTH WEAR AND NEW TECHNOLOGY TO MANAGE DENTIN HYPERSENSITIVITY**  
with Dr. Fotinos Panagakos

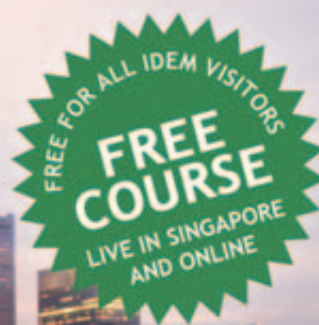**1:00 - 2:30 - LASERS, RESTORATIVES AND THE DENTAL MEDICAL CONNECTION - PART I**  
with Dr. George Freedman and Dr. Fay Goldstep

**3:00 - 4:30 - EXPLORING NEW FRONTIERS IN INDIRECT AESTHETIC RESTORATION**  
with Dr. Shriju Joshi

## APRIL 18

**11:00 - 12:30 - LASERS, RESTORATIVES AND THE DENTAL MEDICAL CONNECTION PART II**  
with Dr. George Freedman and Dr. Fay Goldstep

**1:00 - 2:30 - RISK OF CORONARY HEART DISEASE IN ASSOCIATION WITH PERIODONTITIS AND PERIIMPLANTITIS**  
with Dr. Hans-Dieter John



REGISTER ON [WWW.DTSTUDYCLUB.COM](http://WWW.DTSTUDYCLUB.COM)

Program is subject to change.



QUALIFY FOR ADA CERP C.E. CREDITS!  
Dental Tribune America LLC is a recognized ADA CERP provider.

# Managing maxillary molars

Author\_Dr Mark Dreyer, USA

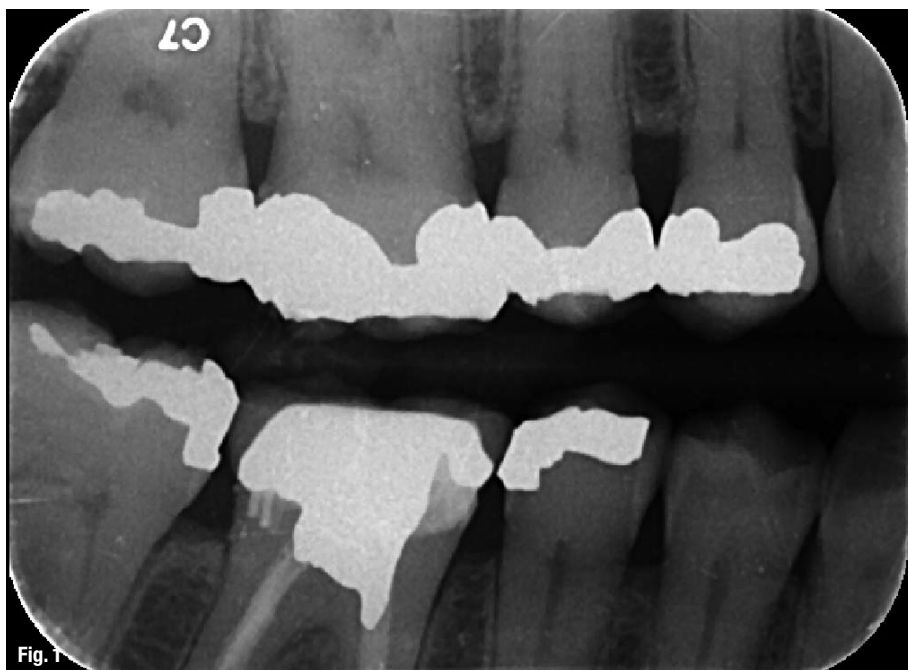


Fig. 1

**\_Maxillary first molars** are notable for their complex root-canal system morphology. The mesio-buccal (MB) roots are characterised by an irregular ovoid morphology, resulting in an isthmus or fin of pulpal tissue extending palatally to the principle MB canal. This case report presents steps taken to address this anatomy in order to maximise the disinfection and debridement of the root-canal system. Failure to address this anatomic complexity may lead to persistence or recurrence of endodontic disease.

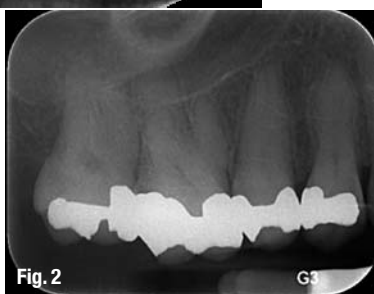

Fig. 2

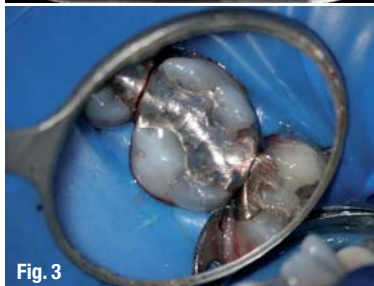
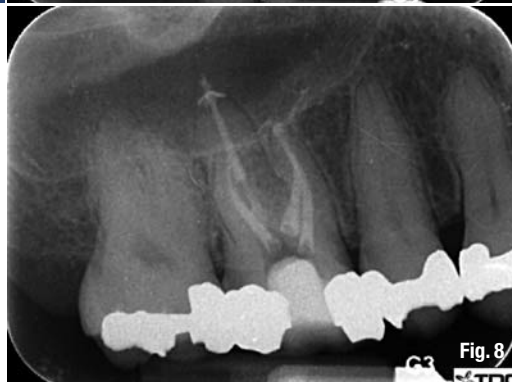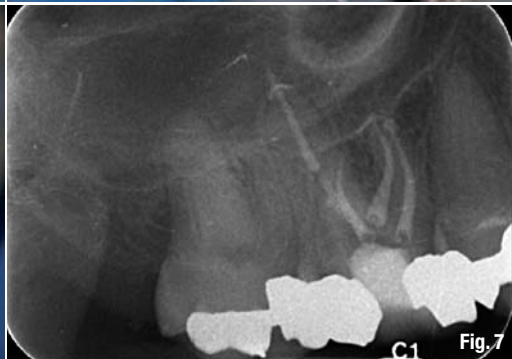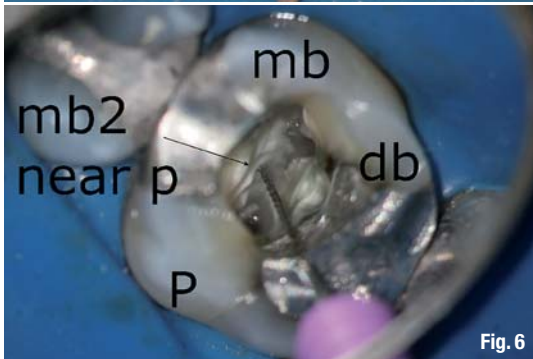
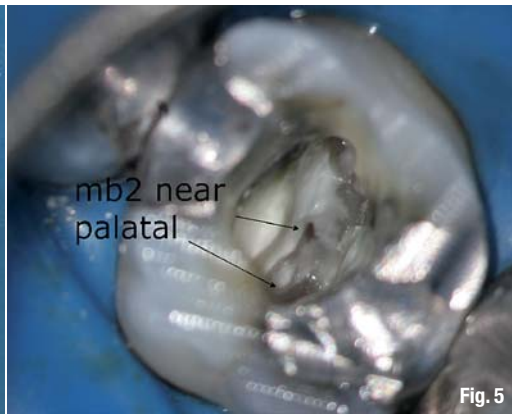


Fig. 3

## \_Endodontic evaluation

A 58-year-old female patient presented for endodontic evaluation and therapy in the upper left quadrant. Mild pain for several days was reported by the patient prior to the appointment. Medical history was non-contributory, and dental history was remarkable for multiple existing large amalgam restorations (Figs. 1–3). Clinical examination and diagnostic evaluation were performed for all posterior teeth on the right side, including cold testing, percussion, palpation, periodontal probing and bite challenge. Findings led to a pre-operative diagnosis of irreversible pulpitis in tooth #3 with normal peri-radicular tissues.

After anaesthesia and isolation with the rubber dam, entry was made into a calcified pulp chamber. Use of the dental operating microscope (OM) greatly enhances lighting and visibility, allowing for careful and deliberate clearing of reparative dentine, pulp stones and other potential impediments to canal orifices. It is important to stress that the files must not be taken into the canals prior to developing proper access form. In such cases, ledging and blockages can easily occur, needlessly compromising and complicating treatment. The palatal pulp tissue was calcified and extirpated *in toto* (Fig. 4).



**\_Ultrasonic tips**

Ultrasonic tips were used to plane the pulpal floor and increase visibility. These instruments are available from many manufacturers in a variety of sizes and shapes designed to address specific case needs. The orifice of the MB2 canal was located towards the palatal orifice in an unusual presentation (Figs. 5 & 6). This stresses the importance of continuing to examine the pulpal floor with the OM throughout the procedure, as irrigants and instrumentation constantly alter the presentation of subtle cues and clues to orifice location.

Once the orifice location had been determined, canal negotiation and instrumentation were completed. Warm vertical compaction of gutta-percha and ZOE sealer was used in this case, demonstrating the treated canal morphology (Figs. 7 & 8). The MB2 canal was addressed as a completely separate canal.

A study that examined more than 1,700 teeth, which included more than 1,000 first molars, demonstrated the presence of the MB2 canal in 93% of these teeth.<sup>1</sup> These findings are not surprising, given the morphology of the MB root in maxillary molars.

In order to better acquaint oneself with this anatomy, examine extracted teeth or consult Brown and Herbranson's *Tooth Atlas*, a rich source of 3-D imagery. The final radiographs demonstrate placement of an orifice barrier, subsequent to temporisation and referral back to the restorative dentist.

**\_A complex system**

This case report has demonstrated the complex root-canal system anatomy present in maxillary molars. Use of the OM throughout a carefully executed coronal and radicular access procedure maximises the ability to disinfect and debride these teeth.

Ultrasonic instrumentation allows for the judicious removal of dentine required to prevent iatrogenic mishaps and unnecessary weakening of the tooth. Meticulous root-canal therapy lays the foundation for successful long-term retention and restorative care for patients who present with endodontic disease.

**\_Reference**

1. Stropko J. Canal morphology of maxillary molars: Clinical observations of canal configurations. *JOE*, June 1999.

_contact	roots
<p><b>Dr Mark Dreyer</b> is a 1986 graduate of the University of Florida College of Dentistry. He practices as a general dentist limited to endodontics in Orlando and Kissimmee, Florida, and can be contacted at <a href="mailto:markdreyer@gmail.com">markdreyer@gmail.com</a>.</p>	

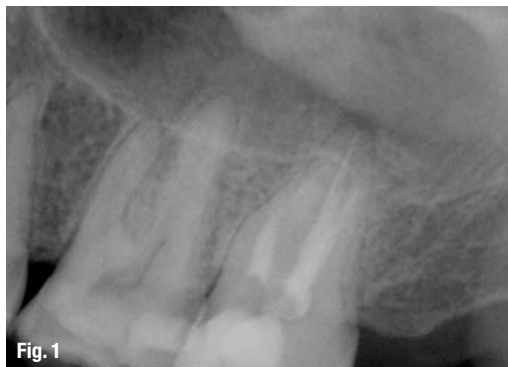# Comprehensive evaluation of previous root-canal therapy

Author\_ Dr Richard E. Mounce, USA

\_I recently received an e-mail from a general dentist with the image of tooth #15 (Fig. 1). The e-mail read: "I have an X-ray of our son's #15 root-canal treatment done five years ago by an endodontist. He has pain. I would like your opinion on the re-treatment?" There was no additional information.

The e-mail gives rise to several additional questions. It directly and indirectly addresses several important clinical and treatment-planning principles. These questions include:

Fig. 1\_Clinical case (tooth #15).



1. Which teeth with previous root-canal treatment can and should be re-treated or have endodontic surgery, and which should be extracted?
2. If re-treatment is the best option, how should this be accomplished?
3. If surgery is the immediate best option, is it also the best long-term option?
4. What clinical and radiographic features of the root canal pictured are needed to decide the answers to Questions 2 and 3 above?
5. What additional subjective and objective information is needed to address fully the question asked by the clinician in the e-mail?

This article was written to answer these questions in a clinically relevant manner, addressing the needed treatment-planning concerns and strategies for clinical management.

There is vital information that has a direct bearing on the management of this case that is not provided. For example, it would be helpful to know the reason this tooth was not restored after the root canal. The answer is unknown. Valid questions include whether the patient may have had significant pain after the procedure that led to the delay in coronal restoration. Is the patient non-compliant? Did the patient move and neglect the coronal restoration for that reason? Is there another possible reason for failure besides coronal leakage? Could another tooth be involved? These questions (and a host of others) have implications for clinical management. These include knowing whether the patient will follow up with the restorative recommendations of the general dentist if this tooth is re-treated. As an aside, if the patient is non-compliant, given all of the other considerations, extraction is indicated. It is wholly unproductive to retreat the tooth to later find out that the patient did not have the tooth restored a second time.

It would also be ideal to have more digital radiographs from different angles and ideally, a Cone-beam Computed Tomography scan of the tooth to determine whether there is a vertical root fracture and/or possibly a perforation. It is reckless to make judgments about clinical situations without a comprehensive understanding of the situation from multiple radiographic angles and without correlating the clinical examination with the symptoms. A correct diagnosis involves blending the findings with regard to percussion, palpation, mobility, probing and radiographic interpretation with the subjective examination in order

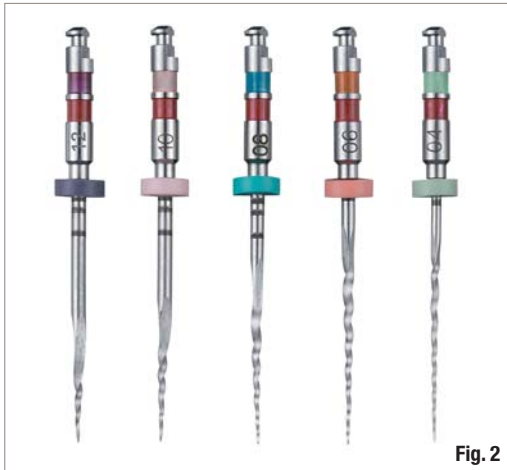


Fig. 2

Fig. 2\_Twisted Files (0.12/25, 0.10/25, 0.08/25, 0.06/25, 0.04/25; SybronEndo).

to determine a diagnosis. Such diligence can ensure that should treatment be undertaken, the patient would understand the procedure, alternatives and risks, and have his questions answered in a way that gives him a realistic expectation of probable success or failure. Based on this standard, it is not possible to judge the treatment as a failure and make decisions based on this one image without a clinical history and subjective and objective examination.

The above notwithstanding, the provided image yields significant information. The radiographic interpretation of this film demonstrates the following:

1. There is no coronal seal. In the endodontic literature, coronal leakage is highly correlated with failure of root-canal treatment. The tooth has not been crowned nor has the pulp chamber been restored. This radiographic appearance is diagnostic of coronal leakage. If accessed, the canals would almost certainly show overt evidence of such leakage, manifested as odour, discoloured gutta-percha, moisture and possible purulence, amongst other signs. Microbiologically, it is virtually certain that evidence of bacterial biofilm would be located alongside the existing gutta-percha in fins, cul de sacs and other inaccessible areas of the root-canal space.
2. There is a lack of continuity in the preparation and obturation in the taper from the crown to the apex of all three roots. The coronal halves of the disto-buccal (DB), mesio-buccal (MB) and palatal canals have greater taper than the apical halves do. It appears that the prepared shape in the coronal halves was made with Gates Glidden drills.

A more predictable canal shape could have been prepared using an instrument like the Twisted File (TF; SybronEndo). For this particular tooth, TF would have prepared the palatal canal in approximately two to three insertions to a 0.10/25 after the creation of a

glide path. The MB and DB canals (and MB2 if present) could also have been prepared to a 0.08/25 in three to four insertions after the creation of a glide path. While a comprehensive discussion of TF is beyond the scope of this article, using TF in this clinical case would have provided an optimal taper with relatively few insertions and preserved root structure. It would also have minimised the possibility of vertical root fracture and strip perforation. The degree of dentine removal at the distal aspect of the MB root and the mesial aspect of the DB root indicates that the remaining root wall is very thin. While it does not appear that a strip perforation has occurred, the radiographic information at hand is limited and it is not possible to determine whether there is a perforation. Such excessive dentine removal is correlated with long-term risk of vertical fracture.

3. There is a radiographic lesion at the apex of the palatal root. It is unknown from this one radiographic view whether additional lesions are present at the apex of the MB and the DB roots.
4. There are obturation voids in the palatal and MB root. The root-canal spaces have not been filled three-dimensionally. Such voids in obturation (aside from a lack of coronal seal) would give rise to questions about the quality of the cleaning and shaping.
5. Although not based on an empirical radiographic observation, the working length of the cleaning, shaping and obturation appears to be appropriate as does the master apical diameter, but this may have little to do with the clinical reality, ideal true working length and/or master apical diameter.

### Clinical considerations

Clinically, that the patient has pain—assuming that #15 is the offending tooth—would demand further treatment. Treatment options include extraction, root resection and root filling, or re-treatment. Part of the missing clinical history is a confirmation that #15 is the offending tooth, but it may not be. As mentioned, it is imperative that the patient have percussion, palpation, mobility and probing determined for teeth #14 and #15 (amongst other teeth) in order to reproduce the patient's symptoms. Clinically, this means that that if there is pain (for example, in reaction to chewing in the upper left), tooth #15 would be expected

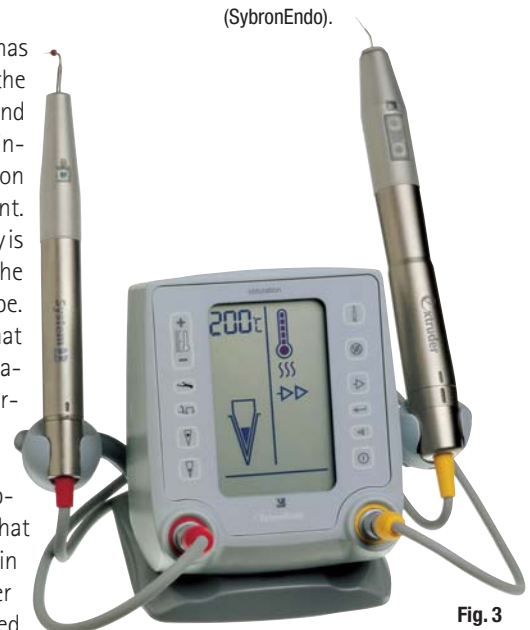
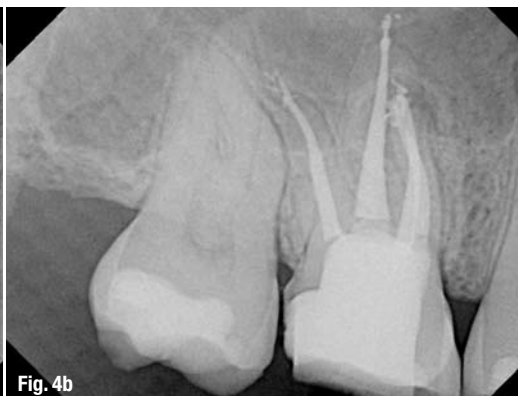
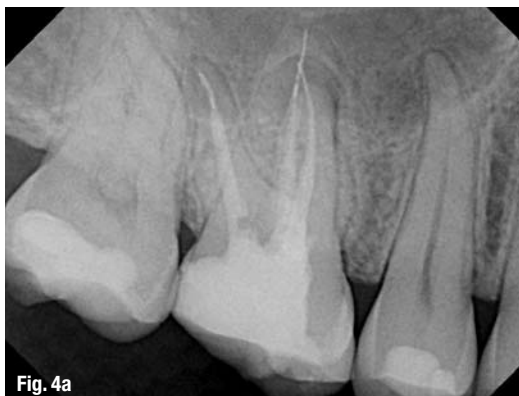

Fig. 3\_Elements Obturation Unit (SybronEndo).

Fig. 3

**Figs. 4a & b** Re-treatment of a failed root-canal treatment using the concepts and strategies discussed in the article.



(based on the radiographic appearance) to be sensitive to percussion and tooth #14 would be within normal limits. In essence, before a determination of a failed root canal on tooth #15 could be made, symptoms arising from tooth #14 would have to be ruled out. Testing tooth #14 with regard to percussion, palpation, mobility and probing, as well as performing a cold test could alert the clinician to any symptoms arising from tooth #14.

In essence, the clinician must reproduce the patient's chief complaint to assure him that the clinician has the correct tooth before making a diagnosis. Knowing whether the patient has pain in reaction to hot or cold would be a vital piece of information. Unfortunately, this information has not been given to us. If the patient's chief complaint is a sharp, lingering pain to hot or cold, it is most likely that a vital tooth is the offender and not pain from a failed root canal. Knowing also whether the pain was localised to tooth #15 would be valuable. Localised pain to tooth #15 that is reproduced by a positive percussion test would go a long way towards confirming the diagnosis.

### Clinical management

While limited to one radiographic view, given what appears to be coronal leakage as the primary source of failure, re-treatment would be the most practical, efficient and economical solution. The tooth appears to have adequate bone support. With a lack of coronal seal, assuming that a proper pre-operative radiographic and clinical examination did not suggest another diagnosis or treatment modality, re-treatment is favoured. Clinically, re-treatment would require that unnecessary dentine removal be avoided in order to minimise the risk of strip perforation. Aggressively removing the existing gutta-percha could easily cause strip perforation and/or remove excessive dentine, and as a result lead to long-term vertical root fracture. Using a heat source such as the Elements Obturation Unit (SybronEndo) as a first line of gutta-percha removal would minimise the risk of unnecessary dentine removal and provide

a passive means to eliminate the obturation before solvents and/or mechanical means are used. While not directly related to re-treatment, this case is a strong argument for the use of bonded obturation. Relative to gutta-percha, in vitro and in vivo bonded obturation has been shown to either decrease the movement of bacteria in a coronal to apical direction and/or reduce apical inflammation and infection that results from a loss of coronal seal. In this clinical case, it could be argued that if the obturation had been bonded that it could have provided some additional defence against the evident loss of coronal seal. RealSeal (SybronEndo) master cones and/or RealSeal 1 Bonded Obturator (SybronEndo) would both have been excellent choices to provide this bonded obturation clinically.

Finally, apical surgery is contra-indicated in this case for several reasons:

1. The crown-to-root ratio is unfavourable. Removing several millimetres of the apex of each root would make a short tooth (#15) even shorter and risk long-term vertical fracture.
2. The endodontic literature states that endodontic surgery is more successful in the short term than the long term. One of the reasons for this is due to coronal leakage, as evident here. Removing the apices and placing an apical filling might heal in the short term, but the long-term assault by coronal leakage would remain unabated, reducing the probabilities of clinical success.
3. The tooth should be re-treated first (if it is to be retained) and if necessary, apical surgery would be one option for the long term, amongst others.

A clinically relevant look at a failed root canal with regard to treatment planning and several clinical considerations has been presented. Emphasis has been placed on a comprehensive examination that combines both the subjective and objective findings in order to determine the correct clinical diagnosis and the most predictable treatment alternatives. I welcome your feedback.

<b>_contact</b>	<b>roots</b>
<p><b>Dr Richard E. Mounce</b>                  12503 S.E. Mill Plain Blvd.,                  Suite 215                  Vancouver, WA 98684                  USA</p> <p>Tel.: +1 360 891 9111                  E-mail: RichardMounce@                  MounceEndo.com                  www.mounceendo.com                  www.deadstuck.com</p>	





# 2010

## GREATER NEW YORK DENTAL MEETING

### FREE REGISTRATION\*

MEETING DATES:  
NOVEMBER 26 -  
DECEMBER 1

EXHIBIT DATES:  
NOVEMBER 28 -  
DECEMBER 1

86<sup>th</sup>  
Annual Session

The  
Largest  
Dental  
Convention/  
Exhibition/  
Congress  
in the  
United  
States



*\*Free registration  
before November 26*

Please send me more information about...

- Attending the Greater New York Dental Meeting
- Participating as a guest host and receiving free CE
- I speak \_\_\_\_\_ and am willing to assist international guests  
enter language



Name \_\_\_\_\_

Address \_\_\_\_\_

City, State, Zip/Country Code \_\_\_\_\_

Telephone \_\_\_\_\_ E-mail \_\_\_\_\_

Fax or mail this to:  
Greater New York Dental Meeting or  
visit our website: [www.gnydm.com](http://www.gnydm.com) for more information.



For More Information:  
Greater New York Dental Meeting™  
570 Seventh Avenue - Suite 800  
New York, NY 10018 USA  
Tel: +1 (212) 398-6922  
Fax: +1 (212) 398-6934  
E-mail: [info@gnydm.com](mailto:info@gnydm.com)  
Website: [www.gnydm.com](http://www.gnydm.com)

# The perceptions of a David in a land of Goliaths

Author\_Dr Barry Lee Musikant, USA

**When you are competing against giants** in a field that has become tremendously lucrative for these giants, you could easily feel out of your depth and should beat a hasty retreat, lest you encounter their true wrath. It is undeniable that we are exposed to the all-encompassing marketing power of these giants. We recognise their ability to dominate endodontic education in the schools (both undergraduate and graduate), commercial exhibits and lectures at all the major meetings, and the majority of the articles published in trade journals, all nicely capped off with an army of salespeople who make sophisticated pitches to dentists to buy one or another of the expensive rotary NiTi systems.

We, however, have one over-riding advantage: we work with the simple but powerful idea that we have a safer, far more cost-effective and efficient way to perform endodontics that is so strongly based in commonsense that for those who expose themselves to these alternative concepts the acceptance rate will be extremely high. We don't have to see many people to convince a small portion that they should adopt our approach, as the logic and application of our approach is readily accepted by a large percentage of the far fewer dentists we come in contact with.

We have no other choice than to think this way, and it has done very well for us these past several years. We created an endodontic system that meets our needs because the products that had been heavily promoted in the marketplace did not. It is an absolute essential that the instruments not break. For us, there is no compromise on this point. We don't want to know they won't break if we only use them once, use them lightly with several iterations of recapitulation, not use them in highly curved, dilacerated, bifurcated or merged canals.

We want to know that these instruments used in the recommended fashion will not break—period. This was not a requirement before the use of rotary NiTi because while breakage occasionally occurred, it was a rarity. Once I had used rotary NiTi, I appreciated the greater tapered shaping, but this advantage did not outweigh the trepidation I had when using them. We came up with a system that incorporated the shaping associated

with NiTi—but without breakage as a worrying side effect. I clearly remember presenting a lecture at a fairly large dental meeting to introduce our concepts. After the lecture, one of the dentists I was friendly with asked a younger dentist if he was interested in the system. The dentist responded that he wasn't interested in what I was talking about because it could not possibly be true. If it were, everyone would be using it.

The dentist's response was an insight into human nature. What I gathered from this remark is:

1. If it sounds like it is too good to be true, then it is most likely not true. Having come to this conclusion, there is little follow-up to see if by chance it actually is true. It is more comforting to dismiss it. This reaction is even more likely if a dentist's attention for new endodontic systems has already been captured by one of the expensive systems offered by the major manufacturers.

Against my single endodontic lecture, the dentists attending the lecture had seen and heard about rotary NiTi systems at other lectures, in articles and testimonials, all by well-known opinion leaders and the ever-present salespeople who convince clinicians to buy their latest system. It is difficult not to give credence to a flow of information that appears to be coming from diverse sources, but in reality is being centrally choreographed.

2. Once an expensive system has been paid for, it is only natural the dentists would wish to defend their decisions, that they made the right choices to make their efforts better and more productive. For many dentists, increased usage familiarises them with the rotary systems' limitations and they thus begin to take the precautions that are necessary for safe usage. It is an unusual phenomenon of rotary NiTi that the more a dentist learns how to use these instruments, the more selectively they are employed. Case selection becomes an important part of treatment.

Case selection has become increasingly necessary simply because there are many situations that can lead to instrument separation. I cannot think of another innovation in dentistry for which the more a dentist

learns how to use the instruments, the less they are used. Now depending upon your point of view, you could consider the selective use of these instruments as a study in sophistication, that only the best and most trained dentists will use them safely and this is somehow a plus. Learning to use a system that is defined by a narrow window of success may appear to be a study in professional growth. I consider it as just the opposite: the need to expend a great deal of energy in mastering a system that will produce results that are (at best) no better than those attained by simpler, far less expensive and far safer approaches.

I teach many dentists, and when a dentist comes to me to learn I always ask him or her what he or she is presently using. The other night I was teaching a dentist from Virginia who came to our NYC endodontic office.

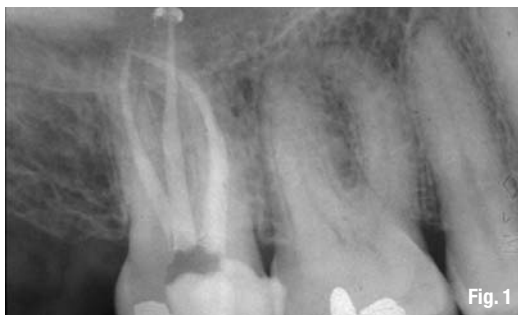

Fig. 1

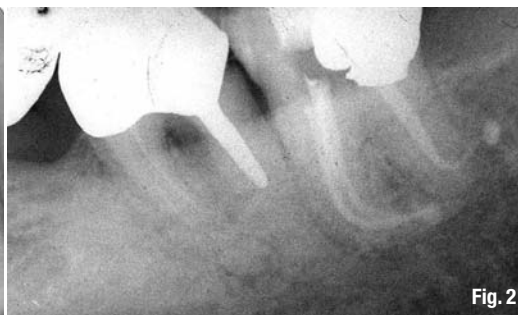

Fig. 2

**Fig. 1** Undistorted shaping even in long, curved roots.

**Fig. 2** Canals with curves greater than 90° can be shaped without concern for instrument separation.

She had been using the GT rotary NiTi system. I asked her if she is concerned about separation and she said she'd only broke one instrument in the past few years.

Despite that single incidence of breakage, she now takes extreme precautions not to separate an instrument. I then asked her how she handles curved canals and she said if they are mildly curved, she would use the GTs in a double sequence (otherwise known as recapitulation) after shaping the canals up to a #15 or 20 using K-files. If the canals are more than mildly curved, she would send the patient to the specialist.

As an endodontist, I have no problem in having patients sent to me, but from an academic point of view, I don't like systems whose vulnerabilities are so obvious they force a dentist to refer. It should not be the vulnerability of the system that determines a referral. A good reason to refer is the referring dentist not being able to negotiate calcified canals, or failing at finding them. Fear of instrument breakage should not be a reason.

Ironically, these referrals are made because of the fear of breakage of rotary NiTi. However, the endodontist has the same concerns, and he or she will use alternative means to shape the curved part of the canal at least up to the point at which the concern for instrument breakage has passed. Certainly, if the specialist

attains safer results using a more cautious approach, the dentist could also adopt this approach. We teach a far safer approach and those using it find the shaping of canals not only safer, but also so highly efficient that there is never any need to transition to rotary NiTi.

I have read a number of articles about the less distorted shaping that rotary NiTi produces, but these results are always in comparison to the use of K-files used with a twist-and-pull motion. When K-files are used with a balanced force technique, the results of non-distorted shaping favour the K-files. The results will favour stainless-steel instruments even more if the instrument is a relieved reamer rather than the traditional K-file and it is negotiated to the apex using a tight watch-winding motion or used in the 30-degree reciprocating handpiece. With the understanding that

both the tight manual watch-winding motion and the 30-degree reciprocating handpiece virtually eliminate all the torsional stress and cyclic fatigue that causes rotary NiTi (and for that matter, stainless steel) to break, we address the basic concerns of dentists.

Solving these basic problems gives dentists the ability to become more productive by turning out superior work on a greater variety of cases than they would have attempted in the past. Extending the dentists' skills by the invention of systems that produce compatibility between the metal and what is asked of it, is what progress is all about—despite being a David, it is worth battling the Goliaths. (I suppose you have to be a dentist to appreciate this last remark.)

For those who are interested in learning about the relieved reamers used in the reciprocating handpiece and learning how to fill canals three-dimensionally without the need for expensive thermoplastic approaches, call me at +1 212 582 8161 for a free two- to three-hour one-on-one workshop in our office. This hands-on experience will definitely open your eyes to a far safer, far less expensive and more efficient way to perform excellent endodontics. Information on additional courses can be found at [www.essentialseminars.org](http://www.essentialseminars.org).

Your wallet and your stomach lining will appreciate

_contact	roots
<p><b>Dr Barry Lee Musikant</b>          Essential Dental Systems, Inc.          89 Leuning Street          S. Hackensack, NJ 07606          USA          E-mail: <a href="mailto:info@edsdental.com">info@edsdental.com</a></p>	

# Determining working length, or how to locate the apical terminus (Part 2)

Authors\_Prof Vladimir Ivanovic & Dr Katarina Beljic-Ivanovic, Serbia

Figs. 1a & b\_Two identical EFLs sold under different brand names.



Fig. 1a



Fig. 1b

We would like to start the second part of our article with a quotation: "Adequate radiographs, knowledge of anatomy, and tactile sense and not apex locators will help to determine apical constriction."<sup>2</sup> We found this statement provocative enough to give electronic locators a chance.

As is well known, apex locators actually locate the foramen and not the root apex. As the foramen is usually not on the root apex, the term *electronic foramen locators* (EFLs) is more accurate. *Electronic root-canal length measuring devices* or similar descriptive terms are also incorrect, since the root-canal length does not appear on a display, particularly not in some standardised units.

EFLs are usually classified into different generations. The following classification of EFLs based on their functional properties is useful for dentists who, besides desiring the latest and best models, would like to know how a particular device works and why it is better than another model:

1. resistance-based devices (Generation I)
2. low frequency based devices (Generation II)
3. high frequency (capacitance) based devices (Generation II)
4. capacitance and resistance based devices (Generation IV)
5. voltage gradient devices
6. two frequency (impedance difference) based devices (Generation III)


7. two frequency (impedance ratio quotient) based devices (Generation III)
8. multi frequency based devices (Generation III).

The authors of this classification give perhaps the most appropriate comment: "The use of Generation X to describe and classify these devices is unhelpful, unscientific and perhaps best suited to marketing issues."<sup>5</sup> Marketing firms and manufacturers often cooperate to increase turnover, which is why, in some cases, you can find two identical devices that are sold under different brand names (Figs. 1a & b).

## In vitro studies

A remarkable number of studies have been conducted in the last 20 to 30 years on the use of EFLs. A majority were conducted *in vitro*, with all research conditions and variables controlled and standardised. We believe it would be useful to point out a number of variables that influence the accuracy of EFLs in *in vitro* studies.

Embedding media simulate periodontal ligaments through their physical and electrical properties and thus could affect the results if those media vary from the natural tissue. Electrical properties of intracanal solution, particularly with extremes of electroconductivity and ion concentration, can significantly influence the EFLs' accuracy. The discrepancies vary amongst the different EFL models.



**Figs. 2a & b\_** The difference between the real values and those shown on the Dentaport ZX (a) and ProPex I (b) is approximately 300 µm.

File size with respect to the diameter of the apical constriction and foramen can also affect precision. Since the measurements are repeated a number of times on the same tooth, it is wise to use smooth canal instruments (for example, small size finger spreader for lateral condensation) that cause less damage to the fine apical structures than endodontic files.

The EFL model used can also affect the results. The majority of studies conducted on this have confirmed that with newer and improved models, higher precision and more consistent results can be obtained.


Pre-flaring of the coronal third of the root canal improves determination of the apical diameter. The first file that binds at the apical constriction, stabilises and increases the precision of the readings in any type of EFL. The range of tolerance, which varies from approximately 0.1 to 0.5 mm, and sometimes 2 mm, significantly affects the EFLs' accuracy; the wider the range is, the higher the percentage of EFL precision is.

From a number of articles, we concluded that the method and the apical landmark selected to determine the real or actual length of the tooth also significantly influences the results. The apical end-points selected varied greatly, from the anatomical apex to the anatomical foramen, and in some cases to the cemento-dental junction. Additionally, only vague explanations for the method and obtained results were offered at times, making the results incomparable.

It is generally believed that *in vitro* studies offer valuable and useful facts and results for the clinical practice. However, most of the currently available

studies are on single-rooted or single-canal teeth. Many of these studies also have too many variables, resulting in confusion rather than leaving the reader with clear and appropriate conclusions.

Owing to the apparent lack of precise and reliable information, Prof Joshua Moshonov (Hadassah University, Jerusalem) and a team of researchers from MedicNRG, which we accompanied at a later stage, tested several of the newer EFL models, namely ProPex I (DENTSPLY Maillefer), Dentaport ZX (J. Morita), Raypex 5 (VDW) and ApexPointer+ (MICRO-MEGA).



**Fig. 3\_** A difference of 200 µm between the real value and that shown on the ApexPointer+.




Fig. 4

**Fig. 4**\_Tolerable difference of 300 µm between the real value and that shown on the Raypex 5.

One of the first questions the study aimed to address was: are differences between real values of distances from the file tip to the referent point and those shown on a EFL display clinically significant? Using a high-tech electronic micrometer, with measuring precision at 0.1 µm, the distances from the file tip to the reference point (anatomical foramen) were measured. We tested and gained almost identical results for all four EFLs.

The findings of this study can be summarised thus:

- a) Figures or marks on the display of the EFL scales do not represent strict values in mm.
- b) The difference between the real values and those on the display is smaller than 0.5 mm (Figs. 2a & b), and

thus may be considered clinically insignificant, owing to our manual inability to distinguish such short movements of the canal instrument.

- c) We may tolerate small differences between real values on a high-tech measuring instrument and those on the display of the EFLs because they are not even detectable by the hand of a practitioner, since they are approximately 300 µm and smaller and are therefore acceptable in clinical work (Figs. 3 & 4).

While taking measurements, we sometimes noticed a slight bouncing on the scale of the EFL, even when the file tip was not moving in the root canal. This was due to a slight mixing of electrolytes and changes in ion concentrations between the embedded media outside and solution inside the root canal at the level of the apical foramen. Therefore, in clinical use waiting for three to four seconds for a stable reading is recommended.

Following this study, Prof Moshonov wished to address a more detailed and profound question: to what extent do the readings on a display correspond to the real values on a high-tech measuring instrument? In addressing this question, he examined two models of mini-EFLs: the MedicNRG-XFR and the MedicNRG-Blue.

The MedicNRG-XFR displayed extra fine resolution with very small values of distortion from the real measurements—only 12 to 38 µm in instances in which the EFL indicated 0.25 mm from the mark 'apex' (Fig. 5a) and 22 to 65 µm at the 0.5 mm mark from the 'apex' on a EFL display (Fig. 5b).


The MedicNRG-Blue enables users to connect to their PC via a Bluetooth connection. Prof Moshonov compared the value on the EFL itself with a scheme on the screen of a PC. He found that there was no

**Figs. 5a & b**\_The MedicNRG-XFR displays extra fine resolution and very small values of distortion from the real measurements: from 12 µm (a) to 65 µm (b).



Fig. 5a

Fig. 5b



**Figs. 6a & b\_** The MedicNRG-Blue displays extremely small differences between real values and those shown on the display: from only 1 µm (a) to 198 µm (b).

difference between real values and the PC screen values when the EFL indicated 'past apex' and 'apex' (Fig. 6a). When the MedicNRG-Blue indicated 0.3 mm to 1.4 mm from the apex (Fig. 6b), the differences ranged from 110 to 158 µm, respectively. These figures coincide with the values of the XFR model, revealing that both EFLs had high precision and a very high level of resolution. Differences are far below the acceptable 0.5 mm and therefore have no relevant influence on clinical work. Prof Moshonov's tests also confirmed that the closer the measuring file tip is to the apex, the more precise the readings are and the higher the resolution of the EFL is (Fig. 6a). When the tip of the measuring file is a bit farther from the apical foramen, the readings coincide slightly less with the real distances (Fig. 6b).

While testing the Raypex 5, we asked ourselves a question that every practitioner might ask: can we trust the values indicated on the EFL display and can we rely on the manufacturer's instructions? The measuring device clearly showed values of 0.5 mm and 0.8 mm (Fig. 7), proving that the EFL very precisely indicates the position of the file tip with respect to anatomical details, since the distance from the foramen to constriction is 0.5 to 1.0 mm. We recommend that practitioners follow what the display indicates as well as the manufacturer's instructions, but reconsider unusual or strange readings.


The last test conducted in our laboratories aimed to determine whether different EFLs display the same values for the same distance in the same root canal. The tip of the finger spreader # 15 was introduced into the canal until it reached the plastic plate barrier firmly placed at the plane of the anatomical foramen (Fig. 8). The tooth was normally mounted and each of the EFLs immediately indicated that the spreader tip was beyond the foramen. Presumably, this was due to the gelatine embedding medium inside the external

portion of the cemental cone of the apical foramen; thus all EFLs indicated the same: contact with artificial periodontal ligament.

For all EFLs, the measuring device was adjusted to 0.001 mm (0.1 µm) at this stage. With the micrometer screw, the canal instrument was retreated until the display of the EFL indicated that the tip was no longer beyond but exactly at the foramen: apex reading (ApexPointer+, MedicNRG-XFR, Dentaport ZX), 0.0 reading (ProPex I) and red square segment (Raypex 5; specific marks on each EFL). At this stage, we had already received a definite answer to our question: the different EFLs do not indicate the same values for the same distance in the same root canal.

After recording this value, the canal instrument was withdrawn further with the micrometer screw until the mark on the display of each EFL indicated that the tip had been moved and switched from the apical foramen to the first next mark/segment

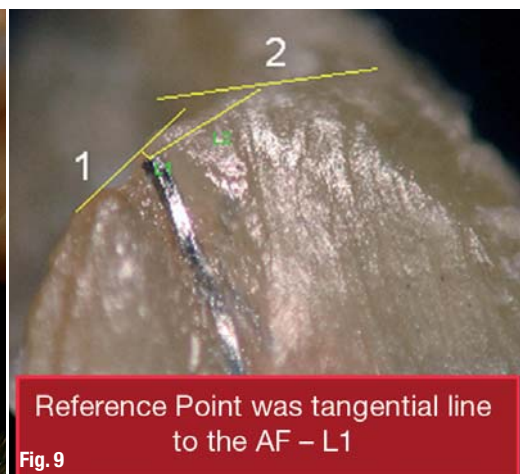
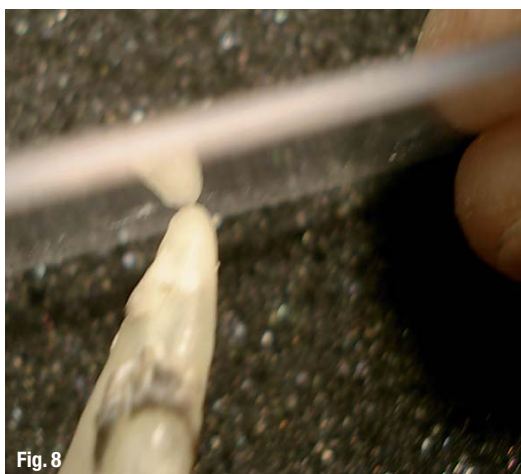**Fig. 7\_** The Raypex 5 very accurately indicated the position of the file tip, which is approximately 0.5 to 0.8 mm between the anatomical foramen and apical constriction.



**Fig. 7**

**Fig. 8**\_The tip of the finger spreader #15 was introduced into the canal until it reached the plastic plate barrier firmly placed at the plane of the anatomical foramen.

**Fig. 9**\_Microscopic image of the distance from the file tip to the line tangent to the anatomical foramen (L1).

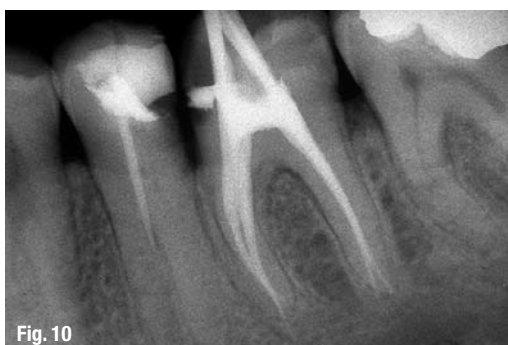

indicated before the foramen. The recorded values are reviewed in Table 1.

The first group of values indicates the moment at which the position of the tip of the finger spreader switched from beyond the apex to the mark apex, 0.0 or red segment (all indicating anatomical or major foramen). These variations are likely due to fine variations in the position of the tip of the finger spreader, since positioning of the plastic plate could not have been identical in each case. The second group of values indicates the moment at which the reading switched from the mark indicating the anatomical foramen to the first mark coronal to this one: 0.1 (ProPex I and ApexPointer+), 0.25 (MedicNRG-XFR), lowest green line (Dentaport ZX) and lowest yellow square (Raypex 5). The red figures in the last column indicate the EFLs' precision in measuring the same distance, in other words, the level of resolution. The blue figures are from previous tests. Together they present the EFLs' ability to make fine distinctions.

Therefore, the answer to our question is that different EFLs show different values with different levels of resolution for the same distance in the same root canal. However, and fortunately, all deviations are far below the range of clinically acceptable tolerance of approximately 0.5mm (about 0.3mm and less), and therefore do not significantly influence the precision and accuracy of EFLs in locating anatomical foramen.

**Fig. 10**\_Post-op radiograph of tooth #46.



### In vivo studies

*In vivo* studies are generally conducted on extracted teeth, offering much more realistic, relevant, reliable, and thus useful data for practitioners. There are several factors that can affect the readings and, consequently, the results achieved in clinical conditions. These factors are:

1. status of pulp tissue (vital, necrotic, infected, etc.);
2. pre-flaring of the coronal and/or middle third of the canal;
3. status of the diameter of the minor and major foramen (preserved in its natural dimension or deviated by pathological resorption or instrumentation);
4. size of measuring file;
5. file material;
6. canal content (empty and dry, or inflamed pulp tissue, pus, necrotic tissue and bacterial detritus, etc.);
7. electroconductive properties and ion concentration of irrigating solution used; and
8. type of tooth (anterior, posterior, single, multi-rooted, etc.).

A number of studies have confirmed that some factors facilitate more consistent, straight forward, faster and precise readings. These beneficial factors are:

1. pre-flaring of the coronal and middle portion of the root canal;
2. removing of the pulp tissue and debris from the canal;
3. foramen not enlarged by instrumentation or peri-apical pathosis;
4. size of the measuring file coincides with the lumen of the apical portion of the canal; and
5. application of moderately conductive irrigating solutions such as 2% NaOCl, chlorhexidine, or EDTA solution.

The type of the tooth and file material have been proven not to affect the readings and accuracy of EFLs.



Contradictory and controversial results and statements about certain factors that influence the accuracy of EFLs when tested in vivo (both with statistical and/or clinical significance) still exist, particularly with regard to vital and necrotic cases. Reports vary from higher precision in teeth with vital pulp to higher precision in cases with necrotic/infected pulp or even no difference at all. Whether EFLs demonstrate better results in moist or dry canals is yet another controversial issue. Here, the type of EFL used is most often the determining factor. The same can be concluded for the type of irrigant used, considering its conductivity and ion concentration.

The following factors adversely affect the accuracy of all tested EFLs:

1. presence of peri-apical lesions associated with periodontal ligament and bone destruction that have destroyed both the anatomical foramen and apical constriction;
2. wide-open apical foramen in immature teeth; and
3. extremes in conductive properties of the irrigating solution in the canal, such as saline versus distilled water.

According to the literature, the precision of EFLs tested in clinical conditions varies between 15 and 100%. Evidently, additional factors or variables that influence clinical results must exist. In general, measurements of an extracted tooth with a revealed apical segment of the root canal taken using a microscope and software programmes are more precise compared to measurements taken using radiographs of a tooth under clinical conditions. Furthermore, the range of tolerance or targeted interval from approximately 0.5 to 1.0 and 1.5mm significantly affects accuracy: the higher the value of tolerance is, the higher the percentage of precision is.

The display mark selected to be the apical terminus for measuring the electronic working length may influence clinical results of the accuracy of EFLs. In reality, each operator will select his/her preferred display mark and therefore select his/her personal apical terminus.

The anatomical landmark selected to measure the distance from the file tip also varies and can significantly affect the results. The cemento-dentinal junction and the apical constriction are not reliable reference points. However, the apical anatomical foramen and, even more so, the anatomical apex are well defined and easy to distinguish, even without magnification.

The type of EFL used also influences the results. Generally, the more sophisticated and newer the

model is, the more accurate the measurements will be. Manufacturers constantly strive to improve their models in order to make our work easier and more precise. However, all instruments are handled and results interpreted by practitioners, which leaves room for random and unforeseeable errors.

In the early 1980s, we conducted a number of studies at the Department of Restorative Odontology and Endodontics in the School of Dentistry at Belgrade University using two EFLs—DIAPEX (DiaDent) and Odontometer (Goof). The results achieved with Odontometer demonstrated 77% precision in locating the apical constriction, checked by the same radiographic criteria as explained before. Significantly less overestimation was found than with the tactile sense and the radiographic method. Similar results were achieved with the Foramatron (Parkell, Inc.) several years later, with measurement deviations of up to -1.0mm.

Traditionally, the accuracy of EFLs has been corroborated with radiographs, but any correction of the file position according to radiographic projections would invariably lead to overextension. Comparing




electronic foramen locator	from – to (in µm)	range (in µm; resolution/subtlety)
Raypex 5	0 – 508 – <u>701</u> 	193 (300)
ProPex I	0 – 354 – <u>705</u> 	351 (340)
MedicNRG-XFR	0 – 305 – <u>380</u> -0.0 Apex 0.25	75 (48)
Dentaport ZX	0 – 367 – <u>674</u> Apex 	307 (350)
ApexPointer+	0 – 143 – <u>312</u> AP <sub>EX</sub> 0.0 0.1	169 (202)

Table 1

electronic foramen locator	mean (+/- SD)	beyond AF
MedicNRG-XFR	0.148 (0.079)	0
Dentaport ZX	165 (0.222)	2; +0.076 +0.131
ProPex I	0.169 (0.149)	9; +0.226 (0.102)
Raypex 5	0.187 (0.142)	3; +0.119 +0.208 +0.075
ApexPointer+	0.189 (0.168)	1; +0.129

Table 2

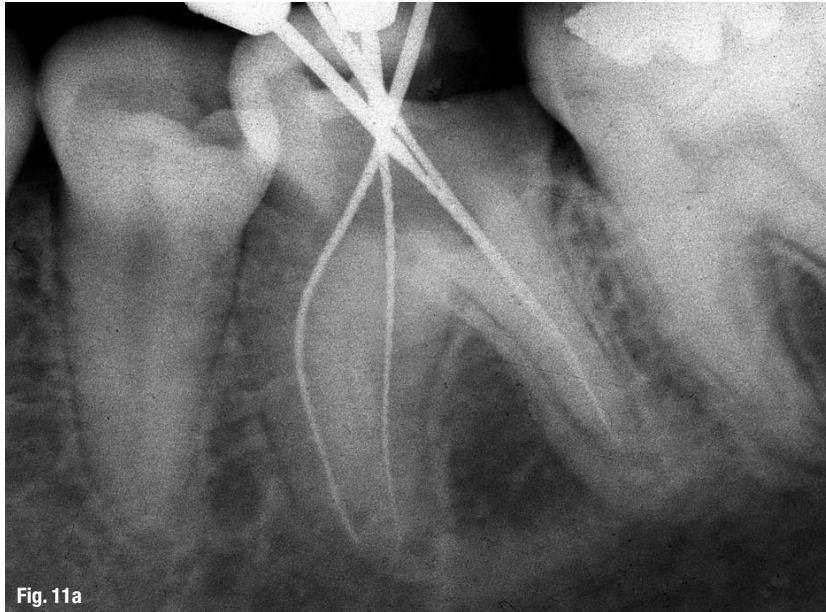


Fig. 11a

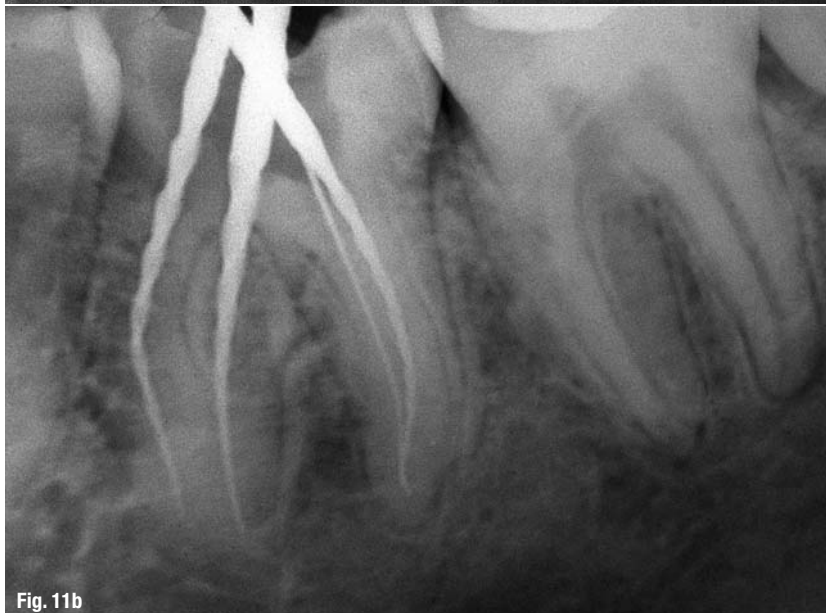

Fig. 11b

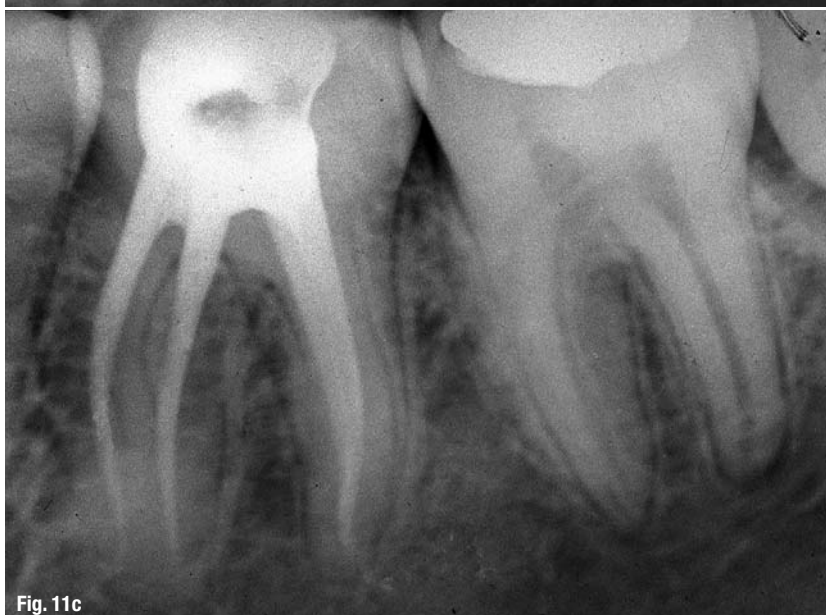

Fig. 11c

the precision of EFLs with radiographs will not lead to accurate results, as the radiographic method is unreliable in determining both the apical constriction and apical foramen.

In 2006, our team conducted the *Belgrade in vivo studies*—which later became an *in vitro* study—in molars and multi-rooted premolars using a strict protocol that was reviewed by Dr Julian Webber, Prof Moshonov and Prof Paul Dummer. The above-mentioned EFL models were tested once again.

We selected a mark on a EFL to be the apical foramen (0.0, apex or red segment). The reference point for measuring the distance from the file tip under the stereomicroscope was the point of crossing the tangential line to the anatomical foramen and extended line of the canal instrument (L1; Fig.9). The results are presented in Table 2.

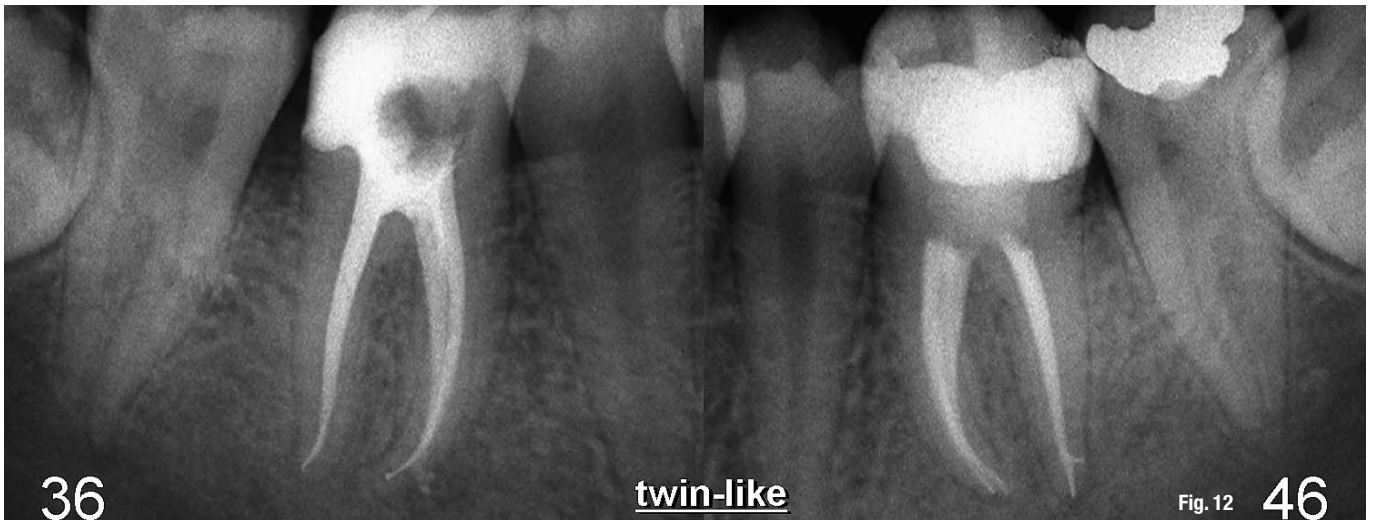None of the mean distances exceeded 0.2 mm. Therefore, it may be concluded that the new generation EFLs were precise in locating the apical foramen within values far below the recognised clinical tolerance of approximately 0.5 mm.

Standard deviations for Dentaport ZX, ApexPointer+, ProPex I and Raypex 5 indicated high dispersion of values (standard deviation above 30%). Standard deviation for the NRG XFR was very low (far below 30%), indicating consistent measurements and a high level of resolution.

Furthermore, NRG XFR never gave overestimations compared to the other EFLs. ApexPointer+, Dentaport ZX and Raypex 5 showed only 1, 2 and 3 overestimations, respectively. ProPex I showed more overestimations than the other four devices (about 1/3 of all measurements).

However, those values were only 0.2 mm and less and thus clinically acceptable. It could be recommended, that after establishing the location of the apical foramen as the most reliable landmark with EFLs, the instrument be withdrawn to either the shorter reading or the mark that specifically indicates the physiological foramen or the apical constriction according to the manufacturer's instructions. Also, practitioners may retreat just 0.5 mm, or even 1.0 mm, short of the apical foramen mark. In short: "When the apical foramen is located, the position of the apical constriction—if it exists—can be estimated."<sup>3</sup>

From our findings, we recommend that the practitioner, above everything, always have a preoperative radiograph handy and stay within the confines of the root canal. Practitioners should trust in EFL but not blindly.



**\_Case studies**

In conclusion, we would like to present three clinical cases. The case shown in Figure 10 presented with necrotic pulp with no peri-apical pathosis and was treated based on the information gained from a single diagnostic film. Working length was determined only by using an EFL. The post-operative radiograph with all four canals obturated demonstrates the successful treatment outcome.

The case presented in Figures 11a to c was completed in accordance with regular endodontic procedure. The result brought us to the following conclusion: the combination and comparison of several methods to locate the apical terminus and determine working

length always gives the practitioner more confidence, accuracy and success than using only one or none.

Predictable, reliable and successful endodontics were performed in teeth #36 and 46 of the same patient (Fig. 12). We are pleased to present this case here but are aware that many practitioners devoted to endodontics could achieve similar, if not better, results. Our goal is to motivate others to achieve even better results and to seek to give patients the best of treatment.

*Editorial note: Figure 3b was erroneously included in Part I of this article, published in roots 4/2009. The corrected PDF version of the article, as well as a complete list of references, can be obtained from the publisher.*

**Figs. 11a-c\_** Tooth #46 with necrotic pulp. Radiograph with ISO standard files (a); Radiograph with ProTaper files after EFL measurement (b); Obturated canals after final working length with paper points (c).

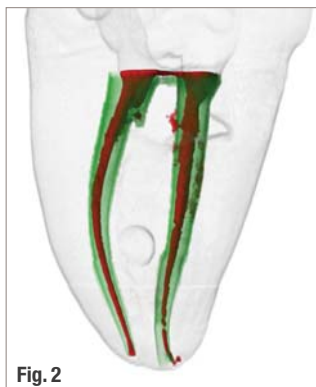
**Fig. 12\_** Endodontic treatment in two different first mandibular molars of the same patient.

<b>_about the author</b>		<b>roots</b>
	<p><b>Prof Vladimir Ivanovic</b> graduated from the Faculty of Dentistry at the University of Belgrade in 1976. He obtained a M.Dent.Sc and Ph.D. with specialisation in Oral and Dental Pathology and Endodontology. He was appointed Professor in Restorative Odontology and Endodontics in 1998 at the Faculty of Dental Medicine and served as a Vice-Dean for postgraduate and undergraduate studies. He has also chaired the School Board for Dental Pathology.</p> <p>Prof Ivanovic conducts research at the University of Belgrade and Edinburgh Dental Institute. His main interests are maintaining vital pulp, resin-based composites and adhesive systems, and endodontology. He has attended numerous international endodontic seminars and courses to further his knowledge and skills. He has delivered over 100 lectures both nationally and internationally, published over sixty articles in national and international journals, and chapters in four dental textbooks.</p> <p>He is founder and President of the Serbian Endodontic Society and has been a member of the ESE since 1989. He is also country representative for the ESE General Assembly, member of the International Association for Dental Research/Continental European Division and school representative for the Association for Dental Education in Europe. He has organised over a dozen endodontic meetings in Belgrade with internationally recognised speakers. Prof Ivanovic can be contacted at <a href="mailto:vladaivanovic@hotmail.com">vladaivanovic@hotmail.com</a>.</p>	

# File selection: Why geometry matters most

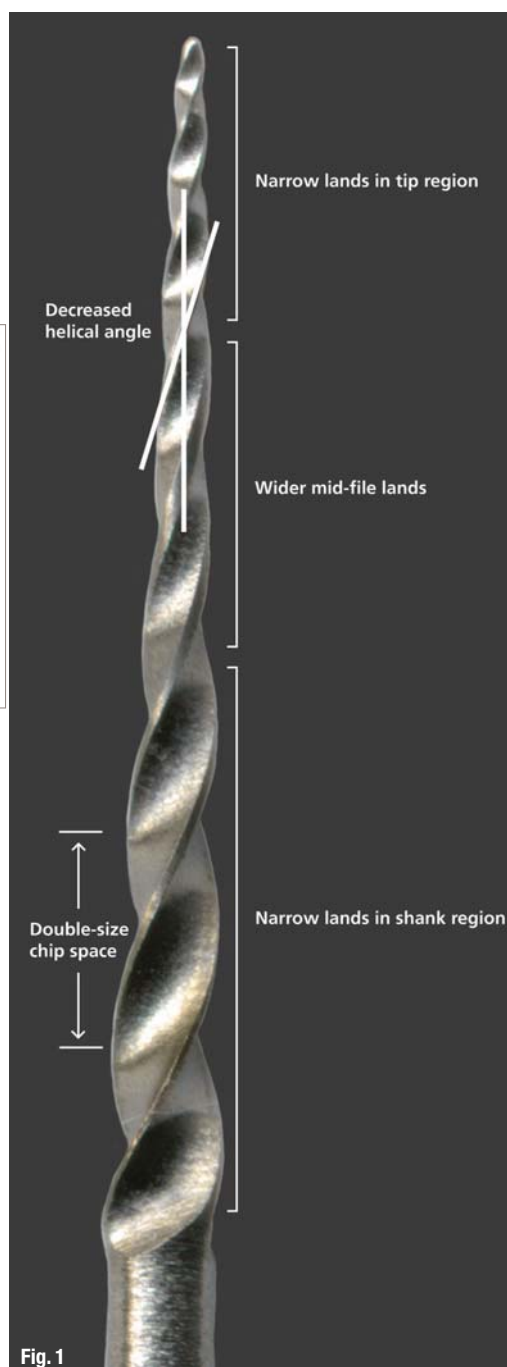
Author\_ Dr L. Stephen Buchanan, USA

**Fig. 1** \_GT Series X File. Note the maximum shank diameter at 1 mm, the radiused tip, the consistent, wider blade angle and the variable-width lands. At the tip and shank ends, the land widths are half the size of the lands in the middle region of the flutes, allowing rapid cutting without transportation.



**Fig. 2** \_Micro-CT reconstruction of curved canals shaped in a mesial root of a mandibular molar, comparing outcomes in the apical third with rotary files of radiused vs. aggressive tip geometry. Note the canal on the right showing severe transportation (aggressive tip) and the canal on the right following the original canal path as the canal terminates (GTX-radiused tip).

**Figs. 3 & 4** \_Maxillary and mandibular molar shaped using 1–3 GTX files in each canal. Notice the fidelity to the original canal path.



\_Shortly after the excitement of the rotary file revolution wore off, the next frontier in shaping technology became the search for faster cutting efficiency. This is logically similar to our continuing search for increasingly faster computers.

However, experienced clinicians started seeing overfills from transportation, shortened canals, apical ripped canal termini, over-shaped coronal regions and cyclic fatigue failures that hadn't occurred with their safer, slower files. The first-order question in file selection became: safe or fast? Landed-blade instruments with radiused-tip geometry were much safer, in terms of avoidance of transportation, but non-landed blades with aggressive cutting tips were faster cutting.

The advent of GTX Files with M-Wire has eliminated the difficult decision between safety and speed. They are the first rotary shaping instruments that deliver speed of cutting with safety from transportation and breakage (Fig. 1).

M-Wire, a new rhombohedral-phase NiTi metal used in GTX Files, has radically improved the files' resistance to cyclic fatigue. While R-phase (the sweet spot between austenite-phase and martensite-phase NiTi) will become the new industry standard for addressing cyclic fatigue, it will never solve the problem of dangerous file geometries.

The radial lands on GTX Files have been optimised by varying the width of these lands along the length of the file. This geometrical change vastly improves cutting efficiency without derangement of the canal path, a claim that no file set without lands can make (Fig. 2). Furthermore, the decreased flute angle has significantly increased GTX File's flexibility compared with other landed instruments, simultaneously doubling the chip space between the flutes for a longer cutting time before clogging.

Another important design feature of GTX Files is their limited maximum flute diameter. Keeping the

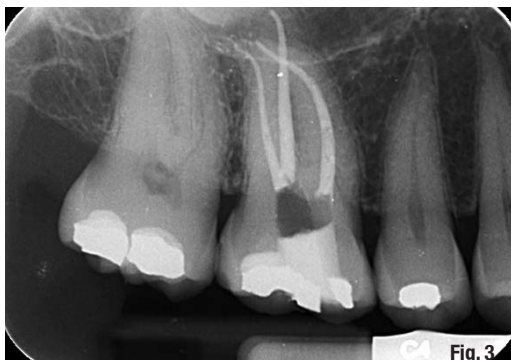


Fig. 3

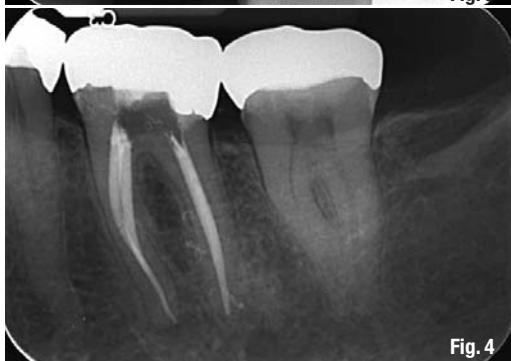

Fig. 4

cutting flute diameters limited to 1mm controls the amount of coronal enlargement during the shaping procedure, which is critical to the maintenance of the structural integrity of roots and to the avoidance of strip perforation.

All of these innovations in design geometry have resulted in a file set that typically cuts the ideal shape in most canals with one to three instruments and in as little time as 30 to 45 seconds (Figs. 3 & 4). That's why geometry matters.

_about the author	<b>roots</b>
 <p><b>Dr. L. Stephen Buchanan</b> is a Diplomate of the American Board of Endodontics and a Fellow of both the International College of Dentists and American College of Dentists. Clinicians interested in his DVD series, <i>The Art of Endodontics</i>, and his hands-on laboratory workshops in Santa Barbara, USA, can call +1 800 528 1590 (US and Canada) or +1 805 899 4529 (for international calls).</p> <p>For more information related to this article and for GTX updates and answers to frequently asked questions, please visit <a href="http://www.endobuchanan.com">www.endobuchanan.com</a>. Free CE online courses are also available on the GTX System and other topics.</p>	<p><b>Dr. L. Stephen Buchanan</b> is a Diplomate of the American Board of Endodontics and a Fellow of both the International College of Dentists and American College of Dentists. Clinicians interested in his DVD series, <i>The Art of Endodontics</i>, and his hands-on laboratory workshops in Santa Barbara, USA, can call +1 800 528 1590 (US and Canada) or +1 805 899 4529 (for international calls).</p>

## Finally, an assistant that gives you the benefits.



It will make your practice more efficient.



The **Endoring® II** organizer enables the clinician to directly place, store, measure and clean endodontic hand and rotary instruments within the operating field. It reduces the risk of cross-contamination and minimizes the passing of sharps between dentist and staff. Using the Endoring II organizer helps make endodontic procedures safer, faster and reduces patient chair time. **Endoring II, hand-held endodontic assistant**, REF: ERK2-s (Premium Kit), ER2SK-s (Starter Kit), ER2-s (with metal ruler).

**FEATURES & BENEFITS**

- Endo Docking Station™**  
Ideal for use with microscopes
- Laser-Etched Metal Ruler**  
Precise 1/2mm markings on high-contrast detachable ruler
- Right/Left-Handed 30mm Scale**  
Rapid calibration of instruments, paper points and gutta percha  
and much more...



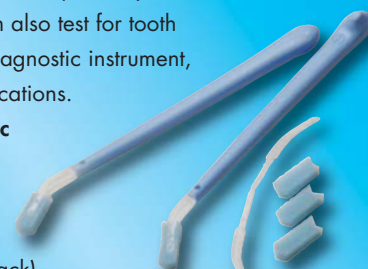Manufactured by Jordco, Inc. USA  
[www.jordco.com](http://www.jordco.com) • TEL 800-752-2812 • FAX 503-531-3757

**QUALITY DENTAL PRODUCTS MANUFACTURED IN THE U.S.A.**

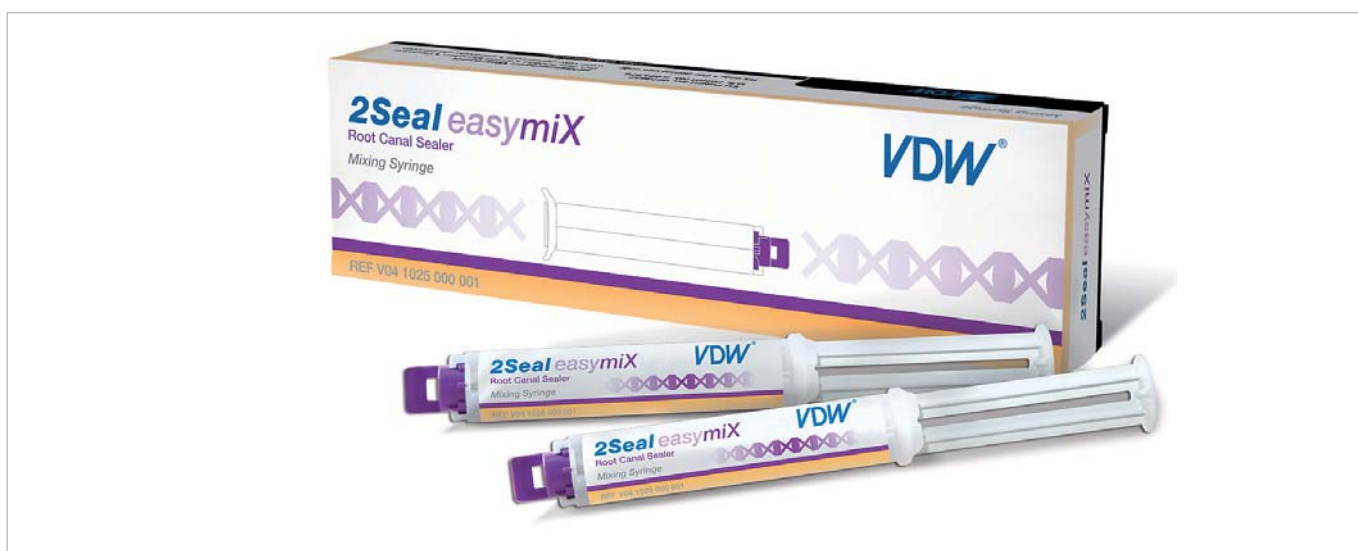To order, please contact your dental supply dealer.  
To find a dealer visit [www.jordco.com](http://www.jordco.com) or call **800-752-2812**

**You're getting colder.** Introducing the **e-Dx™** endodontic diagnostic instrument. The e-Dx instrument can cold test multiple teeth in a precisely controlled manner and can also test for tooth fracture. One diagnostic instrument, two useful applications.

**e-Dx, endodontic diagnostic instrument**,  
REF: EDX-s (kit); EDXRP-s (refill pack).



# Ready-to-use root-canal sealer: 2Seal easymiX



2Seal is a tried and tested epoxy-amine-based root-canal sealer. It has been available for many years in a standard two-tube pack and is now available as 2Seal easymiX in a convenient double-chamber mixing syringe with exchangeable, flexible intra-oral tips. 2Seal easymiX always mixes to an ideal ratio, which can be applied directly into the root canal— with no mess or waste.

It's a classic product made more convenient! 2Seal has excellent, proven properties. It is bio-compatible and characterised by optimal viscosity, as well as ideal radiopacity. It is ideal for use with both cold and warm obturation techniques. The new easymiX syringe significantly improves handling and the precise mixing of both components. This is a clear advantage in daily practice.


2Seal fulfils all criteria cited in the *Quality Guidelines for Endodontic Treatment* of the European Society of Endodontology. Furthermore, epoxy-resin sealers have

been examined in more than 90 studies and proven reliable in clinical application.

2Seal easymiX is available in a starter kit with 1 double-chamber syringe, 20 mixing tips with intra-oral tips, 1 mixing block and 1 convenient organiser. The mixing syringes are available in a double pack. Mixing tips with intra-oral tips come in refills of 40 pieces.

_contact	roots
<p><b>VDW GmbH</b>                      Bayerwaldstr. 15                      81737 Munich                      Germany                      E-mail: <a href="mailto:info@vdw-dental.com">info@vdw-dental.com</a>                      Website: <a href="http://www.vdw-dental.com">www.vdw-dental.com</a></p>	

# FDI Annual World Dental Congress 2-5 September 2010 Salvador da Bahia, Brazil



[congress@fdiworldental.org](mailto:congress@fdiworldental.org)  
[www.fdiworldental.org](http://www.fdiworldental.org)



BRAZIL  
SALVADOR  
DA BAHIA 2010

# International Events

## 2010

### AAE Annual Session

Where: San Diego, CA, USA  
Date: 14–17 April 2010  
E-mail: [info@aae.org](mailto:info@aae.org)  
Website: [www.aae.org](http://www.aae.org)

### Roots Summit 2010

Where: Barcelona, Spain  
Date: 3–5 June 2010  
E-mail: [info.roots@evento.es](mailto:info.roots@evento.es)  
Website: [www.evento.es](http://www.evento.es)

### NEF Annual Meeting

Where: Larvik, Norway  
Date: 4–6 June 2010  
Website: [www.endodonti.no](http://www.endodonti.no)

### SFE International Congress 2010

Where: Nancy, France  
Date: 25 & 26 June 2010  
E-mail: [contacts@sf-endo.com](mailto:contacts@sf-endo.com)  
Website: [www.sf-endo.com](http://www.sf-endo.com)

### SkandEndo 2010

Where: Espoo, Finland  
Date: 19–21 August 2010  
Website: [www.osf.fi](http://www.osf.fi)

### COSAE 2010

Where: Buenos Aires, Argentina  
Date: 26–28 August 2010  
E-mail: [sae@aoa.org.ar](mailto:sae@aoa.org.ar)

### FDI Annual World Dental Congress

Where: Salvador da Bahia, Brazil  
Date: 2–5 September 2010  
E-mail: [congress@fdiworldental.org](mailto:congress@fdiworldental.org)  
Website: [www.fdiworldental.org](http://www.fdiworldental.org)

### 8<sup>th</sup> IFEA World Congress

Where: Athens, Greece  
Date: 6–9 October 2010  
E-mail: [IFEAsecretary@aol.com](mailto:IFEAsecretary@aol.com)  
Website: [www.ifea2010-athens.com](http://www.ifea2010-athens.com)

### Trans-Tasman Endodontic Conference

Where: Christchurch, New Zealand  
Date: 4–6 November 2010  
E-mail: [info@tteconference.com](mailto:info@tteconference.com)  
Website: [www.tteconference.com](http://www.tteconference.com)

### DGEndo Annual Meeting

Where: Berlin, Germany  
Date: 4–6 November 2010  
E-mail: [sekretariat@dgendo.de](mailto:sekretariat@dgendo.de)  
Website: [www.dg-endo.de](http://www.dg-endo.de)

## 2011

### 34<sup>th</sup> International Dental Show

Where: Cologne, Germany  
Date: 22–26 March 2011  
E-mail: [ids@koelnmesse.de](mailto:ids@koelnmesse.de)  
Website: [www.ids-cologne.de](http://www.ids-cologne.de)

### 15<sup>th</sup> Biennial ESE Congress

Where: Rome, Italy  
Date: 28 September–1 October 2011  
Website: [www.eserome2011.com](http://www.eserome2011.com)





## submission guidelines:

Please note that all the textual components of your submission must be combined into one MS Word document. Please do not submit multiple files for each of these items:

- \_ the complete article;
- \_ all the image (tables, charts, photographs, etc.) captions;
- \_ the complete list of sources consulted; and
- \_ the author or contact information (biographical sketch, mailing address, e-mail address, etc.).

In addition, images must not be embedded into the MS Word document. All images must be submitted separately, and details about such submission follow below under image requirements.

### Text length

Article lengths can vary greatly—from 1,500 to 5,500 words—depending on the subject matter. Our approach is that if you need more or less words to do the topic justice, then please make the article as long or as short as necessary.

We can run an unusually long article in multiple parts, but this usually entails a topic for which each part can stand alone because it contains so much information.

In short, we do not want to limit you in terms of article length, so please use the word count above as a general guideline and if you have specific questions, please do not hesitate to contact us.

### Text formatting

We also ask that you forego any special formatting beyond the use of italics and boldface. If you would like to emphasise certain words within the text, please only use italics (do not use underlining or a larger font size). Boldface is reserved for article headers. Please do not use underlining.

Please use single spacing and make sure that the text is left justified. Please do not centre text on the page. Do not indent paragraphs, rather place a blank line between paragraphs. Please do not add tab stops.

Should you require a special layout, please let the word processing programme you are using help you do this formatting automatically. Similarly, should you need to make a list, or add footnotes or endnotes, please let the word processing programme do it for you automatically. There are menus in every programme that will enable you to do so. The fact is that no matter how carefully done, errors can creep in when you try to number footnotes yourself.

Any formatting contrary to stated above will require us to remove such formatting before layout, which is very time-consuming. Please consider this when formatting your document.

### Image requirements

Please number images consecutively throughout the article by using a new number for each image. If it is imperative that certain images are grouped together, then use lowercase letters to designate these in a group (for example, 2a, 2b, 2c).

Please place image references in your article wherever they are appropriate, whether in the middle or at the end of a sentence. If you do not directly refer to the image, place the reference at the end of the sentence to which it relates enclosed within brackets and before the period.

In addition, please note:

- \_ We require images in TIF or JPEG format.
- \_ These images must be no smaller than 6x6 cm in size at 300 DPI.
- \_ These image files must be no smaller than 80 KB in size (or they will print the size of a postage stamp!).

Larger image files are always better, and those approximately the size of 1 MB are best. Thus, do not size large image files down to meet our requirements but send us the largest files available. (The larger the starting image is in terms of bytes, the more leeway the designer has for resizing the image in order to fill up more space should there be room available.)

Also, please remember that images must not be embedded into the body of the article submitted. Images must be submitted separately to the textual submission.

You may submit images via e-mail, via our FTP server or post a CD containing your images directly to us (please contact us for the mailing address, as this will depend upon the country from which you will be mailing).

Please also send us a head shot of yourself that is in accordance with the requirements stated above so that it can be printed with your article.

### Abstracts

An abstract of your article is not required.

### Author or contact information

The author's contact information and a head shot of the author are included at the end of every article. Please note the exact information you would like to appear in this section and format it according to the requirements stated above. A short biographical sketch may precede the contact information if you provide us with the necessary information (60 words or less).

### Questions?

Claudia Salwiczek (Managing Editor)  
c.salwiczek@oemus-media.de

# roots

international magazine of endodontology

## Publisher

Torsten R. Oemus  
[t.oemus@oemus-media.de](mailto:t.oemus@oemus-media.de)

## CEOs

Ingolf Döbbecke  
[doebbecke@oemus-media.de](mailto:doebbecke@oemus-media.de)

Jürgen Isbaner  
[isbaner@oemus-media.de](mailto:isbaner@oemus-media.de)

Lutz V. Hiller  
[hiller@oemus-media.de](mailto:hiller@oemus-media.de)

## Managing Editor

Claudia Salwiczek  
[c.salwiczek@oemus-media.de](mailto:c.salwiczek@oemus-media.de)

## Executive Producer

Gernot Meyer  
[g.meyer@oemus-media.de](mailto:g.meyer@oemus-media.de)

## Designer

Josephine Ritter  
[j.ritter@oemus-media.de](mailto:j.ritter@oemus-media.de)

## Copy Editors

Sabrina Raaff  
Hans Motschmann

## Published by

Oemus Media AG  
Holbeinstraße 29  
04229 Leipzig, Germany  
Tel.: +49-341/4 84 74-0  
Fax: +49-341/4 84 74-2 90  
[kontakt@oemus-media.de](mailto:kontakt@oemus-media.de)  
[www.oemus.com](http://www.oemus.com)

## Printed by

Messedruck Leipzig GmbH  
An der Hebemärchte 6  
04316 Leipzig, Germany

## Editorial Board

Fernando Goldberg, Argentina  
Markus Haapasalo, Canada  
Ken Serota, Canada  
Clemens Bargholz, Germany  
Michael Baumann, Germany  
Benjamin Briseno, Germany  
Asgeir Sigurdsson, Iceland  
Adam Stabholz, Israel  
Heike Steffen, Germany  
Gary Cheung, Hong Kong  
Unni Endal, Norway  
Roman Borczyk, Poland  
Bartosz Cerkaski, Poland  
Esteban Brau, Spain  
José Pumarola, Spain  
Kishor Gulabivala, United Kingdom  
William P. Saunders, United Kingdom  
Fred Barnett, USA  
L. Stephan Buchanan, USA  
Jo Dovgan, USA  
Vladimir Gorokhovskiy, USA  
James Gutmann, USA  
Ben Johnson, USA  
Kenneth Koch, USA  
Sergio Kuttler, USA  
John Nusstein, USA  
Ove Peters, USA  
Jorge Vera, Mexico



Claudia Salwiczek, Managing Editor

roots

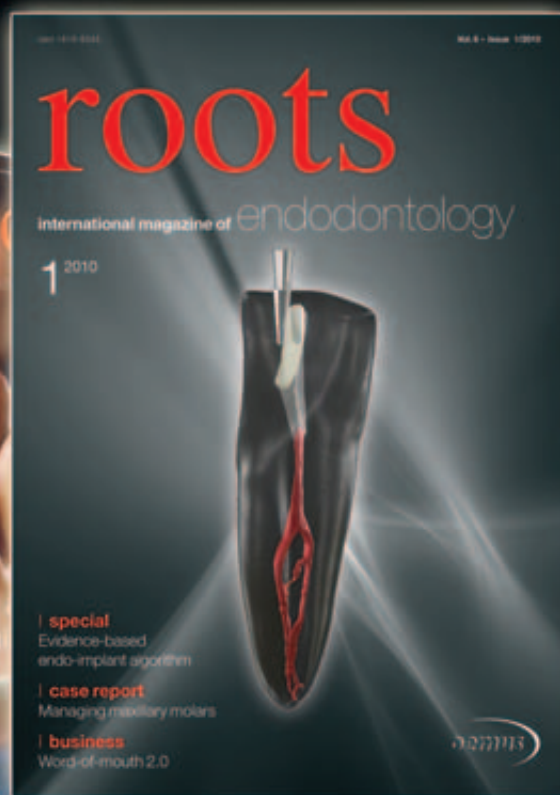
## Copyright Regulations

\_roots international magazine of endodontology is published by Oemus Media AG and will appear in 2010 with one issue every quarter. The magazine and all articles and illustrations therein are protected by copyright. Any utilisation without the prior consent of editor and publisher is inadmissible and liable to prosecution. This applies in particular to duplicate copies, translations, microfilms, and storage and processing in electronic systems.

Reproductions, including extracts, may only be made with the permission of the publisher. Given no statement to the contrary, any submissions to the editorial department are understood to be in agreement with a full or partial publishing of said submission. The editorial department reserves the right to check all submitted articles for formal errors and factual authority, and to make amendments if necessary. No responsibility shall be taken for unsolicited books and manuscripts. Articles bearing symbols other than that of the editorial department, or which are distinguished by the name of the author, represent the opinion of the afore-mentioned, and do not have to comply with the views of Oemus Media AG. Responsibility for such articles shall be borne by the author. Responsibility for advertisements and other specially labeled items shall not be borne by the editorial department. Likewise, no responsibility shall be assumed for information published about associations, companies and commercial markets. All cases of consequential liability arising from inaccurate or faulty representation are excluded. General terms and conditions apply, legal venue is Leipzig, Germany.

# roots

international magazine of endodontology



 **Subscribe now!**

## One issue free of charge!

I hereby agree to receive a free trial subscription of **roots** international magazine of endodontology (4 issues per year). I would like to subscribe to **roots** (€ 44\* for German customers; € 46\* for customers outside of Germany) unless a written cancellation is sent within 14 days of the receipt of the trial subscription. The subscription will be renewed automatically every year until a written cancellation is sent to OEMUS MEDIA AG, Holbeinstr. 29, 04229 Leipzig, Germany, six weeks prior to the renewal date.

▶ **Reply** via Fax to +49 (0) 3 41/4 84 74-2 90 or via E-mail to [grasse@oemus-media.de](mailto:grasse@oemus-media.de)

Last Name, First Name

Company

Street

ZIP/City/Country

E-mail

Signature

Notice of revocation: I am able to revoke the subscription within 14 days after my order by sending a written cancellation to OEMUS MEDIA AG, Holbeinstr. 29, 04229 Leipzig, Germany.

Signature

Holbeinstr. 29, 04229 Leipzig, Germany, Tel.: +49 (0) 3 41/4 84 74-0, Fax: +49 (0) 3 41/4 84 74-2 90, E-mail: [grasse@oemus-media.de](mailto:grasse@oemus-media.de)

OEMUS MEDIA AG





## ADHESIVE CORE BUILD-UP SYSTEM

Complete set for 15 post-endodontic treatment

- Effective five step system
- Monoblock formation of tooth, post and build-up
- Futurabond and Ceramic Bond for highest stability
- Aesthetic foundation for prosthetic restorations

**Rebuilda Post**  
*system*

