

Opalescent composite resin

Author_ Ulf Krueger-Janson, Germany

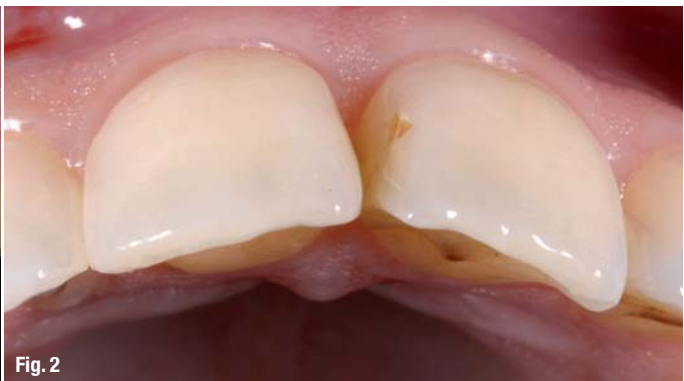
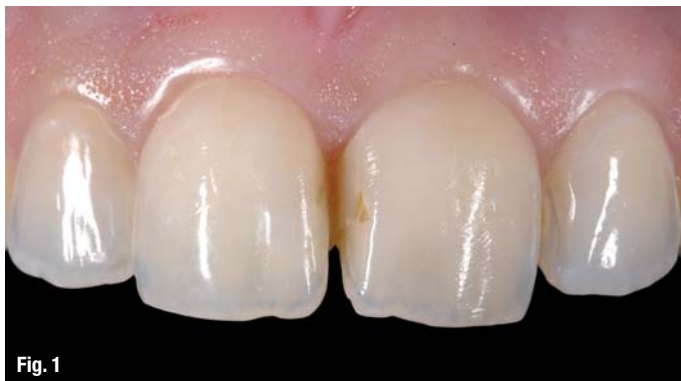
Fig. 1 Initial findings: defective restorations in teeth 11 and 21.

Fig. 2 Incisal view.

Experience has shown that aesthetically pleasing composite restorations in the anterior region can only be created, if the clinician succeeds in achieving a near-perfect shade match between the restorative material and remaining dentition. In general, state-of-the-art composite restoratives should be easy to handle, adapt to cavity walls and offer good surface finishing qualities. At the same time, however, it is essential that they allow the restoration to blend harmoniously into the natural oral environment.

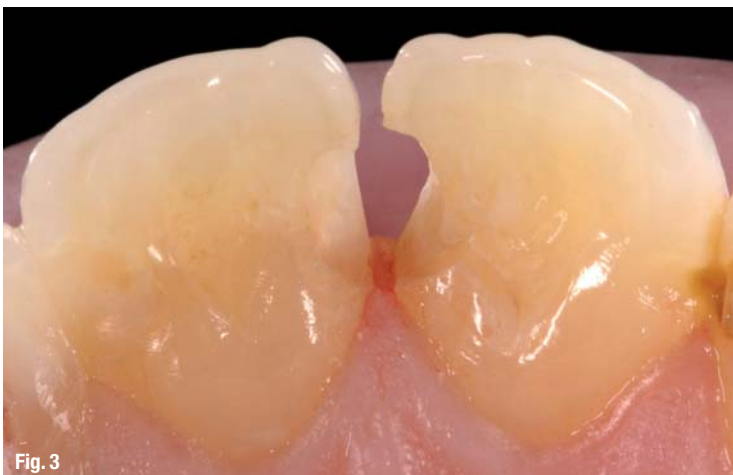Aesthetic integration is accomplished by placing special optical effects. Composite materials with a high opacity (similar to dentine) and relative translucency (similar to enamel) are

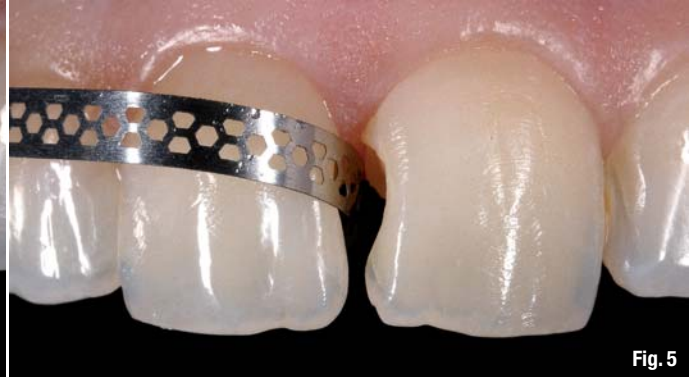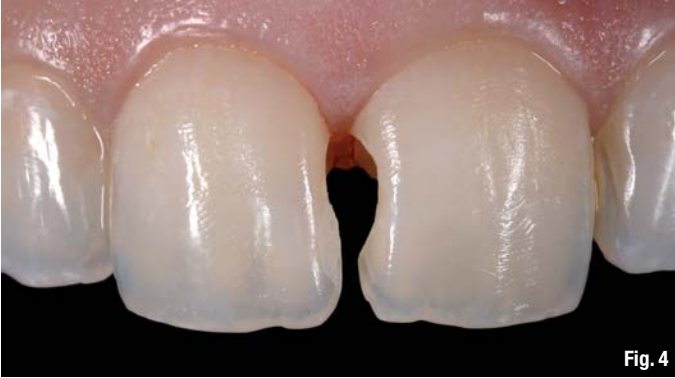required for this. Composite restorative systems that additionally include an opalescent material that allows the bluish areas (frequently observed along the marginal ridges) and yellowish-whitish portion of incisal edges to be reliably mimicked, offer just about everything the clinician needs to restore a case aesthetically. The new IPS Empress Direct system (Ivoclar Vivadent) includes such an opalescent material, which enables the reproduction of the above-mentioned optical phenomena owing to its shade effects.

Opalescence is an optical effect exhibited by some substances. It is caused by the refraction of the various wavelengths of visible light due to the small structures in the substance. As a result, the substance exhibits an intensive bluish tinge in incident light, whereas it has milky yellowish appearance in transmitted light, just as is the case in natural opal stone. In restorations, the light that strikes the composite material and is reflected from it appears bluish. Against the light, however, the composite has a slightly milky appearance with a yellowish tinge. The incisal edge of natural dentition often has this appearance.

The clinical case described here involved the replacement of two defective proximal restorations (Fig. 1). An initial analysis of the various shade layers of which the natural teeth were

Fig. 3 View after removal of the old fillings.




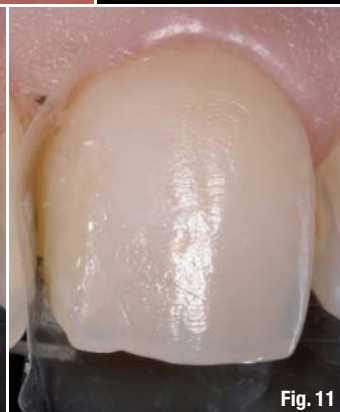
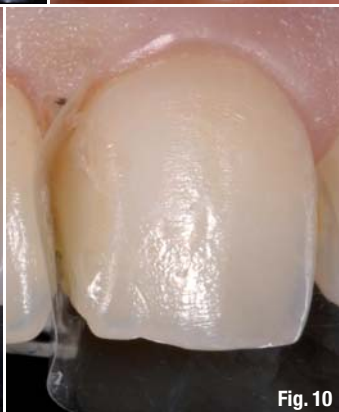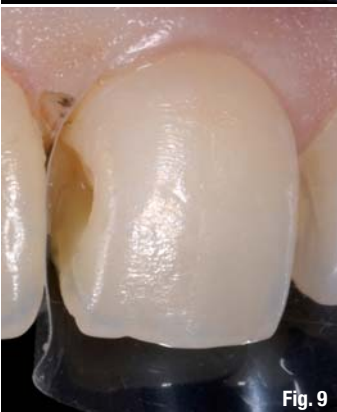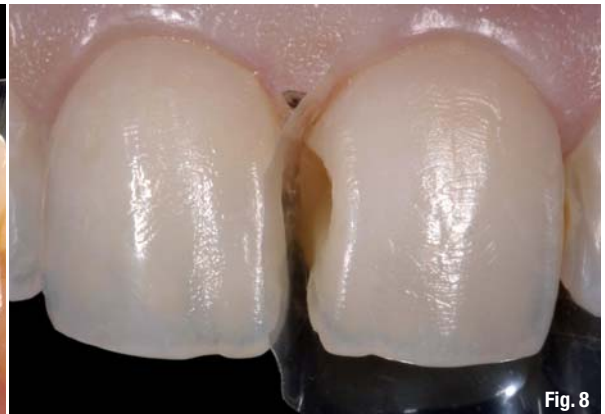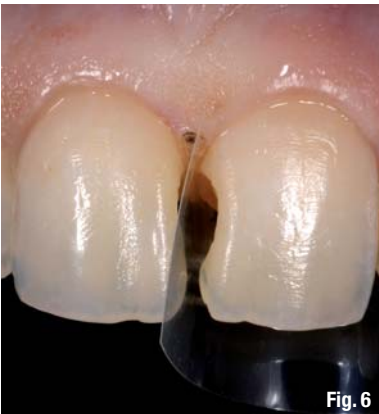composed demonstrated that the optical incisal edge effects described above were particularly eye-catching in this case. Moreover, the bluish-whitish line extended far into the interproximal area. The challenge was to create a highly aesthetic restoration. We strove to achieve this by means of a slight reduction of the diastema and the application of opalescent effects. Following, I describe the way improved restorative results can be achieved if an opalescent material is also available (IPS Empress Direct Trans Opal, Ivoclar Vivadent).

The incisal view of the teeth shows the undulating contour of the incisal edge (Fig. 2). As secondary decay was diagnosed, the old fillings were completely removed (Figs. 3 & 4). A perforated, one-sided diamond abrasive strip was

used to bevel the preparation margin (Fig. 5). Thus, minimally invasive roughening and beveling of the enamel surface were ensured in the equi-gingival cervical region. Following etching with phosphoric acid and conditioning with Excite bonding agent (Ivoclar Vivadent), a matrix band was placed (Fig. 6). The band was slid into the sulcus along the proximal tooth surface and secured with a transparent wedge from the palatal side (Fig. 7). The anaemic appearance of the surrounding gingiva indicated that non-traumatic compression of the tissue had been achieved. In the palatal view, the size-1 wedge is clearly visible. Owing to the pressure it exerts, the interdental space was slightly enlarged. The matrix band was secured once in an optimum position. Then the first layer of composite material (IPS Empress Direct Dentin Shade A3) was placed

Fig. 4 Defects viewed from the vestibular aspect.
Fig. 5 Beveling of the preparation margin using diamond abrasive strips.
Fig. 6 Placement of the matrix band.
Fig. 7 Palatal view.
Fig. 8 Application of the first composite increment.
Fig. 9 Further IPS Empress Direct Dentin Shade A3 increment.
Fig. 10 Completion of the dentine core using IPS Empress Direct Dentin Shade A2.
Fig. 11 Coverage with IPS Empress Direct Enamel Shade A2.
Fig. 12 Contouring of the final tooth shape using IPS Empress Direct Trans Opal.

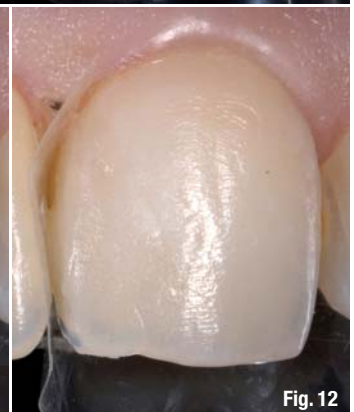
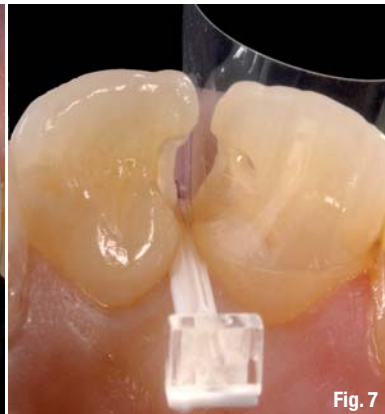
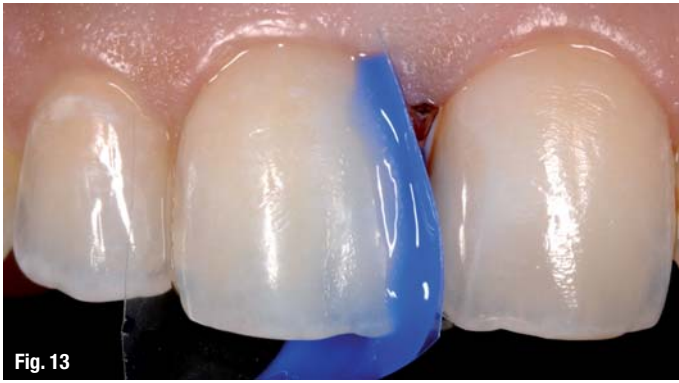



Fig. 13

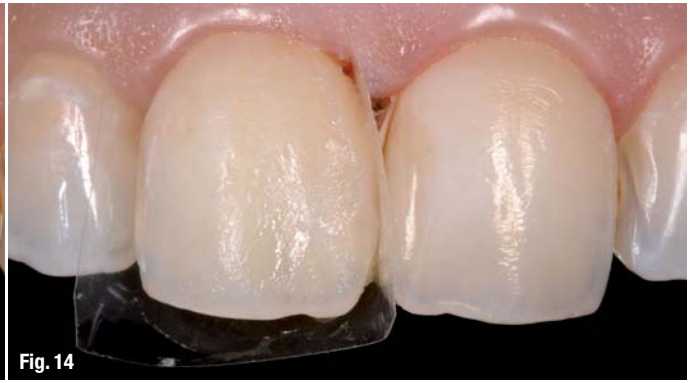

Fig. 14

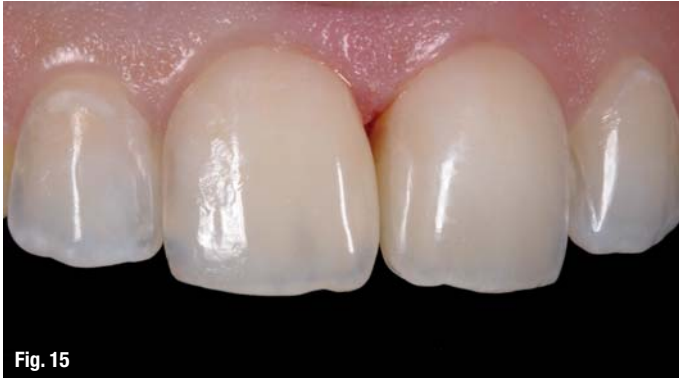

Fig. 15

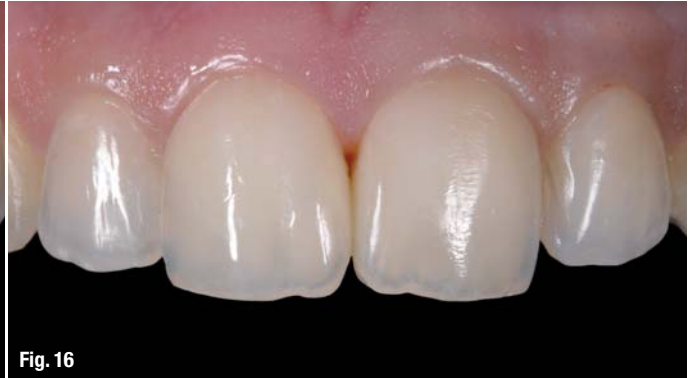

Fig. 16

Fig. 13_ A matrix band has been inserted in the interdental space between teeth 11 and 21; etching gel has already been applied.

Fig. 14_ A layer of IPS Empress Direct Trans Opal was applied to complete the composite build-up.

Fig. 15_ Situation immediately after completion of treatment.

Fig. 16_ Final photograph taken one week after the treatment, showing complete closure of the interdental gap.

and adapted in such a way that it created a preliminary outline of the proximal contours (Fig. 8).

Subsequently, a further layer of composite was added (Fig. 9). This was followed by a layer of Dentin Shade A2 (Fig. 10), which served to optimise the shade adjustment. Next, a layer of Enamel Shade A2 (Fig. 11) was placed and the build-up was completed with Trans Opal. Figure 12 demonstrates the building up of the composite materials to create the final tooth shape, which also simplified morphological contouring during the finishing procedure. For finishing, an EVA tip handpiece was used. This handpiece performs oscillating movements. Owing to the fine tip, completely non-traumatic finishing was ensured, particularly along the transition between the filling material and sulcus. The fine reduction, which was achieved by means of suitable grit size (the green or blue ring is used for pre-polishing), enables targeted finishing. Therefore, over-contouring of the composite restoration was not necessary. The surface was finished exclusively with an EVA tip and subsequently polished with a pre-polisher and high-gloss polishers (Astropol, Ivoclar Vivadent). Polishing brushes (Astrobrush, Ivoclar Vivadent) were used to finish the surface with a final high-gloss sheen.

In tooth 11, a matrix band was used to shape the proximal surface (Fig. 13). The band also served to protect tooth 21 from the etching

gel that was applied immediately afterwards. The wedge was placed with tension in order to establish a perfect separation of the teeth. The intention was to reduce the diastema substantially. The primary composite increments were applied according to the protocol described above. The final layers were also placed based on the previously mentioned criteria. Also, in this case, Trans Opal material was used to complete the build-up (Fig. 14). After polishing the restoration to a high lustre, a slight colour discrepancy due to the dryness of the superficial enamel portion was recognisable. The interdental papilla was still slightly compressed owing to the wedge (Fig. 15). The final photograph (Fig. 16), which was taken one week after placement of the restoration, shows a completely healthy papilla and virtually invisible composite restorations with lifelike opalescence.

_contact		cosmetic dentistry
	<p>Ulf Krueger-Janson Stettenstraße 48 60322 Frankfurt/Main Germany</p> <p>E-mail: ulf.krueger-janson@email.de</p>	