

Apical microsurgery— Part V: REF materials and techniques

Author_ Dr John J. Stropko, USA

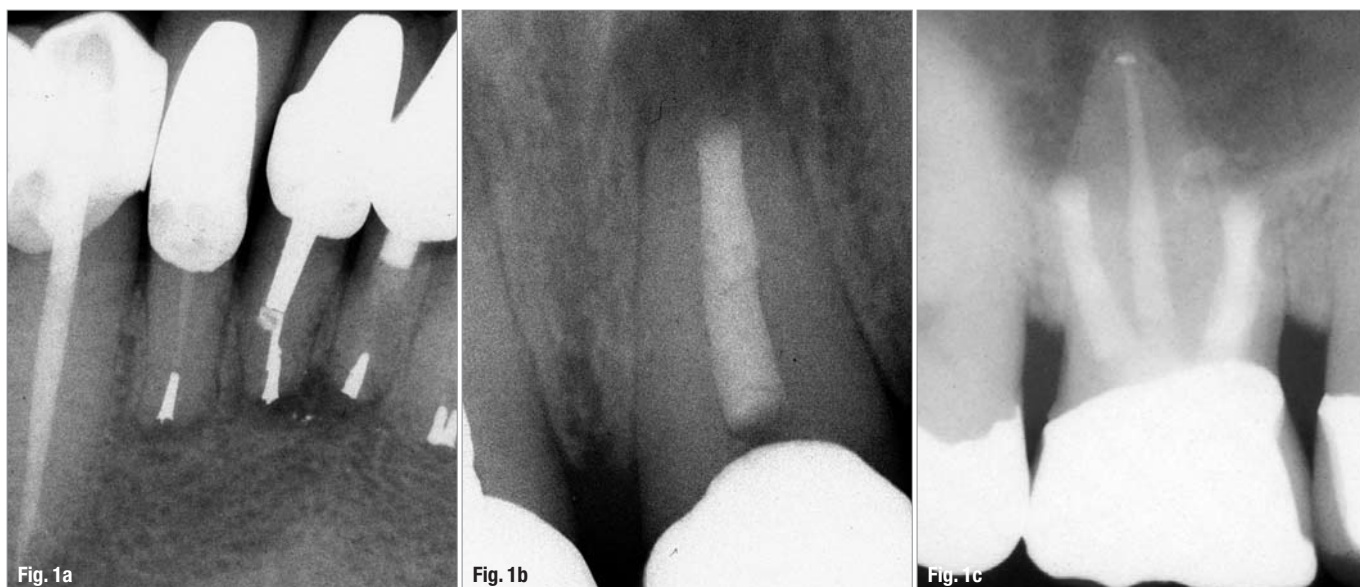


Fig. 1a_Amalgam is the most radiopaque REF material, but its use is highly controversial.

Fig. 1b_SEBA has a radiopacity similar to that of gutta-percha.

Fig. 1c_MTA has a radiopacity just slightly better than gutta-percha.

In Parts I to IV, the necessary steps and procedures were presented, enabling the operator to atraumatically and predictably allow the root-end preparation (REP) to be sealed using any accepted root-end fill (REF) material. The surgical crypt should be clean and dry so that vision is clear and unobstructed. Remember, the steps must be followed completely in order to achieve as predictable a result as humanly possible. If, for some reason, crypt management is not complete or the REP is not clean and finished, it will be necessary to repeat a step, or two, to achieve the desired result. The importance of having total control at this point in the apical microsurgical procedure cannot be over-emphasised.

_The operator is now at a stage in the microsurgical procedure at which the tissues have been atraumatically retracted, the crypt is well managed, the REP is acid etched, rinsed, dried and ready to be filled. By removing the smear-layer barrier, exposing the organic component (collagen fibrils) of the resected cementum and dentine, has been shown to enhance cemento-genesis and is one of the keys to dento-alveolar healing.¹

There are several retro-fill materials currently available: amalgam,IRM, SuperEBA (SEBA; Bosworth), bonded composites (OptiBond, Sybron Dental), glass ionomers (Geristore, Den-Mat) and, more recently, Mineral Trioxide Aggregate (MTA; DENTSPLY Tulsa Dental). The number of publications in the literature regarding research on the above materials is extensive; thus, only a few of these are mentioned. I do not wish to recommend or condemn any retro-fill mate-

Where Science Meets the Art of Beauty

05-06 November 2010

The Address Hotel Dubai Marina
Dubai UAE

DENTAL - FACIAL COSMETIC INTERNATIONAL CONFERENCE

2nd Edition

Platinum Sponsor

Gold Sponsors



CAPP

CME 14 Hours

Tel: +971 4 3616174 | Fax: +971 4 3686883 | Mob: +971 50 2793711 | info@cappmea.com

www.cappmea.com/aesthetic2010




Fig. 2a




Fig. 2b

Fig. 2a_The Lee MTA Pellet Forming Block has multiple sized grooves for MTA.

Fig. 2b_MTA is removed with an instrument to be delivered to the REP.

rial (except amalgam), but will generalise and relate my—and those of others—experience of and opinions about their applications.

Amalgam and IRM were used for many years as the only commonly available retro-fill materials. However, in almost every leakage study published during the past few years, amalgam has proven to be the worst offender, exhibiting the most leakage.^{2,3} This fact, accompanied by the general controversy about mercury in amalgam, strongly suggests that there is no valid reason to continue its use as a retro-fill material. The only real advantage to amalgam is its favourable radiopacity (Fig. 1a). In fact, of all REF materials commonly in use today, none of them compare to the radiopacity of amalgam.

Since the advent of the anatomically correct, ultrasonic REP, one of the most popular REF materials still in use today is SEBA. A recent follow-up study demonstrated a success rate of 91.5% using SEBA.⁴

The author used SEBA routinely in the early nineties with full confidence in its sealing capabilities.

To some, the major drawback of SEBA is its technique sensitivity. The surgical assistant has to mix it until it is sufficiently thick to roll into a thin tapered point with the consistency of dough. For even a well-trained assistant, this is often the most stressful part of the microsurgical procedure. The dough-like tapered end of the thin SEBA roll is then segmented with an instrument, such as a small Hollenback Carver. The small cone-shaped end piece is then inserted into the retro-preparation and gently compacted coronally with the appropriate plugger. Two to five of these small segments are usually necessary to overfill the retro-preparation slightly. Another problem experienced by many is that SEBA is unpredictable as to its setting time, sometimes setting too quickly and at other times, taking much too long for the tired surgeon. At any rate, after the REF has been completed, an instrument and/or bur is used to smooth the resected surface, producing the final finish. A mild etchant is then used to remove the smear layer produced during the final finishing process. SEBA has a radiopacity comparable to that of gutta-percha, so it is necessary to inform the referring doctor that a retro-fill had indeed been performed (Fig. 1b). However, in some recent studies, SEBA has been shown to have a better sealing ability than IRM but does not seal as well as MTA.^{2,3}

Bonding, using composite retro-fill materials, is now possible because surgeons can have total control over the apical environment utilising good crypt management procedures. Many different materials are available for use as an REF. OptiBond and Geristore

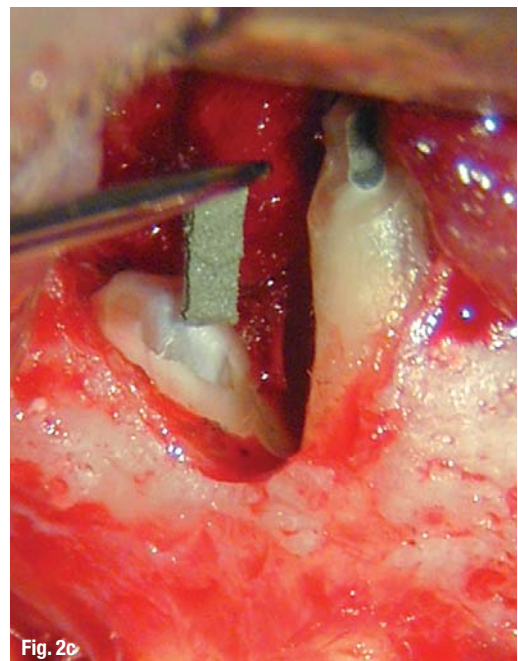


Fig. 2c

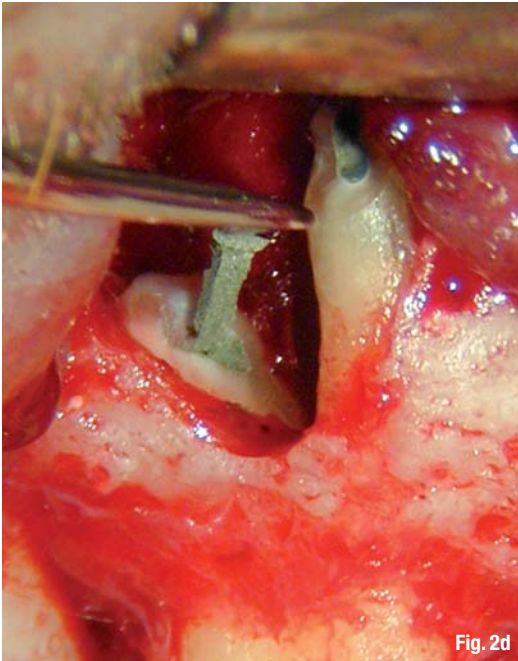


Fig. 2d

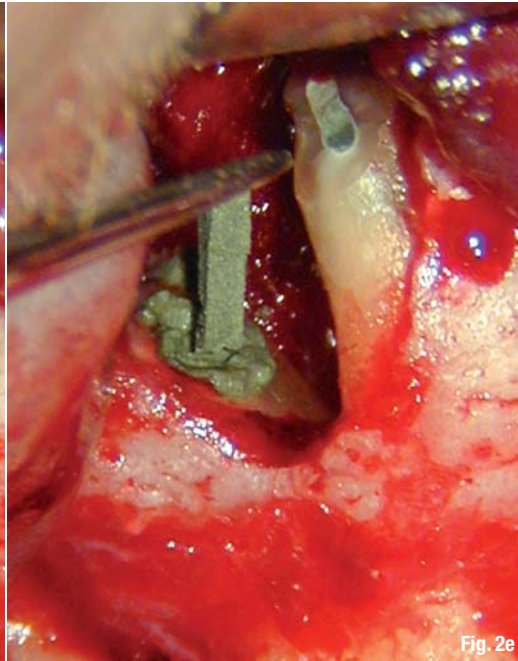


Fig. 2e

Figs. 2c–e—Using the Lee MTA Pellet Forming Block, it takes fewer ‘passes’—usually only two or three—with the instrument to complete the fill of the REP with MTA.

are popular because of their ease of use. They both have good flowability, dual-cure properties and the ability to be bonded to dentine. Geristore is supported by research, demonstrating bio-compatibility to the surrounding tissues.⁵ The usual etching, conditioning of the dentine, insertion of the selected material, and curing by chemical or light is accomplished in a routine manner when bonding into the retro-preparation. *Note: Since the light source for the OM is so intense, it is mandatory to use an orange filter while placing the composite in order to prevent a premature set.* For most microscopes, an orange filter is available that easily and inexpensively replaces the blood filter. After the composite has been completely cured, the material is finished with a high-speed finishing bur and the resected root-end is etched with a 35% blue gel etchant (Ultradent) for about 12 seconds in order to remove the smear layer and to demineralise the surface.

Several studies have demonstrated no leakage with bonding techniques and many operators use bonding as their technique of choice. However, there is some controversy as to whether the resected surface of the root should also be coated with a thin layer of the bonding material. A ‘cap’ of material (usually OptiBond) is placed with the intention of sealing the exposed tubules on the resected surface. Operators that choose to cover the resected surface believe it is necessary to ensure a good seal and enable better predictability. Other operators do not believe that exposed tubules are a factor concerning the predictability of the healing process. They reason that nothing will heal as well or is more bio-compatible than the exposed dentine of the apically resected surface. I do not cover the exposed apical surface and am convinced that a decisive answer regarding this is still awaited.

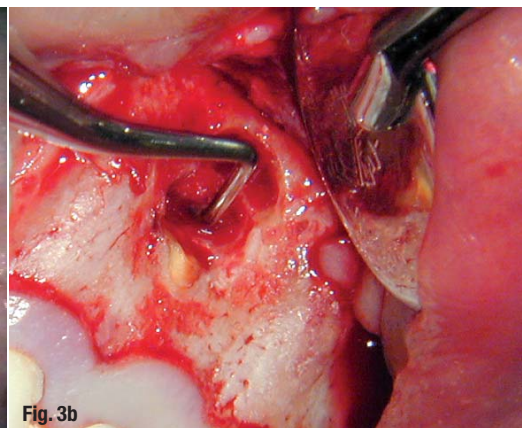
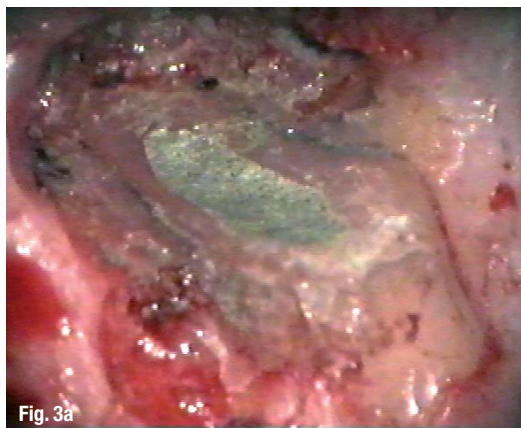
More recently, another material—MTA—has become very popular and is widely used by many. MTA has attracted many converts, and there is much research being conducted and many publications presented so that just one reference would be futile. The evidence extolling the virtues of MTA, regarding its sealing capabilities and its bio-compatibility with the surrounding tissues, is overwhelming. I have talked to many respected endodontists and most are now using MTA as their routine retro-fill material. MTA is chemically similar to calcium sulphate. It is forgiving to work with and has a radiopacity slightly better than gutta-percha (Fig. 1c).

The main advantage of MTA is its ease of use, much like handling Portland Cement. One of the secrets to using MTA is to keep it sufficiently dry so it does not flow too readily (like wet sand), yet sufficiently moist to permit manipulation and maintain a workable consistency. The desired thickness is easily accomplished by using dry cotton pellets, or the MTA mix can be gently dried with a dedicated, air-only, Stropko Irrigator. If the MTA is too dry and needs moisture added, that too is easily done with a cotton pellet saturated with sterile water. Properly mixed MTA can be extruded in pellets of various sizes (depending on the size of the carrier used) using a Dovgan Carrier, and condensed with an appropriate plugger.

More recently, a simple method for delivering MTA into the REP was introduced (Figs. 2a & b). The Lee MTA Pellet Forming Block has several differently sized grooves to create the desired aliquot of MTA. The MTA adheres to the instrument, allowing for easy and efficient placement into the REP (Figs. 2c–e).

Fig. 3a Once placed, the MTA should be carved level with the surface of the REB.

Fig. 3b MTA is hydrophilic so it is important to re-establish the blood supply to cover it after placement.



For a denser and stronger consistency, the assistant can touch the non-working end of the plugger or explorer with an ultrasonic tip during the condensation process. The flow is increased and a much denser fill is achieved. As a result, ultrasonic densification also increases the radiopacity of MTA's appearance in the post-operative radiograph, but it is still similar to gutta-percha (Fig. 1c). MTA has approximately an hour of working time, which is more than adequate for apical microsurgery and reduces the time pressure of the surgical procedure. Finishing the MTA is simply a matter of carving away the excess material to the level of the resected root-end (Fig. 3a). The moisture necessary for the final set is derived from the blood, which fills the crypt after surgery. MTA is very hydrophilic and depends on moisture for the final set, so it is imperative that sufficient bleeding is re-established after crypt management in order to ensure that the crypt is filled (Fig. 3b). If any material, such as ferric sulphate, has been used for crypt management, it must be judiciously removed in order to restore blood supply to the crypt. This can be considered the final step in crypt management, and is especially important when MTA is used for the REF.

If the size of the lesion indicates the use of Guided Bone Regeneration (GBR), good blood supply is indicated anyway, so allow the blood to cover the MTA before placing the GBR material of choice. In a large lesion, it is sometimes difficult, even after curettage, to restore bleeding into the crypt (perhaps the crypt management was a little too effective) and it may be necessary to use a small round bur in the surgical handpiece to make several small holes in the surface of the crypt to aid in the re-establishment of the desired flow of blood.

Based on current studies, the operator can select any one of the above-mentioned REF materials and be comfortable that, if the proper protocol has been followed, the apical seal will be predictable and healing uneventful.

The final part of this series, published in **roots** 3/2010, will discuss *Sutures, suturing techniques and healing* (Part VI).

Editorial note: A complete list of references is available from the publisher.

_about the author

roots

Dr John J. Stropko received his DDS from Indiana University in 1964 and for 24 years practised restorative dentistry. In 1989, he received a certificate for endodontics from Boston University. He recently retired from the private practice of endodontics in Scottsdale in Arizona. Dr Stropko is an internationally recognised authority on micro-endodontics. He has been a visiting clinical instructor at the Pacific Endodontic Research Foundation (PERF), an Adjunct Assistant Professor at Boston University and an Assistant Professor of graduate Clinical Endodontics at Loma Linda University. His research on in vivo root canal morphology has been published in the *Journal of Endodontics*. He is the inventor of the Stropko Irrigator, has published in several journals and textbooks, and is an internationally known speaker. Dr Stropko has performed numerous live micro-endodontic and microsurgical demonstrations. He is the co-founder of *Clinical Endodontic Seminars*. He can be contacted at topendo@aol.com.

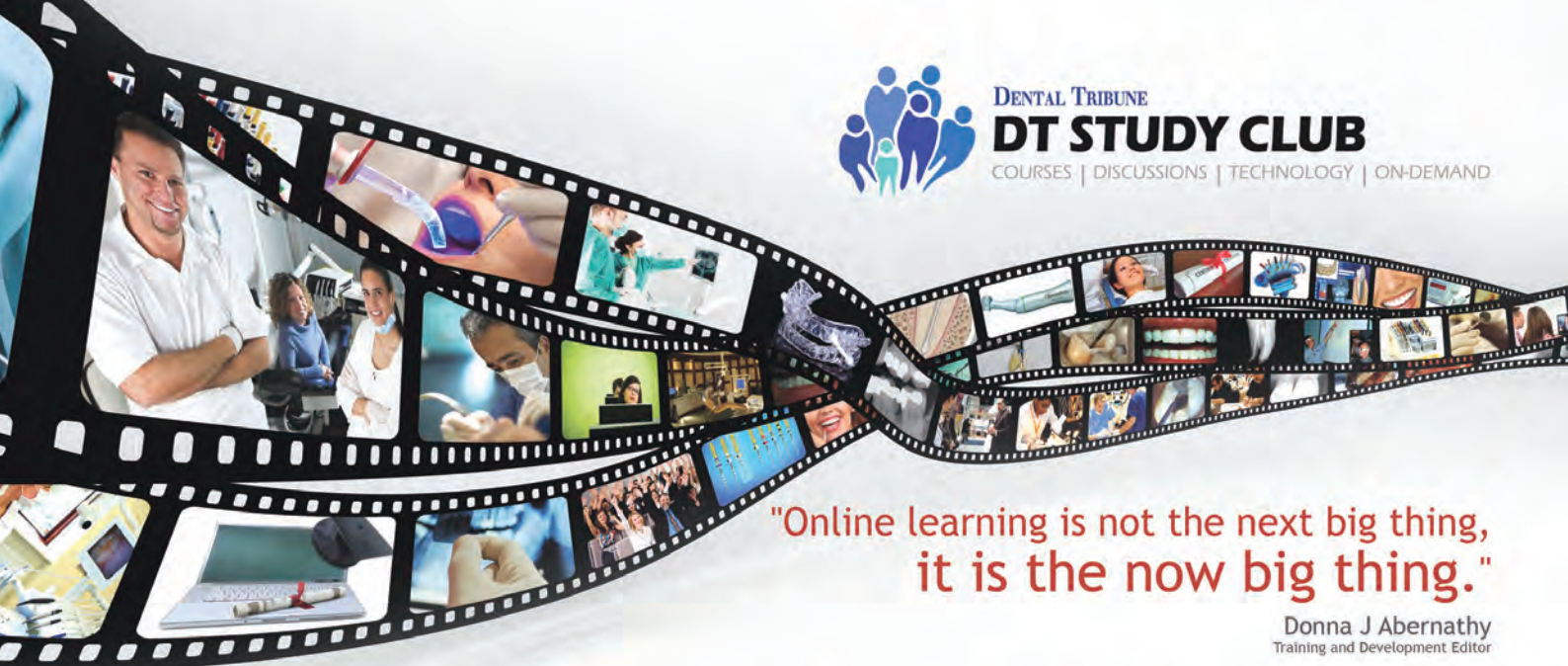



DENTAL TRIBUNE

DT STUDY CLUB

COURSES | DISCUSSIONS | TECHNOLOGY | ON-DEMAND



**"Online learning is not the next big thing,
it is the now big thing."**

Donna J Abernathy
Training and Development Editor

DTSC - COURSES, COMMUNITY, TECHNOLOGY, ON-DEMAND

The DT Study Club makes all of this is possible from the comfort of your own computer and without travel expenses. In other words, welcome to the community!

The purpose of this study club is to provide practitioners like yourself an opportunity to learn and network with like-minded colleagues in a friendly, non-threatening environment. We encourage you to take advantage of Dental Tribune's global outreach to access a variety of fresh perspectives and cultures, enhancing your educational mix.

24/7 LIVE AND INTERACTIVE ONLINE COURSES

Fulfill your yearly CE requirements with our growing list of archived ADA CERP approved courses.



DISCUSSION FORUMS

focused on helping today's practitioners to stay up to date. Networking possibilities that go beyond borders to create a truly Global Dental Village



VIDEO REVIEWS OF PRODUCTS

Our opinion leaders unveil new products, services, and give you their first impressions of the industry's hottest topics.



PEER REVIEWED CASE STUDIES

Upload, comment, participate. We encourage you to share your cases for review with like-minded practitioners.



 REGISTER FOR FREE ON WWW.DTSTUDYCLUB.COM

CONTESTS WITH CHANCES TO WIN FREE TUITION FOR ADA/CERP C.E. ACCREDITED WEBINARS

SPONSORSHIP AND SPEAKING INQUIRIES:
JULIA WEHKAMP, J.WEHKAMP@DTSTUDYCLUB.COM, (416) 907-9836.

ADACERP
CONTINUING EDUCATION RECOGNITION PROGRAM



PRACTICE MANAGEMENT



GENERAL DENTISTRY



COSMETICS



ENDODONTICS



IMPLANTOLOGY



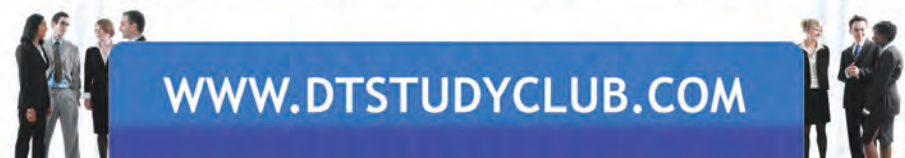PERIODONTICS



ORTHODONTICS



DENTAL HYGIENE



WWW.DTSTUDYCLUB.COM