



# AAE hosts first **live CT-guided endodontic surgery**

**Author\_** Sierra Rendon, USA

**\_On 16 April 2010**, the first live demonstration of a cutting-edge endodontic surgical procedure was presented at the American Association of Endodontists annual scientific session in San Diego.

Performed by Dr L. Stephen Buchanan, the experimental procedure—CT-guided endodontic Surgery (GES)—used SimPlant surgical treatment planning software (Materialise) to plot an ideal path to the diseased mesio-buccal (MB) root and bone of an upper first molar. This was followed by the digital fabrication of a SimPlant drill guide to transfer the treatment planned in computer space to the patient's jaw.

While this drilled guide software has been used successfully for many years in implant dentistry, it had not been previously used for endodontic surgery.

Dr Buchanan said he was introduced to the GES concept when he trained for implant surgery. His friend, the late Dr David Rosenberg, to whom he dedicated this procedure, taught him that drill guides can greatly improve surgical speed and accuracy during implant placement. When a graduate student at UCLA asked whether CT-generated drill guides could work for endodontic surgery, he said that his whole concept of endodontic surgery changed. Surprisingly, upon conducting a literature search, Buchanan found out this concept was first brought into the public domain in 2007.<sup>1</sup>

For the several hundred endodontists who watched this live demonstration, it was clear this was not yet a more efficient procedure. The potential, however, was evident.

Perhaps the most time-consuming part of the demonstration was the placement of a screw-fixed retraction fence he designed, but once the two 1.5 mm bone screws had been set, retraction of the mucosa overlying the drill path required no more effort on Buchanan's part.

He noted that inefficient tissue retraction is probably the largest barrier to shortening surgical times dramatically, and this aspect of GES is obviously a work in progress.

Despite the challenge of placing the retraction fence and dealing with significant bleeding (the patient had high blood pressure), drilling through the guide, to length, with the 2, 3, 4 and 5 mm drills was very straightforward.

After the drill guide had been removed, Buchanan captured a micro-mirror view through the resulting 5 mm drill hole—showing the MB root cut perfectly with the previously treated MB1 canal bisected and beyond it, toward the palatal aspect, a darkened isthmus that led directly to the previously untreated MB2 canal.

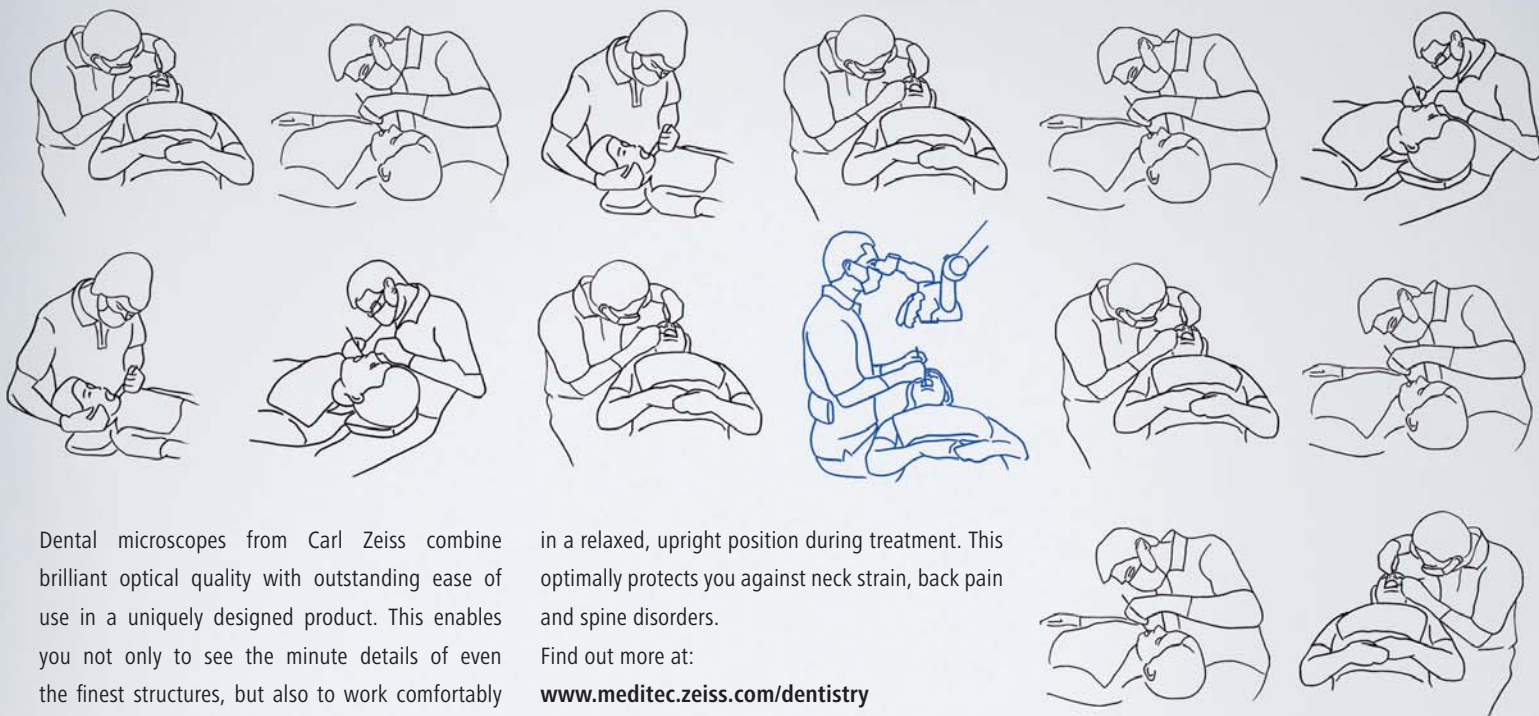He then negotiated and enlarged the MB2 canal through the resected root-end using 0.04 tapered rotary NiTi files in sizes #15/40. He said the 0.04 taper limitation reduced the accumulation of cyclic fatigue caused by the flexure of the files past the cut root surface, allowing him to cut a larger diameter of preparation to the coronal extent of the canal than would have been possible with instruments that were more tapered.

Filling this canal created some additional challenges. However, Dr Buchanan was able to accomplish this with a pressure syringe loaded with pink Cavit and a 27-gauge needle, resulting in a dense fill all the way to the pulp chamber. Dr Buchanan typically uses Cavit because: a) it sets in the presence of moisture; b) it seals against leakage as well as MTA does; and c) its viscosity allows it to be syringed quite a distance from the end of the needle.

An alternative with which he has been experimenting is filling apically instrumented canals with a carrier-based obturator. While early results look good (excellent fills and much less time and frustration), he chose to do the more familiar technique—perhaps for the last time.

AD

## Stand out above the rest!



Dental microscopes from Carl Zeiss combine brilliant optical quality with outstanding ease of use in a uniquely designed product. This enables you not only to see the minute details of even the finest structures, but also to work comfortably

in a relaxed, upright position during treatment. This optimally protects you against neck strain, back pain and spine disorders.

Find out more at:

[www.meditec.zeiss.com/dentistry](http://www.meditec.zeiss.com/dentistry)

### Carl Zeiss Surgical GmbH

A Carl Zeiss Meditec Company  
Carl-Zeiss-Strasse 22  
73447 Oberkochen  
Germany

Fax: +49 (0) 73 64/20-48 23  
[surgical@meditec.zeiss.com](mailto:surgical@meditec.zeiss.com)  
[www.meditec.zeiss.com/dentistry](http://www.meditec.zeiss.com/dentistry)  
[www.meditec.zeiss.com/contacts](http://www.meditec.zeiss.com/contacts)



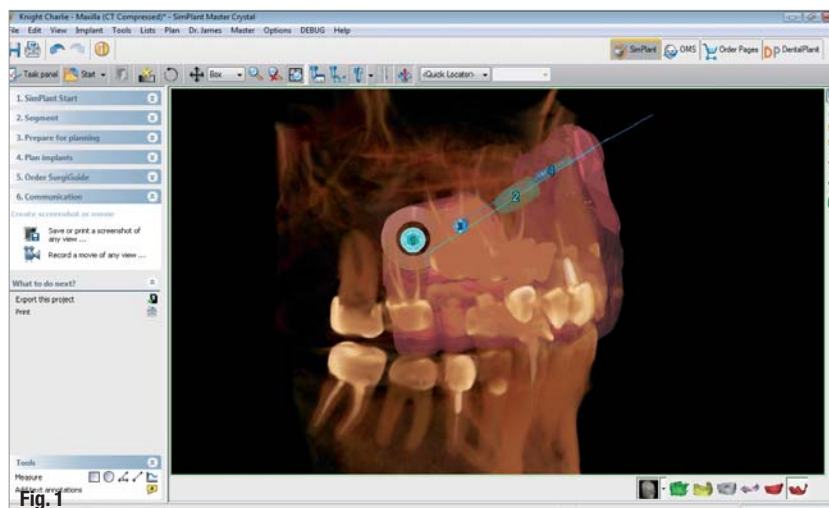


Fig. 1

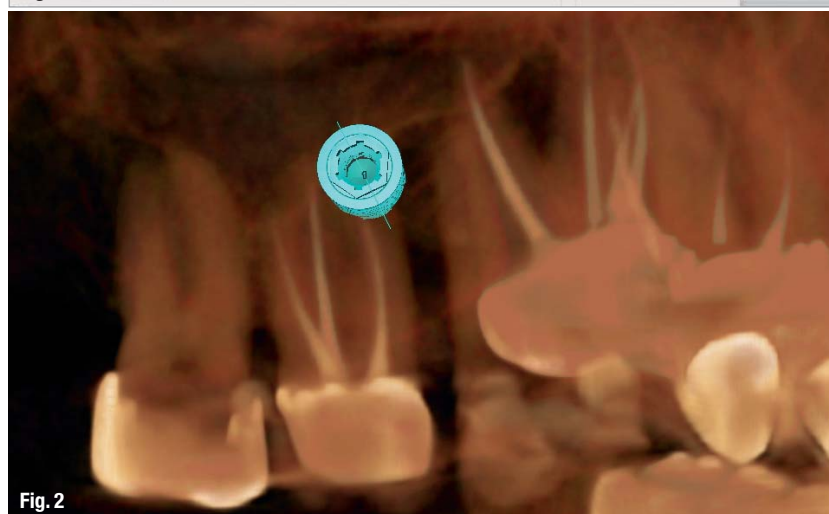


Fig. 2

**Figs. 1 & 2\_** Treatment planning using SimPlant software from Materialise to perfectly position the drill guide over the root end.  
**Fig. 3\_** Post-operative X-ray showing a very accurate circular osteotomy and apicectomy from the drill guides as well as a very dense MTA retro-fill in the trough preparation between the MB1 and MB2 canals.

Following the fill of the MB2 canal, Dr Buchanan brought in one of his newest ultrasonic tip designs, which he referred to as an Isthmus Hatchet (IH; Spartan). Three millimetres in length and 0.4 mm wide, with acute angles on each end, the IH literally dropped down into the root through the centre of the isthmus, resulting in a very smooth, straight-walled retro-preparation.

The apical retro-seal was done with grey ProRoot MTA (DENTSPLY Tulsa) because Dr Buchanan likes the handling characteristics more than the white MTA used in aesthetic areas.

The MTA was delivered with Tulsa's MTA tube carrier/condenser in 5 to 6 aliquots, and condensed using a hatchet plugger (HP) made to fit the preparation made using the IH. A conventional digital radiograph confirmed a dense retro-fill, and the minimally invasive flap was sutured with four 5-0 Supramid sutures.

A CT scan was done then with a Veraviewepocs 3D cone-beam CT machine (J. Morita), showing the final result with the MB2 canal and the apical preparation densely and completely filled.

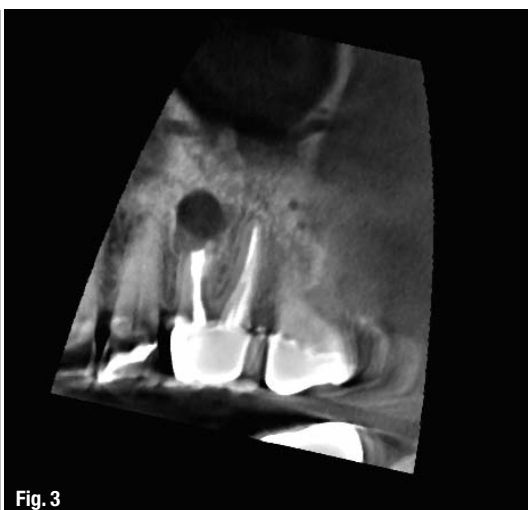

Fig. 3

When attendees were asked their opinion of the demonstration and the new GES procedure, the most consistent response was firstly that Buchanan demonstrated much courage doing an experimental procedure in front of his peers, and secondly that although it is not there yet, the potential benefits of GES are many.

What is up next for Buchanan and the engineering team at Materialise? The next six months to a year will be spent on treatment planning and performing the hundreds of procedures needed to bring this procedure successfully into the mainstream of clinical endodontics, as well as establishing university-based research projects to bring GES into peer-reviewed literature.

At this point, Dr Buchanan says: "The iterative design process will take this from a fascinating but slow way to do endodontic surgery, to an elegant procedure that is much faster, much more precise, and that requires less training than traditional methods."


The American Association of Endodontists welcomed about 4,000 people to its annual meeting in sunny San Diego. The focus of the meeting, which was expanded to four full days this year, was *Acess to Apex, Education and Care*, and offered endodontic specialists 232 CE hours in 120 courses. In addition to the vast learning and educational opportunities, dozens of exhibitors showcased the newest and most innovative endodontic products on the market. Next year's meeting will be held in San Antonio, Texas, from 13–16 April 2011. For more information, see the AAE Website at [www.aae.org](http://www.aae.org).

#### Reference

Pinsky H, Champlaboux G, Sarment D. Periapical surgery using CAD/CAM guidance: Preclinical results. *Journal of Endodontics*, 33/2 (2007), 148–151.



# FDI Annual World Dental Congress 2-5 September 2010 **Salvador da Bahia, Brazil**



[congress@fdiworldental.org](mailto:congress@fdiworldental.org)  
[www.fdiworldental.org](http://www.fdiworldental.org)

