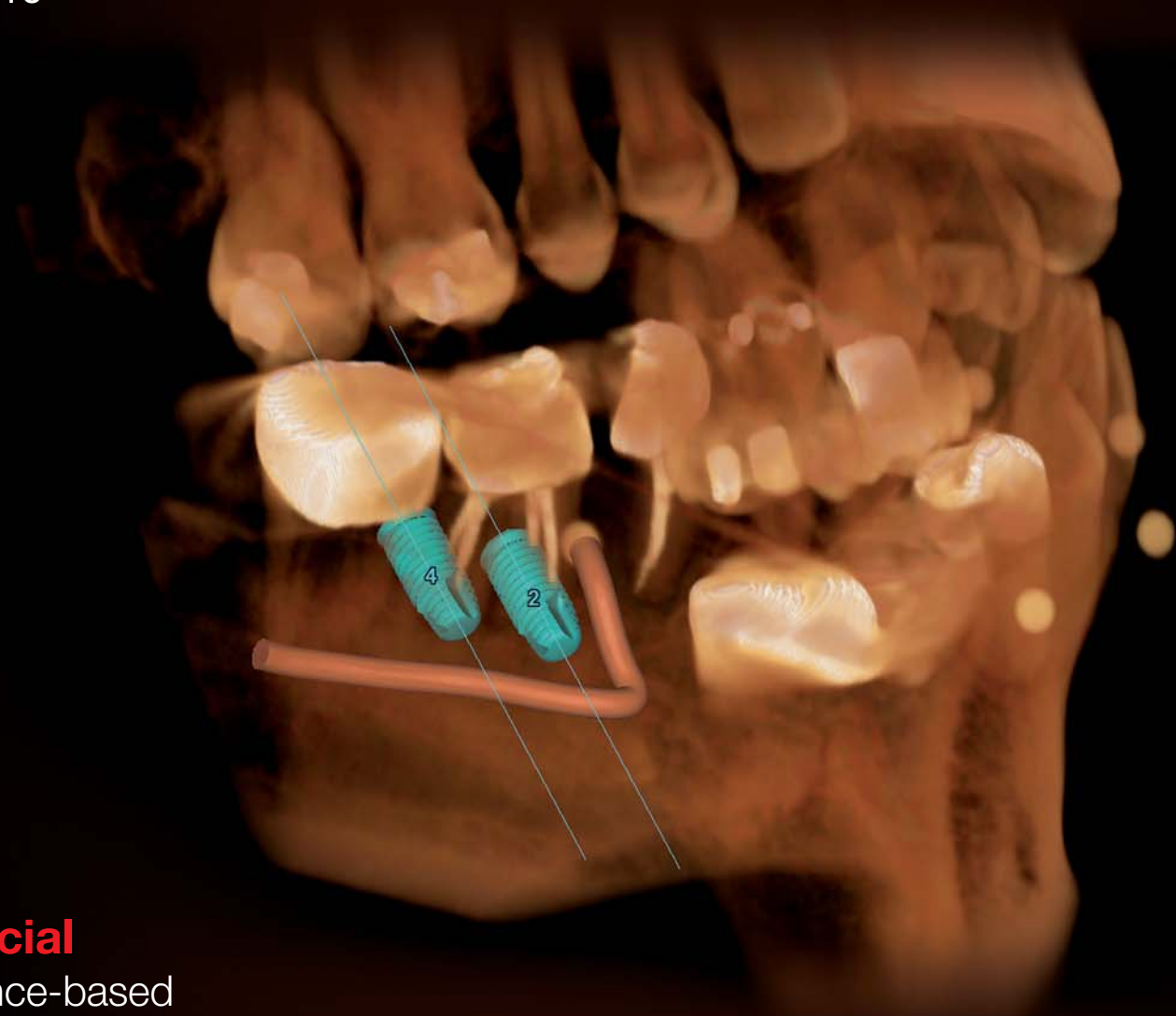


# roots

international magazine of endodontology

2<sup>2010</sup>



| **special**

Evidence-based  
endo-implant algorithm — Part II

| **clinical report**

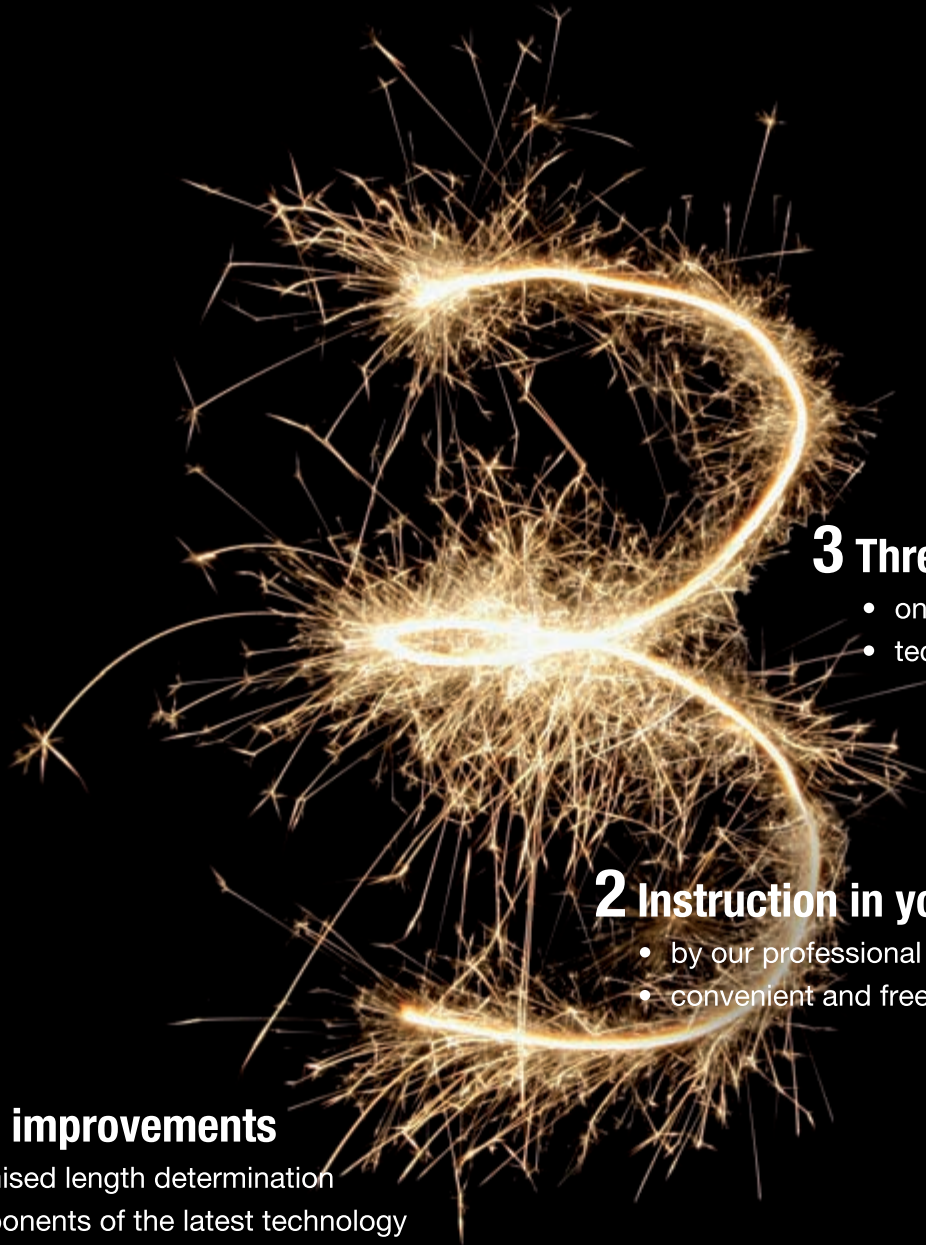Apical microsurgery — Part V

| **opinion**

Tactile perception in endodontics



# The New VDW.GOLD®



## 3 Three year warranty\*

- on new devices
- technical service within 3 days

## 2 Instruction in your office

- by our professional dental representatives
- convenient and free

## 1 Detail improvements

- optimised length determination
- components of the latest technology



## Celebrating 3 years with 3 advantages

3 years of VDW.GOLD®. Our tried and tested endo motor is going strong! With refined technology and focus on top service. Please contact us for further information.

\* Warranty conditions under [www.vdw-dental.com](http://www.vdw-dental.com)

**VDW GmbH**  
Bayerwaldstr. 15 • 81737 Munich • Germany  
Tel. +49 89 62734-0 • Fax +49 89 62734-304  
[www.vdw-dental.com](http://www.vdw-dental.com) • [info@vdw-dental.com](mailto:info@vdw-dental.com)

# VDW.GOLD®

2in1 endo motor with built-in apex locator



Endo Easy Efficient®

# Dear Reader,

**The cyclic rhythms associated with** advances in technology remain the same, regardless of their place in the timeline of human history. Everything from telescopes to teleporters has been received by apathetic acknowledgement or vitriolic condemnation. The message is don't trifle with status quo; and yet time waits for no one.

In a decade or so, there will be a constellation of satellites girdling the Earth that enable wireless communication to speed around the equator and from pole to pole. Holograms, not flat screens, will represent visual media. This construct will drive everything from entertainment to education. Dentistry will benefit from virtual reality learning and virtual on-demand education accessible from our cars, phones, computers and offices, and we will interface with them verbally and intuitively, and they will respond with artificial intelligence.

And yet...

The majority of dental education today comes from an archaic model, moving attendees to presenters, not presenters to attendees. The attendees are not well prepared; they know of the presenters perhaps, but not the presenters themselves, nor have they discoursed with them in person or online, nor for the most part do they know the evidentiary basis of the information they share, nor are they even aware of the style of their delivery, which can be equally as important in what we learn.

The Roots Summit began as means of altering this landscape. Twenty-four hours a day, seven days a week, dentists shared their hopes, dreams and most importantly knowledge and cases, and everyone learned. Once a year, they gathered to put a face to a name and determine their future path. As digital platforms exploded, Roots embraced them as well. Today, we have the Dental Tribune Study Club, Dental XP, glDE and others encouraging the industry and the profession to raise the bar and bring education to everyone, faster, more efficiently and without borders.

I look forward to seeing you all in Barcelona, another star on the horizon of where we are all headed together at last.

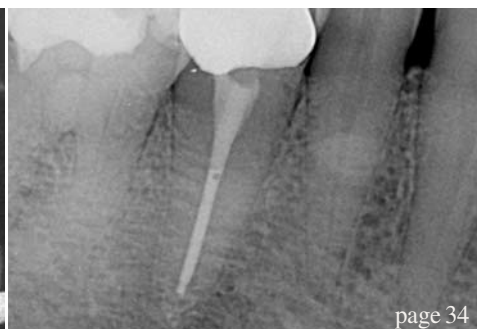
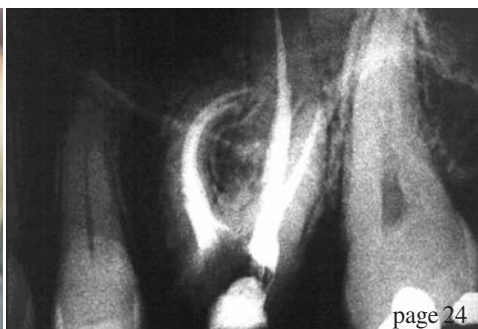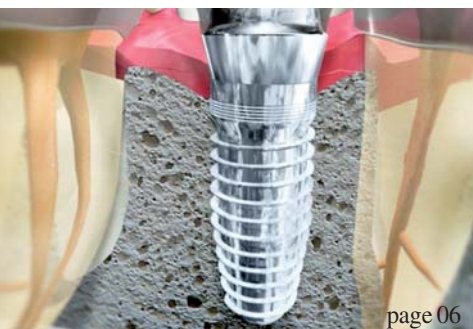
Sincerely yours,



Dr Kenneth Serota  
 Guest Editor  
 Endodontist  
 Mississauga, Ontario, Canada  
[www.endosolns.com](http://www.endosolns.com) | [www.rxroots.com](http://www.rxroots.com) | [www.ankylosworld.com](http://www.ankylosworld.com)



Dr Kenneth Serota  
 Guest Editor



| editorial

- 03 Dear **Reader**  
| Dr Kenneth Serota, Guest Editor

| special

- 06 **Back to the egg: An evidence-based endo-implant algorithm (Part II)**  
| Dr Kenneth Serota

| clinical report

- 18 **Apical microsurgery—Part V: REF materials and techniques**  
| Dr John J. Stropko

| opinion

- 24 **Tactile perception in endodontics**  
| Dr Barry Lee Musikant
- 28 **The GTX rotary system**  
| Dr Chris J. Lampert

| case report

- 30 **Peri-apical microsurgery for removal of a fractured endodontic instrument**  
| Dr Leandro A. P. Pereira
- 34 **Principles of diagnosis and treatment**  
| Dr Kendel Garretson

| feature

- 36 **Endodontics—Does the biology matter?**  
| Dr Alyn Morgan & Dr Ian Alexander

| industry news

- 40 **Excellent: Rebuilda Post System**  
| VOCO

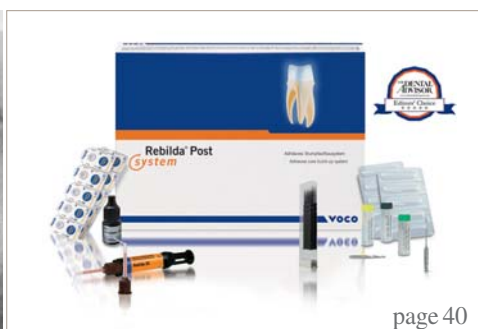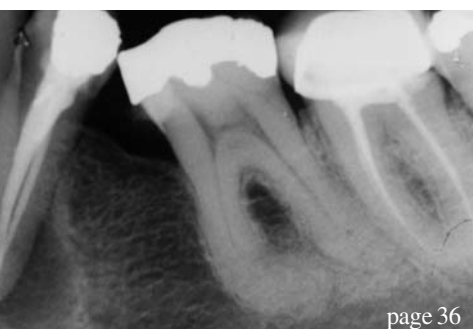| meetings

- 42 **Why worry now?**  
| Dr Philippe Van Audenhove
- 44 **AAE hosts first live CT-guided endodontic surgery**  
| Sierra Rendon
- 48 **International Events**

| about the publisher

- 49 | submission guidelines
- 50 | imprint

Cover image: CT-guided endodontic surgery, courtesy of Dr L. Stephen Buchanan.




# TOOLS TO KEEP SMILING

No less than ...  
...4 launches !


## D-RaCe

*Desobturation made easy*



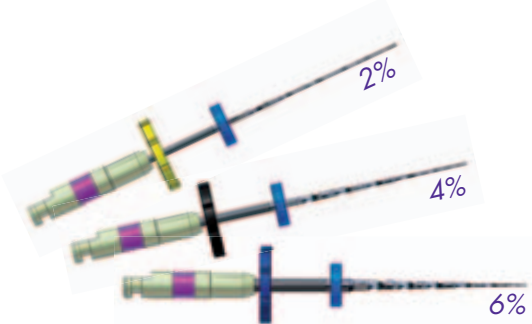
## Scout-RaCe

*Mechanical scouting sequence*




## FKG RaCe ISO 10

*Additional scouting files*



## SMG handle

*Indicator of uses*



[www.fkg.ch](http://www.fkg.ch)

**FKG**  
**FKG DENTAIRE**  
Swiss Dental Products



# Back to the egg: An evidence-based endo-implant algorithm (Part II)

Author\_ Dr Kenneth Serota, USA

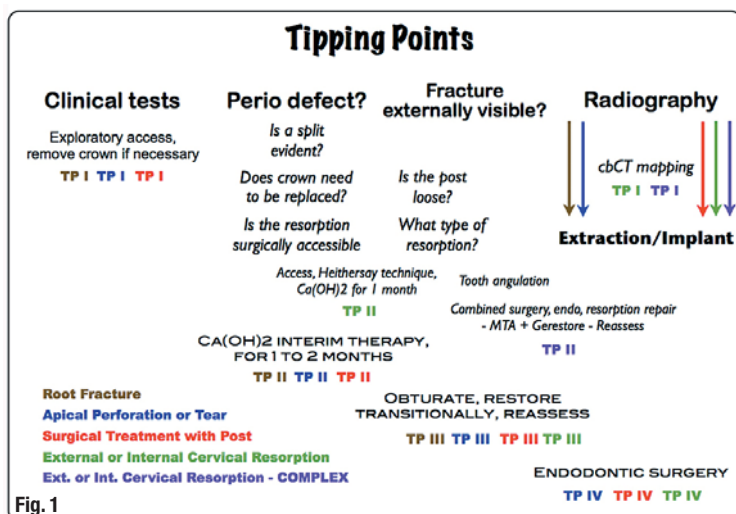


Fig. 1

Fig. 1\_ The term *tipping point* refers to the moment of critical mass, the threshold, the boiling point. The colour sequence highlights the diagnostic steps to be followed in each tipping-point algorithm for the listed pathological states.

*The laws of nature are but the mathematical thoughts of God.*

—Euclid of Alexandria

\_Four thousand years ago, a number of Babylonian legal decisions were compiled in what came to be known as the *Code of Hammurabi*. The decision with reference to the construction of dwellings and the responsibility for their safety begins: If a builder engineers a house for a man and does not make it firm, and the structure collapses and causes the death of the owner, the builder shall be put to death. We are all builders or engineers of sorts; we calculate the path of our arms and legs with the computer of our brain and we catch baseballs and footballs with greater dependability than the most advanced weapons system intercepts missiles. In our professional lives, however, in contradistinction to the paradigm of evidence-based dentistry, our efforts as builders often rely solely upon personal experience, intuitive cognition and anecdotal accounts of successful strategies.

Table I\_ As reported by Chugal *et al.*, the most significant vector relevant to post-op healing is the presence and magnitude of pre-op apical periodontitis.<sup>17</sup>

The challenges posed by implant-driven treatment planning mandate vigilance of the interaction between those involved in research and development, manufacturing and distribution and the leaders of ideologically diverse disciplines. Temporal shifts and trends in the service mix are part of the evolution of the art and science of dentistry; to some degree, the implant-driven vector has captured the hearts and minds of those who seek to nullify preservation of natural tooth structure in the oral ecosystem and deify ortho-biological replacement. The corporate entities from which we derive our tools too often fail to distinguish the point at which science ends and policy begins.

By positioning advocates and acolytes at the vanguard of their marketing campaigns, they effect change; however, their support for education is directed towards dissemination of product, not the fundamentals and rudiments of biological imperatives. Prospective large cohort clinical trials with clearly defined criteria for survival, with and without intervention, quality of life information and economic outcomes are essential to comparing alternative foundational treatments. These studies will require expertise, time and financial support from the various stakeholders, professional and corporate alike.<sup>1</sup>

*The authority of those who teach is often an obstacle to those who want to learn.*

—Marcus Tullius Cicero

| Size in mm | Success in % |
|------------|--------------|
| 0          | 87.6         |
| 1-5        | 65.7         |
| >5         | 56.2         |

Table I

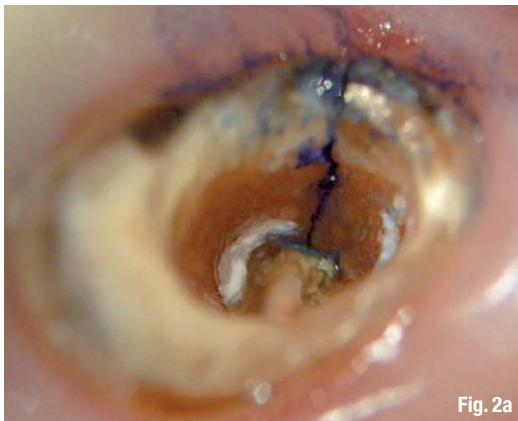


Fig. 2a

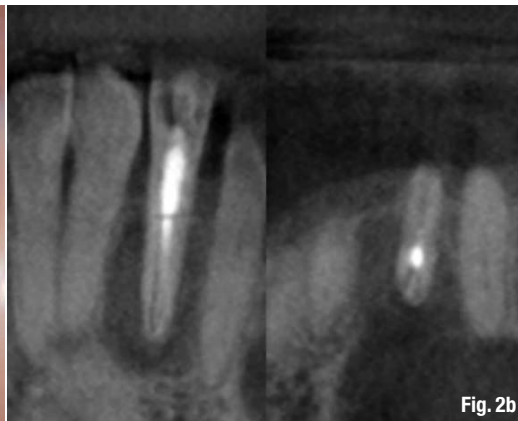


Fig. 2b

**Fig. 2a** The use of dyes, colouring agents and micro-etching is invaluable in visualising a suspected crack in tooth structure. Cohen *et al.* found that when premolars were used as bridge abutments, a surprising number of these abutments sustained a VRF.<sup>61</sup>

**Fig. 2b** The dental literature reports a statistically higher level of accuracy using CBCT (cone-beam computed tomography) scans for detecting VRF than with the use of peri-apical radiography alone.

The prosthodontic pundits maintain that the spiralling costs of saving endodontically **retreated** teeth, for which extraction may well prove to be the common endpoint, bring into question whether such teeth should be sacrificed early. Ruskin *et al.* concluded that implants have greater success than endodontic therapy, are more predictable, and cost less when one considers the 'inevitable' failure of initial root-canal treatment, retreatment and peri-apical surgery.<sup>2</sup> Is it responsible therapeutics or irresponsible expediency that justifies the removal and restoration of such teeth from the outset with an implant-supported restoration? Can one ethically argue that extraction is warranted because the financial cost of orthodontic extrusion/soft-tissue surgery, endodontic retreatment and post/core/crown fabrication is greater than extraction with an implant-buttressed restoration, and in all likelihood, more predictable?<sup>3</sup>

Jokstad *et al.*<sup>4</sup> identified over 220 implant brands in the dental marketplace. With variability in surface, shape, length, width and form, there are potentially more than 2000 implants for any given treatment situation. A systematic review by Berglundh *et al.*<sup>5</sup> assessed the reporting of biological and technical complications in prospective implant studies. Their findings indicated that while implant survival and loss were reported in all studies, biological difficulties, such as sensory disturbance, soft-tissue complications, peri-implantitis/mucositis and crestal bone loss, were considered in only 40 to 60% of studies. Technical complications such as component/connection and superstructure failure were addressed in only 60 to 80% of the studies. Are we as a profession standing idly by and watching marketing pressures force treatment decisions to be made empirically, with untested materials and techniques? There is an unsettling similarity between these events and the early days of implant development.<sup>6</sup>

The endodontic pundits argue that major studies published to date suggest there is no difference in long-term prognosis between single-tooth implants and

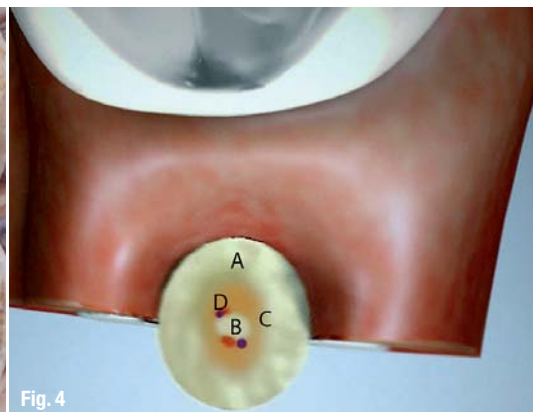
restored root-canal treated teeth. In fact, regardless of the similarity of treatment outcomes, the preponderance of post-treatment complications favours endodontic therapy. Therefore, the decision to treat a tooth endodontically or to place a single-tooth implant should be based on criteria such as restorability of the tooth, quality and quantity of bone, aesthetic demands, cost-benefit ratio, systemic factors, potential for adverse effects and patient preferences.<sup>7-11</sup> A review of endodontic treatment outcomes by Friedman and Mor<sup>12</sup> used radiographic absence of disease and clinical absence of signs and symptoms as the defining parameters for success. They suggested that the chance of having a tooth extracted after failure from initial endodontic treatment, retreatment and apical surgery collectively would be roughly 1 in 500 cases.

The dialogue comparing endodontic treatment to implant therapy jarringly overlooks the crucial fact that it is often the calibre of the restoration and its prognosis, and not the endodontic prognosis *per se*, that is the determinant of the treatment outcome. The primary biological mandate of any dental procedure is the retention of the orofacial ecosystem in a disease-free state. Surgical and non-surgical endodontic therapies

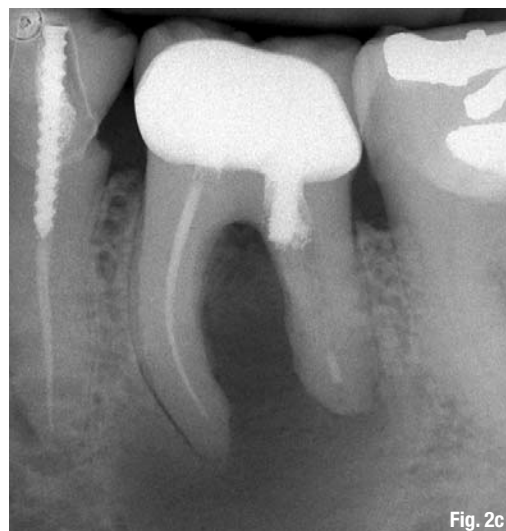

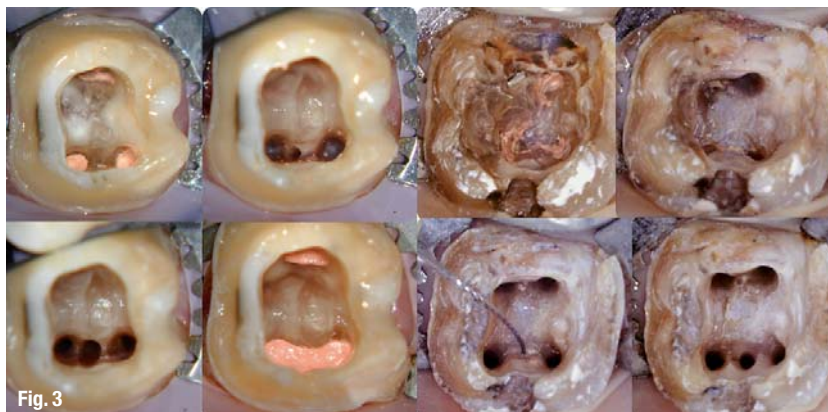Fig. 2c

**Fig. 2c** The multivariate nature of the endo-implant algorithm mandates the use of CBCT to detect and evaluate the degree of peri-apical pathosis. Analysis of the size, extent, nature and position of peri-apical and resorptive lesions in three dimensions is essential for the optimal level of standard of care in diagnosis.



**Fig. 3** Two different retreated teeth; two different potential treatment outcomes. The root-canal system of both teeth has been re-engineered in its anatomic entirety; however, the treatment outcome after restoration for both is unlikely to be the same. Regenerative technologies incorporating mesenchymal stem cells derived from dental tissues may one day obviate the concern.

**Fig. 4** Less porous, less hydrated and highly mineralised outer dentine (a); pulp canal space (b); more porous, more hydrated and less mineralised inner dentine (c); water in the dentinal tubules and pulp space is held in a confined environment under hydrostatic pressure (d).

have historically been key modalities in the attainment of this foundational goal. Friedman noted that "the patient weighing one 'success' rate against the other may erroneously assume their definitions to be comparable and select the treatment alternative that appears to be offering the better chance of 'success.'"<sup>13</sup> The conundrum with which researchers and clinicians alike wrestle increasingly includes the non-science of emotion as well.

This publication will address non-surgical and/or surgical resolution of failing primary endodontic treatment outcomes and the historical and ongoing efforts of the dental industry to engineer the biomimetic replacement of natural teeth successfully and replicate the structural predicates that comprise the substitution algorithm of bone, soft tissue and tooth. There are many levels to the accrual of 'best evidence dentistry'. The purpose of this paper is to ensure that all variables in the treatment planning equation of foundational dentistry are understood and given equal weight in the decision-making process for comprehensive care.

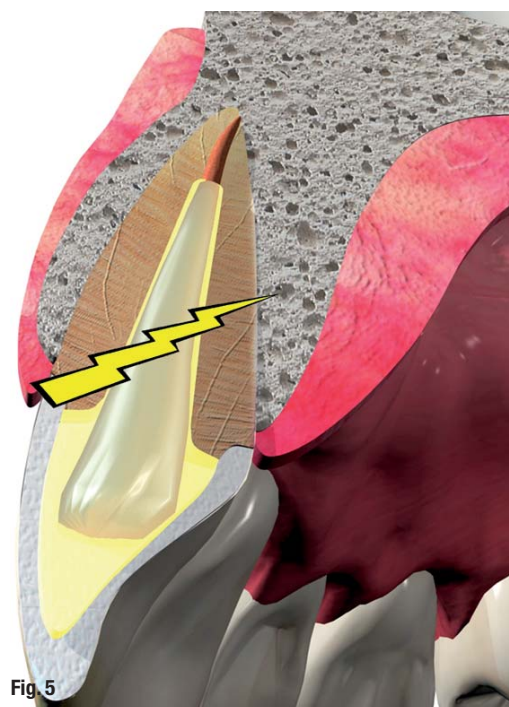
Whenever possible, the treatment choice should be an attempt to salvage a tooth using a multidisciplinary team approach, putting aside preconceived notions and biases. Finances should not dictate the advice proffered. Furthermore, it is advisable to forego being clinically 'conservative'. Treatment should not be initiated in the absence of a critical evaluation of the potential for all contributing factors to equate to a positive outcome. When needed, care must be taken to carry out every diagnostic procedure available, even those of a more invasive nature (Fig. 1). Before arriving at a definitive diagnosis and treatment plan, the clinician should obtain consent from the patient to remove any restoration in order to analyse the residual tooth structure and assess the potential to carry out reliably predictable treatment. The patient must understand in detail, the feasibility of and margin for success of each treatment option presented.<sup>14</sup>

There are few studies in the endodontic literature analysing the reasons for extraction of endodontically

treated teeth. Root-filled teeth are invariably prone to extraction due to non-restorable carious destruction and fracture of unprotected cusps. Tamse *et al.* found that mandibular first molars were extracted with greater frequency than maxillary first molars; the most significant causal difference was the incidence of vertical root fracture (VRF—1.8% maxillary molar, 9.8% mandibular molar).<sup>15</sup> Teeth **not** crowned after obturation are lost with six times the frequency of those restored with full coverage restorations.<sup>16</sup>

Procedural failure, iatrogenic perforation or stripping, idiopathic resorption, trauma and periodontal disease all contribute to a lesser degree. The major biological factor that influences endodontic treatment outcome failure with the possibility of extraction appears to be the extent of microbiological insult to the pulp and peri-apical tissue, as reflected by the peri-apical diagnosis and the magnitude of peri-apical pathosis (Table I and Figs. 2a–c).<sup>17</sup>

**Fig. 5** Primary causes of fracture include excessive structure loss, loss of free unbound water from the root-canal lumen and dentinal tubules, age-induced changes in the dentine and restorations and restorative procedures. Secondary causes of fracture include the effects of endodontic irrigants and medicaments on dentine, the effects of bacterial interaction with dentine substrate and bio-corrosion of metallic post-cores.

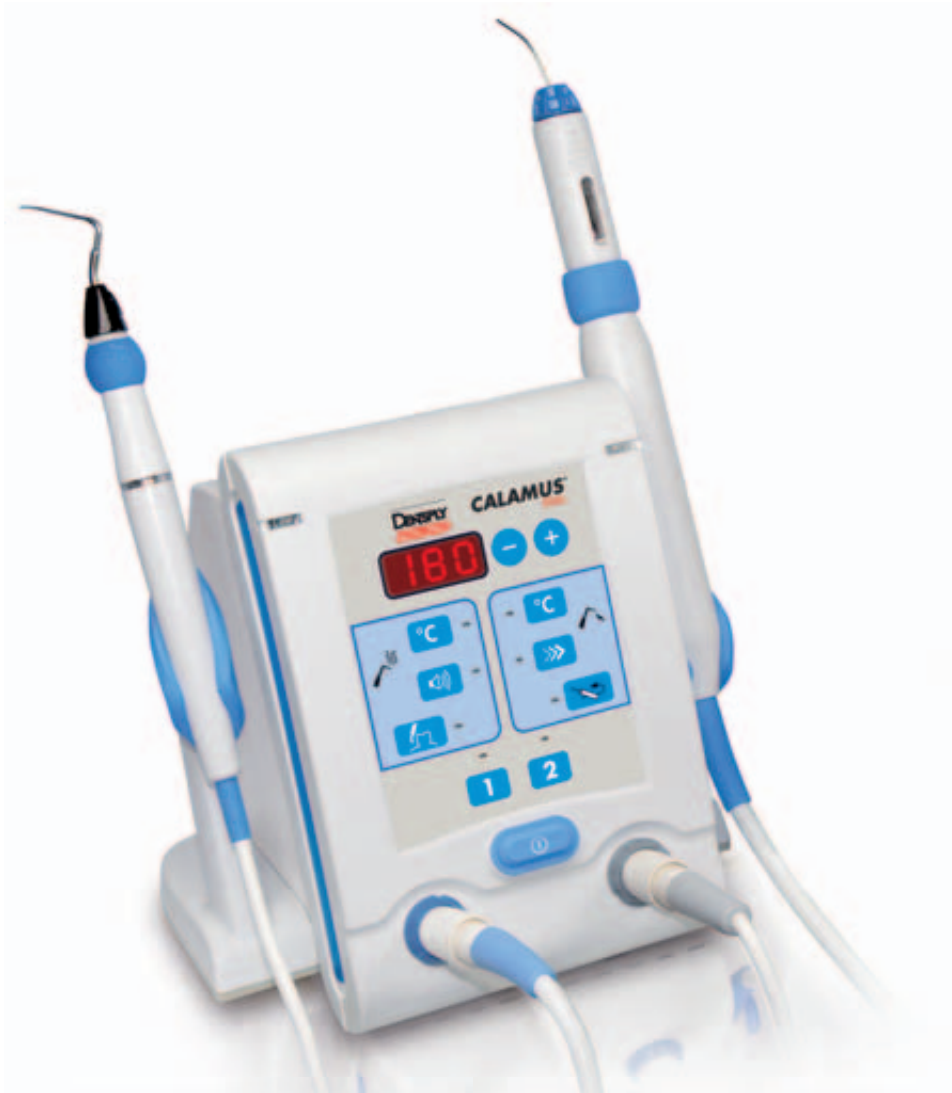



# CALAMUS<sup>®</sup> DUAL

DOWNPACK & BACKFILL

FAST AND TIGHTLY SEALED ROOT CANAL FILLINGS



## TIME-SAVING AND LONG-LASTING 3D OBTURATION OF ROOT CANALS

Filling was never so easy!

- Obturation device for downpack and backfill

Device designed for your comfort

- Ergonomically designed handpieces with large operation angle and feather-touch activation by flexible silicone ring

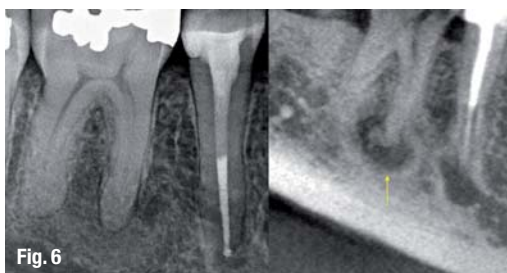Lateral or vertical obturation? Better results with Calamus<sup>®</sup>

- Vertical condensation is a faster method to achieve a long-lasting, tightly sealed, three dimensional root canal filling
- Reliable obturation of lateral canals as well as minimal risk of root fractures

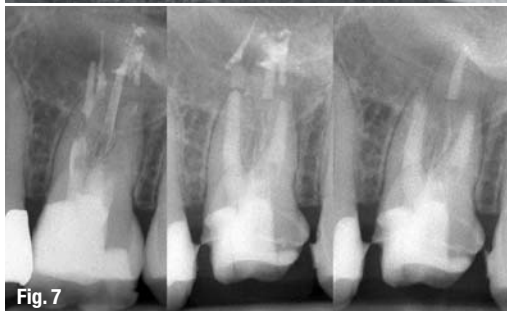**DENTSPLY**  
**MAILLEFER**

[www.dentsplymaillefer.com](http://www.dentsplymaillefer.com)

**Fig. 6** Flat field peri-apical radiograph (left); small focal field CBCT (right; Kodak 90003D, Kodak Dental Systems). The differential in visualisation of peri-apical pathology from a 3-D to a 2-D image is as much as 2:1.<sup>62</sup>



**Fig. 7** The initial endodontic treatment procedure was inadequate and failing. Re-engineering (inclusive of interim calcium hydroxide therapy) ensured optimal eradication of microflora from the root-canal space, and the obturation produced definitive closure of the apical termini. Surgery was performed to redress persistent symptoms.



Dentine is the most abundant mineralised tissue in the human tooth. In spite of this importance, over half a century of research has failed to provide consistent values of dentine's mechanical properties. In clinical dentistry, knowledge of these properties is pivotal to any number of variables, ranging from innovations in preparation design to the choice of bonding materials and methods. The Young's modulus (the measure of the stiffness of an isotropic elastic material) and the shear modulus (modulus of rigidity) are diminished by viscoelastic behaviour (time-dependent stress relaxation) at strain rates of physiological (functional) relevance. The reported tensile strength data suggests that failure initiates at flaws. These flaws may be intrinsic, perhaps regions of altered mineralisation, or extrinsic, caused by cavity or post-channel preparation, wear, or damage. There have been few studies of fracture toughness or fatigue.<sup>18</sup> Finally, little is known about the biomechanical properties of altered forms of dentine subsequent to decay, the influence of irrigants and chemicals, and the choice of curing techniques used for bonded restorations.<sup>19</sup>

Studies suggest that there are at least two forms of transparent or sclerotic dentine: a form associated with caries and a form associated with age-related changes in the root. The impact upon tooth strength as a function of these altered forms of dentine is not well understood. The long-term predictability of residual coronal tooth structure to function in a manner commensurate with the demands of the orofacial ecosystem may need to be reassessed in light of observations that sclerotic dentine, unlike normal dentine, does not exhibit yielding before failure and that the fatigue lifetime is deleteriously affected at high stress levels.<sup>20</sup> Mechanisms for energy dissipation and crack growth resistance present in young dentine are not present in old dentine. Restorative methods and techniques,

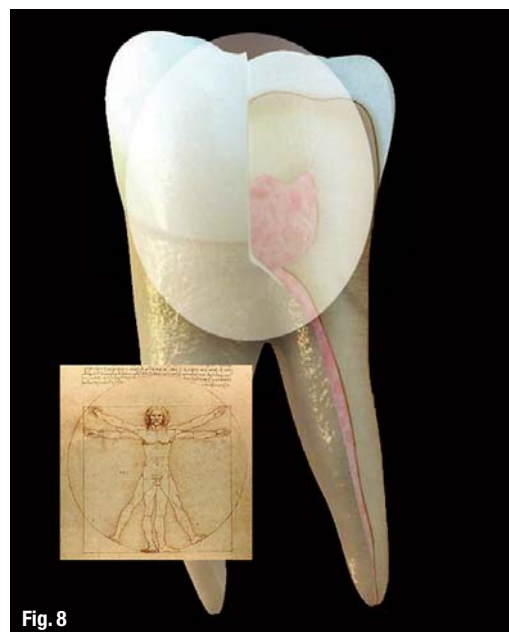
particularly regarding ferrule creation for endodontically treated teeth, may need to be amplified to address the fact that fatigue crack growth resistance of dentine decreases with age (Fig. 3).<sup>21</sup>

Understanding the mechanical properties of teeth is essential in order to address the most common clinical problem affecting all endodontically treated teeth, fracturing, which in spite of even minimal loss of tooth structure may be severe enough to necessitate removal.<sup>22-24</sup> The hypothesis that dentine brittleness increases with diminished moisture content has been debunked; conserving bulk dentine is the *sine qua non* of fracture prevention. Kuttler *et al.* reported that dentine thickness correlates inversely to post-space diameter in the distal roots of mandibular molars.<sup>25</sup> A size #4 Gates-Glidden drill caused strip perforations in 7.3% of canals studied. The authors recommend that Gates-Glidden drills no larger than a size #3 be used. After endodontic treatment, dentine thickness on the furcation side was less than 1 mm in 82% of the distal roots studied (Fig. 4).

There are primary causes that predispose teeth to fracturing and secondary causes that predispose teeth to fracturing after a period of time (Fig. 5). Endodontics is a component of an interdisciplinary process and a chain is only as strong as its weakest link. Subsequent to any endodontic procedure, intensity of stress concentration and tensile stresses within an endodontically treated tooth will depend upon:

- 1) the material properties of the crown, post, and core material chosen;
- 2) the shape of the post;
- 3) the adhesive strength at the crown-tooth, core-tooth, core-post, and post-tooth interfaces;

**Fig. 8** The strength of the egg-like coronal structure of a tooth can support substantial occlusal stress and force; however, disrupting the integrity of the 'dome' or roof of the pulp chamber with an access preparation will invariably lead to a statistically significant degree of fracturing after endodontic therapy.<sup>16</sup>



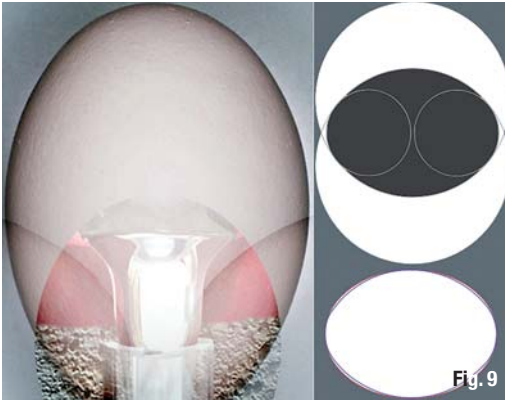


Fig. 9

- 4) the magnitude and direction of occlusal loads;
- 5) the amount of available tooth structure; and
- 6) the anatomy of the tooth.

Any combination of vectored stress concentration and high tensile stresses will predispose these teeth to fracturing without an adequately engineered restorative design.

### Re-engineering

Re-engineering negative treatment outcomes is a significant part of the contemporary endodontic oeuvre. The presence of apical periodontitis may affect the outcome of initial endodontic treatment;<sup>26</sup> however, there is general consensus that apical periodontitis is the most important variable that influences a positive outcome with non-surgical and surgical retreatment.<sup>27-29</sup> Positive treatment outcomes may be more likely in certain teeth with a combination of both procedures, rather than with one or the other alone (Fig. 6).

The premise that non-surgical retreatment improves the outcome of peri-apical surgery has been supported by both historical and current studies.<sup>30-32</sup> Apical surgical 'correction' of intra-canal infections may isolate, but not eliminate, the residual microflora of the root-canal space. It should therefore be limited to situations in which non-surgical retreatment is judged impractical. With the range of sophisticated equipment and material in the conventional endodontic armamentarium, this is a remote consideration at best. When the aetiology is independent of the root-canal system, surgery is the most beneficial treatment.<sup>33</sup> Non-surgical retreatment may still be indicated in these cases, especially when intra-canal infection cannot be ruled out. Time constraints or financial pressures should never be a factor in making surgery the first treatment choice (Fig. 7).

There are a myriad of variables associated with non-surgical retreatment, and treatment outcome studies in endodontics have been egregiously abused by those

wishing to diminish the value of re-engineering natural teeth. Many studies have categorised teeth with caries, fractures, periodontal involvement and poor coronal restorations as negative endodontic outcomes.<sup>34,35</sup>

Prior procedural errors,<sup>36</sup> occlusal considerations,<sup>37</sup> material choice for the restoration<sup>38</sup> and design of the full coverage component all suggest that success is a function of comprehensive treatment planning as much as technical expertise. Evidence-based or controlled best evidence studies should conclude that these are non-endodontic causes of failure and that the success of endodontic treatment itself is high and predictable.

Kvist and Reit<sup>39</sup> have shown that while surgical cases demonstrated higher healing rates than non-surgical retreatment cases initially, four years after treatment there was no difference between the two modalities, owing to 'late' surgical failure. The failure rate for surgical therapy appears to be analogous to the failure rate for retreatment as a function of the size of the lesion treated.<sup>40</sup> Levels of apical resection<sup>41</sup> and the type of root-end filling material make a difference to surgical treatment outcome success;<sup>42</sup> however, the dentine-bonded composite technique and the use of compomer materials has not been widely reported on. As these techniques dome the resected root face, sealing off the cut tubules, they may prove to be the

**Fig. 9** An arch eliminates tensile stresses in spanning an open space, as all forces are resolved into compressive stresses. It requires all of its elements to hold it together, thus making it self-supporting. The incorporation of platform switching into the design of an implant abutment simulates three oblate spheroid shapes—one vertical, two horizontal. The objective is to ensure that axially vectored compressive stresses are contained within an idealised shape that is structurally enhanced by the use of a precise friction-fit connection.

**Fig. 10a** Foundational dentistry mandates that the impact of an ortho-biological replacement unit be commensurate with the biological objectives and functional requirements of the natural tooth.

**Fig. 10b** As the number of implant-supported single-tooth replacements increases, implant-abutment connection design should ensure that occlusal table replication displays equivalency in both dimension and cuspal inclination with the surrounding natural dentition.

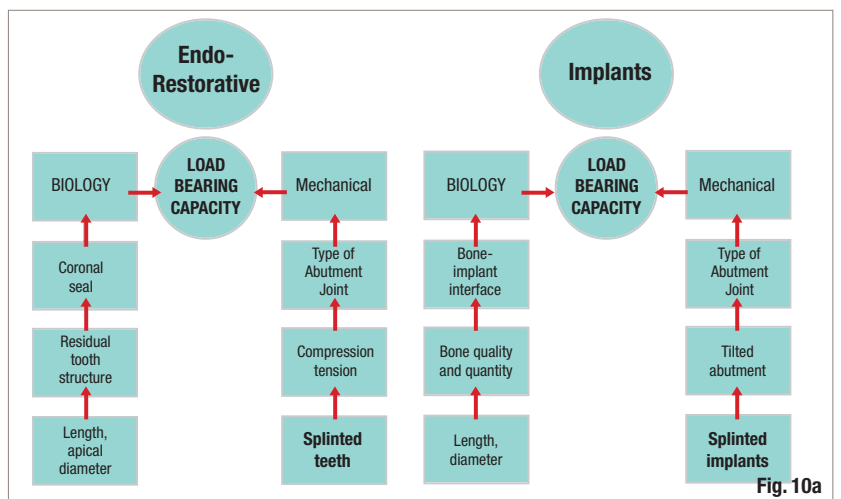


Fig. 10a

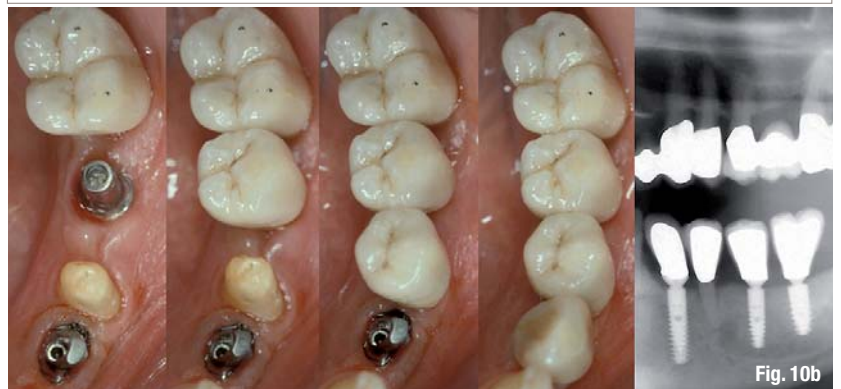

Fig. 10b

most effective retrograde surgical protocols of all. The literature is unclear concerning peri-apical re-surgery.

Gagliani *et al.*<sup>43</sup> compared peri-apical surgery and re-surgery over a five-year follow-up period. Using magnification and microsurgical root-end preparations, the positive outcome for primary surgery was 86% and 59% for re-surgery. While others have shown positive outcomes for re-surgery, the decision remains highly case specific. In spite of our best efforts, negative endodontic treatment outcomes occur and ortho-biological replacement of teeth and their surrounding anchoring structures is an integral part of contemporary foundational treatment planning.

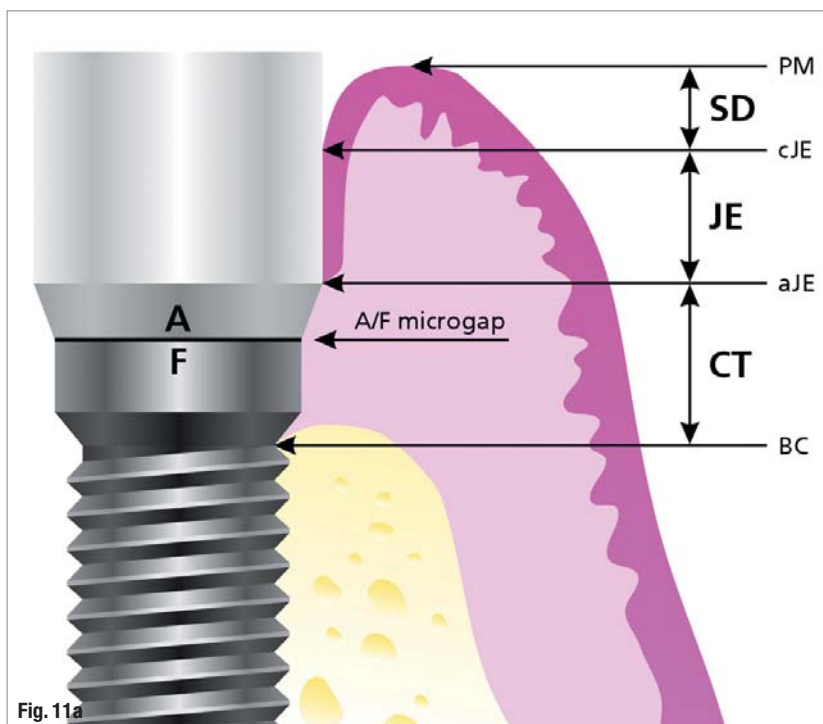


Fig. 11a

**Fig. 11a**—The composition of biological width around implants: sulcus depth (SD), distance from peri-implant mucosal margin (PM) to the most coronal point of junctional epithelium (cJE); junctional epithelium (JE), distance from cJE to most apical point of the junctional epithelium (aJE); connective tissue zone (CT), distance from aJE to the first bone to implant contact (BC).<sup>63</sup>

A recent article by Assuncao *et al.*<sup>44</sup> describes engineering methods used in dentistry to evaluate the biomechanical behaviour of osseointegrated implants. Photoelasticity is used for determining stress-concentration factors in irregular geometries. The application of strain-gauge methodology to dental implants provides both *in vitro* and *in vivo* measurement strains under static and dynamic loads. Finite element analysis can simulate stress using a **computer-generated model** to calculate stress, strain, and displacement. An analysis of the impact of mechanical/technical risk factors on implant-supported reconstructions is beyond the scope of this publication; however, the replacement of lost teeth by implants should, without exemption, provide a feeling of *restitutio ad integrum*. The means by which the restoration of the original condition at the crown-root interface is idealised is detailed in this article.

*The structure and composition of teeth is perfectly adapted to the functional demands of the mouth, and are superior in comparison to any artificial material. So first of all, do no harm.*

—Anonymous

## Back to the egg

An increased uniform amount of coronal dentine significantly amplifies the fracture resistance of endodontically treated teeth regardless of the post system used or the choice of material for the full coverage restoration.<sup>45</sup> A recent article by Coppede *et al.* demonstrated that friction-locking mechanics and the solid design of internal conical abutments provided greater resistance to deformation and fracture under oblique compressive loading when compared to internal hex abutments.<sup>46</sup> These two 'seemingly' disparate observations define the inherent continuum between natural tooth engineering and the principles of engineering necessary to ortho-biologically replicating the native state.

The use of a ferrule or collet and a bonded or intimately fitted post-core to restore function and form to an endodontically treated tooth is analogous to the use of a long, tapered friction-fit interface with a retaining screw (Morse taper) to secure an abutment to a fixture. In both cases, the role of contact pressure between mating surfaces in generating frictional resistance provides a locked connection. This has been shown to effect long-term stability of crestal bone support for the overlying gingival tissues and maintain a healthy protective and aesthetic periodontal attachment apparatus.<sup>47</sup>

The Roman architect Vitruvius' (Marcus Vitruvius Pollio) description of the perfect human form in geometrical terms was a source of inspiration for Leonardo da Vinci, who successfully illustrated the proportions outlined in Vitruvius' work *De Architectura*. The result, the Vitruvian man, is one of the most recognised drawings in the world and is accepted as the standard of human physical beauty. Vitruvius theorised that the essential symmetry of the human body with arms and legs extended should fit into the perfect geometric forms: the circle and the square. Da Vinci recognised that the circle and the square are only tangent at one place, the base. Observe the insert in Figure 8. The stabilising platform for the human form outlined begins at that tangent; the intersection is graphically analogous to the structural configuration of platform switching.

The relative simplicity of this construct reinforces the obvious. When we compare design in living things to the artificial designs they inspire, a striking parallel emerges. Almost all the products of man's technology



# With an extra small head



Endea contra-angle handpieces. The new standard in mechanical endodontics. With their new and extra small heads Endea NiTi contra-angle handpieces provide even better access to the treatment area. For the best results in the shortest amount of time.

People have Priority! W&H supports the humanitarian organization SOS Children's Villages. Get involved! Further information at [wh.com](http://wh.com)

endea

Systematic endodontics

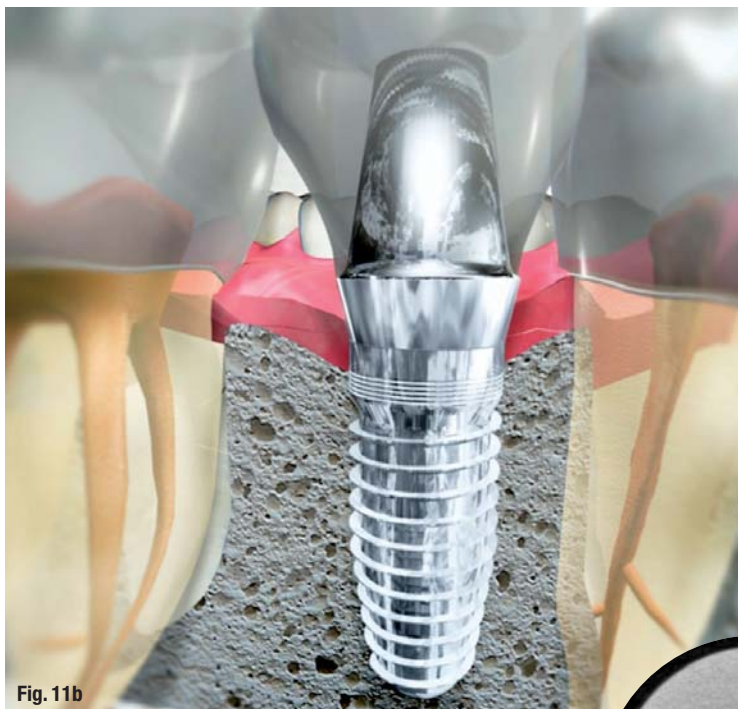


Fig. 11b

**Fig. 11b** When a matching implant-abutment diameter is used, the inflammatory cell infiltrate is located at the outer edge of the implant-abutment junction close to crestal bone; this close proximity may explain in part, the biological and radiographical observations of crestal bone loss or saucerisation around restored implants. This is not peri-implantitis or mucositis; however, any area of bacterial accumulation and stasis, inaccessible to normal hygiene protocols, is a risk factor for exacerbation.

**Fig. 11c** The Morse taper connection of the Ankylos C/X (internal index) fixture distributes oblique and horizontally applied forces over a large area of the matrix joining surface inside the implant. The connection is therefore only loaded in the vertical direction. The cross-section shows no gap between the abutment taper and the implant which avoids micro-loosening. This is in contrast to systems with internal hex connections (clearance fit) that demonstrate micro-motion and 'rotational slop', making them prone to inflammatory reactions at the implant-abutment connection due to micro-leakage.

are no more than imitations of those in nature and usually, they fail to match the superior design in living things. Consider the engineering perfection that is the egg. Its strength lies in its oblate spheroid shape. A blow to the side of an egg from a sharp object places pressure along the thin shell and breaks it easily. However; if the egg is squeezed directly on its poles, the vectored pressure is compressed along the surface structure, not across the shell; the egg cannot be broken without extraordinary force. However, if a pinhole is created in one of the poles disrupting the integrity of the structure, the pressure will readily break the egg, commensurate with a sharp blow to the side.

In geometry, an oval is a curve that resembles an egg or an ellipse. Architects and engineers have used smooth ovate curves to support the weight of structures over an open space literally since the second millennium BC. These arches, vaults and domes can be seen in buildings and bridges all over the world; the most pervasive example is the keystone arch used by the Romans for aqueducts and mills.

An arch directs pressure along its form so that it compresses the building material from which it is constructed. Even a concrete block is readily broken if one hits it on the side with a sledge. But under compression forces from above, the block is incredibly strong and unyielding. Many will remember the weight-bearing

tripod experiments from grade school in which an egg acts as one of three supporting legs of a square section of wood that bears books as the load. The structure could support over sixty books, almost twenty pounds (9 kilograms), before breaking the supporting egg. One need only look at the root trunk and coronal tooth structure of a multi-rooted teeth and it becomes apparent that strength of the tooth form is dependent upon an arch form for its integrity (Figs. 8 & 9).

Is it possible for this natural feat of engineering to be biomimetically replicated to the design parameters of osseointegrated implants? There are a number of paradigms that continue to fuel debate in the dental clinical and scientific communities that pertain to the optimal engineering predicates for implant design. These include smooth versus rough surfaces, submerged versus non-submerged installation techniques, mixed tooth-implant versus solely implant-supported reconstructions, Morse taper abutment fixation versus a butt-joint interface, and titanium abutments versus aesthetic abutments in clinical situations in which aesthetics are of primary concern.

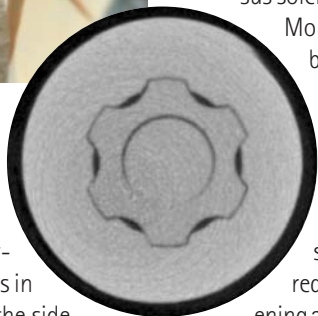



Fig. 11c



The cone-screw abutment has been shown to diminish micro-movement by reducing the burden of component loosening and fracture. This enables the identification of the effects of the parameters such as friction, geometric properties of the screw, the taper angle and the elastic properties of the materials on the mechanics of the system. In particular, a relation between the tightening torque and the screw pre-tension is identified. It was shown that the loosening torque is smaller than the tightening torque for typical values of the parameters. Most of the tightening load is carried by the tapered section of the abutment, and in certain combinations of the parameters the pre-tension in the screw may be reduced to zero. This tapered abutment connection provides high resistance to bending and rotational torque during clinical function, which significantly reduces the possibilities of screw fracture or loosening.

### Biomechanics

*The seed of a tree has the nature of a branch or twig or bud. It is a part of the tree, but if separated and set in the earth to be better nourished, the embryo or young tree contained in it takes root and grows into a new tree.*  
—Isaac Newton

Pressure on the cervical cortical plate, micro-movement of the fixture-abutment interface (FAI), and

microflora leakage and colonisation at and within the FAI are some of the pathological vectors associated with osseous remodelling, both crestal and peripheral to dental implants.<sup>48</sup> Occlusal considerations engineered into fixture design should enable optimum load distribution for permanent load stability during functional loading, reduce functional stress transfer to the interfacial tissues, and enhance the biological reaction of interfacial tissues to occlusally generated stress transfer conditions.<sup>49</sup> Future modifications to implant biomechanics should focus on designs wherein the osseous trabecular framework that retains the fixture will adapt to the amount and direction of applied mechanical forces, cope with off-axis loading, compensate for differences in occlusal plane to implant height ratios, as well as adjust to mandibular flexion and torsion.<sup>50</sup> In this new era of implant-driven treatment planning, fixtures should be engineered to support single crowns with cantilevers instead of implant-implant or implant-teeth connections for a span of any degree. These engineering design iterations will minimise high-stress torque load at the implant-abutment interface and obviate areas with degrees of bone insufficiency. The goal should be to biomimetically replicate the natural state to the greatest degree with regard to load bearing capacity (Figs. 10a & b).

Stable crestal bone levels are the yardstick by which treatment success and health are measured in the orofacial ecosystem, whether success and health relate to natural tooth retention or restorative and/or replacement rehabilitation. It is therefore surprising that the treatment outcome standards for osseointegration accept crestal bone remodelling and resorption of up to 1.5 to 2 mm in the first year following fixture placement and prosthetic insertion.<sup>51</sup>

The concept of *biological width* outlines the *minimum* soft-tissue dimension that is physiologically necessary to protect and separate the osseous crest from a healthy gingival margin surrounding teeth and the peri-implant environment. A bacteria-proof seal, the lack of micro-movement associated with a friction grip interface and a minimally invasive second-stage surgery (where indicated) without any major trauma to the periosteal tissues are also important factors in preventing cervical bone loss. The literature suggests that the stability of the implant-abutment interface may have an important initial role to play in determining crestal bone levels.<sup>52</sup> Tarnow's seminal study on crestal bone height support for the interdental papillae clearly demonstrated the influence of the bony crest on the presence or absence of papillae between implants and adjacent teeth.<sup>53</sup> Twenty years later, logic dictates that anticipated early crestal bone loss and diminished, albeit continual, loss in successive years of function ought to have been engineered out of the substitution algorithm for peri-implant tissues.<sup>54</sup>

## Platform switching: By default or by design

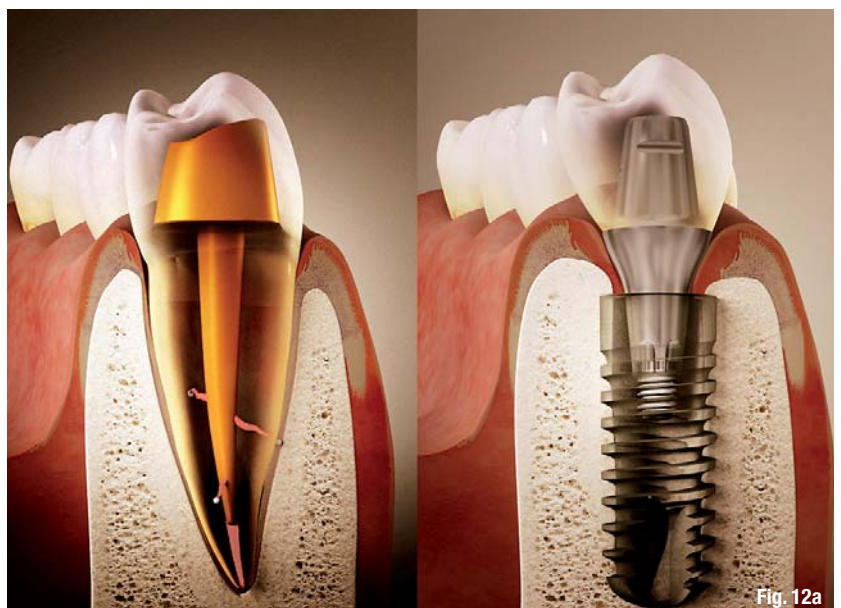*There is no logical way to the discovery of elemental laws. There is only the way of intuition, which is helped by a feeling for the order lying behind the appearance.*

—Albert Einstein

Platform switching theorises that by using an abutment diameter of a lesser dimension than the periphery of the implant fixture, horizontal relocation of the implant-abutment connection will reduce remodelling and resorption of crestal bone after insertion and loading. The concept implies that peri-implant hard tissue stability will engender soft tissue and papilla preservation. Maeda *et al.* reported that stress levels in the cervical bone area peripheral to a fixture were greatly reduced when a narrow diameter abutment was connected, in comparison to a size commensurate with the fixture diameter.<sup>55</sup> The authors concluded that the biomechanical advantage of shifting stress concentrations away from the cervical area will diminish their impact on the biological dimension of hard and soft tissue extending apically from the FAI (Figs. 11a–c). The inherent disadvantage is that this shifts stress to the abutment screw with the potential for loosening or fracture.

Ericsson *et al.*<sup>56</sup> detected neutrophilic infiltrate in the connective tissue zone at the implant-abutment interface. The facility by which platform switching/shifting reduces bone loss around implants has been investigated by Lazzara *et al.*<sup>57</sup> The authors hypothesised that if the abutment diameter matches that of the implant, the inflammatory cell infiltrate will be formed in the connective tissue at the micro-gap created at the FAI. If an abutment of narrower diameter is connected to a wider neck implant, the FAI is shifted away from the

**Fig. 12a** The platform-switched design negates micro-motion and resultant crestal bone resorption. The goal of ortho-biological replacement is the idealised replication of the natural state.



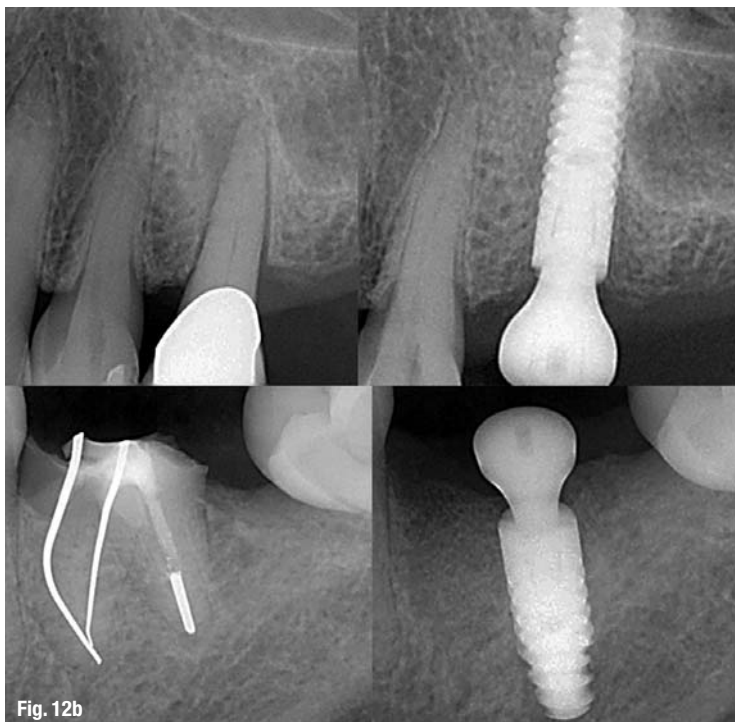


Fig. 12b

**Fig. 12b** The expectation of a precise cone fixture-abutment connection is that the crestal bone will overgrow the fixture platform and remain in that position regardless of whether the implant was placed in a grafted site or immediately placed in an extraction site. Die-back or saucerisation is not a consideration.

outer edge of the implant, thus distancing inflammatory cell infiltrate away from bone. Hypothetically, less crestal bone loss is expected and an increased implant-abutment disparity allows more stable peri-implant soft-tissue integration.

Baggi *et al.* conducted a finite element analysis experiment to define stress distribution and magnitude in the crestal area around three commercially available implants: ITI Straumann (Straumann), Nobel Biocare (Nobel Biocare) and Ankylos C/X (DENTSPLY Friadent).<sup>58</sup> Numerical models of maxillary and mandibular molar bone segments were generated from computed tomography images and local stress vectors were introduced to allow for the assessment of bone overload risk. Different crestal bone geometries were also modelled. Type II bone quality was approximated and complete osseointegration was assumed. It was concluded that the Ankylos C/X implant based on its platform switched and sub-crestally positioned design demonstrated better stress-based performance and lower risk of bone overload than the other implant systems evaluated.

Platform switching with a stable implant-abutment connection is increasingly accepted essential implant design features required to reduce or eliminate early crestal bone loss. A bacteria-proof seal, a lack of micro-movement due to a long friction grip tapered channel, and minimally invasive second-stage surgery without any major trauma for the periosteal tissues are also important factors in preventing cervical bone loss. A preconfigured platform-switched design has a significant impact on the implant treat-

ment in aesthetic areas, as not only is the tissue biotype preserved, but it has also been shown to be enhanced by osseous generation over the collar of the fixture (Figs. 12a & b).<sup>59,60</sup>

The endo-implant algorithm parallels the question: Which came first, the chicken or the egg as an example of circular cause and consequence. It could be reformulated as follows: Which came first, X that cannot arise without Y, or Y that cannot arise without X? An equivalent situation arises in engineering and science known as *circular reference*, in which the parameter is required to calculate that parameter itself. This is the essence of foundational dentistry. If nature creates the ideal, are we as clinicians not responsible for replicating the ideal, should adverse conditions irrevocably alter nature and necessitate its elimination?

Nature wisely created a structure that could harmoniously interpolate hard and soft tissue, act as the portal of nutrition and communication for the body, and be the gatekeeper on guard and in function throughout our lifetime. Our role is to ensure that we re-engineer nature; we must adhere to its rules, its logic and fundamentals. This is not an easy task, as filtering out the best range of evidence from a wide range of sources, presenting clear, comprehensive analyses and incorporating patient experience is a Herculean task. In many ways, this is analogous to *Alice's Adventures in Wonderland*, as so much of what we do grows curiously and curiously as each new innovation demands that we go through the looking glass and determine what Alice found there.

*"There's no use trying," said Alice. "One can't believe impossible things." "I daresay you haven't had much practice," said the Queen. "When I was your age, I always did it for half an hour a day. Why, sometimes I've believed as many as six impossible things before breakfast."*

—Lewis Carroll

*Editorial note: A complete list of references is available from the publisher.*

|   |              |
|---|--------------|
| <b>_contact</b>   | <b>roots</b> |
| <p><b>Dr Kenneth Serota</b><br/>                 4310 Sherwoodtowne Blvd.<br/>                 Suite 300<br/>                 Mississauga, Ontario<br/>                 L4Z 4C4<br/>                 Canada</p> <p>E-mail: <a href="mailto:kendo@endosolns.com">kendo@endosolns.com</a><br/>                 Websites: <a href="http://www.endosolns.com">www.endosolns.com</a>   <a href="http://www.rxroots.com">www.rxroots.com</a>   <a href="http://www.ankylosworld.com">www.ankylosworld.com</a></p> |              |



# EndoInnovations III

SybronEndo offers you advanced technology for safer, more efficient procedures.



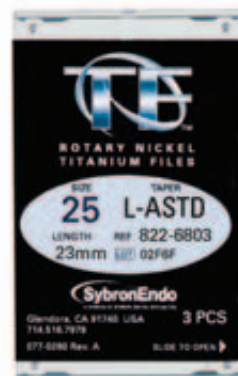## REALSEAL 1 Warm-Bonded Obturator

All the components of RealSeal 1™ – sealer, filler and core – are resin-based materials that chemically bond with each other to form a *superior seal*. As an added benefit, this system's core is engineered to be easily seen on a radiograph.



## TF – Faster, Safer, Stronger

TF™ is twisted, not ground – unlike other nickel titanium files – making it more durable. Endodontic files are made by grinding the flutes, weakening the metal's molecular structure which can lead to separation. Our unique manufacturing process produces a file with optimal sharpness, strength and flexibility. TF allows you to work in difficult situations faster, safer and with a stronger file.



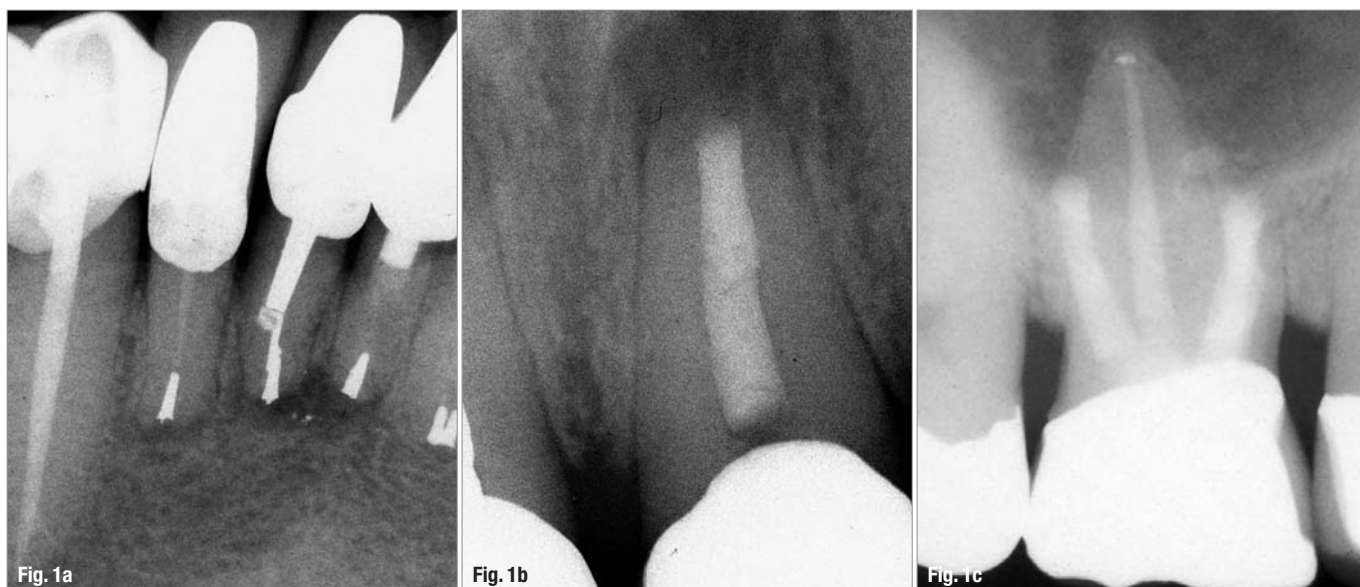
**SybronEndoEurope** | Safe files, superior fills.  
A DIVISION OF SYBRON DENTAL SPECIALTIES

SybronEndo Europe, Basicweg 20, 3821 BR Amersfoort, The Netherlands  
tel: +31 33 4536 159 fax: +31 33 4536 153 email: Endo@SybronDental.com

SybronEndo, 1717 West Collins Avenue, Orange, CA 92867  
800.346.ENDO 714.516.7979 Fax 714.516.7911 SybronEndo.com

# Apical microsurgery— Part V: REF materials and techniques

Author\_ Dr John J. Stropko, USA



**Fig. 1a**\_Amalgam is the most radiopaque REF material, but its use is highly controversial.

**Fig. 1b**\_SEBA has a radiopacity similar to that of gutta-percha.

**Fig. 1c**\_MTA has a radiopacity just slightly better than gutta-percha.

In Parts I to IV, the necessary steps and procedures were presented, enabling the operator to atraumatically and predictably allow the root-end preparation (REP) to be sealed using any accepted root-end fill (REF) material. The surgical crypt should be clean and dry so that vision is clear and unobstructed. Remember, the steps must be followed completely in order to achieve as predictable a result as humanly possible. If, for some reason, crypt management is not complete or the REP is not clean and finished, it will be necessary to repeat a step, or two, to achieve the desired result. The importance of having total control at this point in the apical microsurgical procedure cannot be over-emphasised.

\_The operator is now at a stage in the microsurgical procedure at which the tissues have been atraumatically retracted, the crypt is well managed, the REP is acid etched, rinsed, dried and ready to be filled. By removing the smear-layer barrier, exposing the organic component (collagen fibrils) of the resected cementum and dentine, has been shown to enhance cemento-genesis and is one of the keys to dento-alveolar healing.<sup>1</sup>

There are several retro-fill materials currently available: amalgam,IRM, SuperEBA (SEBA; Bosworth), bonded composites (OptiBond, Sybron Dental), glass ionomers (Geristore, Den-Mat) and, more recently, Mineral Trioxide Aggregate (MTA; DENTSPLY Tulsa Dental). The number of publications in the literature regarding research on the above materials is extensive; thus, only a few of these are mentioned. I do not wish to recommend or condemn any retro-fill mate-

*Where Science Meets the Art of Beauty*

05-06 November 2010

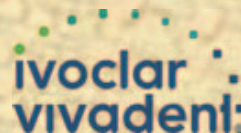
The Address Hotel Dubai Marina  
Dubai UAE

# DENTAL - FACIAL COSMETIC INTERNATIONAL CONFERENCE

2<sup>nd</sup> Edition

Platinum Sponsor

Gold Sponsors



CAPP

CME 14 Hours

Tel: +971 4 3616174 | Fax: +971 4 3686883 | Mob: +971 50 2793711 | [info@cappmea.com](mailto:info@cappmea.com)

[www.cappmea.com/aesthetic2010](http://www.cappmea.com/aesthetic2010)




Fig. 2a




Fig. 2b

**Fig. 2a**\_The Lee MTA Pellet Forming Block has multiple sized grooves for MTA.

**Fig. 2b**\_MTA is removed with an instrument to be delivered to the REP.

rial (except amalgam), but will generalise and relate my—and those of others—experience of and opinions about their applications.

Amalgam and IRM were used for many years as the only commonly available retro-fill materials. However, in almost every leakage study published during the past few years, amalgam has proven to be the worst offender, exhibiting the most leakage.<sup>2,3</sup> This fact, accompanied by the general controversy about mercury in amalgam, strongly suggests that there is no valid reason to continue its use as a retro-fill material. The only real advantage to amalgam is its favourable radiopacity (Fig. 1a). In fact, of all REF materials commonly in use today, none of them compare to the radiopacity of amalgam.

Since the advent of the anatomically correct, ultrasonic REP, one of the most popular REF materials still in use today is SEBA. A recent follow-up study demonstrated a success rate of 91.5% using SEBA.<sup>4</sup>

The author used SEBA routinely in the early nineties with full confidence in its sealing capabilities.

To some, the major drawback of SEBA is its technique sensitivity. The surgical assistant has to mix it until it is sufficiently thick to roll into a thin tapered point with the consistency of dough. For even a well-trained assistant, this is often the most stressful part of the microsurgical procedure. The dough-like tapered end of the thin SEBA roll is then segmented with an instrument, such as a small Hollenback Carver. The small cone-shaped end piece is then inserted into the retro-preparation and gently compacted coronally with the appropriate plugger. Two to five of these small segments are usually necessary to overfill the retro-preparation slightly. Another problem experienced by many is that SEBA is unpredictable as to its setting time, sometimes setting too quickly and at other times, taking much too long for the tired surgeon. At any rate, after the REF has been completed, an instrument and/or bur is used to smooth the resected surface, producing the final finish. A mild etchant is then used to remove the smear layer produced during the final finishing process. SEBA has a radiopacity comparable to that of gutta-percha, so it is necessary to inform the referring doctor that a retro-fill had indeed been performed (Fig. 1b). However, in some recent studies, SEBA has been shown to have a better sealing ability than IRM but does not seal as well as MTA.<sup>2,3</sup>

Bonding, using composite retro-fill materials, is now possible because surgeons can have total control over the apical environment utilising good crypt management procedures. Many different materials are available for use as an REF. OptiBond and Geristore

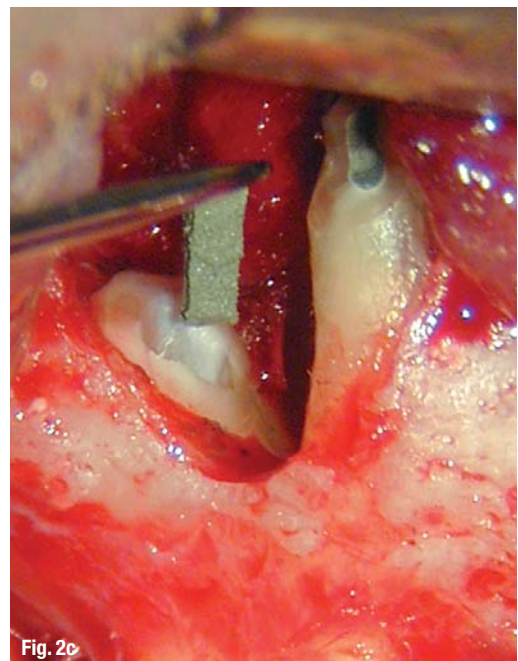


Fig. 2c

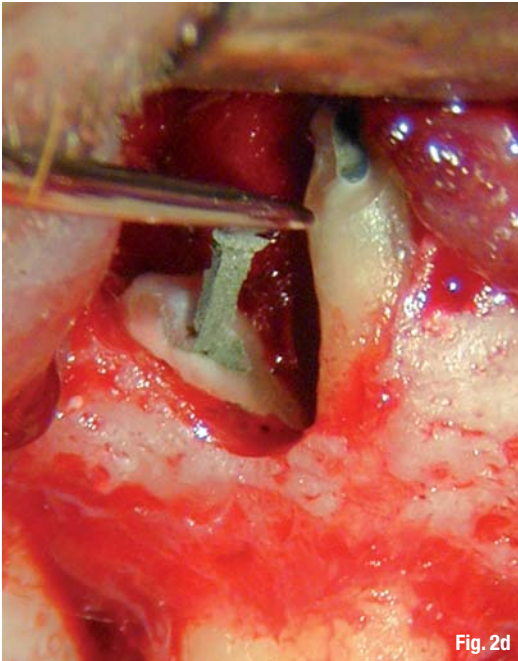


Fig. 2d

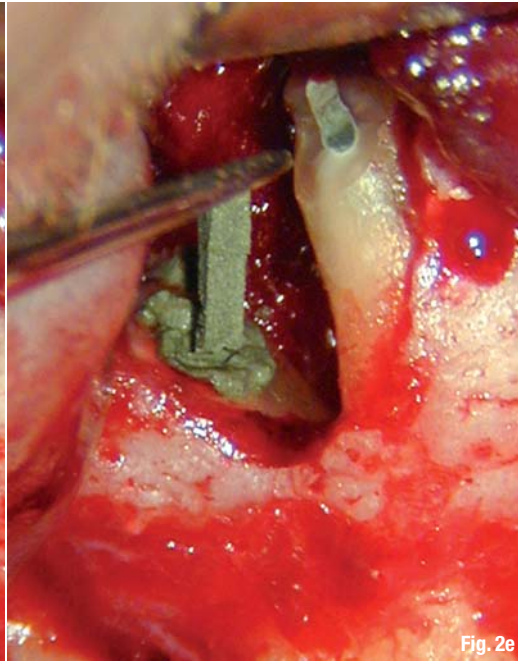


Fig. 2e

**Figs. 2c–e**—Using the Lee MTA Pellet Forming Block, it takes fewer ‘passes’—usually only two or three—with the instrument to complete the fill of the REP with MTA.

are popular because of their ease of use. They both have good flowability, dual-cure properties and the ability to be bonded to dentine. Geristore is supported by research, demonstrating bio-compatibility to the surrounding tissues.<sup>5</sup> The usual etching, conditioning of the dentine, insertion of the selected material, and curing by chemical or light is accomplished in a routine manner when bonding into the retro-preparation. *Note: Since the light source for the OM is so intense, it is mandatory to use an orange filter while placing the composite in order to prevent a premature set.* For most microscopes, an orange filter is available that easily and inexpensively replaces the blood filter. After the composite has been completely cured, the material is finished with a high-speed finishing bur and the resected root-end is etched with a 35% blue gel etchant (Ultradent) for about 12 seconds in order to remove the smear layer and to demineralise the surface.

Several studies have demonstrated no leakage with bonding techniques and many operators use bonding as their technique of choice. However, there is some controversy as to whether the resected surface of the root should also be coated with a thin layer of the bonding material. A ‘cap’ of material (usually OptiBond) is placed with the intention of sealing the exposed tubules on the resected surface. Operators that choose to cover the resected surface believe it is necessary to ensure a good seal and enable better predictability. Other operators do not believe that exposed tubules are a factor concerning the predictability of the healing process. They reason that nothing will heal as well or is more bio-compatible than the exposed dentine of the apically resected surface. I do not cover the exposed apical surface and am convinced that a decisive answer regarding this is still awaited.

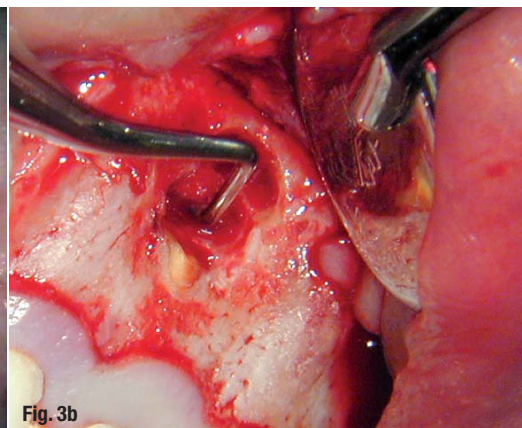
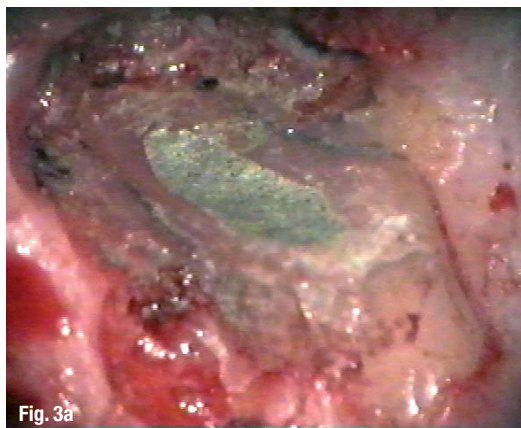
More recently, another material—MTA—has become very popular and is widely used by many. MTA has attracted many converts, and there is much research being conducted and many publications presented so that just one reference would be futile. The evidence extolling the virtues of MTA, regarding its sealing capabilities and its bio-compatibility with the surrounding tissues, is overwhelming. I have talked to many respected endodontists and most are now using MTA as their routine retro-fill material. MTA is chemically similar to calcium sulphate. It is forgiving to work with and has a radiopacity slightly better than gutta-percha (Fig. 1c).

The main advantage of MTA is its ease of use, much like handling Portland Cement. One of the secrets to using MTA is to keep it sufficiently dry so it does not flow too readily (like wet sand), yet sufficiently moist to permit manipulation and maintain a workable consistency. The desired thickness is easily accomplished by using dry cotton pellets, or the MTA mix can be gently dried with a dedicated, air-only, Stropko Irrigator. If the MTA is too dry and needs moisture added, that too is easily done with a cotton pellet saturated with sterile water. Properly mixed MTA can be extruded in pellets of various sizes (depending on the size of the carrier used) using a Dovgan Carrier, and condensed with an appropriate plunger.

More recently, a simple method for delivering MTA into the REP was introduced (Figs. 2a & b). The Lee MTA Pellet Forming Block has several differently sized grooves to create the desired aliquot of MTA. The MTA adheres to the instrument, allowing for easy and efficient placement into the REP (Figs. 2c–e).

**Fig. 3a** Once placed, the MTA should be carved level with the surface of the REB.

**Fig. 3b** MTA is hydrophilic so it is important to re-establish the blood supply to cover it after placement.



For a denser and stronger consistency, the assistant can touch the non-working end of the plugger or explorer with an ultrasonic tip during the condensation process. The flow is increased and a much denser fill is achieved. As a result, ultrasonic densification also increases the radiopacity of MTA's appearance in the post-operative radiograph, but it is still similar to gutta-percha (Fig. 1c). MTA has approximately an hour of working time, which is more than adequate for apical microsurgery and reduces the time pressure of the surgical procedure. Finishing the MTA is simply a matter of carving away the excess material to the level of the resected root-end (Fig. 3a). The moisture necessary for the final set is derived from the blood, which fills the crypt after surgery. MTA is very hydrophilic and depends on moisture for the final set, so it is imperative that sufficient bleeding is re-established after crypt management in order to ensure that the crypt is filled (Fig. 3b). If any material, such as ferric sulphate, has been used for crypt management, it must be judiciously removed in order to restore blood supply to the crypt. This can be considered the final step in crypt management, and is especially important when MTA is used for the REF.

If the size of the lesion indicates the use of Guided Bone Regeneration (GBR), good blood supply is indicated anyway, so allow the blood to cover the MTA before placing the GBR material of choice. In a large lesion, it is sometimes difficult, even after curettage, to restore bleeding into the crypt (perhaps the crypt management was a little too effective) and it may be necessary to use a small round bur in the surgical handpiece to make several small holes in the surface of the crypt to aid in the re-establishment of the desired flow of blood.

Based on current studies, the operator can select any one of the above-mentioned REF materials and be comfortable that, if the proper protocol has been followed, the apical seal will be predictable and healing uneventful.

The final part of this series, published in *roots* 3/2010, will discuss *Sutures, suturing techniques and healing* (Part VI).

*Editorial note: A complete list of references is available from the publisher.*

**\_about the author**

**roots**

**Dr John J. Stropko** received his DDS from Indiana University in 1964 and for 24 years practised restorative dentistry. In 1989, he received a certificate for endodontics from Boston University. He recently retired from the private practice of endodontics in Scottsdale in Arizona. Dr Stropko is an internationally recognised authority on micro-endodontics. He has been a visiting clinical instructor at the Pacific Endodontic Research Foundation (PERF), an Adjunct Assistant Professor at Boston University and an Assistant Professor of graduate Clinical Endodontics at Loma Linda University. His research on in vivo root canal morphology has been published in the *Journal of Endodontics*. He is the inventor of the Stropko Irrigator, has published in several journals and textbooks, and is an internationally known speaker. Dr Stropko has performed numerous live micro-endodontic and microsurgical demonstrations. He is the co-founder of *Clinical Endodontic Seminars*. He can be contacted at [topendo@aol.com](mailto:topendo@aol.com).

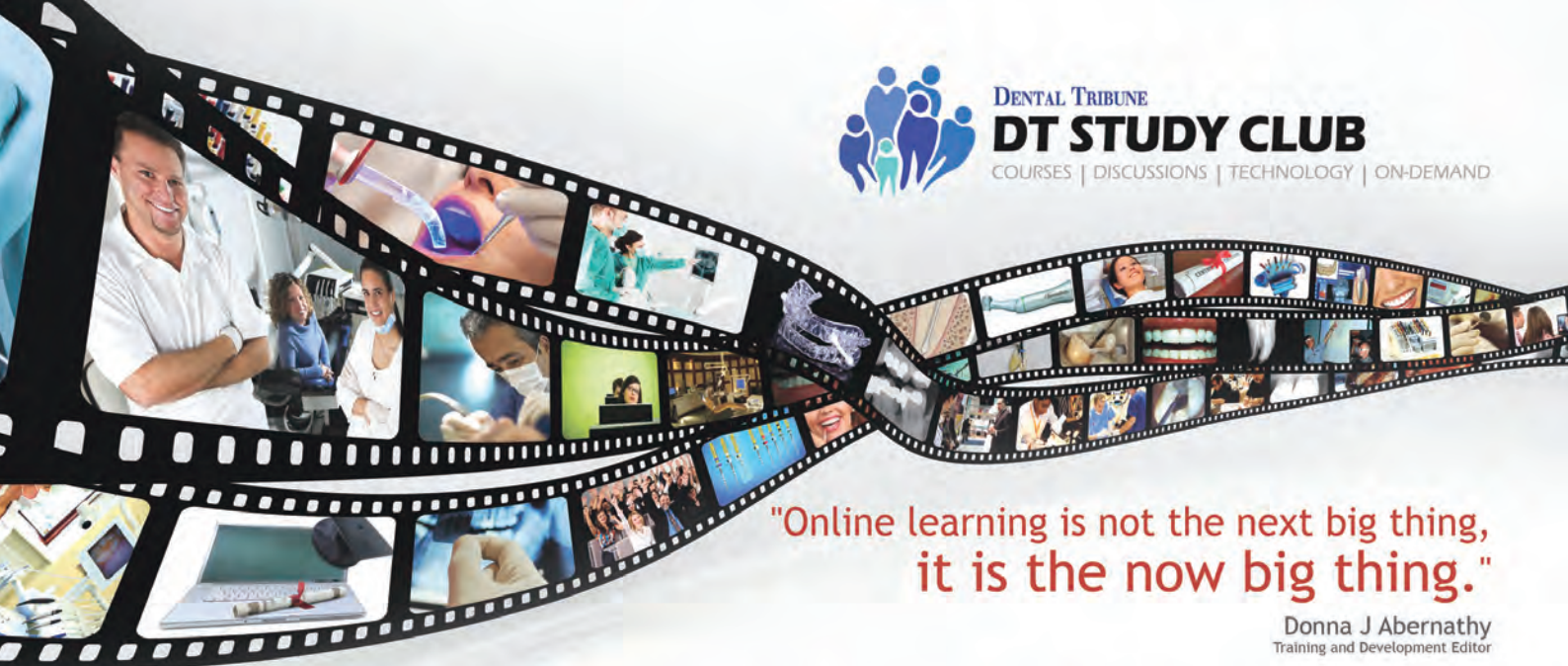



DENTAL TRIBUNE

# DT STUDY CLUB

COURSES | DISCUSSIONS | TECHNOLOGY | ON-DEMAND



**"Online learning is not the next big thing,  
it is the now big thing."**

Donna J Abernathy  
Training and Development Editor

## DTSC - COURSES, COMMUNITY, TECHNOLOGY, ON-DEMAND

The DT Study Club makes all of this possible from the comfort of your own computer and without travel expenses. In other words, welcome to the community!

The purpose of this study club is to provide practitioners like yourself an opportunity to learn and network with like-minded colleagues in a friendly, non-threatening environment. We encourage you to take advantage of Dental Tribune's global outreach to access a variety of fresh perspectives and cultures, enhancing your educational mix.

### 24/7 LIVE AND INTERACTIVE ONLINE COURSES

Fulfill your yearly CE requirements with our growing list of archived ADA CERP approved courses.



### DISCUSSION FORUMS

focused on helping today's practitioners to stay up to date. Networking possibilities that go beyond borders to create a truly Global Dental Village



### VIDEO REVIEWS OF PRODUCTS

Our opinion leaders unveil new products, services, and give you their first impressions of the industry's hottest topics.



### PEER REVIEWED CASE STUDIES

Upload, comment, participate. We encourage you to share your cases for review with like-minded practitioners.



 REGISTER FOR FREE ON [WWW.DTSTUDYCLUB.COM](http://WWW.DTSTUDYCLUB.COM)

CONTESTS WITH CHANCES TO WIN FREE TUITION FOR ADA/CERP C.E. ACCREDITED WEBINARS

SPONSORSHIP AND SPEAKING INQUIRIES:  
JULIA WEHKAMP, [J.WEHKAMP@DTSTUDYCLUB.COM](mailto:J.WEHKAMP@DTSTUDYCLUB.COM), (416) 907-9836.

**ADACERP**  
CONTINUING EDUCATION RECOGNITION PROGRAM



PRACTICE MANAGEMENT



GENERAL DENTISTRY



COSMETICS



ENDODONTICS



IMPLANTOLOGY



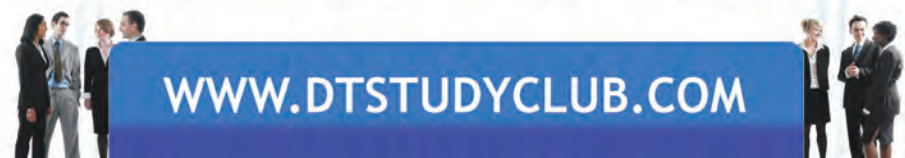
PERIODONTICS



ORTHODONTICS



DENTAL HYGIENE



[WWW.DTSTUDYCLUB.COM](http://WWW.DTSTUDYCLUB.COM)

# Tactile perception in endodontics

Author\_Dr Barry Lee Musikant, USA

When it comes to tactile perception, most dentists doing root canal therapy would agree—more is better. But, what exactly do we mean when we talk about tactile perception? To me,

have a 120 contact points. The greater the number of contact points, the greater the engagement and the consequent increase in resistance to apical negotiation. In short, increasing resistance along length reduces the tactile perception of what the tip of the instrument is engaging. An increase in the number of flutes increases engagement and reduces tactile perception, while the more horizontal orientation of the flutes engages the dentine rather than cutting it when used with the recommended watch-winding motion. The file design is similar to that of a screw and tactile perception at the tip is secondary to engagement along length. While the goal of a screw is engagement, that is not the goal of an endodontic shaping instrument and the more horizontally oriented flutes along the length of a file are counterproductive to the goals the dentist wishes to achieve.




Fig. 1

tactile perception is a measure of the degree to which we can determine what the tip of the negotiating endodontic instrument is encountering. Is it encountering an impediment like a solid wall or is it lodged in a tight canal? Or is the canal that the tip of the instrument is entering round or oval?

Superior tactile perception is a direct result of the instrument's design and the way it is used. Assuming that tactile perception is exactly as I define it, a reasonable analytic task is to determine what endodontic instrument designs and techniques of use enhance tactile perception. One basic insight is that the information conveyed from the tip of the instrument will become increasingly clear as the engagement along length is reduced. If there is a great deal of engagement along length, exactly what the tip of the instrument is encountering becomes murky.

Ideal tactile perception tells the dentist when a solid wall has been encountered. The dentist differentiates this type of engagement from being in a tight canal by the degree of tug-back present when he/she pulls the instrument back. No immediate tug-back means the dentist is encountering a solid wall. Immediate tug-back means the dentist is most likely in a tight canal that will allow him/her to progress to greater depths either using a tight watch-winding motion or via the instrument's use in the 30° reciprocating handpiece. I emphasise the word *immediate* because a solid wall continuously being pecked at with an instrument will start to produce tug-back simply because the repeated pecks into a solid wall will start to establish its own man-made pathway, an inaccuracy a dentist wants to avoid from the start.

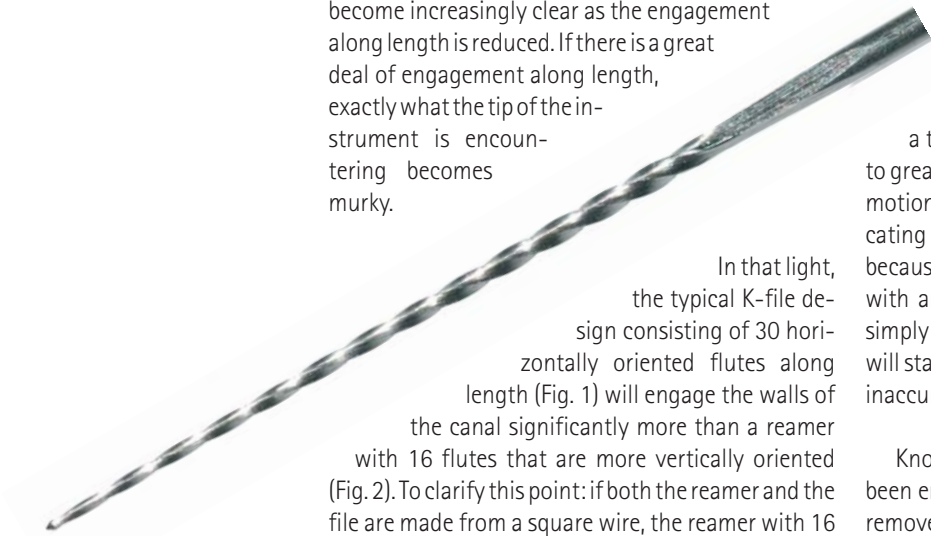


Fig. 2

In that light, the typical K-file design consisting of 30 horizontally oriented flutes along length (Fig. 1) will engage the walls of the canal significantly more than a reamer with 16 flutes that are more vertically oriented (Fig. 2). To clarify this point: if both the reamer and the file are made from a square wire, the reamer with 16 flutes will have a total of 64 points of contact because each flute alone has 4 contact points (fabricated from a twisted square wire), while the file with 30 flutes will

Knowing that a solid wall, as an impediment, has been encountered tells the dentist that he/she must remove the instrument, place a small bend at the tip and attempt to negotiate around the impediment manually. Once around, the dentist leaves the instrument at the newly negotiated depth and reattaches it



to the reciprocating handpiece for what is generally a smooth and rapid negotiation to the apex. As is clear, fewer more vertically oriented flutes increase tactile perception. Fewer flutes also make the instrument less work-hardened, which in turn makes the instrument more flexible, another feature that enhances tactile perception.

Placing a flat along the entire working length further improves tactile perception by further reducing engagement along length, while making the instrument even more flexible. Those 64 contact points are now reduced to 48 (Fig. 3). A cutting tip is an additional feature that can be added to improve tactile perception. Unlike a non-cutting tip that has the potential to impact pulp tissue, a cutting tip tends to pierce it. There is no concern about a cutting tip creating its own pathway because the degree of motion is limited to either a tight watch-winding stroke or the 30° arc generated by the reciprocating handpiece.

If a system of instruments with these design features is used according to the prescribed method for the entire shaping procedure, tactile perception will not be compromised at any point during the instrumentation procedure. Compare this approach to the use of K-files and the subsequent use of rotary NiTi files. The K-files are poorly designed to enhance tactile perception because they engage excessive amounts of tooth structure along length. Their horizontally oriented flutes are designed to engage, not cut, and the great number of flutes resulting from twisting the wire more times produces a stiffer instrument incompatible with superior tactile perception. Rotary NiTi is now used in a crown-down fashion, where the goal is to determine when excessive resistance is encountered along length, not at the tip. In fact, the tips of these rotary NiTi instruments do not engage apically until the shaping procedure is almost completed and then rarely exceed a diameter of apical preparation beyond what was established by the K-files. When rotary NiTi files prepare apical preparations beyond the dimensions produced with K-files in curved roots, the likelihood of separation due to excessive torsional stress and cyclic fatigue increases.

Relieved reamers not only supply more accurate information regarding differentiating a solid impediment from a tight canal, but can also differentiate between a round and oval canal. Some advocates of ro-




Fig. 3

tary NiTi have gone to great lengths to explain the extent to which the apical end of a canal should be prepared, using such terms as *tuning* and *gauging*, where the apical preparation is determined by the presence of clean dentine filings on the flutes of the rotary instruments. Tuning is to first see filings. Gauging is to take the diameter up to the point where the filings are clean. If clean filings are present, rotary NiTi advocates take this as clear evidence that the canals have been shaped adequately to assure clean walls circumferentially.

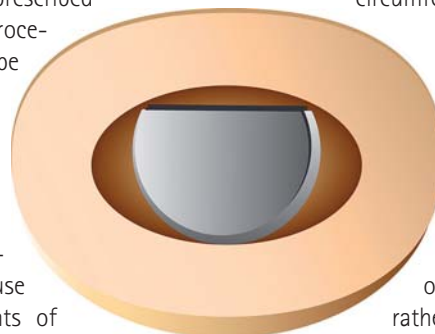
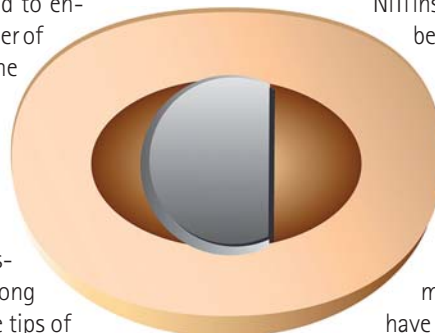
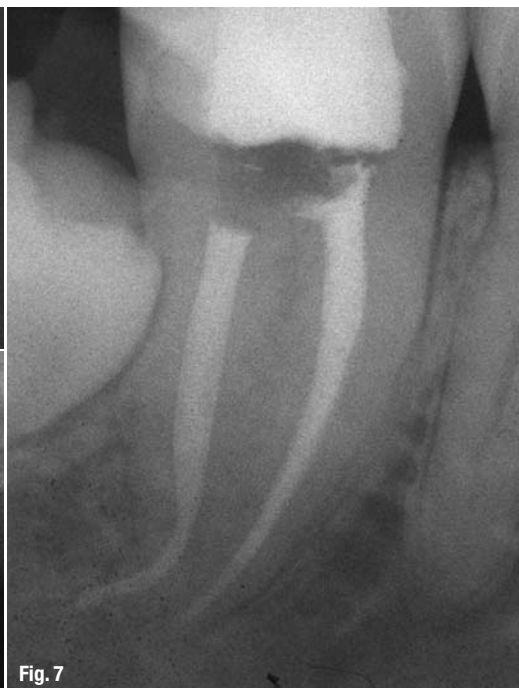
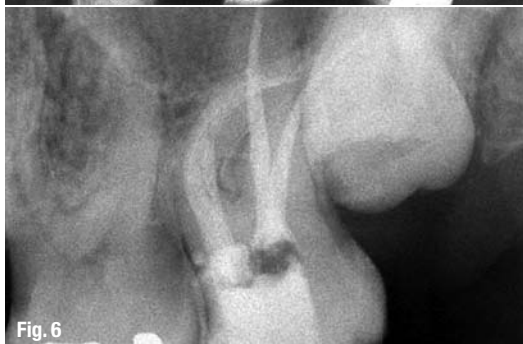
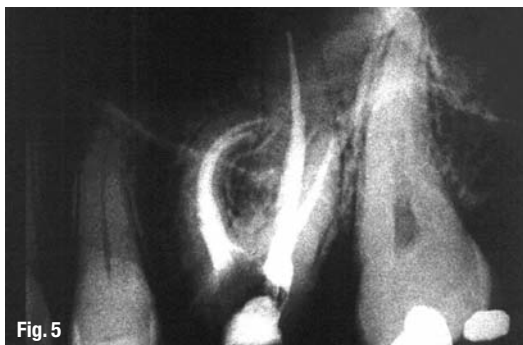Fig. 4



However, two factors make me hesitate in accepting 'tuning' and 'gauging' as effective and predictable procedures. First, the literature clearly demonstrates a high incidence of canals that are oval in their apical anatomy rather than round.<sup>1-3</sup> Second, a symmetrical instrument, like all rotary NiTi instruments, cannot differentiate between a round and oval canal. Only an asymmetrical instrument, one with a flat along its length can make that determination (Fig. 4). When a symmetrical instrument produces dentinal filings at the tip of the instrument, it may only mean that the filings have been removed from the smaller diameter of an oval canal, producing no information about the wider diameter of the oval canal. The literature has reported that the wider portion of an oval canal may be three to five times that of the smaller diameter.<sup>3</sup> Those using rotary NiTi instruments will not know this and will not have taken appropriate steps to adapt to this situation.

Given the increased vulnerability of rotary NiTi files to breakage as the tip size and taper of the instruments increase, it is comforting to consider small preparations as adequate for cleansing and irrigational purposes, even though there is much evidence to counter



these perceptions. From a practical point of view, the smallest apical preparation that allows for effective irrigation is a size 30, with a size 35 apical preparation strongly recommended. There are a number of articles that closely correlate the degree of apical preparation with reduced bacterial count; reduced bacterial count is closely associated with higher success rates.<sup>4,5</sup>

From the above discussion, it is evident that superior tactile perception offers the dentist the tools to differentiate between encountering a solid impediment and negotiating a tight canal. The former situation produces no immediate tug-back on the instrument, while the latter does. No tug-back indicates that the dentist should remove the instrument from the canal immediately, pre-bend it at the tip and seek to negotiate around the present impediment manually. This differentiation is essential to avoid deviating from the correct canal path by the dentist making his/her own canal in error. The cutting tip of relieved reamers confined to a tight manual watch-winding motion or the 30° reciprocating handpiece easily negotiates to the constriction and then 0.5 mm beyond to assure patency throughout the shaping procedure, which in turn keeps the instruments centred, minimising the chances of canal transportation.<sup>6</sup> By instrumenting 0.5 mm beyond the constriction using a size 25, the canals can be predictably opened to the constriction to a minimum of size 35, size 40 1 mm back, and then overlaid with a size 25/06 taper without distortion, assuring a space that is sufficiently large to be well irrigated with NaOCl, digesting chemically any organic debris that may have been missed mechanically. Non-distortion is a result of the modified balanced force that is generated when a tight watch-winding motion is employed. In the same way,

the 30° reciprocating handpiece mimics this tried-and-proven manual motion in keeping the tips of the instruments well centred while negotiating curved canals.

Rotary NiTi files use a motion that can never provide new information about what is occurring at the tip of the instrument. When using rotary NiTi, any information on the apical anatomy of a canal is first attained by employing K-files, instruments that are designed and used in ways that—as this discussion has attempted to address—are incompatible with shaping the canals without distortion and assessing their apical anatomy accurately, at times erroneously giving the dentist the impression that the canals are narrower than they may be.

Relieved reamers are used in a way that assures long life, virtually eliminating separation and giving the dentist more accurate information to determine the width to which the canals should be shaped, with the flexibility to be used both manually and in the reciprocating handpiece. Their use in this manner is supported by a growing body of research that clearly demonstrates that superior results are attainable, while reducing costs per use by 90% compared to rotary NiTi. It is thus no surprise that this alternative approach is garnering increasingly more enthusiastic attention. Clinical examples are shown in Figures 5 to 7.

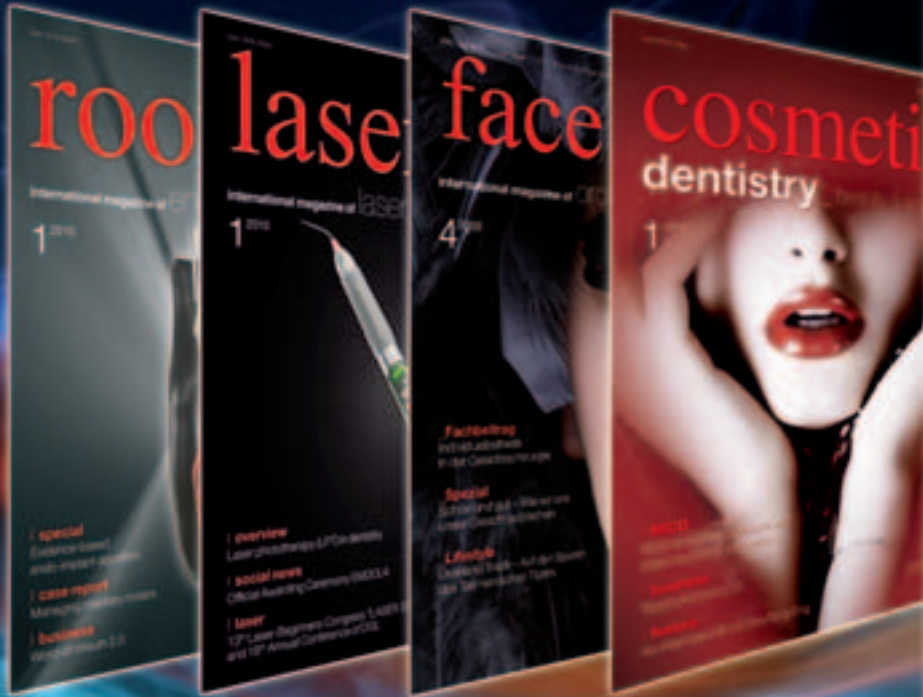
For more information regarding this highly effective and safe approach, please contact me at my free online forum [www.endomailmessageboard.com](http://www.endomailmessageboard.com).

*Editorial note: A list of references is available from the publisher.*

|  |              |
|--|--------------|
| <b>_contact</b>  | <b>roots</b> |
| <p><b>Dr Barry Lee Musikant</b><br/>                 Essential Dental Systems, Inc.<br/>                 89 Leuning Street<br/>                 S. Hackensack, NJ 07606<br/>                 USA<br/>                 E-mail: <a href="mailto:info@edsdental.com">info@edsdental.com</a></p> |              |

# implants

international magazine of oral implantology



Subscribe now!

## One issue free of charge!

I hereby agree to receive a free trial subscription of **implants international magazine of oral implantology** (4 issues per year).

I would like to subscribe to **implants** for € 44\* for German customers, € 46\* for customers outside of Germany, unless a written cancellation is sent within 14 days of the receipt of the trial subscription. The subscription will be renewed automatically every year until a written cancellation is sent to OEMUS MEDIA AG, Holbeinstr. 29, 04229 Leipzig, Germany, six weeks prior to the renewal date.

▶ **Reply** via Fax +49-(0) 3 41/4 84 74-2 90 to OEMUS MEDIA AG or per E-mail to [grasse@oemus-media.de](mailto:grasse@oemus-media.de)

Last Name, First Name

Company

Street

ZIP/City/County

E-mail

Signature

Notice of revocation: I am able to revoke the subscription within 14 days after my order by sending a written cancellation to OEMUS MEDIA AG, Holbeinstr. 29, 04229 Leipzig, Germany.

Signature

Holbeinstr. 29, 04229 Leipzig, Germany, Tel.: +49-(0) 3 41/4 84 74-0, Fax: +49-(0) 3 41/4 84 74-2 90, E-Mail: [grasse@oemus-media.de](mailto:grasse@oemus-media.de)

OEMUS MEDIA AG



# The GTX rotary system

Author | Dr Chris J. Lampert, USA

Nearly fourteen years ago, Dr L. Stephen Buchanan introduced the concept of greater tapered canal shaping and the GT ProFile rotary endodontic system to the world of endodontics. The GT brand is one of the most successful endodontic products in history and has a loyal following amongst clinicians around the world. The original GT ProFile rotary system (DENTSPLY Tulsa Dental Specialties) was also the first NiTi instrument to be part of a comprehensive system-based approach to endodontic treatment. For the first time, predictable and consistent canal shapes could be achieved, followed by a size-matched obturation system, and finally a size-matched post-placement system. The system-based approach of the GT system is brilliant because the paper points, gutta-percha cones, obturators and posts all fit the canal shape produced by the GT rotary instruments. Dr Buchanan and DENTSPLY recently advanced the proven GT ProFile system with the introduction of the GTX rotary system. Below is a technical review of the design features and benefits of the new GTX rotary system.

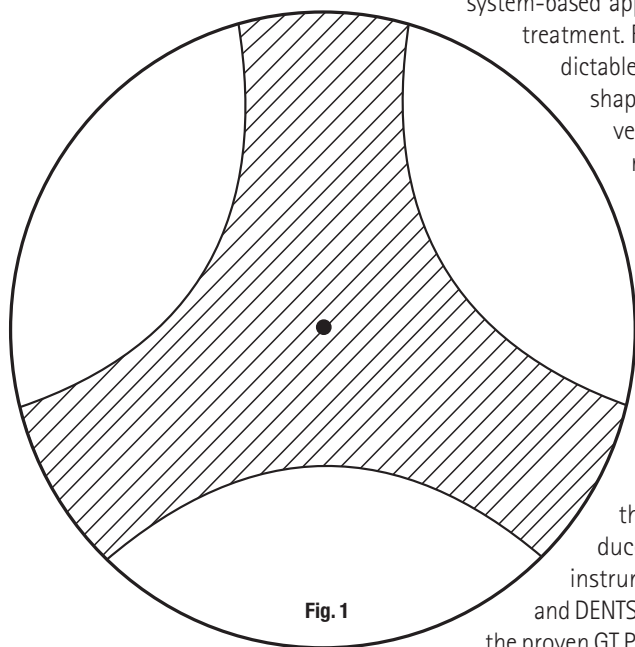


Fig. 1

Fig. 1 | File cross-sectional view showing a radial landed cutting edge design—the radial land is the portion of the file that trails the cutting edge and contacts the radial arc.

## Variable radial land width

Radial landed cutting edges are the only blade design proven to maintain the original canal path and therefore prevent canal transportation. Figures 1 and 2 illustrate the difference between a radial landed cutting edge and a non-radial landed cutting edge. In Figure 1, the radial land portion is the portion of the file that trails the cutting edge and contacts the radial arc. It is the trailing radial surface that limits lateral cutting forces in a curved canal and prevents canal transportation.

Figure 2 shows a non-radial landed triangular cross-section with only the apices of the triangle contacting the radial arc. The non-radial landed cutting blade design in Figure 2 is more likely to transport a curved canal. Similar to the original GT system, the new GTX instruments have radial landed cutting edges.

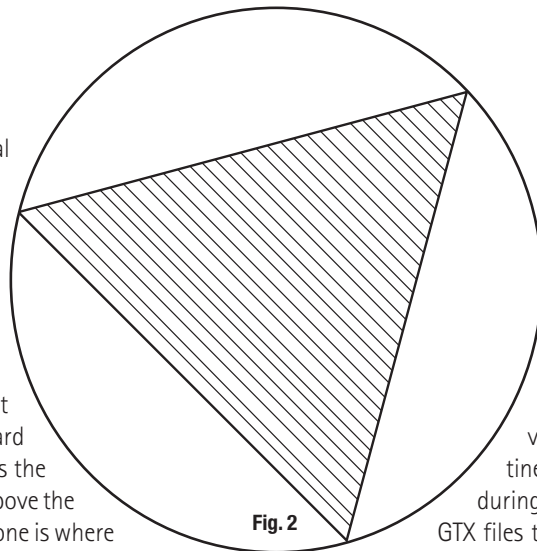
Newer manufacturing technology has allowed for the radial land width to change over the length of the instrument. The variable radial land width feature of GTX allows for thinner radial lands and enhanced cutting efficiency in areas where canal transportation is less likely. Wider width radial lands are used in areas in which canal transportation is more likely to occur. The outcome is improved cutting efficiency without compromising safety. Along with radial landed cutting edges, GTX has the same rounded tip design as the original GT files. This feature is critical to preventing ledge formation and transportation.

## Desired features in a NiTi rotary instrument

In order to appreciate the attributes of the GTX system, we must understand what is desired in a NiTi rotary system. Resistance to breakage, preventing canal transportation, conserving coronal dentine, creating good apical taper, and efficient cutting are what I look for in a rotary instrument system. Until now, clinicians had to choose between safe, flexible, radial landed instruments and faster cutting non-radial landed instruments. GTX design features, such as variable radial land width, 1 mm maximum flute diameters, safe-ended tip configuration, open-spiralled flute geometry and M-Wire, have produced an endodontic instrument that is both safe and efficient.

## Maximum flute diameter

The 1 mm maximum flute diameter is the best feature of the original GT system and has been retained in the new GTX instruments. Maximum flute diameter is defined as the largest diameter of the instrument fluting. It occurs at the most coronal aspect of the instrument's taper. A conventional tapered instrument has a continuous taper for 16mm and the maximum flute diameter is different for different instrument sizes. For example, a conventional size 30 tip 0.06 tapered instrument has a maximum flute diameter of 1.26 mm, which is a diameter 26% larger than that of a 30 tip 0.06 tapered GTX instrument. All instruments in the GTX system have a maximum flute diameter of 1 mm regardless of the tip size or taper.



**Fig. 2** File cross-sectional view showing a non-radial landed cutting edge design: in this design, only the cutting edge contacts the radial arc.

At a time in which canal shapes are moving in the direction of more conservative coronal diameters, the GTX 1 mm maximum flute diameter preserves tooth structure in this region of the canal. The most important area of the tooth with regard to vertical root fracture is the 1 mm region below and above the crestal bone. This 2 mm zone is where the GTX 1 mm maximum flute diameter is most beneficial, which is the reason that I feel it is such an important feature.

Since implants are the comparative treatment against which endodontic treatment is now measured, the bar for endodontic treatment is much higher than it once was, and conserving tooth structure and preserving the structural integrity of the tooth are critical for long-term success—not only long-term success for the treated tooth, but also long-term success for endodontics. If I look back at the canal shapes I was creating ten years ago, I see a significant improvement in the amount of dentine I am saving apical to the pulpal floor. The 1 mm maximum flute diameter of the GTX system automatically preserves canal dentine in the area most critical for maintaining the structural integrity of the tooth.

### M-Wire NiTi

GTX files are the first rotary instruments to use a new type of NiTi wire known as M-Wire. M-Wire NiTi, the raw material used to manufacture GTX files, was developed by Dr Ben Johnson of Tulsa in Oklahoma. M-Wire is manufactured using a proprietary wire-drawing method, which produces a more favourable molecular arrangement of the NiTi alloy matrix. Multiple studies demonstrate that M-Wire is superior to traditional NiTi 508 in both flexibility and cyclic fatigue resistance. Increased flexibility means there are fewer lateral cutting forces applied to the canal in areas of curvature, which results in less lateral transportation of the canal. Cyclic fatigue resistance means the instrument is less likely to separate in areas of canal curvature. M-Wire is the most significant improvement to endodontic instrumentation since NiTi was introduced over two decades ago.

### Increased flute space and reduced core diameter

When you first look at a GTX file, you notice that the flutes are spaced farther apart and there are fewer spirals on the instrument. This feature is the

helical angle. The helical angle for GTX is greatly reduced compared to original GT files. The reduced helical angle produces a more stretched out fluting geometry. The space between flutes is increased, thereby providing more space for dentine shavings to accumulate during use. This feature allows for GTX files to be used in the canal for more revolutions before the flutes fill with debris. Along with increasing the flute space, the reduced helical angle creates a more efficient cutting angle for the rotating blade edges to engage the dentine. This is the same reason reamers are more efficient in rotary action than files.

In order to increase flexibility further, the new GTX system has a reduced core diameter. The reduced core diameter is partly a consequence of the reduced helical angle and increased flute space. Core diameter is the single most important factor affecting instrument flexibility. The reduced core diameter of the GTX instruments offers a flexibility advantage over the original GT system.

### End result

The advances in instrument flute geometry and metallurgy incorporated into the new GTX system have created a superior cutting instrument, while maintaining the inherent safety and system-based approach of the original GT system. From a clinical standpoint, fewer files are needed to produce the final canal shape. At a time in which cutting speed is what many clinicians desire, it is refreshing to see Dr Buchanan and Dentsply take a deliberate approach to maintaining the safety level for which the original GT file system is known. Holding true to radial lands and a safe-ended tip design are what distinguish the GT brand from all the others.

### about the author

roots



**Dr Chris J. Lampert** received his certificate in Endodontics from Boston University and is a full-time practicing Endodontist in Portland, Oregon. Dr Lampert is a Specialist Member of the American Association of Endodontists, the American Dental Association and the Oregon Dental Association. He can be contacted at lampertendo@gmail.com.

# Peri-apical microsurgery for removal of a fractured endodontic instrument

Author\_ Dr Leandro A. P. Pereira, Brazil

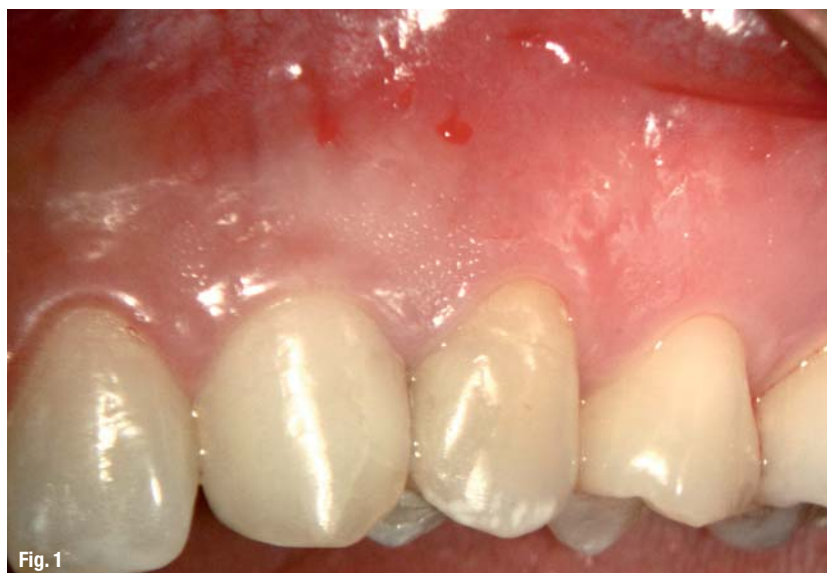

Fig. 1

Fig. 1\_Initial clinical aspect.

Fig. 2\_Initial X-ray.

**\_During endodontic treatment,** procedural errors may occur, such as the breakage of endodontic files. These accidents may compromise the treatment and prognosis of the clinical case. Frequently, it is necessary to perform additional procedures to resolve the problem.

With the development of cleaning and shaping endodontic systems, there is decreasing frequency of procedural problems in dental practice.<sup>1</sup> However, concern persists that rotary NiTi instruments are more susceptible to breakage. This has been the second most common reason for dentists not using rotary instruments.<sup>2</sup>

A recent study has shown that the incidence of broken instruments accounts for 11.7% of all endodontic malpractice cases.<sup>3</sup> The incidence of NiTi file fractures has been shown to range from 0.4 to 5% and their use is considered safe.<sup>4-6</sup> Fractures can occur through torsional failure or as a result of flexural fatigue.

## \_Minimising breakages

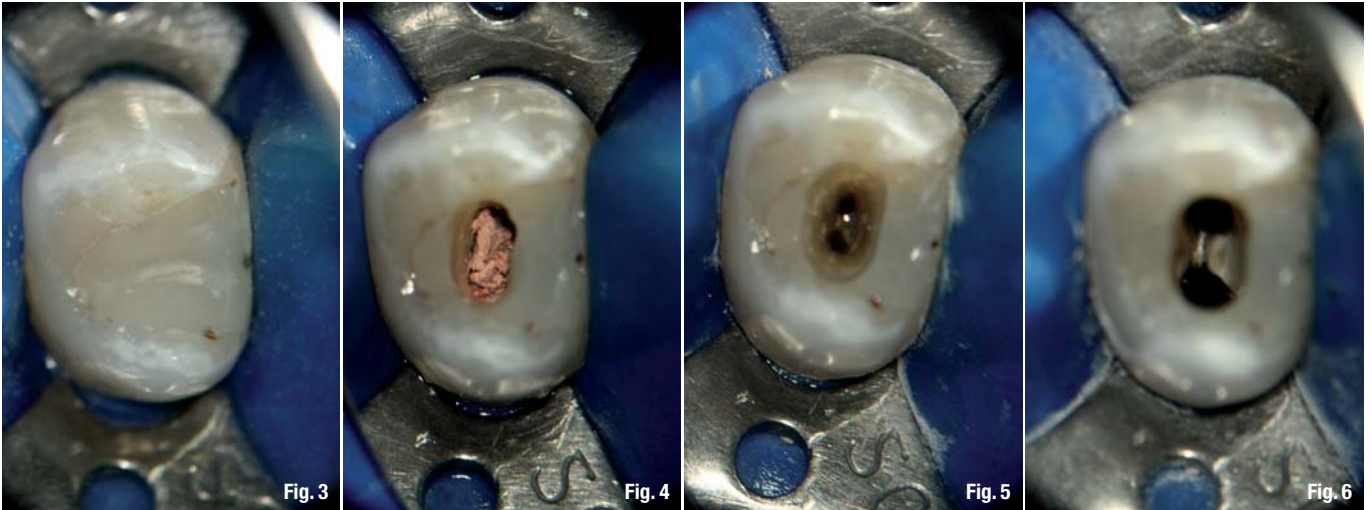
In order to minimise these incidents, care must be taken as follows: evaluate the tooth anatomy carefully before treatment; ensure a straight-line access; create a glide path with small hand files; use the crown-down technique; use a torque-controlled motor; keep files moving in and out of the canal; and control the number of times files are used, discarding files after a specified number and types of canals.

Fractures of endodontic instruments inside canals may be classified according to their intra-radicular position as occurring in the cervical, middle or apical thirds. The success rate for removing fractured instruments in the cervical and middle thirds is higher than it is in the apical third, and the incidence of iatrogenies during the attempt to remove them is lower.<sup>7-9</sup>

The prognosis of treatment can be altered as a result of the presence of endodontic infection. Cases

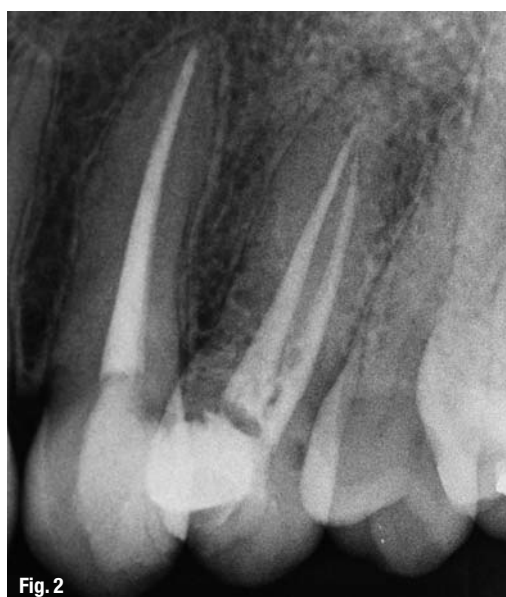

Fig. 2



**Fig. 3** \_Initial occlusal clinical aspect.  
**Fig. 4** \_Gutta-percha removal without solvents.  
**Fig. 5** \_2.5% NaOCl.  
**Fig. 6** \_After shaping.

of pulp necrosis have a worse prognosis than cases with live pulp, as the presence of a large quantity of bacteria and the limitation of correctly eliminating them may lead to treatment failure.

Failure to remove the fractured endodontic instrument results in deficient cleaning, shaping and filling of the root-canal system. Under these conditions, in addition to the endodontic diagnosis, the time during treatment when the instrument fracture occurs is of great importance in the prognosis of the case.<sup>10</sup>

When instrument fracture in a contaminated canal occurs at the beginning of treatment, the prognosis is worse because there is still a large quantity of bacteria, and the presence of the instrument may prevent adequate microbiological control. The presence of the instrument may also contribute to inadequate endodontic filling. The prognosis is better when the fracture occurs near the end of the canal-cleaning and shaping process, as it is at a more advanced stage of endodontic microbiological control.

In situations of instrument fractures associated with pulp vitality, the prognosis does not change significantly.<sup>10</sup>

### **\_Removing broken instruments**

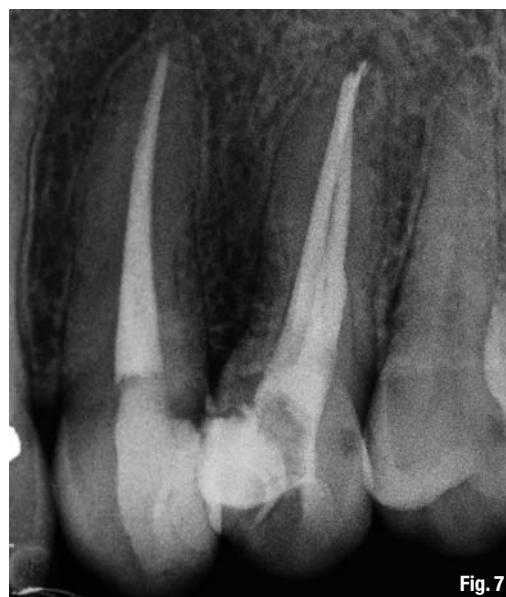When making the decision to remove the instrument, factors such as pulp diagnosis, location, root curvature and length, size and type of fractured instrument, remaining dentinal thickness, and risks of iatrogenies during the attempted removal must be taken into consideration.

A technique commonly used for removing fractured instruments is to achieve a bypass with a manual file, so that the fragment can be drawn to the pulp

chamber and removed. Another removal technique is by means of ultrasonic vibration of the fractured fragment, associated with the use of an operating microscope. The application of ultrasonic energy causes the fractured instrument to vibrate, causing it to detach from the canal wall, and it can then be drawn to the pulp chamber and finally removed.<sup>7</sup>

The application of these methods in atresic canals may result in excessive wear of the root walls. Therefore, their use associated with the operating microscope is safer, owing to the possibility of improving visualisation through the magnification and illumination provided by the microscope.

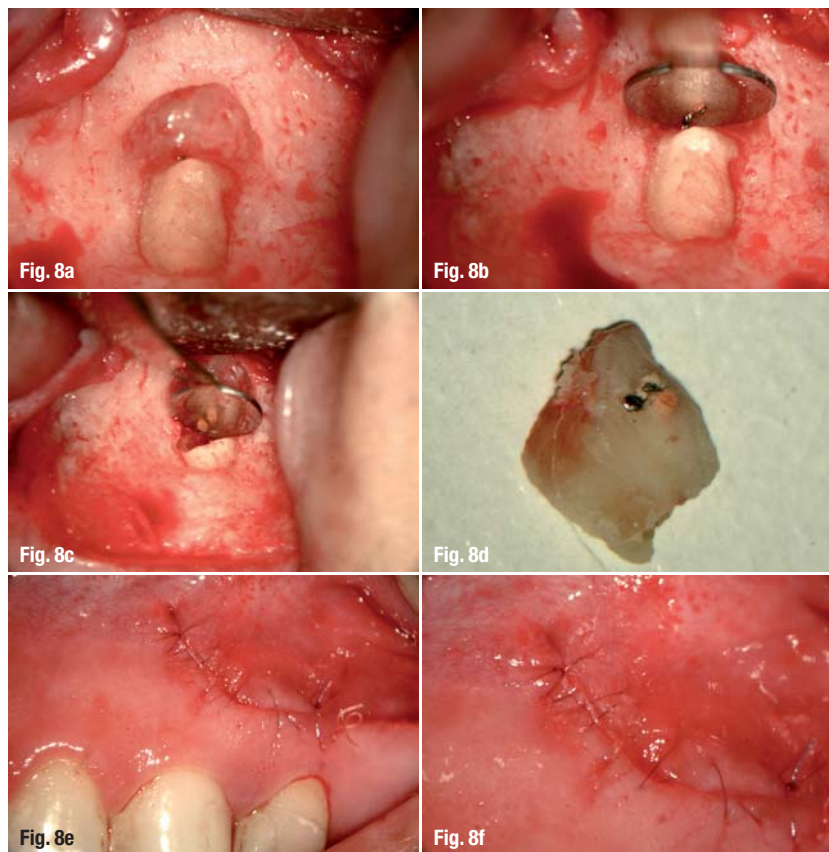
In cases of unsuccessful removal of the instrument and control of infection, with persistence of signs and symptoms of endodontic disease, surgical removal of the fragment may be indicated.



**Fig. 7** \_After filling, with broken file still in place, and before micro-surgery.

## \_A clinical example

This article demonstrates the resolution of a clinical case in which there was fracture of a K3 rotary instrument in the apical third, extending out of the root apex.



restoration, using ultrasonic diamond inserts (CR1, CVDentus; Fig. 3).<sup>11</sup> Filling was removed from the root canals with the use of ultrasound and type K hand files, without the use of solvents (Fig. 4). As auxiliary chemical substances, 2.5% NaOCl (Figs. 5 & 6), ENDO-PTC and 17% EDTA-T were used.

After removing the fillings from the canals and establishing the working length by means of the apical locator Elements Diagnostics (SybronEndo), root-canal preparation began with oscillating hand endodontic files in M4 handpiece up to type K #20 file.

After this, preparation of the canals continued with K3 SybronEndo VTVT Pack files, driven by an NSK electric motor with torque control adjusted to 1.2 N and a speed of 350 rpm.

At the time of using instrument K3 #30.04 in the apical region, there was no adequate control of the pre-established working length and the instrument overtook the root apex and fractured. The fractured fragment measured 3 mm, of which approximately 1 mm was outside of the apex.

## \_The bypass technique

Several attempts were made to remove the fragment using the bypass technique associated with the use of ultrasound and operating microscopy. In spite of making the bypass with a type K #08 file, and successively with type K #10, #15, #20 and #25 files, the fragment did not come out. The position of the instrument in the apical third, associated with the root curvature in the region, was responsible for the failed attempt to remove it.

At this stage of the treatment, disinfection of the root-canal system had not yet been concluded. The presence of the instrument, made it impossible to sanitise the canals correctly and the signs and symptoms of endodontic infection persisted.

In an endeavour to perform additional decontamination, calcium hydroxide was used as intra-canal medication for three weeks, but the signs and symptoms of endodontic infection did not yield.

As a result of the failure to control the infection in this case, complementary surgery was proposed to remove the apical root third, since it was not possible to shape and disinfect it because of the presence of the instrument.

For the complete resolution of infection, the root canals were filled (Fig. 7) and after this, piezoelectric peri-apical microsurgery was performed to resect the apical third of the root.

The patient, a healthy 44-year-old woman, came to the dental office complaining of constant, low intensity, spontaneous pain in the vestibular apical region of tooth #24, and presented intra-oral oedema, pain on chewing and vertical percussion.

She reported having undergone endodontic treatment in tooth #24 more than six years ago. In the peri-apical radiographic examination, it was possible to visualise deficient endodontic treatment and the presence of apical bone rarefaction (Figs. 1 & 2). An acute peri-apical abscess was diagnosed.

The proposed treatment was endodontic re-treatment because in the previously performed treatment there was inadequate canal cleaning and shaping, which had led to filling with empty spaces and prolonged the intra-canal endodontic infection. Peri-apical surgery was contra-indicated, owing to the presence of deficient endodontic treatment.

Endodontic re-treatment began with access to the pulp chamber, with removal of the occlusal resin

**Fig. 8a** \_Broken file, surgical view.  
**Fig. 8b** \_Broken file, micro-mirror view.  
**Fig. 8c** \_Retro view of obturation.  
**Figs. 8d** \_Apical fragment.  
**Figs. 8e** \_Vicryl 8-0 sutures (operating microscope at 12.5x magnification).  
**Fig. 8f** \_Sutures (20x).



A full thickness flap was made with a semilunar incision. Selection of this type of incision was determined by the absence of a large, radiographically visible bone defect (Fig. 2) and for aesthetic reasons. This type of incision does not carry the risk of post-operative gingival recession.

After raising the surgical flap, it was possible to note the integrity of the cortical vestibular bone. The osteotomy was performed using surgical piezoelectric ultrasound and CVDentus W1-0 insert for more precise control of the cut, followed by apicectomy, also performed using ultrasound.

### \_The benefits of ultrasound

There are technical and biological advantages to osteotomy performed using ultrasound when compared to the use of high or low speed burs. Ultrasound has a highly selective tissue cutting ability. Its action occurs only on mineralised tissues such as bone and tooth, preserving soft tissues such as nerves, vessels and mucosae. During osteotomy, the amplitude of the micro-movements generated by the ultrasonic insert ranged between 60 and 210 µm, making the hard-tissue cut extremely precise. This is associated with the formation of acoustic micro-stream and cavitation in the operative field, which promote a clean field, as observed in Figures 8a to c.<sup>13-20</sup>

The biological benefits of piezoelectric surgery particularly involve the maintenance of cellular viability in the operated region, so that the first post-operative stages of the bone repair process are better. It induces a faster increase in morphogenetic bone proteins and modulates the inflammatory reaction, in addition to stimulating healing.<sup>14</sup>

The fractured instrument was removed together with the apical root third in the apicectomy (Fig. 8d). The apical root cut was performed at an angle of 90° to the long axis of the root, in order to expose the smallest quantity of dentinal tubules and preserve the most root extension, favouring microbiological control and function of the dental remainder.<sup>21</sup>

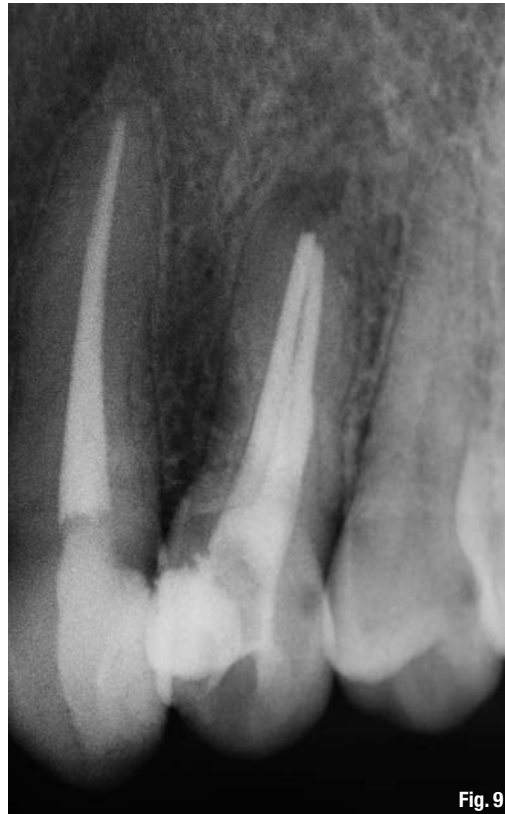

Fig. 9 Post-op X-ray.

The quality of the remainder of the root filling was evaluated by introducing a micro-mirror into the apical bone recess and reviewing the remainder of the root filling, which was considered satisfactory because it filled the root canals uniformly (Fig. 8c).

This was the criterion that determined whether retro-preparation and retro-filling of the root canals should be performed, since this region of the canal had been adequately cleaned, shaped and filled.

The sutures were made with the aid of the operating microscope. Two simple stitches with Vicryl 6-0 thread were made to stabilise the flap, and another continuous stitch was made with Vicryl 9-0 thread to coapt the edges (Fig. 9).

Clinical control was performed after 7, 30 and 90 days. There was remission of all the clinical signs and symptoms of endodontic infection.

*Editorial note: A list of references is available from the publisher.*

### \_about the author

### roots

#### Dr Leandro A. P. Pereira

is a specialist in Endodontics and Professor of Endodontics at the School of Dentistry at São Leopoldo Mandic in Campinas in São Paulo in Brazil. He lectures the Specialist Endodontics course of the Escola Aperfeiçoamento Profissional Associação dos Cirurgiões Dentistas de Campinas in Campinas. Dr Pereira runs his own private clinical in Campinas and can be contacted at [leandroapp@sedcare.com.br](mailto:leandroapp@sedcare.com.br) and via his Website [www.sedcare.com.br](http://www.sedcare.com.br).



# Principles of diagnosis and treatment

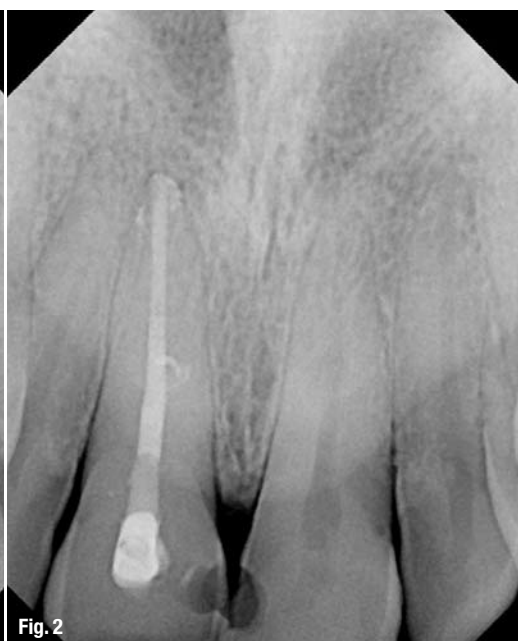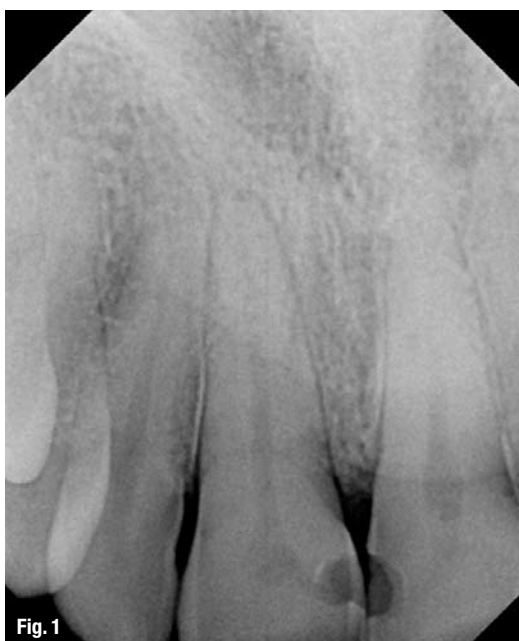Author\_ Dr Kendel Garretson, USA

Fig. 1 \_Pre-op X-ray.

Fig. 2 \_Immediate post-op X-ray.

Fig. 3 \_Immediate post-op X-ray.

Fig. 4 \_X-ray at 16-month control.



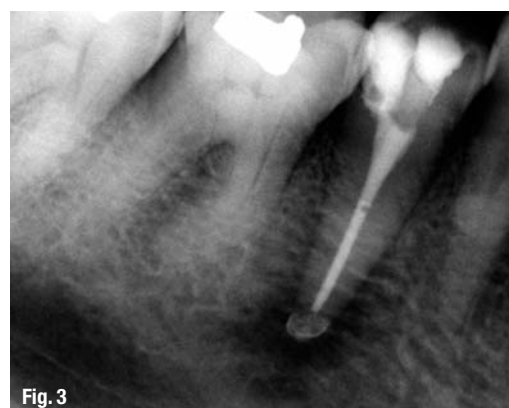
Endodontic anatomy varies greatly and single-canal teeth provide an opportunity to illustrate principles of diagnosis and treatment. In the following case, a patient presented with a toothache (Fig. 1). The medical history was non-contributory. Diagnostic testing revealed a necrotic maxillary central incisor with symptomatic peri-radicular periodontitis. Even in cases with obvious pathology, thorough endodontic diagnosis is completed to determine the proper pulpal and peri-radicular status of teeth in the affected area, including examination of the affected sextant and the opposing arch.

Based on these findings, I decided to treat the tooth in two visits. Emphasising debridement in a crown-down fashion, the canal system was entered and flared coronally. A variety of instruments can be used for this purpose, including Gates-Glidden drills as used in this case, followed by tapered rotary NiTi instruments. No attempt is to be made to instrument to full length until coronal flaring and preliminary disinfection are completed. The goal is to minimise the risk of pushing

debris through the apical foramen. A preliminary canal length is established, followed by a definitive working length as treatment progresses.

## Apical preparation

The apical preparation was sized and finalised with non-tapered rotary instruments (LSX, Discus Dental).



# The MAP System

New with flexible  
NiTi memory  
shape tips

www.pdsa.ch

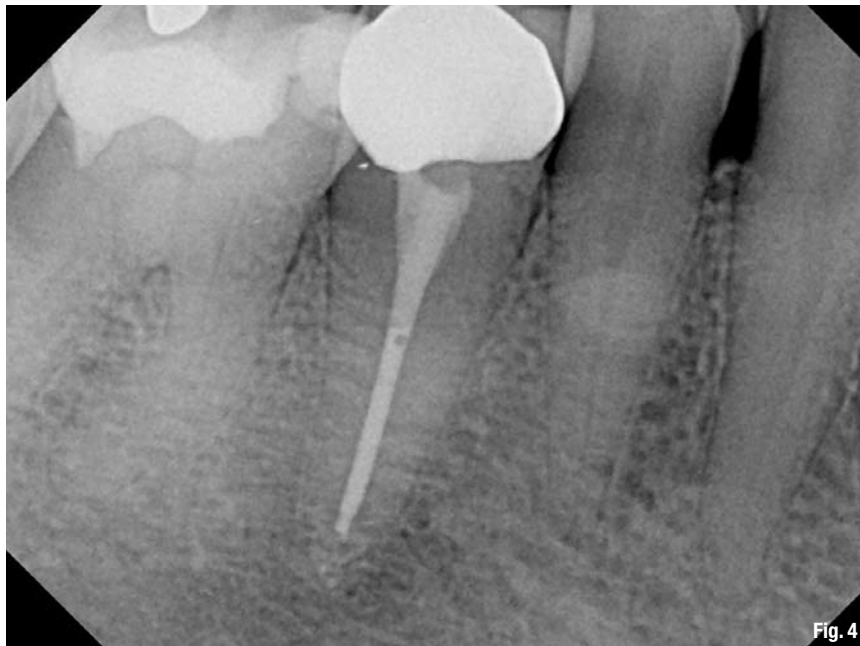
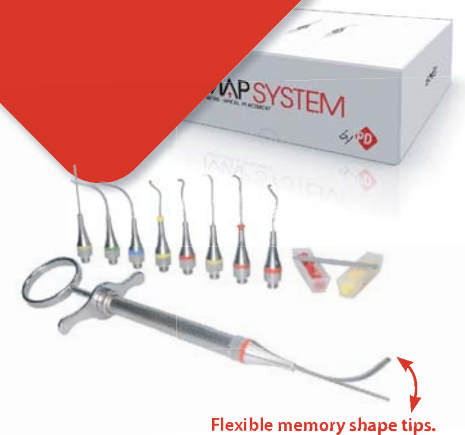
Fig. 4

Again, a variety of instruments can be used for this purpose. The goal is to thoroughly debride the apical extent of canal system and prepare the tooth for obturation. Irrigation was accomplished with NaOCl and aqueous EDTA. Irrigants were activated with sonic agitation and copious irrigant exchange was encouraged with small K-files used in an exploratory fashion.

After drying, a non-setting calcium-hydroxide paste was delivered to length in the canal and a secure interim restoration was placed. Calcium hydroxide aids in tissue digestion, disinfection, and neutralisation of LPS. Other agents may also be used, both as irrigants or dressings, to help optimise microbial control.

The patient returned in two weeks to complete treatment. Symptoms resolved within a day or two of the initial visit. Use of aqueous EDTA, with sonic activation and instrumentation, assisted removal of the dressing. The apical preparation was again verified prior to obturation. Since the tooth was prepared with LSX, a corresponding Simplifill (Discus Dental) gutta-percha obturator was used. This allows for excellent apical control and compaction of gutta-percha. Following this, a backfill using a heated gutta-percha delivery injection device was performed. Composite resin was then used to complete access closure. Several lateral canals were noted after obturation, demonstrating hydraulic pressure

and thorough obturation of the canal system (Fig. 2).

## Predictable healing

The second case (Figs. 3 & 4) that was previously treated with similar presentation and preparation philosophy demonstrates that by adhering to biologically based treatment philosophies that flow from a thorough diagnosis, our patients can expect predictable healing and disease prevention.

## about the author

## roots

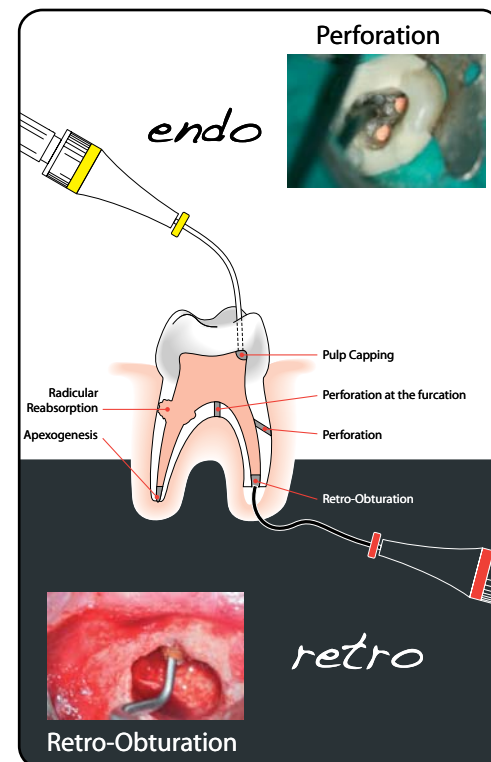


**Dr Kendel Garretson** is a 1989 graduate of the Dental School at the University of Texas Health Science Center at San Antonio. Since 2004, he

has limited his practice to endodontics and lectures on a regular basis to Advanced Education in General Dentistry residents on a variety of endodontic topics. He is a member of the American Dental Association and an associate member of the American Association of Endodontists. He maintains a private practice in San Antonio. Questions and comments are welcomed at [onlyendo@gmail.com](mailto:onlyendo@gmail.com).

## The MAP System

(Micro-Apical Placement System), «endo» and «retro» kits provide a unique and efficient method for placing root-canal repair materials by orthograde or retrograde obturation. The new NiTi Memory Shape tips can be manually shaped to any required curvature. The needle takes back its initial straight shape after autoclave sterilization.



Designed and manufactured by  
Produits Dentaires SA . Rue des Bosquets 18  
1800 Vevey . Switzerland



Swiss quality  
dental products

Your distributor for Germany & Austria

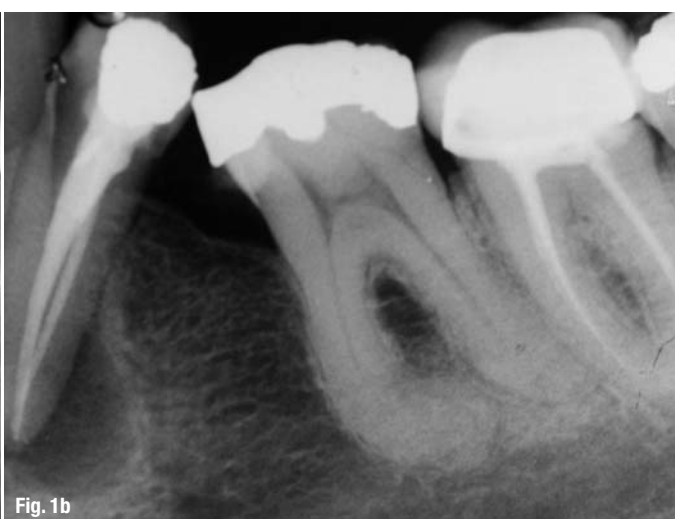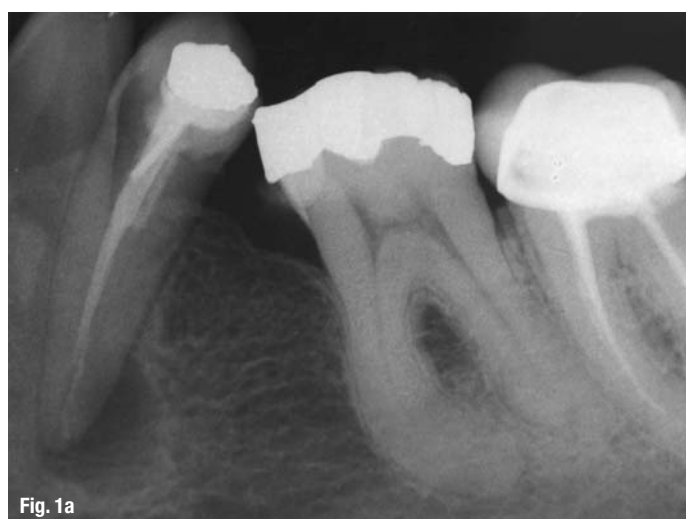Alexander Haid  
Tel. 0049 (0)700 69 69 90 90  
Fax: 0049 (0)700 69 00 90 90  
[info@i-dent.org](mailto:info@i-dent.org)  
[www.i-dent.org](http://www.i-dent.org)

# i-DENT

intelligentes Dentalequipment

# Endodontics—Does the biology matter?

**Authors\_** Dr Alyn Morgan & Dr Ian Alexander, UK



**Figs. 1a & b** An example of technically high-quality endodontics in which biological imperatives have not been met: despite the location and preparation of the second root canal and the well-condensed obturation of the root-canal system to length, the lesion associated with the tooth has increased in size.

**\_Root-canal treatment** is the most technically demanding procedure in dentistry. In order to prepare and obturate successfully the labyrinthine root-canal systems that we are faced with on a daily basis, relying purely on tactile sensation, takes great skill, developed over many years to even come close to mastery of the art. Since the technical difficulties are considerable, it is perhaps understandable that great pride can be taken in the production of an aesthetically pleasing post-operative radiograph. Equally understandable perhaps, if we judge the success of our procedure this way, is that much of the teaching and practice of endodontics focuses on the technical skills required to achieve good results. Does it matter then that we are treating a disease? In order to achieve good outcomes, do we really need to understand the disease we are treating, or simply be proficient at preparing and obturating canals?

Apical periodontitis is the disease that, as endodontists, we spend most of our practising lives treating. Some would argue that a thorough understanding of the aetiology, pathogenesis and microbiology of the disease should be a prerequisite to successful treatment, and essential knowledge for

any student or practitioner of endodontics. It is, however, quite often the case that those undertaking root-canal treatment simply view the procedure as a technical exercise—a series of steps that must be undertaken in order to obtain the desired obturation radiograph. If the success of this approach, in terms of healing, is equivalent to that reported in contemporary literature, then can it be argued that a biological approach to root-canal treatment is not necessary.

These issues were amongst those discussed by Prof Kishor Gulabivala in his keynote lecture to the European Society of Endodontology Congress in Edinburgh last year. As one of the leading researchers and teachers in the field of endodontics, Prof Gulabivala was able to address the subject from several angles. Firstly, he presented a synthesis of the existing literature on the aetiology and pathogenesis of apical periodontitis, and thereafter an examination of several of the microbiological aspects of the disease. Next, he discussed the manner in which clinical intervention influences the disease process. Lastly, he presented a number of conclusions based on his personal insight, along with a discussion on

the disconnect that exists between the biological and technical aspects of endodontic training.

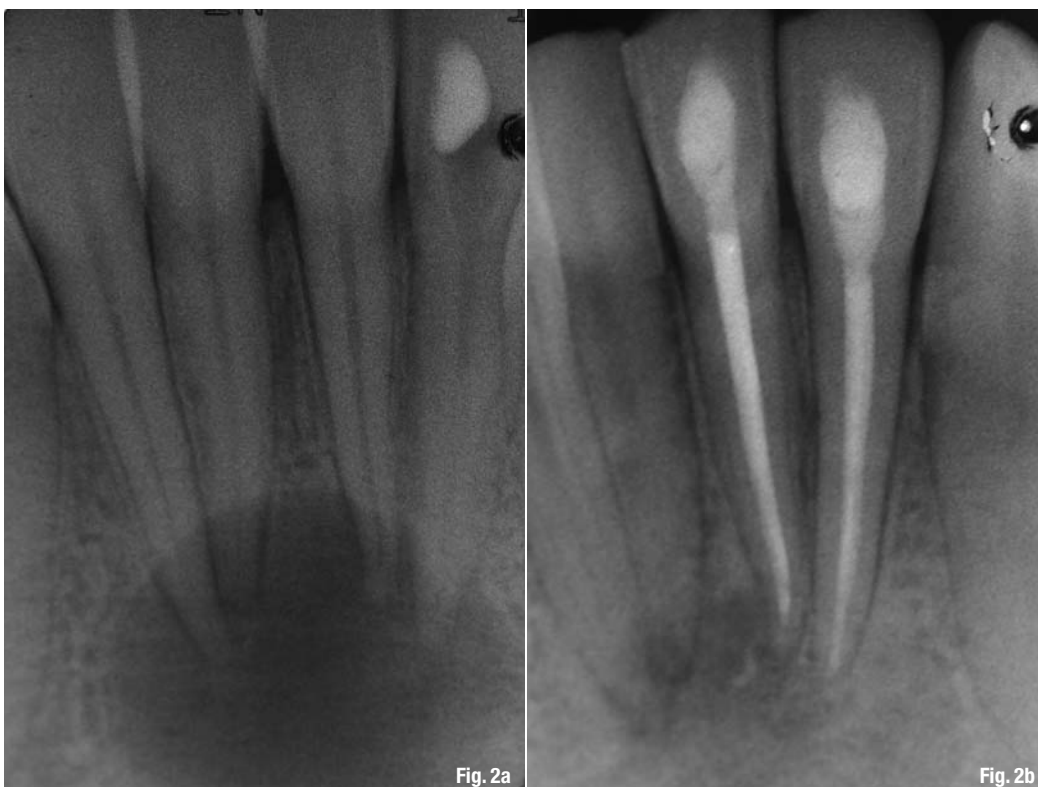The microbial aetiology for apical periodontitis is well established. Classic work by Kakehashi *et al.*,<sup>1</sup> Sundqvist<sup>2</sup> and Moller *et al.*,<sup>3,4</sup> amongst others, demonstrated the causal relationship between the presence of bacteria in the root canal and the development of apical periodontitis. The continued development of the disease appears dependent on the interaction between the host response and the root-canal microbiota; changes in either will have an effect on its progression. As microbial identification methods become increasingly sophisticated, it will hopefully be possible to identify more of the bacterial species present in what is a hugely diverse infection. It is also important to explore and identify those species associated with disease progression, clinical symptoms, treatment resistance and treatment failure. Identification methods that are more complex will be required, as even variations at sub-species strain level can complicate the situation and influence the development of apical periodontitis.

Whilst identification of the microbiota will give insight into the development of the disease and its associated symptoms, this is only part of the picture. The biofilm concept is now well recognised in endodontics; this means that in addition to identifying species present within an endodontic infection, it is also important to understand the way they may interact and communicate with other, whether the

interaction is synergistic or antagonistic, the way nutritional needs are met and the way the biofilm community organises itself for optimum efficiency. Future treatment strategies need to be informed by research conducted into endodontic biofilms; unfortunately much current practice has been developed based on what now appears to be an outdated infection model.

So, having discussed where we are with our knowledge of the microbiology and aetio-pathogenesis of apical periodontitis, the original question still stands. Does a greater understanding of the biology of the disease by those who treat it offer a better chance of enhanced outcomes, and if so how?

Having established a putative disease and microbial model for apical periodontitis, we need to look at our treatment protocols to determine whether they are appropriate for the problems the science has identified. Whilst the technical aspects and difficulties of root-canal treatment cannot be ignored, they need to be considered in conjunction with the biological imperatives, namely reducing the infection within the root-canal system down to a level at which the balance between disease progression and repair is tipped in favour of repair. The highly complex nature of the root-canal system, and the widespread and diverse nature of the infection within it, makes it unlikely that complete disinfection can take place. A study by Nair *et al.*<sup>5</sup> demonstrated that even in well-treated teeth biofilm



**Figs. 2a & b** When high quality technical work is combined with a biological approach to treatment, healing is likely. A substantial reduction in the size of this lesion, over a nine-month period, occurred as a result of good isolation, thorough chemo-mechanical canal preparation, incorporating active irrigation, and then well-condensed obturation to the apical terminus.

remains, particularly in the apical portion of the root. This may explain why endodontic success rates have not improved greatly in over a century. Existing treatment protocols, with their technical bias do not address these problems effectively.

The fundamentals of treatment have not changed in many years: remove as much of the necrotic and infected material from the root-canal system as is possible, and obturate the root-canal system in its entirety to prevent bacterial recontamination and to incarcerate residual bacteria, without extrusion beyond the apical terminus. Our understanding of the nature of the root-canal infection may be developing, but unless this is followed by development of treatment strategies, which are based on this new knowledge, then treatment outcomes are unlikely to improve. One highly desirable development would be the ability to identify bacteria persisting in the root canal with a simple chairside test. Culture testing was once a common part of endodontic treatment; as molecular testing improves, hopefully it can be introduced into the clinical environment to better inform the clinician of his treatment options.

Chemical disinfection plays a large part in the overall preparation phase of root-canal treatment, yet its importance is overlooked by a large number of practitioners, who instead look to the continually evolving file systems with which canals are prepared to improve their treatment. Whilst these file systems may make treatment more efficient, do they make it more efficacious? Only if the time saved in the shaping of the root canal is then devoted to its thorough disinfection, generally by chemical means.

The study of irrigation dynamics and the chemistry of existing and novel irrigants has only recently come under the spotlight. This area of research may give us insight into the way to better to disrupt and deactivate root-canal biofilms and in doing so improve our outcomes.

For the research to be relevant, robust experimental models must be developed that closely approximate to the clinical environment. It is an area that has been the subject of much study at the Eastman Dental Institute, with a number of papers recently published in the endodontic literature.

So, do we have the answer to our question? Success rates for endodontics, as evidenced by contemporary literature have stayed largely constant over the last century. Treatment objectives have remained similar within that period. If we are to improve our outcomes, then we need to let the science better inform our treatment procedures.

To summarise where science has brought us, we can return to the conclusions drawn by Prof Gulabivala at the end of his ESE lecture:

- \_ The nature of intra-radicular infection is complex in its diversity and biological interactions within it and with the host.
- \_ The nature of the infection and the host's reaction to it probably dictate the nature of clinical and radiographic presentation.
- \_ The nature of infection strongly influences the clinician's efforts to control it, and therefore the outcome.
- \_ The clinical presentation may provide a strong clue to the probable outcome of contemporary root-canal treatment.
- \_ The link between the technical aspects of contemporary root-canal treatment and biological events is non-specific at best.
- \_ Improvement of treatment success will require a better understanding of the nature of infection and ways to control it apically.

The answer then is yes; the biology does matter.\_

## about the authors

## roots



**Dr Alyn Morgan** graduated from the Leeds Dental Institute in 1995, and worked in private practice for twelve years. He was awarded an MSc in Endodontics from the UCL Eastman Dental Institute with distinction in 2009.

He currently works both in private practice and as a specialty doctor/clinical teacher in endodontics at the UCL Eastman Dental Institute. He can be contacted at [alyn.morgan@eastman.ucl.ac.uk](mailto:alyn.morgan@eastman.ucl.ac.uk).



**Dr Ian Alexander** graduated from the University of Newcastle Upon Tyne in 1991, and has worked in private practice for nineteen years. He attended the Eastman Certificate course in Endodontics in 2005 and was awarded an

MSc in Endodontics from the UCL Eastman Dental Institute with distinction in 2009. He currently works both in private practice and as a specialty doctor/clinical teacher in endodontics at the UCL Eastman Dental Institute. He can be contacted at [ian.alexander@eastman.ucl.ac.uk](mailto:ian.alexander@eastman.ucl.ac.uk).



# 2010

# GREATER NEW YORK DENTAL MEETING

## FREE REGISTRATION\*

MEETING DATES:  
NOVEMBER 26 -  
DECEMBER 1

EXHIBIT DATES:  
NOVEMBER 28 -  
DECEMBER 1

86<sup>th</sup>  
Annual Session

The  
Largest  
Dental  
Convention/  
Exhibition/  
Congress  
in the  
United  
States



*\*Free registration  
before November 26*

Please send me more information about...

- Attending the Greater New York Dental Meeting
- Participating as a guest host and receiving free CE
- I speak \_\_\_\_\_ and am willing to assist international guests  
enter language



Name \_\_\_\_\_

Address \_\_\_\_\_

City, State, Zip/Country Code \_\_\_\_\_

Telephone \_\_\_\_\_ E-mail \_\_\_\_\_

Fax or mail this to:  
Greater New York Dental Meeting or  
visit our website: [www.gnydm.com](http://www.gnydm.com) for more information.

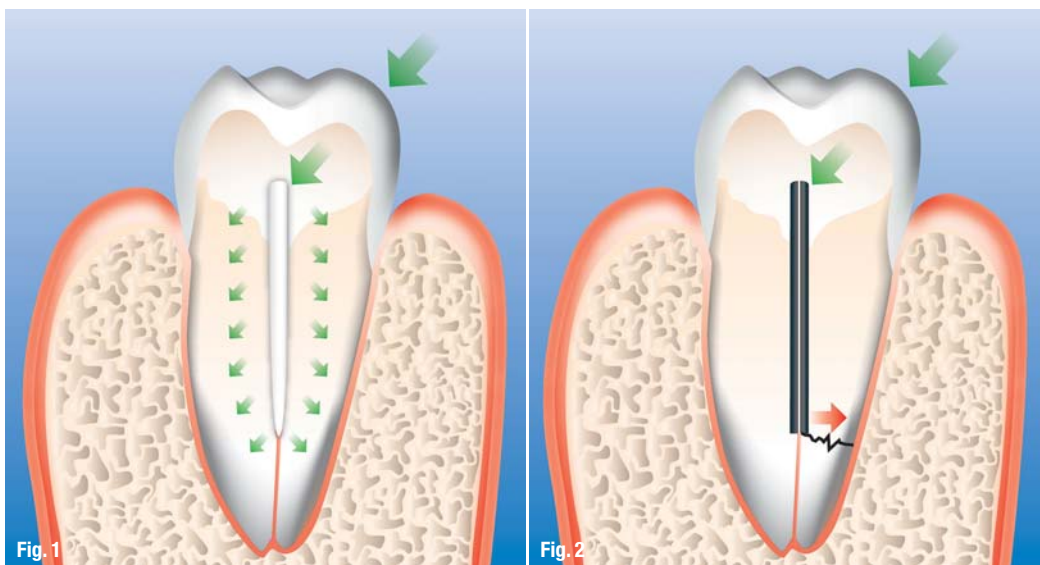


For More Information:  
Greater New York Dental Meeting™  
570 Seventh Avenue - Suite 800  
New York, NY 10018 USA  
Tel: +1 (212) 398-6922  
Fax: +1 (212) 398-6934  
E-mail: [info@gnydm.com](mailto:info@gnydm.com)  
Website: [www.gnydm.com](http://www.gnydm.com)

# Excellent: Rebilda Post System

Fig. 1\_Metal post: root fracture.

Fig. 2\_Rebilda Post: dentine-like elasticity.



*The Dental Advisor* has awarded VOCO's Rebilda Post System, the complete endodontic post build-up set, five out of five possible points. American dentists tested the system in over 200 applications and were impressed by both the range and simple handling of its components. Forty-six per cent of the dentists who participated in this evaluation rated the Rebilda Post System better than the endodontic product they normally used and stated that they would like to keep working with the system in the future.

## Dentine-like properties

With Rebilda Post, the glass-fibre reinforced, composite endodontic post, VOCO presented an ideal addition to Rebilda DC, the dual-curing core build-up and luting material. Rebilda Post allows for a durable and aesthetic, high-quality, metal-free restoration. Its dentine-like elasticity provides an even distribution of arising forces—in contrast with metal or ceramic posts—and it thus minimises the risk of root fractures. The high transverse strength therefore leads to excellent resistance to fatigue and fracture of the post and thus to a longer-lasting restoration. The cylindrical-conical geometry corresponds to the anatomical progression of the root, which facilitates a preparation that is gentle to the tooth substance.

Furthermore, the translucency has been perfectly adapted to the dentine. Rebilda Post combines outstanding optical properties with excellent radiopacity, high bio-compatibility and easy removal.

## The system concept

Rebilda Post is a component of a complete, coordinated post build-up system (Rebilda DC, Futurabond DC, Ceramic Bond and accessories). As with Rebilda DC—the proven core build-up material—the new endodontic post consists of a dimethacrylate matrix to allow for a reliable bond under the build-up of a stable mono-block. With Futurabond DC, a secure bond to the dentine is also achieved in a simple, time-saving application. The post-endodontic work is simplified with new endo-brushes (VOCO Endo Tim) and endo-tips.

This innovative endodontic post build-up set increases clinical safety, as all of the components are coordinated and at hand when endodontic treatment using posts is required. Rebilda Post is available in three sizes (1.2 mm, 1.5 mm, 2.0 mm) with the corresponding drills in both an endodontic introduction set and a complete system that is designed for 15 post-endodontic treatments.

## contact roots

VOCO GmbH  
P.O. Box 767  
27457 Cuxhaven  
Germany  
Website: [www.voco.com](http://www.voco.com)






تحت رعاية  
سمو الشيخ حمدان بن راشد آل مكتوم  
نائب حاكم دبي، وزير المالية  
رئيس هيئة الصحة بدبي



Under the patronage of  
**H. H. Sheikh Hamdan Bin Rashid Al Maktoum**  
Deputy Ruler of Dubai, Minister of Finance  
President of the Dubai Health Authority

مؤتمر الإمارات الدولي لطب الأسنان و معرض طب الأسنان العربي  
UAE International Dental Conference & Arab Dental Exhibition



Delivering Science & Technology

إيدك  
AEDDC®  
Dubai 2011

[www.aeddc.com](http://www.aeddc.com)



**Largest Dental Event**  
in the **Middle East & North Africa**

1 - 3 February, 2011

مركز دبي الدولي للمؤتمرات والمعارض  
Dubai International Convention & Exhibition Centre

Organised by



Strategic Partner



Supported by



For more information, call or visit our website

**INDEX® Conferences & Exhibitions Organisation Est.**

P.O. Box: 13636, Dubai - United Arab Emirates | Dubai Healthcare City, Ibn Sina Bldg. #27 Block B, Office 203  
Tel: +971 4 3624717 | Fax: +971 4 3624718 | E-mail: [index@emirates.net.ae](mailto:index@emirates.net.ae) | Website: [www.aeddc.com](http://www.aeddc.com)

# Why worry now?

**Author\_** Dr Philippe Van Audenhove, Belgium

**Images\_** Dr Stephane Browet, Belgium

**Fig. 1\_** Visual inspection confirms the symptoms of a cracked tooth.

**Fig. 2\_** Multiple cracks become clearly visible and help determine treatment options.

**Fig. 3\_** Occlusal decay. Visual inspection shows need for treatment.

**Fig. 4\_** Preparation confirms progress of decay far into dentine.

**Fig. 5\_** Magnification allows tissue-friendly treatment.

**Fig. 6\_** Precision through vision.

**\_Give me the top five reasons** that a dentist would NOT wish to buy an operating microscope:

1. I am not an endodontist. I refer clients who require endodontic treatment.
2. I have always worked like this, with the naked eye. No patient ever complained!
3. Microscopes are a fad; the hype won't last!
4. Microscopes are very expensive and don't generate income.
5. I have plenty of work. I don't need to invest to attract new patients!

Now, let us take a closer look at these arguments:

1. *I am not an endodontist. I refer clients who require endodontic treatment.* Many endodontists will agree that a microscope is only useful in the coronal third part of the root canal. After the first curve of the canal, you can't see anything, not even with a microscope. Therefore, all other dental disciplines have far more advantages using a microscope because all dental surfaces are clearly visible.
2. *I have always worked like this, with the naked eye. No patient ever complained!* Would you feel the same way about your cardiologist observing your heart valves without an echocardiogram or your wife's gynaecologist following up on her pregnancy with just a stethoscope?
3. *Microscopes are a fad; the hype won't last!* It did last with ophthalmologists, otorhinolaryngologists, gynaecologists and surgeons. I admit it wasn't such a success with psychiatrists, but believe me, microscope magnification is here to stay.
4. *Microscopes are very expensive and don't generate income.* Money isn't all that counts. Consider the financial benefits, joy in your work, well-informed and motivated patients and team—no money can buy them, but you certainly can with a microscope.
5. *I have plenty of work. I don't need to invest to attract new patients!* Indeed. So the time to invest in a microscope is when you have neither patients nor income?! You know better than that! It is time to invest when things are going well.

The main reasons for rejecting the idea of an operating microscope are comfort zones and fear of change. Starting to work with a microscope in your

dental office requires some motivation and an open mind. Patients' reactions are rewarding. They feel like someone is finally taking their teeth seriously.

Imagine you go to two jewellery shops with your mother's family jewels to have their value estimated. The first jeweller takes the rings in his hand, shakes them like dice, looks at them from afar and tells you what they are worth. At the jewellery shop next door, the jeweller measures the rings, weighs them and inspects them with a magnifying glass. He has you look at them too with the magnifying glass, pointing out the stones' cut and their qualities and defects. Finally, he comes up with a value that differs from that given by the previous jeweller. Honestly, whose expertise would you most value?

We as dentists realise that teeth are the natural jewels of the mouth. Any motivated patient will appreciate your treating his or her teeth as such.

Of course, working with an operating microscope requires some training. However, any dentist can learn this and taking courses in this will speed up the process tremendously. The European Society of Microscope Dentistry aims to provide training and lectures for both the experienced microscope user and the beginner. The enthusiasm of the lecturers is such that they readily give advice even in-between courses. See for yourself and join us at ESMD 2010, to be held on 16–18 September 2010 in Vilnius in Lithuania.

'SEEING IS BELIEVING':\_

| _contact  | roots |
|---|-------|
| <p><b>ESMD Secretariat</b><br/>                     ViaConventus<br/>                     Olimpieciu Str. 1–34<br/>                     09200 Vilnius<br/>                     Lithuania</p> <p>Tel.: +370 5 2000778<br/>                     Fax: +370 5 2000782<br/>                     E-mail: info@esmd2010.com   ph.va@wol.be<br/>                     Websites: www.esmd.info   www.esmd2010.com</p> |       |

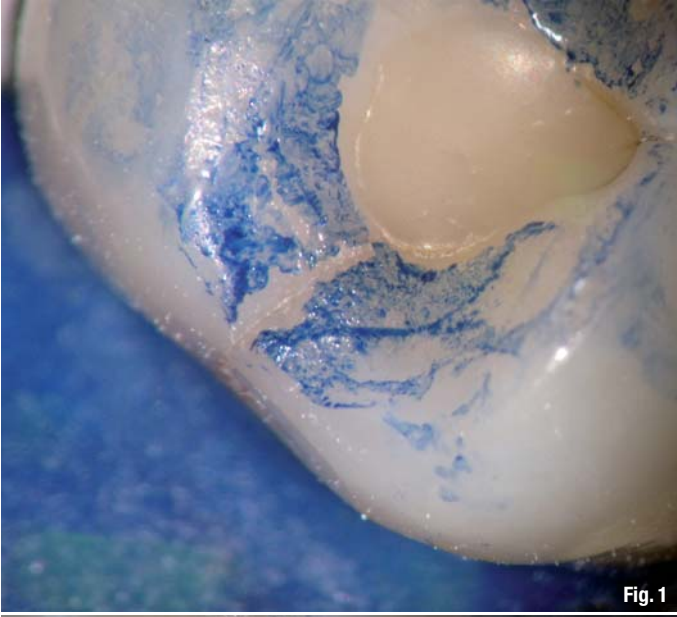


Fig. 1

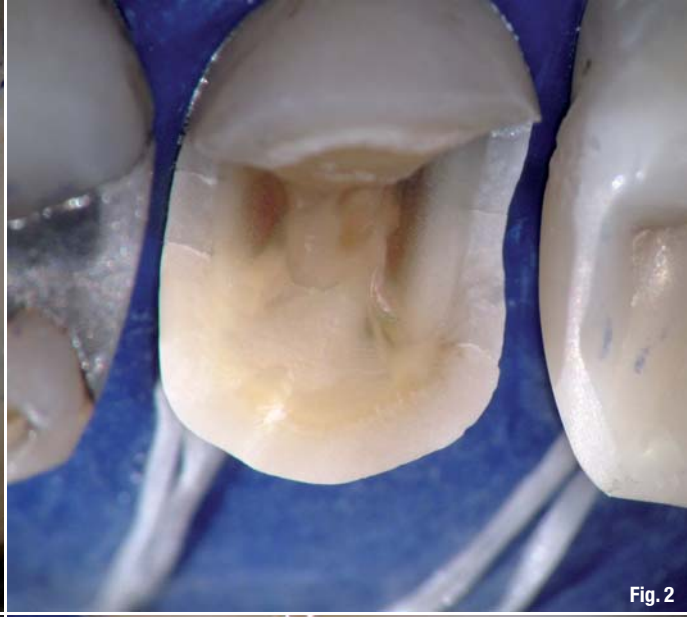

Fig. 2

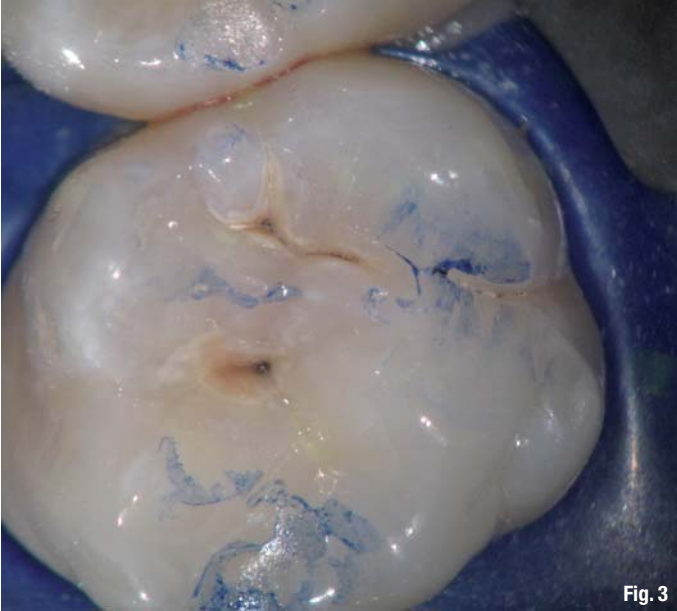

Fig. 3

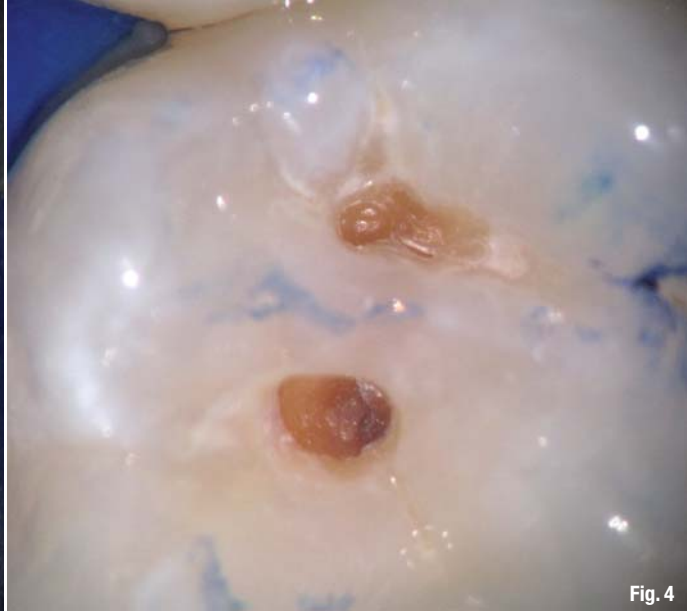

Fig. 4

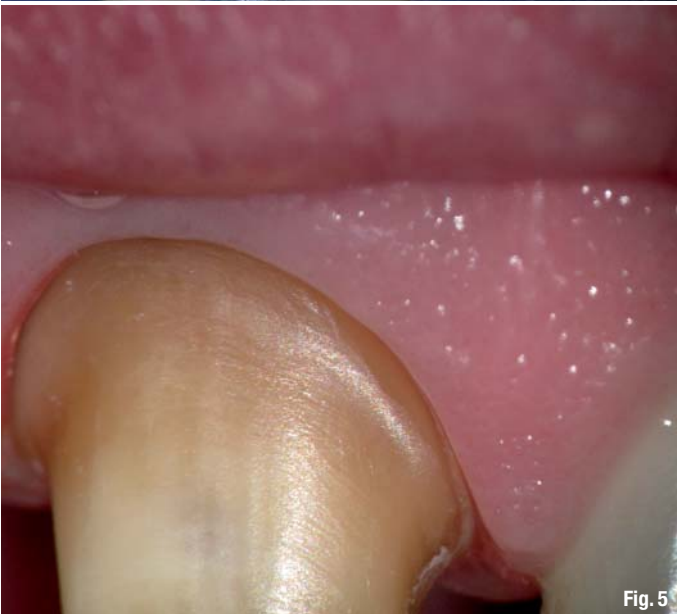

Fig. 5

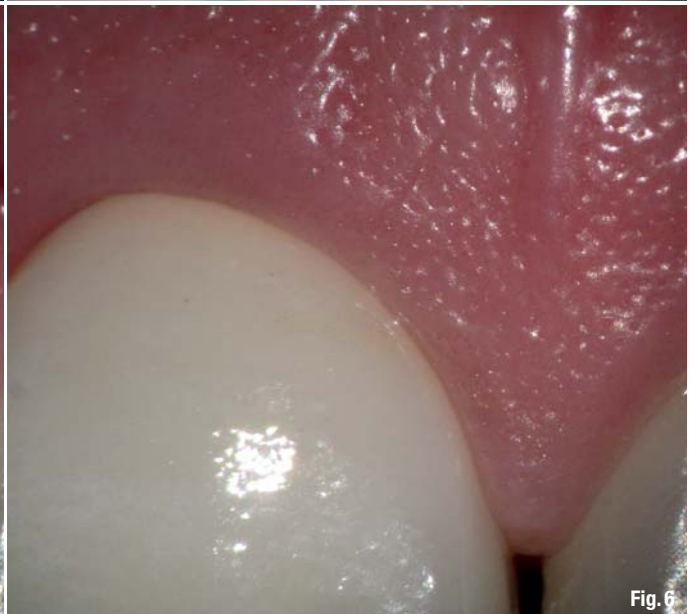

Fig. 6



# AAE hosts first **live CT-guided endodontic surgery**

**Author\_** Sierra Rendon, USA

**\_On 16 April 2010**, the first live demonstration of a cutting-edge endodontic surgical procedure was presented at the American Association of Endodontists annual scientific session in San Diego.

Performed by Dr L. Stephen Buchanan, the experimental procedure—CT-guided endodontic Surgery (GES)—used SimPlant surgical treatment planning software (Materialise) to plot an ideal path to the diseased mesio-buccal (MB) root and bone of an upper first molar. This was followed by the digital fabrication of a SimPlant drill guide to transfer the treatment planned in computer space to the patient's jaw.

While this drilled guide software has been used successfully for many years in implant dentistry, it had not been previously used for endodontic surgery.

Dr Buchanan said he was introduced to the GES concept when he trained for implant surgery. His friend, the late Dr David Rosenberg, to whom he dedicated this procedure, taught him that drill guides can greatly improve surgical speed and accuracy during implant placement. When a graduate student at UCLA asked whether CT-generated drill guides could work for endodontic surgery, he said that his whole concept of endodontic surgery changed. Surprisingly, upon conducting a literature search, Buchanan found out this concept was first brought into the public domain in 2007.<sup>1</sup>

For the several hundred endodontists who watched this live demonstration, it was clear this was not yet a more efficient procedure. The potential, however, was evident.

Perhaps the most time-consuming part of the demonstration was the placement of a screw-fixed retraction fence he designed, but once the two 1.5 mm bone screws had been set, retraction of the mucosa overlying the drill path required no more effort on Buchanan's part.

He noted that inefficient tissue retraction is probably the largest barrier to shortening surgical times dramatically, and this aspect of GES is obviously a work in progress.

Despite the challenge of placing the retraction fence and dealing with significant bleeding (the patient had high blood pressure), drilling through the guide, to length, with the 2, 3, 4 and 5 mm drills was very straightforward.

After the drill guide had been removed, Buchanan captured a micro-mirror view through the resulting 5 mm drill hole—showing the MB root cut perfectly with the previously treated MB1 canal bisected and beyond it, toward the palatal aspect, a darkened isthmus that led directly to the previously untreated MB2 canal.

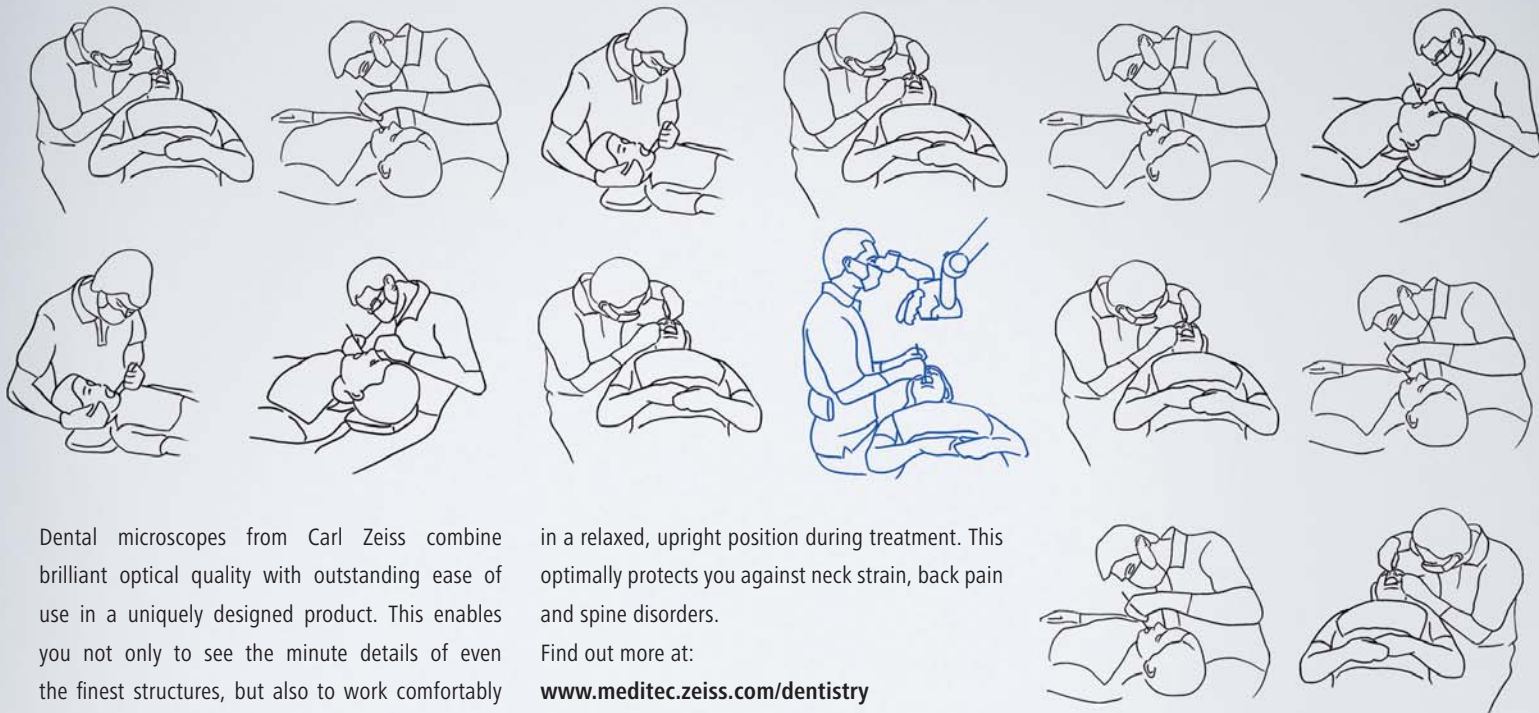
He then negotiated and enlarged the MB2 canal through the resected root-end using 0.04 tapered rotary NiTi files in sizes #15/40. He said the 0.04 taper limitation reduced the accumulation of cyclic fatigue caused by the flexure of the files past the cut root surface, allowing him to cut a larger diameter of preparation to the coronal extent of the canal than would have been possible with instruments that were more tapered.

Filling this canal created some additional challenges. However, Dr Buchanan was able to accomplish this with a pressure syringe loaded with pink Cavit and a 27-gauge needle, resulting in a dense fill all the way to the pulp chamber. Dr Buchanan typically uses Cavit because: a) it sets in the presence of moisture; b) it seals against leakage as well as MTA does; and c) its viscosity allows it to be syringed quite a distance from the end of the needle.

An alternative with which he has been experimenting is filling apically instrumented canals with a carrier-based obturator. While early results look good (excellent fills and much less time and frustration), he chose to do the more familiar technique—perhaps for the last time.

AD

## Stand out above the rest!



Dental microscopes from Carl Zeiss combine brilliant optical quality with outstanding ease of use in a uniquely designed product. This enables you not only to see the minute details of even the finest structures, but also to work comfortably

in a relaxed, upright position during treatment. This optimally protects you against neck strain, back pain and spine disorders.

Find out more at:

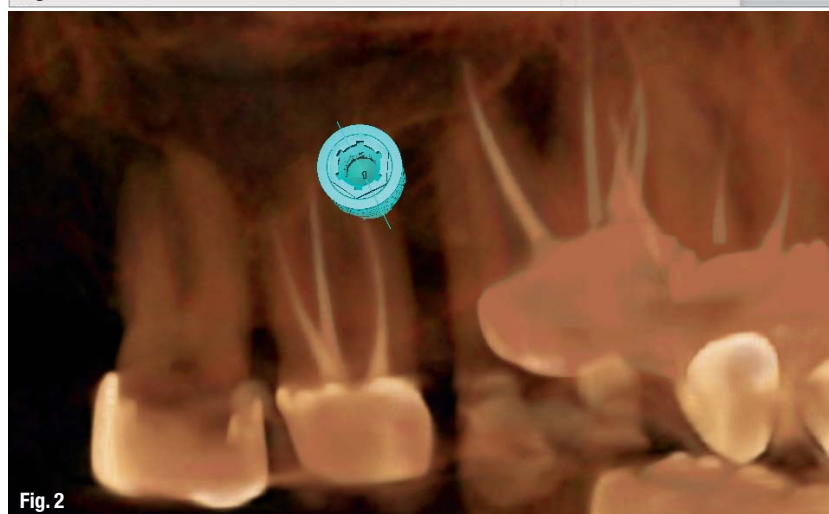
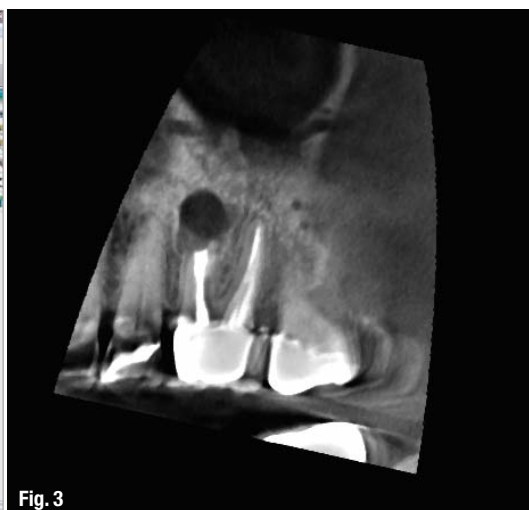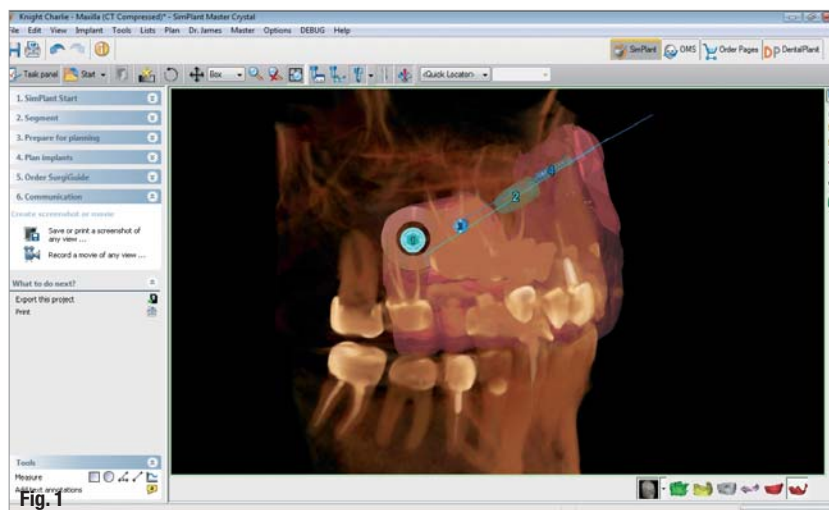
[www.meditec.zeiss.com/dentistry](http://www.meditec.zeiss.com/dentistry)

### Carl Zeiss Surgical GmbH

A Carl Zeiss Meditec Company  
Carl-Zeiss-Strasse 22  
73447 Oberkochen  
Germany

Fax: +49 (0) 73 64/20-48 23  
surgical@meditec.zeiss.com  
[www.meditec.zeiss.com/dentistry](http://www.meditec.zeiss.com/dentistry)  
[www.meditec.zeiss.com/contacts](http://www.meditec.zeiss.com/contacts)





**Figs. 1 & 2** Treatment planning using SimPlant software from Materialise to perfectly position the drill guide over the root end.

**Fig. 3** Post-operative X-ray showing a very accurate circular osteotomy and apicesection from the drill guides as well as a very dense MTA retro-fill in the trough preparation between the MB1 and MB2 canals.

Following the fill of the MB2 canal, Dr Buchanan brought in one of his newest ultrasonic tip designs, which he referred to as an Isthmus Hatchet (IH; Spartan). Three millimetres in length and 0.4 mm wide, with acute angles on each end, the IH literally dropped down into the root through the centre of the isthmus, resulting in a very smooth, straight-walled retro-preparation.

The apical retro-seal was done with grey ProRoot MTA (DENTSPLY Tulsa) because Dr Buchanan likes the handling characteristics more than the white MTA used in aesthetic areas.

The MTA was delivered with Tulsa's MTA tube carrier/condenser in 5 to 6 aliquots, and condensed using a hatchet plugger (HP) made to fit the preparation made using the IH. A conventional digital radiograph confirmed a dense retro-fill, and the minimally invasive flap was sutured with four 5-0 Supramid sutures.

A CT scan was done then with a Veraviewepocs 3D cone-beam CT machine (J. Morita), showing the final result with the MB2 canal and the apical preparation densely and completely filled.

When attendees were asked their opinion of the demonstration and the new GES procedure, the most consistent response was firstly that Buchanan demonstrated much courage doing an experimental procedure in front of his peers, and secondly that although it is not there yet, the potential benefits of GES are many.

What is up next for Buchanan and the engineering team at Materialise? The next six months to a year will be spent on treatment planning and performing the hundreds of procedures needed to bring this procedure successfully into the mainstream of clinical endodontics, as well as establishing university-based research projects to bring GES into peer-reviewed literature.


At this point, Dr Buchanan says: "The iterative design process will take this from a fascinating but slow way to do endodontic surgery, to an elegant procedure that is much faster, much more precise, and that requires less training than traditional methods."

The American Association of Endodontists welcomed about 4,000 people to its annual meeting in sunny San Diego. The focus of the meeting, which was expanded to four full days this year, was *Access to Apex, Education and Care*, and offered endodontic specialists 232 CE hours in 120 courses. In addition to the vast learning and educational opportunities, dozens of exhibitors showcased the newest and most innovative endodontic products on the market. Next year's meeting will be held in San Antonio, Texas, from 13–16 April 2011. For more information, see the AAE Website at [www.aae.org](http://www.aae.org).

#### Reference

Pinsky H, Champlébox G, Sarment D. Periapical surgery using CAD/CAM guidance: Preclinical results. *Journal of Endodontics*, 33/2 (2007), 148–151.

# FDI Annual World Dental Congress 2-5 September 2010 Salvador da Bahia, Brazil



[congress@fdiworldental.org](mailto:congress@fdiworldental.org)  
[www.fdiworldental.org](http://www.fdiworldental.org)



BRAZIL  
SALVADOR  
DA BAHIA 2010

# International Events

## 2010

### Roots Summit 2010

Where: Barcelona, Spain  
Date: 3–5 June 2010  
E-mail: [info.roots@evento.es](mailto:info.roots@evento.es)  
Website: [www.evento.es](http://www.evento.es)

### NEF Annual Meeting

Where: Larvik, Norway  
Date: 4–6 June 2010  
Website: [www.endodonti.no](http://www.endodonti.no)

### SFE International Congress 2010

Where: Nancy, France  
Date: 25 & 26 June 2010  
E-mail: [contacts@sf-endo.com](mailto:contacts@sf-endo.com)  
Website: [www.sf-endo.com](http://www.sf-endo.com)

### IADR General Session & Exhibition

Where: Barcelona, Spain  
Date: 14–17 July 2010  
E-mail: [sherren@iadr.org](mailto:sherren@iadr.org)  
Website: [www.iadr.org](http://www.iadr.org)

### SkandEndo 2010

Where: Espoo, Finland  
Date: 19–21 August 2010  
Website: [www.osf.fi](http://www.osf.fi)

### COSAE 2010

Where: Buenos Aires, Argentina  
Date: 26–28 August 2010  
E-mail: [sae@aoa.org.ar](mailto:sae@aoa.org.ar)

### FDI Annual World Dental Congress

Where: Salvador da Bahia, Brazil  
Date: 2–5 September 2010  
E-mail: [congress@fdiworldental.org](mailto:congress@fdiworldental.org)  
Website: [www.fdiworldental.org](http://www.fdiworldental.org)

### International Congress of the Turkish Endodontic Society

Where: Istanbul, Turkey  
Date: 23–25 September 2010  
E-mail: [www.endoistanbul2010.com](http://www.endoistanbul2010.com)

### 8<sup>th</sup> IFEA World Congress

Where: Athens, Greece  
Date: 6–9 October 2010  
E-mail: [IFEASecretary@aol.com](mailto:IFEASecretary@aol.com)  
Website: [www.ifea2010-athens.com](http://www.ifea2010-athens.com)

### Trans-Tasman Endodontic Conference

Where: Christchurch, New Zealand  
Date: 4–6 November 2010  
E-mail: [info@tteconference.com](mailto:info@tteconference.com)  
Website: [www.tteconference.com](http://www.tteconference.com)

### DGEndo Annual Meeting

Where: Berlin, Germany  
Date: 4–6 November 2010  
E-mail: [sekretariat@dgendo.de](mailto:sekretariat@dgendo.de)  
Website: [www.dg-endo.de](http://www.dg-endo.de)

## 2011

### 34<sup>th</sup> International Dental Show

Where: Cologne, Germany  
Date: 22–26 March 2011  
E-mail: [ids@koelnmesse.de](mailto:ids@koelnmesse.de)  
Website: [www.ids-cologne.de](http://www.ids-cologne.de)





## submission guidelines:

Please note that all the textual components of your submission must be combined into one MS Word document. Please do not submit multiple files for each of these items:

- \_ the complete article;
- \_ all the image (tables, charts, photographs, etc.) captions;
- \_ the complete list of sources consulted; and
- \_ the author or contact information (biographical sketch, mailing address, e-mail address, etc.).

In addition, images must not be embedded into the MS Word document. All images must be submitted separately, and details about such submission follow below under image requirements.

### Text length

Article lengths can vary greatly—from 1,500 to 5,500 words—depending on the subject matter. Our approach is that if you need more or less words to do the topic justice, then please make the article as long or as short as necessary.

We can run an unusually long article in multiple parts, but this usually entails a topic for which each part can stand alone because it contains so much information.

In short, we do not want to limit you in terms of article length, so please use the word count above as a general guideline and if you have specific questions, please do not hesitate to contact us.

### Text formatting

We also ask that you forego any special formatting beyond the use of italics and boldface. If you would like to emphasise certain words within the text, please only use italics (do not use underlining or a larger font size). Boldface is reserved for article headers. Please do not use underlining.

Please use single spacing and make sure that the text is left justified. Please do not centre text on the page. Do not indent paragraphs, rather place a blank line between paragraphs. Please do not add tab stops.

Should you require a special layout, please let the word processing programme you are using help you do this formatting automatically. Similarly, should you need to make a list, or add footnotes or endnotes, please let the word processing programme do it for you automatically. There are menus in every programme that will enable you to do so. The fact is that no matter how carefully done, errors can creep in when you try to number footnotes yourself.

Any formatting contrary to stated above will require us to remove such formatting before layout, which is very time-consuming. Please consider this when formatting your document.

### Image requirements

Please number images consecutively throughout the article by using a new number for each image. If it is imperative that certain images are grouped together, then use lowercase letters to designate these in a group (for example, 2a, 2b, 2c).

Please place image references in your article wherever they are appropriate, whether in the middle or at the end of a sentence. If you do not directly refer to the image, place the reference at the end of the sentence to which it relates enclosed within brackets and before the period.

In addition, please note:

- \_ We require images in TIF or JPEG format.
- \_ These images must be no smaller than 6x6 cm in size at 300 DPI.
- \_ These image files must be no smaller than 80 KB in size (or they will print the size of a postage stamp!).

Larger image files are always better, and those approximately the size of 1 MB are best. Thus, do not size large image files down to meet our requirements but send us the largest files available. (The larger the starting image is in terms of bytes, the more leeway the designer has for resizing the image in order to fill up more space should there be room available.)

Also, please remember that images must not be embedded into the body of the article submitted. Images must be submitted separately to the textual submission.

You may submit images via e-mail, via our FTP server or post a CD containing your images directly to us (please contact us for the mailing address, as this will depend upon the country from which you will be mailing).

Please also send us a head shot of yourself that is in accordance with the requirements stated above so that it can be printed with your article.

### Abstracts

An abstract of your article is not required.

### Author or contact information

The author's contact information and a head shot of the author are included at the end of every article. Please note the exact information you would like to appear in this section and format it according to the requirements stated above. A short biographical sketch may precede the contact information if you provide us with the necessary information (60 words or less).

### Questions?

Claudia Salwiczek (Managing Editor)  
c.salwiczek@oemus-media.de

# roots

international magazine of endodontology

## Publisher

Torsten R. Oemus  
[oemus@oemus-media.de](mailto:oemus@oemus-media.de)

## CEO

Ingolf Döbbecke  
[doebbecke@oemus-media.de](mailto:doebbecke@oemus-media.de)

## Members of the Board

Jürgen Isbaner  
[isbaner@oemus-media.de](mailto:isbaner@oemus-media.de)

Lutz V. Hiller

[hiller@oemus-media.de](mailto:hiller@oemus-media.de)

## Managing Editor

Claudia Salwiczek  
[c.salwiczek@oemus-media.de](mailto:c.salwiczek@oemus-media.de)

## Executive Producer

Gernot Meyer  
[meyer@oemus-media.de](mailto:meyer@oemus-media.de)

## Designer

Josephine Ritter  
[j.ritter@oemus-media.de](mailto:j.ritter@oemus-media.de)

## Copy Editors

Sabrina Raaff  
Hans Motschmann

## Published by

Oemus Media AG  
Holbeinstraße 29  
04229 Leipzig, Germany  
Tel.: +49-341/4 84 74-0  
Fax: +49-341/4 84 74-2 90  
[kontakt@oemus-media.de](mailto:kontakt@oemus-media.de)  
[www.oemus.com](http://www.oemus.com)

## Printed by

Messedruck Leipzig GmbH  
An der Hebemärchte 6  
04316 Leipzig, Germany

## Editorial Board

Fernando Goldberg, Argentina  
Markus Haapasalo, Canada  
Ken Serota, Canada  
Clemens Bargholz, Germany  
Michael Baumann, Germany  
Benjamin Briseno, Germany  
Asgeir Sigurdsson, Iceland  
Adam Stabholz, Israel  
Heike Steffen, Germany  
Gary Cheung, Hong Kong  
Unni Endal, Norway  
Roman Borczyk, Poland  
Bartosz Cerkaski, Poland  
Esteban Brau, Spain  
José Pumarola, Spain  
Kishor Gulabivala, United Kingdom  
William P. Saunders, United Kingdom  
Fred Barnett, USA  
L. Stephan Buchanan, USA  
Jo Dovgan, USA  
Vladimir Gorokhovskiy, USA  
James Gutmann, USA  
Ben Johnson, USA  
Kenneth Koch, USA  
Sergio Kuttler, USA  
John Nusstein, USA  
Ove Peters, USA  
Jorge Vera, Mexico



Claudia Salwiczek, Managing Editor



## Copyright Regulations

\_roots international magazine of endodontology is published by Oemus Media AG and will appear in 2010 with one issue every quarter. The magazine and all articles and illustrations therein are protected by copyright. Any utilisation without the prior consent of editor and publisher is inadmissible and liable to prosecution. This applies in particular to duplicate copies, translations, microfilms, and storage and processing in electronic systems.

Reproductions, including extracts, may only be made with the permission of the publisher. Given no statement to the contrary, any submissions to the editorial department are understood to be in agreement with a full or partial publishing of said submission. The editorial department reserves the right to check all submitted articles for formal errors and factual authority, and to make amendments if necessary. No responsibility shall be taken for unsolicited books and manuscripts. Articles bearing symbols other than that of the editorial department, or which are distinguished by the name of the author, represent the opinion of the afore-mentioned, and do not have to comply with the views of Oemus Media AG. Responsibility for such articles shall be borne by the author. Responsibility for advertisements and other specially labeled items shall not be borne by the editorial department. Likewise, no responsibility shall be assumed for information published about associations, companies and commercial markets. All cases of consequential liability arising from inaccurate or faulty representation are excluded. General terms and conditions apply, legal venue is Leipzig, Germany.

# cosmetic dentistry \_ beauty & science



 **Subscribe now!**

**One issue free of charge!**

I hereby agree to receive a free trial subscription of **cosmetic dentistry** \_ beauty & science (4 issues per year).

I would like to subscribe to **cosmetic dentistry** (€ 44\* for German customers; € 46\* for customers outside of Germany) unless a written cancellation is sent within 14 days of the receipt of the trial subscription. The subscription will be renewed automatically every year until a written cancellation is sent to OEMUS MEDIA AG, Holbeinstr. 29, 04229 Leipzig, Germany, six weeks prior to the renewal date.

▶ **Reply** via Fax +49 (0) 3 41/4 84 74-2 90 or via E-mail to [grasse@oemus-media.de](mailto:grasse@oemus-media.de)

Last Name, First Name

Company

Street

ZIP/City/County

E-mail

Signature

Notice of revocation: I am able to revoke the subscription within 14 days after my order by sending a written cancellation to OEMUS MEDIA AG, Holbeinstr. 29, 04229 Leipzig, Germany.

Signature



## ADHESIVE CORE BUILD-UP SYSTEM

Complete set for 15 post-endodontic treatment

- Effective five step system
- Monoblock formation of tooth, post and build-up
- Futurabond and Ceramic Bond for highest stability
- Aesthetic foundation for prosthetic restorations

# Rebilda Post system

