

Rehabilitation of **atrophic maxillas** using zygomatic implants

A literature review

Authors Joan Pi-Urgell¹, Javier Mir-Mari², Rui Figueiredo & Cosme Gay-Escoda³, Spain

_ Introduction

Zygomatic implants, first introduced by Brånemark in 1988, are especially suitable for patients with advanced atrophy of the maxilla and who refuse or have suffered a complication after bone grafting procedures. The few studies with large samples and adequate follow-ups¹⁻⁶, show excellent results. Survival and success rates, as well as, the incidence of complications are detailed below based on a Medline review on zygomatic implant papers.

Traditionally, these implants had a palatal emergence, crossed the maxillary sinus and were anchored in the zygomatic bone. Nowadays, the palatal emergence can be avoided by using the "extramaxillary" implants technique, where the zygomatic implant goes through the lateral wall of the maxillary sinus. The high survival rates (higher than 90%) and the low incidence of complications reported in the reviewed papers, make zygomatic implants a good treatment option for the rehabilitation of severely resorbed maxillas. In this paper, the authors will address the anatomy of the region, the indications of these implants, the several available surgical techniques, the survival rates and complications.

_The zygomatic implant

The classical zygomatic fixture design (Brånemark Osseointegration Centre and Exopro, Gothenburg, Sweden) was a self-tapping implant in c.p. (commercially pure) titanium with a well-defined machined surface. It was available in different lengths ranging from 30 to 52.5 mm, and was slightly tapered (coronal diameter of 4.5 mm

and apical diameter of 4.0 mm). This diameter variation was due to the necessity of increasing the anchorage at the alveolar process while reducing the risk of complications (orbital bleeding, infraorbital nerve affection, etc.) in the apical region. The coronal portion of the implant presented a tilted connection of 45° to facilitate the prosthetic rehabilitation.¹

At present, this implant has a rough surface and the coronal portion of the implants may present different angles ranging from 25° to 55°. Boyes-Varley et al.⁷ proposed a 55° angle in order to avoid the palatal emergence of the prosthetic connection, which is one of the most discussed inconveniences of these fixtures.

_Anatomical basis for the zygomatic implant

The zygomatic bone could be compared to a pyramid, offering a solid anatomic structure for implant anchorage.⁸ A histological analysis of this area revealed the presence of a regular and dense bone with very high osseous density (up to 98%).⁹ Due to these features, the zygomatic bone has already been used to place miniplates as a part of the orthodontic treatment. According to an anatomical study, the mean length of useful bone in this region is 14 mm.¹⁰

_Indications of the technique

According to Malevez et al.⁶ and Aparicio et al.¹¹ the zygomatic implants are a valid alternative to bone grafting in patients with advanced maxillary atrophy. This technique would be suitable when the following conditions are present:

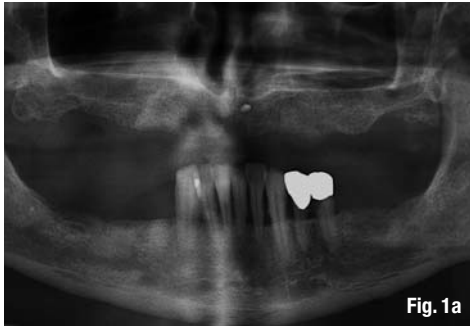

Fig. 1a

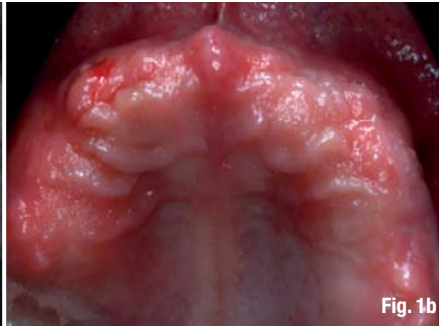


Fig. 1b

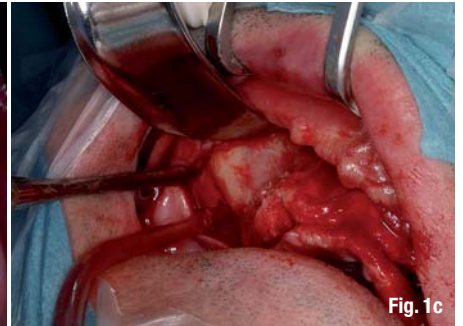


Fig. 1c

1. Light to moderate bone atrophy in the anterior region of the maxilla, with a posterior resorption of the alveolar process: This situation allows the placement of two to four implants in the anterior region, but the resorption of the posterior maxilla makes the placement of standard fixtures in this area unfeasible. In this case two zygomatic implants will be placed, one for each side.

2. Advanced atrophy of the maxilla (anterior and posterior): In this case two options are available: the use of bone grafting techniques in the anterior region can be performed and the placement of two zygomatic implants for the posterior region; or the placement of four zygomatic implants, two on each side without any anterior standard implants.

Presurgical evaluation

Maxilla, maxillary sinus and zygomatic bone are the three main structures to be considered before surgery. A panoramic radiography, a computed tomography (CT), as well as an adequate clinical examination are paramount to perform a correct diagnosis and treatment planning of the case (Figs. 1a & b).

The presence of sinus pathology might compromise the final result and the survival of the zygomatic implants, so it is essential to treat this kind of conditions before the surgical procedure.⁶

Surgical procedure

General anaesthesia in conjunction with the administration of a local anaesthetic is the traditional recommendation for the management of patient undergoing zygomatic implants placement. More recently, some authors have also used intravenous conscious sedation techniques for the same purpose.¹²

Blocks of the alveolar superior nerves, infraorbital nerves, and palatal nerves² are required.

A buccal approach using the traditional Le Fort I incision, can be made between the first molar regions¹ (Fig. 1c). Another option is to perform a crestal incision allowing improved palatal access for implant placement.² After raising the mucoperiosteal flap, soft tissue dissection has to be extended along the inferior and frontal lateral surfaces of the zygomatic bone, with identification of the infraorbital foramen. Special care has to be taken to avoid invasion of the orbit or sectioning the insertion of the masseter muscles in excess, as important bleeding could occur. The palatal mucosa has then to be detached, especially in the zone of the second premolar/first molar. Afterwards, a 10 x 5 mm infrazygomatic window in the lateral wall of the maxillary sinus should be created to keep the Schneiderian membrane intact (Fig. 1d). This window should allow the observation of the drilling sequence as well as the implant placement (Figs. 1 e–g). Brånemark et al.¹ recommend to place a gauze soaked in adren-

Fig. 1a_Preoperative panoramic radiography of a 54-year-old male with total maxillary edentulism.

Fig. 1b_ Preoperative aspect of the maxilla.

Fig. 1c_Raising of the mucoperiosteal flap up to the zygomatic arch.

Fig. 1d_Performing a lateral sinus window with a bone scraper.

Fig. 1e_Drilling from the 2nd premolar- 1st molar region to the zygomatic bone.

Fig. 1f_The machined surface zygomatic implant. Notice that the main anchorage site is the zygomatic bone and the residual crestal bone.

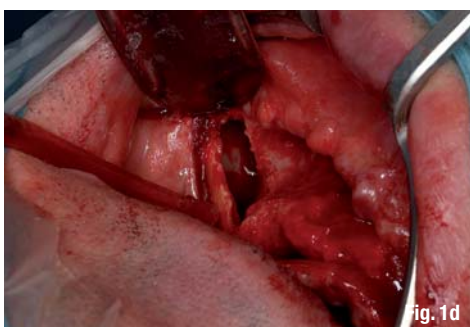


Fig. 1d

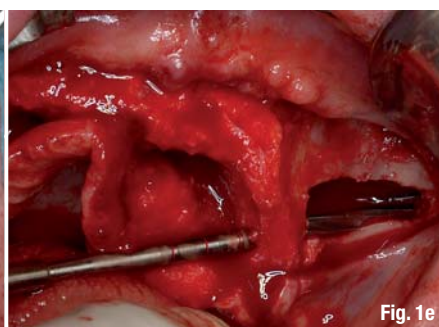


Fig. 1e

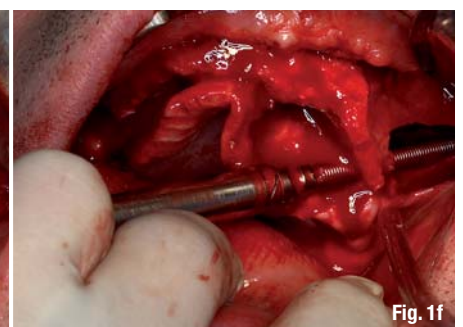


Fig. 1f

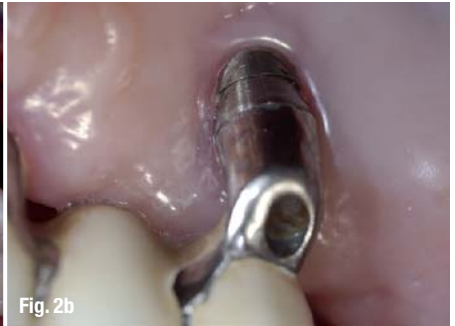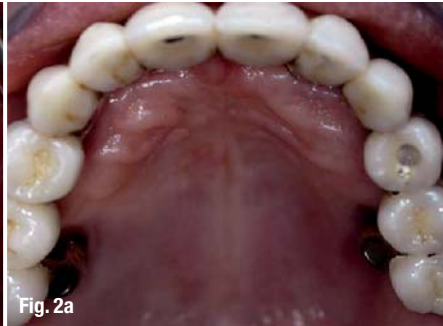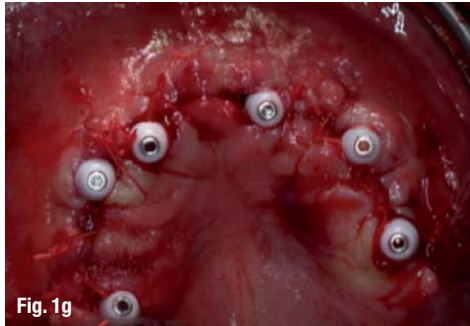


Fig. 1g_Final aspect of the maxilla. See the abutments for immediate loading and the palatal position of the distal implant in the first quadrant.

Fig. 2a_Metal-ceramic full-arch rehabilitation with four anterior implants and two zygomatic implants. Notice the palatal emergence of the zygomatic implants.

Fig. 2b_Detail of the palatal emergence.

align inside the sinus for a few minutes to prevent bleeding and deter mucosal tissue from blocking the view.

Technique modifications

The main disadvantage of this technique is related to the palatal emergence (Figs. 2a & b) of the implants that complicates the design of the prosthesis, reduces the patient's ability to speak and compromises the long-term health of the peri-implant tissues due to the difficulty that patients have to clean this area. Secondly, due to the intrasinus path of the implants the risk of sinus pathology development must be considered.²

Recently, some authors have proposed modifications of the classical technique described before. We would like to emphasize the following:

Extramaxillary implants

Basically, it consists of a modification of the implant entrance in the alveolar process and its trajectory up to the zygomatic bone.¹⁴ In this technique, the implant emergence is located just in the middle of the alveolar process, hence correcting the palatal entrance of the Brånemark technique. In its trajectory to the zygomatic bone, the fixture goes through the lateral sinus wall keeping the Schneiderian membrane intact. This technique not only improves the design of the prosthesis but also seems to reduce the incidence of sinusitis. Malo et al.¹⁴ and Aparicio et al.¹⁵ have already published some reports with excellent results (98.5–100% survival rates). On the other hand, the main complaint would be the fact that the middle part of the implant rests in direct contact with the soft tissue of the cheek.

Zygomatic implants without anterior standard implants

Frequently, the high degree of maxillary atrophy of these patients forces the surgeon to perform bone grafting techniques in the anterior area of the maxilla in order to place four standard implants. A modification first described by Bothur et al.¹⁶ recommended the placement of four to six zygomatic

implants in order to avoid the need of anterior fixtures and therefore to reduce the necessity of bone grafting in this area. In a study with 40 edentulous skulls, with atrophic alveolar processes and premaxillas, Rossi et al.¹⁷ measured the distances between the alveolar process emergence at the canine region and the premolar/molar region to the zygomatic bone. The authors stressed the fact that the mean length of distance between the canine regions to the zygomatic bone was 53.42 mm and the maximum distance was 61.94 mm. Given that the longest commercially available implant is 52.5 mm, the authors emphasize the importance of a precise presurgical evaluation of the available distance when the placement of four zygomatic implants is planned.

Sinus-slot technique

Stella and Warner¹⁸ described this method in 2000. Mainly, the "slot technique" is a reduction of the sinus wall perforation doing a slot instead of a window. Likewise, this modification permits a good control of the drilling direction and insertion of the zygomatic fixture. Furthermore, according to the authors a higher amount of bone is preserved and also the flap size can be reduced, improving the patients' postoperative recovery. Peñarrocha et al.¹² published in 2007 a series of 21 cases with the "Slot technique" with a 100% survival rate, but the Schneiderian membrane was perforated in all cases, even though the incidence of sinus pathology was low (two cases).

Immediate loading

Traditionally, the zygomatic implant loading protocol has been a two-stage approach. Nowadays, just a few numbers of authors have published results with an immediate loading protocol. To our knowledge, the first case-series was published in 2006 by Bedrossian et al.¹⁹ The review included a total of 28 zygomatic implants and 55 standard implants that were loaded immediately after surgery. The authors reported very good results with a survival rate of 100% and without any complications. Other recent studies have also reported similar findings with survival rates ranging from 95.8% to 100%.^{4, 14, 15, 20-22}

Survival rates

The literature review revealed a mean survival rate for zygomatic implants higher than 90 %, regardless of the technique used. The most common option is the classical technique, with machined surface implants, in a two-stage loading protocol. Twelve of the 19 papers reviewed with follow-up, met this criteria.^{1-3, 5-7, 12, 23-27} The other alternatives also present very good results with 95.8–100 % survival rates.^{4, 14, 15, 19-22} A surprising outcome is that the survival rate of the standard implants placed in the anterior region is quite low (73–98 %). This is probably related to the high degree of resorption that surgeons find in this area, therefore requiring more complex grafting procedures.

A total of 1,163 zygomatic implants were found in our review of 19 articles with adequate follow-up. Twenty-three implants (2.0 %) were lost, 14 (60.1 %) during the osseointegration period and nine (39.1 %) after loading. These data can be observed in table 1.

Complications

Sixteen papers reported complications. Different authors comment as possible complications orbital lesions, maxillary sinus posterior wall and infratemporal fossa perforation, intraoperative bleeding, nerve lesions (infraorbital nerve), sinus pathology, lip lesion during the drilling, among others. Nevertheless, only some of these were actually registered in the reviewed studies (26 cases of sinus pathology^{1-3, 5, 12, 14, 22, 23, 26, 27}, seven cases of infraorbital nerve impairment^{3, 5}, six cases of lip lesion during drilling^{3, 23} and nine cases of suborbital haematoma^{3, 23}).

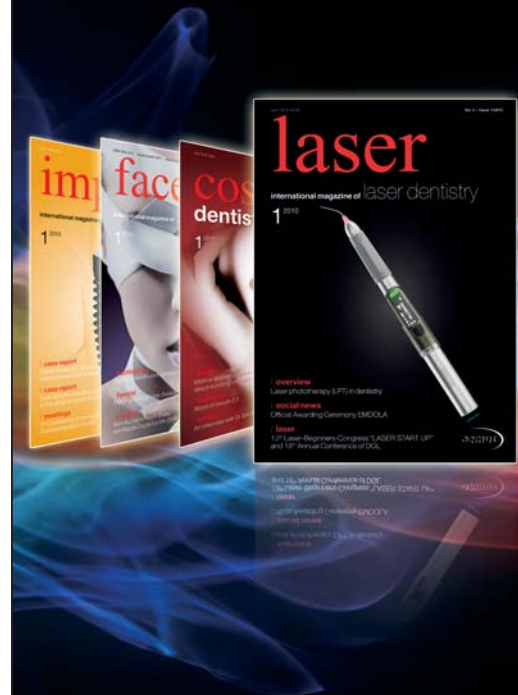It is important to stress that most of the cases with sinus pathology were favourably solved. Some of them only needed pharmacological therapy, while others were treated with an antrostomy surgery. Only three zygomatic implants, all from the same report²⁷, were removed due to their association with recurrent sinusitis.

Discussion

First of all, the few number of papers published related with zygomatic implants was surprisingly low, 59 articles in our Medline review (December, 2009). Among them, only 19 presented follow-up results.^{1-7, 12, 14, 15, 19-27} Moreover, most of the authors are broadly experienced oral surgeons, which may difficult the reproducibility of their results.

Among all published techniques and modifications, the most common treatment option published is the classical technique, with machined surface implants, in a two-stage loading protocol (12 studies).^{1-3, 5-7, 12, 23-27} Another important factor is that the majority of the studies have reduced samples (only five articles had more than 100 implants)^{2, 4-6} and short follow-up times (only Brånemark et al.¹ presented a follow-up of five to ten years). These are important limitations that need to be corrected in future research. Nevertheless, the placement of these implants seems to be a good treatment option since the published results so far are excellent, regardless of the used technique (95.8–100 %). On the other hand, the standard implants placed in the anterior region have low survival rates (73–98 %). These differences could be related with the grafting techniques used in combination with the cited conventional implants. Accordingly, Brånemark et al.¹ presented a 73 % survival rate of the standard implants, but in this study, 70 % of the patients received bone grafts in the same surgical procedure in which the anterior implants were placed.

The failure pattern of zygomatic implant is very similar to that of the standard implants. If one takes the studies cited in this review into account, a total of 23 implants



One issue free of charge!

Subscribe now! ✂

I hereby agree to receive a free trial subscription of **laser international magazine of laser dentistry** (4 issues per year). I would like to subscribe to cosmetic dentistry for € 44* for German customers, € 46* for customers outside Germany, unless a written cancellation is sent within 14 days of the receipt of the trial subscription. The subscription will be renewed automatically every year until a written cancellation is sent to OEMUS MEDIA AG, Holbeinstr. 29, 04229 Leipzig, Germany, six weeks prior to the renewal date.

▶ Reply per Fax +49 341 48474-290 to OEMUS MEDIA AG or per E-mail to grasse@oemus-media.de

*Prices include shipping and VAT

Last Name

First Name

Company

Street

ZIP/City/County

E-Mail

Signature

Notice of revocation: I am able to revoke the subscription within 14 days after my order by sending a written cancellation to OEMUS MEDIA AG, Holbeinstr. 29, 04229 Leipzig, Germany.

Signature

OEMUS MEDIA AG
Holbeinstr. 29, 04229 Leipzig
Tel.: +49 341 48474-0
Fax: +49 341 48474-290
E-Mail: grasse@oemus-media.de



Author and year	Number of implants	Follow-up	Technique ¹	Survival	Failures ²	Complications
Brånemark et al. 2004 ¹	52 turned consecutive 28 patients	5–10 years	A Two-stages	94% (3/52)	2 E.F. 1 L.F.	Implant suppuration (2 patients) Sinusitis (2 patients)
Pi-Urgell et al. 2008 ²	101 turned 54 patients	1–72 months	A Two-stages	96,0% (4/101)	2 E.F. 2 L.F.	Sinusitis (1 patient)
Ahlgren et al. 2006 ²³	25 NR ³ 13 patients	11–49 months	A Two-stages	100%	0	Haematoma (3 patients) Lip lesion (1 patient)
Al-Nawas et al. 2004 ²⁴	20 NR 4 patients	12–30 months	A Two-stages	95% (1/20)	1 E.F.	Sinus fistula (1 patient)
Balshi et al. 2009 ⁴	110 76 turned 34 TiUnite 56 patients	9–60 months	A Immediate loading	96,4% (4/110)	4 E.F.	Not reported
Bedrossian et al. 2002 ²⁵	44 turned 22 patients	34 months	A Two-stages	100% (0/44)	0	Not reported
Bedrossian et al. 2006 ¹⁹	28 TiUnite 14 patients	12 months	A Immediate loading	100% (0/28)	0	Without complications
Boyes-Varley et al. 2003 ⁷	77 NR 47 45° 30 55° 45 patients	6–30 months	A Two-stages	100% (0/77)	0	Not reported
Davo et al. 2007 ²²	36 turned consecutive 18 patients	Mean 14 months	A Immediate loading	100% (0/36)	0	Sinusitis (1 patient)
Farzard et al. 2006 ²⁶	22 turned 11 patients	18–46 months	A Two-stages	100% (0/22)	0	Sinus discomfort (3 patients)
Kahnberg et al. 2007 ⁵	145 Turned and TiUnite 76 patients	36 months	A Two-stages	96,3% (5/145)	3 E.F. 2 L.F.	Sinus discomfort (14 patients) Sinusitis (1 patient) Nerve impairment (1 patient)
Malevez et al. 2004 ⁶	103 turned 55 patients	6–48 months	A Two-stages	100% (0/103)	0	Sinusitis (6 patients)
Maló et al. 2008 ¹⁴	67 TiUnite 29 patients	6–18 months	A, B, C Immediate loading	98,5% (1/67)	1 E.F.	Sinusitis (4 patients)

Table 1_ Results from the reviewed studies with adequate follow-ups.

Author and year	Number of implants	Follow-up	Technique ¹	Survival	Failures ²	Complications
Aparicio et al. 2006 ³	131 turned consecutive 69 patients	6–60 months	A Two-stages	100% (0/131)	0	Haematoma (6 patients) Lip lesion (5 patients) Nerve impairment (6 patients) Sinusitis (3 patients)
Becktor et al. 2005 ²⁷	31 NR 16 patients	9–69 months	A Two-stages	90,3 % (3/31)	3 L.F.	Sinusitis (6 patients) Sinus fistula (5 patients)
Aparicio et al. 2008 ²¹	36 turned consecutive 20 patients	36–48 months	B Immediate loading	100% (0/36)	0	Without complications
Aparicio et al. 2008 ¹⁵	47 turned consecutive 25 patients	24–60 months	A and B Immediate loading	100% (0/47)	0	Without complications
Duarte et al. 2007 ²⁰	48 turned 12 patients	6–30 months	C Immediate loading	95,8% (2/48)	1 E.F. 1 L.F.	Without complications
Peñarrocha 2007 ¹²	40 turned 21 patients	12–45 months	A Two-stages	100% (0/40)	0	Sinusitis (2 patients)
Total	1,163 implants 598 patients	6–69 months	A (17) B (3) C (2) Two-stages (12) Immediate loading (7)	98,0% (23/1,163)	14 E.F. (60.9%) 9 L.F. (39.1%)	Sinusitis (26 patients) Sinus discomfort (17 patients) Haematoma (9 patients) Nerve impairment (7 patients) Lip lesion (6 patients) Sinus fistula (6 patients) Implant suppuration (2 patients)

1 A) 1 or 2 intrasinusal zygomatic implants combined with anterior standard implants

B) 1 or 2 extramaxillary zygomatic implants combined with anterior standard implants

C) 4 zygomatic implants without anterior standard implants

2 E.F.: Early Failure (during first 12 months) or L.F. (after 12 months)

3 NR: Not Reported

were lost (23/1163; 2.0%), fourteen (60.1%) before loading and nine (39.1%) after loading. Only one author (Pi-Urgell et al.)² presented the fracture of one of the zygomatic implants, which is probably a rare complication. Farzard et al.²⁶ observed that the marginal bone loss in the zygomatic implants would represent a decrease in the stability of the implant over time, with progressively lower Implant Stability Quotient (ISQ) values (<50). This confirms that the main anchorage site of the zygomatic implants is the zygomatic bone, especially in the long term, since and the resorption of the residual crestal bone can occur. This unfavourable biomechanical situation could eventually lead to an increase in the incidence of implant fractures in future studies with long follow-ups.

Although some authors comment on the level of satisfaction or quality of life in their reports^{6, 19, 28}, only Al-Nawas et al.²⁴ introduce success criteria in their results. These authors analysed the periimplant soft tissue's health (gingival bleeding index, probing depth, microbiological testing, etc.) concluding that only eleven of the 20 zygomatic implants (55%) would be considered successful, while the survival rate was 95%.

A precise surgical evaluation of the patient is mandatory in this complex technique, since serious complications might occur, especially due to the length of the implant and to the presence of important anatomical structures (orbit, infratemporal fossa, etc) in the zygomatic anchorage area. Moreover, our literature review showed a low rate of complications (9.5%), all being minor problems. Sinus pathology seems to be the most frequent complication, although other conditions have been reported. According to Maló et al.¹⁴ the sinus pathology is related to previous episodes of sinusitis or to the intraoperative perforation of the Schneiderian membrane. On the contrary, other authors like Brånemark et al.¹ mention in their article that no special effort was made to keep the sinus membrane intact. As a matter of fact, Peñarrocha et al.¹², perforated all the sinus membranes in their study with 40 zygomatic implants and reported only two cases of sinusitis. This is an interesting aspect to discuss in future research, since the available data is clearly insufficient. When sinus pathology is diagnosed long after implant placement, it is difficult to identify the cause of the sinusitis. In fact, only one of the papers mentioned the removal of three implants because the patients had frequent episodes of sinus infections. On the other hand, all the other authors decided to maintain the implants and the sinus pathologies were favourably managed with antibiotics or with antibiotics in combination with antrostomy surgery. The maxillary sinus could also be affected if there is a

substantial marginal bone loss, as described by Al-Nawas et al.²⁴ In these cases, the infection will reach the maxillary sinus through the periimplant pockets.

The lack of stability, aesthetics and/or function of the prosthesis and the deficient hygiene of the abutment areas are also important complications. Probably, these are often related to the palatal emergence of the zygomatic implants. Nowadays, this limitation has been solved with the extramaxillary implants procedure.^{14, 21} Nevertheless, the long-term exposure of the titanium threads to the cheek's soft tissue has to be evaluated carefully.

Conclusions

Based on the current literature review, zygomatic implants show excellent survival rates (>90%) and a low incidence of complications, so this should be considered a valid and safe treatment option when dealing with patients with advanced maxillary atrophy. Nevertheless, the authors would like to express their concern with the scarce amount of published studies (most of them of retrospective nature), with the low level of scientific evidence available, and with the lack of studies with long follow-up periods. The introduction of success criteria also based on periodontal parameters should be considered in future research.

Editorial note: A complete list of references is available from the publisher.

_contact	implants
<p>Dr Rui Figueiredo DDS Associate professor of the Oral Surgery and Implantology Department, Barcelona Institut de Recerca Biomèdica de Bellvitge (IDIBELL) Facultat d'Odontologia Universitat de Barcelona Campus de Bellvitge Pavelló de Govern 2a planta, Despatx 2.9 08907 – L'Hospitalet de Llobregat, Spain Phone: +34 93 402 42 74 E-mail: ruifigueiredo@hotmail.com</p>	
<p>¹ MD, DDS., Professor of the Master degree program of Oral Surgery and Implantology, Barcelona ² DDS. Fellow, Master degree program of Oral Surgery and Implantology, Barcelona ³ MD, DDS, PhD. Chairman, Oral Surgery and Implantology Department, and Director, Master degree Program of Oral Surgery and Implantology, Barcelona.</p>	