

implants

international magazine of oral implantology

2²⁰¹⁰

| **case report**

Immediate implant placement and temporisation
in the aesthetic zone

| **user report**

Use of an X-ray phantom in dental
3-D diagnostics in digital volume tomographs

| **meetings**

6th Arab-German Implantology Meeting of DGZI





Intelligent design shows in the details.

Help us support SOS Children's Villages!
120 Years W&H.



A program menu that covers all stages of implantation and is easy to use.
A motor with sensitive power control that feels supremely comfortable in the hand.
An aesthetic design with attractive clear shapes. A price / performance ratio that will give you a pleasant surprise.
An additional feature: the new endodontics function allows retrograde root apex resections of the root canal to be prepared in an orthograde manner – without having to change to an endodontic device. That's rather intelligent, isn't it?

People have Priority! W&H supports the humanitarian organization SOS Children's Villages.
Get involved! Further information at wh.com

implantmed

Straight forward or backward planning?



Dr Rolf Vollmer

I am seeing more and more misadventures dealing with complex implant cases. In particular, in the last several months I have seen numerous loading problems dealing with full arch restorations. By and large, the vast majority of these issues relate to a failure in the initial diagnosis. We know from our experience in continuing education courses that diagnosis and decision-making are always the most difficult things to teach and convey. Implant dentistry is now an integral part of many dental practices, however most dentists receive their education in implant dentistry after graduation, with little emphasis on the identification of the complexity and risks of treatment.

I recently became interested in a concept called the SAC classification. SAC stands for Straightforward, Advanced, and Complex. The SAC classification was first described by Sailer and Pajarola in 1999 as a method to categorize degrees of difficulty in oral surgery. In 2003 SAC underwent extensive review and was adapted for implant dentistry; it was also the topic of the ITI Consensus Conference in 2007 to standardize their application.

The basis of the SAC classification is that clinical situations in implant dentistry present with varying degrees of complexity. The SAC classification has applications in esthetical, restorative and surgical situations but can also be helpful in all forms of implant dentistry. Knowing in advance how complex an implant case is can ensure there are no surprises in the course of treatment, or if necessary, can allow you to refer the case to someone who is better able to perform the risky portion and return the case to you for the easy treatment. Usage of the SAC classification can assist practitioners in avoiding difficulties in implant and prosthetic cases as well.

It is, therefore, vitally important that we as practitioners are willing to acknowledge that some cases are more complex or difficult than others, and that we may need experts to deal with such cases. Finding an appropriately qualified colleague to manage a particularly complex case can prevent the case developing catastrophic complications and can avert a poor outcome.

Complex cases simply cannot be treated with a straightforward approach of "open the flap and see what we can do". For these types of cases more of a "reverse planning" approach is recommended—i.e. determine the plan of treatment by starting at the end-point. Generally, working forward from today incorporates neither resource implications nor integration needs. We are mentally so accustomed to the traditional form of thinking that we overlook important items and needs, and make subconscious assumptions that are not necessarily valid. Instead, periodic "reality checks" of the content of our plan of action and its implementation should occur. Regardless of how well planned cases are, 'things' never work out quite as envisaged— all too often real-time developments lead to detours. To minimise such occurrences, modern implantology diagnostic tools like DVT and computer assisted planning are very helpful in complex cases.

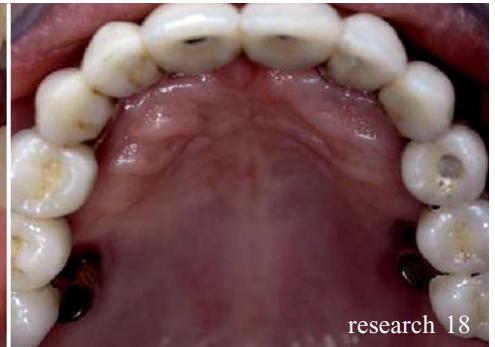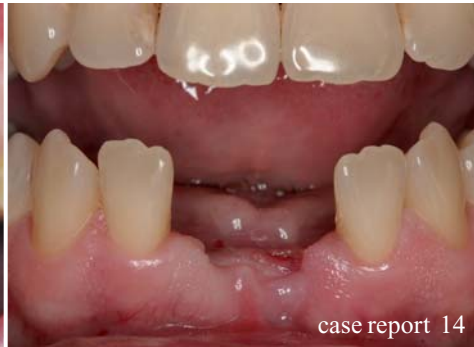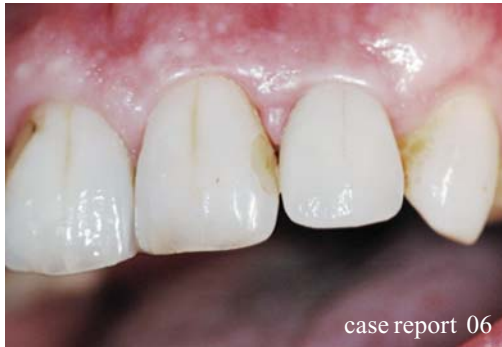Establish the goal, begin at the end and work backward! If done correctly, we will have an ever-evolving, reality-based, integrated plan that will actually work to achieve our patients' aims.

Currently we, as an expert scientific implant association, are happy to offer our colleagues the possibility of undertaking company-independent implant training courses including masters programs at universities. Many dentists involved in the surgical or restorative aspects of implant care obtain continuing education in implant dentistry and belong to professional implant organizations like the German Association of Dental Implantology (DGZI). Our continuing education programs (e.g. our basic curriculum and our Annual Meetings) are some of the best I have ever attended, nationally or internationally.

I hope to see many of you later this year in Berlin from the 1st to 2nd of October to celebrate our fortieth anniversary with an outstanding scientific and social program.

Sincerely

Dr Rolf Vollmer



| editorial

- 03 **Straight forward or backward planning?**
| Dr Rolf Vollmer

| case report

- 06 **Immediate implant placement and temporisation in the aesthetic zone**
| Dr Philip J. Friel
- 14 **Bone Harvesting—nice and easy**
| Dr Steffen Hohl & Dr Anne Sophie Brandt Petersen

| research

- 18 **The concept of “platform switching” in implant dentistry—Part II**
| Dr Virgil Koszegi Stoianov
- 24 **Rehabilitation of atrophic maxillas using zygomatic implants**
| Joan Pi-Urgell, Javier Mir-Mari, Rui Figueiredo & Cosme Gay-Escoda

| user report

- 10 **Use of an X-ray phantom in dental 3-D diagnostics in digital volume tomographs**
| Dr Georg Bach, Christian Müller & Alexander Rottler

| meetings

- 32 **International events 2010/2011**
- 34 **25th Anniversary of the Academy of Osseointegration**
| Dr Rolf Vollmer & Dr Rainer Valentin
- 36 **6th Arab-German Implantology Meeting of DGZI**
- 41 **ITI World Symposium 2010**
- 42 **Interdisciplinary insights from theory to practice**

| implants

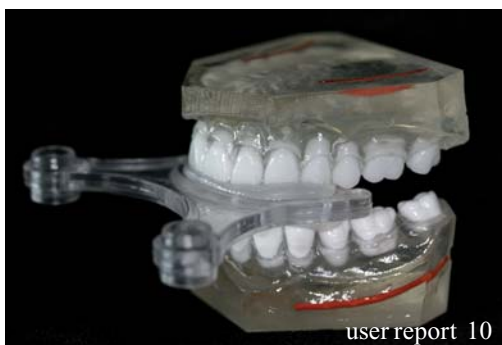- 33 **DGZI's anatomy weekend a full success!**
| Dr Christian Ehrensberger

| news

- 44 **Manufacturer news**
- 48 **Congratulations and Happy Birthday to all DGZI-members around the world**

| about the publisher

- 50 | imprint




NobelReplace™

The world's most used implant system.*

Internal tri-channel connection for accurate and secure prosthetic restorations.

TiUnite® surface and Groovy™ to enhance osseointegration.

Implant design that replicates the shape of natural tooth roots.



Color-coded system for accurate and fast component identification and ease of use.

Color-coding: step-by-step drilling protocol for predictable surgical procedures.

10 YEARS WITH
TIUNITE® SURFACE
New data confirm
long-term stability.

* Source: Millennium Research Group

Versatility, ease-of-use and predictability have made NobelReplace Tapered the most widely used implant design in the world.* NobelReplace Tapered is a general use, two-piece implant system that performs both in soft and hard bone, one- and two-stage surgical procedures, while consistently delivering

optimal initial stability. NobelReplace Tapered is a system that grows to meet the surgical and restorative needs of clinicians and their patients – from single-tooth restorations to more advanced multi-unit solutions. Whether clinicians are just starting or are experienced implant users, they will benefit from a system that

is unique in flexibility and breadth of application. Nobel Biocare is the world leader in innovative and evidence-based dental solutions. For more information, visit our website.

www.nobelbiocare.com

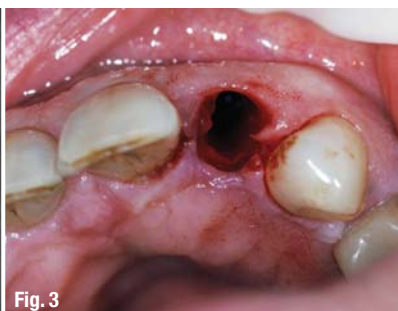
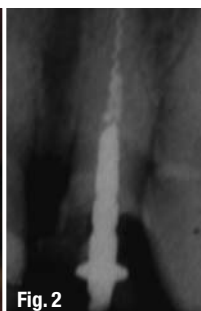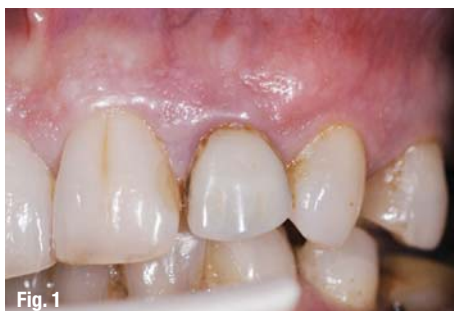Immediate implant placement and temporisation in the aesthetic zone

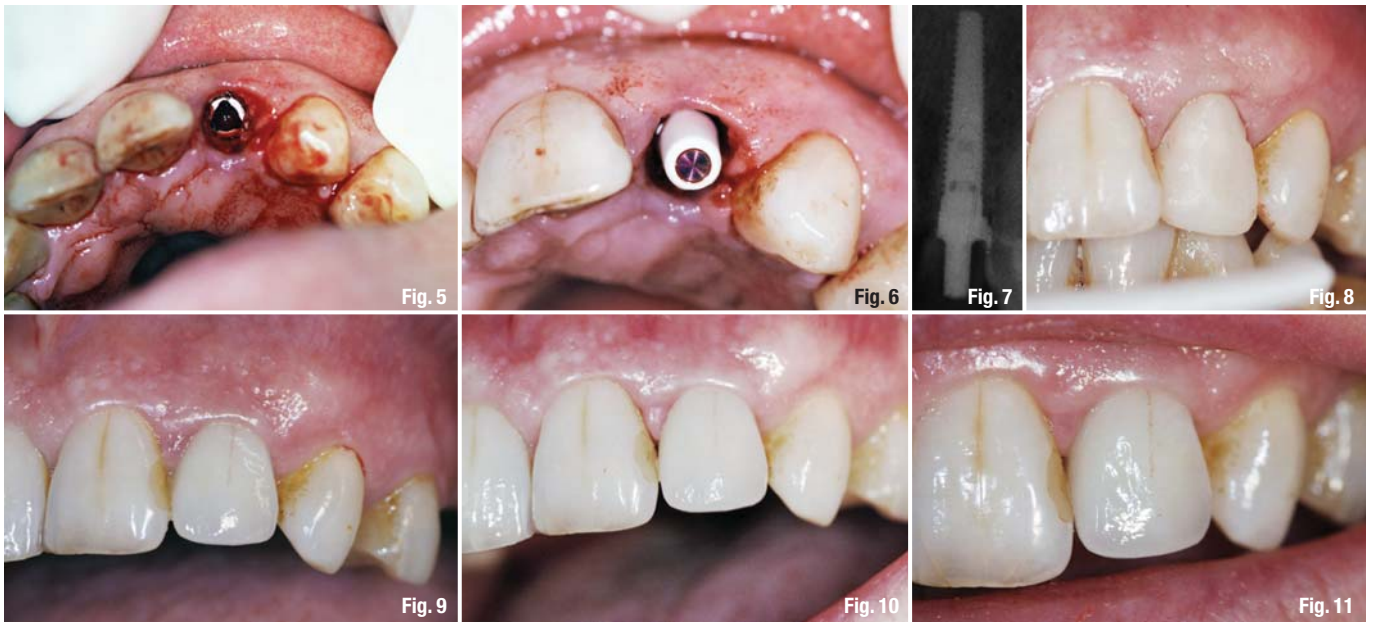
Author_ Dr Phillip J. Friel, Great Britain

The success of dental restorations can be measured in terms of biological stability over time. With regards to dental implantology, the challenge is no longer one of integration, more long term aesthetic stability of the final restoration. Nowhere is this biological and aesthetic stability more important than in the aesthetic zone.

Teeth and their roots have a supportive role to the alveolar bone in which they are retained. This bone in turn gives support to the gingival tissue overlying it, and the level of this bone directly affects the position of this gingival tissue.¹ Following tooth loss, this support is lost, and both the hard and soft tissue begin a process of remodelling. This process invariably results in the loss of bone, and an alteration in the gingival position. While it is possible to replace this support with the use of bone grafting or collagen plug techniques, this can involve a number of surgical procedures in order to achieve the final result. Original protocols in implantology required that implants be placed into healed edentulous ridges. Implants can, however, be placed at the time of tooth extraction.² Such techniques can be used with simultaneous augmentation to

preserve ridge width, decreasing total treatment time. This paper, and its case presentation, outline a technique which allows, in the right conditions, the replacement of the support of a lost root, and consequently prevents major bone remodelling and subsequent alteration of soft tissue position. The following case is one of many completed, ranging from the single tooth to multiple units, all of which have a minimum of twelve months follow-up, and the results of which will be collectively published in the near future. The illustrated case involves a 63 year old, retired female patient who was referred to the clinic timeously by her general dental practitioner following root fracture affecting the upper left lateral incisor. Her chief complaint was one of poor aesthetics affecting this tooth (Fig. 1). The condition of this tooth had declined gradually, following placement of a composite crown three years previously. The composite crown had been placed, retained by a temporary post, following failed root canal therapy during which an endodontic instrument was fractured in the tooth (Fig. 2). The patient was in good health, a regular dental attendee with an adequate oral hygiene regime. A full dental assessment was undertaken to include assessment of

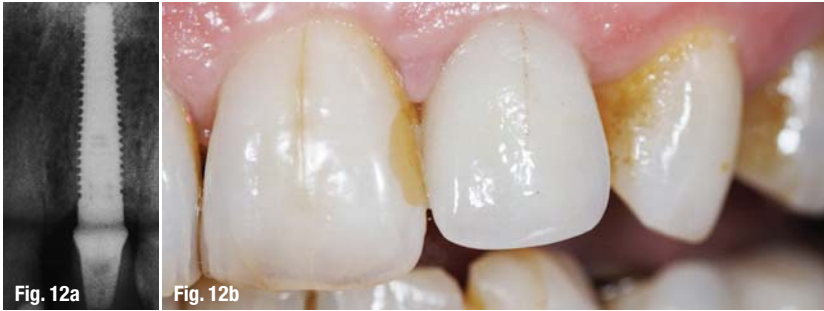



soft and hard tissue, remaining dentition, occlusion and parafunction, current and required oral hygiene and maintenance. The patient was noted to have a high smile line, clearly showing the dentogingival complex in function. A full discussion outlined the options available to the patient, who after consideration, elected a fixed option, with implant restoration being her solution of choice. The patient was fully aware of the risks and alternatives to the procedure, and given her very recent root fracture affecting the tooth, surgery was scheduled for the same week. Mounted study models were produced, upon which, two vacuum formed stents were made over the tooth in question. Full radiographic assessment was undertaken to determine the condition of the remaining root, adjacent teeth and roots, while assessing the area dimensionally for implant placement. The patient was prepared for surgery following pre operative consent and antibiotics together with repeated pre operative rinsing with chlorhexidine gluconate 0.2%. Standard surgical scrub and drapes were employed. The upper left lateral incisor tooth was carefully extracted using periostomes to preserve both hard and soft tissue around the socket.³ This technique facilitates tooth removal without traumatising the alveolar bone of the socket or surrounding gingival tissue. The technique can be performed for any extraction, but it is of particular importance when the subsequent placement of dental implants is envisaged.

Following atraumatic tooth removal, the socket was thoroughly irrigated, debrided and fully assessed (Fig. 3). The socket was found to be intact, stable and formed from solid bone. The

buccal crestal bone was found to be intact, at a good level and supporting the thick gingival genotype overlying it. Having fully assessed the socket, the implant osteotomy was undertaken, following a flapless surgery protocol with both external and internal irrigation, and using the surgical stent as a guide to the final required position. Bone removed during the procedure was harvested (Fig. 4). The osteotomy was prepared and the fixture placed slightly towards the palatal plane. The implant was seated to the desired vertical position to allow ideal soft tissue position after healing. The implant (Nobel Biocare RST 16 mm NP) was inserted and torqued to 35 Ncm (Fig. 5). After implant placement, the socket was then reassessed. As expected there was found to be a slight void between implant and buccal plate. The harvested bone was packed into this defect, as an adjunctive graft, in order to support the buccal plate and its overlying gingivae.⁴ Having placed the implant and harvest graft, the bony socket was now supporting its overlying hard and soft tissues once more. Attention then turns towards gaining support for the crestal soft tissues. An immediate temporary abutment was torqued on to the implant again to 35 Ncm, and a Teflon cap placed over this (Fig. 6). Using the second vacuum formed stent, a temporary crown was constructed using a flowable composite resin, and light cured before being removed. Following removal, the crown is added to and carefully polished, especially in the cervical area, to give a highly polished, ergonomic temporary restoration which is adequately supportive to the cervical gingival tissues, providing a circumferential seal around the marginal area. Following final polishing, the



temporary crown is luted to the temporary abutment using a temporary cement. The post operative radiograph (Fig. 7) shows this situation and highlights a small excess of temporary cement which can be easily removed with floss. The temporary restoration is kept clear of the occlusion. Given the implant is placed directly into the extraction socket, and that the adequately supportive temporary crown provides an excellent crestal gingival seal, no flap is required and consequently, no sutures are used in this procedure. Standard post operative protocols are followed. As a result of this flapless approach, the trauma of surgery is lessened, and review one week post surgery shows an excellent recovery (Fig. 8), with very little sign of any trauma, swelling or alteration of the surrounding gingival tissue, which largely remains unchanged. After a five to six month healing period, during which regular review is undertaken, the temporary crown is removed using a crown remover. The temporary abutment is removed and the socket irrigated. A standard open tray impression technique is used to record the position of the implant, and the temporary abutment and crown replaced. The subsequently produced model is used to construct an abutment and crown, replicating the exact support given by the temporary set up. The case is completed by final abutment placement and torque to 35 Ncm. Following trial fit, and approval of the definitive restoration, the occlusion is checked and adjusted as required. The Zirconia crown is cemented using a resin cement, with care being taken to minimally load the cement and remove any excess prior to and after cure. Occlusion is again assessed and adjusted as required. The success of the restoration is evident immediately after cementation (Fig. 9), at 3 month (Fig. 10), six month (Fig. 11) and 18 month review (Fig. 12 a & b). In order to successfully perform the procedure outlined above, timing is essential, particularly in the case of the root fractured tooth. In these cases, if such treatment is not initiated in good time, the area can become infected with corresponding sinus formation and inevitable loss of the buccal plate of bone. This would entail re-assessment and treatment using a multi-staged, delayed placement regime. In order to perform

flapless surgery, the operator must have suitable experience, and be competent in the procedure. Added to this, as with any surgery, a full knowledge and appreciation of the anatomy surrounding the surgical site is essential to ensure a successful outcome. It is sometimes necessary to carry out further special tests or procedures during the planning stages, to ascertain further information prior to commencement of treatment. These may include CT scanning or ridge mapping of the proposed surgical site. Following atraumatic tooth extraction and socket assessment it may, occasionally, not be possible to proceed with immediate implant placement for a number of reasons. In such cases proper planning is essential to ensure that an alternative treatment option may be undertaken. While flapless surgery incurs decreased trauma and faster healing, during any flapless procedure, it must be remembered that the operator can, at any time, raise a flap, if at all concerned with regards to surgical progress. Biological stability has been maintained from removal of the damaged root right through to cementation of the definitive restoration. By respecting and understanding the natural tissues in this way, predictably excellent results can be achieved time after time.

The clinical photographs and case discussion are included with the expressed permission of the patient involved. All of the laboratory stages for the case were completed by Lincoln Ceramics, Glasgow.

References

1. Gargiulo et al J.Periodontol,1961,31:261–267.
2. Lazzara R J. Immediate implant placement into extraction sites: surgical and restorative advantages. Int J Periodont Rest Dent 1989;9:332–343.
3. Quayle A. Atraumatic removal of teeth and root fragments in Dental Implantology. Int J Oral Maxillofac Implants 1990;5:293–296.
4. Botticelli et al. The jumping distance revisited : An experimental study in the dog. Clin Oral Implants Res 2003;14(1):35–42.

First published in Scottish Dentist March-April 2008.

_contact	implants
Dr Philip J. Friel Philip Friel Advanced Dentistry 170 Hyndland Road G12 9HZ Glasgow, Great Britain	



SIMPLY BETTER

STRAUMANN® SLActive

Straumann® SLActive – The next generation in surface technology

- Higher security and faster osseointegration for every indication
- Reduced healing times from 6–8 weeks down to 3–4 weeks
- Increased treatment predictability in critical protocols

Please contact us at **+41 (0)61 965 1111** More information on **www.straumann.com**



Based on the following studies: preclinical: Buser et al. (2004), Schwarz et al. (2006/2007) clinical: Zöllner et al. (2007), Oates et al. (2007) internal data on file

COMMITTED TO
SIMPLY DOING MORE
FOR DENTAL PROFESSIONALS

Use of an X-ray phantom in dental 3-D diagnostics in digital volume tomographs

Authors_Dr Georg Bach¹, Christian Müller² and Alexander Rottler³

Introduction

Undoubtedly, digital volume tomography has significantly expanded the range of dental imaging diagnostics. Just as Paatero succeeded in ushering in a new era of dental radiology at the end of the 1950s with the development of an orthopantomograph and the resulting introduction of panoramic view imaging, three-dimensional processes will, in turn, replace panoramic view imaging.

Although digital volume tomography has to date been mostly used for preimplantological planning and in reconstruction surgery, now other dental disciplines are beginning to appreciate and use the high value of this process – it is in orthodontia, endodontia, dental surgery as well as periodontics that digital volume tomography represents a significant improvement of the possibilities of imaging processes. Sometimes their significance can even be assessed as being greater than in the current domain, preimplantological diagnostics.

Fig. 1a and 1b_ DVT phantom ("maxillary sinus floor" and "nervus alveolaris mandibulae" are simulated with radiopaque wire structures).

Volume—available volume tomographs

After digital volume tomographs had been on the market for a good decade, the number of suppliers of such devices increased dramatically – and the number is still increasing. When observing the device market, two clear trends can be seen:

- a) The trend towards an "all-in-one device" (also called "dual use")
- b) The trend of offering various volumes

All-in-one-devices ("dual use")

In addition to offering 3-D diagnostics, the majority of digital volume tomographs available on the market also provide the option of producing panoramic view images ("real" images, not reconstructed from a data record) and sometimes even an FRS image.

These devices thus cover the entire range of dental "large-scale diagnostics" – in contrast to the first generation, which only gave the DVT option.

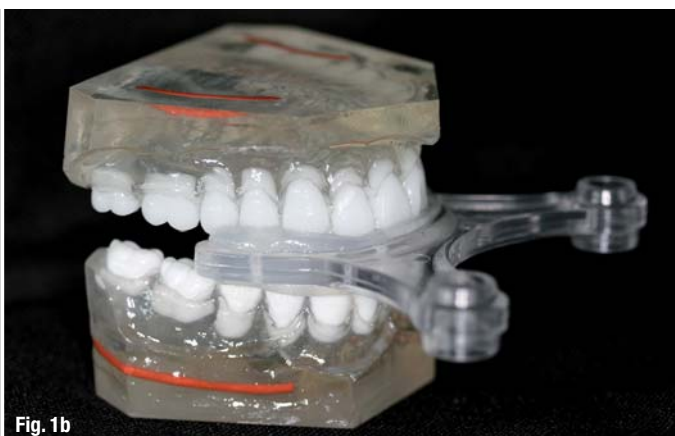
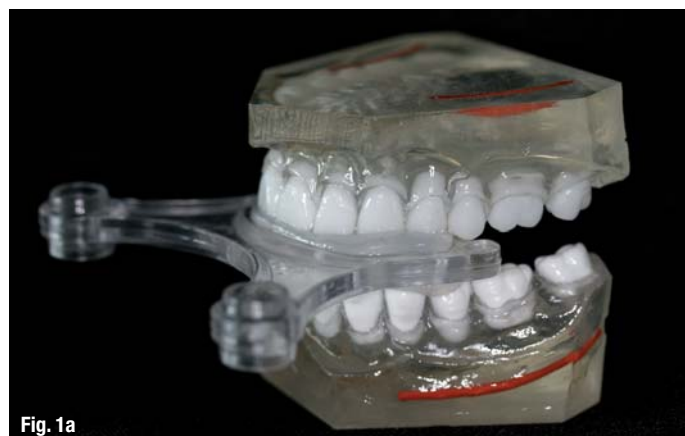
Fig. 1a

Fig. 1b

The DVT devices of today's generation are often similar in design and appearance to traditional digital volume tomographs; the position of the patient with these and other "frame" devices is typically standing or sitting, while the once dominant supine patient position of the first device generation is passé except for one manufacturer.

Various volumes

Such first-generation devices featured very large volumes which required time-consuming reworking of the immense data record for problems beyond large and reconstruction surgery in order to be able to evaluate the "relevant" data and/or regions in a target-oriented manner. Today numerous manufacturers offer devices with mid-size and small volumes. Three types of devices are available:

- Devices with a large volume (18 x 20 cm and higher) for oral surgery and reconstruction.
- Devices with a medium volume (8 x 10 cm and higher) for oral surgery and reconstruction.
- Devices with a small volume (4 x 5 cm) for oral surgery and dental procedures.

Problems with devices with small and medium volume

Devices with small and medium volume are generally used in oral surgery and dental practices; they are mostly used for preimplantological diagnostics, for oral surgery and orthodontic and endodontic procedures.

The "finiteness" of the volume size requires careful device setting and patient positioning so that the relevant structure is also depicted and/or "encountered"; it must also be "well targeted."

For new users and those colleagues who only do volume tomographies once in a while, this correct setting can pose difficulties.

This was our motivation to develop a DVT phantom which can be used for training purposes as well as for direct preparation of an image with a patient.

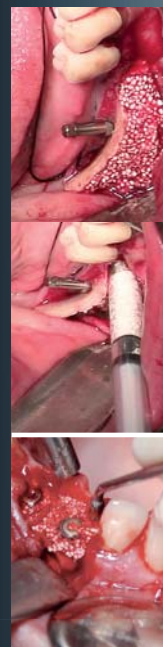The DVT phantom and its application

The DVT phantom is an X-ray phantom which depicts a medium-sized mandibular and maxillary dental arch; the teeth are positioned in ideal denticulation.

The divided phantom (mandible and maxilla) is mounted on the individual biting or positioning aid/support of the respective device. Barium sulfate is added to the plastic teeth so that they are visible in

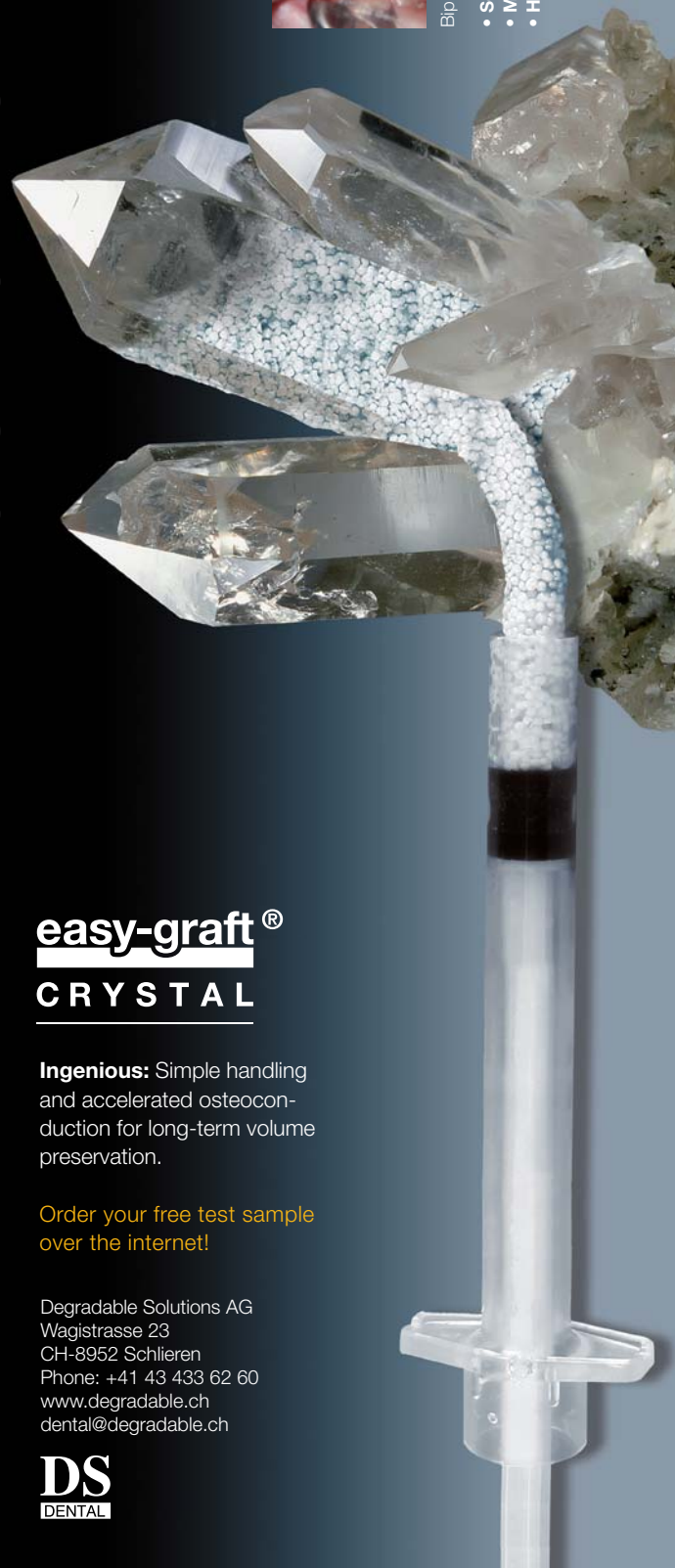
bionic sticky granules

easy-graft® CRYSTAL



Biphasic composite substitute, 60% HA/40% β -TCP, PLGA coated

- Soft from the syringe
- Mouldable in the defect
- Hardens in situ
- 100% synthetic
- Accelerated osteoconduction
- Long-term volume preservation



easy-graft®
CRYSTAL

Ingenious: Simple handling and accelerated osteoconduction for long-term volume preservation.

Order your free test sample over the internet!

Degradable Solutions AG
Wagistrasse 23
CH-8952 Schlieren
Phone: +41 43 433 62 60
www.degradable.ch
dental@degradable.ch

DS
DENTAL

Fig. 2_ DVT phantom in a volume tomograph (Kodak 9000 3d, small volume) fixated on the original patient biting aid.

Fig. 3_ Device settings: With the aid of the light visors, a volume is placed on the region to be depicted (here region 26 and maxillary sinus floor).

Fig. 4_ DVT phantom image of the maxilla with the X-ray phantom.

Fig. 5_ DVT phantom image of the mandible with the X-ray phantom.

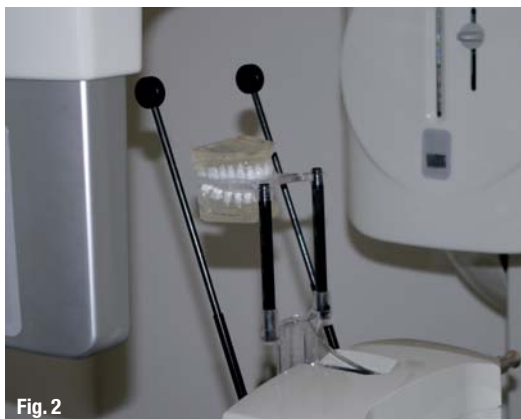

Fig. 2

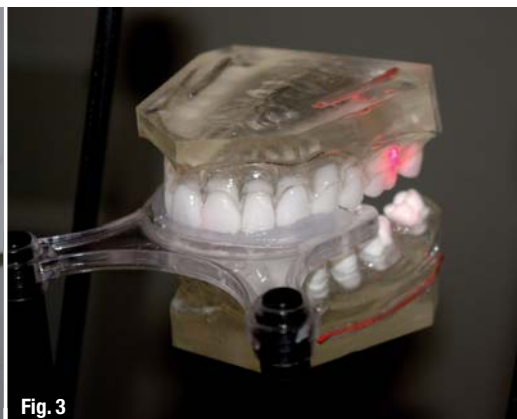


Fig. 3

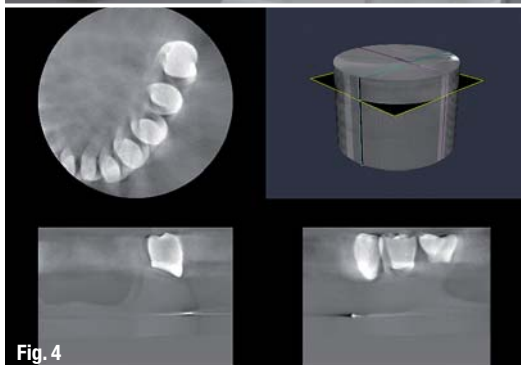


Fig. 4

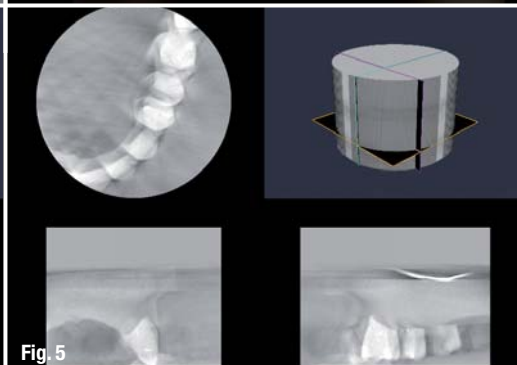


Fig. 5

the X-ray image; these teeth have been made by the manufacturer especially for X-ray applications.

The DVT platform is now mounted in the device with the original biting aid/support instead of a patient. The device setting can occur in two different ways:

- a) The desired volume is preset using the device program and then manually fine-tuned.
- b) The device is manually set directly on the region to be depicted with the aid of the light visors. Then the set positioning is saved.

Using the DVT phantom for training and practice purposes

With the aid of the DVT phantom and the above-mentioned setting techniques, new users or colleagues seeking technical qualifications can learn how to set the device for the regions to be examined, generate one or more individual images using the "preview function" and check to see if the setting was correct. In the event of incorrect settings, a better image can be immediately generated so that there is a direct learning curve.

Using the DVT phantom for preparing a patient image

Time-consuming and tedious setting ("aiming") of the volume on a patient who is already in the device is not something that will generally meet with

the patient's whole-hearted agreement. This is where presetting the device with the aid of the DVT phantom comes in handy. The desired region is depicted with the phantom and, if needed, is checked with the preview function. Then the phantom is removed, and the patient is fetched and positioned in the device. Generally, only one device setting for the patient's body size and small fine-tuning are required and the image is set.

How to obtain a DVT phantom

Such a DVT phantom can be produced in cooperation with practicing dental technicians, the barium sulfate-containing plastic teeth are available on the market and a phantom can be made in the manner described above. An easier option is to send a DVT positioning aid of your device to www.dtcmfreiburg.de or dtecmfreiburg@aol.com. Master Dental Technician Christian Müller will then mount a prepared DVT phantom on your positioning aid. Industrially manufactured barium-sulfate-containing plastic teeth (SR Vivo Tac/SR Ortho Tac, Ivoclar Vivadent) will be used which are then incorporated into a mandibular and maxillary model made of transparent plastic.

The authors of this article hope that the fascinating field of 3-D diagnostics will establish itself quickly in dentistry and that it will remain an imaging procedure that significantly expands upon the hitherto range of dental X-ray diagnostics in the long term.

_contact	implants
<p>Dr Georg Bach Rathausgasse 36 79098 Freiburg im Breisgau, Germany E-mail: doc.bach@t-online.de</p>	
<p>¹ DDS; specialist in oral surgery ² Diploma Master Dental Technician ³ Bachelor Dental Technician</p>	



NEW IMPLANTS, NEW ABUTMENTS
LIBERTY OF CHOICE
NATURALLY FROM **CAMLOG**

Reliable implants, patented Tube-in-Tube™ connection, and from now on as an option: platform switching. Camlog offers more. More information: www.camlog.com

a perfect fit®

camlog

Bone Harvesting— nice and easy

Authors _Dr Steffen Hohl, Germany & Dr Anne Sophie Brandt Petersen, Denmark

Figs. 1 & 2 _Initial situation in region 031, 041. State 3 months after the removal of the teeth 31, 41. In region 041 the vestibular lamella has completely collapsed.

Fig. 3 _Noticeably visible three wall bone defect in region 031 vestibular.

Fig. 4 _After drilling the implant shafts, region 031 showed to be significantly atrophied.

Fig. 5 _The implant shafts are dilated using condensers and the periimplantational bone is condensed.

Fig. 6 _Implant insertion in the regions 031, 041. In region 031 it is visible that a vestibular augmentation must take place.

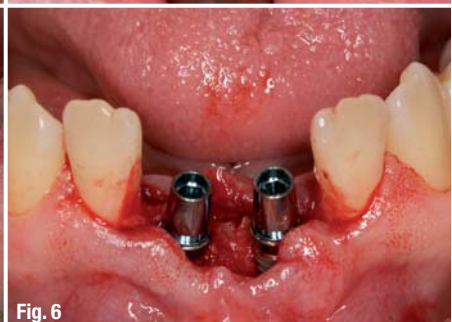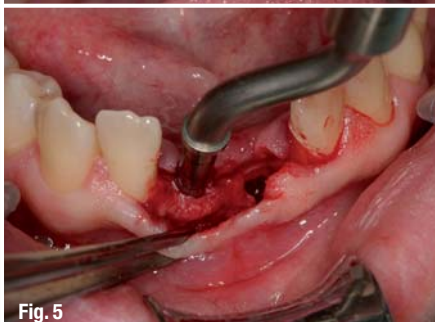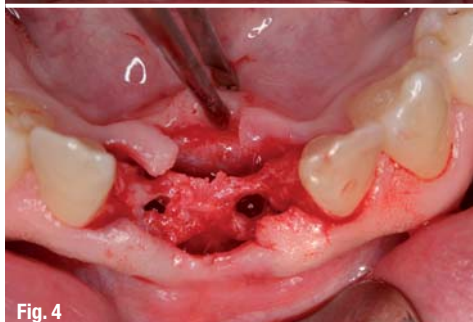
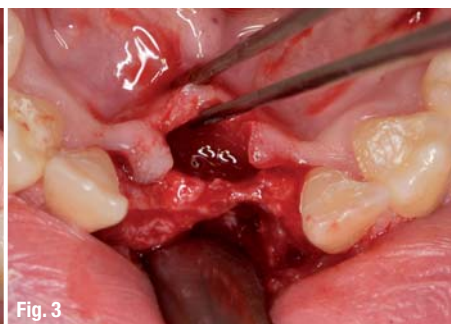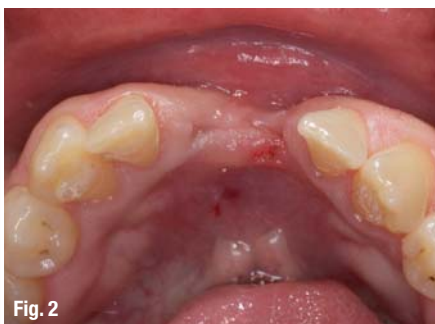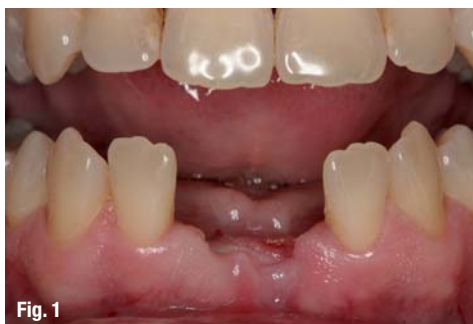_Introduction

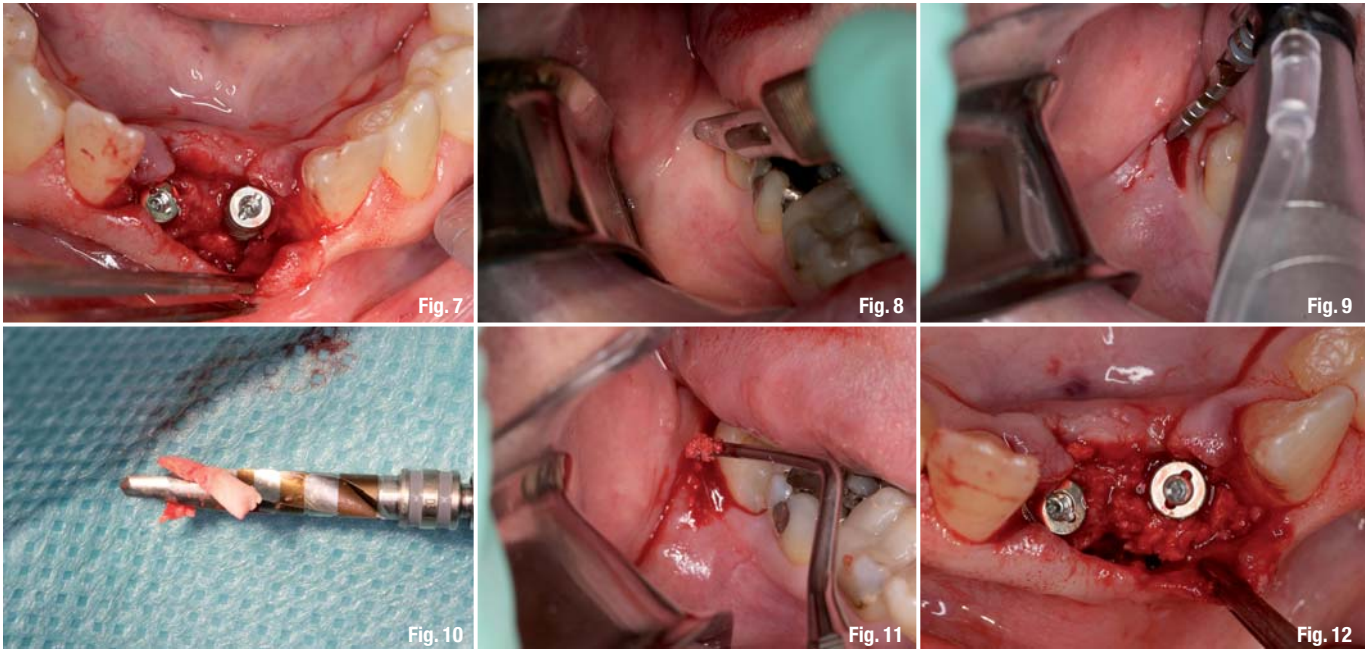
The desire to use bone from your own body to build new bone in another place is almost as old as humanity itself. We call this procedure autologous bone grafting.

In the case of autologous bone grafting the bone is removed from the same organism that the graft is to be incorporated in. The body's own bone cells have the greatest potency for rebuilding of bones and are the gold standard in oral augmentation surgery. Donor areas are: the tuber maxillae, the retromolar space, the chin region or the iliac crest, the ribs or the shin. Gaining the required quantity is sometimes elaborate (large

surgical interventions, in patient stay) and afflicted with particular problems, especially when it comes from regions far away from the oral cavity (e.g. the iliac crest). The extraction of autologous bone grafts from the retromolar space find the best acceptance with patients.

Particularly in implantology lateral augmentations are necessary in more than 75 per cent of cases. These augmentative measures mostly require low bone volumes of less than 0.3 mg. If the decision is made intraoperatively, that the patient's own bone must be used, as a rule the following question must be asked: "Which region should the bone be taken from and how can it be removed quickly?"





The retromolar space is chosen here in more than 70 per cent of cases. Until now exclusively block grafts have been used.

Case description

The 36 year old patient wants the gaps in his teeth in the regions 031, 041 to be filled with implants due to his otherwise intact dentition. However in this situation the question is raised of whether implantation and necessary augmentation of the crestal jaw line can occur synchronously. It was planned for the patient to have autologous bone adhered in the region of the 031

vestibular. Hereby the right retromolar space and the right tuber area were considered as donor areas. The patient could be assured pre-operatively that an extraction defect of bone extraction would only involve few complaint symptoms. Intraoperatively the crestal incision was begun in the areas 031 and 041. After forming a minimally invasive mucoperiosteal flap, in particular region 031 showed strong vestibular atrophies. Initially implant drilling was carried out and the bore shaft was extended using bone condenser, i.e. the periimplantational bone was condensed. Subsequently, the implant bodies were inserted. Here it became obvious that the implant

Fig. 7_ the implant body in region 031 must be vestibularly covered with autologous bone over approx. 2/3 of its surface.

Fig. 8_ Retromolar stab incision with an 11 scalpel.

Fig. 9_ A conventional implant drill is used to drill directly in the area of the linea obliqua through the stab incision. A "two spade drill" is excellently suited to bone extraction.

Fig. 10_ Bone excavation via simple shaft drilling with the conventional "two spade drill".

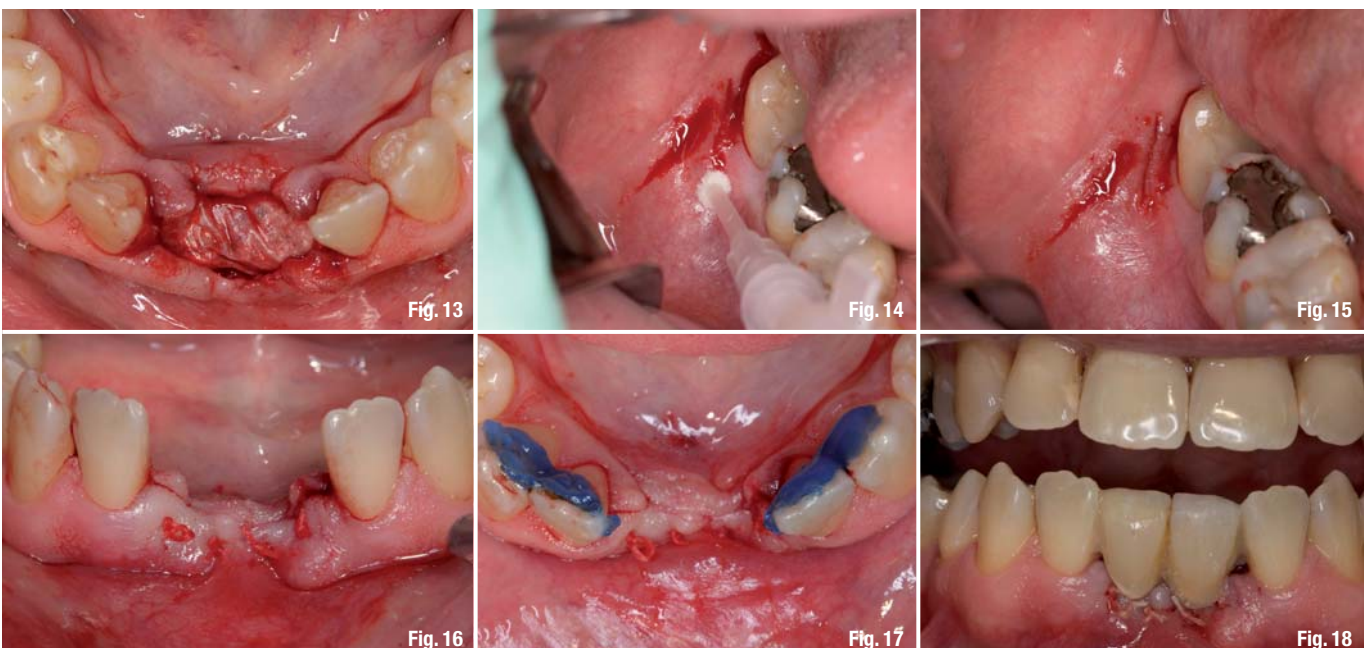

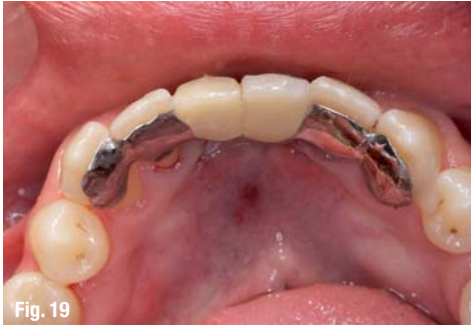


Fig. 19

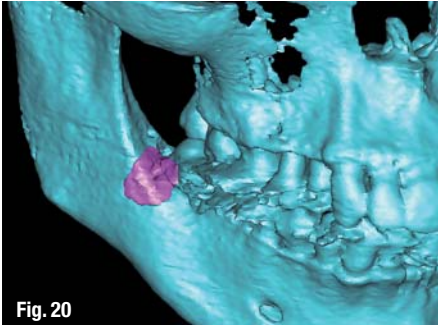


Fig. 20

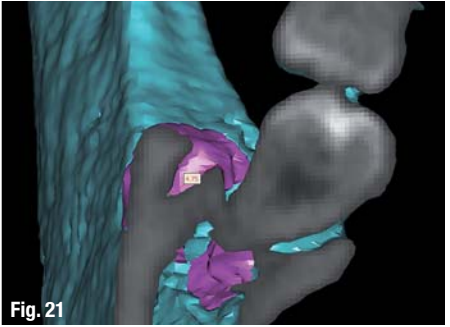


Fig. 21

Fig. 11 additional bone excavation by hollowing out the shaft drill hole in the linea obliqua with the excavator.

Fig. 12 Implants and autologous bone augmentation in situ. In order to achieve this result it was only necessary to drill into the retromolar!

Fig. 13 Covering the implants and augmentations with a simple collagen membrane.

Figs. 14 & 15 The stab incision of the retromolar extraction region is glued with cyanoacrylate. Hereby the patient only incurs a microscopic extraction defect.

Figs. 16 & 17 The soft tissue in the implant region is closed with absorbable suture material. The neighbouring teeth 43,42,32,33 are lingually cauterised.

Figs. 18 & 19 Insertion of a Maryland provisional prosthesis, directly after the augmentative-implantological intervention.

Fig. 20 DVT of excavation defect.

was 2/3 exposed on its vestibular side in region 031. Both implants were primarily stable. After measuring the missing bone volume, a stab incision was made in the right retromolar. Then a conventional implant drill was driven through the gums and drilled precisely 9 mm deep. When withdrawing the drill the bone meal was already able to be retained. Additionally further spongiose bone was extracted with a mini-excavator.

The transplant bone was able to be adsorbed into the implant body in an ideal manner. Finally a thin collagen membrane was applied for complete coverage. The soft tissue defects were closed with absorbable materials. The stab incision in the retromolar was glued with cyanoacrylate. In regions 031/041 the wound closure was carried out using absorbable suture material and horizontal mattress stitches.

Finally as a provisional restoration a Maryland temporary prosthesis was affixed, which additionally ensured a good soft tissue stabilisation. A digital volume tomography (DVT) was produced in order to evaluate the removal defect and document the augmentative result.

Summary

Autologous bone grafting represents the gold standard in augmentation surgery. Particularly with implant operations it is often only shown intraoperatively that a small quantity of autologous bone is needed for augmentation. In this situation quick

reaction is often indicated. The retromolar space is frequented most often for this purpose. As the patient should have the least possible discomfort due to the bone extraction, minimally invasive procedures are the means of choice.

The technique presented above is a new method which is impressive due to its minimally invasive and simple characteristics. The shown procedure is especially ideal for augmentation planning with volumes up to 0.5 mg. Of course larger bone volumes can also be extracted using this minimally invasive method. Soft tissues can be closed discreetly and so that they are hardly noticeable to the patient using adhesive techniques. Minimally invasive procedures in implantology can be perfectly planned and executed by including modern 3-D-diagnostics (DVT).

contact

implants

Dr Dr Steffen Hohl

DIC Dental Implant
Competence
Estetalstr. 1
21614 Buxtehude, Germany
www.dr-hohl.de

Dr Anne Sophie Brandt Petersen

Tandlaegerne I Kogade
Kogade 4
6270 Tonder, Denmark
www.dentist.dk

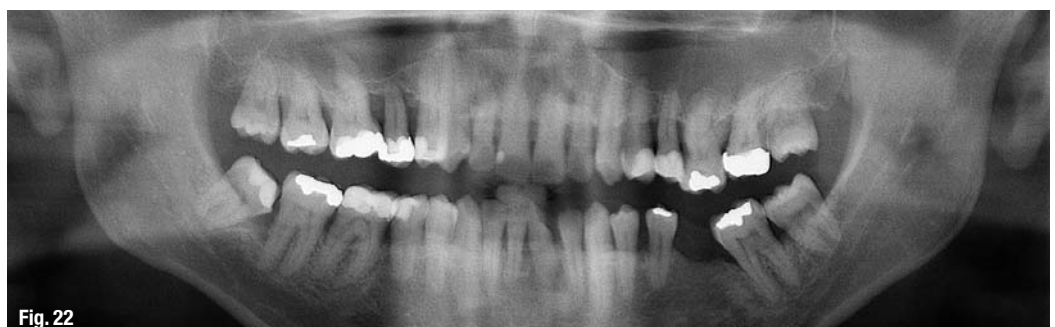

Fig. 22

PIEZON-MASTER-SURGERY.COM

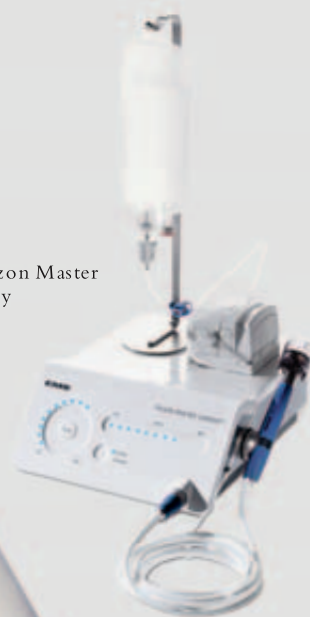EMS⁺
ELECTRO MEDICAL SYSTEMS

PIEZON MASTER SURGERY® –
THE WORLD OF DENTAL
AND ORAL SURGERY NOW
CELEBRATES A NEW HERO

**REVOLUTION IN
YOUR HANDS**

INNOVATIVE technology, easy to operate, multiple applications, exclusive instruments, great results, extensive experience – the Original Piezon Method now also available for periodontal surgery, implantology, oral and maxillary surgery.

> Piezon Master Surgery



UNIQUE in the realm of surgery – 3-touch panel for intuitive user guidance.

EXCLUSIVE design tailored to the new piezoceramic surgery hand-piece – the new Swiss Instruments Surgery.

REVOLUTIONARY in the smallest details – once you've experienced Piezon Master Surgery, you'll ask yourself: Why didn't we have this before?

**TOUCH
'N'
GO**

For more information,
please visit www.piezon-master-surgery.com

The concept of “platform switching” in implant dentistry

A literature review—Part II

Author_ Dr Virgil Koszegi Stoianov, Romania

Discussion

There is an association between bone and soft tissue preservation around implants with direct influence on aesthetics.

Some authors have proposed different methods to maintain supporting bone: improved implant micro-geometry and implant surface treatment, improved implant abutment connection (elimination of bacterial reservoir, absence of movements under bending forces) as well as the use of wide implants with smaller sized abutments (platform switching concept).

An alternative in preserving marginal bone levels around implants is the platform switching concept that refers to the use of a smaller diameter abutment on a larger diameter implant platform. This connection shifts the perimeter of the implant–abutment junction (IAJ) inward towards the central implant axis.

Lazzara and Porter demonstrated that the inward movement of IAJ also shifts the inflammatory cell infiltrate inward and away from the

bone implant interface, creating a horizontal biologic width that will limit bone resorption around the coronal aspect of the implant.

From a biomechanical perspective, stress in the bone is concentrated around the crestal region because of the difference in modulus of elasticity between bone and implant, as demonstrated in photo - elastic and finite element analysis studies.¹⁴

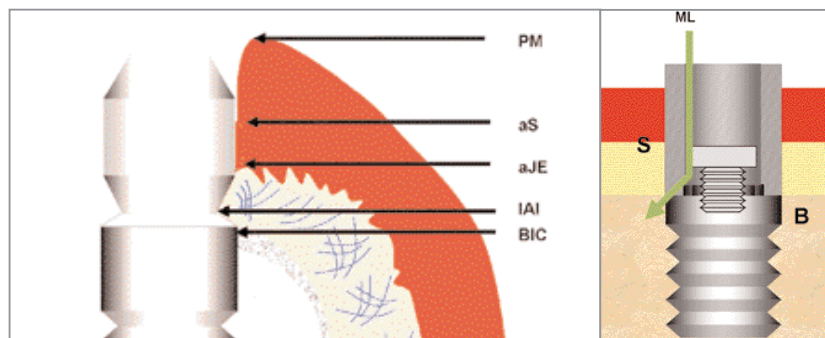
Peak bone stresses occurring in marginal bone have been hypothesized to cause bone micro-fracture and may be responsible, at least partially for peri-implant bone loss with saucerization patterns after prosthetic loading.

The issue of whether platform switching may affect stress patterns by minimizing peak bone stresses in the marginal bone has not been demonstrated yet.

The original criteria established for assessing implant success and survival⁶ identified marginal bone levels as an important indicator for measuring the response of the peri-implant tissues to functional loading.

More recent studies have considered the effect of stresses established in bone by the direct influence of non passive prosthetic work to be a causative factor in marginal bone loss.^{7,8}

Another more recent explanation of marginal bone loss is the theory of establishing the biologic width directly related to the position of the implant-abutment microgap and its associated microbial flora.^{9,10}



In addition, some studies have shown that certain designs in the geometry of implant coronal part may contribute to bone loss, while other studies have indicated that such bone loss can be prevented by incorporating a biomechanical stable connection and a more retentive surface on the implant collar.^{11, 12}

Prevention of horizontal and vertical marginal peri-implant bone resorption during the post-loading period is fundamental in maintaining stable gingival levels around implant-supported restorations.¹³ It has been demonstrated that peri-implant marginal bone loss is time-related with significantly more acute bone loss during the preloading period than in the following loading phases (two years after surgery) and also during the first year after loading (six months to one year after surgery) than in the second one (one year to two years after surgery).

Aesthetic outcomes cannot be attributed to a single parameter. They are the result of a number of important factors, especially in the aesthetic area.


Both biologic width and the integration of platform switching concept are of utmost significance in preserving a stable marginal bone level around implant neck. It is important to understand mainly the meaning of biologic width.

Hence, the stable bone serves as a support for the soft tissue determining the long-term aesthetic and functional treatment, the outcome stability being ensured in this manner.

The following points should be noted:

- The use of a single post for temporary and final prosthetic work;
- As long as the frequent replacement of parts is not avoided, repeated destruction of the connective-tissue attachment of the biologic width occurs increasing the risk of bone resorption;
- A special implant and abutment design (a ledge and integration of the biologic width/tapered shape of the post) facilitates nonsurgical lengthening and thickening of the peri-implant soft tissue.

This leads to the establishment of a wider and more resistant zone of connective tissue. A micro-rough and nano-rough titanium surface extending to the implant shoulder in conjunction with the platform switching concept provides osseous integration along the entire length of the implant.



A fine thread optimally distributes the masticatory forces in the region of the implant neck, avoiding further bone loss in this region.¹⁵

Possible interactions amongst factors contributing to peri - implant bone loss.


These factors include:

- Surgical and anatomical considerations such as mucoperiosteal flap design, thickness of buccal and lingual cortical plates of bone remaining after osteotomy preparation, bone quality, healing technique submerged or non-submerged, early unintentional cover screw exposure by mucosal dehiscence and amount of keratinized Gingiva;
- Patient risk factors such as medical and pharmacological status, habits including cigarette smoking, poor oral hygiene, excessive alcohol consumption, mucosal erosive pathology like lichen planus, previous or present periodontitis (chronic or aggressive);
- Biologic width related factors such as level of the micro-gap, platform switching and implant-tooth or implant-implant distance;
- Implant design including geometry, surface, length and diameter;
- Biomechanical factors including time of loading, type of loading, type of prosthesis, habits like bruxism.

Flap design

It was reported in the literature long time ago³² that, whenever a mucoperiosteal flap is reflected about a tooth, some crestal bone resorption will occur. Similarly elevating a flap to place a dental implant will lead to crestal bone loss and there is evidence suggesting a direct relationship between size of full thickness flap and the resulting post op bone loss.

Other studies³³ reported no statistically significant differences using more traditional histological evaluation of retrieved specimens after twelve weeks of site healing. Becker reported the same magnitude of difference in buccal vertical



bone loss as Jeong, one millimeter less for flap-less approach.

Alveolar bone thickness

The main blood supply for buccal alveolar bone is supplied by vessels in the overlying muco periosteum³⁴ and is greatly affected by elevating a full thickness flap to facilitate placement of a dental implant. Studies suggest that if residual facial bone thickness is less than 2 mm and/or if dehiscences or fenestrations of facial bone occurred during osteotomy preparation, consideration should be given to augmenting facial bone thickness with GBR procedures.^{35,36}

Premature exposure of an implant cover screw through the overlying mucosa may result where mucosal tissues fail to achieve primary closure, or are too thin to avoid dehiscence, or have been traumatized with the transitional prosthesis. It was reported in the literature that patients with prematurely exposed cover screws suffered 3.9 times greater bone loss than non-exposed ones.³⁷

Quantity of keratinized tissue

Adequate keratinized tissue may be more important around implants than natural teeth for several reasons: supracrestal collagen fibers are oriented in a parallel rather than in a perpendicular configuration adjacent to transmucosal surfaces of implants³⁸, providing less resistance to local trauma and microbial penetration. Peri-implant mucosa may have a reduced capacity to regenerate itself due to compromised number of cells and poor vascular supply.³⁹

Oral hygiene, smoking, alcohol abuse

Patients with poor oral hygiene and/or existing periodontal disease experience greater peri-implant crestal bone loss than patient with good oral hygiene and stable periodontal status. Both

current and lifetime cigarette are associated with deterioration in bone quality and impaired wound healing.⁴⁰ Smoking has been shown to be one of the most significant factors predisposing to implant failure.⁴¹ Individuals who use alcohol in excess may have inadequate nutrition including vitamin deficits which may compromise initial site healing.⁴²

Diabetes

It is well known that diabetic patients are at higher risk for developing periodontitis and are also more prone to infection.⁴³ It is very likely that performance of dental implant will be affected as well. Poor metabolic control in diabetic patients increases the risk of peri-implantitis.⁴⁴

Biologic width

Crestal bone remodeling to establish "biologic width" or soft tissue seal in peri-implant mucosal tissues is considered to be an important factor contributing to early crestal bone loss with all types of endosseous dental implants (Fig. 4).^{45,46}

Factors known to affect this crestal bone loss include the level of micro-gap in relation to the bone crest, platform switching achieved either by implant body design and/or by using an abutment smaller in diameter than the implant body and tooth-implant or inter-implant horizontal distance. Another factor with deleterious effect on crestal bone resorption is considered to be the repeated removal and replacement of abutments because of disruption of the soft tissue seal.⁴⁷

The biologic width has changed horizontally within the platform switched implant.

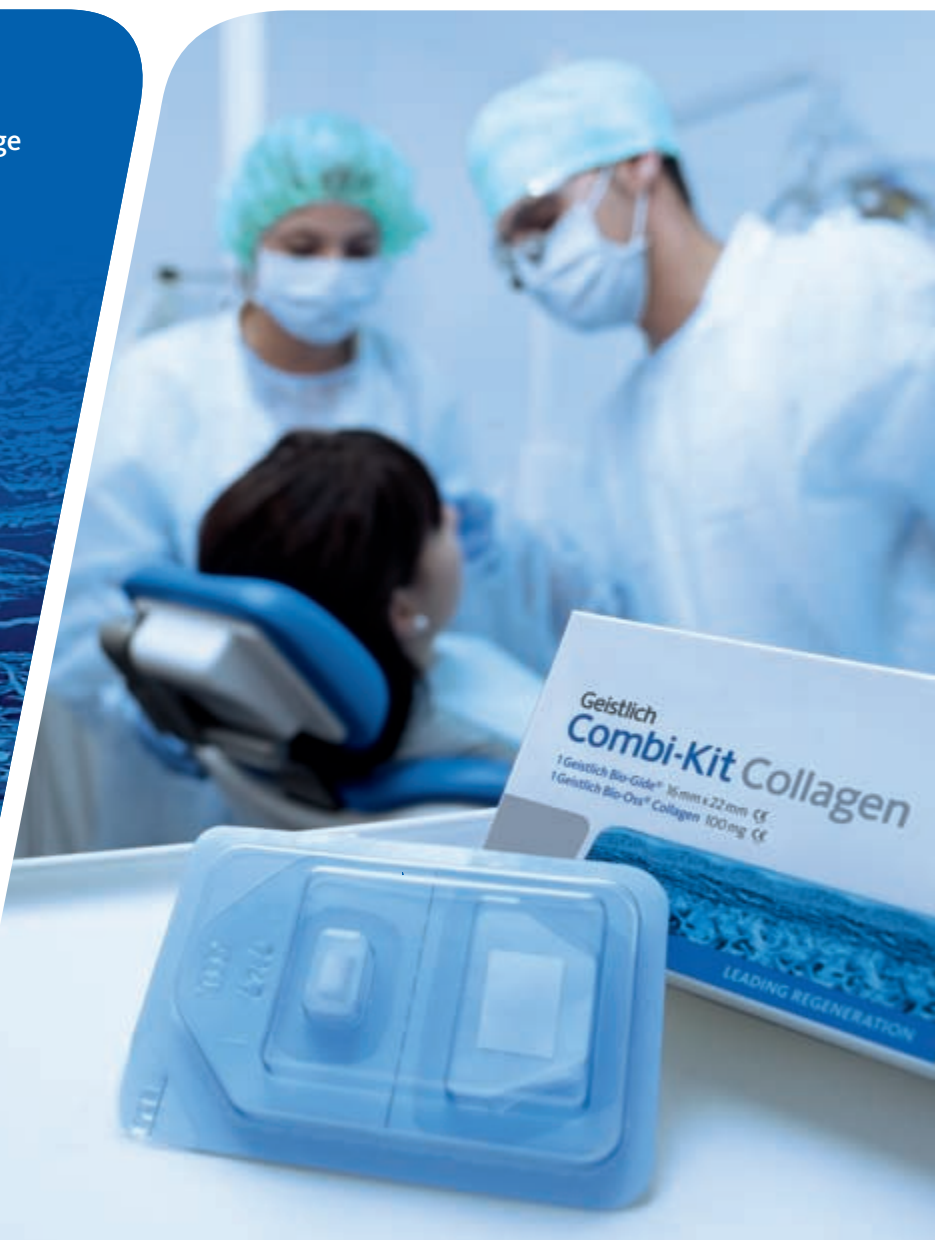Level of the micro-gap

The connection between implant body and prosthetic abutment is termed "micro-gap" and, in most cases, it is susceptible to microbial seeding and micro-movements between the parts during clinical function. Both micro-gap and micro-movements may lead to localized inflammation and associated crestal bone loss if the micro-gap is within a minimum distance from the alveolar crest. Biologic width around the neck of a dental implant constitutes a mucosal seal intended to protect the underlying bone. It is formed apically to the micro-gap and requires a minimum of about 1.5 mm of fibrous connective tissue between bone and epithelial attachment of the gingival sulcus of the implant (Fig. 5).^{48,49}

Geistlich Combi-Kit Collagen

The new kit for success.

Geistlich Combi-Kit Collagen – the best kit for successful and predictable results in ridge preservation and minor augmentations.



Platform switching

This design feature can be created in an implant body or achieved by the clinician using a compatible abutment of a narrower diameter than the implant platform. It can be acquired even with the healing abutment in case of non-submerged approach. The purpose of platform switching is to create a horizontal component for the total linear distance between micro-gap and bone crest required for biologic width⁵⁰ and eventually to shift the stress concentration away from the cervical bone-implant interface.⁵¹

Generally, the horizontal component created by platform switching is around 0.5 mm (Fig. 6), sufficient to result in significantly less radiological detectable crestal bone loss in humans.^{51, 52} Not only does this concept reduce the risk of peri-implantitis in the future but also has the benefit in the aesthetic zone of providing better soft tissue support.⁵³

Implant-tooth or inter-implant distance

For single tooth dental implants, a minimum horizontal distance of 1.5 mm must be left between the implant and the two approximating tooth root surfaces in order to avoid crestal bone loss after biologic width accommodation.

When two implants are placed side by side, the crestal bone loss that occurs between them has a more complicated aetiology. First and foremost, inter-implant crestal bone loss will be affected by the horizontal distance between the two implants which should be minimum 3 mm (Fig. 7). It will also be influenced by the level of micro-gap, biologic width, and whether platform switching was used or not. A clear tendency for increased inter-implant vertical bone loss occurs as the distance between two implants decreases below 3 mm.^{54, 55}

Histological data from animal experiments using 2-piece, moderately rough surface, submerged implants, showed that vertical inter-implant bone loss decreased from 1.98 mm for a 2 mm inter-implant distance to 0.23 mm for 5 mm inter-implant distance.⁵⁶

Conclusion

Significant differences in marginal bone loss have been identified between implants with platform switching and implants without platform switching only in the first year after loading. It may be concluded that the platform switching concept represents a bone preserving technique.

Preservation of crestal bone around dental implants cannot be attributed to a single parameter. That is the result of a number of important factors, especially in the challenging aesthetic zone.

It is important to understand the mechanism that permits the implant-abutment connection to maintain a seal against the bacterial ingress before and after loading due to absence of micromovements.

An appropriate understanding of the importance of biologic width and the use of platform switching concept in the routine treatment is of real support in maintaining a more stable marginal bone level around implants.

This stable marginal bone as a support of the soft tissue is determinant for the long-term aesthetic stability.

Further neutral clinical studies are required to demonstrate the importance of micro-gap, biologic width and platform-switching in crestal bone preservation around dental implants.

For the support I thank:

Dr. Mazen Tamimi, Private Practice, Amman, Jordan, Dr. Rainer Valentin, Private practice, Cologne, Germany, Dr. R. & M. Vollmer, Private practices, Wissen, Germany

Editorial note: The literature list can be requested from the author.

_contact	implants
Dr Virgil Koszegi Stoianov Msc Office: Str.Paciurea No. 5 300036 Timisoara, Romania Tel.: +40 356433733 Mobile: +40 723573443 E-mail: virgil.koszegi@medicis.ro	

Willkommen in München am Oktoberfest!

2nd European Implant Direct Congress
September 24th - 26th 2010

2nd European Implant Direct Congress - September 24th - 26th 2010

Challenging
Conventional
Thinking in
Implant
Dentistry



Send us your best cases and
**Win trip to
Munich!**

Program Preview

Scientific Lecture Program
Hands-On Session

Friday Afternoon, 24.09.10,
13:00-17:00, 95 Euro

Sunday Morning, 26.09.10,
9:00-13:00, 95 Euro

Congress Speakers

Dr. Gerald Niznick (USA)
Dr. Ferdinando D'Avenia (Italy)
Dr. Roberto Martelli (Italy)
Dr. Pedro Peña (Spain)
Dr. Frederic Hermann (Switzerland)
Dr. Marius Steigmann (Germany)
Dr. Achim Sieper (Germany)
Dr. Roland Török (Germany)
Dr. Jan- Willem Vaartjes (Netherlands)

Entertaining social and
cultural program

Enjoy the very popular "Oktoberfest"
or BMW Drivertaining

Top participation options

5 star Package 799 Euro*

4 star Premium Package 699 Euro*

4 star Basic Package 599 Euro*

* includes accomodation from 24th to
26th, reception, entry to the congress,
evening program



Register today!

www.implantdirect.eu
Tollfree Infoline 00800 4030 4030
info-eu@implantdirect.com



**Implant
Direct™**

simply smarter.

Rehabilitation of **atrophic maxillas** using zygomatic implants

A literature review

Authors Joan Pi-Urgell¹, Javier Mir-Mari², Rui Figueiredo & Cosme Gay-Escoda³, Spain

_ Introduction

Zygomatic implants, first introduced by Brånemark in 1988, are especially suitable for patients with advanced atrophy of the maxilla and who refuse or have suffered a complication after bone grafting procedures. The few studies with large samples and adequate follow-ups¹⁻⁶, show excellent results. Survival and success rates, as well as, the incidence of complications are detailed below based on a Medline review on zygomatic implant papers.

Traditionally, these implants had a palatal emergence, crossed the maxillary sinus and were anchored in the zygomatic bone. Nowadays, the palatal emergence can be avoided by using the "extramaxillary" implants technique, where the zygomatic implant goes through the lateral wall of the maxillary sinus. The high survival rates (higher than 90%) and the low incidence of complications reported in the reviewed papers, make zygomatic implants a good treatment option for the rehabilitation of severely resorbed maxillas. In this paper, the authors will address the anatomy of the region, the indications of these implants, the several available surgical techniques, the survival rates and complications.

_The zygomatic implant

The classical zygomatic fixture design (Brånemark Osseointegration Centre and Exopro, Gothenburg, Sweden) was a self-tapping implant in c.p. (commercially pure) titanium with a well-defined machined surface. It was available in different lengths ranging from 30 to 52.5 mm, and was slightly tapered (coronal diameter of 4.5 mm

and apical diameter of 4.0 mm). This diameter variation was due to the necessity of increasing the anchorage at the alveolar process while reducing the risk of complications (orbital bleeding, infraorbital nerve affection, etc.) in the apical region. The coronal portion of the implant presented a tilted connection of 45° to facilitate the prosthetic rehabilitation.¹

At present, this implant has a rough surface and the coronal portion of the implants may present different angles ranging from 25° to 55°. Boyes-Varley et al.⁷ proposed a 55° angle in order to avoid the palatal emergence of the prosthetic connection, which is one of the most discussed inconveniences of these fixtures.

_Anatomical basis for the zygomatic implant

The zygomatic bone could be compared to a pyramid, offering a solid anatomic structure for implant anchorage.⁸ A histological analysis of this area revealed the presence of a regular and dense bone with very high osseous density (up to 98%).⁹ Due to these features, the zygomatic bone has already been used to place miniplates as a part of the orthodontic treatment. According to an anatomical study, the mean length of useful bone in this region is 14 mm.¹⁰

_Indications of the technique

According to Malevez et al.⁶ and Aparicio et al.¹¹ the zygomatic implants are a valid alternative to bone grafting in patients with advanced maxillary atrophy. This technique would be suitable when the following conditions are present:

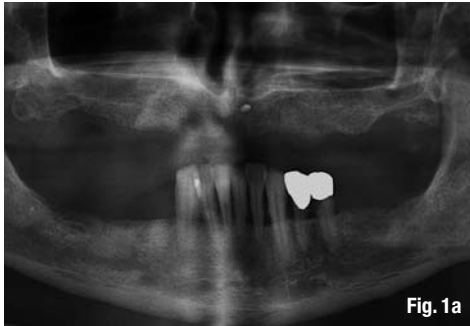

Fig. 1a

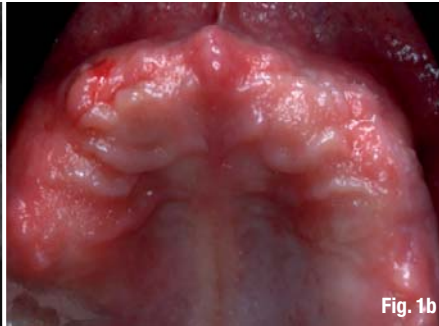


Fig. 1b

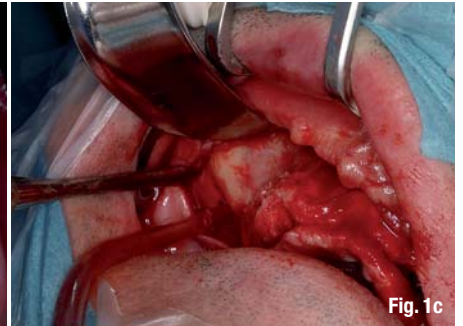


Fig. 1c

1. Light to moderate bone atrophy in the anterior region of the maxilla, with a posterior resorption of the alveolar process: This situation allows the placement of two to four implants in the anterior region, but the resorption of the posterior maxilla makes the placement of standard fixtures in this area unfeasible. In this case two zygomatic implants will be placed, one for each side.

2. Advanced atrophy of the maxilla (anterior and posterior): In this case two options are available: the use of bone grafting techniques in the anterior region can be performed and the placement of two zygomatic implants for the posterior region; or the placement of four zygomatic implants, two on each side without any anterior standard implants.

Presurgical evaluation

Maxilla, maxillary sinus and zygomatic bone are the three main structures to be considered before surgery. A panoramic radiography, a computed tomography (CT), as well as an adequate clinical examination are paramount to perform a correct diagnosis and treatment planning of the case (Figs. 1a & b).

The presence of sinus pathology might compromise the final result and the survival of the zygomatic implants, so it is essential to treat this kind of conditions before the surgical procedure.⁶

Surgical procedure

General anaesthesia in conjunction with the administration of a local anaesthetic is the traditional recommendation for the management of patient undergoing zygomatic implants placement. More recently, some authors have also used intravenous conscious sedation techniques for the same purpose.¹²

Blocks of the alveolar superior nerves, infraorbital nerves, and palatal nerves² are required.

A buccal approach using the traditional Le Fort I incision, can be made between the first molar regions¹ (Fig. 1c). Another option is to perform a crestal incision allowing improved palatal access for implant placement.² After raising the mucoperiosteal flap, soft tissue dissection has to be extended along the inferior and frontal lateral surfaces of the zygomatic bone, with identification of the infraorbital foramen. Special care has to be taken to avoid invasion of the orbit or sectioning the insertion of the masseter muscles in excess, as important bleeding could occur. The palatal mucosa has then to be detached, especially in the zone of the second premolar/first molar. Afterwards, a 10 x 5 mm infrazygomatic window in the lateral wall of the maxillary sinus should be created to keep the Schneiderian membrane intact (Fig. 1d). This window should allow the observation of the drilling sequence as well as the implant placement (Figs. 1 e–g). Brånemark et al.¹ recommend to place a gauze soaked in adren-

Fig. 1a_Preoperative panoramic radiography of a 54-year-old male with total maxillary edentulism.

Fig. 1b_ Preoperative aspect of the maxilla.

Fig. 1c_Raising of the mucoperiosteal flap up to the zygomatic arch.

Fig. 1d_Performing a lateral sinus window with a bone scraper.

Fig. 1e_Drilling from the 2nd premolar- 1st molar region to the zygomatic bone.

Fig. 1f_The machined surface zygomatic implant. Notice that the main anchorage site is the zygomatic bone and the residual crestal bone.

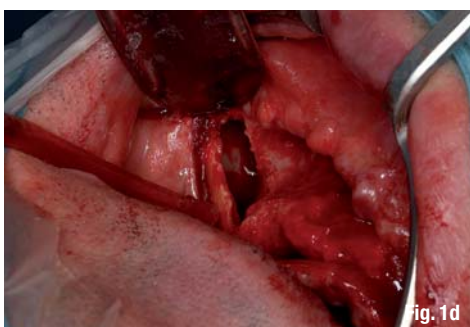


Fig. 1d

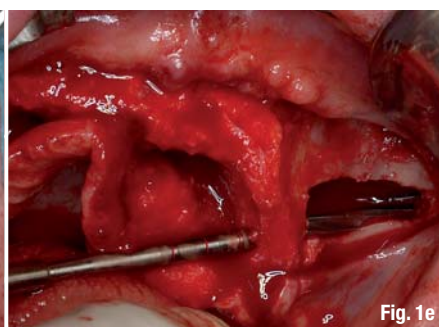


Fig. 1e

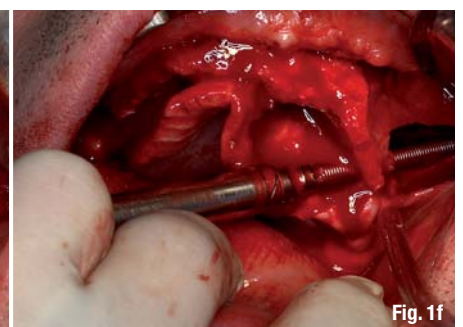


Fig. 1f

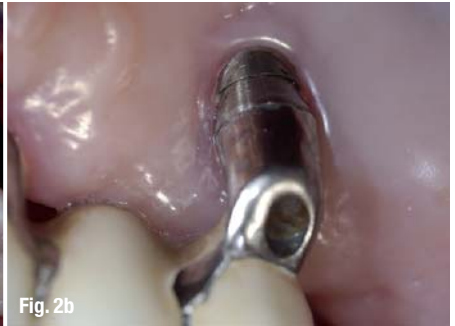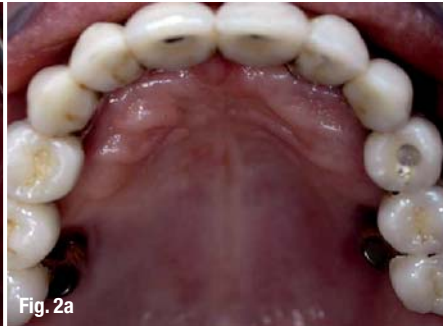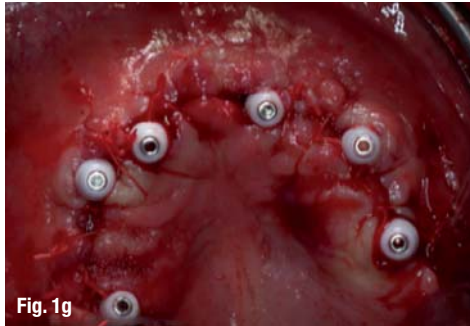


Fig. 1g_Final aspect of the maxilla. See the abutments for immediate loading and the palatal position of the distal implant in the first quadrant.

Fig. 2a_Metal-ceramic full-arch rehabilitation with four anterior implants and two zygomatic implants. Notice the palatal emergence of the zygomatic implants.

Fig. 2b_Detail of the palatal emergence.

align inside the sinus for a few minutes to prevent bleeding and deter mucosal tissue from blocking the view.

Technique modifications

The main disadvantage of this technique is related to the palatal emergence (Figs. 2a & b) of the implants that complicates the design of the prosthesis, reduces the patient's ability to speak and compromises the long-term health of the peri-implant tissues due to the difficulty that patients have to clean this area. Secondly, due to the intrasinus path of the implants the risk of sinus pathology development must be considered.²

Recently, some authors have proposed modifications of the classical technique described before. We would like to emphasize the following:

Extramaxillary implants

Basically, it consists of a modification of the implant entrance in the alveolar process and its trajectory up to the zygomatic bone.¹⁴ In this technique, the implant emergence is located just in the middle of the alveolar process, hence correcting the palatal entrance of the Brånemark technique. In its trajectory to the zygomatic bone, the fixture goes through the lateral sinus wall keeping the Schneiderian membrane intact. This technique not only improves the design of the prosthesis but also seems to reduce the incidence of sinusitis. Malo et al.¹⁴ and Aparicio et al.¹⁵ have already published some reports with excellent results (98.5–100% survival rates). On the other hand, the main complaint would be the fact that the middle part of the implant rests in direct contact with the soft tissue of the cheek.

Zygomatic implants without anterior standard implants

Frequently, the high degree of maxillary atrophy of these patients forces the surgeon to perform bone grafting techniques in the anterior area of the maxilla in order to place four standard implants. A modification first described by Bothur et al.¹⁶ recommended the placement of four to six zygomatic

implants in order to avoid the need of anterior fixtures and therefore to reduce the necessity of bone grafting in this area. In a study with 40 edentulous skulls, with atrophic alveolar processes and premaxillas, Rossi et al.¹⁷ measured the distances between the alveolar process emergence at the canine region and the premolar/molar region to the zygomatic bone. The authors stressed the fact that the mean length of distance between the canine regions to the zygomatic bone was 53.42 mm and the maximum distance was 61.94 mm. Given that the longest commercially available implant is 52.5 mm, the authors emphasize the importance of a precise presurgical evaluation of the available distance when the placement of four zygomatic implants is planned.

Sinus-slot technique

Stella and Warner¹⁸ described this method in 2000. Mainly, the "slot technique" is a reduction of the sinus wall perforation doing a slot instead of a window. Likewise, this modification permits a good control of the drilling direction and insertion of the zygomatic fixture. Furthermore, according to the authors a higher amount of bone is preserved and also the flap size can be reduced, improving the patients' postoperative recovery. Peñarrocha et al.¹² published in 2007 a series of 21 cases with the "Slot technique" with a 100% survival rate, but the Schneiderian membrane was perforated in all cases, even though the incidence of sinus pathology was low (two cases).

Immediate loading

Traditionally, the zygomatic implant loading protocol has been a two-stage approach. Nowadays, just a few numbers of authors have published results with an immediate loading protocol. To our knowledge, the first case-series was published in 2006 by Bedrossian et al.¹⁹ The review included a total of 28 zygomatic implants and 55 standard implants that were loaded immediately after surgery. The authors reported very good results with a survival rate of 100% and without any complications. Other recent studies have also reported similar findings with survival rates ranging from 95.8% to 100%.^{4, 14, 15, 20-22}

Survival rates

The literature review revealed a mean survival rate for zygomatic implants higher than 90 %, regardless of the technique used. The most common option is the classical technique, with machined surface implants, in a two-stage loading protocol. Twelve of the 19 papers reviewed with follow-up, met this criteria.^{1-3, 5-7, 12, 23-27} The other alternatives also present very good results with 95.8–100 % survival rates.^{4, 14, 15, 19-22} A surprising outcome is that the survival rate of the standard implants placed in the anterior region is quite low (73–98 %). This is probably related to the high degree of resorption that surgeons find in this area, therefore requiring more complex grafting procedures.

A total of 1,163 zygomatic implants were found in our review of 19 articles with adequate follow-up. Twenty-three implants (2.0 %) were lost, 14 (60.1 %) during the osseointegration period and nine (39.1 %) after loading. These data can be observed in table 1.

Complications

Sixteen papers reported complications. Different authors comment as possible complications orbital lesions, maxillary sinus posterior wall and infratemporal fossa perforation, intraoperative bleeding, nerve lesions (infraorbital nerve), sinus pathology, lip lesion during the drilling, among others. Nevertheless, only some of these were actually registered in the reviewed studies (26 cases of sinus pathology^{1-3, 5, 12, 14, 22, 23, 26, 27}, seven cases of infraorbital nerve impairment^{3, 5}, six cases of lip lesion during drilling^{3, 23} and nine cases of suborbital haematoma^{3, 23}).

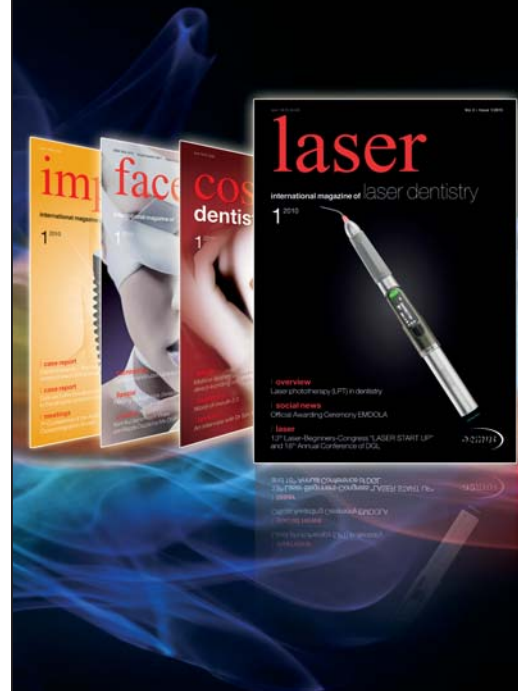It is important to stress that most of the cases with sinus pathology were favourably solved. Some of them only needed pharmacological therapy, while others were treated with an antrostomy surgery. Only three zygomatic implants, all from the same report²⁷, were removed due to their association with recurrent sinusitis.

Discussion

First of all, the few number of papers published related with zygomatic implants was surprisingly low, 59 articles in our Medline review (December, 2009). Among them, only 19 presented follow-up results.^{1-7, 12, 14, 15, 19-27} Moreover, most of the authors are broadly experienced oral surgeons, which may difficult the reproducibility of their results.

Among all published techniques and modifications, the most common treatment option published is the classical technique, with machined surface implants, in a two-stage loading protocol (12 studies).^{1-3, 5-7, 12, 23-27} Another important factor is that the majority of the studies have reduced samples (only five articles had more than 100 implants)^{2, 4-6} and short follow-up times (only Brånemark et al.¹ presented a follow-up of five to ten years). These are important limitations that need to be corrected in future research. Nevertheless, the placement of these implants seems to be a good treatment option since the published results so far are excellent, regardless of the used technique (95.8–100 %). On the other hand, the standard implants placed in the anterior region have low survival rates (73–98 %). These differences could be related with the grafting techniques used in combination with the cited conventional implants. Accordingly, Brånemark et al.¹ presented a 73 % survival rate of the standard implants, but in this study, 70 % of the patients received bone grafts in the same surgical procedure in which the anterior implants were placed.

The failure pattern of zygomatic implant is very similar to that of the standard implants. If one takes the studies cited in this review into account, a total of 23 implants



One issue free of charge!

Subscribe now! ✂

I hereby agree to receive a free trial subscription of **laser international magazine of laser dentistry** (4 issues per year). I would like to subscribe to cosmetic dentistry for € 44* for German customers, € 46* for customers outside Germany, unless a written cancellation is sent within 14 days of the receipt of the trial subscription. The subscription will be renewed automatically every year until a written cancellation is sent to OEMUS MEDIA AG, Holbeinstr. 29, 04229 Leipzig, Germany, six weeks prior to the renewal date.

▶ Reply per Fax +49 341 48474-290 to OEMUS MEDIA AG or per E-mail to grasse@oemus-media.de

*Prices include shipping and VAT

Last Name

First Name

Company

Street

ZIP/City/County

E-Mail

Signature

Notice of revocation: I am able to revoke the subscription within 14 days after my order by sending a written cancellation to OEMUS MEDIA AG, Holbeinstr. 29, 04229 Leipzig, Germany.

Signature

OEMUS MEDIA AG
Holbeinstr. 29, 04229 Leipzig
Tel.: +49 341 48474-0
Fax: +49 341 48474-290
E-Mail: grasse@oemus-media.de



Author and year	Number of implants	Follow-up	Technique ¹	Survival	Failures ²	Complications
Brånemark et al. 2004 ¹	52 turned consecutive 28 patients	5–10 years	A Two-stages	94% (3/52)	2 E.F. 1 L.F.	Implant suppuration (2 patients) Sinusitis (2 patients)
Pi-Urgell et al. 2008 ²	101 turned 54 patients	1–72 months	A Two-stages	96,0% (4/101)	2 E.F. 2 L.F.	Sinusitis (1 patient)
Ahlgren et al. 2006 ²³	25 NR ³ 13 patients	11–49 months	A Two-stages	100%	0	Haematoma (3 patients) Lip lesion (1 patient)
Al-Nawas et al. 2004 ²⁴	20 NR 4 patients	12–30 months	A Two-stages	95% (1/20)	1 E.F.	Sinus fistula (1 patient)
Balshi et al. 2009 ⁴	110 76 turned 34 TiUnite 56 patients	9–60 months	A Immediate loading	96,4% (4/110)	4 E.F.	Not reported
Bedrossian et al. 2002 ²⁵	44 turned 22 patients	34 months	A Two-stages	100% (0/44)	0	Not reported
Bedrossian et al. 2006 ¹⁹	28 TiUnite 14 patients	12 months	A Immediate loading	100% (0/28)	0	Without complications
Boyes-Varley et al. 2003 ⁷	77 NR 47 45° 30 55° 45 patients	6–30 months	A Two-stages	100% (0/77)	0	Not reported
Davo et al. 2007 ²²	36 turned consecutive 18 patients	Mean 14 months	A Immediate loading	100% (0/36)	0	Sinusitis (1 patient)
Farzard et al. 2006 ²⁶	22 turned 11 patients	18–46 months	A Two-stages	100% (0/22)	0	Sinus discomfort (3 patients)
Kahnberg et al. 2007 ⁵	145 Turned and TiUnite 76 patients	36 months	A Two-stages	96,3% (5/145)	3 E.F. 2 L.F.	Sinus discomfort (14 patients) Sinusitis (1 patient) Nerve impairment (1 patient)
Malevez et al. 2004 ⁶	103 turned 55 patients	6–48 months	A Two-stages	100% (0/103)	0	Sinusitis (6 patients)
Maló et al. 2008 ¹⁴	67 TiUnite 29 patients	6–18 months	A, B, C Immediate loading	98,5% (1/67)	1 E.F.	Sinusitis (4 patients)

Table 1_ Results from the reviewed studies with adequate follow-ups.

Author and year	Number of implants	Follow-up	Technique ¹	Survival	Failures ²	Complications
Aparicio et al. 2006 ³	131 turned consecutive 69 patients	6–60 months	A Two-stages	100% (0/131)	0	Haematoma (6 patients) Lip lesion (5 patients) Nerve impairment (6 patients) Sinusitis (3 patients)
Becktor et al. 2005 ²⁷	31 NR 16 patients	9–69 months	A Two-stages	90,3 % (3/31)	3 L.F.	Sinusitis (6 patients) Sinus fistula (5 patients)
Aparicio et al. 2008 ²¹	36 turned consecutive 20 patients	36–48 months	B Immediate loading	100% (0/36)	0	Without complications
Aparicio et al. 2008 ¹⁵	47 turned consecutive 25 patients	24–60 months	A and B Immediate loading	100% (0/47)	0	Without complications
Duarte et al. 2007 ²⁰	48 turned 12 patients	6–30 months	C Immediate loading	95,8% (2/48)	1 E.F. 1 L.F.	Without complications
Peñarrocha 2007 ¹²	40 turned 21 patients	12–45 months	A Two-stages	100% (0/40)	0	Sinusitis (2 patients)
Total	1,163 implants 598 patients	6–69 months	A (17) B (3) C (2) Two-stages (12) Immediate loading (7)	98,0% (23/1,163)	14 E.F. (60.9%) 9 L.F. (39.1%)	Sinusitis (26 patients) Sinus discomfort (17 patients) Haematoma (9 patients) Nerve impairment (7 patients) Lip lesion (6 patients) Sinus fistula (6 patients) Implant suppuration (2 patients)

1 A) 1 or 2 intrasinusal zygomatic implants combined with anterior standard implants

B) 1 or 2 extramaxillary zygomatic implants combined with anterior standard implants

C) 4 zygomatic implants without anterior standard implants

2 E.F.: Early Failure (during first 12 months) or L.F. (after 12 months)

3 NR: Not Reported

were lost (23/1163; 2.0%), fourteen (60.1%) before loading and nine (39.1%) after loading. Only one author (Pi-Urgell et al.)² presented the fracture of one of the zygomatic implants, which is probably a rare complication. Farzard et al.²⁶ observed that the marginal bone loss in the zygomatic implants would represent a decrease in the stability of the implant over time, with progressively lower Implant Stability Quotient (ISQ) values (<50). This confirms that the main anchorage site of the zygomatic implants is the zygomatic bone, especially in the long term, since and the resorption of the residual crestal bone can occur. This unfavourable biomechanical situation could eventually lead to an increase in the incidence of implant fractures in future studies with long follow-ups.

Although some authors comment on the level of satisfaction or quality of life in their reports^{6, 19, 28}, only Al-Nawas et al.²⁴ introduce success criteria in their results. These authors analysed the periimplant soft tissue's health (gingival bleeding index, probing depth, microbiological testing, etc.) concluding that only eleven of the 20 zygomatic implants (55%) would be considered successful, while the survival rate was 95%.

A precise surgical evaluation of the patient is mandatory in this complex technique, since serious complications might occur, especially due to the length of the implant and to the presence of important anatomical structures (orbit, infratemporal fossa, etc) in the zygomatic anchorage area. Moreover, our literature review showed a low rate of complications (9.5%), all being minor problems. Sinus pathology seems to be the most frequent complication, although other conditions have been reported. According to Maló et al.¹⁴ the sinus pathology is related to previous episodes of sinusitis or to the intraoperative perforation of the Schneiderian membrane. On the contrary, other authors like Brånemark et al.¹ mention in their article that no special effort was made to keep the sinus membrane intact. As a matter of fact, Peñarrocha et al.¹², perforated all the sinus membranes in their study with 40 zygomatic implants and reported only two cases of sinusitis. This is an interesting aspect to discuss in future research, since the available data is clearly insufficient. When sinus pathology is diagnosed long after implant placement, it is difficult to identify the cause of the sinusitis. In fact, only one of the papers mentioned the removal of three implants because the patients had frequent episodes of sinus infections. On the other hand, all the other authors decided to maintain the implants and the sinus pathologies were favourably managed with antibiotics or with antibiotics in combination with antrostomy surgery. The maxillary sinus could also be affected if there is a

substantial marginal bone loss, as described by Al-Nawas et al.²⁴ In these cases, the infection will reach the maxillary sinus through the periimplant pockets.

The lack of stability, aesthetics and/or function of the prosthesis and the deficient hygiene of the abutment areas are also important complications. Probably, these are often related to the palatal emergence of the zygomatic implants. Nowadays, this limitation has been solved with the extramaxillary implants procedure.^{14, 21} Nevertheless, the long-term exposure of the titanium threads to the cheek's soft tissue has to be evaluated carefully.

Conclusions

Based on the current literature review, zygomatic implants show excellent survival rates (>90%) and a low incidence of complications, so this should be considered a valid and safe treatment option when dealing with patients with advanced maxillary atrophy. Nevertheless, the authors would like to express their concern with the scarce amount of published studies (most of them of retrospective nature), with the low level of scientific evidence available, and with the lack of studies with long follow-up periods. The introduction of success criteria also based on periodontal parameters should be considered in future research.

Editorial note: A complete list of references is available from the publisher.

_contact	implants
<p>Dr Rui Figueiredo DDS Associate professor of the Oral Surgery and Implantology Department, Barcelona Institut de Recerca Biomèdica de Bellvitge (IDIBELL) Facultat d'Odontologia Universitat de Barcelona Campus de Bellvitge Pavelló de Govern 2a planta, Despatx 2.9 08907 – L'Hospitalet de Llobregat, Spain Phone: +34 93 402 42 74 E-mail: ruiptfigueiredo@hotmail.com</p>	
<p>¹ MD, DDS., Professor of the Master degree program of Oral Surgery and Implantology, Barcelona ² DDS. Fellow, Master degree program of Oral Surgery and Implantology, Barcelona ³ MD, DDS, PhD. Chairman, Oral Surgery and Implantology Department, and Director, Master degree Program of Oral Surgery and Implantology, Barcelona.</p>	

40th INTERNATIONAL ANNUAL CONGRESS OF THE DGZI

Essential Oral Implantology

October 1-2, 2010, Berlin, Germany

Anniversary Conference



40 YEARS OF DGZI
1970-2010
 **DGZI**
Deutsche Gesellschaft für
Zahnärztliche Implantologie e.V.

Gold Sponsor



Silver Sponsor



Bronze Sponsor



Please fax this form to: +49-3 41/4 84 74-2 90

More information:

40th INTERNATIONAL ANNUAL CONGRESS OF THE DGZI

October 1-2, 2010, Berlin, Germany

office stamp

International events

2010

1st Croatian-German Implantology Meeting of DGZI

Where: Hvar, Croatia
Date: 10–12 June 2010
Website: www.hvarkongres.hr

FDI Annual World Dental Congress

Where: Salvador da Bahia, Brazil
Date: 02–05 September 2010
Website: www.fdiworldental.org

7th Forum of Innovations in Dentistry

Where: Leipzig, Germany
Date: 10–11 September 2010
Website: www.event-fiz.de

40th International Congress of DGZI

Where: Berlin, Germany
Date: 01–02 October 2010
Website: www.dgzi.de

19th Annual Scientific Meeting of EAO

Where: Glasgow, Scotland
Date: 06–09 October 2010
Website: www.eao.org

AAID 59th Annual Meeting

Where: Boston, MA, USA
Date: 20–23 October 2010
Website: www.aaid.com

96th Annual Meeting of AAP

Where: Honolulu, USA
Date: 30 October–2 November 2010
Website: www.perio.org

17th AIDC 2010

Where: Alexandria, Egypt
Date: 2–5 November 2010
Website: ww.aidc-egypt.org

Greater New York Dental Meeting

Where: New York, NY, USA
Date: 26 November–01 December 2010
Website: www.gnydm.org

2011

34th International Dental Show

Where: Cologne, Germany
Date: 22–26 March 2011
E-Mail: ids@koelnmesse.de
Website: www.ids-cologne.de

International Osteology Symposium

Where: Cannes, France
Date: 14–17 April 2011
Website: www.osteology-cannes.org



DGZI's anatomy weekend a full success!

Author_Dr Christian Ehrensberger, Germany

The large number of participants (40 in total) who attended DGZI's (German Association of Dental Implantology) weekend course "Anatomy" in early October 2009 in Dresden has clearly shown that many colleagues want to be kept up to date about research in this field, in order to make the right professional decisions. This course is now also offered in English.

Thanks to the clearly-structured concept and a theoretical introduction (an impressive demonstration including a live video broadcast from the dissecting room and patient-side practices using human specimens), the participants obtained the professional skills needed by practicing surgeons and implantologists in only two days.

A specially designed DGZI course module for anatomy has already been part of the Implantology curriculum for one decade. In particular, colleagues who only want to refresh their anatomical knowledge in a two-day professional training course can register for the current weekend course—ideal for colleagues who may have realized that two years after their state examination they are no longer able to recall the enormous knowledge required. Consequently there were many guest participants who took part in the Implantology curriculum. The contributions of anatomist Dr med. habil. Wolfgang Schwab of TU Dresden, oral biologist and anatomist Prof Dr Werner Götz of the University of Bonn, dissection assistant Ute Nimtschke, implantologists Dr Rainer Valentin and Dr Rolf Vollmer, and oral surgeons Dr Martina Vollmer and Dr Uta Voigt meant that the course was in competent hands as well as ensuring that the different points of view of the various disciplines were considered. The first day of the course was dedicated to a thorough introduction to the anatomy of the skull, including an exact demonstration of the supply for



nerves and blood vessels and the anatomy of bones, tongue, throat and larynx. In order to explain the particular surgical basics, the speakers demonstrated the procedures used for autologous and xenogenous augmentation and those for bone spreading. The highlight of the day was the application by Dr med. habil. Schwab and Prof Dr Götz of their theoretical knowledge to an actual anatomical specimen. Courtesy of certain modern techniques, including the video broadcast from the dissecting room, the participants could ask questions in real time during the presentation. The second day of the course started again with a theoretical introduction—this time Dr Rolf Vollmer introduced the different implantological techniques. The sponsoring companies (Geistlich, Mectron, Schütz, Zepf) explained the features of all of the instruments and working materials which they had provided so that the participants could practice the acquired techniques with them. Towards the end, Dr Schwab and Dr Valentin demonstrated an autologous bone removal from the iliac crest. This highly successful professional training weekend was completed efficiently and to high standard. All participants agreed that a follow-up of this course should take place in October 2010.

25th Anniversary of the Academy of Osseointegration

Authors_Dr Rolf Vollmer & Dr Rainer Valentin, Germany



_Various approaches, complications among meeting highlights, different approaches to implant therapy and solutions to unexpected complications were among the highlights of the Academy of Osseointegration's 25th Anniversary Annual Meeting, March 4–6, at the Walt Disney World Dolphin Resort in Orlando.

It is no surprise that the German Association of Dental Implantology (DGZI) took part in this year's congress in the United States of America, as the AO is the DGZI's largest affiliated association. Members of the Board Dr Rainer Valentin and Dr Rolf Vollmer as well as DGZI's international representative Dr Mazen Tamimi attended lectures and exhibitions at the Walt Disney World Dolphin Resort.

To start the conference the current President of the AO Vincent J. Jacono presented the congress program and noted that the Academy's mission should be the improvement of oral health. In order to be able to do so, colleagues were brought up to date about the state of the art in implantology and tissue regeneration.

The 25th anniversary annual meeting started on Thursday, March 4, with the opening symposium, "A Quarter Century of Experience: The Formula for Predictable Implant Success in the Esthetic Zone." Other AO Annual Meeting highlights included Hands-on workshop: The pre-meeting, daylong series of sessions explored how 3-D imaging and navigation technology helps providers fabricate surgical templates, generate final prosthesis and place implants more effectively as part of the "team approach" concept.

AO's 2010 Corporate Forum featured 36 manufacturer-hosted educational sessions concerning the latest research, products and developments. During the congress different options concerning implant therapies and solutions for unexpected complications were discussed in details in the main podium. Colleagues could also attend hands-on workshops and listen to the AO corporate panel.

"Treatment Approaches: Controversies in Implant Dentistry," held on Friday, March 5, and Saturday's "Unexpected Complications: Complications and Solutions," were the key pillars of the meeting's overall



theme, "The Formula for Predictable Implant Success."

Approaches, controversies Friday's implant therapy program gathered an international roster of experts to review the latest treatments and materials through an evidence-based approach. Saturday's session on complications explored why problems occur, how to treat them and what we can do to prevent them.

"Two-Track" scientific program

The surgical track explored "Surgical Procedures to enhance implant success in the Esthetic Zone." The restorative track, "Where, When, Why and How," covered prosthetic considerations for restoring angled or tilted implants; endodontics vs. implants and early predictors for biological and technical complications.

Round table clinics

Twelve separate sessions offered attendees the opportunity to discuss diverse topics.

Limited attendance lectures

Increased interaction between annual meeting attendees and world-class clinicians on a wide range of topics.

Allied staff program

The annual meeting's allied staff program offered concurrent sessions designed for dental lab technicians and hygienists.

In addition, colleagues from all over the world exhibited more than 250 posters throughout the conference. One full day was dedicated to surgical problems in the esthetic zone as well as to the types of esthetic problems prosthodontists have to deal with. The prosthetic handling of angulated placed implants, biological and technical complications, and endodontics, which completes against implants, were discussed in particular. Altogether this was a very successful congress with more than 2000 participants. Like every year, DGZI was invited to the International

Affiliates Committee on Saturday afternoon, an event also attended by delegations from Canada, Japan, England and Italy. The current President Iacono asked all participants to contribute ideas concerning future cooperation amongst affiliates.

The participants agreed on the fact that, in these times of globalization, no single country should be secluded from the global community. However, the situation in other countries may nonetheless be extremely different. One point for example is the language barrier of the Japanese colleagues. The so called Annual Business Meeting took place after the meeting of the international affiliates. The new President Dr. Peter Moy delivered his inaugural speech, and he thanked all speakers and representatives of affiliated associations, especially those who came from far away, for their attendance.

"The 2010 meeting served as a celebration of everything we have learned in the past 25 years, and how that knowledge can be applied for the benefit of our patients today," Annual Meeting Committee Chair Dr Stuart Froum, New York, N.Y., explained.

The next AO congresses will be held in Washington, DC from March 3–5, 2011, in Phoenix, Arizona from March 1–3, 2012, in Tampa, Florida from March 7–9, 2013, and in Seattle, Washington from March 6–8, 2014. All colleagues interested in attending one of those meetings together with us, should contact the DGZI office in Düsseldorf for further details.

_contact

implants

DGZI Office Düsseldorf

Feldstraße 80
40479 Düsseldorf,
Germany
Tel.: +49 211 16970-77
Fax: +49 211 16970-66
E-mail: hartmann@dentalnet.de

6th Arab-German Implantology Meeting of DGZI

March traditionally blesses Egypt with superb weather - warm days and soft evenings, which allow Egyptian hospitality to be showcased perfectly. Certainly the weather conditions were just one of the reasons to join the second international dental congress and 6th Arab-German Implantology Meeting held in Cairo on 24–26 March 2010.

On behalf of the Faculty of Oral and Dental Medicine of Cairo University, Professor Nour Habib, Dean of the Faculty, addressed a warm welcome to all the participants of the second international dental congress held in Cairo on 24–26 March, 2010.

In the opening ceremony of the Congress he highlighted the Conference's aims to promote professional development among dentists by acting as a means for communication and by encouraging dis-

ussion and research in all areas of dental practice. "We seek also to promote the dental profession in the community at large and to develop a spirit of cooperation with other organizations and groups with common interests and concerns," Professor Nour Habib explained.

The Congress also hosted the 6th Arab-German Implantology Meeting, moderated by well known scientific presenters from the Board of the German Association of Dental Implantology (DGZI) who worked as a team of distinguished professionals to resolve a tricky dental scenario.

The venue chosen to host the congress was Cairo InterContinental City Stars Hotel, where a huge floor-space accommodated the innovative associated Dental Trade Industry display. There was ample space for



the profession to experience the new technologies and materials that were showcased at the event. The Conference was complemented by an exhibition which provided the participants with the valuable opportunity to engage with vendors and explore the diversity of dental products and services available to support them in their work. Dr Mazen Tamimi, International Representative of DGZI, Scientific chairman and Dr. Rolf Vollmer, 1st Vice President of DGZI and Congress Chairman welcomed more than 30 participants from Egypt and Middle East. They promised an interesting one day scientific program with international key note speakers and colleagues presenting their master thesis as well. "Excellent education is one of the main focuses of DGZI and is something we concentrate on for the sake of our patients. In this way, we can ensure that our professionals benefit from the best education possible without having to turn to fee-charging companies," was the statement of Dr Tamimi.

_Scientific Program on Friday 26th of March 2010

Abstracts

Keynote Speakers



Dr Roland Hille

Dr Roland Hille, Germany The way to the esthetical success

Implantology in the aesthetic zone is one of the biggest challenges in dentistry. An exact analysis of the clinical situation before we start with our treatment

gives us confidence in our treatment plan. We must know the problems as well as the outcome before we start with our surgery and we also must have a clear conception of the final aesthetic prosthetic situation. The patient contemplates only the crown, not the implant in the bone. The patient's desire is to get a perfect aesthetic restoration which lasts for a long time. In particular, we need soft tissue support to achieve a perfect aesthetic result. This lecture provides information about important points to achieve success in the aesthetic zone, and also shows mistakes one should avoid.

Dr Suheil Boutros, USA

New Concept in Preparing the Lateral Window in Sinus Lift Surgery

The lateral window sinus lift is a well-documented treatment modality used to augment the posterior maxilla when the remaining alveolar bone is 5 mm or less in height. Several methods of preparing the win-



Dr Suheil Boutros

dow have been proposed and documented, including the use of diamond and end-cutting burs and more recently the use of piezo surgery. Each of these techniques has its limitations; for example, the use of cutting burs presents higher incidences of the Schneideri membrane perforation, where as high as 40% has been documented. More recently the use of piezo surgery has been presented as an effective and safe means in lateral window preparation. The only limitation found with this surgery is that if the lateral wall is thick, it may become a time-consuming and less effective technique. The new innovation utilizes a large size side cutting bur, which is 5-7mm in diameter, making it very safe, predictable and a fast way to prepare the window.



Dr Mazen Tamimi

Dr Mazen Tamimi, Jordan Block Grafts as an option of treatment of severely atrophied mandible and maxilla

Several options for treating a severely atrophied mandible with less than 8 mm of bone remaining above the inferior alveolar nerve will be discussed. These include:

- _ Bone block grafts of autogeneous origin or allograft
- _ Distraction Osteogenesis
- _ Nerve trans-positioning; exact technique & videos
- _ How to perform these advanced surgery solutions
- _ Short implants as an alternative.

There will be a discussion regarding how to choose a suitable treatment option, and how to perform that technique.



Dr Robert Laux

Dr Robert Laux, Germany Telescopic Attachments, New Modern Concept of Abutments and Transfers

Telescope or conical crowns have been recognized as successful connection elements for natural abutments for several decades now. They also offer excellent hygiene. Telescopes require perfect parallelism or a well-defined slight conicity of the primary copings. This can only be achieved with custom components or customized prefabricated components. Conical crowns with a cone angle of 4° allow for axial divergence between adjacent implants of up

to 8°. However, given the anatomical shape of the jaws, especially the maxilla, it is almost impossible to place anterior implants so that they do not exceed this axial divergence. The problem of angle compensation has to be resolved in the simplest possible manner. Any manipulation at the laboratory constitutes a compromise that defeats the purpose of working with prefabricated components. The Kobold, the Titan and the complete abutment are systems which lead to easier success in fixed and removable implant-prosthetics.



Dr Rolf Vollmer

Dr Rolf Vollmer, Germany
The posterior atrophied maxilla. Patient-centered choice of treatment

Sinus lifting techniques have been known about for more than 20 years and are accepted as standard techniques, ie beyond the experimental stage. This lecture describes the development of sinus lift from its origins and explains the indirect and direct methods as well as giving hints for their different indications. However, alternatives to these sinus lift procedures should also be considered, and we will therefore discuss minimally invasive procedures which may be possible in the future.



Prof Dr Dr Ralf Gutwald

Prof Dr Dr Ralf Gutwald, Germany
Bioengineering in Implantology

For reconstruction prior to dental implantation the gold standard is still autologous bone. Disadvantages are the limited availability of bone and the necessity of an additional surgical procedure which always implies the risk of donor site morbidity. External Tissue Engineering procedures for hard tissue augmentations of the maxilla offer advantages compared with conventional grafts, as there is minimal or no donor site morbidity. Additionally, Internal Tissue Engineering with bone-inducing factors like BMP-2 look promising for use in bone augmentation procedures.

Current research aims at investigating the influence of stem cells on biomaterials. In animal experiments stem cell application (a chair side procedure) in combination with a biomaterial (BioOss) show lamellar bone formation. The volume preservation was better in the test side than in the control side where cancellous bone was applied only. The new bone formation was comparable.

In a clinical multi centre study 45 sinuses were augmented with BioOss and stem cells (test) and 25 sinuses were treated with a mixture of BioOss and autologous bone (control). Biopsies were obtained when implants were inserted after three months. There were also no differences in new bone formation.

Master Student presentations



Dr Iyad Ghoneim (L)

Dr Iyad Ghoneim, MSc
Krems University, Syria
Immediate implantation at the time of extraction— Clinical study with literature review

Missing teeth is a very old problem which has plagued humankind for many years. Various solutions have been attempted, ranging from re-implanting the teeth extracted, to making artificial prosthesis in the shape of the missing teeth, to implantation of a biologically accepted material like titanium, which is the material of choice today. A vast number of studies have taken place to assess the rate of success of Titanium implants and much development has taken place by researchers to develop these implants and to improve their mechanical and technical characteristics. At the same time, a variety of new surgical techniques have been developed in order to provide a larger range of treatments options.



Dr Hussam Bakki (L)

Dr Hussam Bakki, MSc
Krems University, Kuwait
The Presence of Underwood's Septa in the Maxillary Sinus Among The Population of Kuwait

This thesis is intended to examine the frequency of Underwood's Septa amongst the population of Kuwait, and consider how to deal with it while implementing sinus lift surgery by proper planning considering the septa's morphology and location, based on a reliable CT scan imaging. For this purpose radiographs from 8 patients who underwent sinus lift operation were re-evaluated in our specialist dental centre.

Materials & Methods

In this study, a relatively small sample population of 8 patients was considered (2 males and 6 females), with an average age of 35 years, ranging between 26 and 44 years. Nine sinuses were operated on (sinus lift). All patients were candidates for dental implant-supported restorations placement - they were in good

health, all of them were partially edentulous (patients for whom we planned to extract teeth during surgery were considered as partially edentulous in this study) and all surgeries were performed by the same surgeon.

Results

It appears that antral septa are more commonly found in edentulous atrophic maxillae than in dentate ones, in the posterior portion of the maxillae than in the anterior portion and in the left side rather than the right side of the maxillae. ACT scan is the radiographic method of first choice for detecting the presence of septa, while panoramic radiography was found to be less sensitive and sometimes misleading in detecting sinus septa. Precise knowledge of patient's maxillary sinus anatomy allows for exact planning of surgery and helps to avoid unexpected complications.



Dr Ahmed Fadl (l.)

Dr Ahmed Fadl, MSc Krems University, Sudan Evaluation of laser application to uncover dental Implant in the second stage surgery

Lasers have been used in oral surgeries for many years with great success. In this research (in which a diode laser 980 nm was used), 10 patients participated, each of whom had been treated with dental implants more than three months ago, with a conventional first surgical stage.

All the implants were uncovered successfully with laser aid. For each implant the procedure was completed in less than 10 minutes. All patients reported very minimal postoperative discomfort or very slight pain at the one-week recall appointment. A fixture level impression was taken at that recall appointment.

According to the results of this research, soft tissue laser should be considered as an effective alternative technique for implant uncovering in the second surgical stage.



Dr Hisham Abueljebain

Dr Hisham Abueljebain, MSc Krems University, Kuwait Stem Cell Derived Bone

Implant therapy has become the standard of care for edentulous areas of the oral cavity. Following tooth extraction, there is often an inadequate amount of bone in which to place dental implants. In such cases, a ridge augmentation procedure

is performed prior to implant placement. Ridge augmentation techniques to correct these defects include guided bone regeneration (GBR) utilizing a barrier membrane, bone graft alone or bone graft with a membrane.

In elderly patients bone grafting may cause another injury in the donor site which may take days or even months to heal. This is often unacceptable to many patients. We propose here a new technique which is less traumatic and hence more acceptable to the patients.

Bone marrow contains osteoblast progenitor cells which appear to arise from a population of pluripotential connective-tissue stem cells, which can be obtained with aspiration. When cultured *in vitro* under conditions that promote an osteoblastic phenotype, osteoblast progenitor cells proliferate to form colonies of cells that express alkaline phosphatase and, subsequently, a mature osteoblastic phenotype. These cells will produce new bone at the ridge which may give an implantologist adequate bone width at the ridge where an implant should be inserted.



Dr Subea Hijazi (r.)

Dr Subea Hijazi MSc Krems University, Syria Atrophied posterior mandible. Where to start?

Implant treatment is becoming the first choice to replace missing teeth or fill free spaces in the jaws. Nowadays, the bone resorption or bone defects can appear in horizontal or vertical direction or both. Bone reconstruction should restore bone volume in both directions. The type of handling this defect will allow the maintenance of implant and the primary stability, a favourable occlusal axis and an environment around implant that will facilitate prosthetic reconstruction and hygiene access to the implanted area.

Therefore, the posterior mandible region is always a challenge for doctors because of the anterior alveolar nerve, especially if there is advanced bone resorption in the area. Over the last decade many articles have been written detailing the scientific discussion of this problem and the search for possible solutions; we can divide them into:

1. Alternatives to implant treatment (no implant)
2. Bone augmentation techniques
3. Alveolar distraction
4. Nerve transposition or lateralization
5. Short implant
6. Subperiosteal implant



Dr Salah Daffalah

**Dr Salah Daffalah, MSc
Krems University, Sudan
New Implant Abutment**

The goal of modern dentistry is to restore the patient to normal health by restoring the contour, function and esthetics. As a result of continued research and improvement in diagnostic tools and treatment techniques, predictable success is now a reality for the rehabilitation of many challenging clinical situations. In recent years, dentistry has become greatly influenced by aesthetic considerations. The primary reason for this is patients' demands for natural appearing restorations. This has resulted in a massive development in the field of dental implantology over the past 30 years. A new implant abutment made of fiberglass was introduced recently. This new implant abutment option is cost- and time-effective and it meets the patients' expectations in relation to function and esthetics as the implant closely resembles the natural tooth color. This presentation aims at evaluating the effectiveness of fiberglass dental implants in relation to function and esthetics.



Dr Nicholas Papadopoulos

**Dr Nicholas Papadopoulos, MSc
Krems University, Cyprus
The two stage mandibular ridge split, an alternative bone expansion technique**

Introduction

Cases of narrow mandibular ridges (less than 5 mm in mandible) require horizontal augmentation for the placement of screw-type dental implants. A two stage mandibular ridge splitting to decrease the risk of malfracture during osteotomy and minimize the possibility of losing crestal bone is presented.

Method

After corticotomy of a rectangular buccal segment with thin separating disc and a three week healing period, the mandibular ridge was expanded and in some advanced cases split buccally, leaving the buccal periosteum attached to the lateralized segment.

Results

With buccal segments expanded with no complications, we can gain on average 2-3 mm of horizontal bone width.

Discussion

In the mandible, greenstick fracture during widening with osteotomes or expanders has not been con-

trollable to date because of cortical thickness and strength of the bone; the risk of malfracture in the middle of the thinnest buccal region is high, with the possibility of future bone receding being very high.

With this Two Stage Mandibular Ridge Split technique the location of the greenstick fracture is predetermined away from the midfacial crestal area, and the perfusion of the buccal segment remains attached and intact. The buccal cortical segment remains a pediculated graft after ridge splitting and thus the practical benefit is no bone loss crestally.



Dr Rouven Bönsel (r.)

**Dr Rouven Bönsel, MSc
Krems University, Germany
Prerequisites for immediate loading of dental implants**

Modern clinical approaches to loading of dental implants promise the patients immediately loaded implants. Based on this observation, this study will examine whether, considering the processes occurring during bone healing, immediate functional loading of dental implants is possible.

This study evaluates the predictability of early and immediate loading protocols of implants in the upper and lower jaw. In this observational study 450 dental implants were loaded early. The implants were inserted into various regions of the jaw in the maxilla and mandible. The criteria determined was whether the osseointegration had been completed after three months. The success rate in this observational study ranged from 92 % (upper jaw) to 100 % (lower jaw). The clinical applicability of the treatment concept is very favourable, due to the shortening of the treatment time.



Dr Adel Byadsi

**Dr Adel Byadsi, MSc
Krems University, Palestine
Sinus Lift—New Technique**

This lecture will show the advantages of a unique usage of the Piezo technique in fine and precise cutting of the bone, without damaging or causing perforation of the Schneiderian membrane.

This technique enables us to reuse the bone and thus negate the need for additional membrane. The success rate in such surgery is high and the complications are very low.

ITI World Symposium 2010



The International Team for Implantology (ITI), a leading academic organization dedicated to the promotion of evidence-based education and research in the field of implant dentistry, welcomed more than 4,000 participants from all over the world to the 2010 edition of its much anticipated ITI World Symposium. The city of Geneva, Switzerland, provided a picturesque backdrop to a full program of topical presentations and debate.

With his keynote address, world-renowned adventurer and scientist Bertrand Piccard set the tone for the three-day event that explored new and emerging territory in implant dentistry. The collective knowledge represented by the faculty of 113 experts from 26 countries provided a springboard for lively debate and discussion that continued beyond the official program. The scientific program was divided into three main facets of treatment: New clinical methods for diagnosis and treatment planning; New and proven treatment procedures; Complications in implant dentistry or dealing with reality. The smooth delivery and breadth of information provided over the three days served to underline the truth of the ITI's claim of "30 years of leadership and credibility".

For the first time, the main program was complemented by a pre-symposium program of two parallel full-day courses that allowed participants the luxury of total immersion in two narrowly defined areas of treatment. The highly popular Limited Attendance Sessions were also expanded from three to four compact lectures per session. "The ITI is fortunate that it can call on such a wide variety of opinion leaders in implant dentistry on an international basis to share their knowledge," said Stephen Chen, Chairman of the Scientific Program Committee. "This pool of expertise is the foundation for the success of the event and rein-

forces its well deserved reputation as the most prestigious academic event in the implant dentistry calendar."


"Every effort was made to ensure the smooth running of the event and give participants the best possible Symposium experience," commented Friedrich Buck, Executive Director of the ITI. "We also took the decision to hold an industry exhibition that drew 38 exhibitors from Europe as well as the USA, giving participants the opportunity to review some of the latest developments in the field and discuss their needs directly with manufacturers."

Rounding off the event was the Research award which attracted a great deal of interest. Competition for the nine presentation slots was fierce and the total of 118 posters testified to the central role played by research among the ITI membership as well as their readiness to share results.

The success of the ITI World Symposium is undisputed, it can be measured not only in terms of attendance figures, but also the accessibility of the event which provided simultaneous translation in 12 languages for the main program. The next ITI World Symposium will take place in 2014.



Interdisciplinary insights from theory to practice




„It was a congress of superlatives. 2,500 participants from more than 60 countries met in Barcelona on March 19–20, 2010. More than 100 internationally known lecturers presented the latest scientific insights to an attentive audience and described how they could be successfully integrated into practice. Professor Lim Kwong Cheung of Hong Kong, Dr Henry Salama from the USA and Professor Heiner Weber from Germany were the scientific chairmen of the congress.

„We offer not only implants but also dental solutions from root to crown.“ With these words Dr Werner Groll, managing director of DENTSPLY Friadent, defined the slogan of the congress: „Focus on your Practice Success.“ The company's partnership with users is based on three pillars. The products and processes of the DENTSPLY Friadent company for implantology and bone augmentation are proven in clinical applications throughout the world. Future-

oriented and innovative technology is aligned to the requirements of the practitioner and the desires of the patient. Finally, easy-to-implement marketing concepts are available for systematic development of the dental practice under the stepps brand. DENTSPLY Friadent has based its growth on these three pillars to become number three in the world implant market, as described by Dr Groll at the press conference.

The wide and varied range of topics covering all aspects of modern implant-supported therapy was clearly structured, allowing attendees to concentrate intensively on topics of interest to them and leave the congress thoroughly informed. While the lectures in the "Proven Applications and New Approaches" forum were primarily practice oriented, the "Today's Progress for Tomorrow's Practice" forum focused on procedural techniques, study results relevant to dental practice and new materials and technologies. The focus on interdisciplinary therapy techniques with





interfaces to periodontics, endodontics and dental technology played a central role: the congress delivered on the promise of „solutions from root to crown.“

Keynote lectures concentrated on the four success factors timing, esthetics, treatment protocols and risk management, which are critical for implantology, using practical examples and also with detailed descriptions of the essential scientific background.

In the Expert Talk session, which attracted a very interested audience on Friday afternoon, Dr Dietmar Weng, Dipl.-Ing. Holger Zipprich, Dr Marco Degidi, Professor Tord M. Lundgren, Professor Karl-Andreas Schlegel and Professor Dennis Tarnow discussed the TissueCare Concept and the significance of primary stability. The various discussions concluded that important trends—including immediate loading or esthetic long-term success rate—should be considered in more detail with reference to scientific proofs and

there should be a more detailed examination of the current insights.

The final sessions presented by Dr Henry Salama and Dr Bernhard Saneke described the team approach as a success factor. Interdisciplinary networks and an open working atmosphere are the foundation stones of the dental practice of the future. Relaxation was on the program for Friday evening. Attendees celebrated with an exciting range of culinary specialties and rhythms on the grounds of the 1929 World Exposition at the Magic Fountain at the foot of Montjuic.

The DENTSPLY Friadent World Symposium has now become one of the most important implantology congresses in the world and still retains a family atmosphere in spite of its size. Many attendees have already indicated that they will be attending the next World Symposium on March 16–17, 2012, in Hamburg.



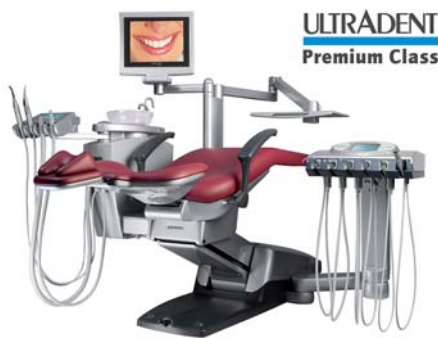Manufacturer news

ULTRADENT

Premium Units—made in Germany

With the U 1500, U 5000S and U 5000F treatment units, dental manufacturer ULTRADENT from Munich has created an entirely new class of unit that also offers exclusive premium standards in the compact treatment unit segment. The special modular ULTRADENT structure makes it possible to equip units in line with dentists' individual requirements and specifications. It also sets extremely high standards in terms of design and quality of workmanship.

The dental equipment for these treatment units has also been redesigned, with a view to meeting all possible requirements in terms of positioning, programming and information, while also supporting treatment using numerous exclusive instruments and all possible options. The central unit can be used to control everything—from the tartar remover and new micro motors with torque control and an extended speed range to the intraoral camera, the electrosurgery unit and an integrated saline pump. The simple, symbol-controlled programming covers all instruments and chair positions. It goes without saying that this workstation can also be fitted with the ULTRADENT-VISION multimedia system.



Details such as the new touch-screen display, an optional wireless foot control and exchangeable control valves facilitate treatment and promote the provision of service. Comfort is provided by the supersoft chair upholstery, available in 12 colors, plus an individual headrest system with magnetic supports. Movable armrests make it easier to get into the chair. Exclusive comfort upholstery with air conditioning or massage function is an ULTRADENT innovation. This is achieved by six silent ventilators in the backrest and seat that provide pleasant fresh air, or by special electric motors that provide calming relaxation by means of a gentle massage. This option is especially advantageous for long treatments, for the dentist and patient alike.

The ULTRADENT Premium class realizes many technical visions and its overall design generates a degree of fascination and customer satisfaction that is only possible in the top-of-the-range segment. So, treat yourself to innovation and perfection, and gain inspiration for your practice. Request the latest ULTRADENT Premium brochure and let us surprise you.

ULTRADENT Dental-Medizinische Geräte GmbH & Co.KG

Eugen-Sänger-Ring 10
85649 Brunnthal, Germany
E-mail: info@ultradent.de
Web: www.ultradent.de

Materialise DENTAL

New General Manager for Germany, Austria and Switzerland

Materialise Dental announced today the appointment of Dr Berthold Reusch as General Manager for Germany, Austria and Switzerland. Dr Reusch brings over 17 years of global marketing, sales, clinical and business management experience in the field of dental materials and digital dentistry. Most recently, Berthold worked for the dental division of 3MESPE where he was Director of Operations for the digital imaging device business which he successfully developed outside the US. From 2007 to 2009 Berthold was a member of the executive man-



agement team of Brontes Technologies, a 3M company based in Boston, MA, building the digital impressioning business in the US. As General Manager at Materialise Dental GmbH, Berthold and his team will further develop the SimPlant® and SurgiGuide® business within the German, Austrian and German-speaking Swiss markets. SimPlant® dental implant treatment planning software allows clinicians to plan the ideal location of implants while taking into account vital anatomical structures and clinical and esthetical considerations. SurgiGuide®, for which the company has partnered up with various implant companies and which offers solutions for every implant case, subsequently provides the link between implant planning and actual surgery. With SimPlant® and SurgiGuide®, dental professionals have a flexible

treatment planning system at their fingertips to guarantee predictable and safe implant treatment regardless of the clinical situation. Dr Berthold Rausch received his diploma and PhD (Dr rer. nat.) in Physics from the University of Tübingen, Germany and then went on to receive his MBA, with an emphasis in marketing and international business management, from the Business School at the Catholic University of Eichstätt. When asked about his new position, Dr Reusch said, "I'm very enthusiastic to join Materialise Dental, an innovative and technologically driven organization. I'm looking forward to undertaking the challenging task of heading my division and—together with my team—offering our customers the most innovative and advanced products to meet their computer-guided implant dentistry needs."

Materialise DENTAL GmbH

Argelsrieder Feld 10
82234 Oberpfaffenhofen, Germany
Web: www.materialisedental.com

Nobel Biocare

The ideal abutment for posterior restorations

Nobel Biocare is pleased to announce the expansion of the popular Snappy abutment product portfolio with the addition of taller abutment options. Starting immediately the Snappy Abutment is available in 4.0 and 5.5 mm abutment heights. Thanks to its profile and design, the Snappy Abutment permits clinical use without any modification. In addition, the included snap-on impression coping ensures simplified impression-taking. The Snappy Abutment is an easy to use prosthetic solution that is highly suitable for posterior restorations, especially in partially edentulous jaws, and for single-crown restorations with an implant.

Easy to use

The Snappy Abutment is easy to use and ensures optimal precision. In addition, all the prosthetic compo-



The improved Snappy Abutment package contains all the components required including the final abutment, the impression coping used to take the impression, and the temporary coping for fabricating a provisional restoration.

nents and individual elements required for restoration, e.g. the abutment, abutmentscrew, impression coping, healing cap and temporary coping, are supplied in a single package. Thus, the Snappy Abutment provides a cost-effective, time-saving and highly functional prosthetic solution.

Efficient restoration

The Snappy Abutment is seated on the implant and the screw is engaged to a torque of 35 Ncm with the Unigrip Driver and prosthetic torque wrench. Once the Snappy Abutment has been secured, the easy-to-use impression coping is snapped in place, an arrow on the impression coping should be oriented buccally. The impression material is then injected around the coping, and a pick-up impression is taken.

This technique allows very precise impressions of the Snappy Abutment and the finish line without the need for retraction cord.

The dental laboratory can then use an off-the-shelf abutment replica to prepare the

definitive restoration. In addition, a temporary coping for fabricating a provisional restoration is included, allowing the patient to leave the clinician's practice with a functional tooth. The final restoration for the crown is fabricated by the conventional technique. For this purpose NobelProcera™ supplies a full range of restorations for all indications, esthetic and cost effective.

Models and sizes

The improved Snappy Abutment package contains all the components required including the final abutment, the impression coping used to take the impression, and the temporary coping for fabricating a provisional restoration. The available components are designated with the code 4 or 5, depending on the height of the abutment used: the Snappy Abutment 4.0 or the Snappy Abutment 5.5. The Snappy Abutment is available for all Nobel Biocare implant systems, NobelReplace, Brånemark, NobelActive, and for all platform diameters NP, RP, WP, and 6.0.

Nobel Biocare Holding AG

P.O. Box
8058 Zurich Airport, Switzerland
E-mail: info@nobelbiocare.com
Web: www.nobelbiocare.com

AD

Geistlich Pharma AG

The right cap for the job

The unique Biofunctional properties of Geistlich Bio-Oss® have been proven through 24 years of excellent practical experience worldwide. Geistlich Bio-Oss® is characterised by volume stability throughout the extensive indication areas of periodontology, implantology and cranio-maxillofacial surgery.

Geistlich Bio-Oss® is now available with an optimised handling in vials: NEW CAP "EASY+SAFE".

- SAFE - no sharp edges
- EASY - to open



The new vial cap of Geistlich Bio-Oss® — safe and easy to open.

Your opinion is important to us. Answer three questions at <http://www.geistlich.com/index.cfm?dom=2&rub=20&id=105702>

By participating in this survey, you will be entered into a draw to win an unforgettable weekend of regeneration at the Victoria-Jungfrau in Interlaken, (Switzerland) which is a member of the Leading Hotels of the World.

Deadline for entry is September 30, 2010. Legal recourse is excluded.

Geistlich Pharma AG

Bahnhofstrasse 40
6110 Wolhusen, Switzerland
Web: www.geistlich-pharma.ch

Since our beginnings, we have always been focused on quality and innovation toward the battle against cross - contamination and infections.

In the last 20 years, we have ensured safety and protection to you and your patients, with advanced and reliable products. Tools that represent the ideal solution for who is operating in dentistry, implantology/oral surgery and general surgery.

With Omnia sure to be safe.

Surgical Line **Safety Line** **OMNIA**

OMNIA
Disposable Medical Devices

OMNIA S.p.A.
Via F. Delnevo, 190 - 43036 Fidenza (PR) Italy
Tel. +39 0524 527453 - Fax +39 0524 525230
VAT. IT 01711860344 - R.E.A. PR 173685
Company capital € 200.000,00
www.omniaspa.eu

SOS Children's Villages visit W&H

As the world's first manufacturer of dental transmission instruments and devices, W&H has long been known for its high-quality products and social awareness. In its official anniversary year, from 6 April 2010 to 31 March 2011, W&H will be even more active in the social realm by offering support to SOS Children's Villages. At the launch of the anniversary year, W&H welcomed a children's group from SOS Children's Village Seekirchen on 8 April 2010. With the motto "I'm not scared of the dentist", the children had the opportunity to examine up-close the production of traditionally feared dental instruments and also to test them out. During its anniversary year, W&H Dentalwerk Bürmoos will mainly be supporting the Family Strength-



ening Programme in Kakiri, Uganda, initiated by SOS. Thanks to this support, the financing of the entire programme will be secure for more than two years. The Family Strengthening Programme in Kakiri was established in 2006 by SOS Children's Villages, in order to provide support for children and families who need help as a result of poverty or illness. The goal is to improve their health and their so-

cial situation. This is not a normal SOS children's village, but rather a programme for an entire region. At present, the programme assists around 480 children from 130 families. Its activities include: medical assistance for families, securing basic food for families, and educational programmes for children of school age. In addition to the Family Strengthening Programme in Kakiri, Uganda, which is supported by W&H Dentalwerk Bürmoos, other SOS Children's Villages campaigns are being carried out by W&H subsidiaries and area managers. Celebrate 120 years of W&H and help us support SOS Children's Villages — staying true to the W&H company philosophy: People have Priority.

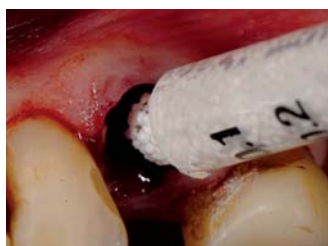W&H Deutschland GmbH

Raiffeisenstraße 4
83410 Laufen, Germany
E-mail: office.de@wh.com
Web: www.wh.com

Degradable Solutions

Moldable, in situ hardening bone graft substitutes

easy-graft® and easy-graft® CRYSTAL are moldable, fully synthetic bone defect fillers for indications in oral surgery, implantology and periodontology. In contact with blood, the materials harden within minutes into a porous, inherently stable body. A membrane to contain the materials is not necessary in most cases. The easy-graft® products are frequently used for ridge preservation after tooth extraction. The socket must be free of infected and inflamed tissue prior to graft insertion. The materials are applied directly from the syringe into the defect where they harden and seal the extraction wound. For most cases, a membrane or suturing of soft



tissue are unnecessary. easy-graft® and easy-graft® CRYSTAL are designed to have different resorption characteristics. easy-graft® is composed of phase-pure β -tricalcium phosphate (β -TCP). It degrades completely and is replaced by bone. easy-graft® CRYSTAL contains 40% β -TCP and 60% hydroxyapatite (HA). It is degraded only partially and remains integrated in the newly formed bone for long-term volume preservation. In summary, the easy-graft® products combine established biomaterials for bone regeneration with a unique handling advantage—moldable from the syringe, hardening in the defect.

Degradable Solutions AG

Wagistrasse 23
8952 Schlieren, Switzerland
E-mail: info@degradable.ch
Web: www.degradable.ch

Straumann

15th André Schroeder Research Prize goes to Maria Retzepi

One of the most prestigious awards in dentistry, the André Schroeder Research Prize, was presented at the World Symposium of the International Team for Implantology (ITI) in Geneva. Beat Spalinger, President and CEO of Straumann, presented the award to Dr Maria Retzepi, a specialist periodontist and clinical lecturer at the University College London Eastman Dental Institute. Dr Retzepi is commended for her work on 'The Effect of Experimental Diabetes on Guided Bone Regeneration'. It shows that—although diabetes compromises the initial stages of bone healing—guided bone regeneration can pro-



vide an environment that is conducive for significant, even though delayed, formation of new bone. The use of insulin to control diabetes may enhance

the bone regeneration potential. Understanding the genetic aspects of the metabolic status may lead to new approaches for treating oral bone defects in diabetic patients. The coveted André Schroeder Research Prize was first presented in 1992 to promote new scientific findings in oral implantology and related fields. It is given in honor of the late Professor André Schroeder (1918–2004), who pioneered dental implantology. The André Schroeder Prize furthers illustrates Straumann's commitment in the field of research and development.

Institut Straumann AG

Peter Merian-Weg 12
4052 Basel, Switzerland
E-mail: info@straumann.com
Web: www.straumann.com

3rd International CAMLOG Congress, June 10th through 12th, 2010

Apparently, interest in and expectations for the 3rd International CAMLOG Congress 2010 in Stuttgart are enormously high—analogous to the above-average standards that CAMLOG has created and set for itself in the variety and quality of the congress program and the qualification of top speakers. This again clearly illustrates the company's goals: to offer scientifically based, up-to-date continuing education, to set new benchmarks in the industry, and to continuously increase user benefits.

The renowned names of the scientific congress committee speak for themselves and vouch for quality: Prof Dr Jürgen Becker, Dr Sven Marcus Beschmidt, Prof Dr Dr Rolf Ewers, Prof Dr Dr Dr Robert Sader, PD Dr Frank Schwarz, Prof Dr Dr Wilfried Wagner. Although the majority of the speakers are from Germany, internationalization is playing an increasingly prominent role for the CAMLOG Group. Proof is in the growing number of internationally renowned congress speakers.

CAMLOG is experiencing a significant increase in the number of participants at the 3rd International Congress in Stuttgart and some workshops are already fully booked.



All information about the Congress and registration options are available at www.camlogcongress.com.

CAMLOG Foundation

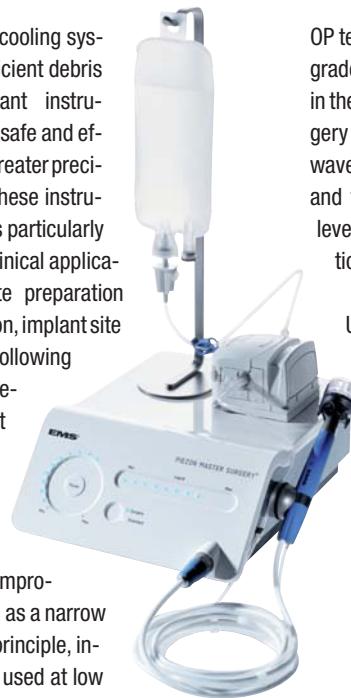
Margarethenstrasse 38
4053 Basel, Switzerland
E-mail: foundation@camlog.com
Web: www.camlogfoundation.org

EMS

Piezon Master Surgery with three new instrument systems

Since it was introduced, Piezon Master Surgery—based on Piezon technology—has had a remarkable track record in many practices. Today, EMS has expanded the clinical scope of application of the Piezon Master Surgery product range. With an enhanced product offering—and special instruments such as Sinus System and Implant System—practitioners have access to technologies allowing them to work even more efficiently. With Piezon Master Surgery, application-specific instruments are now available: a total of four perio instruments especially designed for resective and regenerative periodontal surgery, five advanced surgical instruments for gentle and uniform sinus lifts, as well as six special fully diamond-coated instruments for implant appli-

cations with dual cooling system and extra-efficient debris evacuation. Implant instruments provide for safe and efficient work with greater precision, says EMS. These instruments are seen as particularly suitable for four clinical applications: implant site preparation following extraction, implant site preparation following splitting of the alveolar ridge, implant site preparation in the posterior tooth area, and implant site preparation in compromised areas, such as a narrow alveolar ridge. In principle, instruments can be used at low



OP temperature of no more than 33 degrees centigrade. They provide drilling efficiency and precision in the maxillary area. The entire Piezon Master Surgery method is based on piezoceramic ultrasound waves producing high-frequency, rectilinear back-and-forth oscillations. These vibrations raise the level of precision and safety in surgical applications, notes EMS.

Ultrasound instruments are used selectively to cut hard tissue only. The device delivers reliable results in periodontal and oral surgery as well as implantology due in part to a user-friendly ergonomic touch board, says EMS.

EMS Electro Medical Systems S.A.

Ch. de la Vuarpillière 31
1260 Nyon, Switzerland
E-mail: welcome@ems-ch.com
Web: www.ems-dent.com

AD

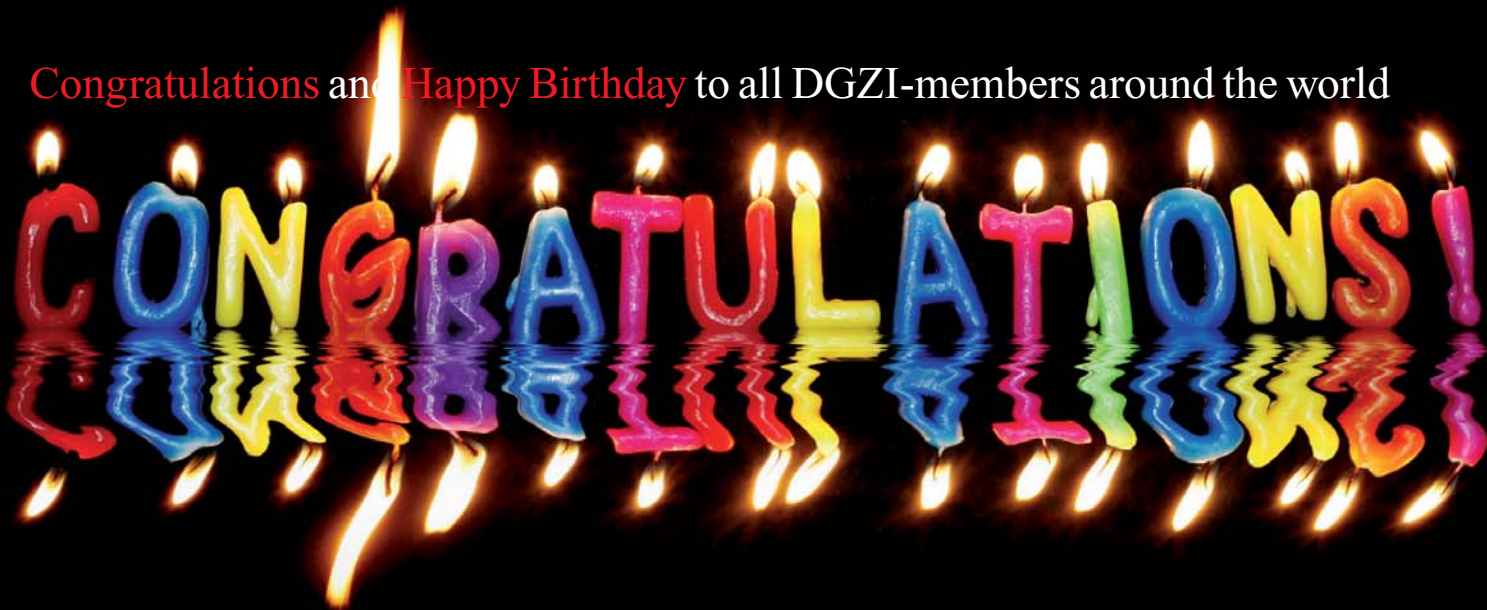Solaris LED Light as it should be!

The best light for the best treatment!

ULTRADENT

Dental-Medizinische Geräte GmbH & Co. KG
D-85649 Brunnthal · Eugen-Sänger-Ring 10
T. +49 89-420992-70 F. +49 89-420992-50
www.ultradent.de · info@ultradent.de

Congratulations and Happy Birthday to all DGZI-members around the world



APRIL 2010

70th Birthday

Dr Hans-Jürgen Friemert (10.04.)
Dr Hartmut Steinkrüger (26.04.)
Dr Jürgen Huhmann (27.04.)

65th Birthday

Dr Osman Sahovic (07.04.)
Dr Elizabeth Siswanto-Hartmann (08.04.)

60th Birthday

Dr Johannes Schüssler (21.04.)

55th Birthday

Dr Rüdiger Hobohm (14.04.)
Dr Bernd Thomaschewski (16.04.)
Josef Pechl (21.04.)
ZTM Ulrich Gonsberg (25.04.)
Dr Veselko Jovanovic (29.04.)
Dr Thomas Gross (30.04.)

50th Birthday

Ines Ayoub (05.04.)
Dr Helmuth Althoff (06.04.)
Dr Dr Stephan Wolf (08.04.)
ZTM Claus Fiderer (13.04.)

ZA Rolf Hoppenrath (16.04.)
Dr Rene Kleinlugtenbelt (17.04.)
Dr Kamal Tizieni (18.04.)
Günter Somberg (23.04.)
Drs Marcel A. Kruitbosch (26.04.)
Dr Masud Sayed (28.04.)

45th Birthday

Dr Robert Suetter (02.04.)
Dr Jan van den Daele (02.04.)
Dr Stefan Eckardt (05.04.)
Dr Bernd Ronneburg (06.04.)
Dr Susanne Martin (17.04.)

Dr Stephan Arnold (20.04.)
Dr Mario Heupel (26.04.)
Dr Knut Langer (28.04.)

40th Birthday

Dr Jan Kielhorn (03.04.)
Dr Sven Schultze (13.04.)
Dr Marc Hausamen (17.04.)
ZA Anka Fritzsich (19.04.)
Dr Ammar Hamdah (19.04.)
Dr Timo Weihing (21.04.)
Dr Jörg Umfermann, MSc, (24.04.)

MAY 2010

75th Birthday

Dr Hany Moharm (25.05.)

70th Birthday

Dr Goizot Indra (05.05.)

65th Birthday

Dr Johannes Wolf (16.05.)

60th Birthday

Dr Dr. Hans-Joachim Schütz (01.05.)
Dr Harald Rahmann (07.05.)
Gustav Stecher (11.05.)
Dr Hermann Klumpen (12.05.)

Dr Nenad Bogdanovic (13.05.)
Dr Herbert Sirch (19.05.)
Dr Volkmar Karnstedt (25.05.)
Dr Klaus Engstler (27.05.)
Dr Gerhard Treuel (28.05.)

55th Birthday

Dr Klaus-Peter Ullmann (07.05.)
Dr Robert Kempfer (09.05.)
Dr Barbara Melchior (09.05.)

50th Birthday

Dr Martin Angermeier (01.05.)
Dr Bert Eger (02.05.)

Christian Lelonek (08.05.)
Dr Hansjörg Schmidt (09.05.)
Dr Rolf Olbertz (12.05.)
Armin Göring (25.05.)
Dr Michael Stumpf (25.05.)
Wolfgang Balmes (28.05.)
Dr Matthias Wolf (30.05.)

45th Birthday

Dr Hans-Joachim Nickenig (03.05.)
ZÄ Catrin Westermann-Lammers (10.05.)
ZA Mattgias Erich Mergner (12.05.)
Dr Khaldoun Khourdaji (17.05.)

Dr Sigmar Schnutenhaus (19.05.)
Dr Christian Jänichen (20.05.)
Dr Monika Sausen-Bootsch (23.05.)
Dr Frank Scott (25.05.)
Dr Thomas Ducke (28.05.)

40th Birthday

ZA Stavros Avgerinos (01.05.)
Emanuel Adrian Brauti (15.05.)
Nicolao Tsacmacidis (24.05.)
Dr Matthias Baierl (25.05.)

JUNE 2010

65th Birthday

Dr Franz Konczwald (03.06.)
Dr Jan Erik Rosenbaum (10.06.)
Ortwin Hüsken (22.06.)

60th Birthday

Dr Dr. Peter Barth (12.06.)
Dr Enver Yazicioglu (22.06.)

55th Birthday

ZA Andreas Wiegand (11.06.)
Dr Elvira Perder-Seipold (13.06.)
Dr Alexander Györfy (19.06.)

Dr Abdul Rahman AlTayeh (21.06.)
Dr Arisaka Ryuichi (25.06.)
Dr Robert Böttcher (28.06.)

50th Birthday

ZA Frank Dehnert (06.06.)
ZA Haris Apostolidis (08.06.)
ZA Michael Röhner (08.06.)
Dr Arleta Stefaniak-Brzuchalski (10.06.)
Dr Fritz Bergmann (11.06.)
Dr Mohammad Jamal Mourtada (11.06.)
Dr Johan de Jonge (19.06.)
ZA Bernfried Hauf (19.06.)

Dr Jamil Al Sabuba (21.06.)
Dr Reiner Tegeler (24.06.)
Dr Kirsten von Helldorff (29.06.)

45th Birthday

Dr Mohammad Al Harkan (01.06.)
Dr Hermann Steffens (02.06.)
ZA Jens Tartsch (02.06.)
Dr Thomas Maier (03.06.)
Dr Norbert Wellens (04.06.)
Dr Jan von der Brelie (05.06.)
Dr Frank-Lothar Kirchberg (09.06.)
Dr Mahmoud Al Hariri (10.06.)

Kachoum Farouk (12.06.)
Ahmad Kalach (12.06.)
Dr Claus Schüttler-Janikulla (14.06.)
Dr Tamrouk Khaled (16.06.)
ZA Adolf Thürmann (18.06.)
Dr Gregor Dohmen (28.06.)
Dr Jan Scheuer (29.06.)

40th Birthday

Dr Michel Dibb (01.06.)
ZA Navid Zomorodi (20.06.)
ZA Gernbot Bartl (25.06.)
Mhd Firas Kharboutly (26.06.)



1st Croatian-German implantology meeting of DGZI

Dear Colleagues,

we take great pleasure in inviting you to participate in the 1st Hvar International Dental Congress.

From 10. to 12. of June 2010., HSK - Croatian Dental Chamber in cooperation with Oral Dent company, supported by three international associations DGZI - Deutsche Gesellschaft für Zahnärztliche Implantologie e.V., IADFE - International Academy for Dental Facial Esthetics and ESCD - European Society of Cosmetic Dentistry organizes an extraordinary assembly of experts from all over the world on the island of Hvar, Croatia.

More than 40 lecturers from Europe, the United States of America and Middle East will give lectures on the island of Hvar. We organize programs for dentists, dental technicians, world Ozon Symposium, Laser Symposium, many workshops and big international exhibition. Along with the educational program, we organize luxurious entertaining social programs with numerous surprises during all three congress days.

The whole event will be held in Grand Hotel Amfora, in the town of Hvar, in the period of 10. to 12. of June 2010. It is important to mention that the Croatian Dental Chamber rated this Congress with the maximal 12 points, which ranks this Congress among the best events in Croatia in 2010.

The island of Hvar is the queen of the Croatian Dalmatian islands. It has been famous since the antique because of its important strategic and nautical position, the rich of the various historical periods, the culture and natural monuments and the literature. Thanks to the mild climate, the warm winters and pleasant summers Hvar receives many guests, scientists and travellers, who are attracted by the dense mediterranean nature, rich tradition and architecture, and nightlife.

All dental companies which are interested in participation and renting exhibition booths on this congress can find all the information on our web site www.hvarkongres.hr or can contact us directly via e-mail info@hvarkongres.hr We will be happy to provide you with detailed information.

Looking forward to welcoming you on the island of Hvar.

Sincerely Yours,

the Organizing committee

Lecturers:

Dr. David L.Hoexter - USA
 Prof.Dr. Bilal Al-Nawas - GER
 Dr. Istvan Urban - HUN
 Dr. Suheil Michael Boutros - USA
 Dr. Francesco Mintrone - ITA
 Dr. Darko Slova - CRO
 Prof. Dr. Claus Udo Fritzemeier - GER
 Dr. Mazen Tamimi - JOR
 Dr. Nadim Abou Jaoude - LBN
 Prof.Dr. Nabil Jean Barakat - LBN
 MUDr. Jiri Holahovski - CZE
 Dr. Rainer Valentin - GER
 Dr. Rolf Vollmer - GER
 Dr. Ulf Krueger Janson - GER
 Dr. Wolfgang Richter - AUT
 Dr. Luca Lorenzo Dalloca - ITA

Dr. Stefano Ardu - CHE
 Dr. Dusko Gedosev - GER
 Dr. Gregory Brambilla - ITA
 Prof. Dr. Ivica Anic - CRO
 Prof. Dr. Ivana Miletic - CRO
 Dr. Thomas Schindler - AUT
 Dr. Vanja Coric - CRO
 Dr. Fay Goldstep - CAN
 Dr. Ross W. Nash - USA
 Dr. Elliot Mechanic - CAN
 Dr. George Freedman - CAN
 Prof. Dr. Edward Lynch - GBR
 Dr. Orsolya Rigo - HUN
 Prof. Dr. Hrvoje Juric - CRO
 Prof. Dr. Bozidar Pavelic - CRO
 Dr. Zeljka Cabunac - SRB

Dr. Mark P. Collona - USA
 Dr. Zelimir Bozic - CRO
 Dr. Douglas Ness - USA
 Dr. Oscar Von Stetten - GER
 Prof. Dr. Davor Katanec - CRO

DT Lecturers:

MDT. Harald Hoer - AUT
 MDT. Roberto Iafrate - IT
 CDT. Przemek Seweryniak - SWE
 DT. Jorn Trocha - GER
 MDT. Jerko Marsic - CRO
 DT. Senad Bajramagic - CRO
 DT. Leon Cebovski - CRO



HVAR 2010 CONGRESS

INTERNATIONAL DENTAL CONGRESS CROATIA

10.06.2010. - 12.06.2010.



sunčani hvar hotels
 creating sunsational experiences every day



www.hvarkongres.hr

implants
international magazine of oral implantology



Publisher

Torsten R. Oemus
oemus@oemus-media.de

CEO

Ingolf Döbbbecke
doebbecke@oemus-media.de

Members of the Board

Jürgen Isbaner
isbaner@oemus-media.de

Lutz V. Hiller
hiller@oemus-media.de

Chief Editorial Manager

Dr Torsten Hartmann (V. i. S. d. P.)
hartmann@dentalnet.de

Editorial Council

Dr Friedhelm Heinemann
friedhelmheinemann@web.de

Dr Roland Hille
dr-hille@t-online.de

Prof Dr Dr Kurt Vinzenz
kurt.vinzenz@aon.at

Dr Torsten Hartmann
hartmann@dentalnet.de

Dr Suheil Boutros
SMBoutros@aol.com

Editorial Office

Kristin Urban
k.urban@oemus-media.de

Eva Kretschmann
e.kretschmann@oemus-media.de

Executive Producer

Gernot Meyer
meyer@oemus-media.de

Designer

Sarah Fuhrmann
s.fuhrmann@oemus-media.de

Customer Service

Marius Mezger
m.mezger@oemus-media.de

Published by

Oemus Media AG
Holbeinstraße 29
04229 Leipzig, Germany
Tel.: +49 341 48474-0
Fax: +49 341 48474-290
kontakt@oemus-media.de

Printed by

Messedruck Leipzig GmbH
An der Hebemärchte 6
04316 Leipzig, Germany

implants

international magazine of oral implantology
is published in cooperation with the German
Association of Dental Implantology (DGZI).

DGZI President

Dr Friedhelm Heinemann
DGZI Central Office
Feldstraße 80, 40479 Düsseldorf, Germany
Tel.: +49 211 16970-77
Fax: +49 211 16970-66
office@dgzi-info.de

www.dgzi.de
www.oemus.com

Copyright Regulations

_implants international magazine of oral implantology is published by Oemus Media AG and will appear in 2010 with one issue every quarter. The magazine and all articles and illustrations therein are protected by copyright. Any utilization without the prior consent of editor and publisher is inadmissible and liable to prosecution. This applies in particular to duplicate copies, translations, microfilms, and storage and processing in electronic systems.

Reproductions, including extracts, may only be made with the permission of the publisher. Given no statement to the contrary, any submissions to the editorial department are understood to be in agreement with a full or partial publishing of said submission. The editorial department reserves the right to check all submitted articles for formal errors and factual authority, and to make amendments if necessary. No responsibility shall be taken for unsolicited books and manuscripts. Articles bearing symbols other than that of the editorial department, or which are distinguished by the name of the author, represent the opinion of the afore-mentioned, and do not have to comply with the views of Oemus Media AG. Responsibility for such articles shall be borne by the author. Responsibility for advertisements and other specially labeled items shall not be borne by the editorial department. Likewise, no responsibility shall be assumed for information published about associations, companies and commercial markets. All cases of consequential liability arising from inaccurate or faulty representation are excluded. General terms and conditions apply, legal venue is Leipzig, Germany.

implants

international magazine of oral implantology



Subscribe now!

One issue free of charge!

I hereby agree to receive a free trial subscription of **implants international magazine of oral implantology** (4 issues per year).

I would like to subscribe to **implants** for € 44* for German customers, € 46* for customers outside of Germany, unless a written cancellation is sent within 14 days of the receipt of the trial subscription. The subscription will be renewed automatically every year until a written cancellation is sent to OEMUS MEDIA AG, Holbeinstr. 29, 04229 Leipzig, Germany, six weeks prior to the renewal date.

▶ Reply via Fax +49 341 48474-290 to OEMUS MEDIA AG or per E-mail to grasse@oemus-media.de

Last Name, First Name

Company

Street

ZIP/City/County

E-mail

Signature

Notice of revocation: I am able to revoke the subscription within 14 days after my order by sending a written cancellation to OEMUS MEDIA AG, Holbeinstr. 29, 04229 Leipzig, Germany.

Signature

Holbeinstr. 29, 04229 Leipzig, Germany, Tel.: +49 341 48474-0, Fax: +49 341 48474-290, E-Mail: grasse@oemus-media.de

OEMUS MEDIA AG



*Prices include shipping and VAT

IM 2/10

Official care provider
to the German Olympic teams
since 2002

GO FOR GOLD.



Bionic Engineering Design transfer of
optimal living nature solutions
to technical products

BEGO Semados®
Mini-Implant

BEGO Semados®
S-Implant

BEGO Semados®
RI-Implant

BIONIC ENGINEERING DESIGNED IMPLANTS

BEGO Semados® patented Implants embody:

- Indication-optimised contour design
- Function-optimised implant-abutment-connection
- High purity and ultra-homogenous-surface
- Polished rim for an inflammation-free gingiva-attachment
- 100 % German design – 100 % German manufacturing
- Value for money

**Are You
Interested?**

info@bego-implantology.com

www.adwork.de

BEGO 
Partners in Progress

www.bego-implantology.com