

Lasers in dental Traumatology

Author_Claudia Caprioglio, Italy

_Introduction

Dental traumas are frequent in children. They can be complex events and sometimes real emergencies. Traumatic injuries involve all the branches of dentistry (endodontics, restorative, periodontics, oral surgery, orthodontics) so that traumatology can be considered a multidisciplinary discipline.

Laser technology lends itself well to the problems encountered in dental traumatology (from simple crown fractures, to replantation, root fractures and different types of luxation injury) because it is able to replace or complete, and also to simplify, traditional dental procedures. It contributes to the reduction of post-operative sensitivity through a minimally invasive and highly selective technique that furthermore has a positive psychological impact for the patients. In addition it is an alternative technique for non vital bleaching procedure, to solve post-traumatic aesthetic problems.

Working without anaesthesia through laser induced analgesia is another challenge. Laser-as-

sisted therapies drastically reduce the need for post-operative medications compared with conventional procedures.

The international literature doesn't report extensive references on laser assisted dental trauma therapy and there are not well-coded guidelines for specific laser application in this clinical field.

Even though this challenging technology is ideal for trauma-related problems, the existing dental trauma guidelines and protocols should nevertheless be widely consulted (Andreasen et al. 2007).

_Epidemiology and Prevention

Dental traumas are sustained mainly during play (56 %), sports activities (21 %), road accidents (11 %) or as a result of acts of violence (12 %), which continue to be underestimated. The high incidence of dental trauma is demonstrated, in the literature, by large-scale American studies which show that one in six adolescent boys are twice as likely as girls to suffer a dental trauma and the type of lesion varies depending on the age of the subject; in young age groups the incidence

Figs. 1a & b_Complicated enamel-dentin crown fracture of 1.2, with complete detachment of the palatal tooth fragment.

(Courtesy of Prof R. Grandini)

Figs. 2a & b_The tooth fragment.

A partial pulpotomy is performed and dental margins are treated by using an Erbium laser.

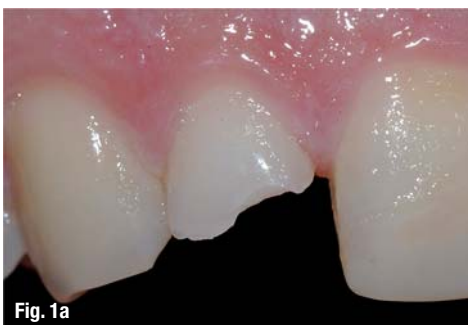

Fig. 1a

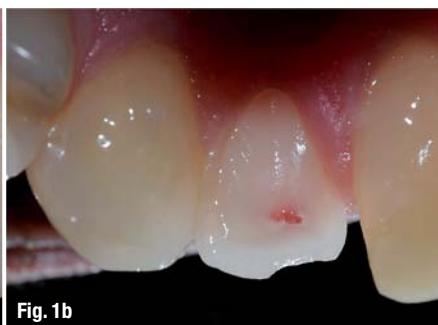

Fig. 1b

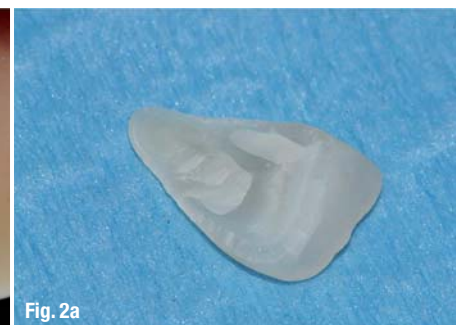
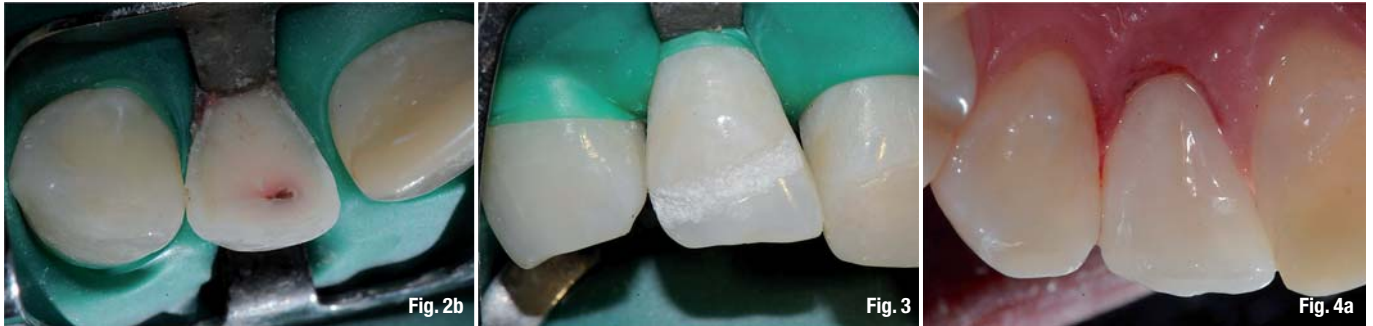
Fig. 2a



is usually equally high in both sexes (Glendor 2008).

Around 20 % of children suffer a traumatic injury to their primary teeth and over 15 % to their permanent teeth (Andreasen et al. 2007). The teeth most frequently affected, both in primary and in permanent dentition, are the upper central incisors (50 %) and the upper lateral incisors (30 %). Paediatricians and dentists need to draw attention to the importance of prevention in this field.

These injuries, together with tooth decay, are the most frequent pathologies encountered in paediatric dentistry: a specific training, adequate continuing education conventions, high level of knowledge and updated guidelines for the management of traumatic dental injuries are needed.

Classification

In 1978 the World Health Organisation created a classification of traumatic dental injuries. In 1992, this classification, revised and extended, was published.

The following classification includes injuries to the teeth, supporting structures, gingival and oral mucosa. It is applicable both to primary and permanent dentition (Table I) (Andreasen et al. 2007).

Lasers application in dental traumatology

Careful dental history report and clinical examination are the basis of an accurate diagnosis and in order to save time and to be exhaustive, specific standardised charts are recommend. Every phase, both pre- and post-treatment, must be fully documented through radiographic and photographic examinations and pulp vitality tests, making easier and quicker to monitor the evolution of the clinical case at subsequent visits and to compile a full medico-legal report, which is often required during and at the end of dental trauma treatment.

In dental trauma pulp testing is a controversial issue; different tests have been proposed: the laser doppler flowmetry (LDF) is an experimental value method to diagnose the state of pulp revascularization; however at this time this method cannot be of general use but it looks promising.

Laser technology is an advancement that fits into the two concepts of tooth preservation (MICRODENTISTRY) and prevention.

The use of lasers in many medical fields has become the standard treatment; this is not the case of dental traumatic injuries but the author is confident that these technologies will offer better quality treatments and will make our profession more enjoyable.

There are different types of lasers available to treat dental injuries. The properties of each type make them suitable for different tissues and procedures; each wavelengths has a particular use determined by its specific tissue-interaction and affinities.

Due to their versatility two types of lasers are more frequently used by paediatric dentists in dental traumatic injuries: Er:YAG and Er,Cr:YSGG since they can be used in hard and soft tissues (Gutknecht et al. 2005). Also other technologies are indicated: the KTP, the Nd:YAG laser, the Diode laser and the CO₂ (Table II).

No randomized clinical studies exist concerning traumatic dental injuries and laser-assisted therapy, in this article the author describes its own clinical experience and aims to stimulate more extensive scientific research.

Traumatic injuries to hard dental tissue and the pulp

Uncomplicated and complicated crown fracture

This type of fracture involves the enamel and dentin and expose the pulp (if complicated).

Fig. 3 The tooth and the fragment are acid-etched and reattached by using a flow composite resin to better adaption. Reinforcing the labial aspect of the fracture site: preparation of a facial bevel by using an Er:YAG laser.

Figs. 4a & b Final appearance (palatal view) after rubber dam removal. Clinical appearance (labial view) after 6 months.

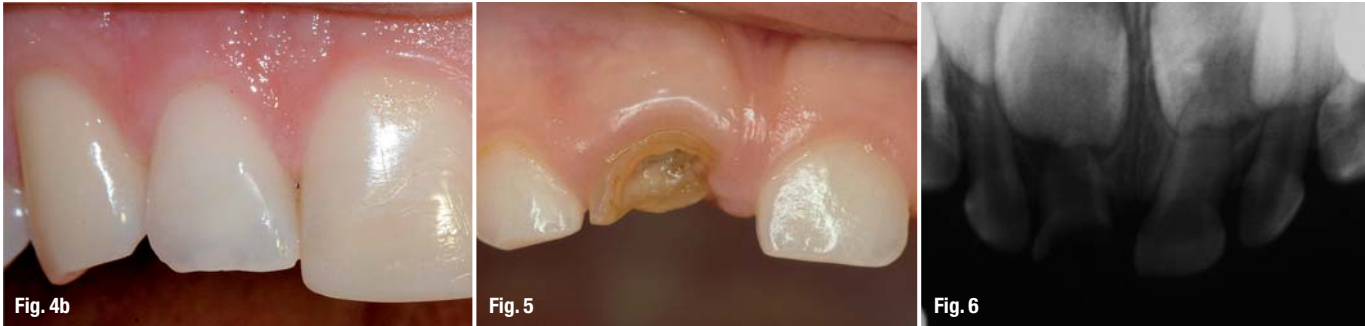

Fig. 5 Patient aged 4.2 years. Complicated crown fracture. Three months have elapsed since the trauma occurred. Gingival hypertrophy of 5.1 covers the fracture margin.

Fig. 6 X-ray examination.

The examination should be proceeded by cleaning the injured area and careful search for pulp exposure.

Take an X-ray, perform vitality tests, sometimes there is accompanying damage to the soft tissue (tongue and lips: look for tooth fragments).

The use of modern bonding agents and laser technology has changed considerably our clinical practice. Erbium lasers can guarantee good results reducing post-operative discomfort and sensitivity as well as providing minimally invasive dentistry (Genovese et al. 2008).

Erbium lasers are indicated for the treatment of crown fractures, both complicated and uncomplicated, and whether or not the tooth fragment is available. In the first decade of research, various authors studied the parameters and variables for using the Erbium laser, evaluating the morphological effects on hard and pulp tissues: the effects of energy density, pulse repetition rate, and air-water jet were reported: the results obtained with the laser were the same as those achieved with orthophosphoric acid (Moritz et al. 2006).

Various studies and clinical reports showed how the laser, used by numerous operators as an alternative to rotary instruments in paediatric restorative dentistry, brings an added measure of safety even when used in the treatment of very young children, a new possibility for minimal interventions (Kornblit et al. 2008), and overall better acceptance compared to traditional techniques (Keller et al. 1998).

Laser cavity preparation is closed related to different variables. Fluence, power density and pulse length, but also laser angulation, focus mode, the amount of air-water jet are all factors that can cause substructural damage to the dentin. A final conditioning at low wattage both on dentin and enamel is advisable. Acid etching

on lased dentin and enamel produces uniform results, eliminating the thin layer of substructural damage, exposing the collagen fibers and creating a substrate for the formation of the hybrid layer; acid etching modifies the Silverstone enamel class 2 and 3 into class 1, allowing better composite adaptation.

The action of Erbium lasers on hard tissues and pulp is extremely precise: the surface treated are cleansed and sterilized.

Temperature increase during treatment is minimal and may decrease while working with water-spray cooling.

Due to bactericidal capacities, no production of smear layer, opening of dentinal tubules, allowing hybrid layer formation these lasers can be used to perform the hole procedure: excavation, coagulation of the exposed pulps (if needed), pulpotomy or pulpectomy (Figs. 1–4).

Another feature is the very superficial thermal effect, therefore the necrotic zone is likely to be very small.

This kind of injury exposes a large number of dentinal tubules: 1 mm² of dentin exposes 20.000 to 45.000 dentinal tubules.

They constitute a pathway for bacteria, thermal and chemical irritants which can determine pulpal inflammation: Erbium lasers are effective for removing organic material, smear layer and can achieve a bactericidal effect but the Nd:YAG laser and the diode laser can provide an effective decontamination action as well.

The Erbium laser's fusion and sealing capacity of the dentinal tubules (depth of up to 4µm) can result in a reduction of the tissues's permeability to fluids, thus reducing dentinal hypersensitivity.

Another structural change induced by these lasers is the phenomenon of vitrification, this can

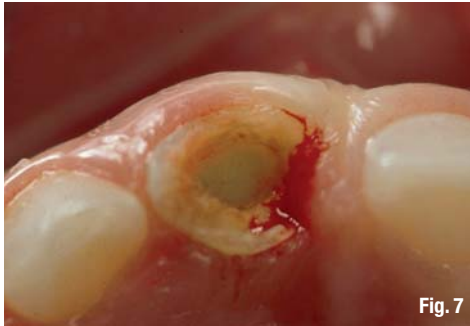


Fig. 7

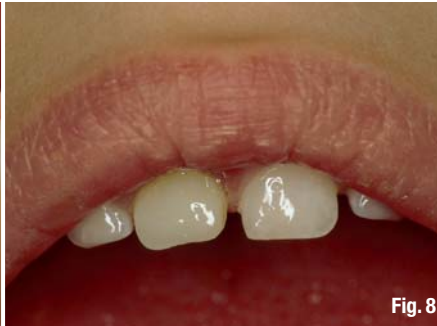

Fig. 8

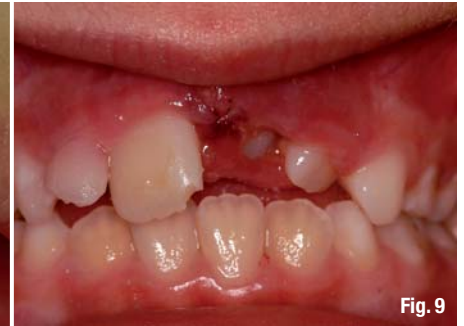

Fig. 9

be very useful because it increases hard tissue resistance to acid remineralization, dental hardness and dental abrasion.

The Nd:YAG and the diode laser have a beneficial therapeutic action in direct traumas.

These lasers, exploiting their photothermic effect, can be used to treat both pulp and dentin.

They can be applied:

- _to treat dentinal hypersensitivity
- _to perform indirect or direct pulp capping
- _to remove endodontic material
- _to treat infected root canals.

The CO₂ laser has a purely thermal effect on the tissue, 90–95 % of the energy it delivers to tissue is absorbed by a fine tissue layer and transformed into heat.

It's indicated for:

- _pulp capping (following dentin fracture)
- _pulpotomy (following crown or root-crown fractures)
- _surgical cutting (e.g. to remove a tooth fragment) (Figs. 3, 4, 5 & 15).

Few studies that investigate laser performance in maintaining pulp tissue vitality are indexed in the PubMed library. Different laser wavelengths and parameters related to the different devices were used. The common delimitator was the low laser energy applied (from 0.5 to 1.0 W), delivered in defocused mode, preferably using low repetition rate or superpulsed mode.

Pulpotomy is a very common technique in primary teeth: although pulpotomy with formocresol (1 : 5 dilution) is used with success, there is a tendency today to seek alternative techniques, considering the carcinogenic and mutagenic potential of this formaldehyde component. Lasers

have been proposed for pulpotomy, and study (Pescheck et al. 2002) compared favourably CO₂ laser treatment to formocresol for pulpotomy in primary teeth, with a survival rate from 91 % to 98 %. Other studies reported that the superpulsed mode produced a markedly higher success rate than the continuous wave mode.

During this procedure, attention must be given to the energy applied. Low energy delivered in defocused mode and pulse or superpulsed mode guarantees good superficial coagulation and good decontamination to maintain the vitality of the residual pulp in pulp capping application (Olivi et al. 2007).

Particular care must be taken with the application of laser energy into primary root canals for root canal cleaning and disinfecting, due to the characteristic anatomy of the apex and to the penetration depth of near infrared lasers (Soares et al. 2008).

Crown-fracture and root fracture

Fractures healing cannot be expected in crown-fractures, in contrast to root fractures where the fracture is located entirely within the alveolous.

The coronal fragment is usually removed and the treatment should be focused on the possibility of using the remaining fragment.

On superficial fracture without pulp exposure it's suggested to remove loose fragments, smoothing the rough subgingival fracture surface and covering the exposed dentin.

When the coronal fragment comprises 1/3 or less of the clinical root, after the removal of loose fragments, a pulpectomy and root canal filling is advocated.

The fracture surface has to be exposed with a gingivectomy or osteotomy and subsequently a prosthetic restoration (Figs. 5–8).

Fig. 7 Gingivoplasty is performed by using an Erbium laser, without local anesthesia. The root canal is filled with calcium hydroxide. Dental margins are treated with an Erbium laser (minimal intervention).

Fig. 8 The tooth 5.1 is restored with composite. Clinical appearance after finishing and polishing phases.

Fig. 9 Patient aged 7.8 years. Severe intrusive luxation of 2.1 which also presents a crown fracture. Subluxation and enamel fracture of 1.1.

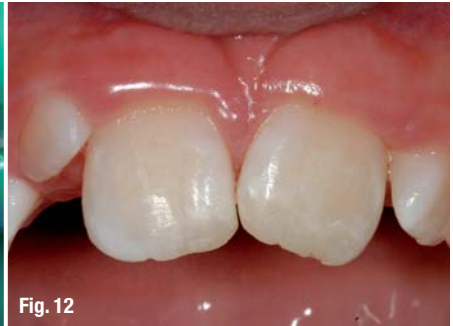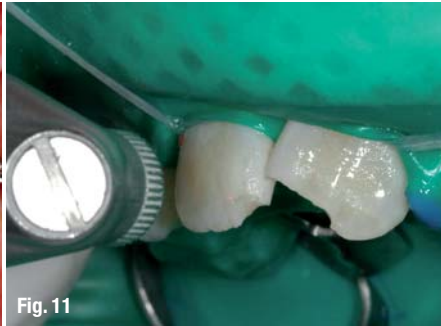

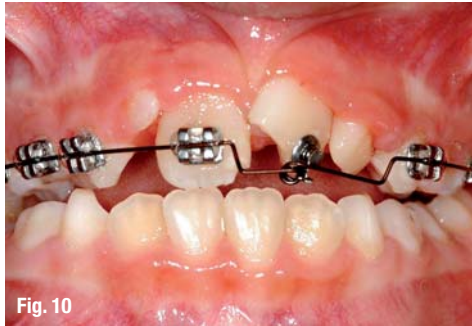
Fig. 10_Before orthodontic extrusion (using 0.016-inch Australian wire for 2 weeks) the periodontal tissues were treated (decontaminated) with Nd:YAG laser.

Fig. 11_Once 1.1 and 2.1 had been repositioned, they were restored with an Er:YAG laser.

Fig. 12_Final clinical appearance.

1. Traumatic Injuries to hard dental tissue and pulp	
crown infraction	
uncomplicated crown fracture	
complicated crown fracture	
uncomplicated crown-root fracture	
complicated crown-root fracture	
root fracture:	<ul style="list-style-type: none"> _apical third _middle third _coronal third
2. Traumatic Injuries to the periodontal tissues	
conclusion	
subluxation	
extrusive luxation	
lateral luxation	
intrusive luxation	
avulsion	
3. Injuries to the supporting bone	
not described as they are related to maxillo-facial surgery	
4. Injuries to gingiva or oral mucosa	
laceration of gingival or oral mucosa	
contusion of gingival or oral mucosa	
abrasion of gingival or oral mucosa	

Tables 1_1.-4. Classification of traumatic injuries.

Hard and soft tissues	Er:YAG 2,940 Er,Cr:YSGG 2,780
Soft tissues	KTP 532 Argon Diode 810, 940, 980 Nd:YAG 1,064 CO ₂ 10,600
Low Level Laser	Elium neon 635 Diode 810

Table 2_Laser classification hard and soft tissues.

Laser-assisted therapy can be useful not only for the coronal fragment restoration but also for supporting tissue surgery and endodontic therapy (gingivoplastic, gingivectomy, crown lengthening) (Sarver & Yanosky, 2005).

Lasers are effectively used in these soft tissue procedures; they can easily incise, cut, ablate, reshape the soft tissue with no or minimal bleeding, less pain and have a bacteria killing effect.

In these clinical events deeply-penetrating type of lasers (Nd:YAG and diode-lasers) show a thicker coagulation layer than superficially-absorbed ones (CO₂-Erbium lasers).

The technique used with the first ones is similar to removing the tissue with electrosurgery.

Treatment factors as optimal repositioning and a flexible splinting have a positive influence upon healing, such as an immature root formation, lower age, less displacement of the coronal fragment.

As splint has to be kept in situ for at least several weeks an aesthetic orthodontic splint can be used (ceramic brackets).

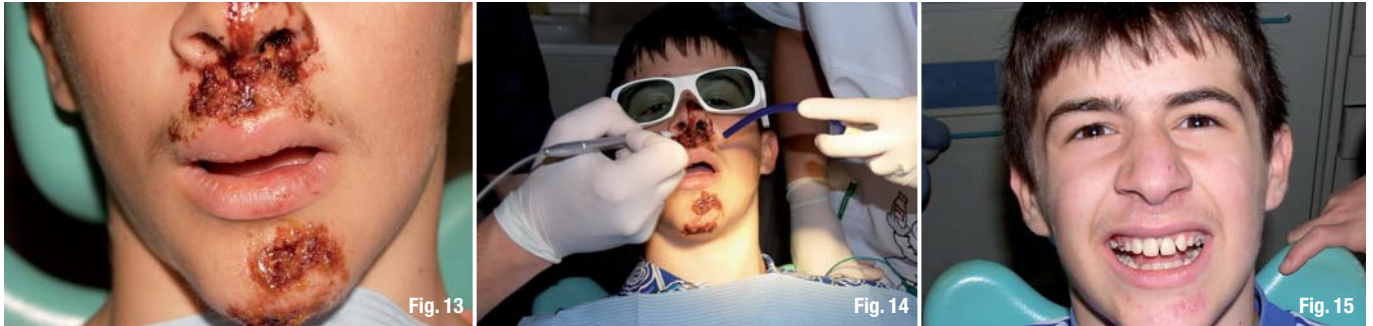Debonding procedures can be atraumatic when using a Nd:YAG laser.

Intra-pulpal temperature rises less than using conventional high-low speed instruments for orthodontic brackets removal.

Therefore laser-assisted procedure is safer, quicker and more comfortable (Figs. 3, 4, 5 & 15).

Traumatic injuries to the periodontal tissues

Indirect traumas are lesions to the supporting structures, in particular the alveolar bone, the periodontium, the gingiva, the ligaments, the fraenum and the lips.



The Nd:YAG laser and the diode laser have a beneficial therapeutic action in traumatic injuries to the periodontal tissues.

These lasers have a decontaminating effect, as well as a biostimulating and reparative effect, with no suture, good and rapid healing by second intention and minor discomfort for the patient.

They are useful for:

- _decontamination of the alveolus following a traumatic avulsion
- _treatment of a periodontal defect following a dental luxation or sub-luxation
- _microgingival surgery for the treatment of a traumatic dental injury
- _gingivectomy and gingivoplasty
- _surgical cutting (e.g. to remove a tooth fragment) (Martens 2003).

Finally they also exert an appreciable analgesic effect both on hard and soft tissues.

In oral surgery both the diode laser and the Nd:YAG laser are used, the former is used in continuous or pulsed mode, the latter always in pulsed mode but with different pulse amplitudes.

The increase in temperature that these lasers produce has an excellent thermostatic effect. In all luxation injuries the bactericidal effect and detoxification of lasers (Er:YAG, Nd:YAG, diode and argon lasers) to provide favorable conditions for the attachment of periodontal tissue can be achieved (Figs. 9, 10, 11, 12).

Laser decontamination and/or laser photobiomodulation can be required for tissue repair (cutaneous and subcutaneous tissue irradiation) and for pain relief. It has been reported that photodynamic changes may occur in several physiologic processes: further clinical studies are necessary to establish suitable irradiation conditions. Nd:YAG laser, diode laser and KTP can also be alternative technique for non vital bleaching procedure.

Lasers are increasingly being used for gingival dental surgery and to replace the use of electro-surgery. A study to evaluate and compare the temperature rise in hard and soft tissue when using CO₂ and diode laser and electro-surgery units for soft-tissue dental surgery became to the conclusion that both procedures are considered soft to local tissue in terms of temperature rise if provided guide-lines are used. The CO₂ laser caused more heat in the gingival.

The CO₂ is specifically used for surgical cutting (e.g. to remove a tooth fragment from lip or oral mucosa) (Figs. 3, 4, 5).

Injuries to developing teeth

Disorders of permanent teeth caused by traumatic injury to primary teeth can be divided into two groups according to the type of dental trauma (direct traumatic impact or indirect lesion). The prevalence of these disturbances ranges from 12 to 69 % depending on the study; avulsion and intrusive luxation are injuries associated with very high frequencies of developmental complications.

Laser assisted therapy can be useful in:

- _enamel discolouration: treatable with Erbium laser
- _circular enamel hypoplasia: treatable with Erbium laser
- _ectopic eruption: treatable with surgical exposure or soft-tissue laser surgeries (all the wavelengths of the near-medium and far infrared spectrum of light).

Low Level Laser Therapy or Soft Laser Therapy (LLLT)

A non-traumatic introduction to dentistry can be represented by low level laser therapy or soft laser therapy.

There is a large body of literature on this particular topic even though, methodologically and

Fig. 13_Patient aged 16.2 years. Avulsion of 2.1. Deep abrasion of upper lip oral mucosa, nose and chin. (Courtesy of Dr. V. Lazzarini)

Fig. 14_The soft tissue injuries are treated every day for 7 days with a Nd:YAG laser.

Fig. 15_Final clinical outcome of the face and smile. A removable orthodontic space maintainer is placed to restore temporarily the frontal tooth loss.

in terms of doses, there is still considerable difference of opinion.

Even though helium-neon lasers were initially used (632.8 nm = λ), the ones in use today are the semiconductor diode type (830 nm or 635 nm = λ).

The water absorption coefficient of the wavelengths used for this purpose is reduced and the beams are able to penetrate both soft and hard tissues from a distance of 3 to 15 mm.

LLLT has a number of applications in dentistry; both at soft tissue level (biostimulation of lesions, aphthous stomatitis, herpetic lesions, mucosity, pulpotomy) and neurally (analgesia, neural regeneration, temporo-mandibular pain, post-surgical pain, orthodontic pain).

Between 1 and 3 days after biostimulation, it is already possible to observe a considerable reduction of swelling and an acceleration of the epithelisation and collagen deposition phase.

The clinical importance of this acceleration of the reparative processes is considerable, especially when the general defense system of the patient is compromised (young patients but also older patients insulin dependent diabetes, valvar dysfunction or malformations, history of endocarditis, patients with prosthetic cardiac valves, cardiac surgical reconstruction).

In short, LLLT stimulates tissue repair processes and, influencing a large number of cell systems, can also have a series of benefits on inflammatory mechanism. (Antalgic—Biostimulating—Anti-inflammatory effects) (Nascimento et al. 2004, Weber et al. 2006) (Figs. 13, 14, 15).

These effects are specific to some wavelengths and they cannot be obtained with non-polarised and non-coherent light sources, such as LEDs.

The author hopes that the pursuit of these new horizons might lead to the definition of protocols containing more specific indications as regards times, doses and sites of application.

LLLT has main indication in dental traumatology (Caprioglio C & Caprioglio A 2010, Tuner & Hode 2004): Brief analgesic effect in the mucosa allowing painless injection with a needle or treatment without anaesthesia.

Direct application into the exposed cavity of a deciduous tooth can be used for pain reduction;

also the trans-mucosal irradiation in the apical portion and a reticular irradiation to the cervical area of the tooth has an analgesic effect.

In post-traumatic treatment after lip and front-tooth trauma to reduce swelling and pain.

Post-endodontic therapy, after pulp-capping, after apexogenesis or apification.

- _ Orthodontic movements.
- _ TMJ disorders and pain.
- _ Traumatic mucosal lesions (ulcers), aphthous or herpetic lesions.

Knowing that the analgesic effect of light at 800–900 nm is 30 joules x cm² and the biostimulating effect is 50 joules x cm², it becomes possible to develop operating protocols that can be compared, standardised and repeated (Benedicenti 2005).

_ Conclusions

Lasers are very effective not only in paediatric dentistry but also in traumatic dental injuries. They enable optimal preventive, interceptive, and minimally invasive interventions for both hard and soft tissue procedures. It is important for the professional to understand the physical characteristics of the different laser wavelengths and their interaction with the biological tissues to ensure that they are used in a safe way, in order to provide the benefits of this technology.

Therefore a period of education and training is highly recommended before applying this technology especially to paediatric patients.

Editorial note: The literature list can be requested from the editorial office.

_contact

laser

Claudia Caprioglio

Doctor Dental Science
 Post-graduate in Orthodontics
 Visiting professor University of Parma (Italy)
 Director Centro Internazionale di Aggiornamento
 Odontoiatrico (C.I.A.O. s.r.l.)
 Via San Zeno 1, 27100 Pavia, Italy
 E-mail: ac.caprioglio@tin.it

AMD LASERS™

Effective. Practical. Affordable. World Class Lasers.

*The Fine Art of
Laser Dentistry*



picasso
IS #1

picasso
st Lite

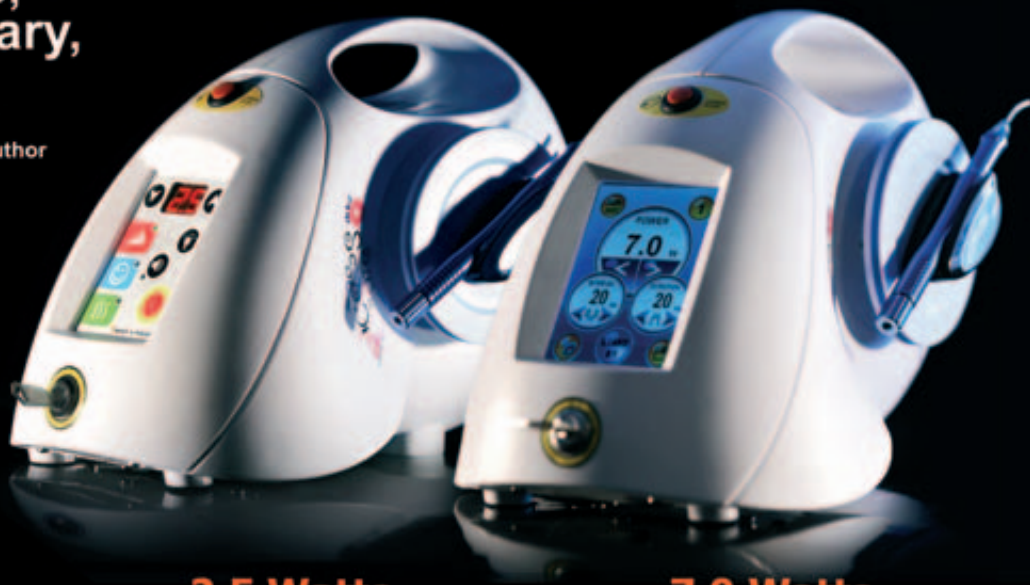picasso

2 Year
Warranty

\$2,495

3 Year
Warranty

\$4,995



2.5 Watts

3 Custom Presets
Continuous/Pulse Modes
Universal Icon Menu

7.0 Watts

8 Custom Presets
Continuous/Pulse Modes
Multi-Lingual Menu



“recognized leader,
**superior
products,**
that every dentist can afford.”

Larry Rosenthal, DDS
Director Aesthetic
Advantage
New York, NY



“easy to use,
**revolutionary,
affordable!”**

George Freedman, DDS
International Lecturer, Author
Toronto, Canada



“impressive,
every dentist
should have one.”

Ross Nash, DDS
Nash Institute
Charlotte, NC

Get out of the
dark ages and
**laser focus
your practice**



DENTAL PRODUCTS REPORT
TOP 100

Dental PRODUCT SHOPPER
**BEST PRODUCT
2009**

▶ *the only lasers to offer*
STRIPPABLE FIBERS OR DISPOSABLE TIPS



AMD LASERS™, LLC.
www.amdlasers.com

7405 Westfield Blvd.
Indianapolis, IN 46240, USA

866.WWW.AMDL
866.999.2635

TEL: 317.202.9530
FAX: 678.868.4108
sales@amdlasers.com

FDA CE
0197
ISO 13485

T7 8.Mv2-2010