

Implant exposure with Er:YAG laser (=2,940 nm)

A comparison with lasers of different wavelengths

Author_Dr Gerd Volland, Germany

The use of lasers in oral surgery is known to have many advantages compared to conventional surgery. Zeredo et al.¹⁸ did prove in an study on incision in rats that the nociception is reduced with a factor of 3 compared to the conventional scalpel use. Surgical cuts with electrotome and scalpel cause a bacterial invasion in the treated animals. Kaminer et al.⁹ did not find this problem using laser techniques.

Lasers of different wave lengths are proven to reduce bacteria efficiently in different fields of dentistry and medicine.^{4,5,6,13} After an initial lac in healing the application of superpulsed carbondioxide laser light reduced the configuration of scars significantly compared to electrotome and scalpel (Romanos et al.¹⁵

Because of these reasons, the healing^{14,16} and the bloodless operation field lasers use is more and more common in all fields. Depending on the wavelength laser light is absorbed, transmitted or scattered very differently depending on the irradiated tissue.² Nd:YAG lasers are not proriarte in second stage surgery because of the high absorption in metal, especially titanium. They are used for laser melting in dental labs by the technicians. Whereas diode lasers with 810, 980 or 1,064 nm penetrate uncoloured tissue up to

4 mm, carbondioxide an Erbium lasers are absorbed very superficially in a range between 3 (Er:YAG) and 17 μm (carbondioxide).³ Chromophores of the skin are oxyhemoglobine, hemoglobine, melanine and carotene.³ Not only in different ethnical groups we find different coloration of the skin, even in people of central Europe we find different coloration of the oral mucosa and the palate.⁸

Aside the ethnical aspects we find different coloration of the mucosa in different parts of the mouth in the same patient depending on pigmentation, vascularisation and per cent of fibrous tissue such as palate or vestibulum. Watching the absorption curves we find differences with factor 10 to 10,000 comparing the absorption coefficient of the different compartments.⁷ This causes the problem that we do not have a predictable absorption using diode or Argon lasers in oral surgery.

So the surgeon needs a lot of experience because he has no protocol which is always the same.

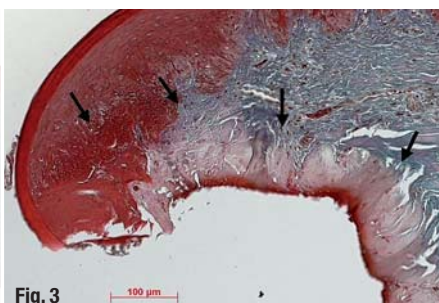
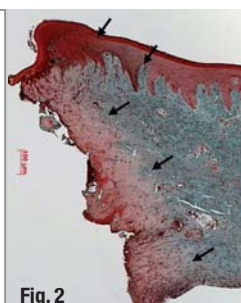
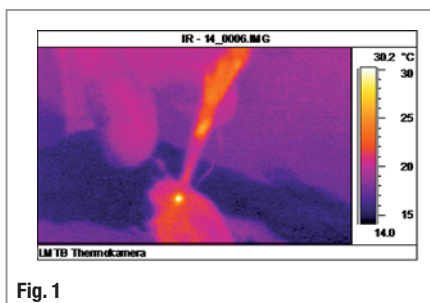
Neither power setting nor velocity of the cut are fixed parameters. Starting with low power settings may cause long treatment time. High power enables fast cutting but uncontrolled heat because the alteration of the tissue

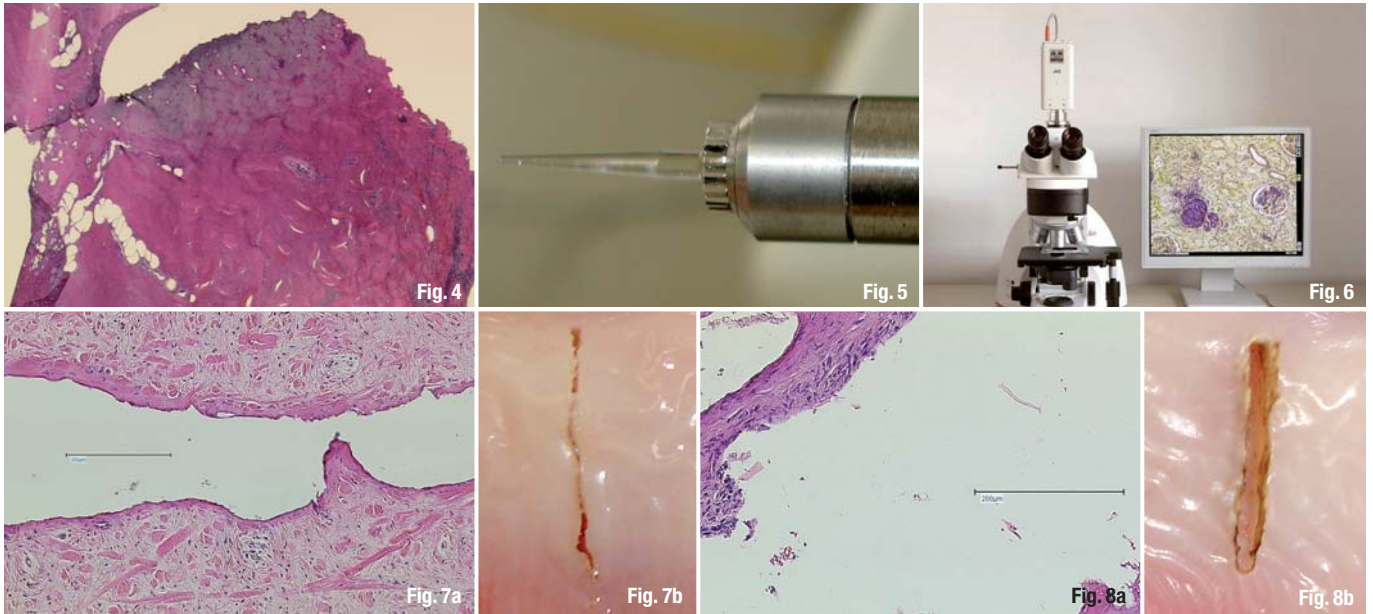
leads to extreme development of temperature increase. Especially for surgeons who start with laser it would be perfect to have an instrument with which you can see what you do, that does not have a high

Fig. 1 _Infrared camera.

Fig. 2 _980 nm 300 μm fiber 5 W cw.

Fig. 3 _980 nm 300 μm fiber 7 W spray.





penetration and have a fixed protocol to reach best possible success.

Gutknecht⁷ described the way of cutting with fibre diode lasers and gave the name "hot tip" cutting. But this also means that the main danger is the overheating and the caused by this uncontrolled necrosis especially in fibrous non coloured parts of the mouth such as the palate or a fibrous frenulum. Own investigation in 2001 at LMTB in Berlin using a spray of distilled water (diode laser 980 nm Ceralas D15, 7 W cw, 300 mm fibre, 10 ml/min. 3 bar air pressure) showed that by water cooling a lot of the heating can be transported away from the "hot tip" by the water flow.

The picture of a thermo camera shows the cooling effect very good.

Nevertheless we need the hot fibre end for the cut as seen in the picture

The uncontrolled heating in fibrous tissue causes deep necrosis up to 400 µm cutting mucosa of a pig, which can disturb healing very much (Fig. 3).

In comparison the cut with 7W and spray shows a clearly defined zone of necrosis of about 200 µm. Nd:YAG lasers (6 W 100 Hz 300 µm fiber) in unpigmented skin of a pig make very uncontrolled carbonization .

The only constant part in oral mucosa is water with about 85%.⁷

Because of this the only lasers which have always the same effect regarding the zone of periphery necrosis in the whole mouth soft tissue are carbon-

dioxide and erbium lasers. Especially in Er:YAG lasers the thermal damage goes down to zero using pulse width of 300 µs¹⁰ because the cut is not thermal but almost completely thermomechanical. Parts of the subsurface water are sublimated within 2 µs.³

By this effect there is almost no thermal damage in this pulse width.

Aside from cavity preparation the Erbium can also be used for oral surgery.^{1,17}

The remaining problem with the normal settings is the bleeding.

From theory using less power per pulse and using a higher frequency should lead to more thermal effect using the same pulse width.

For the *in vitro* experiment a laser with pulse width 300 µs, a fiber as light transmission system and special conical sapphire tip 300 µm (Hoya, Versawave) were used.

The exact energy output at the end of the tip could not be asked by the company. So the parameters shown on the display had to be used for definition of energy density and power density.

Material and Method

Different frequencies enabling an effective cutting were compared.

Mandibula mucosa of fresh pig that were not cooled after the slaughtering for having always the same amount of water in the mucosa were put in

Fig. 4 Nd:YAG 6 W 100 Hz pulse width 150 µs 300 µm fiber.

Fig. 5 Surgical tip.

Fig. 6 Measuring structure.

Fig. 7a 40 Hz/125 mJ with Spray.

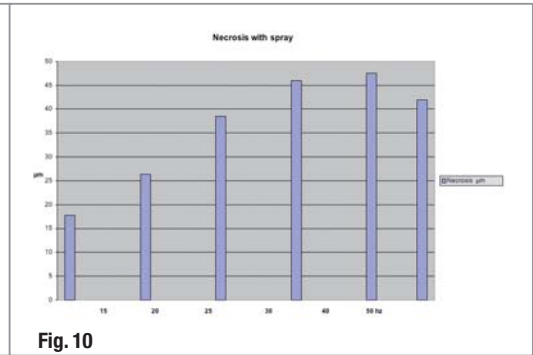
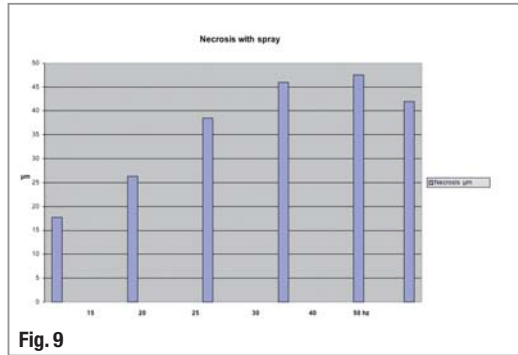
Fig. 7b 40 Hz/125 mJ with Spray.

Fig. 8a 50 Hz/40 mJ no spray.

Fig. 8b 50 Hz/40 mJ no spray.

Fig. 9_Statistics without spray.

Fig. 10_Statistics no water.



Ringer Solution. After making smaller parts the mucosa on the tongue side including the periost was cut through in contact mode. The average thickness of the mucosa was 1,0 mm.

They were put in 10 per cent formaline and examined in Ansbach pathology institute.

The pathologist made histologies using cuts over the length using hematoxyline-eosine colouring. The cuts were examined in a depth of 0,6 mm.

The evaluation was made by using a Zeiss microscope with magnification 5x to 40x with Discus software by Hilgers.

The necrosis with spray was between 17,72 µm at 15 Hz/420 mJ up to 47,54 µm using 40 Hz/125 mJ.

Without spray the lateral necrosis was between 18,9 µm at 15 Hz/420 mJ up to 102,18 µm at 50 Hz/40 mJ.

_Discussion

Using a higher frequency in Er:YAG lasers with spray leads to coagulation of a maximum of 47,54 µm. Without using spray the average necrosis goes up to 102,18 µm. The higher frequency leads to an almost linear increase of the tissue alteration. This enables the surgeon to work with predictable coagulation results on the tissue.

Kreisler et al.^{11,12} proved that applying 11,2 J/cm², pulse width 300 µs the titanium surface of implants gets no harm. So a damage of the implant/ bone interface using available settings can be excluded. For effective laser work in implant exposure also in esthetic critical areas Er:YAG lasers can be used. There is no risk for loss of tissue by uncontrolled heating with maintenance of reduction of bleeding or even no bleeding. The bone below the cut is damaged up to 12 µm using the no spray parameters. So it is a safe way also when cutting fibrous tissue, i.e. a wisdom tooth cut eliminating risk of bacteriemy or cuts on the

palate. More controlled increase of the coagulation area over the measured may be reached by using other parameters with less power per pulse, higher frequency or a higher pulse width.

_Indications

Vestibuloplastics, frenectomies, hyperplasia, excisions in the lip red or implant recovery in fibrous regions will be the indications for the Erbium instead of a knife.

The limitation using the Erbium laser in incisions are the regions with vessels.

Because of no light penetration bleedings cannot be stopped using this laser.

Normally compression should help. This laser should not be used in vessel producing tumors such as hemangioma.

People with hemorrhage diathesis or anticoagulation will have no benefit.

In these people diode lasers (810, 980, 1,064 nm) Argon(488/514 nm) or long pulsed Nd:YAG lasers are the first choice in treatment of these patients.

The aim for the future is to develop an appliance that combines easy and safe cutting of a scalpel with controlled coagulation and all the other benefits of laser like sterilisation of the cut or low level effects.

Editorial note: The literature list can be requested from the editorial office.

_contact	laser
<p>Prof Dr MSc mult Gerd Volland Facultad de Odontología Cirurgia bucal Universidad de Sevilla C/ Avicena s/n Sevilla, Spain</p>	