

laser

international magazine of laser dentistry

2²⁰¹⁰



| overview

LLLT activated latent TGF- β 1


| laser

Graduation of the 10th year of the master programme “Lasers in Dentistry”


| meetings

UAE International Dental Conference & Arab Dental Exhibition — WFLD took part at AEEDC 2010





When I bought my Fidelis my colleagues told me Fotona never stops innovating. They never stop pushing the boundaries of laser dentistry. How right they were! I've just started working with my new set of **Preciso endodontic and Varian periodontic** fiber tips. Both are fully compatible with the **AT/HT Fidelis Er:YAG laser**. I can now choose from almost 20 fiber tips to make my hard and soft tissue treatments less invasive, more effective and to reduce my patients' chair time.


Fotona user since 2000

NEW

Fotona
choose perfection

AT Fidelis Highest Performance in Dental Care

Revolutionizing Dentistry

The AT Fidelis is Fotona's newest generation in dental laser systems. With dentistry's two best lasers in one system, you can provide the ultimate in dental care! AT Fidelis' Er:YAG, the world's fastest drilling, hard tissue laser, features broadened soft tissue surgery capabilities with the finest low pulse, high repetition rates. Its top-of-the-line Nd:YAG laser provides trouble-free endodontic, surgical and aesthetic procedures. Both lasers feature VSP technology, enabling controlled and constant laser intensities, in an unprecedented five, selectable pulse duration modes.

Convenience and Safety First

The AT Fidelis includes the newest Comfort Mode touch screen navigation system. Its pre-set treatment programs and data storage facility offer ultimate treatment management. Selecting the right treatment settings has never been easier!

Its Advanced Mode enables users to quickly fine-tune procedures through its all-encompassing interface. The AT Fidelis offers the industry's only Tissue effect Graphical Interface (TeGI) which provides precise graphical representations of laser-tissue effects as treatment settings are changed. For improved user comfort, the AT Fidelis features a wireless footswitch. While ESC Technology allows you to perfect water and air spray mixes, the AT Fidelis does not require external air or water sources, making it uniquely mobile.

Unlimited Possibilities!

Apart from providing the widest range of hard and soft tissue dental treatments, you can also upgrade your system with aesthetic upgrade packages. This enables you to provide aesthetic treatments ranging from facial laser hair removal and rejuvenation treatments to facial vascular treatments.



The Highest Performance, Best Made Laser Systems in the World

Put a smile on your patients' faces!
Visit www.fotona.com now!



Dr Georg Bach

Dear Reader,

_Globalization progresses steadily and has also found its way into laser dentistry. This issue of laser—the international magazine of laser dentistry is going to prove this thesis.

We, whose goal it is to treat patients with monochromatic light, realize that the individual problems we are facing in our daily routines are, in fact, quite diverse.

We have been dealing with an array of problems: hesitant acceptability of laser dentistry within the universities and professional dental societies, availability of laser wavelengths and equipment and problems with reimbursements.

If we choose to stick together, we will realize the outstanding and notable level today's laser dentistry has reached, a level many didn't think was achievable only a few decades ago.

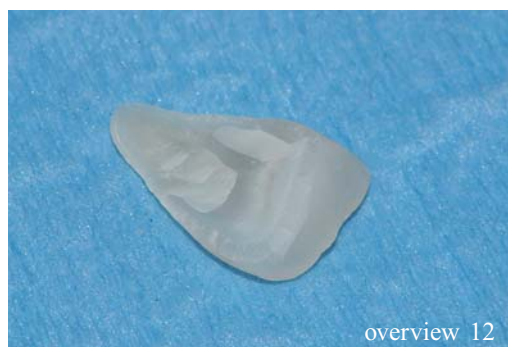Invigorated by this awareness, each and every one of us should play their part and contribute to a truly global laser network for the benefit of the community.

laser is an excellent platform for scientific exchange. I hope you will enjoy this issue and welcome your feedback!

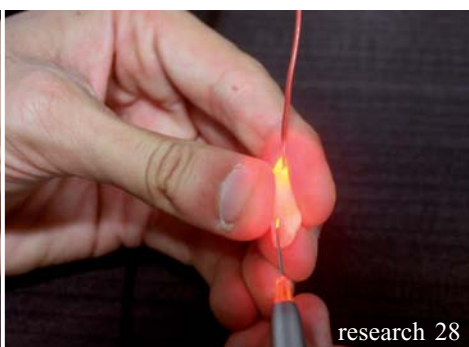
Yours sincerely,

A stylized, handwritten signature in black ink, consisting of a large, fluid 'h' shape.

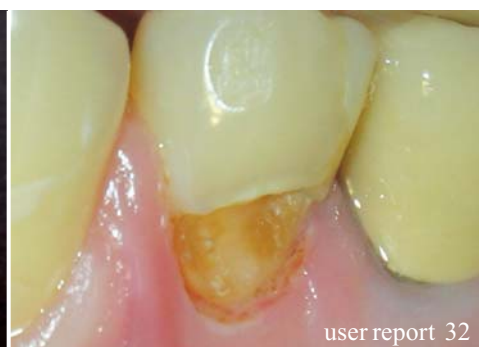Dr Georg Bach
Guest Editor



overview 12



research 28



user report 32

| editorial

- 03 **Dear Reader**
| Dr Georg Bach

| overview

- 06 **LLLT** activated latent TGF- β 1
| Tristan Hunt, Eason Hahm & Praveen Arany
- 12 **Lasers in dental Traumatology**
| Claudia Caprioglio

| research

- 20 **Electrotome and Er:YAG laser**
| Dr Anastasios Manos & Prof Nicolaos Parisis
- 24 **Implant exposure** with Er:YAG laser
($\lambda = 2,940$ nm)
| Dr Gerd Volland
- 28 **Laser endodontic therapy** using 940 nm
diode laser
| Dr Pradhan Suchetan & Dr Karnik Rohit

| user report

- 32 **Diode lasers:** the soft tissue handpiece
| Dr Fay Goldstep

| feature

- 36 **From the first working laser until now**
| Ingmar Ingenegeren

| laser

- 38 **Graduation of the 10th year of the master programme**
“Lasers in Dentistry”
| Dajana Klöckner
- 40 **First year of Mastership Course “Lasers in Dentistry”**
graduated successfully
| Dajana Klöckner
- 42 **Cyprus** invited out to **laser**
| Dajana Klöckner

| meetings


- 44 **UAE International Dental Conference & Arab Dental**
Exhibition—**WFLD took part at AEEDC 2010**
- 46 **International events 2010–2012**

| news

- 48 **Manufacturer** News

| about the publisher

- 47 | submissions
50 | imprint



feature 36



laser 38



meetings 44

elexxion


powered by technology

elexxion
claros

elexxion
duros

elexxion
delos

elexxion
claros nano



Four laser specialists for a wide range of applications

- Highest cutting performance
- Short pulse duration guarantees smooth soft-tissue application
- Compliance to all hygienic standards through autoclavable handpieces and fibres

elexxion AG

Schützenstraße 84 · D-78315 Radolfzell · Germany
Tel. +49 7732-822 99 0 · Fax +49 7732-822 99 77
info@elexxion.com · www.elexxion.com

LLLT activated latent TGF- β 1

Authors_Tristan Hunt, Eason Hahm & Praveen Arany, USA

A potential molecular pathway mediating the nexus between inflammation and wound healing in oral tissues.

_Low-level laser therapy in dentistry

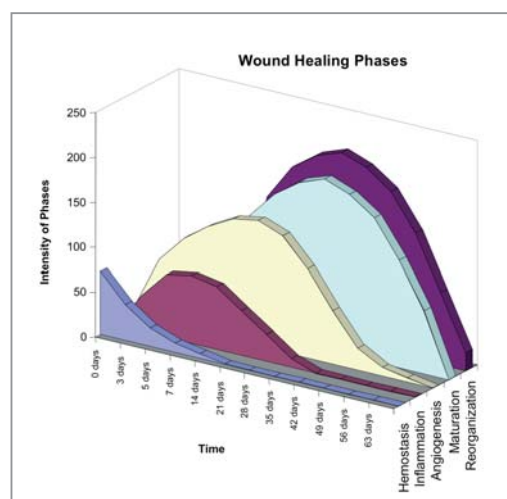
For over 30 years lasers have been a part of dentistry and oral surgery predominantly as surgical tools. Surgical lasers currently used in dental practice include CO₂ lasers, Nd:YAG lasers, Er:YAG lasers, and diode lasers.¹ CO₂ lasers have been used to remove superficial tissue layers while leaving underlying tissues undamaged and are especially valued for their coagulation effects. Er:YAG lasers have been used for ablation of soft and hard tissues and to sterilize root canals and periodontal pockets while Nd:YAG lasers have been used for debridement of calculus and the reduction of endodontic microbes. The diodes have been used for variety of low level applications from analgesia to stimulating healing.

Low-level laser therapy (LLLT) is considered a non-invasive and painless process that uses photonic energy to provide biological therapeutic ad-

vantages, including analgesic capabilities.² While these types of lasers are still used surgically, clinicians have been increasingly using LLLT in the past ten years. Rather than cut or ablate, low-level lasers take advantage of certain photobiological processes, the mechanistic molecular basis of which are yet to be fully characterized. These lasers function in the milliwatt range instead of the higher wattage (0.5 to over 1 W) used by the surgical lasers. The clinical applications of low-power laser for patient care in dentistry have been used to reduce inflammation, relieve pain and discomfort including hypersensitive dentine and promote wound healing.³ There are some clinical studies but few rigorously controlled trials to demonstrate the efficacy of LLLT definitively as well as a paucity of basic science research to probe its mechanistic underpinnings in its various dental applications. This short review does not attempt to comprehensively overview the state of field but highlights some of the recent human clinical studies that have attempted to directly explore the efficacy of LLLT on inflammation and healing in oral tissues.

_Inflammation

Inflammation is a complex reaction to injurious agents such as microbes and damaged, usually necrotic, cells that consist of vascular response, migration, and activation of leukocytes, and systemic reaction.⁴ Inflammation is usually a protective pathophysiological response of the body to help prevent noxious damage and return to a homeostatic physiological state. But in scenarios of persistent stimuli or uncontrolled inflammatory reactions, this mechanism can turn pathological and harm the host instead.



Wound Healing and Regeneration

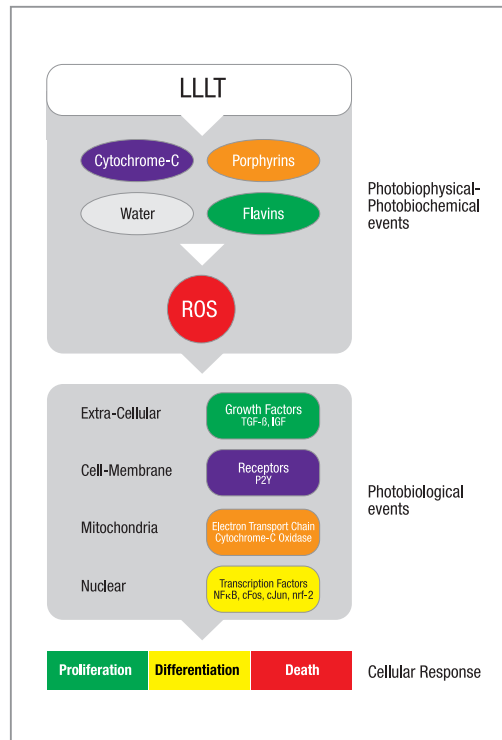
Wound healing, on the other hand, is the resolution of inflammation that succeeds the inflammatory reaction. The ultimate goal of healing is to remove all traces of the inflammatory reaction, along with the noxious stimuli, and return tissues to their original structural and functional homeostatic state. The ideal outcome of wound healing is a complete restoration of the damaged tissue and is termed regeneration. There are two possible modes of regeneration although these two processes are not sharply delineated and may co-exist in the certain scenarios. The mode of regeneration involves proliferation of material preceding development of the new part termed 'Epimorphosis' while the other involves transformation directly into a new organism, or part of an organism without proliferation at the cut surfaces termed 'Morphallaxis'.⁵

The nexus of inflammation and healing with timing of LLLT

While inflammation is critically important and precedes healing, a persistent inflammatory reaction will interfere with effective healing. The ability to modulate the inflammatory response by changing the initial milieu of factors can potentially direct the eventual healing process. The use of LLLT attempts to do just this by delivering photonic energy in this early inflammatory, post-injury scenario that could activate or inactivate specific molecular pathways, accelerating the resolution and the subsequent healing process. The early or repeated use of LLLT during the persistence of the inflammatory phase is therefore a central aspect in defining its clinical efficacy. The use of LLLT in a chronic inflammatory scenario will probably be inefficacious due to the recurrent, persistent noxious stimuli and the poor healing milieu. We believe LLLT does not create a novel *in vivo* scenario but aids in the re-establishment of homeostatic mechanisms often accelerating its natural trajectory.

LLLT in Gingivitis and Periodontitis

Gingivitis generally is not associated with significant pain and thus the LLLT studies have focused on its anti-inflammatory effects.¹ In one study, 10 female subjects refrained from all oral hygiene for 28 days in efforts to induce gingivitis. On the 21st and 24th days, the marginal gingival, buccal to the one of the lateral mandibular incisors, was irradiated for 4 minutes by LLLT. Results showed no statistical difference between the laser and control sites in regards to the level of plaque formation or gingival bleeding.⁶ In a more recent



study, patients were subjected to ten LLLT sessions with 670 nm laser to treat gingival inflammation. Clinical parameters such as the gingival index, plaque index and probing index at 1, 3 and 6 months after laser or conventional oral hygiene therapy were assessed. While both methods are successful at reducing gingivitis, the authors concluded that LLLT leads to better therapeutic results.⁷

Periodontitis, due to pathogenic bacterial species, often presents with bleeding and swelling of the gums, halitosis, gingival recession, and if untreated can lead to tooth loss. Qadri et al showed that treatment with LLLT along with routine oral hygiene measures reduced gingival inflammation.⁸ In a split mouth, double-blind study, patients with moderate chronic periodontitis were treated with a 635 nm InGaAlP diode laser at 4.5 J/cm² and a 820 nm GaAlAs diode laser at 8.75 J/cm² following basic periodontal treatments of scaling, root planing, and oral hygiene instructions. Following treatment, plaque and gingival indices as well as pocket depth were all reduced for the laser-treated side indicating a reduction in inflammation. Additionally, analyses of gingival crevicular fluid showed decrease Matrix Metalloproteinase-8 (MMP-8) in the laser treated side that has been linked directly to the severity of inflammation. Another study by the same group observed that the longer coherence length of an HeNe laser had a more pronounced biological effect than an InGaAlP diode laser on gingival inflammation.⁹

In a study performed to evaluate LLLT as an initial treatment for periodontitis, 30 subjects ranging from ages 20 to 60 who had periodontal pockets of at least 5 mm deep in each quadrant underwent treatment in which half of their mouth was treated with traditional scalpel and root planning (SRP) procedures and the other half was treated with for SRP and a Nd:YAP laser. The Nd:YAP laser was used at 10 W with a 200 nm fiber, time and total fluences were not reported. Evaluations were done at day 0 and day 90 based on the quantity of plaque, gingival inflammation, bleeding on probing (BOP), pocket probing depth (PPD) and clinical attachment level (CAL). The analysis showed that although both methods were equally effective in treating periodontitis, there was no difference in post-operative pain as reported by the patients.¹⁰ Similarly, another study used a He-Ne laser at 0.2 mW, 10 min for 8 days in the first 3 months to treat advanced chronic periodontitis (probing pocket depth over 5 mm) in 16 patients and evaluated supragingival plaque (PL), BOP, PPD and probing attachment level (PAL) were recorded at baseline and at 3, 6, 9, and 12 months. Their results also showed no additional clinical benefit with the He-Ne laser compared to conventional periodontal therapy.¹¹

Other studies, however, using diode laser treatment as a therapeutic method for periodontitis proved to be more promising. In a study done in Greece, 30 patients diagnosed with aggressive periodontitis in all four quadrants were initially evaluated for plaque index, BOP, PPD, and CAL at 2 weeks, 12 weeks and 6 months after treatment. Each quadrant was randomly assigned to either SRP alone, SRP with laser, laser alone or control. In this study, a 980 nm diode laser in continuous mode at 2 W was used. Plaque samples obtained six months after treatment showed a statistically significant reduction in total bacterial load, PPD and CAL in the SRP plus laser group compared to either treatment alone, however there was no difference in plaque index and BOP.¹² In a similar LLLT study using a diode laser (630–670 nm) in combination with SRP in 60 patients randomly sorted into three treatment groups where the first group received only SRP treatment for four days, the second group received SRP treatment for four days followed by five days of laser treatment while the third group received four days of SRP treatment followed by ten days of laser treatment. The clinical parameters measured included the plaque index, gingival index and BOP demonstrated a statistically significant improvement with both LLLT groups.¹³

While there appears to be some discrepancies in clinical outcomes of these studies, there appears to be a large variation in type and manner of lasers used

to perform these LLLT studies. Another important aspect is the varying clinical scenario and the nature of underlying patho-physiological processes in each of these diseased states that might need a more tailored therapeutic LLLT regimen for its clinical efficacy.

_LLLT and oral wound healing

A study by Amorim JC et al used LLLT on gingivectomy wounds in twenty patients with periodontal disease using the split mouth design. They used a 685 nm, 50 mW laser at and 4 J/cm².¹⁴ The authors observed a significant improvement in clinical parameters evaluated in the laser group at 21 and 28 days post surgery compared to the control sites. They postulated that the improvement likely derived from higher collagen production leading to a better remodeling of connective tissue and a reduction of the probing depth, the latter in turn aiding oral hygiene and synergistically contributing to limiting inflammation.

In a similar split mouth study design by Ozcelik et al. also showed that LLLT could enhanced epithelization and improved wound healing after gingivectomy and gingivoplasty procedures.¹⁵ Using a Mira-2-tone solution to visualize areas of epitheliazation, the investigators treated patients with a 588 nm diode laser at 120 mW and 4 J/cm² for seven days post surgery. They observed a significant decrease in the non-epithelialized surfaces following LLLT suggesting that besides stimulating collagen production, LLLT might facilitate fibroblast and keratinocyte motility, angiogenesis and growth factor release contributing to decreased inflammation and improved wound healing.

Two recent studies have looked at the physiological mechanism implicating Mast cell degranulation following LLLT. Sawasaki et al. and Silveira et al. used histological evaluation of hypertrophic gingival tissues (epulis fissuratum) irradiated with 670 nm AsGaAl laser at 8 J/cm². Both groups observed significantly increased degranulation indexes of mast cells in the irradiated samples than in the non-irradiated controls. This increase of degranulated mast cells and the resultant release of histamine would lead to increased inflammation. While this would seem counterintuitive to the anti-inflammatory effects of LLLT, it is suggested that hastening the inflammatory response by the degranulation of mast cells and, hence, heralding inflammatory resolution could in turn expedite the succeeding wound healing process. The intricate interplay following Mast cell degranulation by LLLT on monocyte-macrophage influx and fibroblast proliferation and collagen synthesis remains to be investigated.^{16, 17}

Our clinical study recruited 30 patients scheduled to undergo multiple extractions for complete dentures. Following institutional ethical approval and obtaining informed consent, two sites in each patient were used in our study, each patient acting as their own control. Following tooth extraction, one site was irradiated with a 10 mW, 904 nm GaAs laser in contact for 5 min for a total dose of 3 J/cm². A small soft tissue biopsy was obtained from the two sites and wound healing parameters like inflammatory infiltrate, vascularity, matrix synthesis-organization and TGF- β 1 expression were assessed using routine histopathology and immunostaining. We observed a better organized healing response in laser irradiated oral tissues and it is significant to note that the laser accelerated healing did not preclude any normal wound healing phase, demonstrating all the usual phases but seem to occur at a more rapid pace (Fig. 1). This accelerated laser healing correlated with an increased expression of TGF- β 1 immediately post laser irradiation. A major regulatory step in defining the physiological role of TGF- β *in vivo* is its activation from a naturally-secreted latent complex. Various physico-chemical modalities like heat, extreme pH, proteases and reactive oxygen species (ROS) that all induce a change in the conformation of the latent complex causing dissociation and, hence, activation of the TGF- β 1 dimer. Therefore, the ability to activate the latent TGF- β (LTGF- β 1) complex would provide a precise and natural manner of exploiting its role in various biological processes. The histological analysis from our clinical study suggested that a potential source of LTGF- β 1 could be the abundant degranulating platelets from the serum present in the early wound environment that are among known potent source of *in vivo* LTGF- β 1. We then used a cell-free system with serum and assessment by an isoform-specific ELISA and a reporter based (p3TP) assay system to demonstrate the ability of LLLT to activate the latent TGF-beta complexes *in vitro* at varying fluences from 10 sec (0.1 J/cm²) to 600 secs (6 J/cm²). We conclude that activation of latent TGF- β 1 by LLLT could contribute to the photobiomodulatory effects and promote oral wound healing.¹⁸

Potential mechanisms of LLLT on inflammation and healing

Despite the increased clinical popularity of LLLT due to its non-invasive, physiological mode of action, lack of information on the precise molecular mechanisms and well-controlled clinical trials have prevented LLLT from being more widely accepted as a routine treatment option. LLLT broadly utilizes wavelengths in the red and near-infrared

spectrum to change intra-cellular photoreceptors such as endogenous growth factor complexes, porphyrins, flavins, surface transmembrane receptors and cytochrome c oxidase in the respiratory chain. To broadly categorize these intermediates, we outline a putative hierarchical level of interaction from the literature in the context of the LLLT and cell-tissue compartments (Figure 2).

Our work with a latent growth factor complex Transforming Growth Factor- β (TGF- β), a multifaceted cytokine, and LLLT has unraveled one such molecular pathway providing an attractive molecular mechanism for photobiomodulation.¹⁸ TGF- β plays key roles in biological processes like development, wound healing and malignancies and has a myriad range of effects based on its spatio-temporal expression on a wide range of cells from epithelial keratinocytes to fibroblasts, endothelial, neural and inflammatory cells. The intricate role of TGF- β on inflammatory cell subsets displays a fascinating dichotomy between its immune-suppressor versus immune surveillance functions and is an ongoing area of intense lab investigation. Interestingly, although primarily identified as a pro-matrix, fibrosis promoting wound cytokine, TGF- β transgenic mice have shown a startling variety of healing phenotypes further indicating its diverse roles on epithelial migration and survival, chemotaxis of monocytes-macrophages and mechanical homeostasis of the matrix milieu.¹⁹ The activation of such a multifaceted growth factor by LLLT with its broad effects on various component of inflammatory-healing process could 'short-circuit' or 'kick-start' the complex cascade of biological events effecting the eventual healing and regenerative outcomes. Clinically, one of the most attractive features of exploiting this mechanism is the activation of endogenous levels of TGF- β and thus, potentially only gently nudging the natural physiological process along, without a major perturbation of the biological system as seen with addition of exogenous factors. We speculate that there might be more such latent molecular complexes amenable to low power laser modulation in the inflammatory and early wounding scenarios. Our present research has established that the photophysical and photochemical events can correlate with large magnitudes of laser fluences. In contrast, the photobiological events are tightly limited within a narrower range of laser fluences through an unknown biological regulatory mechanism. This mechanism along with potential chromophores, wavelength and fluence parameters affecting the latent TGF- β activation process by LLLT for oral wound healing and other biological applications are our present focus of research.

Conclusions and future challenges

It might be prudent to point out that irrespective of the precise molecular intermediate being activated, the high energy laser densities have a deleterious effect in the realm of photodynamic therapy as has been well documented. Akin to the parallels drawn to the biphasic mode of the Arndt-Schultz therapeutic dose curve, careful use of a therapeutic LLLT dose regimen will be key to its successful clinical usage.²⁰ Another significant aspect in this field of research is the attention to standardization. As evident from the studies listed here, we observe a wide variation in laser parameters such as delivery modes, energy density and wavelengths. Questions about the significance of coherence, collimation or pulsing, optimal time and distance remain to be elucidated and must be carefully documented in each study. Finally, the clinical scenario where LLLT is being attempted should be of prime consideration.

The quest for a universal 'therapeutic window' (wavelength and fluence) for LLLT is probably a myth and treatment parameters will range with its application and individual patient scenarios. We strongly feel the attention to these details in future research trials, especially clinical studies, would be the key to establishing stringent and precise therapeutic regimens. A few of these parameters that we feel are most promising as evident from our own work and the published literature are wavelengths in the red and near-infra-red (800 to 980 nm) and fluences ranging from less than 10 J/cm² with a median at 3 J/cm² while the lower end of this range is yet unclear. The use of a split mouth design, acknowledging the limitation of systemic spill over effects, is probably the best clinical study design as it accounts for the local and regional factors affecting the wound healing process. In summary, LLLT offers an attractive, painless and non-invasive therapeutic avenue to modulate inflammation for oral applications. Nevertheless, a great deal of research on the mechanism of LLLT action remains to be investigated in order to optimize it as a routine physician tool.

References

- Walsh, L.J., The current status of low level laser therapy in dentistry. Part 1. Soft tissue applications. *Aust Dent J*, 1997. 42(4): p. 247–54.
- Chow, R.T., et al., Efficacy of low-level laser therapy in the management of neck pain: a systematic review and meta-analysis of randomised placebo or active-treatment controlled trials. *Lancet*, 2009. 374(9705): p. 1897–908.
- Nanami, T., et al., Clinical applications and basic studies of laser in dentistry and oral surgery. *Keio J Med*, 1993. 42(4): p. 199–201.
- Kumar, V., Abbas A and Fausto, N *Cotran and Robbins Pathologic Basis of Disease*. 7th ed. 2005: Elsevier Inc. 1525.
- Morgan, T., *Regeneration*. 1901, New York: Macmillan Co.
- Ryden, H., et al., Effect of low level energy laser irradiation on gingival inflammation. *Swed Dent J*, 1994. 18(1–2): p. 35–41.
- Pejicic, A., et al., The Effects of Low Level Laser Irradiation on Gingival Inflammation. *Photomed Laser Surg*, 2009.
- Qadri, T., et al., The short-term effects of low-level lasers as adjunct therapy in the treatment of periodontal inflammation. *J Clin Periodontol*, 2005. 32(7): p. 714–9.
- Qadri, T., et al., The importance of coherence length in laser phototherapy of gingival inflammation: a pilot study. *Lasers Med Sci*, 2007. 22(4): p. 245–51.
- Ambrosini, P., et al., Clinical and microbiological evaluation of the effectiveness of the Nd:YAP laser for the initial treatment of adult periodontitis. A randomized controlled study. *J Clin Periodontol*, 2005. 32(6): p. 670–6.
- Lai, S.M., et al., Clinical and radiographic investigation of the adjunctive effects of a low-power He-Ne laser in the treatment of moderate to advanced periodontal disease: a pilot study. *Photomed Laser Surg*, 2009. 27(2): p. 287–93.
- Kamma, J.J., V.G. Vasdekis, and G.E. Romanos, The Effect of Diode Laser (980 nm) Treatment on Aggressive Periodontitis: Evaluation of Microbial and Clinical Parameters. *Photomed Laser Surg*, 2009.
- Angelov, N., et al., Periodontal treatment with a low-level diode laser: clinical findings. *Gen Dent*, 2009. 57(5): p. 510–3.
- Amorim, J.C., et al., Clinical study of the gingiva healing after gingivectomy and low-level laser therapy. *Photomed Laser Surg*, 2006. 24(5): p. 588–94.
- Ozcelik, O., et al., Improved wound healing by low-level laser irradiation after gingivectomy operations: a controlled clinical pilot study. *J Clin Periodontol*, 2008. 35(3): p. 250–4.
- Sawasaki, I., et al., Effect of low-intensity laser therapy on mast cell degranulation in human oral mucosa. *Lasers Med Sci*, 2009. 24(1): p. 113–6.
- Silveira, L.B., et al., Investigation of mast cells in human gingiva following low-intensity laser irradiation. *Photomed Laser Surg*, 2008. 26(4): p. 315–21.
- Arany, P.R., et al., Activation of latent TGF-beta1 by low-power laser in vitro correlates with increased TGF-beta1 levels in laser-enhanced oral wound healing. *Wound Repair Regen*, 2007. 15(6): p. 866–74.
- Arany, P.R., et al., Smad3 deficiency alters key structural elements of the extracellular matrix and mechanotransduction of wound closure. *Proc Natl Acad Sci USA*, 2006. 103(24): p. 9250–5.
- Huang, Y.Y., et al., Biphasic dose response in low level light therapy. *Dose Response*, 2009. 7(4): p. 358–83.

_contact

laser


Praveen Arany BDS, MDS

Harvard University, Cambridge MA 02138
arany@fas.harvard.edu

Introducing iLase™

The next
instrument
for your tray.

Powerful.
Affordable.
Beyond Portable.



Actual Size

iLase™ gives Biolase the most complete family of dental laser solutions, to match the needs of you and your patients perfectly as you expand your laser applications:



iLase™

The Personal Laser, for everyday soft-tissue procedures.



ezlase™

The Total Diode Laser Solution, including whitening and pain relief.



waterlase™ MD TURBO™

Best-of class soft and hard tissue laser for common and advanced restorative, periodontics, endodontics, cosmetic, surgical and pediatric procedures.

© 2010 | www.Biolase.com | Call Henry Schein Germany +49 0180 140 0044 or Biolase at +1 949 361 1200 | CE

An Exclusive
Partner of **HENRY SCHEIN®**
DENTAL

The Biolase
Total Solution



Clinical
R+D



Industry Leading
Technology



Training +
Certification



Practice
Integration



Service +
Support

BIOLASE

Lasers in dental Traumatology

Author_Claudia Caprioglio, Italy

_Introduction

Dental traumas are frequent in children. They can be complex events and sometimes real emergencies. Traumatic injuries involve all the branches of dentistry (endodontics, restorative, periodontics, oral surgery, orthodontics) so that traumatology can be considered a multidisciplinary discipline.

Laser technology lends itself well to the problems encountered in dental traumatology (from simple crown fractures, to replantation, root fractures and different types of luxation injury) because it is able to replace or complete, and also to simplify, traditional dental procedures. It contributes to the reduction of post-operative sensitivity through a minimally invasive and highly selective technique that furthermore has a positive psychological impact for the patients. In addition it is an alternative technique for non vital bleaching procedure, to solve post-traumatic aesthetic problems.

Working without anaesthesia through laser induced analgesia is another challenge. Laser-as-

sisted therapies drastically reduce the need for post-operative medications compared with conventional procedures.

The international literature doesn't report extensive references on laser assisted dental trauma therapy and there are not well-coded guidelines for specific laser application in this clinical field.

Even though this challenging technology is ideal for trauma-related problems, the existing dental trauma guidelines and protocols should nevertheless be widely consulted (Andreasen et al. 2007).

_Epidemiology and Prevention

Dental traumas are sustained mainly during play (56 %), sports activities (21 %), road accidents (11 %) or as a result of acts of violence (12 %), which continue to be underestimated. The high incidence of dental trauma is demonstrated, in the literature, by large-scale American studies which show that one in six adolescent boys are twice as likely as girls to suffer a dental trauma and the type of lesion varies depending on the age of the subject; in young age groups the incidence

Figs. 1a & b _Complicated enamel-dentin crown fracture of 1.2, with complete detachment of the palatal tooth fragment.

(Courtesy of Prof R. Grandini)

Figs. 2a & b _The tooth fragment. A partial pulpotomy is performed and dental margins are treated by using an Erbium laser.

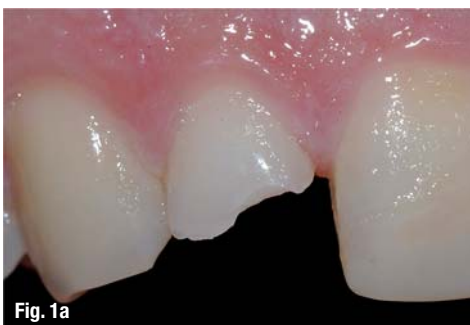

Fig. 1a

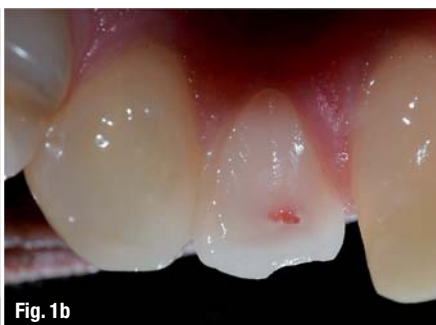

Fig. 1b

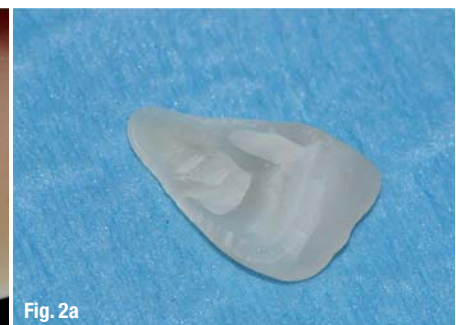

Fig. 2a

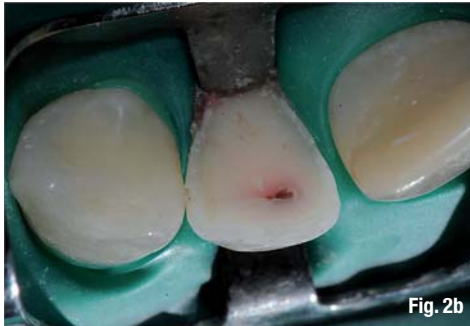

Fig. 2b

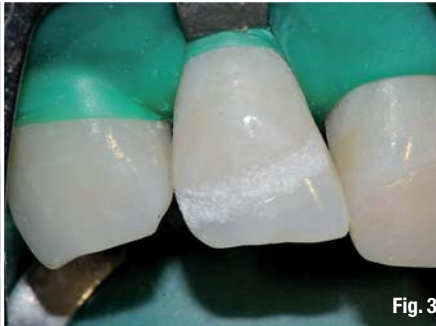

Fig. 3

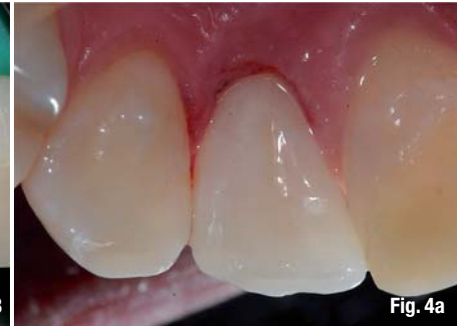

Fig. 4a

is usually equally high in both sexes (Glendor 2008).

Around 20 % of children suffer a traumatic injury to their primary teeth and over 15 % to their permanent teeth (Andreasen et al. 2007). The teeth most frequently affected, both in primary and in permanent dentition, are the upper central incisors (50 %) and the upper lateral incisors (30 %). Paediatricians and dentists need to draw attention to the importance of prevention in this field.

These injuries, together with tooth decay, are the most frequent pathologies encountered in paediatric dentistry: a specific training, adequate continuing education conventions, high level of knowledge and updated guidelines for the management of traumatic dental injuries are needed.

Classification

In 1978 the World Health Organisation created a classification of traumatic dental injuries. In 1992, this classification, revised and extended, was published.

The following classification includes injuries to the teeth, supporting structures, gingival and oral mucosa. It is applicable both to primary and permanent dentition (Table I) (Andreasen et al. 2007).

Lasers application in dental traumatology

Careful dental history report and clinical examination are the basis of an accurate diagnosis and in order to save time and to be exhaustive, specific standardised charts are recommended. Every phase, both pre- and post-treatment, must be fully documented through radiographic and photographic examinations and pulp vitality tests, making easier and quicker to monitor the evolution of the clinical case at subsequent visits and to compile a full medico-legal report, which is often required during and at the end of dental trauma treatment.

In dental trauma pulp testing is a controversial issue; different tests have been proposed: the laser doppler flowmetry (LDF) is an experimental value method to diagnose the state of pulp revascularization; however at this time this method cannot be of general use but it looks promising.

Laser technology is an advancement that fits into the two concepts of tooth preservation (MICRODENTISTRY) and prevention.

The use of lasers in many medical fields has become the standard treatment; this is not the case of dental traumatic injuries but the author is confident that these technologies will offer better quality treatments and will make our profession more enjoyable.

There are different types of lasers available to treat dental injuries. The properties of each type make them suitable for different tissues and procedures; each wavelength has a particular use determined by its specific tissue-interaction and affinities.

Due to their versatility two types of lasers are more frequently used by paediatric dentists in dental traumatic injuries: Er:YAG and Er,Cr:YSGG since they can be used in hard and soft tissues (Gutknecht et al. 2005). Also other technologies are indicated: the KTP, the Nd:YAG laser, the Diode laser and the CO₂ (Table II).

No randomized clinical studies exist concerning traumatic dental injuries and laser-assisted therapy, in this article the author describes its own clinical experience and aims to stimulate more extensive scientific research.

Traumatic injuries to hard dental tissue and the pulp

Uncomplicated and complicated crown fracture

This type of fracture involves the enamel and dentin and expose the pulp (if complicated).

Fig. 3 The tooth and the fragment are acid-etched and reattached by using a flow composite resin to better adaption. Reinforcing the labial aspect of the fracture site: preparation of a facial bevel by using an Er:YAG laser.

Figs. 4a & b Final appearance (palatal view) after rubber dam removal. Clinical appearance (labial view) after 6 months.

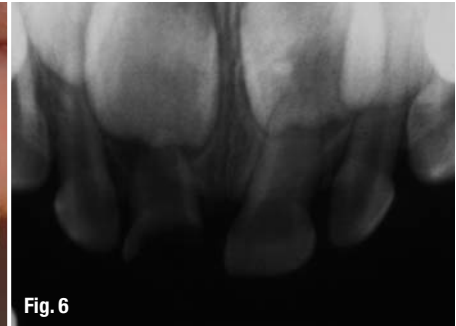
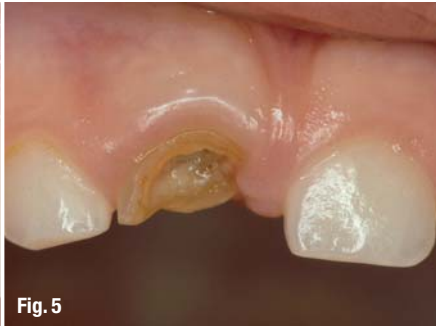
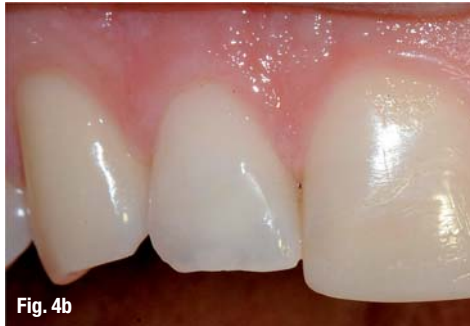
Fig. 5 Patient aged 4.2 years. Complicated crown fracture. Three months have elapsed since the trauma occurred. Gingival hypertrophy of 5.1 covers the fracture margin.

Fig. 6 X-ray examination.

The examination should be proceeded by cleaning the injured area and careful search for pulp exposure.

Take an X-ray, perform vitality tests, sometimes there is accompanying damage to the soft tissue (tongue and lips: look for tooth fragments).

The use of modern bonding agents and laser technology has changed considerably our clinical practice. Erbium lasers can guarantee good results reducing post-operative discomfort and sensitivity as well as providing minimally invasive dentistry (Genovese et al. 2008).

Erbium lasers are indicated for the treatment of crown fractures, both complicated and uncomplicated, and whether or not the tooth fragment is available. In the first decade of research, various authors studied the parameters and variables for using the Erbium laser, evaluating the morphological effects on hard and pulp tissues: the effects of energy density, pulse repetition rate, and air-water jet were reported: the results obtained with the laser were the same as those achieved with orthophosphoric acid (Moritz et al. 2006).

Various studies and clinical reports showed how the laser, used by numerous operators as an alternative to rotary instruments in paediatric restorative dentistry, brings an added measure of safety even when used in the treatment of very young children, a new possibility for minimal interventions (Kornblit et al. 2008), and overall better acceptance compared to traditional techniques (Keller et al. 1998).

Laser cavity preparation is closely related to different variables. Fluence, power density and pulse length, but also laser angulation, focus mode, the amount of air-water jet are all factors that can cause substructural damage to the dentin. A final conditioning at low wattage both on dentin and enamel is advisable. Acid etching

on lased dentin and enamel produces uniform results, eliminating the thin layer of substructural damage, exposing the collagen fibers and creating a substrate for the formation of the hybrid layer; acid etching modifies the Silverstone enamel class 2 and 3 into class 1, allowing better composite adaptation.

The action of Erbium lasers on hard tissues and pulp is extremely precise: the surface treated are cleansed and sterilized.

Temperature increase during treatment is minimal and may decrease while working with water-spray cooling.

Due to bactericidal capacities, no production of smear layer, opening of dentinal tubules, allowing hybrid layer formation these lasers can be used to perform the hole procedure: excavation, coagulation of the exposed pulps (if needed), pulpotomy or pulpectomy (Figs. 1–4).

Another feature is the very superficial thermal effect, therefore the necrotic zone is likely to be very small.

This kind of injury exposes a large number of dentinal tubules: 1 mm² of dentin exposes 20.000 to 45.000 dentinal tubules.

They constitute a pathway for bacteria, thermal and chemical irritants which can determine pulpal inflammation: Erbium lasers are effective for removing organic material, smear layer and can achieve a bactericidal effect but the Nd:YAG laser and the diode laser can provide an effective decontamination action as well.

The Erbium laser's fusion and sealing capacity of the dentinal tubules (depth of up to 4µm) can result in a reduction of the tissues's permeability to fluids, thus reducing dentinal hypersensitivity.

Another structural change induced by these lasers is the phenomenon of vitrification, this can

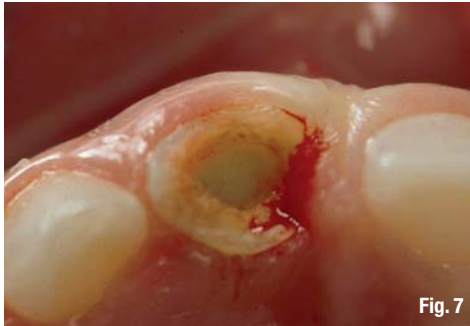


Fig. 7

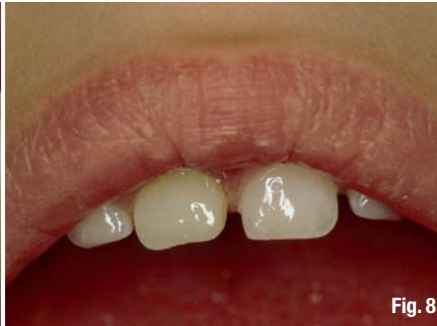

Fig. 8

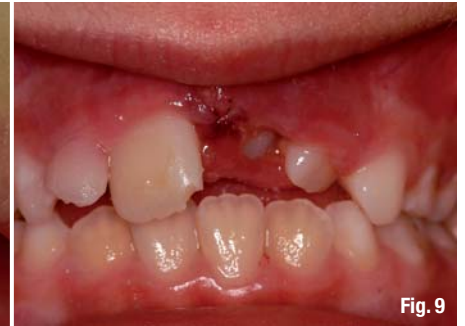

Fig. 9

be very useful because it increases hard tissue resistance to acid remineralization, dental hardness and dental abrasion.

The Nd:YAG and the diode laser have a beneficial therapeutic action in direct traumas.

These lasers, exploiting their photothermic effect, can be used to treat both pulp and dentin.

They can be applied:

- _to treat dentinal hypersensitivity
- _to perform indirect or direct pulp capping
- _to remove endodontic material
- _to treat infected root canals.

The CO₂ laser has a purely thermal effect on the tissue, 90–95 % of the energy it delivers to tissue is absorbed by a fine tissue layer and transformed into heat.

It's indicated for:

- _pulp capping (following dentin fracture)
- _pulpotomy (following crown or root-crown fractures)
- _surgical cutting (e.g. to remove a tooth fragment) (Figs. 3, 4, 5 & 15).

Few studies that investigate laser performance in maintaining pulp tissue vitality are indexed in the PubMed library. Different laser wavelengths and parameters related to the different devices were used. The common delineator was the low laser energy applied (from 0.5 to 1.0 W), delivered in defocused mode, preferably using low repetition rate or superpulsed mode.

Pulpotomy is a very common technique in primary teeth: although pulpotomy with formocresol (1 : 5 dilution) is used with success, there is a tendency today to seek alternative techniques, considering the carcinogenic and mutagenic potential of this formaldehyde component. Lasers

have been proposed for pulpotomy, and study (Pescheck et al. 2002) compared favourably CO₂ laser treatment to formocresol for pulpotomy in primary teeth, with a survival rate from 91 % to 98 %. Other studies reported that the superpulsed mode produced a markedly higher success rate than the continuous wave mode.

During this procedure, attention must be given to the energy applied. Low energy delivered in defocused mode and pulse or superpulsed mode guarantees good superficial coagulation and good decontamination to maintain the vitality of the residual pulp in pulp capping application (Olivi et al. 2007).

Particular care must be taken with the application of laser energy into primary root canals for root canal cleaning and disinfecting, due to the characteristic anatomy of the apex and to the penetration depth of near infrared lasers (Soares et al. 2008).

Crown-fracture and root fracture

Fractures healing cannot be expected in crown-fractures, in contrast to root fractures where the fracture is located entirely within the alveolus.

The coronal fragment is usually removed and the treatment should be focused on the possibility of using the remaining fragment.

On superficial fracture without pulp exposure it's suggested to remove loose fragments, smoothing the rough subgingival fracture surface and covering the exposed dentin.

When the coronal fragment comprises 1/3 or less of the clinical root, after the removal of loose fragments, a pulpectomy and root canal filling is advocated.

The fracture surface has to be exposed with a gingivectomy or osteotomy and subsequently a prosthetic restoration (Figs. 5–8).

Fig. 7_Gingivoplasty is performed by using an Erbium laser, without local anesthesia. The root canal is filled with calcium hydroxide. Dental margins are treated with an Erbium laser (minimal intervention).

Fig. 8_The tooth 5.1 is restored with composite. Clinical appearance after finishing and polishing phases.

Fig. 9_Patient aged 7.8 years. Severe intrusive luxation of 2.1 which also presents a crown fracture. Subluxation and enamel fracture of 1.1.

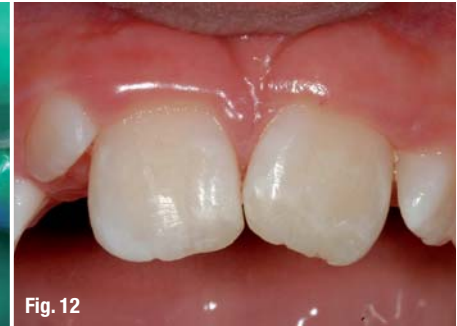
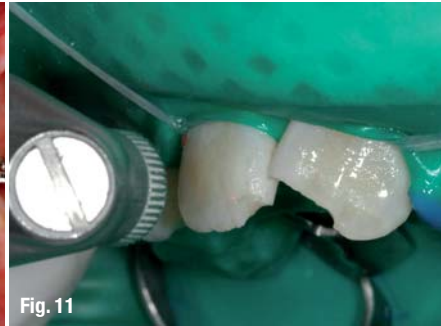
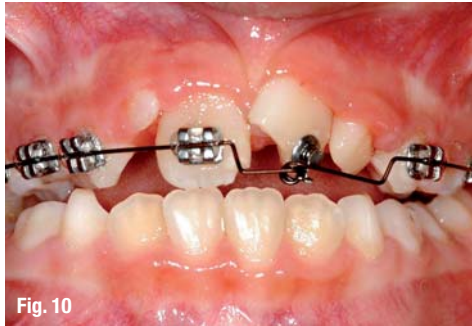Fig. 10_Before orthodontic extrusion (using 0.016-inch Australian wire for 2 weeks) the periodontal tissues were treated (decontaminated) with Nd:YAG laser.

Fig. 11_Once 1.1 and 2.1 had been repositioned, they were restored with an Er:YAG laser.

Fig. 12_Final clinical appearance.

1. Traumatic Injuries to hard dental tissue and pulp

crown infraction
uncomplicated crown fracture
complicated crown fracture
uncomplicated crown-root fracture
complicated crown-root fracture
root fracture: _apical third
 _middle third
 _coronal third

2. Traumatic Injuries to the periodontal tissues

conclusion
subluxation
extrusive luxation
lateral luxation
intrusive luxation
avulsion

3. Injuries to the supporting bone

not described as they are related to maxillo-facial surgery

4. Injuries to gingiva or oral mucosa

laceration of gingival or oral mucosa
contusion of gingival or oral mucosa
abrasion of gingival or oral mucosa

Tables 1_1.–4. Classification of traumatic injuries.

Hard and soft tissues	Er:YAG 2,940 Er,Cr:YSGG 2,780
Soft tissues	KTP 532 Argon Diode 810, 940, 980 Nd:YAG 1,064 CO ₂ 10,600
Low Level Laser	Elium neon 635 Diode 810

Table 2_Laser classification hard and soft tissues.

Laser-assisted therapy can be useful not only for the coronal fragment restoration but also for supporting tissue surgery and endodontic therapy (gingivoplastic, gingivectomy, crown lengthening) (Sarver & Yanosky, 2005).

Lasers are effectively used in these soft tissue procedures; they can easily incise, cut, ablate, re-shape the soft tissue with no or minimal bleeding, less pain and have a bacteria killing effect.

In these clinical events deeply-penetrating type of lasers (Nd:YAG and diode-lasers) show a thicker coagulation layer than superficially-absorbed ones (CO₂-Erbium lasers).

The technique used with the first ones is similar to removing the tissue with electrosurgery.

Treatment factors as optimal repositioning and a flexible splinting have a positive influence upon healing, such as an immature root formation, lower age, less displacement of the coronal fragment.

As splint has to be kept in situ for at least several weeks an aesthetic orthodontic splint can be used (ceramic brackets).

Debonding procedures can be atraumatic when using a Nd:YAG laser.

Intra-pulpal temperature rises less than using conventional high-low speed instruments for orthodontic brackets removal.

Therefore laser-assisted procedure is safer, quicker and more comfortable (Figs. 3, 4, 5 & 15).

_Traumatic injuries to the periodontal tissues

Indirect traumas are lesions to the supporting structures, in particular the alveolar bone, the periodontum, the gingiva, the ligaments, the fraenum and the lips.

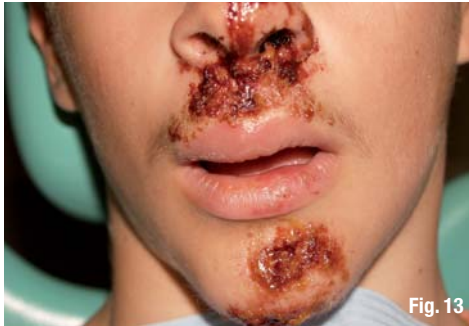

Fig. 13

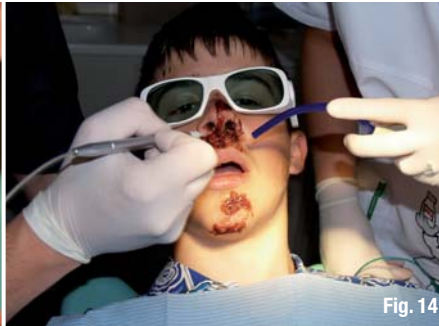

Fig. 14

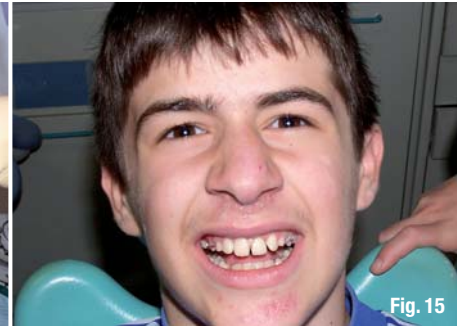

Fig. 15

The Nd:YAG laser and the diode laser have a beneficial therapeutic action in traumatic injuries to the periodontal tissues.

These lasers have a decontaminating effect, as well as a biostimulating and reparative effect, with no suture, good and rapid healing by second intention and minor discomfort for the patient.

They are useful for:

- _decontamination of the alveolous following a traumatic avulsion
- _treatment of a periodontal defect following a dental luxation or sub-luxation
- _microgingival surgery for the treatment of a traumatic dental injury
- _gingivectomy and gingivoplasty
- _surgical cutting (e.g. to remove a tooth fragment) (Martens 2003).

Finally they also exert an appreciable analgesic effect both on hard and soft tissues.

In oral surgery both the diode laser and the Nd:YAG laser are used, the former is used in continuous or pulsed mode, the latter always in pulsed mode but with different pulse amplitudes.

The increase in temperature that these lasers produce has an excellent thermostatic effect. In all luxation injuries the bactericidal effect and detoxification of lasers (Er:YAG, Nd:YAG, diode and argon lasers) to provide favorable conditions for the attachment of periodontal tissue can be achieved (Figs. 9, 10, 11, 12).

Laser decontamination and/or laser photobiomodulation can be required for tissue repair (cutaneous and subcutaneous tissue irradiation) and for pain relief. It has been reported that photodynamic changes may occur in several physiologic processes: further clinical studies are necessary to establish suitable irradiation conditions. Nd:YAG laser, diode laser and KTP can also be alternative technique for non vital bleaching procedure.

Lasers are increasingly being used for gingival dental surgery and to replace the use of electrosurgery. A study to evaluate and compare the temperature rise in hard and soft tissue when using CO₂ and diode laser and electrosurgery units for soft-tissue dental surgery became to the conclusion that both procedures are considered soft to local tissue in terms of temperature rise if provided guide-lines are used. The CO₂ laser caused more heat in the gingival.

The CO₂ is specifically used for surgical cutting (e.g. to remove a tooth fragment from lip or oral mucosa) (Figs. 3, 4, 5).

Injuries to developing teeth

Disorders of permanent teeth caused by traumatic injury to primary teeth can be divided into two groups according to the type of dental trauma (direct traumatic impact or indirect lesion). The prevalence of these disturbances ranges from 12 to 69 % depending on the study; avulsion and intrusive luxation are injuries associated with very high frequencies of developmental complications.

Laser assisted therapy can be useful in:

- _enamel discolouration: treatable with Erbium laser
- _circular enamel hypoplasia: treatable with Erbium laser
- _ectopic eruption: treatable with surgical exposure or soft-tissue laser surgeries (all the wavelengths of the near-medium and far infrared spectrum of light).

Low Level Laser Therapy or Soft Laser Therapy (LLLT)

A non-traumatic introduction to dentistry can be represented by low level laser therapy or soft laser therapy.

There is a large body of literature on this particular topic even though, methodologically and

Fig. 13_Patient aged 16.2 years. Avulsion of 2.1. Deep abrasion of upper lip oral mucosa, nose and chin. (Courtesy of Dr. V. Lazzarini)

Fig. 14_The soft tissue injuries are treated every day for 7 days with a Nd:YAG laser.

Fig. 15_Final clinical outcome of the face and smile. A removable orthodontic space maintainer is placed to restore temporarily the frontal tooth loss.

in terms of doses, there is still considerable difference of opinion.

Even though helium-neon lasers were initially used ($632.8 \text{ nm} = \lambda$), the ones in use today are the semiconductor diode type (830 nm or $635 \text{ nm} = \lambda$).

The water absorption coefficient of the wavelengths used for this purpose is reduced and the beams are able to penetrate both soft and hard tissues from a distance of 3 to 15 mm.

LLLT has a number of applications in dentistry; both at soft tissue level (biostimulation of lesions, aphthous stomatitis, herpetic lesions, mucositis, pulpotomy) and neurally (analgesia, neural regeneration, temporo-mandibular pain, post-surgical pain, orthodontic pain).

Between 1 and 3 days after biostimulation, it is already possible to observe a considerable reduction of swelling and an acceleration of the epithelisation and collagen deposition phase.

The clinical importance of this acceleration of the reparative processes is considerable, especially when the general defense system of the patient is compromised (young patients but also older patients insulin dependent diabetes, valvar dysfunction or malformations, history of endocarditis, patients with prosthetic cardiac valves, cardiac surgical reconstruction).

In short, LLLT stimulates tissue repair processes and, influencing a large number of cell systems, can also have a series of benefits on inflammatory mechanism. (Antalgic—Biostimulating—Anti-inflammatory effects) (Nascimento et al. 2004, Weber et al. 2006) (Figs. 13, 14, 15).

These effects are specific to some wavelengths and they cannot be obtained with non-polarised and non-coherent light sources, such as LEDs.

The author hopes that the pursuit of these new horizons might lead to the definition of protocols containing more specific indications as regards times, doses and sites of application.

LLLT has main indication in dental traumatology (Caprioglio C & Caprioglio A 2010, Tuner & Hode 2004): Brief analgesic effect in the mucosa allowing painless injection with a needle or treatment without anaesthesia.

Direct application into the exposed cavity of a deciduous tooth can be used for pain reduction;

also the trans-mucosal irradiation in the apical portion and a reticular irradiation to the cervical area of the tooth has an analgesic effect.

In post-traumatic treatment after lip and front-tooth trauma to reduce swelling and pain.

Post-endodontic therapy, after pulp-capping, after apexogenesis or apicification.

- _Orthodontic movements.
- _TMJ disorders and pain.
- _Traumatic mucosal lesions (ulcers), aphthous or herpetic lesions.

Knowing that the analgesic effect of light at $800\text{--}900 \text{ nm}$ is $30 \text{ joules} \times \text{cm}^2$ and the biostimulating effect is $50 \text{ joules} \times \text{cm}^2$, it becomes possible to develop operating protocols that can be compared, standardised and repeated (Benedicenti 2005).

Conclusions

Lasers are very effective not only in paediatric dentistry but also in traumatic dental injuries. They enable optimal preventive, interceptive, and minimally invasive interventions for both hard and soft tissue procedures. It is important for the professional to understand the physical characteristics of the different laser wavelengths and their interaction with the biological tissues to ensure that they are used in a safe way, in order to provide the benefits of this technology.

Therefore a period of education and training is highly recommended before applying this technology especially to paediatric patients.

Editorial note: The literature list can be requested from the editorial office.

_contact	laser
Claudia Caprioglio Doctor Dental Science Post-graduate in Orthodontics Visiting professor University of Parma (Italy) Director Centro Internazionale di Aggiornamento Odontoiatrico (C.I.A.O. s.r.l.) Via San Zeno 1, 27100 Pavia, Italy E-mail: ac.caprioglio@tin.it	



Effective. Practical. Affordable. World Class Lasers.

*The Fine Art of
Laser Dentistry*



Picasso
IS #1



"recognized leader,
**superior
products,**
that every dentist can afford."

Larry Rosenthal, DDS
Director Aesthetic
Advantage
New York, NY



"easy to use,
**revolutionary,
affordable!"**

George Freedman, DDS
International Lecturer, Author
Toronto, Canada



"impressive,
every dentist
should have one."

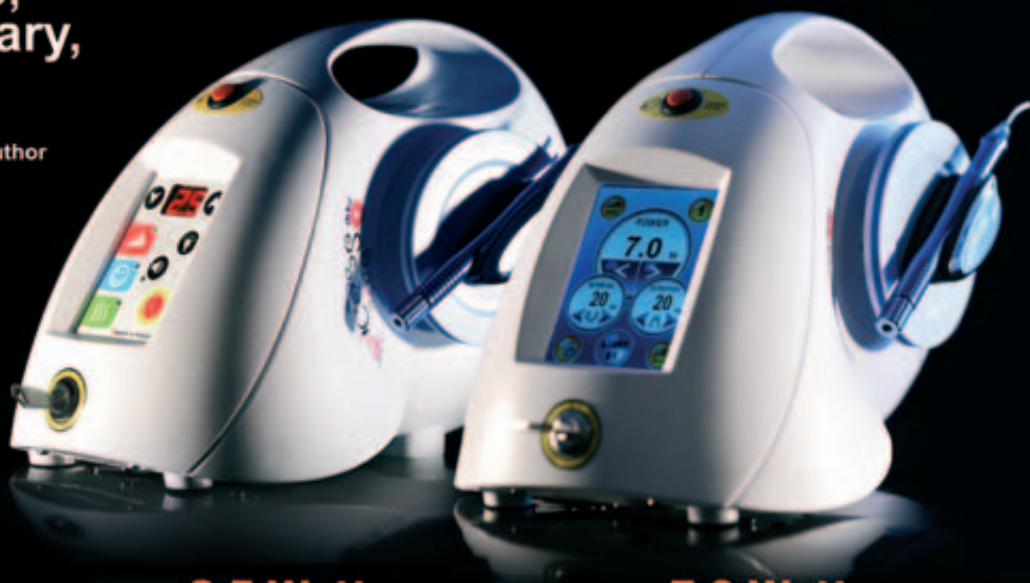Ross Nash, DDS
Nash Institute
Charlotte, NC

Picasso
st Lite

Picasso

2 Year
Warranty ▶ **\$2,495**

3 Year
Warranty ▶ **\$4,995**



2.5 Watts
3 Custom Presets
Continuous/Pulse Modes
Universal Icon Menu

7.0 Watts
8 Custom Presets
Continuous/Pulse Modes
Multi-Lingual Menu

Get out of the
dark ages and
**laser focus
your practice**



▶ the only lasers to offer
STRIPPABLE FIBERS OR DISPOSABLE TIPS

T7 & Mv2-2010



AMD LASERS™, LLC.
www.amdlasers.com

7405 Westfield Blvd.
Indianapolis, IN 46240, USA

866. **WWW.AMDL**
866. **999.2635**

TEL: 317.202.9530
FAX: 678.868.4108
sales@amdlasers.com

FDA CE
0197
ISO 13485

Electrotome and Er:YAG laser

A comparison of the temperature changes in subperiosteal bone and the risk for bone damage during frenectomies

Authors_Dr Anastasios Manos & Prof Nicolaos Parisis, Greece

_Abstract

The aim of this study is to investigate the temperature changes in subperiosteal bone and the risk for bone damage during frenectomies with electrotome and Er:YAG laser.

Thirty parts of sheep lower jaws with the frenulum preserved were used in the study. Electrodes from thermocouples were inserted in the subperiosteal bone tissue in three places, coronal, middle, apical. A water bath with 37 °C was used to stabilize the start temperature in 36.8–37.2 °C. The sheep jaw were stabilized in gypsum inside the water bath with the frenulum part be extended out of the water. The sheep jaws were divided in three groups with 10 parts in every group. In

these jaw parts frenectomies were performed using electrotome and Er:YAG laser with water spray and without water spray. The results of temperature changes, the maximum temperature, the irradiation time, the cooling time and the time of the temperature staying above the 47 °C were registered and statistically analyzed.

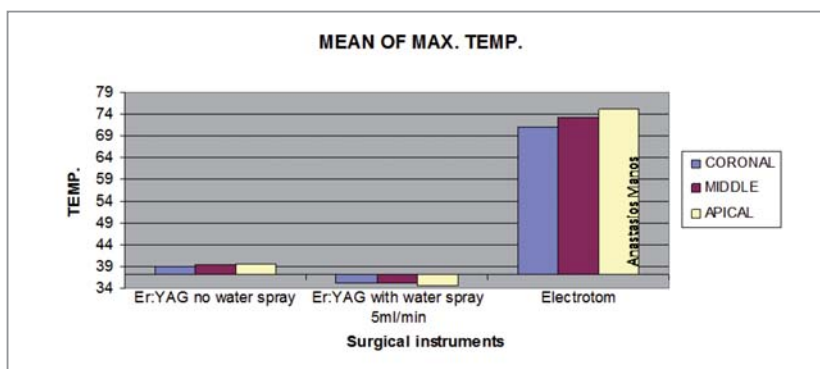
The results of the temperature changes have shown that the electrotome is creating a much higher temperature elevation in subperiosteal tissues (up to 80.3 °C) than the Er:YAG laser without the water spray (up to 40.3 °C) while the use of the water spray in Er:YAG laser creates a maximum temperature drop down to 34.1 °C.

As conclusion we can say that in frenectomies with Er:YAG laser, there are much less thermal changes to the subperiosteal bone tissues than with electrotome and therefore the risk of thermal damage with Er:YAG in subperiosteal bone tissue compare to the electrotome is minimal.

_Introduction

The temperature rising and its side effects is always a problem in the surgical procedures when an electronic surgical instrument (e.g., electrotome, laser) it is used instead of the scalpel. Electric or electromagnetic energy can spread in deeper tissues and create side effects which could influence the healing process of the tissues or the prognosis of our therapy. Since 1930's electrotome is used in different surgical procedures and since 25 years ago the laser started to be used in similar surgical procedures. Although different investigators have looked on the temperature rising in the surface of the treated tissues little has been done in investigating the temperature fluctuations in the deeper

Fig. 1 & Tab. 1_The mean of the maximum temperature.



	Coronal	Middle	Apical
Er:YAG No Water	38.93	39.24	39.61
Er:YAG No Water	35.25	35.01	34.57
Electrotom	71.01	73.06	75.02
95% Confidence Interval			

parts of the tissues. This research project is trying to investigate the temperature changes in the subperiosteal bone tissue during frenectomies in sheep jaws with an Er:YAG laser and an electrotome.

Materials and methods

An electrotome and an Er:YAG laser was used as surgical instruments in this study. These two electronic surgical instruments were used as a scalpel for performing frenectomies in sheep jaws. These frenectomies were performed in order to investigate the temperature fluctuations in the subperiosteal bone under the frenulum.

30 parts of lower sheep jaw with preserved frenulum were used in the study. Electrodes from thermocouples were inserted in the subperiosteal bone tissue in three different places 5 mm away from each other in the vertical dimension (coronal—middle—apical) in order to register the temperature changes in the subperiosteal bone during the frenectomy procedures. The sheep jaws were stabilized in a gypsum base in a water bath. The water bath was used in order to simulate the physiological temperature of the living tissues of 37 °C. The preserved frenulum, with the electrodes of the thermocouples was kept out of the water in order to avoid any interference during the frenectomy procedure from water in the water bath.

The thirty lower sheep jaw parts were divided in three groups of ten. In the first group the electrotome was used to perform the frenectomies in the central frenulum, in the second group the Er:YAG laser was used without water spray and in the third group the Er:YAG laser with water spray (5 ml/min).

The parameters used in this study was:

The power used in electrotome in the scale of 10 was 5. That means 50% of the maximum power of the electrotome (50 watts) which is 25 watts. The tip of the electrotome had a diameter of 0.40 mm.

The energy used in the Er:YAG laser was 150 mJ, with the pulse frequency of 20 Hz and the pulse duration in 700 µsec (long pulses).

The incision was made 3 mm away from the attached gingival in a depth up to 15 mm from the surface of the frenulum.

Results and statistical analysis

The results that were registered have shown that the temperature rising was much higher in the frenectomies with the electrotome than with the Er:YAG laser without the water spray. On the other hand in the frenectomies with the Er:YAG with water spray the

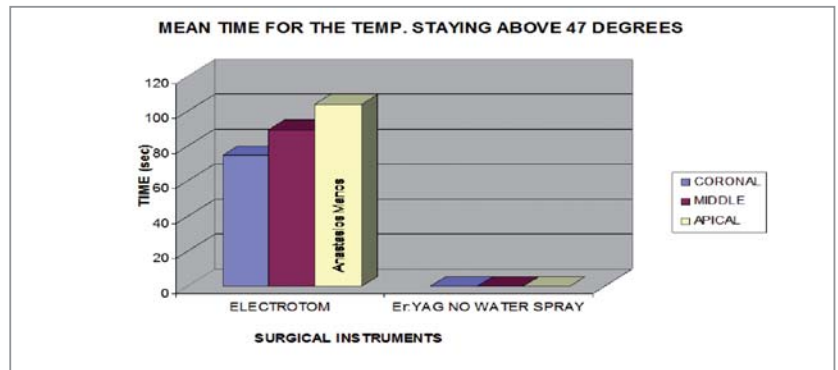


Fig. 2 & Tab. 2 Mean time of the temp. staying above 47 °C.

	Electrotom	Er:YAG No Water Spray
Coronal	74.6	0
Middle	89.4	0
Apical	104.0	0
95% Confidence Interval		

temperature dropped under the physiological temperature of 37 °C creating hypothermia in the tissues.

The statistical analysis was done with SPSS 13 statistical package and Bonferroni method. The results have shown that the temperature changes between the Er:YAG laser with water spray and without water spray have great differences. While in the frenectomies with the Er:YAG laser with water spray we have found a drop of the temperature under the physiological temperature of the living tissue down to 34.1 °C, in the frenectomies with the Er:YAG laser without water spray we could see a temperature elevation in the subperiosteal bone up to 40.3 °C.

The mean of the maximum temperature rising/dropping had significant differences between the three different techniques that were used for the frenectomies in this study. These differences can be seen in the Tab. 1 and Fig. 1.

The mean time of the temperature staying above the threshold time level of 1 min gave significant differences between the electrotome and the Er:YAG laser without the water spray. In the frenectomies with the electrotome the time of the temperature staying above the 47 °C always exceeded the time threshold of 1 min. while in the frenectomies with the Er:YAG laser this time threshold was never exceeded. These results can be seen in the Tab 2 and Fig. 2.

The mean of the cooling time gave also big differences with the longer cooling time in the apical part of the frenectomies with the electrotome and the shortest cooling time in the coronal part of the frenectomies with the Er:YAG laser.

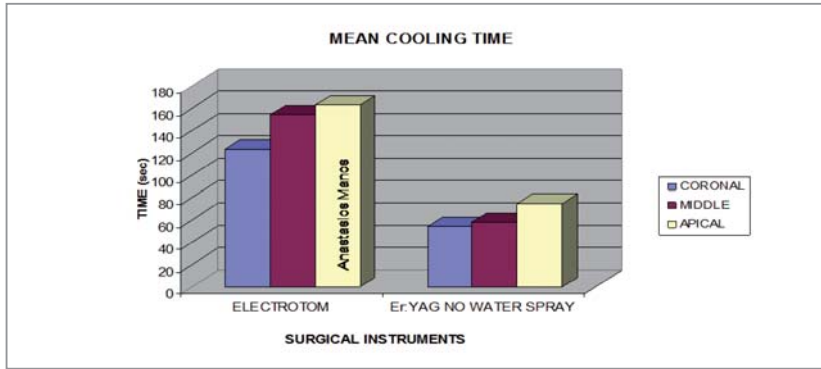


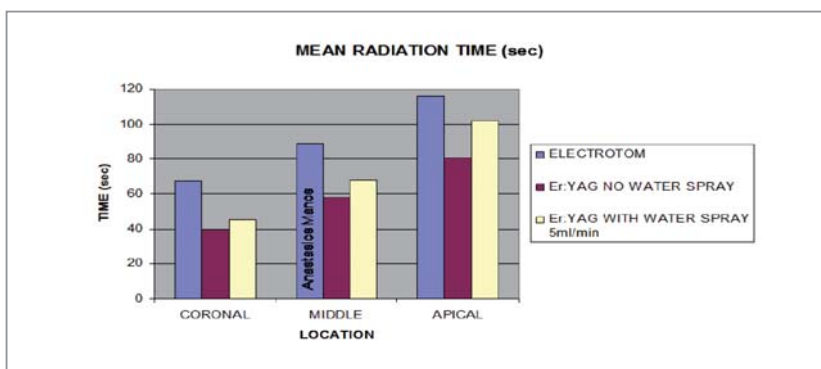
Fig. 3 & Tab. 3_ The mean cooling Time.

	Electrotom	Er:YAG No Water Spray
Coronal	123	54
Middle	154	58
Apical	163	75
95% Confidence Interval		

These results can be better seeing in the Tab. 3 and Fig. 3. The mean irradiation (or working) time was also registered and show significant differences between the three frenectomy techniques used in this study. The longest working time was in the frenectomies with the electrotoe and the shortest in the frenectomies with the Er:YAG laser without the water spray. These differences can be seeing in the Tab. 4 and Fig. 4.

Discussion

Fig. 4 & Tab. 4_ The mean radiation time. There has been a lot of research in the temperature elevation on the living tissues both in Medicine^{3,4,14,16,19}, Dentistry^{2,4,5,6,7,9,10,12,15,20} and biophysics¹.



	Electrotom	Er:YAG No Water	Er:Yag with Water
Coronal	67.75	39.96	45.34
Middle	88.66	57.96	67.90
Apical	115.79	80.86	101.96
95% Confidence Interval			

Researchers are trying to investigate the temperature rising and its effects on the living tissues after the use of mechanical instruments, Lasers or electrotoes for different surgical procedures.

In 1983, Eriksson and Albrektsson with their research project have define the thermal threshold level for bone necrosis in 47 °C for 1 min.³

In 1989, Walsh et al. were investigating the thermal effect of a q-switched Er:YAG laser on the skin, cornea, aorta and bone. They could see that the thermal damage had a penetration 5–10 µm.¹⁹

In 1992, Prokova et al. were investigating the thermal effects of the CO₂ laser during surgical incisions on the bone tissue. They found that when the power density was rising the temperature was rising also. They also found that the temperature rising was dropping in a logarithmic rate to the distance from the incision point. The temperature dropping was depending on the tissue thermal conductivity.¹⁴

In the same year, Perry et al. were investigating the results after irradiation of the oral soft tissue with Nd:YAG laser. They found that if the applied power was grater than 5 W there was an increase of the temperature rising without any rising in the incision speed.¹³

In 1993, Sardar et al. found in their research that the thermal effect on the tissues is depended of the absorption and diffusion of the laser beam on the biological tissues and of the energy fluence on them.¹⁶

In our project we could also see that the thermal damage was influenced by the physical and optical properties of the tissues and of the power that was applied on them. Looking in our results we can see that the much stronger power of the electrotoe did not speed up our incision on the tissues but on the other hand gave a much higher temperature on them. This is in agreement with the results found by Perry et al. in 1992. There must be a threshold point in the applied power (electrical or electromagnetic) from which and after that the only given effect in the tissues is the temperature rising and the risk of thermal trauma. Also in our project we could see the temperature dropping when we used the water spray cooling with the Er:YAG laser. This was happening because part of the applied laser energy was absorbed from the water in the water spray. The energy fluence on the tissues became much smaller giving us longer incision speed and also a cooling effect on them. This is in agreement with the results found by Miserendino et al. in 1993 and Frenzen et al. in 2003 in their research.^{11, 4}

The temperature rising in our experiments was depended on the power applied on the tissues. The time

for the temperature staying above the threshold point for thermal damage (47 °C) is depending not only in the applied power but also in the energy fluence, the absorption, the diffusion of that energy in the tissues and the tissue conductivity.^{16, 14} The energy fluence applied on the tissues was giving the temperature rising while the energy diffusivity in the tissues and the tissue conductivity were giving the cooling time of the tissues. Because the diffusivity and conductivity in the oral tissues of the same species (sheep) can be consider having the same value we can say that the higher the applied energy fluence the longer the cooling time.

Conclusions

For conclusions we can say that:

The threshold point of 47 °C for bone necrosis has been exceeded in all the frenectomies with the electro-tome (a rate of 100 %) while this never happen in the Frenectomies with Er:YAG laser (a rate of 0 %).

The mean time for the temperature staying above 47 °C was always more than 60 sec with the electro-tome presenting risk for thermal damage in the subperiosteal bone tissue, while the mean time for the temperature staying above 47 °C with the Er:YAG laser was 0 sec. The cooling time was significant longer with the

electrotome. The mean irradiation (or working) time was significant longer with the electro-tome. It is safe to use the Er:YAG laser for frenectomies using the parameters used in this study.

It is expected to have less temperature rising in living tissues due to the blood microcirculation in the surrounding tissues _

contact

laser

Dr Anastasios Manos (DDS, LSO, MSc)

Department of Oral Surgery, Implantology and Roentgenology, Dental School, Aristotle University of Thessaloniki
K. Paleologou 2, 17121, Nea Smyrni – Athens, Greece
E-mail: tandlaek@otenet.gr

Associated Prof Nicolaos Parisis

Department of Oral Surgery, Implantology and Roentgenology, Dental School, Aristotle University of Thessaloniki

AD

cosmetic dentistry _ beauty & science

One issue free of charge!



Subscribe now!

*Prices include shipping and VAT

☐ I hereby agree to receive a free trial subscription of **cosmetic dentistry** (4 issues per year). I would like to subscribe to **cosmetic dentistry** for € 44* for German customers, € 46* for customers outside of Germany, unless a written cancellation is sent within 14 days of the receipt of the trial subscription. The subscription will be renewed automatically every year until a written cancellation is sent to OEMUS MEDIA AG, Holbeinstr. 29, 04229 Leipzig, Germany, six weeks prior to the renewal date.

▶ Reply via Fax +49 341 48474-290 to OEMUS MEDIA AG or per E-mail to grasse@oemus-media.de

Last Name, First Name

Company

Street

ZIP/City/Country

E-mail

Signature

Notice of revocation: I am able to revoke the subscription within 14 days after my order by sending a written cancellation to OEMUS MEDIA AG, Holbeinstr. 29, 04229 Leipzig, Germany.

Signature

laser 2/10

Implant exposure with Er:YAG laser (=2,940 nm)

A comparison with lasers of different wavelengths

Author_Dr Gerd Volland, Germany

The use of lasers in oral surgery is known to have many advantages compared to conventional surgery. Zeredo et al.¹⁸ did prove in an study on incision in rats that the nociception is reduced with a factor of 3 compared to the conventional scalpel use. Surgical cuts with electrotome and scalpel cause a bacterial invasion in the treated animals. Kaminer et al.⁹ did not find this problem using laser techniques.

Lasers of different wave lengths are proven to reduce bacteria efficiently in different fields of dentistry and medicine.^{4,5,6,13} After an initial lac in healing the application of superpulsed carbondioxide laser light reduced the configuration of scars significantly compared to electrotome and scalpel (Romanos et al.¹⁵

Because of these reasons, the healing^{14,16} and the bloodless operation field lasers use is more and more common in all fields. Depending on the wavelength laser light is absorbed, transmitted or scattered very differently depending on the irradiated tissue.² Nd:YAG lasers are not proriare in second stage surgery because of the high absorption in metal, especially titanium. They are used for laser melting in dental labs by the technicians. Whereas diode lasers with 810, 980 or 1,064 nm penetrate uncoloured tissue up to

4 mm, carbondioxide an Erbium lasers are absorbed very superficially in a range between 3 (Er:YAG) and 17 μ m (carbondioxide).³ Chromophores of the skin are oxyhemoglobine, hemoglobine, melanine and carotene.³ Not only in different ethnical groups we find different coloration of the skin, even in people of central Europe we find different coloration of the oral mucosa and the palate.⁸

Aside the ethnical aspects we find different coloration of the mucosa in different parts of the mouth in the same patient depending on pigmentation, vascularisation and per cent of fibrous tissue such as palate or vestibulum. Watching the absorption curves we find differences with factor 10 to 10,000 comparing the absorption coefficient of the different compartments.⁷ This causes the problem that we do not have a predictable absorption using diode or Argon lasers in oral surgery.

So the surgeon needs a lot of experience because he has no protocol which is always the same.

Neither power setting nor velocity of the cut are fixed parameters. Starting with low power settings may cause long treatment time. High power enables fast cutting but uncontrolled heat because the alter-

ation of the tissue leads to extreme development of temperature increase. Especially for surgeons who start with laser it would be perfect to have an instrument with which you can see what you do, that does not have a high

Fig. 1 _Infrared camera.

Fig. 2 _980 nm 300 μ m fiber 5 W cw.

Fig. 3 _980 nm 300 μ m fiber 7 W spray.

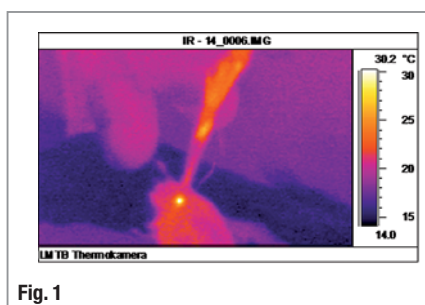


Fig. 1

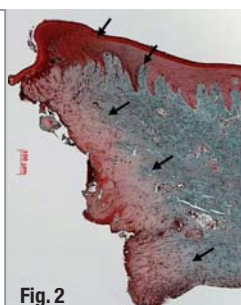


Fig. 2

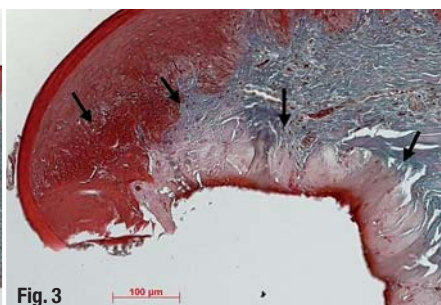
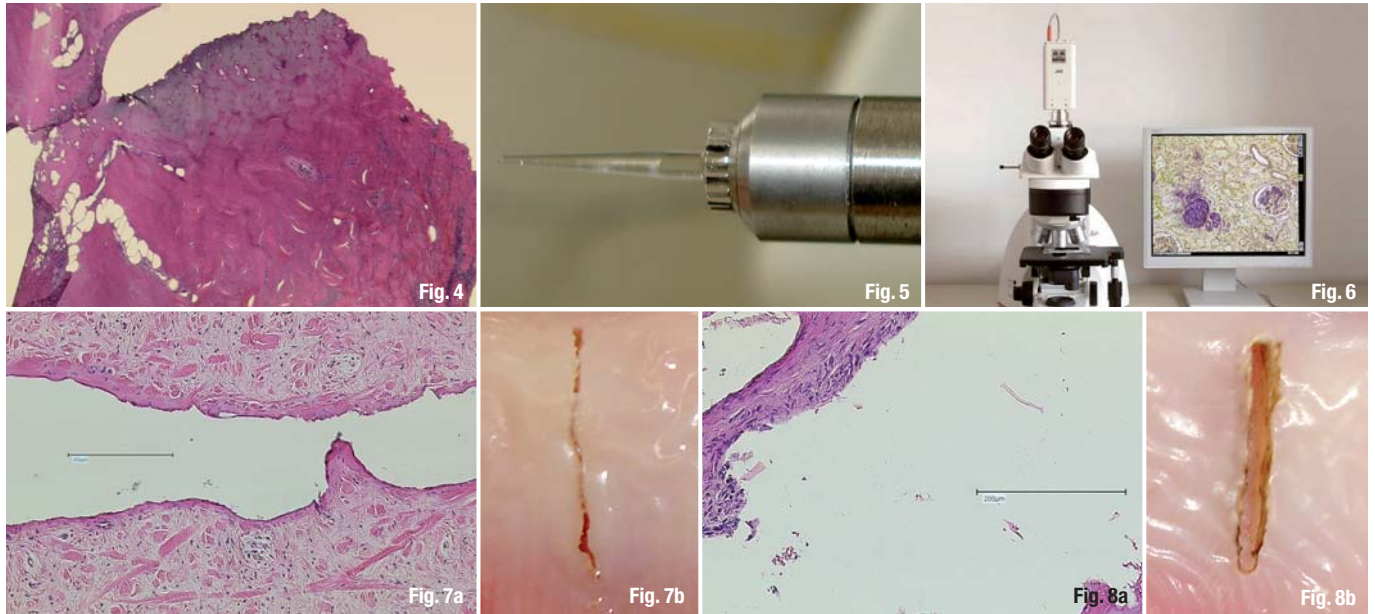


Fig. 3



penetration and have a fixed protocol to reach best possible success.

Gutknecht⁷ described the way of cutting with fibre diode lasers and gave the name "hot tip" cutting. But this also means that the main danger is the overheating and the caused by this uncontrolled necrosis especially in fibrous non coloured parts of the mouth such as the palate or a fibrous frenulum. Own investigation in 2001 at LMTB in Berlin using a spray of distilled water (diode laser 980 nm Ceralas D15, 7 W cw, 300 mm fibre, 10 ml/min. 3 bar air pressure) showed that by water cooling a lot of the heating can be transported away from the "hot tip" by the water flow.

The picture of a thermo camera shows the cooling effect very good.

Nevertheless we need the hot fibre end for the cut as seen in the picture

The uncontrolled heating in fibrous tissue causes deep necrosis up to 400 µm cutting mucosa of a pig, which can disturb healing very much (Fig. 3).

In comparison the cut with 7W and spray shows a clearly defined zone of necrosis of about 200 µm. Nd:YAG lasers (6 W 100 Hz 300 µm fiber) in unpigmented skin of a pig make very uncontrolled carbonization.

The only constant part in oral mucosa is water with about 85 %.⁷

Because of this the only lasers which have always the same effect regarding the zone of periphery necrosis in the whole mouth soft tissue are carbon-

dioxide and erbium lasers. Especially in Er:YAG lasers the thermal damage goes down to zero using pulse width of 300 µs¹⁰ because the cut is not thermal but almost completely thermomechanical. Parts of the subsurface water are sublimated within 2 µs.³

By this effect there is almost no thermal damage in this pulse width.

Aside from cavity preparation the Erbium can also be used for oral surgery.^{1,17}

The remaining problem with the normal settings is the bleeding.

From theory using less power per pulse and using a higher frequency should lead to more thermal effect using the same pulse width.

For the *in vitro* experiment a laser with pulse width 300 µs, a fiber as light transmission system and special conical sapphire tip 300 µm (Hoya, Versawave) were used.

The exact energy output at the end of the tip could not be asked by the company. So the parameters shown on the display had to be used for definition of energy density and power density.

Material and Method

Different frequencies enabling an effective cutting were compared.

Mandibula mucosa of fresh pig that were not cooled after the slaughtering for having always the same amount of water in the mucosa were put in

Fig. 4 _Nd:YAG 6 W 100 Hz pulse width 150 µs 300 µm fiber.

Fig. 5 _Surgical tip.

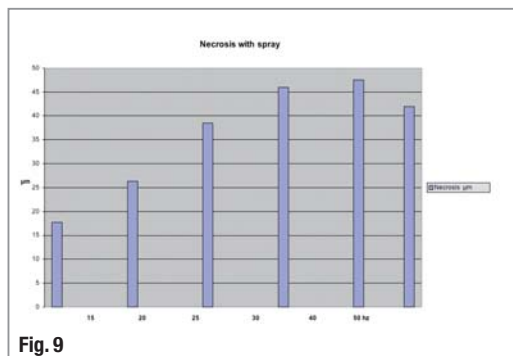
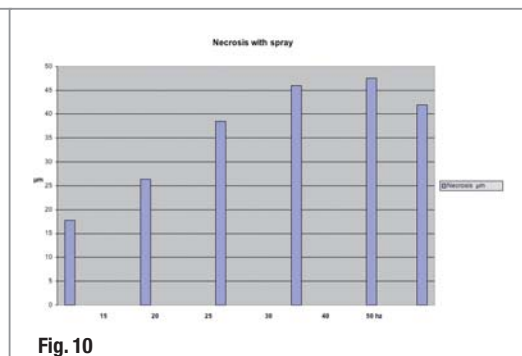
Fig. 6 _Measuring structure.

Fig. 7a _40 Hz/125 mJ with Spray.

Fig. 7b _40 Hz/125 mJ with Spray.

Fig. 8a _50 Hz/40 mJ no spray.

Fig. 8b _50 Hz/40 mJ no spray.

Fig. 9 Statistics without spray.**Fig. 10** Statistics no water.**Fig. 9****Fig. 10**

Ringer Solution. After making smaller parts the mucosa on the tongue side including the periost was cut through in contact mode. The average thickness of the mucosa was 1,0 mm.

They were put in 10 per cent formaline and examined in Ansbach pathology institute.

The pathologist made histologies using cuts over the length using hematoxyline-eosine colouring. The cuts were examined in a depth of 0,6 mm.

The evaluation was made by using a Zeiss microscope with magnification 5x to 40 x with Discus software by Hilgers.

The necrosis with spray was between 17,72 µm at 15 Hz/420 mJ up to 47,54 µm using 40 Hz/125 mJ.

Without spray the lateral necrosis was between 18,9 µm at 15 Hz/420 mJ up to 102,18 µm at 50 Hz/40 mJ.

_Discussion

Using a higher frequency in Er:YAG lasers with spray leads to coagulation of a maximum of 47,54 µm. Without using spray the average necrosis goes up to 102,18 µm. The higher frequency leads to an almost linear increase of the tissue alteration. This enables the surgeon to work with predictable coagulation results on the tissue.

Kreisler et al.^{11,12} proved that applying 11,2 J/cm², pulse width 300 µs the titanium surface of implants gets no harm. So a damage of the implant/ bone interface using available settings can be excluded. For effective laser work in implant exposure also in esthetic critical areas Er:YAG lasers can be used. There is no risk for loss of tissue by uncontrolled heating with maintenance of reduction of bleeding or even no bleeding. The bone below the cut is damaged up to 12 µm using the no spray parameters. So it is a safe way also when cutting fibrous tissue, i.e. a wisdom tooth cut eliminating risk of bacteriemia or cuts on the

palate. More controlled increase of the coagulation area over the measured may be reached by using other parameters with less power per pulse, higher frequency or a higher pulse width.

_Indications

Vestibuloplastics, frenectomies, hyperplasia, excisions in the lip red or implant recovery in fibrous regions will be the indications for the Erbium instead of a knife.

The limitation using the Erbium laser in incisions are the regions with vessels.

Because of no light penetration bleedings cannot be stopped using this laser.

Normally compression should help. This laser should not be used in vessel producing tumors such as hemangioma.

People with hemorrhage diathesis or anticoagulation will have no benefit.

In these people diode lasers (810, 980, 1,064 nm) Argon (488/514 nm) or long pulsed Nd:YAG lasers are the first choice in treatment of these patients.

The aim for the future is to develop an appliance that combines easy and safe cutting of a scalpel with controlled coagulation and all the other benefits of laser like sterilisation of the cut or low level effects.

Editorial note: The literature list can be requested from the editorial office.

_contact

laser

Prof Dr MSc mult Gerd Volland

Facultad de Odontología
Cirugía bucal
Universidad de Sevilla
C/ Avicena s/n Sevilla, Spain

19th ANNUAL CONGRESS OF THE DGL

LASER START UP 2010

OCTOBER 29–30, 2010, BERLIN, GERMANY



» Please fax this form
+49 341 48474-290

- ☒ More informations:
- ☐ **LASER START UP 2010**
 - ☐ **19th ANNUAL CONGRESS OF THE DGL**
- October 29–30, 2010, Berlin, Germany

office stamp

Laser endodontic therapy using 940 nm diode laser

Temperature rise on external root surface—Part I

Authors_Dr Pradhan Suchetan & Dr Karnik Rohit, India

_Introduction

Nearly 50 years after the first dental laser was created, lasers have finally found their way onto the shelves of dental clinics. A perceived mysterious technology, whose most dramatic use is in the art of warfare, is now an integral part of the medical and dental armamentarium.

As presently used in therapeutic medical and dental applications, lasers are, in essence, devices that produce a monochromatic and directional beam of light powerful enough to do biomedical work, and with much less electrical energy converted into waste heat.

occur, producing a monochromatic, collimated and coherent beam of light.

One of the most commonly used lasers in dentistry is a diode laser. Diode laser is a solid active medium laser manufactured from semiconductor crystals similar to that found in a light-emitting diode using some combinations of aluminum or indium, gallium and arsenic. Diode lasers emit light when an electric current passes through them. Laser light is generated in a beam that is directional and monochromatic which enables laser light to be focused to a very small spot diameters needed for medical and dental applications.

The available wavelengths for dental usage for diode laser range from about 800 nm for the active medium containing aluminum to 980 nm for the active medium composed of indium, placing them at the beginning of the near-infrared portion of the invisible nonionizing spectrum.

The principle effect of laser energy is photothermal i.e. conversion of light energy into heat energy. This thermal effect of laser energy on tissue depends on the degree of temperature rise and corresponding reaction of the interstitial and intracellular water. The rate of temperature rise plays an important role in this effect and is dependent on several factors such as cooling of the surgical site and the surrounding tissue ability to dissipate the heat.

This rise in temperature due to thermal effect is commonly seen in laser assisted root canal therapy. Use of diode laser as an adjunct during root canal therapy provides an additional advantage in reducing bacterial counts and thus improves the success of root canal therapy.

Fig. 1 _The 940 nm diode laser that was used for this study: Ezlase 940, Biolase®.



Fig. 1

In 1960, Theodore Maiman, a scientist with the Hughes Aircraft Corporation, developed the first working laser device which emitted a deep red colored beam from a ruby crystal (Coluzzi 2004)⁷. During the next few years dental researcher studied the possible applications of this visible laser energy.

The word LASER is an acronym for Light Amplification by Stimulated Emission of Radiation.

All available dental laser devices have emission wavelength of approximately 500 nm to 10,600 nm. A laser consists of lasing medium contained within an optical cavity, with an external energy source to maintain a population inversion so that stimulated emission of a specific wavelength can

Successful endodontic therapy mainly depends on the elimination of micro-organism from the root canal system which is traditionally accomplished by the means of biomechanical instrumentation of the root canal. Studies have shown however, that the complete removal of microorganisms from the root canal system is virtually impossible (Bystrom and Sundquist 1981⁵, Sjogren et al 1990²⁶) and a smear layer covering the instrumented walls of the root canal is formed (McComb and Smith 1975²⁰, Moodnik et al 1976²¹, Mader et al 1984¹⁸).

Peters et al (2001)²³ clearly demonstrated that more than 35 % of the canals surface area remained unchanged following instrumentation of the root canal using four Ni-Ti preparation techniques.

The presence of bacteria in the dentinal tubules of infected teeth at approximately half the distance between the root canal walls and the cemento-dentinal junction was also reported (Ando and Hoshino 1990², Armitage et al 1983³). These findings justify the rationale and the need for developing effective means of removing the smear layer from root canal walls following biomechanical instrumentation. This would allow disinfectants and laser irradiation to reach and destroy micro-organisms harbored in the dentinal tubules.

Gutknecht et al (2004)¹⁰ in his research using a 980 nm diode laser showed that the 980 nm diode laser can eliminate bacteria that have immigrated deep into the dentin, thus being able to increase the success rate in endodontic therapy. Benedicenti et al. (2008)⁴ did an *in vitro* study to investigate the bactericidal effects on root canals using an 810 nm diode laser and found that when used as an adjunct to conventional therapy, it results in increasing treatment efficiency and significantly better decontamination of the root canal. However it also concomitantly results in a rise in the external root surface temperature which can be hazardous to the surrounding periodontal tissues and the bone if temperature rises above 10 °C (Ericson et al 1983⁸).




Fig. 2 Tooth being held between the fingers and thermocouple while in contact with the tooth surface to measure temperature changes with the laser in activated mode.

The threshold temperature level of 7 °C is commonly considered as the highest temperature limit biologically accepted to avoid periodontal damage (Saunders 1990²⁵, Nammour et al 2004²²).

Studies have been done with 810 nm and 980 nm diode laser which show rise in temperature on external root surface of teeth following diode laser assisted root canal therapy (Gutknecht et al 2005¹¹, Alfredo et al 2008¹). Gutknecht et al 2005¹¹ found that there was temperature rise of not more than 7 °C when irradiated upto 1.5 W and thus can be considered safe for use in laser assisted endodontic therapy.

Heyselaer et al 2007¹² using a 980 nm laser used 3 W, 2 W and 1 W in continuous mode and found average rise in temperature at 20.7 ± 0.3 °C, 9.3 ± 0.4 °C and 5.8 ± 0.8 °C for 3 W, 2 W and 1 W of laser irradiation on external root surface. Results showed that the use of diode laser in root canal treatments may be harmful for periodontal tissues if the irradiation conditions are not strictly respected.

Manos and Gutknecht 2007¹⁹ did a study using 980 nm diode laser with the same power settings of 2.5 W at continuous mode and chopped mode and found that the temperature rising never exceeds the threshold point of thermal bone necrosis of 47 °C and thus can be considered safe for periodontal tissues during laser assisted root canal treatment.

Laser Treatment	N	Mean	Standard Deviation	Standard Error	Maximum	Minimum
1 W, Continuous	30	4.17	1.262	0.230	7	2
1 W, Gated	30	1.80	0.664	0.121	3	1
2 W, Continuous	30	6.47	1.756	0.321	11	3
2 W, Gated	30	2.43	0.774	0.141	4	1
Total	120	3.72	2.166	0.198	11	1

Table 1 Descriptive statistics for four treatments on apical third.

Pairs compared	Mean difference	Standard error	P-value
1 W, continuous vs 1 W, gated	2.367*	0.260	0.0005
1 W, continuous vs 2 W, continuous	2.300*	0.395	0.0005
1 W, continuous vs 2 W, gated	1.733*	0.270	0.0005
1 W, gated vs 2 W, continuous	4.667*	0.343	0.0005
1 W, gated vs 2 W, gated	0.633*	0.186	0.007
2 W, continuous vs 2 W, gated	4.033*	0.350	0.005

Table 2 Multiple comparisons (for apical third).

*The mean difference is significant at the 0.05 level (Tamhane Test).



Fig. 3

Fig. 3 The power meter measuring the power at the distal end of the tip.

Alfredo et al. 2008¹ in his study assessed the temperature variation at 1.5 W, 3 W and 5 W and found that at 1.5 W in all operating modes, and 3.0 W, in the pulsed mode, for 20 sec, can safely be used in endodontic treatment, irrespective of the presence of humidity. The 810 nm and 980 nm diode lasers are available in varying fiber diameters ranging from 200 µm to 600 µm. The end cutting property of the fiber along with a variation in diameter results in varying energy density at the tip.

Recently a 940 nm diode laser has been manufactured for clinical use. This machine has a fiber which is constant in diameter of 400 µm but with varying tips. Thus only the tip needs to be changed according to the usage for a particular patient. The tip most commonly used for endodontic purpose is 200 µm in diameter and 14 mm in length. No studies are available which describe the use of this wavelength for endodontics and its effectiveness in bac-

terial decontamination. Consequently safety parameters for 940 nm wavelength are not available. The purpose of this study was to evaluate the thermal effect of 940 nm diode laser on external root surface during laser assisted root canal therapy so that this particular laser can be used at appropriate laser settings safely and effectively, without any collateral damage to the periodontal tissues. _

_contact

laser

Dr Suchetan Pradhan

MDS (Prosthodontics), MSc Laser Dentistry (Aachen Univ., Germany), EMDOLA (European Union), Co-worker, Aachen University, Germany
 Founder President, Indian Academy of Laser Dentistry, Director, Department of Laser Dentistry, Manipal Faculty, Implant Department, Manipal Professor, Department of Implantology, SS Dental College, Hyderabad, India
 E-mail: suchetanpradhan@gmail.com

Dr Rohit Karnik

MDS (Periodontics), FAGE
 Ex-Faculty, Nair Hospital Dental College, Mumbai, India
 Currently in private practice at Pradhan Dental Center
 E-mail: drrohitkarnik@gmail.com

DenTech China 2010

www.dentech.com.cn

The 14th China Int'l Exhibition & Symposium on Dental Equipment, Technology & Products

The 4th Asian Dental Lab Outsourcing Exhibition 2010 International Exhibition On Oral Health (Shanghai)

November 2~5, 2010

Shanghai Everbright Convention & Exhibition Center, Shanghai, China



Approved by: Ministry of Science and Technology of the People's Republic of China

Sponsored by: Chinese Stomatological Association / Shanghai Stomatological Association

Organized by: China International Conference Center for Science & Technology / Ninth People's Hospital, School of Medicine, Shanghai Jiao Tong University

Co-organized by: College of Stomatology, Shanghai Jiao Tong University / School of Stomatology, Tong Ji University /

Shanghai Stomatological Disease Center / Shanghai ShowStar Exhibition Service Co., Ltd.

If you are interested in participating or visiting the Exhibition, please fill the form below and fax or post to: Shanghai ShowStar Exhibition Service Co., Ltd.

Room 22C/D, Jiali Mansion, No. 1228, Yan'an Road (W), Shanghai 200052, China

Tel: +86-21-6294 6966 / 6294 6967 / 6294 6968, Fax: +86-21-6280 0908, E-mail: mail@showstar.net

I am interested in DenTech China 2010, please send me more information on

☐

EXHIBITING

☐

VISITING

Name _____ Company _____

Address _____

Telephone _____ Fax _____

Zip _____ E-mail _____

Diode lasers: the soft tissue handpiece

Author_Dr Fay Goldstep, Canada

_Dental lasers have been commercially available for several decades. They have been thoroughly documented in the dental literature. Lasers are an exciting technology, widely used in medicine, kind to tissues, and excellent for healing. So why have they not been more widely embraced by the practicing dentist? There is a wide perception that the dental laser is not useful, too complicated, and too expensive. This has changed with the arrival of the diode laser onto the dental scene. There is now a convergence of documented scientific evidence, ease of use and greater affordability that makes the diode laser a "must have" for the dental practice.

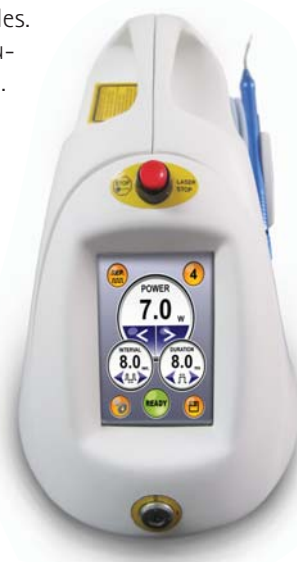

Fig. 1

named for the substance which is stimulated. In the diode laser this substance is a semiconductor (a class of materials which are the foundation of modern electronics including computers, telephones and radios). This innovative technology has produced a laser that is compact and lower in cost. Most of the research has focused on the 810 nm diode laser. This wavelength is ideally suited for soft tissue procedures since it is highly absorbed in haemoglobin and melanin. This gives the diode laser the ability to precisely cut, coagulate, ablate or vaporize the target tissue.¹

Treatment with the 810 nm diode laser (Fig. 1, Picasso diode laser, AMD LASERS) has been shown to have a significant long-term bactericidal effect in periodontal pockets. *A. actinomycetemcomitans*, an invasive pathogen associ-

_The science behind the laser

"Laser" is an acronym for Light Amplification by Stimulated Emission of Radiation. Lasers are

Fig. 1 Soft tissue covering gingival margin of fractured tooth.

(Photo courtesy Dr. Phil Hudson)

Fig. 2 Laser outline of gingivectomy.

(Photo courtesy Dr. Phil Hudson)

Fig. 3 Laser gingivectomy completed.

(Photo courtesy Dr. Phil Hudson)

Fig. 4 Hard tissues etched for immediate restoration.

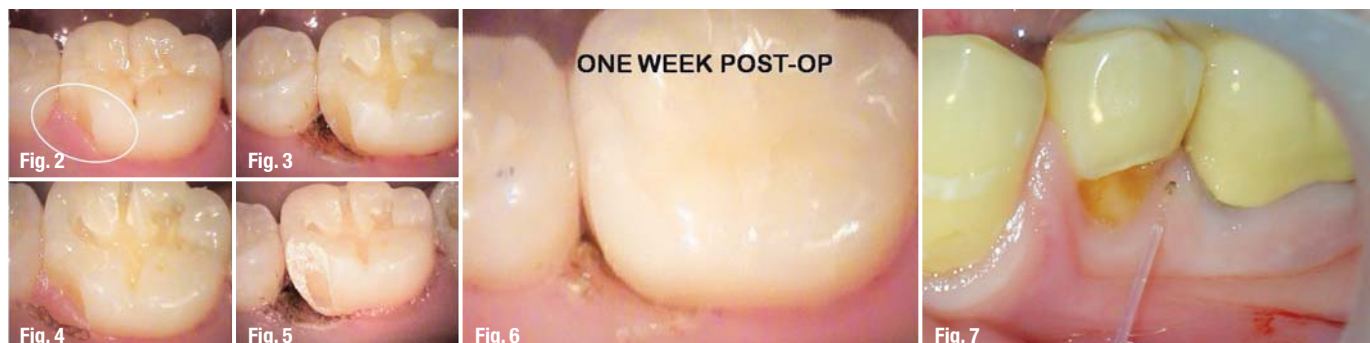(Photo courtesy Dr. Phil Hudson)

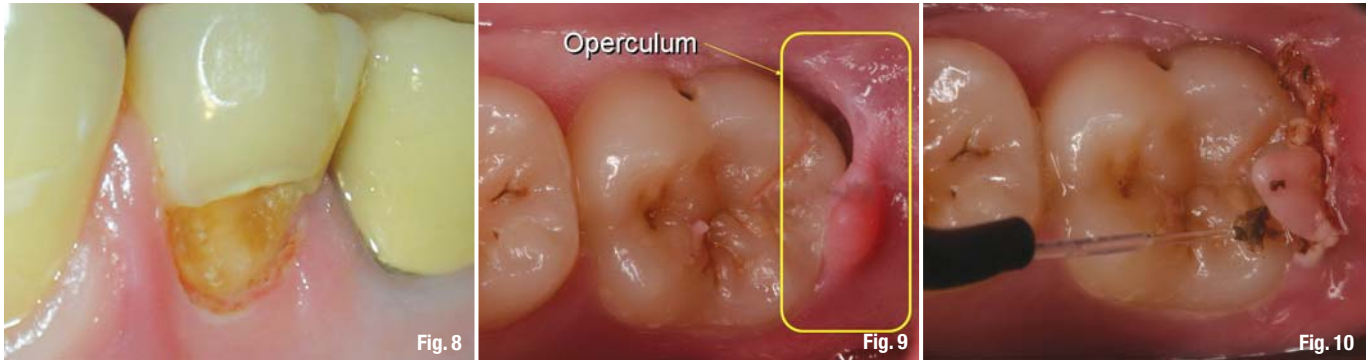
Fig. 5 One week post-op.

(Photo courtesy Dr. Phil Hudson)

Fig. 6 Laser positioning for gingival troughing.

(Photo courtesy Dr. Robert Lowe)





ated with the development of periodontal disease and generally difficult to eliminate, responds well to laser treatment.^{2,3} Scaling and root planing outcomes are enhanced with the addition of diode laser therapy. The patient is typically more comfortable, and gingival healing is faster and more stable.^{4,5}

Ease of Use

Early adopter dentists thrive on new technology. They enjoy the challenges that come with being the first to use a product. Most dentists are not early adopters. Lasers have intimidated mainstream dentists with their large footprint, lack of portability, their high maintenance profile of operating tips and complex procedural settings. When do I use which tip? What setting works for which procedure? Why do I need a laser when I have been managing well without one?

Enter the diode laser. It is compact. It can easily be moved from one treatment room to another. It is self-contained and does not have to be hooked up to water or air. It has one simple fiberoptic cable which is easily transformed to an operating tip. The units come with several presets, although after a very short time, the operator becomes so comfortable that they are not even needed. The power and pulse settings are simply adjusted to suit the particular patient and procedure.

On a personal note, I am a dentist who does not thrive on the challenge of brand new high-tech, high-stress technology. I have tried many lasers in the past that promised to be user-friendly; they were anything but. With the 810 nm diode laser, after a short in-office demonstration, I was able to pick up the handpiece and to feel comfortable enough to perform some simple procedures. I have since taken on-line training, as well as lecture courses, which have enhanced both my comfort level and my competency.

Affordability

Laser technology has always come with a high price tag. Manufacturing costs are high and cutting edge technology commands steep pricing. Diode lasers are less expensive to produce. Break-through pricing for this technology has now reached well under CAN\$10,000. At this level the diode laser becomes affordable for the average practicing dentist.

Why do I need this technology?

The 810 nm diode laser is specifically a soft tissue laser. This wavelength is ideally suited for soft tissue procedures since it is highly absorbed in haemoglobin and melanin, both of which are prevalent in soft tissues. This gives the diode laser the ability to precisely cut, coagulate, ablate or vaporize the target tissue with less trauma, improved post-operative healing, and faster recovery times.^{6,7,8} Given the incredible ease of use and its versatility in treating soft tissue, the diode laser becomes the "soft tissue handpiece" in the dentist's armamentarium. The dentist can use the diode laser soft tissue handpiece to remove, refine and adjust soft tissues in the same way that the traditional dental handpiece is used on enamel and dentin. This extends the scope of practice of the general dentist to include many soft tissue procedures.

The following procedures are an easy entry point for the new laser user:

1. Gingivectomy, haemostasis, gingival troughing for impressions

The diode laser makes restorative dentistry a breeze. Any gingival tissue that is covering a tooth during preparation can be easily removed and haemostasis achieved simultaneously. The restoration is no longer compromised because of poor gingival conditions. There is no more battling with unruly soft tissue and blood (Figs. 1–5).

Fig. 7 Close-up of laser positioning in sulcus.

(Photo courtesy Dr. Robert Lowe)

Fig. 8 Infected operculum distal to second molar.

(Photo courtesy Ivoclar Vivadent)

Fig. 9 Laser removing operculum.

(Photo courtesy Ivoclar Vivadent)

Fig. 10 Operculectomy completed.

(Photo courtesy Ivoclar Vivadent)

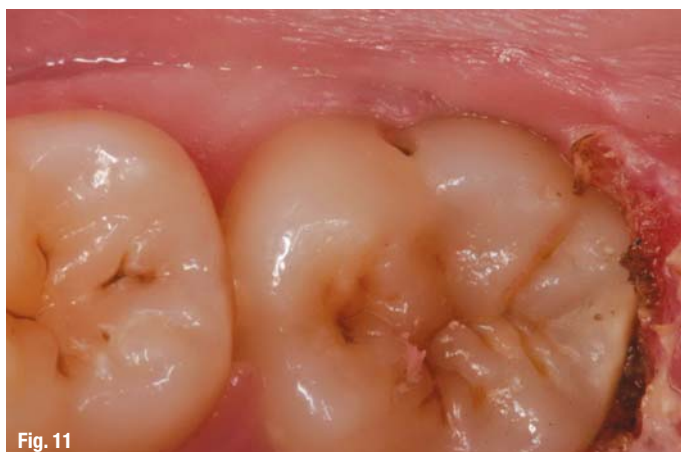

Fig. 11

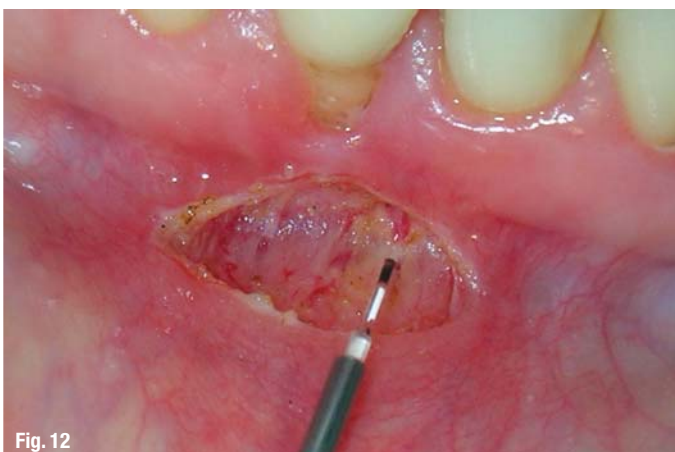


Fig. 12

Fig. 11_ Gingival condition prior to Laser Assisted Periodontal Treatment.

(Photo courtesy Dr. William Chen)

Fig. 12_ Gingival condition after Laser Assisted Periodontal Treatment.

(Photo courtesy Dr. William Chen)

Gingival troughing prior to impression taking helps to ensure an accurate impression and an improved restorative outcome. Packing cord is no longer necessary (Figs. 6 & 7).

With these procedures, restorative dentistry becomes less stressful, more predictable and more enjoyable for the dental team and the patient.

2. Operculectomy Gingival Hyperplasia

Excision and/or recontouring of gingival hyperplasia frenectomy.

These procedures are usually not offered or performed by the general dentist. They are examples of the expanded range of services readily added to the general practice. The dentist becomes more proactive in dealing with hyperplastic tissues that can increase risk of caries and periodontal disease (Figs. 8–10).

3. Laser Assisted Periodontal Treatment

The use of the diode laser in conjunction with scaling and root planing is more effective than scaling and root planning alone. It enhances the speed and extent of the patient's gingival healing and post-operative comfort.^{4,5} This is accomplished through laser bacterial reduction, debridement and biostimulation (Figs. 11 & 12, courtesy of Dr Phil Hudson).

A. actinomycescomitans which has been implicated in aggressive periodontitis may also be implicated in systemic disease. It has been found in atherosclerotic plaque⁹ and there has been recent data suggesting that it may be related to coronary heart disease.¹⁰

The diode laser is effective in decreasing *A. actinomycescomitans*,^{2,4} and thereby indirectly improving the patient's heart health.

_Laser Education

Most diode laser manufacturers provide some education to get the new user started. The most comprehensive online, unbiased, unaffiliated diode laser introductory course with certification (which includes the science, safety and clinical procedures) can be found at www.advancedlaser-training.com. This course provides everything necessary to get you started with soft tissue diode lasers. Advanced courses are available for more complex procedures.

The soft tissue diode laser is rapidly becoming a "must have" mainstream technology for the general practice. The science, ease of use, and affordability make it simple to incorporate. It becomes the essential "soft tissue handpiece" for the practice. The time may soon come when a diode laser will be placed in each restorative and each hygiene treatment room. Restorative dentistry becomes easy, predictable and less stressful. The scope of practice is expanded to include new soft tissue procedures that keep patients in the office. The patient's gingival health is improved in a minimally invasive, gentler manner. Every time the dentist picks up the diode laser the question is: where have you been all my life?_

Editorial note: The literature list can be requested from the author.

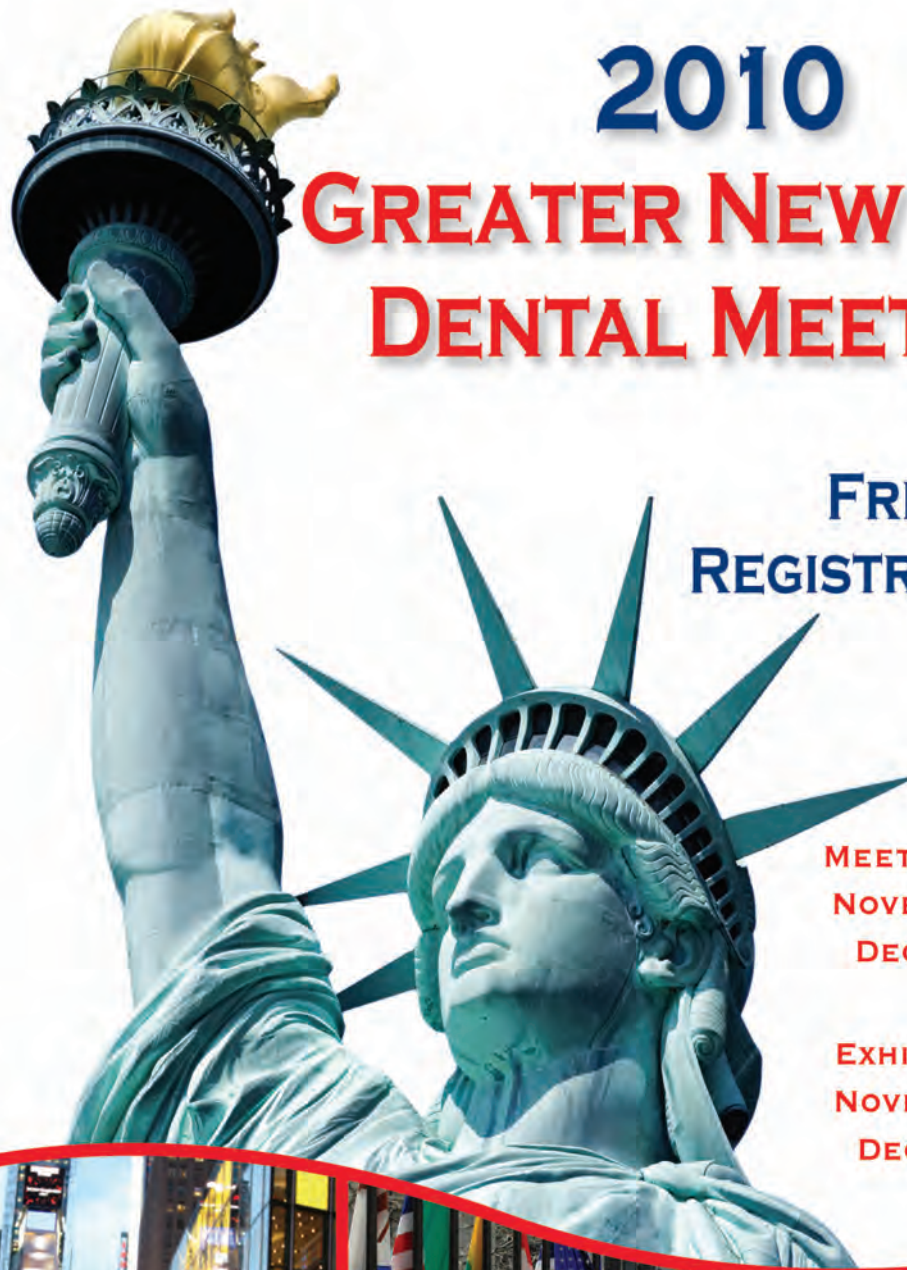_contact

laser

Dr Fay Goldstep

DDS, FACD, FADFE

E-mail: goldstep@epdot.com



2010

GREATER NEW YORK DENTAL MEETING

**FREE
REGISTRATION***

**MEETING DATES:
NOVEMBER 26 -
DECEMBER 1**

**EXHIBIT DATES:
NOVEMBER 28 -
DECEMBER 1**



86th
Annual Session

The
Largest
Dental
Convention/
Exhibition/
Congress
in the
United
States

**Free registration
before November 26*

Please send me more information about...

- ☐ Attending the Greater New York Dental Meeting
☐ Participating as a guest host and receiving free CE
☐ I speak _____ and am willing to assist international guests
enter language



Name _____

Address _____

City, State, Zip/Country Code _____

Telephone _____ E-mail _____

Fax or mail this to:
Greater New York Dental Meeting or
visit our website: www.gnydm.com for more information.



For More Information:
Greater New York Dental Meeting™
570 Seventh Avenue - Suite 800
New York, NY 10018 USA
Tel: +1 (212) 398-6922
Fax: +1 (212) 398-6934
E-mail: info@gnydm.com
Website: www.gnydm.com

From the **first** working **laser** until **now**—Part II

Javan, Basov, Hall, Holonyak, Zhores and others











Author_Ingmar Ingenegeren, Germany


In 1960, after the first working laser was made, Ali Javan (Fig.1), William Bennet Jr. and Donald Herriot succeeded in creating the first continuous wave laser using helium-neon stimulated by high voltage DC, producing 632,6 nanometer green light. Javan received the Albert Einstein Award in 1993. Together with Nikolai Basov Javan (Fig. 2) proposed the semiconductor laser concept in 1962. Basov was granted the Nobel Prize in Physics in 1964. In the same year, Alexander M. Prokhorov received the Nobel Prize for his pioneering work on lasers and masers.

Also in 1960, Peter P. Sokorin and Mirek J. Stevenson demonstrated a four stage solid state uranium laser at the IBM Thomas J. Watson Research Center.

In 1961, Elias Schnitzler first combines laser with optical fibers and reports the first operating neodymium glass laser. In 1962, Robert N. Hall (Fig. 4) demonstrated the first laser diode device, made of gallium arsenide emitting in the near-infrared band of the spectrum at 850 nm. He retired in 1987 having been granted 43 US patents during his career. Hall was elected to the National Academy of Engineering in 1977, and to the National Academy of Sciences in 1978 and was inducted into the National Inventors Hall of Fame in 1994.

In December 1961 a human patient received the first laser medical treatment at the Columbia-Presbyterian Hospital in Manhattan, by Dr. Charles J. Campbell of the Hospitals Institute of Ophthalmology and Charles D. Koester of the American Optical Corporation.

	1961	Implementation of a combination of lasers and optic fibers by E. Snitzer.
	1962	Development of a semiconductor laser by Robert N. Hall.
	1964	Nobel Prize in Physics for Charles Townes, Nikolai Bassow and Alexander Prochorow for the development of Masers and Lasers. William B. Bridges develops the argon ion laser. J. E. Geusic realised the stimulated emission of the Nd:YAG. Stern und Sognnaes started to try to remove concretions with a rubin laser. C. Kumar Patel develops the CO ₂ laser.
	1974	Zharikov et al. presented the Er:YAG laser as a solid state laser with a wave length of 2,940nm.
	1980er	Development of different pulsed laser systems.
	1988	1 st Congress of International Society of Laser Dentistry (ISLD, since 2006 WFLD—The World Federation for Laser Dentistry).
	1991	Foundation of Deutsche Gesellschaft für Laserzahnheilkunde e.V. (DGL).
	1992	Implementation of Er:YAG laser to laser dentistry.
	1997	FDA administration of the Er:YAG laser. It was the first laser which can be used for dentin in caries treatment.
	2010	Happy Birthday Laser!



In 1962, Nick Holonyak Jr. (Fig. 3) demonstrated the first semiconductor laser with a visible emission (LED). It could only be used in pulsed beam operation, and when cooled to liquid nitrogen temperature (77 K). Many colleagues have expressed their belief that he deserves the Nobel Prize for his invention of the LED. Holonyak commented: "It's ridiculous to think that somebody owes you something. We're lucky to be alive, when it comes down to it." Among other prizes like the Frederic Ives Medal of the Optical Society of America, Holonyak has been presented awards by George H.W. Bush, George W. Bush, Emperor Akihito of Japan and Vladimir Putin and in 1995, he was awarded the \$500,000 Japan Prize for his outstanding contributions to research and practical applications of light emitting diodes and lasers. In 2008, he was inducted into the National Inventors Hall of Fame.

The Neodymium laser was invented by Elias Schnitzer as the Nd:glass laser and first demonstrated by Joseph E. Geusic and Richard G Smith at the Bell Laboratories in 1962 as the yttrium aluminium garnet (YAG) laser. It became the most commonly used solid state laser. It is used for example for (endoscopic retrograde) surgery or metal melting and cutting in industry and dental laboratories. Also is appeared to be an excellent instrument for skin resurfacing and laser assisted in situ keratomileusis (lasik). To obtain a better beam quality the Nd:YAG laser could be pumped with diode lasers and in putting a KTP crystal in the laser beam, the frequency can be doubled, which means that the invisible near infrared Nd:YAG laser beam with 1,064 nm, then emits a visible green beam with 532 nm. These so called green light lasers, exist since 2002. Due to their absorption properties,


an operator can perform precise and bloodless operations.

In 1964, William B. Bridges of the Hughes Research Laboratories discovered and patented the pulsed noble gas ion laser (argon, krypton, xenon). He was president of the Optical Society of America in 1988. He worked on many projects using lasers: an airborne night reconnaissance system (AN/AVD-3), space communications systems, early high power laser weapons (the carbon dioxide gas dynamic laser, now extinct), hydrogen maser clocks for the global positioning system. In 1977, Bridges became Professor of Electrical Engineering and Applied Physics at Caltech; then the

Carl F Braun Professor of Engineering in 1983. He was president of the Optical Society of America in 1988.

Also in 1964, Stern and Sognnaes started investigations to remove caries with a ruby laser. As the absorption properties of the 694 nm ruby laser does not correspond well with the tooth material, and the results were very poor, later on, other lasers were tried for that purpose.

To be continued._



_contact

laser

drs. Ingmar Ingenegeren MSc MSc

Private Dental Laser Clinic
46240 Bottrop and
47608 Geldern, Germany
E-mail: Laser@praxis-ie.de
Web: www.praxis-ingenegeren-ewert.de

Graduation of the 10th year of **the master programme** “Lasers in Dentistry”

Author_Dajana Klöckner, Germany



_With the completion of the tenth course of the master programme “Lasers in Dentistry” participants celebrated their graduation from RWTH Aachen University on 24 April 2010. Ten graduates from six, mostly Arabic nations were awarded the master certificates in a festive ceremony.

After two days of stressful examinations the atmosphere was brilliant and the faces beamed of joy when the graduates received their certificates from the scientific director of the programme Prof Dr Norbert Gutknecht. During the ceremony he introduced every candidate and his/her master thesis topic. In his

closing address he pointed out that only through scientific backgrounds as well as theoretical and practical principles profound points of view on the current patient situation are possible and allow the right decisions for laser treatments. The most challenging parts in the future of laser dentistry are only be coped with excellent educated people.

Prof Dr Friedrich Lampert, Director of the Clinic of Periodontology, Conservative and Preventive Dentistry at the RWTH Aachen University Hospital, emphasized in his speech that it was a big challenge to go through a two-years study programme besides the daily practice. All participants handled it very well.

Mrs Dagmar Dirzus, General Manager of RWTH Aachen University, certified the graduates that they take along not only a lot of knowledge but also experiences out of the communications and exchange with their fellow students. They laid the foundations to an international network.

The study programme of the RWTH Aachen University in collaboration with the Aachen Dental Laser Center (AALZ) started the first course in 2004. 119 laser specialists graduated since and earned not only the title Master of Science in “Lasers in Dentistry” but also with the European master degree “Master of Oral Laser Applications”.

The Beginners from 2006 consciously decided to participate in this programme because they want to offer innovative and gentle treatments to their patients. Building on a university degree in dentistry, the necessary professional knowledge for laser applications in dental practice is taught at the highest academic level in theoretical and practical modules during this two-year extra occupational Master course. The internationality of this programme emphasized by the expertise of referees from all over the world.



Under the direction of Prof Gutknecht these experts teach scientific and practice oriented know-how. Thus, the participants gained an outstanding qualification for their daily practice. All important theories and application options pertaining to laser use in dentistry were taught. Skill training sessions, exercises, practical applications, live operations and workshops with intensive assistance from scientific associates with doctorates guide participants towards using lasers successfully and professionally in their own surgeries.

During the ten modules, the graduates remained in steady contact with the RWTH Aachen University and the lecturers between attendance days via the e-learning system. This kind of segmentation allowed them to remain active in their surgeries while getting their Master degree.

Four semesters, a master thesis and the compilation and presentation of clinical cases in Dubai and Aachen are left behind. "Now, we need new business cards" the graduates were happily mentioning after

successfully finishing their exams. They are now allowed to bear the official university degree of Master of Science.

During the following Gala dinner in the cellar of the Aachen town hall the graduates celebrated in a festive manner their deserved certification.

Upcoming courses

In 2010, the 12th and 13th courses are starting: The next programme starts on 26 September 2010 at the Ras Al Khaimah College of Dental Science (RAK CODS) at the RAK Medical Health Sciences University in the United Arab Emirates. The next start in Aachen will be on 8 September 2010.

_contact

laser

Mrs Dajana Klöckner

Tel.: +49 241 9632672

E-mail: kloeckner@aalz.de



First year of **Mastership Course “Lasers in Dentistry”** graduated successfully

Author_Dajana Klöckner, Germany



On 20 March 2010, 40 international dentists successfully finished the first course of the one-year Mastership Course on RWTH Aachen University. Among the participants were German, Swedish, Norwegian and Iranian laser specialists. The German dentists received a joint certificate from the RWTH Aachen University and the German Society for Laser Dentistry (DGL). The Scandinavian participants were coordinated by the local Scientific Coworker of AALZ Dr Peter Fahlstedt, MSc in Stockholm and obtained a certificate from the RWTH Aachen University and the Nordic Dental Laser Society (NDLS). The Iranian dentists were guided from the AALZ Scientific Coworker Dr Alireza Fallah, MSc. Both laser specialists successfully graduated in 2008 with the Master of Science degree “Lasers in Dentistry” from the RWTH Aachen University.

The Mastership Course is a one-year clinical specialisation course in laser dentistry. During 10 days of lectures the participants learnt the theoretical settings, clinical indications as well as the biophysical background (absorption and transmission in certain

tissues). Additionally, they applied and deepened their knowledge in Skill trainings and patient demonstrations. An e-learning system supported them between the modules.

In Module 1, an understanding of laser physics and laser safety was given. The participants received the Laser Safety Officer certificate (LSO) after successfully finishing the multiple-choice test. Back-



ground information and application possibilities of Nd:YAG laser and CO₂ laser mainly in the areas of endodontics, periodontics as well as hard- and soft tissue were given in Module 2. Er:YAG and Er,Cr:YSGG lasers and their applications in periodontics, soft tissue surgery and implantology were the topics in Module 3. Besides the theoretical part the participants attended skill trainings and patient demonstrations to get the learnt the closer.

The assignments of the last module were a written examination and the presentation of clinical cases. The participants showcased many very interesting and outstanding cases and laser application from their clinics. In the evening the certificates were awarded to the graduates in a solemnly ceremony at the Bloemendal



in Vaals, The Netherlands. Prof Dr Norbert Gutknecht, executive Director of the WFLD and Scientific Director of the programme handed out the certificates to every graduate. At the Gala dinner afterwards the Iranian New Year (Nouruz) was also celebrated. An important component of this celebration is the preparation of the Haft Sin (Seven "S"). Thereby, seven items are placed on a table that all starts with the Persian letter "S": Sekke (Coins, Money), Sib (Apple), Somagh (an acid Persian herb), Sonbol (Hyacinth), Sir (Garlic), Sabze (Wheat- or lentils scions) and Serke (Vinegar).

The third German Mastership Course has successfully started on June 16, 2010 in Iran.

_contact

laser

Mrs Dajana Klöckner

Tel.: +49 241 9632672

E-mail: kloekner@aalz.de

Cyprus invited out to laser

Author_Dajana Klöckner, Germany

In February AALZ Cyprus set a milestone in Laser education with the completion of three very successfully completed events. Two lectures with a total of 65 participants were held at the KES College in Nicosia for their Beautician students in the last semesters. AALZ Cyprus Ltd. is a research & training centre, which is located in Nicosia, Cyprus. It was founded to develop laser treatments in Cyprus. It is a franchise of the German AALZ (Aachen Dental Laser Center), a worldwide center with famous international professors as partners. Since its foundation in 1991 AALZ has been the leading specialist in the field of laser trainings and was the first dental laser education institute in Europe.

Furthermore, on 27 February 2010 the first Greek speaking Laser Safety Officer Seminar in Nicosia was concluded with 11 participants who have been awarded the Certificate as Laser Safety Officer (LSO), issued from the RWTH University Hospital in Aachen, Germany.

The participants came from different medical fields such as Physiotherapists, Plastic surgeons, Dermatologists and Beauticians. The seminar was held at the Hilton Hotel in Nicosia and everybody was highly motivated to follow the presentation of Dr. Yannikou, MSc, who succeeded to encourage everybody to learn more

about physics, biophysics, laser tissue interaction on the skin as well as Laser Safety measurements. The theoretical introduction was followed by a practical exercise on the laser at the Yiannikou Dental Clinic in Nicosia. The participants were able to carry out some practical experiments and complete the multiple-choice test in order to receive the certification as Laser Safety Officer. All participants did very well and gave very positive feedback about the organisation, presentation and structure of the seminar.

Due to strong demands from Laser users of different fields, additional seminars in English and Greek have been held in the meantime. The next course takes place on 26 June 2010 in Nicosia. Please contact Silke Rabe, Project Manager AALZ Cyprus for further information and registration._



_contact

laser

AALZ CYPRUS

Silke Rabe

Tel.: +357 992171-77

Fax: +357 22756-160

E-mail: aalzcypus@yahoo.com





***Lay the Foundations to your
successful Future now!***

The next master course starts on 08 September 2010



Master of Science (M.Sc.) in Lasers in Dentistry

Would you also like to be part of the International Dentists' Elite?

- *The first accredited M.Sc. programme in dentistry in Germany*
- *Career-accompanying postgraduate programme of two years at the University of Excellence RWTH Aachen*
- *Double degree: European M.Sc. in „Oral Laser Applications“ (EMDOLA)*
- *Internationally accepted and accredited by the German Government, the European Union, the Washington Accord and the Bologna Process*
- *Science-based and practice-orientated on highest national and international level*
- *Bronze Award of the European Union for „Life-Long Learning programmes“*



Aachen Dental Laser Center

More information:

AALZ GmbH · Pauwelsstrasse 19 · 52074 Aachen · Germany
Tel. +49 - 2 41 - 9 63 26 70 · Fax +49 - 2 41 - 9 63 26 71
www.aalz.de · info@aalz.de

In cooperation with the University
of Excellence RWTH Aachen

**RWTHAACHEN
UNIVERSITY**

UAE International Dental Conference & Arab Dental Exhibition

WFLD took part at AEEDC 2010

Under the theme of "Oral Health Progress" the UAE International Dental Conference & Arab Dental Exhibition—AEEDC Dubai 2010 concluded with tremendous success and recognition from various organizations globally. AEEDC Dubai is highly acclaimed for its continuous growth year on year. This year's achievements at AEEDC Dubai included more partnerships and support from major dental companies, associations and institutions. AEEDC Dubai continues to be the no. 1 meeting place for the best science, innovations and business opportunities in the Middle East and North Africa region.

"Dubai managed to impose itself as a strong competitor in holding high profile conferences and exhibitions in a very short period of time. Dubai possess the perfect structures and facilities to present the best international conferences and exhibitions." Index Conferences and Exhibitions Organisation Est. is achieving great success in this regard."

Dr Roberto Vianna,
President of the World Dental
Federation (FDI)

international representatives during the traditional inauguration and the ribbon cutting ceremony. HH Sheikh Hamdan toured the exhibition halls, and viewed the latest dental technologies, innovations and equipment showcased by over 800 exhibiting companies from 65 countries.

AEEDC Dubai Conference

AEEDC Dubai Conference is the most significant annual meeting for regional and international dental professionals to attend in the MENA region. Every year, the AEEDC scientific program focuses more on diverse educational

HH Sheikh Hamdan Bin Rashid Al Maktoum, Deputy Ruler of Dubai, Minister of Finance and President of Dubai Health Authority was accompanied by a number of ministers and local and in-

activities and the most relevant topics offering, the best scientific education and information. The conference has run over three days attending in three concurrent sessions with more than 6,000





professional conference delegates. Around 110 regional and international distinguished speakers presented and contributed to the success of this scientific meeting. The conference program has received accreditation from five highly regarded accreditation bodies.

This year's conference, the participation has increased to 25 per cent and observed an increased number of participation from international attendees. AEEDC Dubai conference remains the premier dental meeting in the MENA region providing the most advanced educational programs and integrated solutions.

_WFLD Dubai Congress

AEEDC Dubai hosted for the first time the World Federation of Laser Dentistry Congress—WFLD for a period of three days from 9–11 March 2010, where more than 140 speakers presented at two concurrent sessions. The attendance reached more than 500 profes-

sional conference delegates. Approximately 80 posters were displayed during the event.

_AEEDC Dubai Night 2010

„The exhibition and participation turn out to be very great success for our companies and to the members of the German Associations participated here. The members of the German Pavilion were very satisfied with the talks with the dentists from the Arabian world and representatives of the dental trade. This is a great success and one of the best opportunity throughout the Arabian world. The conference organized in a professional and excellent way, everybody feels comfortable here and had opportunities to do business.“

Dr Markus Heibach, Managing Director, VDDI Association of German Dental Manufacturers

AEEDC Dubai Night was held at the Grand Hyatt Dubai, Baniyas Ballroom on 10th of March 2010. The special evening also celebrated the 20 years achievements of INDEX Conferences & Exhibitions Organisation Est. (Member of INDEX Holding). Mr Abdul Salam Al Madani, Executive Chairman of AEEDC Dubai and President of INDEX Holding marked the occasion with his welcome address.

The main highlight of the evening was the launch of the INDEX 2020 logo, honored by the presence of HH Sheikh Majid Bin Mohammed Bin Rashid Al Maktoum, Chairman of Dubai Culture and Arts Authority, with HE Qadhi Saeed Al Murooshid, Director General of Dubai Health Authority, Mr Abdul Salam Al Madani, Executive Chairman of AEEDC Dubai and President of INDEX Holding, and Mr Tariq Al Madani, Director of bigdot (member of INDEX Holding).

The evening program was made even more exciting and unique with the traditional UAE local band, Oud player, saxophonist, Jordanian traditional band, henna painting, calligraphic artists and traditional Arabic tent. To find out more about 2020 INDEX vision and 20 years of achievements, please contact INDEX Media (member of INDEX Holding).



International events

2010

IADR 88th General Session & Exhibition

Where: Barcelona, Spain
Date: 14–17 July 2010
E-mail: sherren@iadr.org
Website: www.iadr.org

FDI Annual World Dental Congress

Where: Salvador da Bahia, Brazil
Date: 02–05 September 2010
Website: www.fdiworldental.org

40th International Congress of DGZI

Where: Berlin, Germany
Date: 01 & 02 October 2010
Website: www.dgzi.de

19th Annual Scientific Meeting of EAO

Where: Glasgow, Scotland
Date: 06–09 October 2010
Website: www.eao.org

Annual Congress of DGL

Where: Berlin, Germany
Date: 29 & 30 October 2010
Website: www.dgl-online.de

LASER START UP 2010

Where: Berlin, Germany
Date: 29 & 30 October 2010
Website: www.startup-laser.de

International Laser Dentistry Symposium

Where: Sydney, Australia
Date: 1 & 2 November 2010
Website: www.wfld-org.info

Greater New York Dental Meeting

Where: New York, NY, USA
Date: 26 November–1 December 2010
Website: www.gnydm.org

2011

34th International Dental Show

Where: Cologne, Germany
Date: 22–26 March 2011
E-mail: ids@koelnmesse.de
Website: www.ids-cologne.de

3rd European Congress World Federation for Laser Dentistry (WFLD)

Where: Rome, Italy
Date: 10 & 11 June 2011
Website: www.wfld-org.info

2012

LaserOptics Berlin

Where: Berlin, Germany
Date: 19–21 March 2012
Website: www.laser-optics-berlin.de



submission guidelines:

Please note that all the textual components of your submission must be combined into one MS Word document. Please do not submit multiple files for each of these items:

- _ the complete article;
- _ all the image (tables, charts, photographs, etc.) captions;
- _ the complete list of sources consulted; and
- _ the author or contact information (biographical sketch, mailing address, e-mail address, etc.).

In addition, images must not be embedded into the MS Word document. All images must be submitted separately, and details about such submission follow below under image requirements.

Text length

Article lengths can vary greatly—from 1,500 to 5,500 words—depending on the subject matter. Our approach is that if you need more or less words to do the topic justice, then please make the article as long or as short as necessary.

We can run an unusually long article in multiple parts, but this usually entails a topic for which each part can stand alone because it contains so much information.

In short, we do not want to limit you in terms of article length, so please use the word count above as a general guideline and if you have specific questions, please do not hesitate to contact us.

Text formatting

We also ask that you forego any special formatting beyond the use of italics and boldface. If you would like to emphasise certain words within the text, please only use italics (do not use underlining or a larger font size). Boldface is reserved for article headers. Please do not use underlining.

Please use single spacing and make sure that the text is left justified. Please do not centre text on the page. Do not indent paragraphs, rather place a blank line between paragraphs. Please do not add tab stops.

Should you require a special layout, please let the word processing programme you are using help you do this formatting automatically. Similarly, should you need to make a list, or add footnotes or endnotes, please let the word processing programme do it for you automatically. There are menus in every programme that will enable you to do so. The fact is that no matter how carefully done, errors can creep in when you try to number footnotes yourself.

Any formatting contrary to stated above will require us to remove such formatting before layout, which is very time-consuming. Please consider this when formatting your document.

Image requirements

Please number images consecutively throughout the article by using a new number for each image. If it is imperative that certain images are grouped together, then use lowercase letters to designate these in a group (for example, 2a, 2b, 2c).

Please place image references in your article wherever they are appropriate, whether in the middle or at the end of a sentence. If you do not directly refer to the image, place the reference at the end of the sentence to which it relates enclosed within brackets and before the period.

In addition, please note:

- _ We require images in TIF or JPEG format.
- _ These images must be no smaller than 6x6 cm in size at 300 DPI.
- _ These image files must be no smaller than 80 KB in size (or they will print the size of a postage stamp!).

Larger image files are always better, and those approximately the size of 1 MB are best. Thus, do not size large image files down to meet our requirements but send us the largest files available. (The larger the starting image is in terms of bytes, the more leeway the designer has for resizing the image in order to fill up more space should there be room available).

Also, please remember that images must not be embedded into the body of the article submitted. Images must be submitted separately to the textual submission.

You may submit images via e-mail, via our FTP server or post a CD containing your images directly to us (please contact us for the mailing address, as this will depend upon the country from which you will be mailing).

Please also send us a head shot of yourself that is in accordance with the requirements stated above so that it can be printed with your article.

Abstracts

An abstract of your article is not required.

Author or contact information

The author's contact information and a head shot of the author are included at the end of every article. Please note the exact information you would like to appear in this section and format it according to the requirements stated above. A short biographical sketch may precede the contact information if you provide us with the necessary information (60 words or less).

Questions?

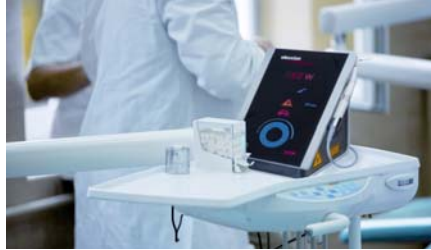Eva Kretzschmann
e.kretzschmann@oemus-media.de

Manufacturer News

elexxion

A promising future ahead

elexxion AG, a specialist in the development, manufacture and sale of dental laser systems, increased its basic share capital to € 6,005,645 in February 2010. By increasing its capital in this way, it managed to raise € 1,801,693 in liquid funds. According to experts, this will be sufficient to secure the company's long-term further development. Discussing the move, Per Liljenqvist, Chairman of the



Board of Directors at elexxion AG, said: "We are delighted to have taken these steps which will allow us to channel all our energy into ensuring continued company growth and developing new, innovative

products." Through consistently developing its products and offering ongoing further training, elexxion AG has evolved into one of the most successful laser manufacturers in Germany. The specialists from Lake Constance offer a range of up-to-the-minute products which cater for virtually all dental laser needs.

elexxion AG

Schützenstrasse 84
78315 Radolfzell, Germany
E-Mail: info@elexxion.com
Web: www.elexxion.com

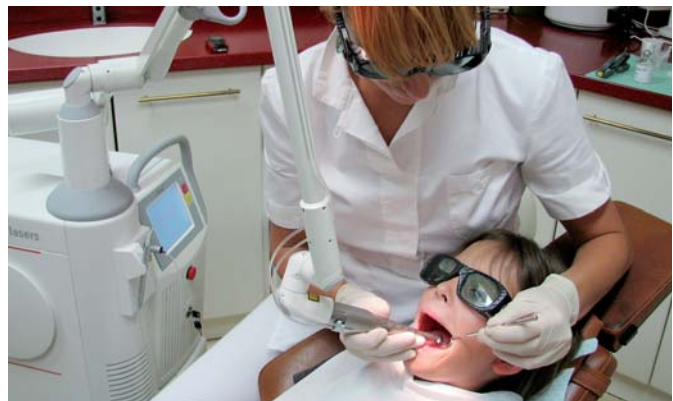Fotona

New minimally invasive periodontal disease treatment optimizing dentistry's two best laser wavelengths

Fotona has co-developed Wavelength-optimized Periodontal Therapy™ (WPT™) with US partner Lares Research. WPT™ is a minimally invasive method for treating periodontal disease using fully optimized Nd:YAG and Er:YAG laser with the AT Fidelis.

In a first treatment phase the Nd:YAG laser is used to remove the diseased epithelial lining and improve access to the root service. The AT Fidelis' Er:YAG laser energy is then used to accurately and thoroughly remove calculus from the root surface. The last step is using the Nd:YAG laser to coagulate and leave a stable fibrin clot.

Wavelength-optimized Periodontal Therapy™ creates the optimal conditions for healing periodontal disease by removing the diseased epithelial lining of the periodontal pocket, removing calculus from the root surface and sealing the pocket after treatment with a stable fibrin clot. Treatment acceptance is extremely high considering the scalpel/suture treatment alternative. Fotona of-



fers a complete range of procedure optimized fiber tips and handpieces for its AT/HT Fidelis line of highest performance dental laser treatment platforms.

Fotona d.d.

Stegne 7
SI-1210 Ljubljana, Slovenia
Web: www.fotona.com

AMD Lasers

It's time to laser

AMD LASERS, LLC is the global leader in providing ultra-affordable laser technology for dental professionals who desire to take their practice to the next level. AMD LASERS, proudly announces that dental practitioners now have the option of using disposable tips or a strippable fiber with the #1 selling dental lasers in the world—Picasso and Picasso Lite. This marks just another breakthrough



in technology by AMD LASERS as Picasso and Picasso Lite are the only diode lasers to offer dentists two tip options. To celebrate this achievement AMD is offering a special new office price for Picasso Lite. If you've been waiting for the right moment to practice the Fine Art of Laser Dentistry—now is the time!

AMD LASERS™, LLC.

7405 Westfield Blvd.
IN 46240 Indianapolis, USA
Web: www.amdlasers.com

NMT

Syneron Dental at the IDEM 2010

Syneron Dental, the manufacturer of the LITETOUGH laser with its revolutionary laser-in-the-hand-piece technology made an impressive new appearance during the IDEM in Singapore. „Express your mastery“ is the slogan with which the upcoming company addressed itself to distribution partners and dentists. At the distributor meeting on 15th April in the top-class Conrad Hotel the president of Syneron Dental Division, who has been in office since the end of last year, presented his ambitious goals:

Syneron Dental is to be the leading dental manufacturer worldwide due to: Technological leadership, which the company already holds with LITETOUGH, complete customer focus, which means fast response and innovation to customer wishes and suggestions International recognition in both scientific and practically-based progress reports Insertion of the financial power of the parent company, which has become market leader in the cosmetic-aesthetic field, since its merger with the renowned company Candela additional market developments in Europe, Asia and America by the year 2011. As a feature of the new marketing campaign, visitors were given the chance to try out their artistic skills, using pens placed in the hand-piece.

More than 50 dentists from the most diverse countries attended the first ever clinical course, where they had the opportunity to listen to lecturers from Switzerland, Germany, Bulgaria, Taiwan and Japan. These experts elaborated on the advantages of laser treatment in a modern dental surgery and, in particular, of working with the LITETOUGH.

Dr Bader from Switzerland, a recognized laser expert, drew up a list of the main requirement criteria for the choice of an erbium laser with which to work most effectively:

Power, which is also to be considered depending on its application and pulse duration Good water spray, which speeds up the process of hard tissue removal and diminishes possible thermic side-effects pulse duration and pulse form, very short pulse for the effective treatment of hard tissue, long pulse to enable work on soft tissue with as little haemorrhaging as possible transmittance of the laser light, direct and hollow-shaft transmittance bring about an optimal radiation profile, due to the even distribution of the beams tips and hand-piece should be designed for fast contact and for the spectrum of possible indications Other speakers emphasized the superiority of laser-supported treatments, in particular of those carried out using the LITETOUGH, for example in the areas of implantology and in “normal” cavity preparation, and also in periodontal treatment. The partic-



Participants of the distributors meeting.



Dr Bader, University Geneva lecturing.

ipants were presented with their certificates during a festive gala dinner.

At the distributor meeting, as Syneron's sales partner, NMT München presented the very latest research findings from the University of Vienna on the surface character of a tooth after treatment with the LITETOUGH on various settings. The finding which caused the most amazement of all was the absolutely spotless surface structure with its open dentinal tubules, which guarantee the ideal adhesion of fillings.

The opportunity presented by this event to share experiences with colleagues provided a significant enrichment for each of the participant's daily work. Syneron will proactively encourage this kind of exchange in the future. There is much to be excited about and to look forward to: upcoming events include, for example, a training course in Israel for German users and interested parties from 31st August.

**NMT Neue Medizintechnik
München GmbH**

Flurstr. 5
82166 Gräfelfing, Germany
E-mail: info@nmt-muc.de
Web: www.nmt-muc.de



T. Koop, NMT lecturing in distributors' meeting.



Awarding of the certificate to Prof Dr Volker Black, by Ira Prigat, President of Syneron Denal (left) and Thomas Koop, general manager NMT Munich (right).

Publisher

Torsten R. Oemus
oemus@oemus-media.de

CEO

Ingolf Döbbecke
doebbecke@oemus-media.de

Members of the Board

Jürgen Isbaner
isbaner@oemus-media.de

Lutz V. Hiller

hiller@oemus-media.de

Chief Editorial Manager

Norbert Gutknecht
ngutknecht@ukaachen.de

Managing Editors

Georg Bach
Leon Vanweersch

Division Editors

Matthias Frenzen
European Division

George Romanos
North America Division

Carlos de Paula Eduardo
South America Division

Toni Zeinoun
Middle East & Africa Division

Loh Hong Sai
Asia & Pacific Division

Senior Editors

Aldo Brugneira Junior
Yoshimitsu Abiko
Lynn Powell

John Featherstone

Adam Stabholz

Jan Tuner

Anton Sculean

Editorial Board

Marcia Martins Marques, Leonardo Silber-
man, Emina Ibrahim, Igor Cernavin, Daniel
Heysselaer, Roeland de Moor, Julia Kame-
nova, T. Dostalova, Christliebe Pasini, Peter
Steen Hansen, Aisha Sultan, Ahmed A Has-
san, Marita Luomanen, Patrick Maher, Marie
France Bertrand, Frederic Gaultier, Antonis
Kallis, Dimitris Strakas, Kenneth Luk, Mukul
Jain, Reza Fekrazad, Sharonit Sahar-Helft,
Lajos Gaspar, Paolo Vescovi, Marina Vitale,
Carlo Fornaini, Kenji Yoshida, Hideaki Suda,
Ki-Suk Kim, Liang Ling Seow, Shaymant
Singh Makhani, Enrique Tevino, Ahmed Kabir,
Blanca de Grande, José Correia de Campos,
Carmen Todea, Saleh Ghabban Stephen Hsu,
Antoni Espana Tost, Josep Arnabat, Ahmed
Abdullah, Boris Gasparic, Peter Fahlstedt,
Claes Larsson, Michel Vock, Hsin-Cheng Liu,
Sajee Sattayut, Ferda Tasar, Sevil Gurgan,
Cem Sener, Christopher Mercer, Valentin
Preve, Ali Obeidi, Anna-Maria Yannikou,
Suchetan Pradhan, Ryan Seto, Joyce Fong,
Ingmar Ingenegeren, Peter Kleemann, Iris
Brader, Masoud Mojahedi, Gerd Volland, Ga-
briele Schindler, Ralf Borchers, Stefan Grü-
mer, Joachim Schiffer, Detlef Klotz, Herbert
Deppe, Friedrich Lampert, Jörg Meister, Rene
Franzen, Andreas Braun, Sabine Sennhenn-
Kirchner, Siegfried Jänicke, Olaf Oberhofer,
Thorsten Kleinert

Executive Producer

Gernot Meyer
meyer@oemus-media.de

Designer

Sarah Fuhrmann
s.fuhrmann@oemus-media.de

Customer Service

Marius Mezger
m.mezger@oemus-media.de

Published by

Oemus Media AG
Holbeinstraße 29
04229 Leipzig, Germany
Tel.: +49 341 48474-0
Fax: +49 341 48474-290
kontakt@oemus-media.de
www.oemus.com

Printed by

Messedruck Leipzig GmbH
An der Hebmärchte 6
04316 Leipzig, Germany

laser

international magazine of laser dentistry
is published in cooperation with the World
Federation for Laser Dentistry (WFLD).

WFLD President

University of Aachen Medical Faculty
Clinic of Conservative Dentistry
Pauwelsstr. 30
52074 Aachen, Germany
Tel.: +49 241 808964
Fax: +49 241 803389644
ngutknecht@ukaachen.de
www.wfld-org.info

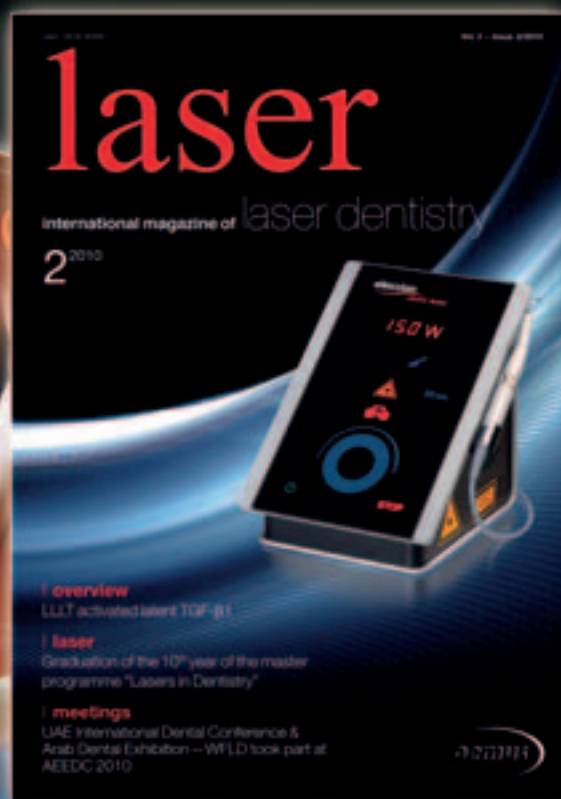
Copyright Regulations

The **laser** international magazine of laser dentistry is published by Oemus Media AG and will appear in 2010 with one issue every quarter. The magazine and all articles and illustrations therein are protected by copyright. Any utilization without the prior consent of editor and publisher is inadmissible and liable to prosecution. This applies in particular to duplicate copies, translations, microfilms, and storage and processing in electronic systems.

Reproductions, including extracts, may only be made with the permission of the publisher. Given no statement to the contrary, any submissions to the editorial department are understood to be in agreement with a full or partial publishing of said submission. The editorial department reserves the right to check all submitted articles for formal errors and factual authority, and to make amendments if necessary. No responsibility shall be taken for unsolicited books and manuscripts. Articles bearing symbols other than that of the editorial department, or which are distinguished by the name of the author, represent the opinion of the afore-mentioned, and do not have to comply with the views of Oemus Media AG. Responsibility for such articles shall be borne by the author. Responsibility for advertisements and other specially labeled items shall not be borne by the editorial department. Likewise, no responsibility shall be assumed for information published about associations, companies and commercial markets. All cases of consequential liability arising from inaccurate or faulty representation are excluded. General terms and conditions apply, legal venue is Leipzig, Germany.

laser

international magazine of laser dentistry



Subscribe now!

One issue free of charge!

☐ I hereby agree to receive a free trial subscription of **laser international magazine of laser dentistry** (4 issues per year).

I would like to subscribe to cosmetic dentistry for € 44* for German customers, € 46* for customers outside Germany, unless a written cancellation is sent within 14 days of the receipt of the trial subscription. The subscription will be renewed automatically every year until a written cancellation is sent to OEMUS MEDIA AG, Holbeinstr. 29, 04229 Leipzig, Germany, six weeks prior to the renewal date.

Last Name, First Name

Company

Street

ZIP/City/County

E-mail

Signature

Notice of revocation: I am able to revoke the subscription within 14 days after my order by sending a written cancellation to OEMUS MEDIA AG, Holbeinstr. 29, 04229 Leipzig, Germany.

Signature

► **Reply** per Fax +49 341 48474-290 to OEMUS MEDIA AG or per E-mail to grasse@oemus-media.de

Holbeinstr. 29, 04229 Leipzig, Germany, Tel.: +49 341 48474-0, Fax: +49 341 48474-290, E-Mail: grasse@oemus-media.de

OEMUS MEDIA AG



A.R.C.
LASER

LASER...INNOVATION
MADE IN GERMANY

FOX

- Power calibration at distal end
- Green aiming beam
- Touch screen
- Video screen capability



www.arclaser.de