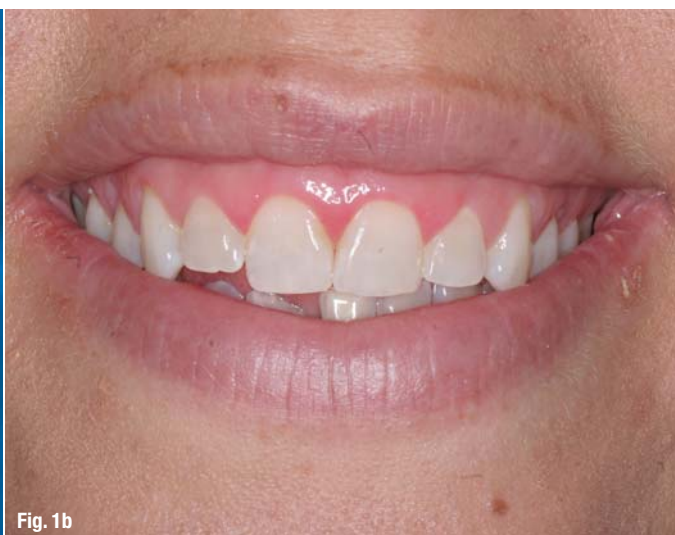

# Bite alteration for reducing gummy smiles: Two case reports

Author \_ Dr David S. Frey, USA



**The traditional method** for correcting a gummy smile with too high a gum-to-teeth ratio is enormously invasive. It involves cutting and lifting the gum tissue back in order to remove bone, after which the gums have to be sewn back in place.

This process requires a six- to eight-week healing process, which is not only painful<sup>1</sup>, but also aesthetically displeasing. Another method, which involves repositioning the lip after cutting into the vestibule, is equally invasive and requires an excessively long period of healing.<sup>2</sup>

Today, cosmetic dentists often perform a gingivectomy utilising a scalpel, electrosurge or diode laser in order to correct an overly gummy smile. However, these methods are contingent upon the amount of biological width available in the patient.<sup>3</sup>

Two to three millimetres of gum tissue must remain over the bone after the tissue has been

removed. This biological width limitation usually creates one of two options. Either the patient must be subjected to invasive surgical gum flaps accompanied by bone removal or the patient must be satisfied with very little change in the gum-to-teeth ratio. If the patient presents with a significantly short vertical index (VI; measured from the cemento-enamel junction [CEJ] of tooth #8 or 9 to the CEJ of tooth #24 or 25), the gummy smile condition may not be satisfactorily corrected when only a gingivectomy is performed.

Cosmetic dentists undertake regular training to adjust horizontal smile abnormalities such as overcrowding and large gaps. The idea of changing the vertical dimension of occlusion as part of improving dento-facial aesthetics is not new.<sup>4</sup> While occlusal philosophies may differ, most will agree that the occlusion must be given careful consideration when changing its vertical dimension, both as part of the diagnostic process and to avoid possible iatrogenic results.

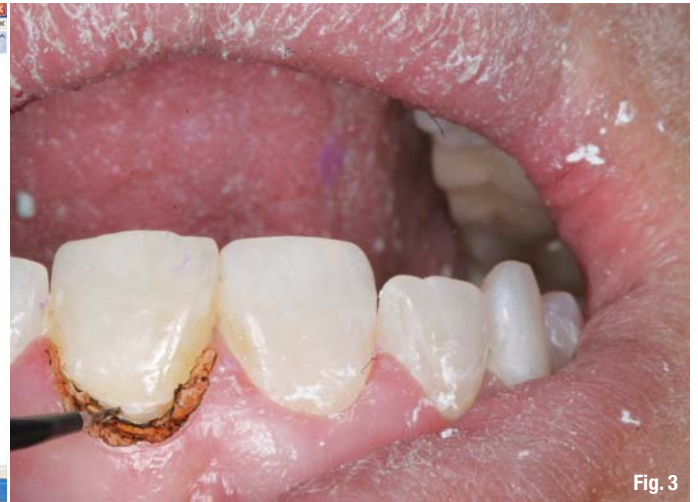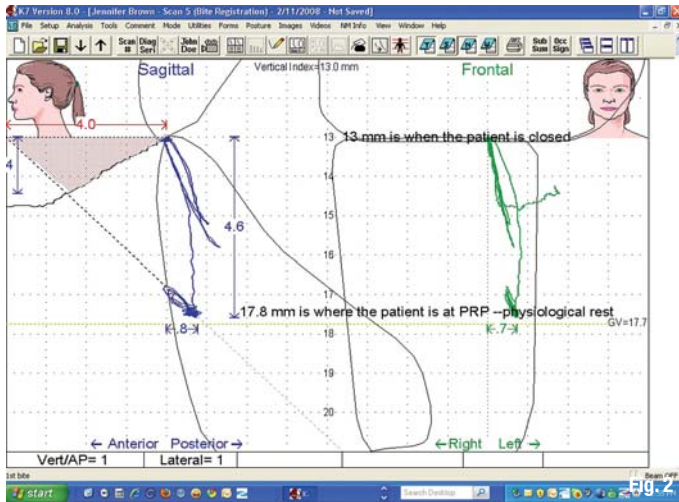


Fig. 3

When the patient presents with a significant difference between the mandibular position at habitual occlusion relative to an optimised occlusal position, increasing vertical dimension by increasing the crown-to-gum ratio and effectively decreasing the gummy smile can have a dramatic cosmetic effect on a patient. The cases presented here illustrate that vertical abnormalities such as gummy smiles may sometimes be further enhanced and the need for surgical intervention minimised if the vertical dimension of the bite is altered.

In adjusting the vertical dimension, care must be taken to ensure a functional occlusion in the finished case. Jankelson described the method for muscle relaxation in order to determine mandibular position at true physiological rest.<sup>5</sup> Application of transcutaneous electrical nerve stimulation (J5 Myomonitor TENS, Myotronics) for a period of 30 to 40 minutes allows the muscles of mastication innervated by cranial nerves #5 and 7 to relax.

While there is no universal agreement amongst dentists on occlusal philosophy, I have found the Jankelson method of establishing a true mandibular physiological rest position (PRP) to be highly effective. Physiological rest position is objectively verified with surface electromyography and computerised jaw tracking (K7 Evaluation System, Myotronics).

The K7 System provides calculations that indicate when the patient is at physiological rest as compared with habitual rest. These calculations indicate the extent to which VI can be increased or the extent to which freeway space can be decreased without interrupting the patient's true PRP.

Concerns about changing the entire arch to effect anterior defects are unfounded for two reasons. Firstly, the newly diagnosed mandibular position is verified as correct by using an orthotic before anything is done to the natural teeth. Secondly, this technique of treating a

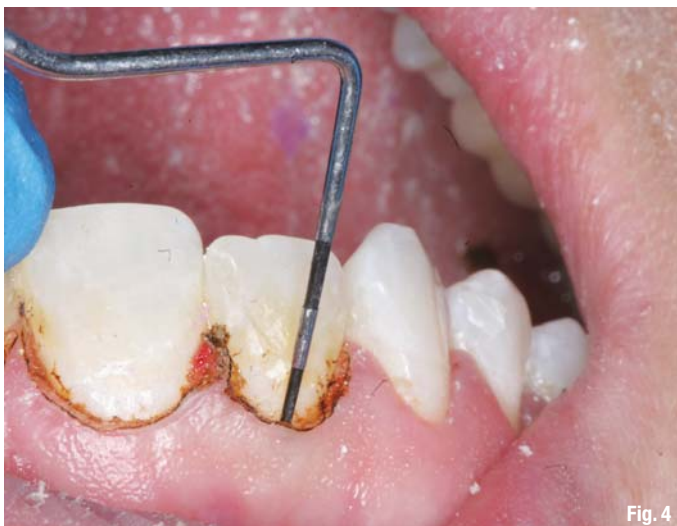

Fig. 4

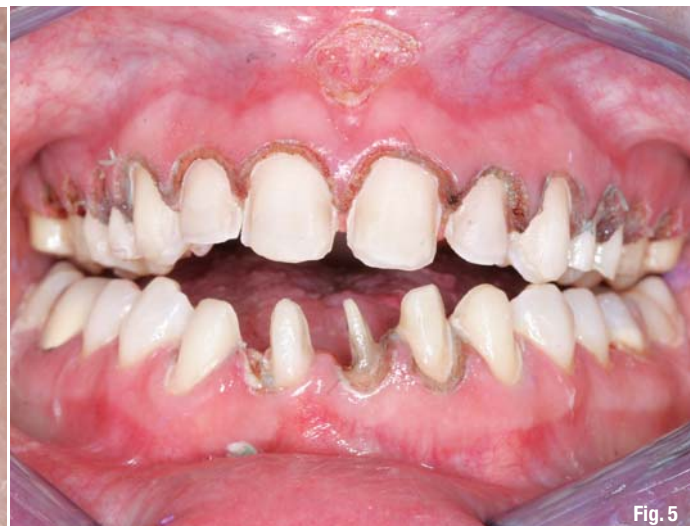

Fig. 5





Fig. 6

gummy smile is based upon opening the bite. Therefore, when porcelain is added to the full arch to increase vertical dimension, it involves little to no destruction of the natural dentition because the restorations are placed over the occlusal surface.

In my experience and as illustrated in these cases, once the PRP of the mandible has been established, the increased gum-to-teeth ratio is significant prior to the removal of any gum tissue. It is prudent to mention here that if the patient's PRP does not differ significantly from habitual rest after TENS relaxation, very little change in vertical dimension would be available for this procedure.

Use of the Golden Proportion to establish a pleasing aesthetic effect has been seen in art, architecture and various scientific fields for centuries and used in dentistry for at

least 25 years.<sup>6</sup> Like occlusal philosophy, some question its validity.<sup>7,8</sup> However, it is used by many today in plastic surgery, orthodontics and aesthetic dentistry as an aspect of treatment planning for facial aesthetics and, in my experience, patients are highly pleased with the outcome.

Calculations utilising the Golden Proportion equation can also be applied to tooth shape and will indicate whether the 'golden' VI can be reached through a combination of bite correction and gingivectomy. These simple calculations indicate whether the vertical length of the patient's smile will be more aesthetically pleasing after the corrections have been made:

$\text{Width of central incisor} \div 1.618 = \text{golden length of central incisor}$

$\text{Length of central incisor} \times 1.618 = \text{golden VI}$

Based on these two calculations, an orthotic in the optimal bite position for both aesthetics and function can be fitted for the patient's upper teeth. The orthotic is worn for approximately one month in order to be certain that no headaches, neck pain, grinding or chewing issues ensue. This period also provides the patient with time to become psychologically accustomed to the additional tooth length that shows prior to the gingivectomy and application of veneers. If the patient is dissatisfied with the length-to-width ratio of the teeth in the orthotic, adjustments can be made to the orthotic before beginning the procedure.

Correcting the bite before performing a gingivectomy can offer a greater aesthetic result, significantly reducing the amount of gum tissue that shows before a gingivectomy is performed.



Fig. 7a

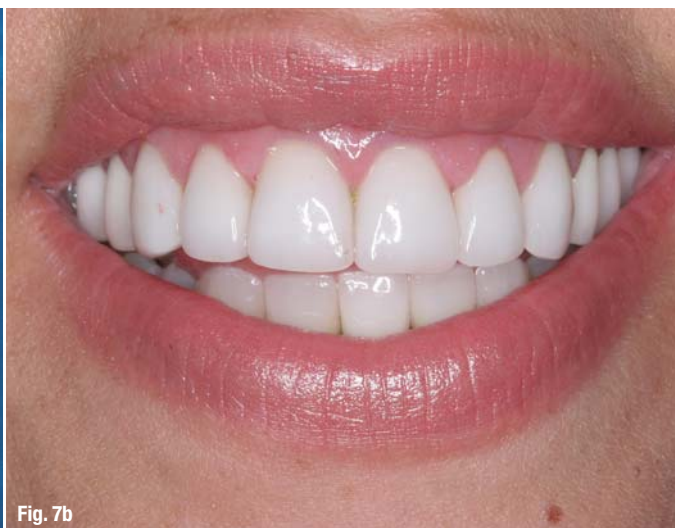

Fig. 7b

It should be noted that placement of porcelain on the molar teeth to increase vertical height is extremely conservative because the porcelain lies on top of the existing teeth.

Even if the available biological width is significant, correcting the bite allows the dentist to remove less gum tissue during the gingivectomy. A frenectomy can also be performed, when appropriate, to remove a small portion of the lip frenulum with a diode laser. This allows the lip to move down slightly over the previously exposed gums and can also reduce the amount of gum tissue that must be removed during the gingivectomy.

### \_Case I

A 27-year-old female presented with 13 mm VI, requesting that her gummy smile be corrected or reduced. The average VI is 17 to 21 mm. Therefore, her VI would be aesthetically pleasing if increased by a minimum of 4 mm, reducing the gum-to-teeth ratio.

The patient's teeth were out of proportion, with the length-to-width ratio of the central incisors almost identical, rather than the aesthetically pleasing length-to-width ratio of 75 to 80 per cent. Her gums were inflamed and in poor condition. Therefore, she was first referred to a hygienist for cleaning, root planing, deep scaling and debriding (Figs. 1a & b).

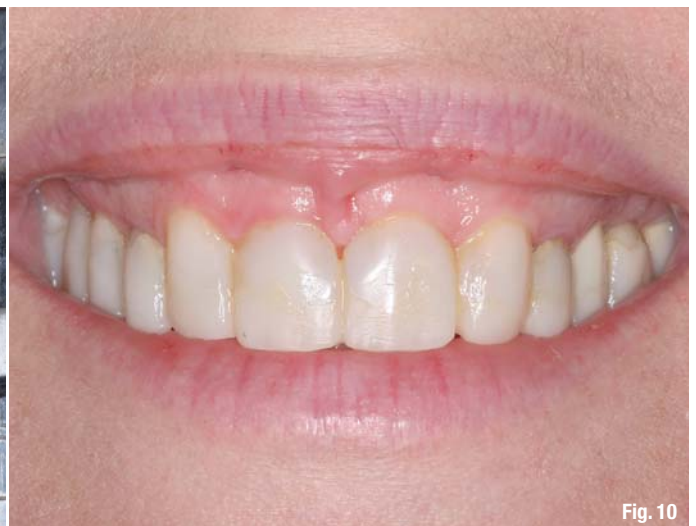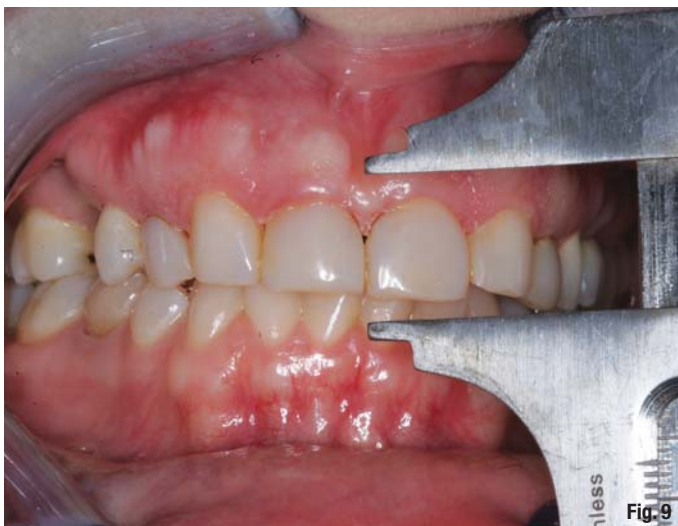At physiological rest, the K7 Evaluation System calculated that the patient's VI was increased to 17 mm before any gum tissue was removed. The gum-to-teeth ratio had already been increased significantly. The Golden Proportion equations were also utilised. The patient's



golden VI was calculated at 16.7 mm, and the orthotic gave her a VI of 17 mm (Fig. 2).

It was determined that the patient would have an even greater aesthetic result by further increasing the gum-to-teeth ratio. Sounding determined that 2 mm of gum tissue could be removed safely, so an additional 2 mm was burned away utilising a diode laser. The diode laser immediately cauterises the tissue and causes less bleeding and less post-operative stress for the patient than other gingivectomy methods. As demonstrated in Figure 3, gum tissue had been removed from three teeth, showing the additional vertical length compared to the remaining teeth. The healing process following the diode laser gingivectomy is approximately two weeks.

Sounding indicated that a gingivectomy alone would have allowed for the removal of no





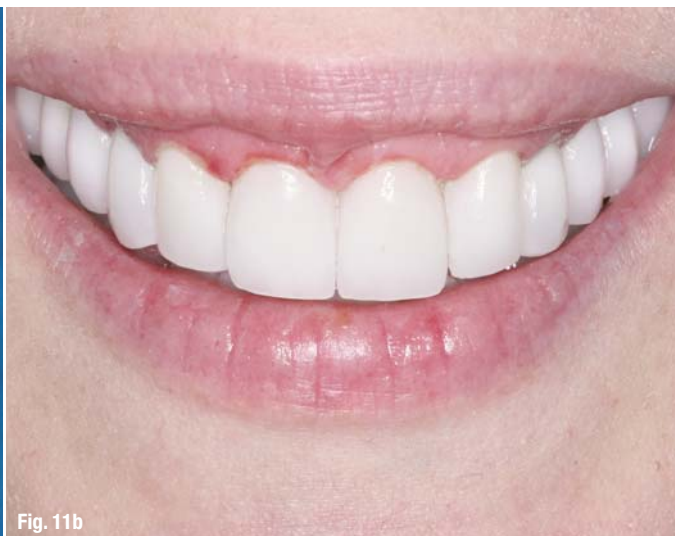

Fig. 11a

Fig. 11b

more than 2 mm of gum tissue. In this case, the patient's VI would have increased only to 15 mm, leaving her with a gummy smile even after the procedure was completed (Fig. 4).

After administering a local anaesthetic, a frenectomy was performed on the patient to further release the upper lip and reduce the gum-to-teeth ratio (Fig. 5).

The bite was checked again and the temporaries were applied. The final VI increase for the patient following the bite correction, frenectomy and gingivectomy was 6 mm, increasing the VI from 13 to 19 mm. While the increase could have remained at 17 mm, the additional 2 mm was an aesthetic improvement (Fig. 6).

After the veneers had been applied and the gums healed, the patient showed an exceptional reduction in her gummy smile, as well as increased gum health with proper stippling (Figs. 7a & b).

## \_Case II

A 37-year-old female patient presented with a 12 mm VI and complaints of an overly gummy smile (Fig. 8). Although her gums were healthy, she was referred to a hygienist for a thorough cleaning prior to treatment.

The patient's central incisors were 9 mm wide, while the Golden Proportion was 11.6 mm. The patient's golden VI, therefore, was 18.8 mm, which was an increase of 6.8 mm from her current VI. Measurements of the patient's teeth showed that the length-to-width ratio was almost identical (Fig. 9).

The Myomonitor and K7 Bite Evaluation System determined that the patient's bite could be opened to a VI of 17 mm, which was a significant increase of 5 mm from her original VI. The patient wore an orthotic for one month, after which her bite was re-checked and temporary teeth applied (Fig. 10).

Sounding determined that 2 mm of gum tissue could safely be removed. After a frenectomy and gingivectomy utilising the diode laser, 2 mm of tissue was removed, further increasing the patient's VI to 19 mm, allowing for an exceptional correction to the gummy smile condition of 7 mm from the original 12 mm VI (Figs. 11a & b).

*Editorial note: A complete list of references is available from the publisher.*

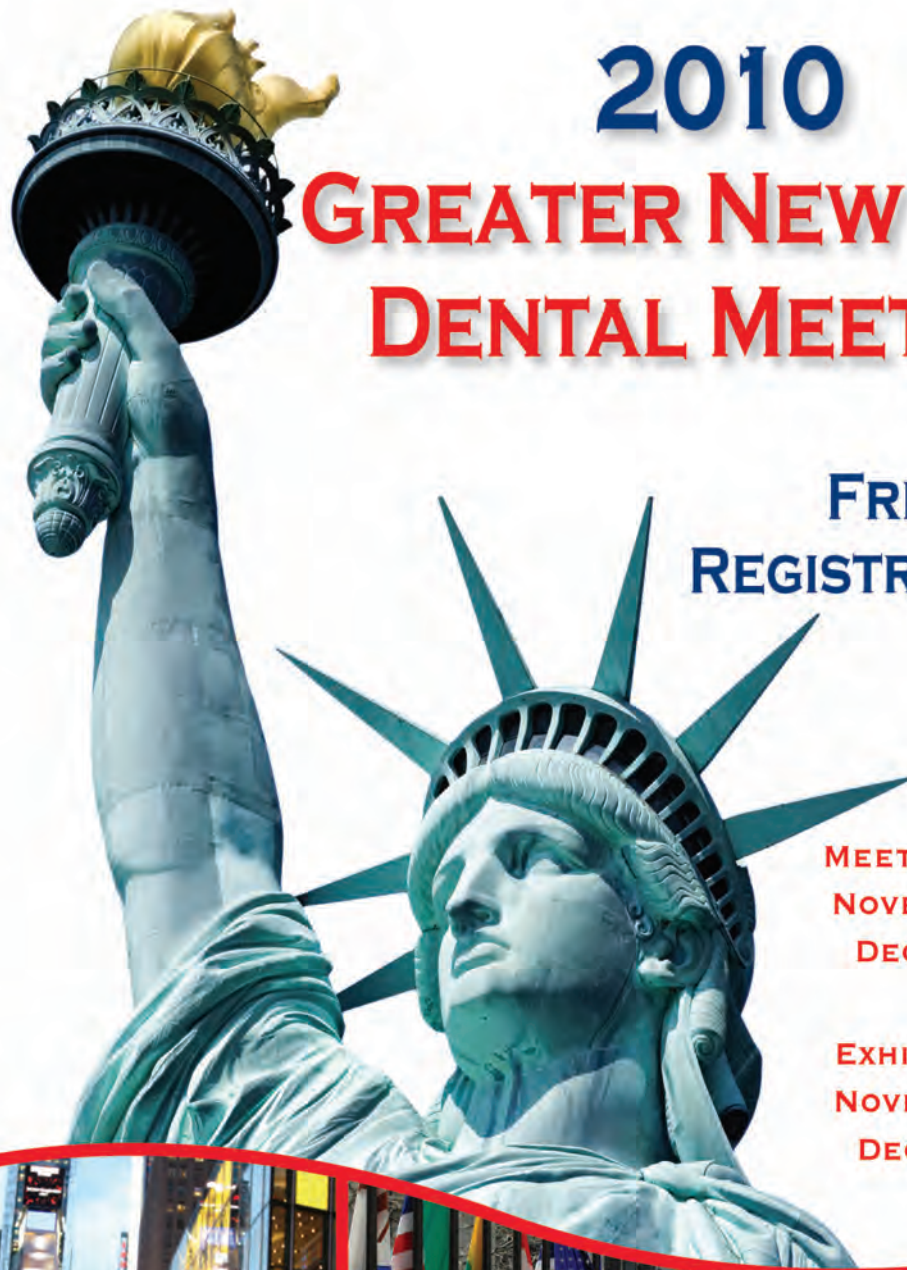## \_about the author

cosmetic  
dentistry



**Dr David S. Frey** has been in private practice in Beverly Hills for over 20 years. A graduate of the University of Pacific Dental School in 1989, Dr Frey's passion for learning and excellence has allowed him to establish a very high-end cosmetic and reconstructive practice. Furthermore, Dr Frey has pursued extensive training and education at the prestigious Las Vegas Institute allowing him to more comprehensively evaluate his patients. He has authored two books, *Revitalize Your Smile* and *Revitalize Your Mouth*, and written for top US dental journals. He has appeared in *People* magazine for his work on celebrity idol Elliott Yamin, and has made multiple appearances on the *Learning Channel's* programmes *Ten Years Younger* and *A Personal Story*.





# 2010

## GREATER NEW YORK DENTAL MEETING

**FREE  
REGISTRATION\***

**MEETING DATES:  
NOVEMBER 26 -  
DECEMBER 1**

**EXHIBIT DATES:  
NOVEMBER 28 -  
DECEMBER 1**

86<sup>th</sup>  
Annual Session

**The  
Largest  
Dental  
Convention/  
Exhibition/  
Congress  
in the  
United  
States**

*\*Free registration  
before November 26*

Please send me more information about...

- ☐ Attending the Greater New York Dental Meeting  
☐ Participating as a guest host and receiving free CE  
☐ I speak \_\_\_\_\_ and am willing to assist international guests  
enter language



Name \_\_\_\_\_

Address \_\_\_\_\_

City, State, Zip/Country Code \_\_\_\_\_

Telephone \_\_\_\_\_ E-mail \_\_\_\_\_

Fax or mail this to:  
Greater New York Dental Meeting or  
visit our website: [www.gnydm.com](http://www.gnydm.com) for more information.



For More Information:  
Greater New York Dental Meeting™  
570 Seventh Avenue - Suite 800  
New York, NY 10018 USA  
Tel: +1 (212) 398-6922  
Fax: +1 (212) 398-6934  
E-mail: [info@gnydm.com](mailto:info@gnydm.com)  
Website: [www.gnydm.com](http://www.gnydm.com)