

The Inman Aligner— An effective tool for minimally invasive cosmetic dentistry (Part I)

Author_Dr Tif Qureshi, UK

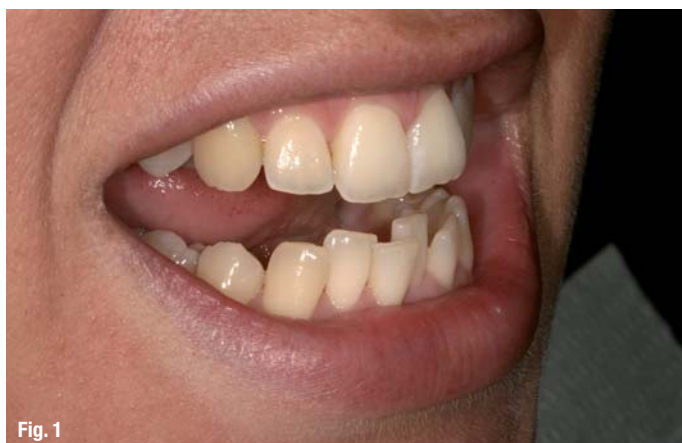

Fig. 1

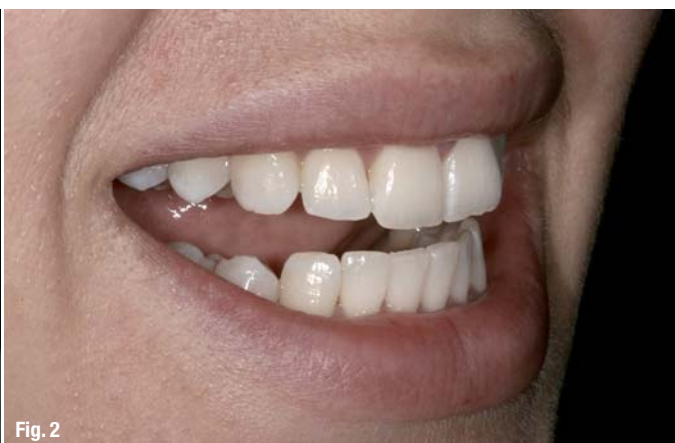

Fig. 2

Fig. 1_Side smile view
before treatment.

Fig. 2_Side smile view after nine
weeks with an Inman Aligner.

Traditionally, cosmetic dentistry has always been faced with the challenge of treating poorly aligned teeth. Treatment options available for mildly and moderately crowded teeth include orthodontics and restorative dentistry. Many patients have chosen the restorative approach, for example porcelain veneers, over orthodontic techniques because of longer treatment times combined with either unsightly labial wires and brackets or the expense of 'invisible' braces.

In cases in which patients choose to have crowded upper and lower anterior teeth treated with veneers, it is extremely challenging to prepare teeth conservatively, owing to their anatomy and the minimum thickness of porcelain required. A difficult balance has to be found between over-preparing the teeth and placing over-contoured restorations. However, owing to the excitement and emotion created by the effect of popular large smile makeovers, aggressive tooth preparations, in which teeth are prepared to stumps, seem to have been accepted as normal practice, simply

because there has been no alternative that could achieve the patient's objectives in a sufficiently short period.

Inman Aligners are now offering a minimally invasive alternative to patients in the UK. With only one appliance, most Aligner cases can be completed in six to 16 weeks. In anterior crowding cases, Inman Aligners have proven to be much more time and cost effective than invisible braces or conventional fixed and short-term orthodontics. To date, I have treated about 1,000 cases and have found that case acceptance has been close to 100 per cent, simply because many patients much prefer a removable solution that fits their lifestyle more easily. Treatment can also easily be combined with simultaneous bleaching and final edge-bonding for quick and non-invasive, dramatic results. From this, a new procedure has arisen in cosmetic dentistry—alignment, bleaching, bonding—which will be covered in the second part of this series. The cases presented in this article will outline some case types that can be treated.

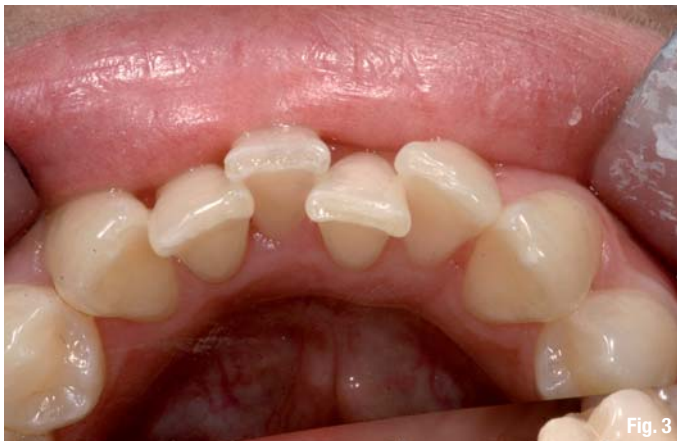

Fig. 3

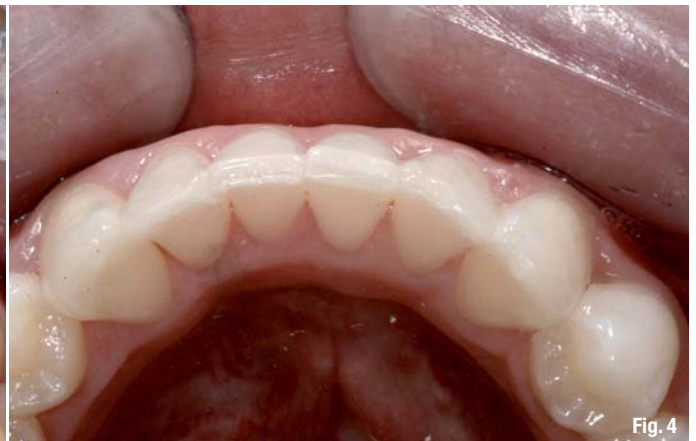

Fig. 4

The Inman Aligner

For over 30 years, spring aligners were used to correct minor tooth movements. Early designs were developed for minor tooth movements and to treat slight rotations. Previous spring aligners were useful, but several problems always limited the amount of tooth movement achievable. Their active components were made from stainless-steel wire, which is relatively inflexible and lacks any innate springiness. As a result, traditional removable appliances required periodic reactivation, leading to short-lived force application that limited the speed of tooth movement, owing to the need to allow the bone around the roots of the teeth being moved to 'rest' between successive activations. In addition, the direction of force application with traditional springs was less easy to control, leading to a mousetrap-like force that tended to unseat the appliance. These factors limited the degree of correction that could be accomplished. For larger movements, single appliances were insufficient to complete the movement.

In developing the Inman Aligner, Donal Inman CDT created a patented design that takes advantage of the gentle, steady and consistent forces generated by NiTi. The design relies on piston-like components driven by NiTi coil springs. Inman designed

lingual and labial components to function or move in parallel to the occlusal plane, eliminating the mousetrap-like unseating forces and allowing actual physiological movement of teeth. Inman Aligners are ideally worn for 16 to 20 hours a day. Studies have demonstrated that the removal of orthodontic forces for four hours a day massively reduces the risk of root resorption¹ and that risk of root resorption is lower in removable versus fixed appliances.²

A standard Inman Aligner as described in the following cases consists of both lingual and labial components. The forces have the effect of squeezing the teeth into alignment. The components can be used in isolation to retract teeth with a more steady force, requiring less adjustment than a standard labial bow retractor. In Case III, a unique approach that incorporates an expander on the Inman Aligner is described.

Patient selection

Case selection for the Inman Aligner is critical. The following criteria should be met before treatment proceeds:

1. Cases should require movement of incisor and/or canine teeth only.
2. Root formation of the teeth to be moved must be complete.

Fig. 3_ Occlusal view before treatment.

Fig. 4_ Occlusal view after treatment.

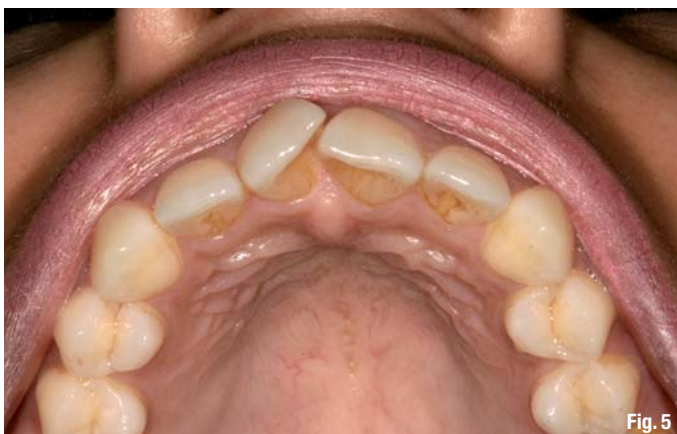

Fig. 5

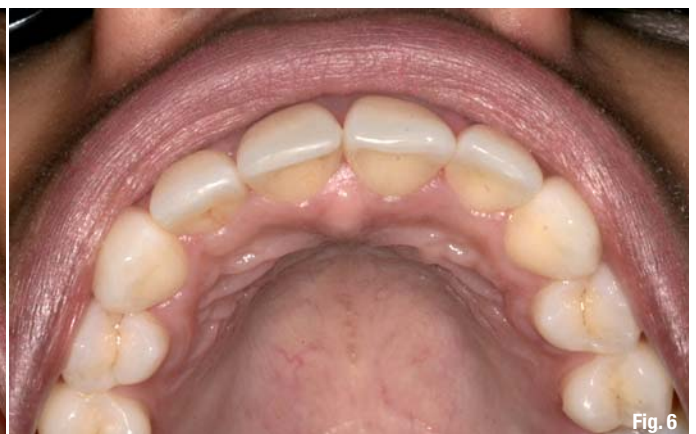

Fig. 6

Fig. 5_ Occlusal view before treatment.

Fig. 6_ Occlusal view after 13 weeks with an Inman Aligner.

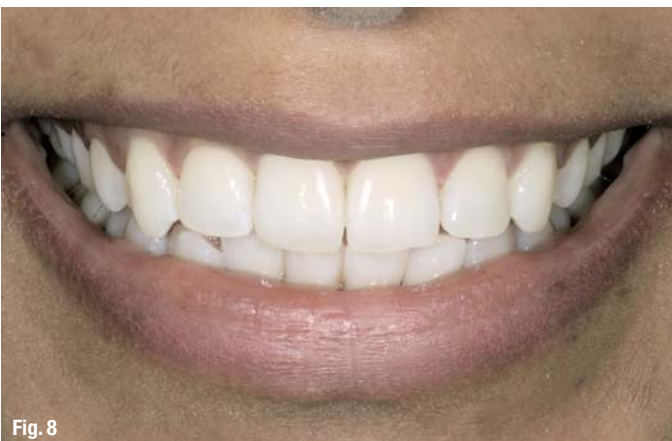
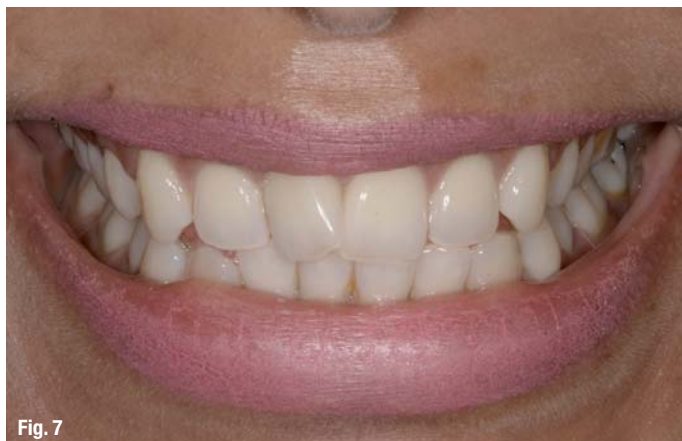
Fig. 7_Smile view before treatment.

Fig. 8_Smile view after treatment.

3. Crowding or spacing should be less than or equal to 3 mm. Arch evaluation must be performed to determine the amount of space required. Cases with over 3 mm of crowding require additional space creation techniques, as pioneered in the UK, which should only be attempted with training. It is quite possible to treat cases with 5.5 mm crowding easily and predictably in less than 16 weeks.
4. Cases should have fully erupted posterior teeth to facilitate retentive clasps, with a reasonably well-aligned arch form to facilitate the path of insertion of the appliance.
5. Cases should be stable and preferably free from periodontal disease.
6. Patients must agree to wear the Aligner for about 20 hours a day and be responsible for good appliance and oral hygiene. Should the patient wear the Aligner for 14 hours a day only, treatment will still be successful.

Model evaluation/arch analysis with Spacewize

Arch analysis should be performed before any Aligner case is attempted in order to ensure that the case is suitable and, if not, what additional space creation techniques will be needed to allow the Inman Aligner to work. The extent of crowding present is calculated³ by measuring the sum of the mesial-distal widths of the teeth to be moved. This distance is called the *required space or the teeth*. If canines and incisors are to be moved, this distance will be measured from the distal surface of one canine to the distal surface of the other canine.

Using an orthodontic retaining or jeweller's chain or a polishing strip, the ideal arch form is then measured from the distal of each canine in alignment with the ideal arch form following orthodontic correction. Critically, the arch needs to pass through the suggested position of the contact points and not the incisal edges. This is described as the *available space or the curve*.

It is possible to perform this task more quickly and just as accurately with software such as

Spacewize. Just one simple occlusal photograph is required, which can be taken chairside. One tooth needs to be measured for calibration. A curve can be digitally established and this is normally easier when observing the patient's aesthetic requirements and occlusion directly. The extent of crowding is immediately calculated using such software.

Laboratory requirements

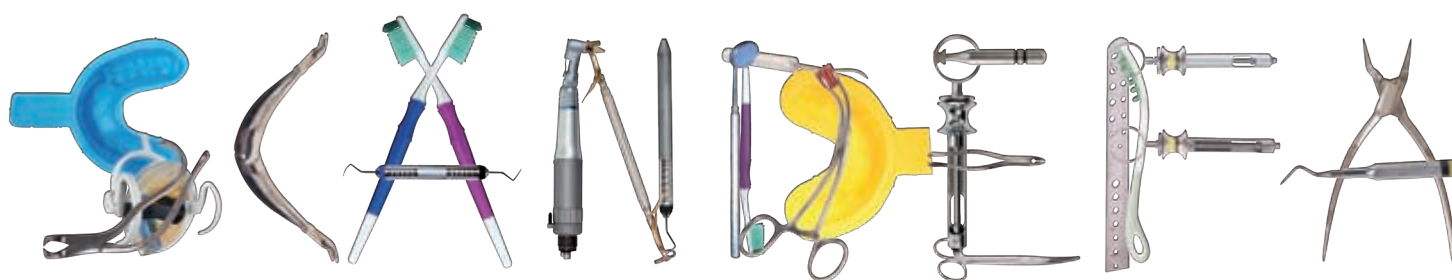Accurate upper and lower impressions are taken, preferably two of the arch being treated. Simple alginate can be used if cast quickly. A bite registration and prescription should be completed and sent to a certified Inman Aligner Laboratory. The technician should be informed of the amount of crowding calculated. The teeth to be repositioned should be noted clearly. The prescription should provide full details to the technician regarding the teeth to be moved, the area they are to be moved to and the distance they are to be moved. A Spacewize trace of the ideal curve can also be submitted.

Interproximal reduction

Interproximal reduction (IPR) is begun at the fitting appointment using abrasive strips or discs. The model analysis will have already calculated the extent of IPR required.

Many authors acknowledge that the reduction of half of the interproximal enamel on the mesial and distal of each incisor tooth is a safe technique.⁴⁻⁷ This equates to 0.5 mm per contact point, creating 2.5 mm of space between the canines. In some cases, the distal of the canine and mesial of the premolar can be reproximated allowing for a total of 3.5 to 4.5 mm. These cases will require more experience in using the system but offer a number of possibilities for clinicians once trained to use the system correctly.

Meticulous records of the amount of stripping performed should be kept. An in-surgery fluoride rinse or application of topical fluoride is recommended after any enamel reduction procedure.



APRIL 7- 9, 2011 • BELLA CENTER • COPENHAGEN • DENMARK

Welcome to the 44th Scandinavian Dental Fair
The leading annual dental fair in Scandinavia

SCANDEFA 2011



The 44th SCANDEFA invites you to exquisitely meet the Scandinavian dental market and sales partners from all over the world in springtime in wonderful Copenhagen

SCANDEFA, organized by Bella Center, is being held in conjunction with the Annual Scientific Meeting, organized by the Danish Dental Association (www.tandlaegeforeningen.dk).

More than 200 exhibitors and 11.349 visitors participated at SCANDEFA 2010 on 14,220 m² of exhibition space.

Reservation of a booth

Book online at www.scandefa.dk
Sales and Project Manager, Jo Jaqueline Ogilvie
jjo@bellacenter.dk, T +45 32 47 21 25

Travel information

Bella Center is located just a 10 minute taxi drive from Copenhagen Airport. A regional train runs from the airport to Orestad Station, only 15 minutes drive.

Book a hotel in Copenhagen

www.visitcopenhagen.com/tourist/plan_and_book

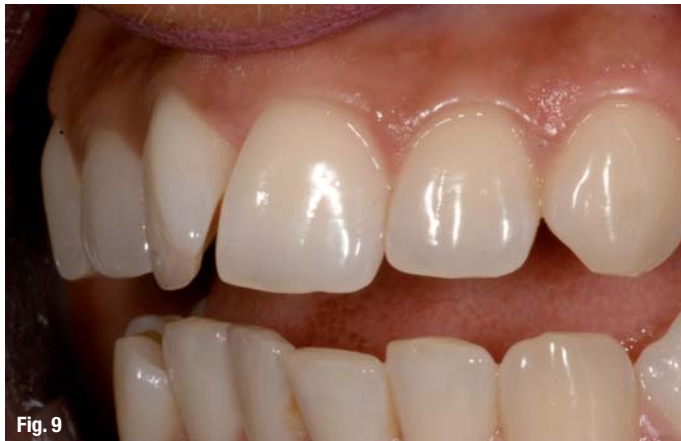

Fig. 9

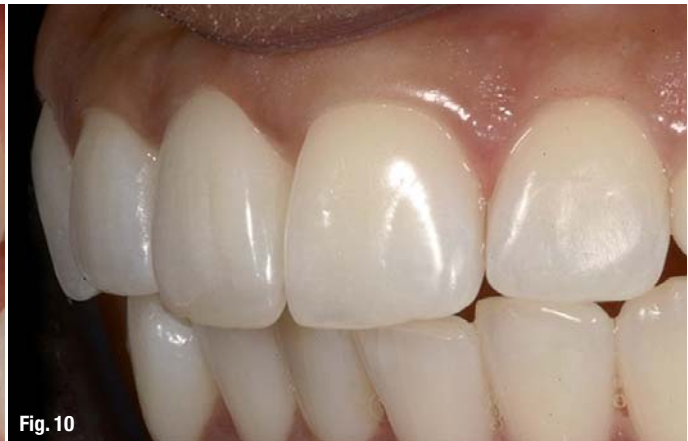

Fig. 10

Fig. 9 Close side view
before treatment.

Fig. 10 Close side view
after treatment.

El-Mangoury *et al.*⁸ and Radlanski⁹ have demonstrated that there is no increased risk of caries after IPR, provided surfaces are smoothed correctly. Heins *et al.*¹⁰ and Tal¹¹ have demonstrated that there is no increased risk of periodontal disease, despite the decreased interproximal space.

Critically, Inman Aligner treatment uses progressive, anatomically respectful IPR. While the extent of IPR required is already known, it is **never** carried out in one treatment. In order to ensure minimal risk, IPR (0.13 mm per visit per contact point) is carried out only in small increments. The patient is sent away with the Aligner. Owing to the Aligner forces, the gaps will be closed after two weeks. Interproximal reduction is performed at each appointment only as needed, using strips or discs, which ensures the stripping is far more anatomically conservative than would be the case using burs. This significantly reduces the risk of excess space formation, gouging or poor contact anatomy.

Lingual/labial anchors

Composite resin just incisal placed either incisal or gingival to where the bows contact will help them to function more efficiently. This can also be used for the labial surface, especially in cases in which teeth are being retracted. Strategic placement is vital for success and can be very helpful in the treatment of rotated teeth and the extrusion of teeth.

Appliance adjustment

The forces can be varied by adjusting the spring components or replacing springs for larger, longer springs. Generally, adjustments are not necessary, except in more complex cases, for which training is required to understand the correct spring types and compression rates to use.

_Case I

The 25-year-old female patient complained about the appearance of her lower anterior teeth.

She gave a history of orthodontic treatment in her teenage years, having a fixed appliance fitted for a period of two years. She had been given a retainer at the time but was told to wear it at night for three months only. She had noticed her lower four incisors starting to become crowded again. Treatment options discussed were invisible braces, conventional fixed brackets or an Inman Aligner.

The amount of space required for reduction was calculated as 3.5 mm. Interproximal reduction was performed using diamond strips (Brasseler). A reduction of 0.13 mm at each contact point was achieved at the fitting appointment. This was verified with a thickness gauge. The patient was seen three weeks later and a further 0.13 mm reduced at each contact point. The teeth were aligned in just over nine weeks. The Aligner was left in for one month to stabilise the tooth positions. Tooth whitening was undertaken for two weeks during the last two weeks of treatment. Simultaneous bleaching is a significant advantage in removable systems and helps patient motivation. Finally, an orthodontic retention wire was bonded in place on the lingual surfaces, ensuring the patient could still use super floss for hygiene.

_Case II

A female patient presented complaining mainly about her rotated upper right central tooth. She was considering veneers to redistribute the space over the four front teeth. This would have meant that she would undergo three aggressive preparations and one invasive preparation with endodontic treatment of the upper right central tooth.

Space calculation with model analysis indicated that treatment would be possible with an Inman Aligner. Because of the relatively low cost, the patient selected this option, understanding that we would not be able to achieve Golden Proportion, owing to the width and length of her lateral teeth.

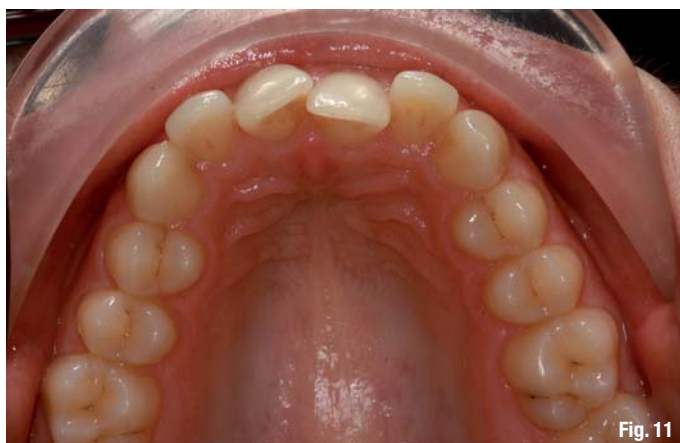

Fig. 11

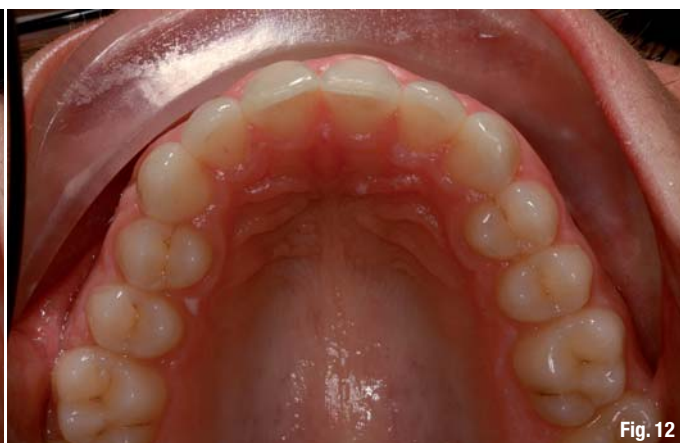

Fig. 12

A midline screw was incorporated to allow for a small amount of operator-controlled expansion to provide a little more space. (Incorporated expanders can be used to release extra space in cases with very constrained space.) Up to 2 mm of space can be created by expansion, which has the effect of pushing the cuspid away from the lateral. After alignment, this expansion will just relapse. It is a temporary technique to create sufficient space to align the anterior teeth. After alignment, the expander can even be unwound if required.

Treatment took 13 weeks with three sessions of IPR. A total of 3 mm was stripped and 1 mm was gained with the expander. The teeth were retained using orthodontic gold chain bonded from canine to canine. An upper Essix Retainer was also worn nightly as back-up for retention.

Case III

The patient in this case originally presented for porcelain veneers on her upper anterior teeth. The preparations would have required root-canal treatment of two of her incisors in order to achieve adequate emergence profiles.

After case options had been discussed in detail, the patient decided upon an Inman Aligner to align the teeth with veneers following this treatment. The patient was aware that after alignment, retention would be mandatory. Spacewise arch analysis calculated only 0.8 mm crowding in deviation from the ideal curve.

An upper Inman Aligner with combined expander was fabricated and fitted. Minimal IPR was carried out with a 0.1 mm reproposition strip to separate the teeth. The patient turned the screw every five days for six weeks, which created nearly 2 mm of space. This allowed space for the centrals to advance and de-rotate. At this point, the expander was unwound to ensure that any mild residual spacing had

closed. The teeth were aligned within nine weeks. An Essix Retainer was used to retain the teeth passively for a further four weeks, after which a bonded wire retainer was placed.

The patient was very pleased with the alignment and decided that she would not need veneers. Veneers could always be used at a later stage if necessary, after more enamel has eroded with age and when veneers can be placed additively, for example.

The result was not a perfect smile with regard to the criteria defined by Smile Design theory. Yet, that she no longer wanted veneers arguably provides us with a far better and more ethical outcome long term.

Retention

Retention for anterior alignment is essential.¹²⁻¹⁴ Recommended retainer types are bonded canine-to-canine fixed retainers commonly fabricated from .0195" or .0175" multi-strand stainless-steel wire. An indirect method can be used to adapt the wire to a working model. This can then be transferred to the teeth, using a specially made jig and bonded with flowable composite resin to the backs of the aligned teeth. The occlusion must be clear when placing a retainer on the maxillary arch.

Advantages of this method are that the flexibility of the arch wire allows for physiological tooth movement and prevents bond fracture through occlusal forces. Periodontal ligament stability is also achieved with this technique.¹⁵

Essix Retainer

This retainer is a thermo-formed, clear, thin appliance that is easily made and very comfortable for patients. The recommended post-operative regimen for Inman Aligner treatment is to wear the retainer at night for 18 months and after that for two nights a week indefinitely.

Fig. 11_ Occlusal view before treatment.

Fig. 12_ Occlusal view after nine weeks with an Inman Aligner.

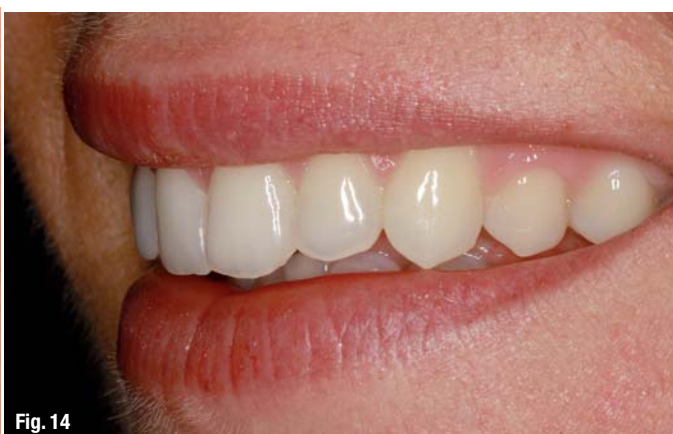
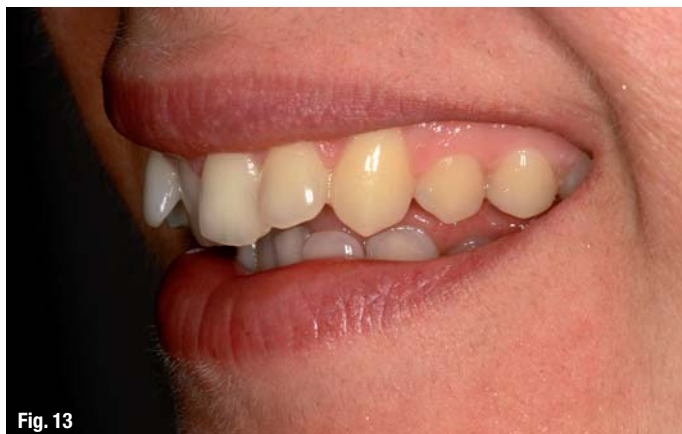
Fig. 13_Side smile view
before treatment.

Fig. 14_Side smile view
after treatment.

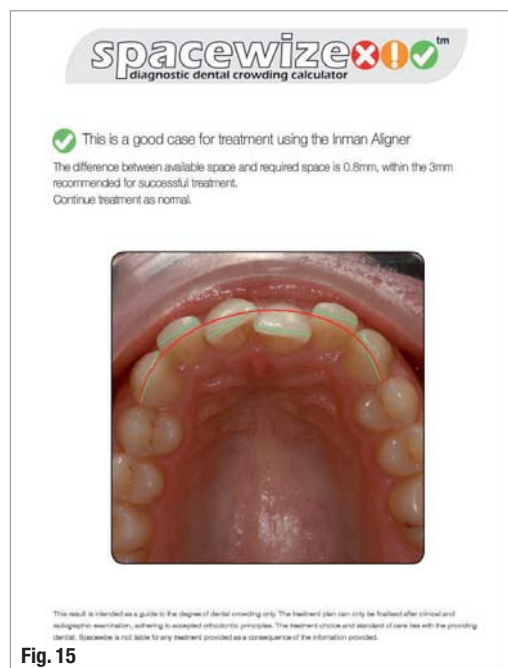
Conclusion

With the Inman Aligner, patients previously put off by the treatment time and fixed brackets of traditional orthodontic techniques or the expense of more recent invisible braces, could, if their case is suitable, achieve anterior tooth alignment far more

As a result, the Inman Aligner is profoundly changing the approach to cosmetic dentistry by those using it with the advanced techniques of domino effect, combined expansion and strategic anchor placement in the UK and Europe.

This new approach to cosmetic dentistry in the UK has been confirmed by figures from the British Academy of Cosmetic Dentistry (BACD). The 2008 study of data from 200 BACD members demonstrated a massive 345 per cent increase in orthodontics used in cosmetic cases but no increase in the use of veneers. Of this increase, 230 per cent was solely due to the use of the Inman Aligner in cases in which patients would not otherwise have had their teeth treated, owing to the time cost of fixed braces and no desire to have appliances adhered to their teeth. Many of these patients were those who would have opted for aggressive preparation of their teeth for veneers, before the Inman Aligner.

Fig. 15_Spacewize calculation.



quickly with a simpler, single appliance. Inman Aligners are suitable for alignment of incisors and canines with up to 3 mm of crowding—5.5 mm once the treating clinician is trained in using the system—and represent a very conservative and potentially revolutionary alternative to radical tooth preparation for achieving tooth alignment using porcelain restorations.

The Inman Aligner allows for a rapid and aesthetic alignment at low risk and cost to our patients. The patient is able to preview the staged changes of alignment, perhaps followed by bleaching and bonding.

Acknowledgements

I would like to thank Donal Inman CDT (Inman Orthodontic Laboratory), NimroDENTAL Orthodontic Laboratory—the only Straight Talks Seminars-certified Inman Aligner laboratories—and Dr James Russell for Case III.

Editorial note: A complete list of references is available from the publisher.

about the author

cosmetic
dentistry

Dr Tif Qureshi is Vice-President of the British Academy of Cosmetic Dentistry. He presents hands-on courses and lectures on the Inman Aligner worldwide. For information on course dates and training, please go to www.straight-talks.com or www.inmanaligner.com. Alternatively, contact Caroline Cross on +44 207 255 2559 or at info@straight-talks.com.



DENTAL TRIBUNE

DT STUDY CLUB

COURSES | DISCUSSIONS | TECHNOLOGY | ON-DEMAND

"Online learning is not the next big thing,
it is the now big thing."

Donna J Abernathy
Training and Development Editor

DTSC - COURSES, COMMUNITY, TECHNOLOGY, ON-DEMAND

The DT Study Club makes all of this is possible from the comfort of your own computer and without travel expenses. In other words, welcome to the community!

The purpose of this study club is to provide practitioners like yourself an opportunity to learn and network with like-minded colleagues in a friendly, non-threatening environment. We encourage you to take advantage of Dental Tribune's global outreach to access a variety of fresh perspectives and cultures, enhancing your educational mix.

24/7 LIVE AND INTERACTIVE ONLINE COURSES

Fulfill your yearly CE requirements with our growing list of archived ADA CERP approved courses.



DISCUSSION FORUMS

focused on helping today's practitioners to stay up to date. Networking possibilities that go beyond borders to create a truly Global Dental Village



VIDEO REVIEWS OF PRODUCTS

Our opinion leaders unveil new products, services, and give you their first impressions of the industry's hottest topics.



PEER REVIEWED CASE STUDIES

Upload, comment, participate. We encourage you to share your cases for review with like-minded practitioners.



REGISTER FOR FREE ON WWW.DTSTUDYCLUB.COM

CONTESTS WITH CHANCES TO WIN FREE TUITION FOR ADA/CERP C.E. ACCREDITED WEBINARS

SPONSORSHIP AND SPEAKING INQUIRIES:
JULIA WEHKAMP, J.WEHKAMP@DTSTUDYCLUB.COM, (416) 907-9836.

ADACERP
CONTINUING EDUCATION RECOGNITION PROGRAM



PRACTICE MANAGEMENT



GENERAL DENTISTRY



COSMETICS



ENDODONTICS



IMPLANTOLOGY



PERIODONTICS



ORTHODONTICS



DENTAL HYGIENE

WWW.DTSTUDYCLUB.COM