

cosmetic dentistry

— beauty & science

2²⁰¹⁰

| MICD

The Inman Aligner

| special

A simplified method for the removal
of cemented implant prosthetics

| opinion

The gold standard

dentistry



Minimally Invasive
Cosmetic Dentistry

Adopt the trend...

SHOFU recognizes the development of new clinical techniques in minimally invasive cosmetic dentistry (MiCD) procedures and is fully committed to support the MiCD movement through the contribution in developing and providing dental professionals with newer aesthetic biocompatible materials to achieve their goals.



For more information, simply contact your nearest **SHOFU** dealer.



SHOFU INC. SINGAPORE BRANCH

Tel (65) 6377 2722 Fax (65) 6377 1121 eMail mailbx@shofu.com.sg website www.shofu.com.sg

Dear Reader,

_Welcome to this year's second edition of **cosmetic dentistry**!

Under the great leadership of AAAD President Dr Sim Tang Eng, the 11th Biennial Asian Academy of Aesthetic Dentistry Scientific Meeting was successfully held in Kuala Lumpur, Malaysia, from 14 to 17 May 2010. The meeting highlights were the four international keynote speakers: Dr Rhys Spoor (USA), Dr Didier Dietschi (Switzerland), Dr Mauro Fradeani (Italy) and Dr Galip Gurel (Turkey) presented lectures on direct composite restorations in the anterior and posterior region, as well as on all-ceramic restorations and porcelain laminate veneer restorations. The lectures and the well-organised, hands-on courses actively engaged participants, and were received with great appreciation.

Since the first Scientific Meeting in Singapore in 1990, the AAAD Scientific Meeting has been held biannually in wonderful locations, like Seoul, Kagoshima, Taipei, Singapore, Mumbai, Nagoya and Bali. At the closing ceremony in Kuala Lumpur, Dr Sim Tang Eng passed the Presidency to Dr Hisashi Hisamitsu. We look forward to the 12th Biennial AAAD Scientific Meeting, which will be held in Sapporo in Japan, with great anticipation, expecting another wonderful meeting that will bring all our members together to share precious moments, knowledge and expertise with colleagues.

The AAAD was established in 1990 with the purpose of promoting the art and science of disciplines in aesthetic dentistry. The scientific meetings serve as the primary tool in accomplishing the goals of the Academy. Additionally, past and current editors have strived to fulfil this mission through the official AAAD publication, but all faced difficulties in collecting high-quality articles from AAAD members. In 2008, we were very fortunate to join with German-based publishers Dental Tribune International and Oemus Media, who have strongly motivated our members.

cosmetic dentistry has grown to be one of the most popular aesthetic dental magazines in the Asia Pacific region and I am confident that you will enjoy this edition filled with articles on clinical practice, practice management, research and industry reports!

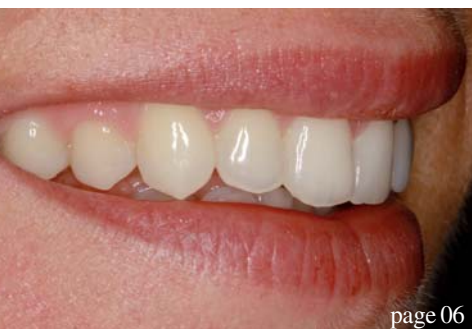Sincerely yours,



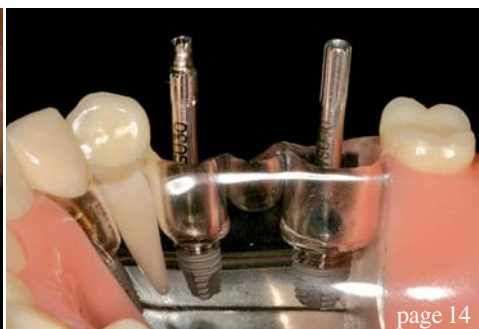Dr So-Ran Kwon
Co-Editor-in-Chief
President, Korean Bleaching Society
Seoul, Korea



Dr So-Ran Kwon
Co-Editor-in-Chief



page 06



page 14



page 18

| editorial

- 03 **Dear Reader**
| Dr So-Ran Kwon, Co-Editor-in-Chief

| MICD

- 06 **The Inman Aligner**—An effective tool for minimally invasive cosmetic dentistry (Part I)
| Dr Tif Qureshi

| special

- 14 A simplified method for **the removal of cemented implant prosthetics**
| Dr Scott Davis

| case report

- 18 **Bite alteration** for reducing gummy smiles: Two case reports
| Dr David S. Frey
- 24 **Provisional restorations** in complex restorative cases
| Dr Christopher Ho

| research

- 28 **In vitro bleaching study** with a 20 % hydrogen-peroxide system
| Dr Daniel C.N. Chan *et al.*

| opinion

- 34 **The gold standard**
| Dr Michael B. Miller

| feature

- 36 **You can't always get what you want** (unless you ask clearly!)
| Laura Kelly
- 40 An interview with **Prof Albert Mehl**, University of Zürich

| industry report

- 42 **Minimally invasive** anterior restorations with **non-prep veneers**
| Dr Harald Streit & Bernhard Hellmuth

| industry news

- 46 **Compatibility** of products **offers flexibility**
| Ivoclar Vivadent

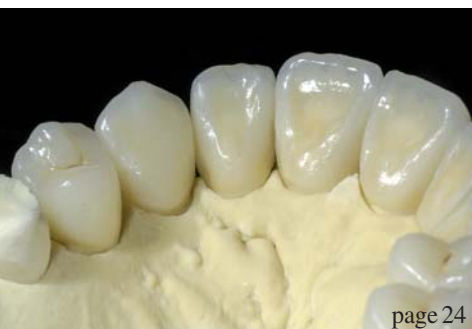| meetings

- 48 **International Events**

| about the publisher

- 49 | submission guidelines
- 50 | imprint

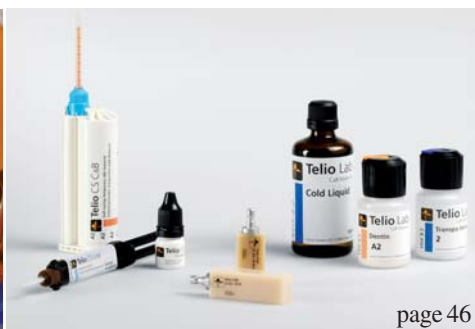Cover image courtesy of dash



page 24



page 28



page 46

Europe's dental care bridge

HUNGARY:

hi-level education

dental care prices -70%

high EUR/HUF rate

easy access

more than 75.000 dental tourists annually

5.500 local dental practice

20.000 regional dental practice



SEE THE
NEW PERSPECTIVE

www.dentalworld.hu

DENTALWORLD2010BUDAPEST

141516october

fairconferenceexhibition



The Inman Aligner— An effective tool for minimally invasive cosmetic dentistry (Part I)

Author_ Dr Tif Qureshi, UK

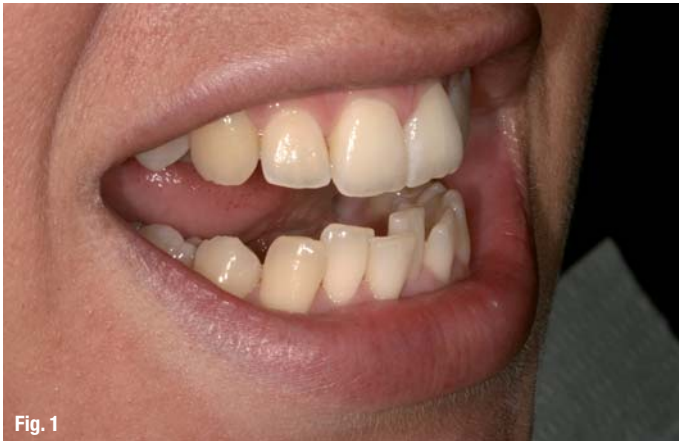

Fig. 1

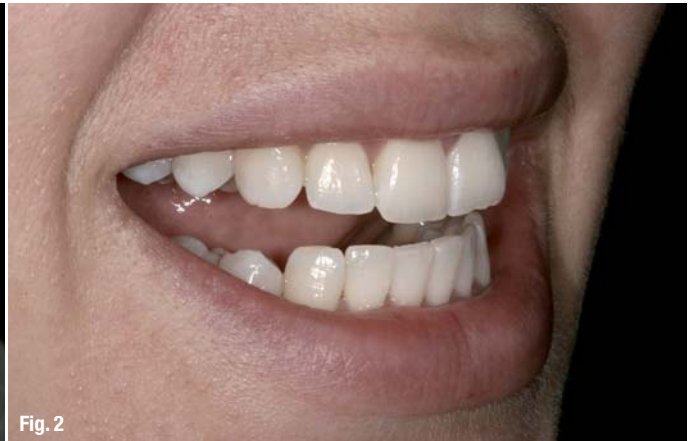

Fig. 2

Fig. 1 Side smile view before treatment.

Fig. 2 Side smile view after nine weeks with an Inman Aligner.

Traditionally, cosmetic dentistry has always been faced with the challenge of treating poorly aligned teeth. Treatment options available for mildly and moderately crowded teeth include orthodontics and restorative dentistry. Many patients have chosen the restorative approach, for example porcelain veneers, over orthodontic techniques because of longer treatment times combined with either unsightly labial wires and brackets or the expense of 'invisible' braces.

In cases in which patients choose to have crowded upper and lower anterior teeth treated with veneers, it is extremely challenging to prepare teeth conservatively, owing to their anatomy and the minimum thickness of porcelain required. A difficult balance has to be found between over-preparing the teeth and placing over-contoured restorations. However, owing to the excitement and emotion created by the effect of popular large smile makeovers, aggressive tooth preparations, in which teeth are prepared to stumps, seem to have been accepted as normal practice, simply

because there has been no alternative that could achieve the patient's objectives in a sufficiently short period.

Inman Aligners are now offering a minimally invasive alternative to patients in the UK. With only one appliance, most Aligner cases can be completed in six to 16 weeks. In anterior crowding cases, Inman Aligners have proven to be much more time and cost effective than invisible braces or conventional fixed and short-term orthodontics. To date, I have treated about 1,000 cases and have found that case acceptance has been close to 100 per cent, simply because many patients much prefer a removable solution that fits their lifestyle more easily. Treatment can also easily be combined with simultaneous bleaching and final edge-bonding for quick and non-invasive, dramatic results. From this, a new procedure has arisen in cosmetic dentistry—alignment, bleaching, bonding—which will be covered in the second part of this series. The cases presented in this article will outline some case types that can be treated.

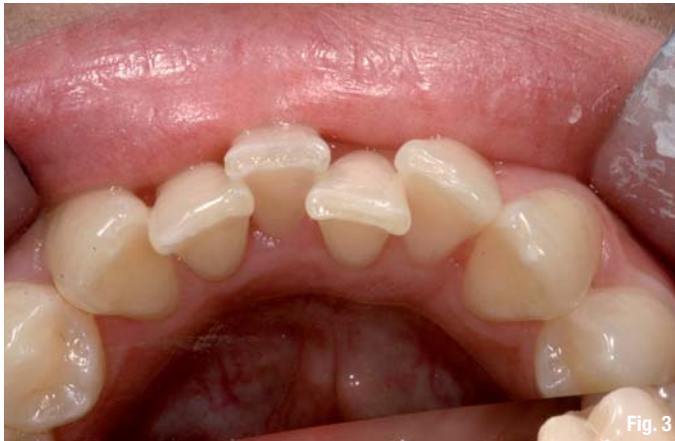

Fig. 3

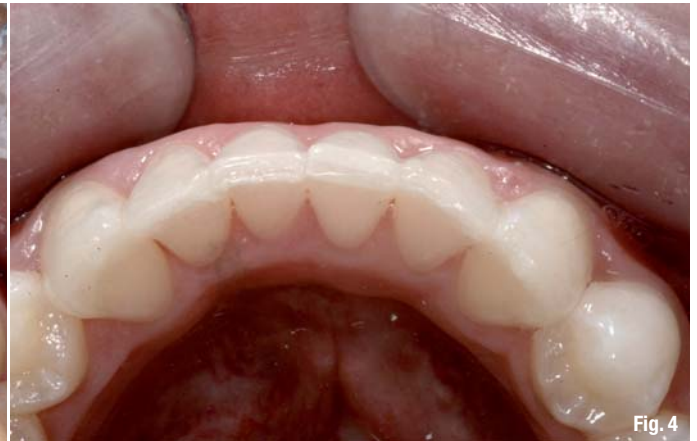

Fig. 4

The Inman Aligner

For over 30 years, spring aligners were used to correct minor tooth movements. Early designs were developed for minor tooth movements and to treat slight rotations. Previous spring aligners were useful, but several problems always limited the amount of tooth movement achievable. Their active components were made from stainless-steel wire, which is relatively inflexible and lacks any innate springiness. As a result, traditional removable appliances required periodic reactivation, leading to short-lived force application that limited the speed of tooth movement, owing to the need to allow the bone around the roots of the teeth being moved to 'rest' between successive activations. In addition, the direction of force application with traditional springs was less easy to control, leading to a mousetrap-like force that tended to unseat the appliance. These factors limited the degree of correction that could be accomplished. For larger movements, single appliances were insufficient to complete the movement.

In developing the Inman Aligner, Donal Inman CDT created a patented design that takes advantage of the gentle, steady and consistent forces generated by NiTi. The design relies on piston-like components driven by NiTi coil springs. Inman designed

lingual and labial components to function or move in parallel to the occlusal plane, eliminating the mousetrap-like unseating forces and allowing actual physiological movement of teeth. Inman Aligners are ideally worn for 16 to 20 hours a day. Studies have demonstrated that the removal of orthodontic forces for four hours a day massively reduces the risk of root resorption¹ and that risk of root resorption is lower in removable versus fixed appliances.²

A standard Inman Aligner as described in the following cases consists of both lingual and labial components. The forces have the effect of squeezing the teeth into alignment. The components can be used in isolation to retract teeth with a more steady force, requiring less adjustment than a standard labial bow retractor. In Case III, a unique approach that incorporates an expander on the Inman Aligner is described.

Patient selection

Case selection for the Inman Aligner is critical. The following criteria should be met before treatment proceeds:

1. Cases should require movement of incisor and/or canine teeth only.
2. Root formation of the teeth to be moved must be complete.

Fig. 3_Occlusal view before treatment.

Fig. 4_Occlusal view after treatment.

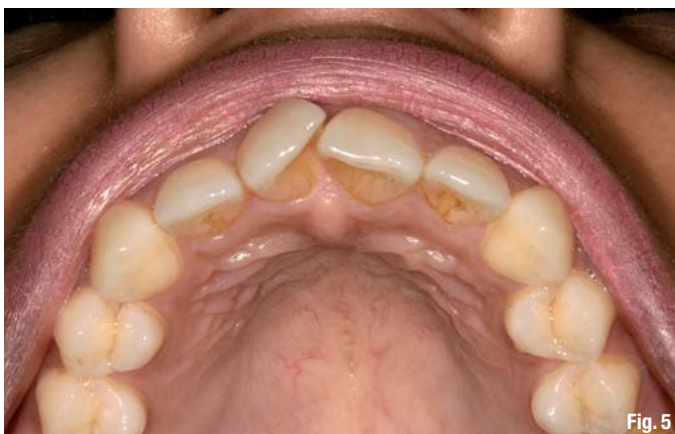

Fig. 5

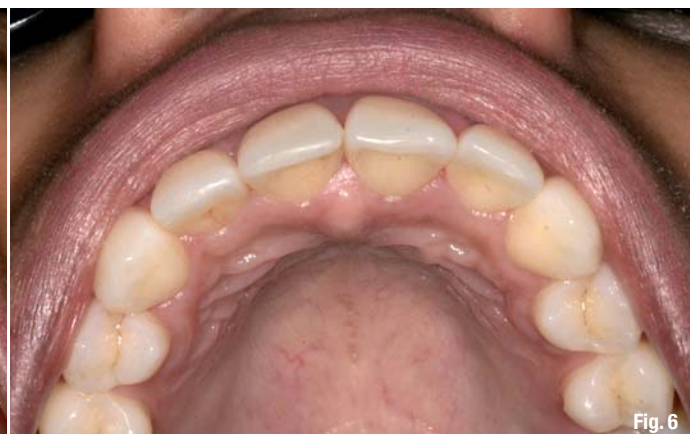

Fig. 6

Fig. 5_Occlusal view before treatment.

Fig. 6_Occlusal view after 13 weeks with an Inman Aligner.

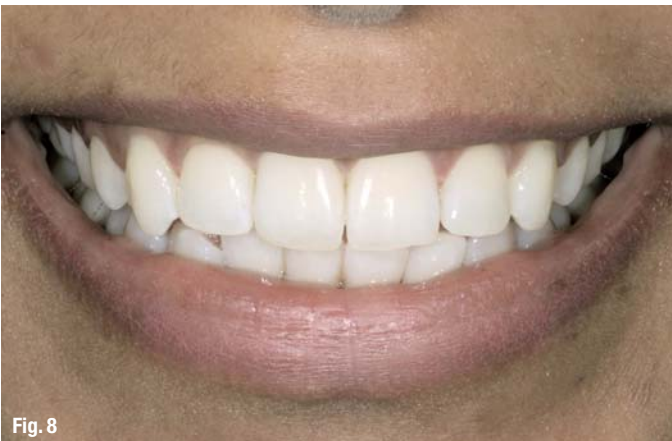
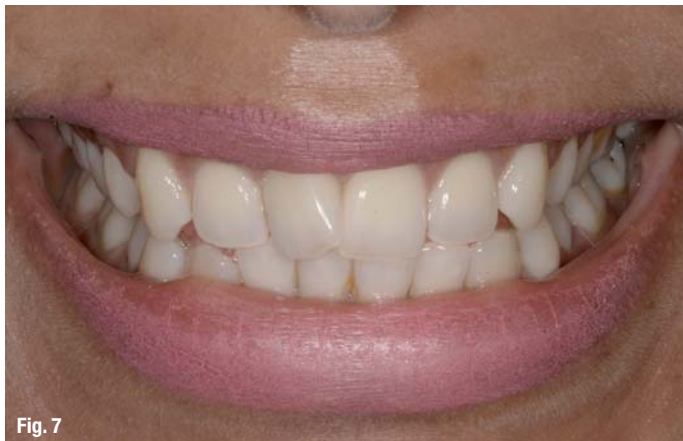
Fig. 7_Smile view before treatment.

Fig. 8_Smile view after treatment.

3. Crowding or spacing should be less than or equal to 3 mm. Arch evaluation must be performed to determine the amount of space required. Cases with over 3 mm of crowding require additional space creation techniques, as pioneered in the UK, which should only be attempted with training. It is quite possible to treat cases with 5.5 mm crowding easily and predictably in less than 16 weeks.
4. Cases should have fully erupted posterior teeth to facilitate retentive clasps, with a reasonably well-aligned arch form to facilitate the path of insertion of the appliance.
5. Cases should be stable and preferably free from periodontal disease.
6. Patients must agree to wear the Aligner for about 20 hours a day and be responsible for good appliance and oral hygiene. Should the patient wear the Aligner for 14 hours a day only, treatment will still be successful.

Model evaluation/arch analysis with Spacewise

Arch analysis should be performed before any Aligner case is attempted in order to ensure that the case is suitable and, if not, what additional space creation techniques will be needed to allow the Inman Aligner to work. The extent of crowding present is calculated³ by measuring the sum of the mesial-distal widths of the teeth to be moved. This distance is called the *required space or the teeth*. If canines and incisors are to be moved, this distance will be measured from the distal surface of one canine to the distal surface of the other canine.

Using an orthodontic retaining or jeweller's chain or a polishing strip, the ideal arch form is then measured from the distal of each canine in alignment with the ideal arch form following orthodontic correction. Critically, the arch needs to pass through the suggested position of the contact points and not the incisal edges. This is described as the *available space or the curve*.

It is possible to perform this task more quickly and just as accurately with software such as

Spacewise. Just one simple occlusal photograph is required, which can be taken chairside. One tooth needs to be measured for calibration. A curve can be digitally established and this is normally easier when observing the patient's aesthetic requirements and occlusion directly. The extent of crowding is immediately calculated using such software.

Laboratory requirements

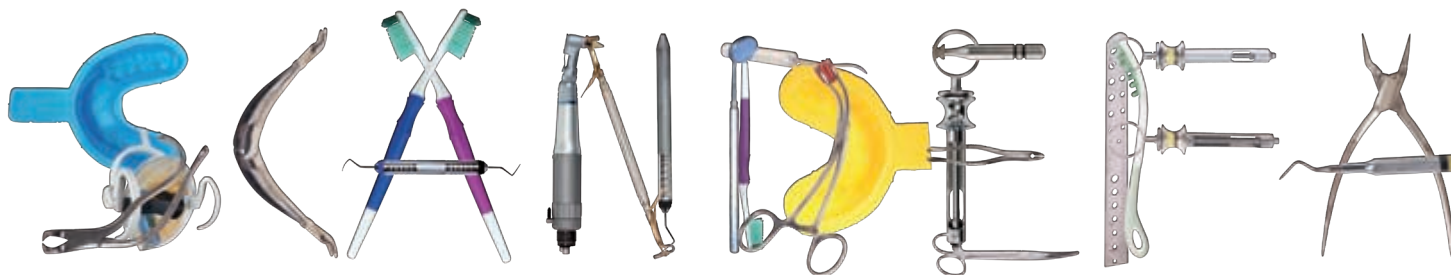
Accurate upper and lower impressions are taken, preferably two of the arch being treated. Simple alginate can be used if cast quickly. A bite registration and prescription should be completed and sent to a certified Inman Aligner Laboratory. The technician should be informed of the amount of crowding calculated. The teeth to be repositioned should be noted clearly. The prescription should provide full details to the technician regarding the teeth to be moved, the area they are to be moved to and the distance they are to be moved. A Spacewise trace of the ideal curve can also be submitted.

Interproximal reduction

Interproximal reduction (IPR) is begun at the fitting appointment using abrasive strips or discs. The model analysis will have already calculated the extent of IPR required.

Many authors acknowledge that the reduction of half of the interproximal enamel on the mesial and distal of each incisor tooth is a safe technique.⁴⁻⁷ This equates to 0.5 mm per contact point, creating 2.5 mm of space between the canines. In some cases, the distal of the canine and mesial of the premolar can be reproximated allowing for a total of 3.5 to 4.5 mm. These cases will require more experience in using the system but offer a number of possibilities for clinicians once trained to use the system correctly.

Meticulous records of the amount of stripping performed should be kept. An in-surgery fluoride rinse or application of topical fluoride is recommended after any enamel reduction procedure.



APRIL 7- 9, 2011 • BELLA CENTER • COPENHAGEN • DENMARK

Welcome to the 44th Scandinavian Dental Fair
The leading annual dental fair in Scandinavia

SCANDEFA 2011



The 44th SCANDEFA invites you to exquisitely meet the Scandinavian dental market and sales partners from all over the world in springtime in wonderful Copenhagen

SCANDEFA, organized by Bella Center, is being held in conjunction with the Annual Scientific Meeting, organized by the Danish Dental Association (www.tandlaegeforeningen.dk).

More than 200 exhibitors and 11.349 visitors participated at SCANDEFA 2010 on 14,220 m² of exhibition space.

Reservation of a booth

Book online at www.scandefa.dk
Sales and Project Manager, Jo Jaqueline Ogilvie
jjo@bellacenter.dk, T +45 32 47 21 25

Travel information

Bella Center is located just a 10 minute taxi drive from Copenhagen Airport. A regional train runs from the airport to Orestad Station, only 15 minutes drive.

Book a hotel in Copenhagen

www.visitcopenhagen.com/tourist/plan_and_book

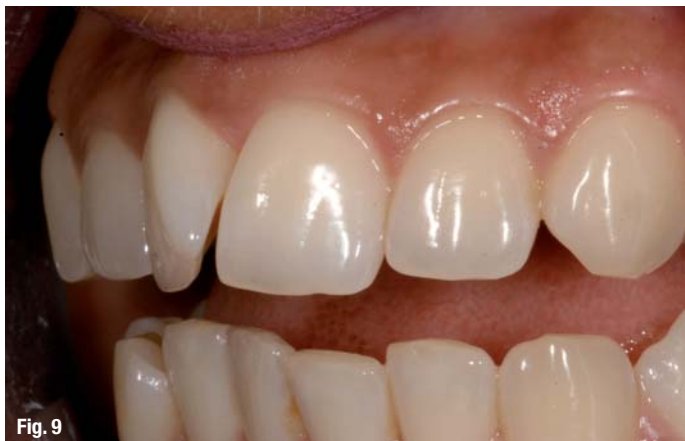

Fig. 9

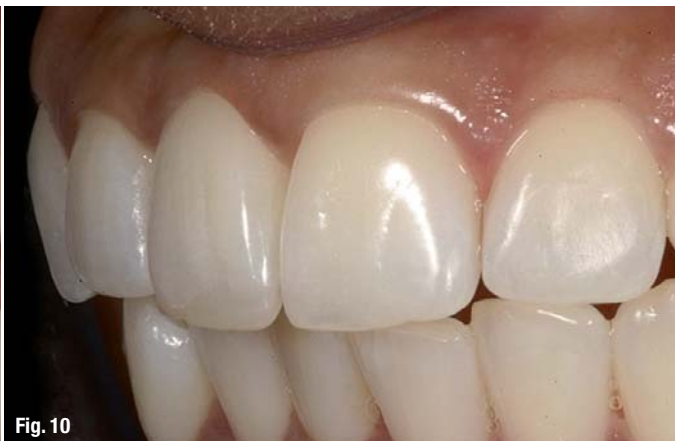

Fig. 10

Fig. 9 Close side view before treatment.

Fig. 10 Close side view after treatment.

El-Mangoury *et al.*⁸ and Radlanski⁹ have demonstrated that there is no increased risk of caries after IPR, provided surfaces are smoothed correctly. Heins *et al.*¹⁰ and Tal¹¹ have demonstrated that there is no increased risk of periodontal disease, despite the decreased interproximal space.

Critically, Inman Aligner treatment uses progressive, anatomically respectful IPR. While the extent of IPR required is already known, it is **never** carried out in one treatment. In order to ensure minimal risk, IPR (0.13 mm per visit per contact point) is carried out only in small increments. The patient is sent away with the Aligner. Owing to the Aligner forces, the gaps will be closed after two weeks. Interproximal reduction is performed at each appointment only as needed, using strips or discs, which ensures the stripping is far more anatomically conservative than would be the case using burs. This significantly reduces the risk of excess space formation, gouging or poor contact anatomy.

Lingual/labial anchors

Composite resin just incisal placed either incisal or gingival to where the bows contact will help them to function more efficiently. This can also be used for the labial surface, especially in cases in which teeth are being retracted. Strategic placement is vital for success and can be very helpful in the treatment of rotated teeth and the extrusion of teeth.

Appliance adjustment

The forces can be varied by adjusting the spring components or replacing springs for larger, longer springs. Generally, adjustments are not necessary, except in more complex cases, for which training is required to understand the correct spring types and compression rates to use.

Case I

The 25-year-old female patient complained about the appearance of her lower anterior teeth.

She gave a history of orthodontic treatment in her teenage years, having a fixed appliance fitted for a period of two years. She had been given a retainer at the time but was told to wear it at night for three months only. She had noticed her lower four incisors starting to become crowded again. Treatment options discussed were invisible braces, conventional fixed brackets or an Inman Aligner.

The amount of space required for reduction was calculated as 3.5 mm. Interproximal reduction was performed using diamond strips (Brasseler). A reduction of 0.13 mm at each contact point was achieved at the fitting appointment. This was verified with a thickness gauge. The patient was seen three weeks later and a further 0.13 mm reduced at each contact point. The teeth were aligned in just over nine weeks. The Aligner was left in for one month to stabilise the tooth positions. Tooth whitening was undertaken for two weeks during the last two weeks of treatment. Simultaneous bleaching is a significant advantage in removable systems and helps patient motivation. Finally, an orthodontic retention wire was bonded in place on the lingual surfaces, ensuring the patient could still use super floss for hygiene.

Case II

A female patient presented complaining mainly about her rotated upper right central tooth. She was considering veneers to redistribute the space over the four front teeth. This would have meant that she would undergo three aggressive preparations and one invasive preparation with endodontic treatment of the upper right central tooth.

Space calculation with model analysis indicated that treatment would be possible with an Inman Aligner. Because of the relatively low cost, the patient selected this option, understanding that we would not be able to achieve Golden Proportion, owing to the width and length of her lateral teeth.

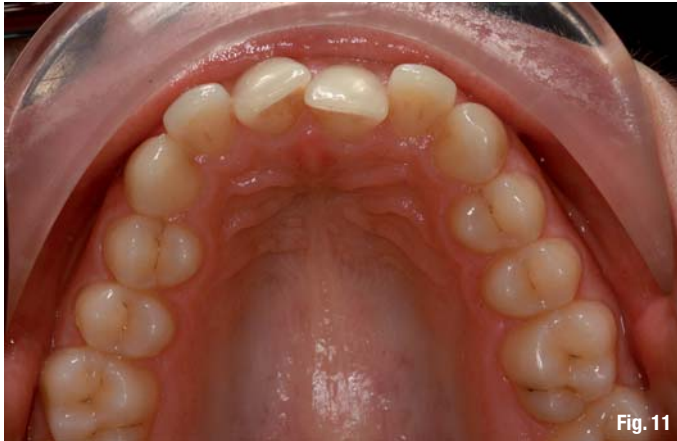

Fig. 11

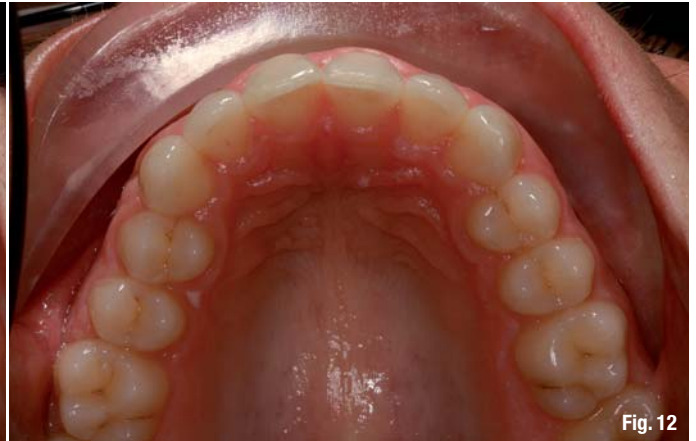

Fig. 12

A midline screw was incorporated to allow for a small amount of operator-controlled expansion to provide a little more space. (Incorporated expanders can be used to release extra space in cases with very constrained space.) Up to 2 mm of space can be created by expansion, which has the effect of pushing the cuspid away from the lateral. After alignment, this expansion will just relapse. It is a temporary technique to create sufficient space to align the anterior teeth. After alignment, the expander can even be unwound if required.

Treatment took 13 weeks with three sessions of IPR. A total of 3 mm was stripped and 1 mm was gained with the expander. The teeth were retained using orthodontic gold chain bonded from canine to canine. An upper Essix Retainer was also worn nightly as back-up for retention.

Case III

The patient in this case originally presented for porcelain veneers on her upper anterior teeth. The preparations would have required root-canal treatment of two of her incisors in order to achieve adequate emergence profiles.

After case options had been discussed in detail, the patient decided upon an Inman Aligner to align the teeth with veneers following this treatment. The patient was aware that after alignment, retention would be mandatory. Spacewise arch analysis calculated only 0.8 mm crowding in deviation from the ideal curve.

An upper Inman Aligner with combined expander was fabricated and fitted. Minimal IPR was carried out with a 0.1 mm reproximation strip to separate the teeth. The patient turned the screw every five days for six weeks, which created nearly 2 mm of space. This allowed space for the centrals to advance and de-rotate. At this point, the expander was unwound to ensure that any mild residual spacing had

closed. The teeth were aligned within nine weeks. An Essix Retainer was used to retain the teeth passively for a further four weeks, after which a bonded wire retainer was placed.

The patient was very pleased with the alignment and decided that she would not need veneers. Veneers could always be used at a later stage if necessary, after more enamel has eroded with age and when veneers can be placed additively, for example.

The result was not a perfect smile with regard to the criteria defined by Smile Design theory. Yet, that she no longer wanted veneers arguably provides us with a far better and more ethical outcome long term.

Retention

Retention for anterior alignment is essential.¹²⁻¹⁴ Recommended retainer types are bonded canine-to-canine fixed retainers commonly fabricated from .0195" or .0175" multi-strand stainless-steel wire. An indirect method can be used to adapt the wire to a working model. This can then be transferred to the teeth, using a specially made jig and bonded with flowable composite resin to the backs of the aligned teeth. The occlusion must be clear when placing a retainer on the maxillary arch.

Advantages of this method are that the flexibility of the arch wire allows for physiological tooth movement and prevents bond fracture through occlusal forces. Periodontal ligament stability is also achieved with this technique.¹⁵

Essix Retainer

This retainer is a thermo-formed, clear, thin appliance that is easily made and very comfortable for patients. The recommended post-operative regimen for Inman Aligner treatment is to wear the retainer at night for 18 months and after that for two nights a week indefinitely.

Fig. 11_Occlusal view before treatment.

Fig. 12_Occlusal view after nine weeks with an Inman Aligner.

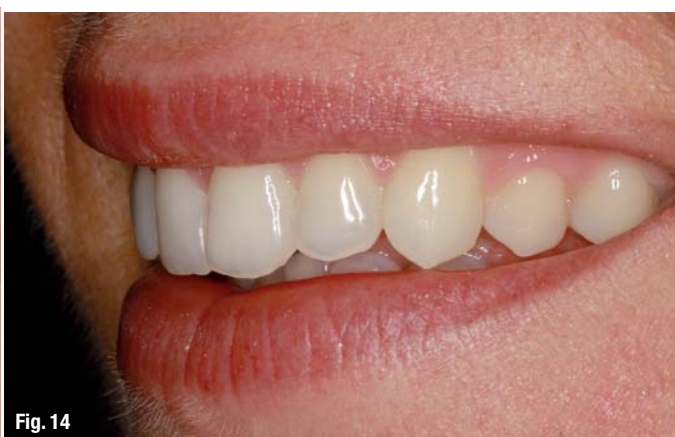
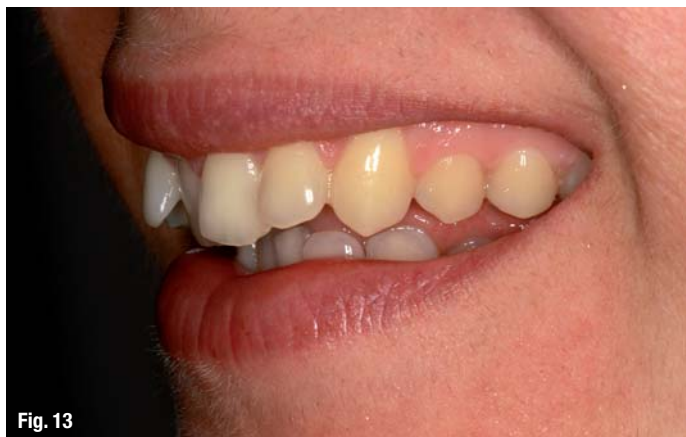
Fig. 13

Fig. 14

Fig. 13_Side smile view before treatment.

Fig. 14_Side smile view after treatment.

Conclusion

With the Inman Aligner, patients previously put off by the treatment time and fixed brackets of traditional orthodontic techniques or the expense of more recent invisible braces, could, if their case is suitable, achieve anterior tooth alignment far more

As a result, the Inman Aligner is profoundly changing the approach to cosmetic dentistry by those using it with the advanced techniques of domino effect, combined expansion and strategic anchor placement in the UK and Europe.

This new approach to cosmetic dentistry in the UK has been confirmed by figures from the British Academy of Cosmetic Dentistry (BACD). The 2008 study of data from 200 BACD members demonstrated a massive 345 per cent increase in orthodontics used in cosmetic cases but no increase in the use of veneers. Of this increase, 230 per cent was solely due to the use of the Inman Aligner in cases in which patients would not otherwise have had their teeth treated, owing to the time cost of fixed braces and no desire to have appliances adhered to their teeth. Many of these patients were those who would have opted for aggressive preparation of their teeth for veneers, before the Inman Aligner.

Fig. 15_Spacewize calculation.

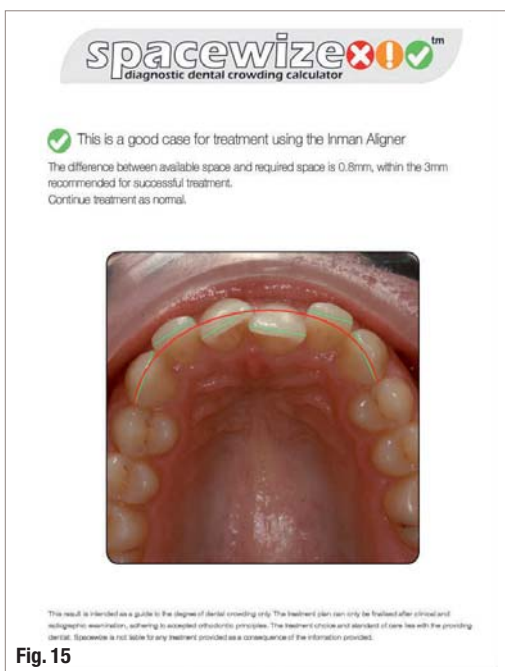


Fig. 15

quickly with a simpler, single appliance. Inman Aligners are suitable for alignment of incisors and canines with up to 3 mm of crowding—5.5 mm once the treating clinician is trained in using the system—and represent a very conservative and potentially revolutionary alternative to radical tooth preparation for achieving tooth alignment using porcelain restorations.

The Inman Aligner allows for a rapid and aesthetic alignment at low risk and cost to our patients. The patient is able to preview the staged changes of alignment, perhaps followed by bleaching and bonding.

Acknowledgements

I would like to thank Donal Inman CDT (Inman Orthodontic Laboratory), NimroDENTAL Orthodontic Laboratory—the only Straight Talks Seminars-certified Inman Aligner laboratories—and Dr James Russell for Case III.

Editorial note: A complete list of references is available from the publisher.

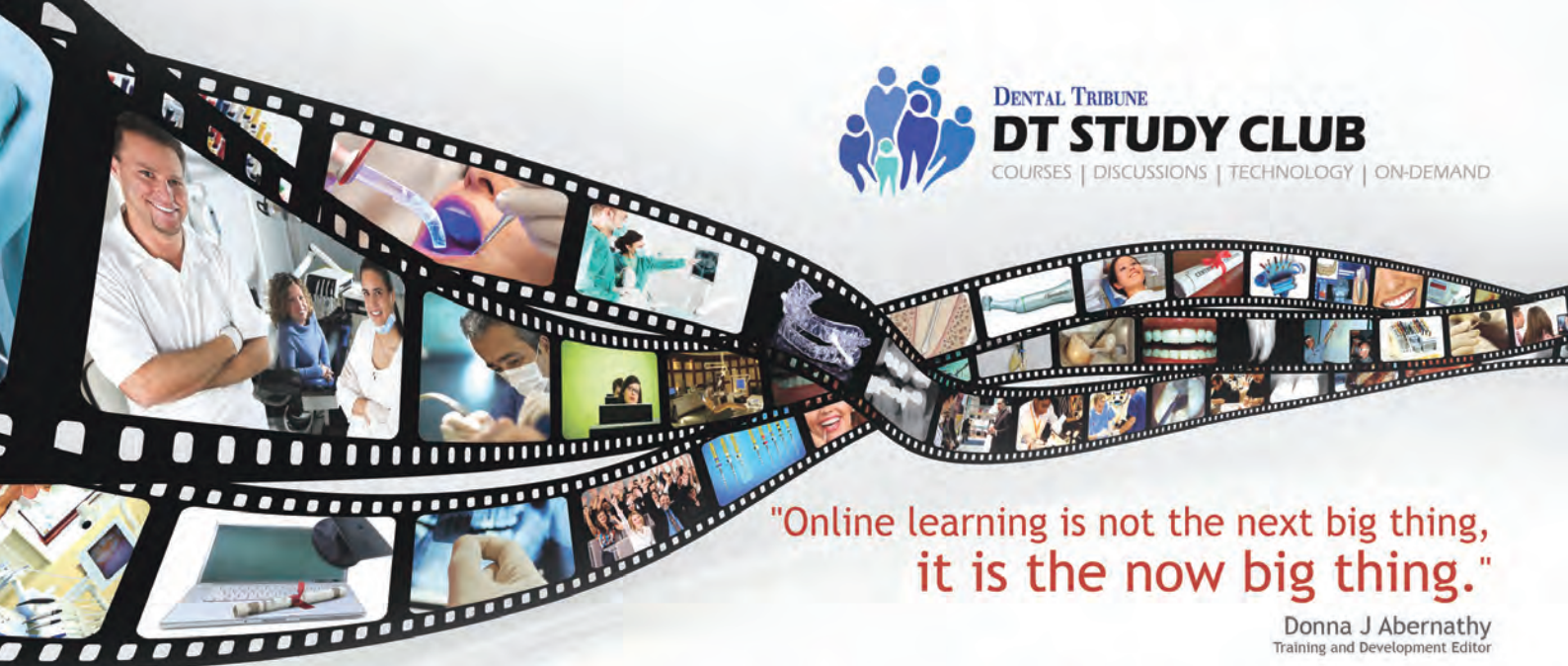about the author	cosmetic dentistry
<p>Dr Tif Qureshi is Vice-President of the British Academy of Cosmetic Dentistry. He presents hands-on courses and lectures on the Inman Aligner worldwide. For information on course dates and training, please go to www.straight-talks.com or www.inmanaligner.com. Alternatively, contact Caroline Cross on +44 207 255 2559 or at info@straight-talks.com.</p>	



DENTAL TRIBUNE

DT STUDY CLUB

COURSES | DISCUSSIONS | TECHNOLOGY | ON-DEMAND



**"Online learning is not the next big thing,
it is the now big thing."**

Donna J Abernathy
Training and Development Editor

DTSC - COURSES, COMMUNITY, TECHNOLOGY, ON-DEMAND

The DT Study Club makes all of this is possible from the comfort of your own computer and without travel expenses. In other words, welcome to the community!

The purpose of this study club is to provide practitioners like yourself an opportunity to learn and network with like-minded colleagues in a friendly, non-threatening environment. We encourage you to take advantage of Dental Tribune's global outreach to access a variety of fresh perspectives and cultures, enhancing your educational mix.

24/7 LIVE AND INTERACTIVE ONLINE COURSES

Fulfill your yearly CE requirements with our growing list of archived ADA CERP approved courses.



DISCUSSION FORUMS

focused on helping today's practitioners to stay up to date. Networking possibilities that go beyond borders to create a truly Global Dental Village



VIDEO REVIEWS OF PRODUCTS

Our opinion leaders unveil new products, services, and give you their first impressions of the industry's hottest topics.



PEER REVIEWED CASE STUDIES

Upload, comment, participate. We encourage you to share your cases for review with like-minded practitioners.



 REGISTER FOR FREE ON WWW.DTSTUDYCLUB.COM

CONTESTS WITH CHANCES TO WIN FREE TUITION FOR ADA/CERP C.E. ACCREDITED WEBINARS

SPONSORSHIP AND SPEAKING INQUIRIES:
JULIA WEHKAMP, J.WEHKAMP@DTSTUDYCLUB.COM, (416) 907-9836.

ADACERP
CONTINUING EDUCATION RECOGNITION PROGRAM



PRACTICE MANAGEMENT



GENERAL DENTISTRY



COSMETICS



ENDODONTICS



IMPLANTOLOGY



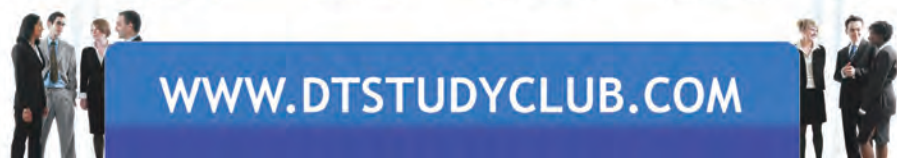PERIODONTICS



ORTHODONTICS



DENTAL HYGIENE



WWW.DTSTUDYCLUB.COM

A simplified method for the removal of cemented implant prosthetics

Author_ Dr Scott Davis, Australia

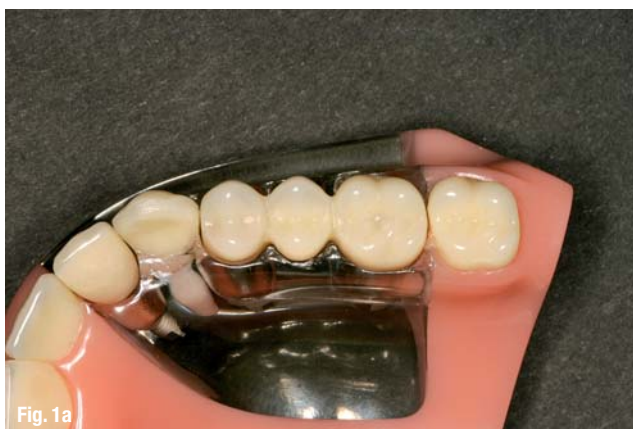

Fig. 1a

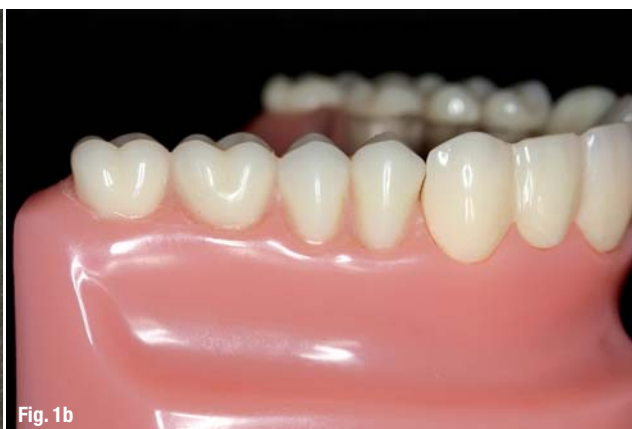

Fig. 1b

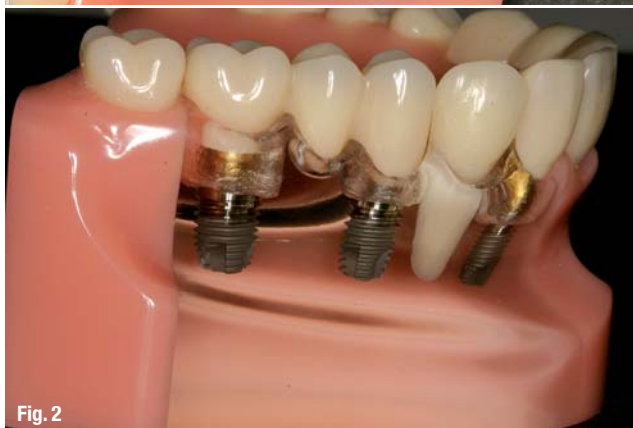

Fig. 2

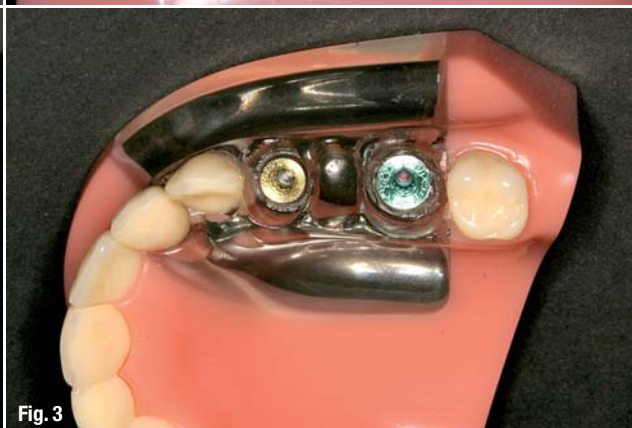

Fig. 3



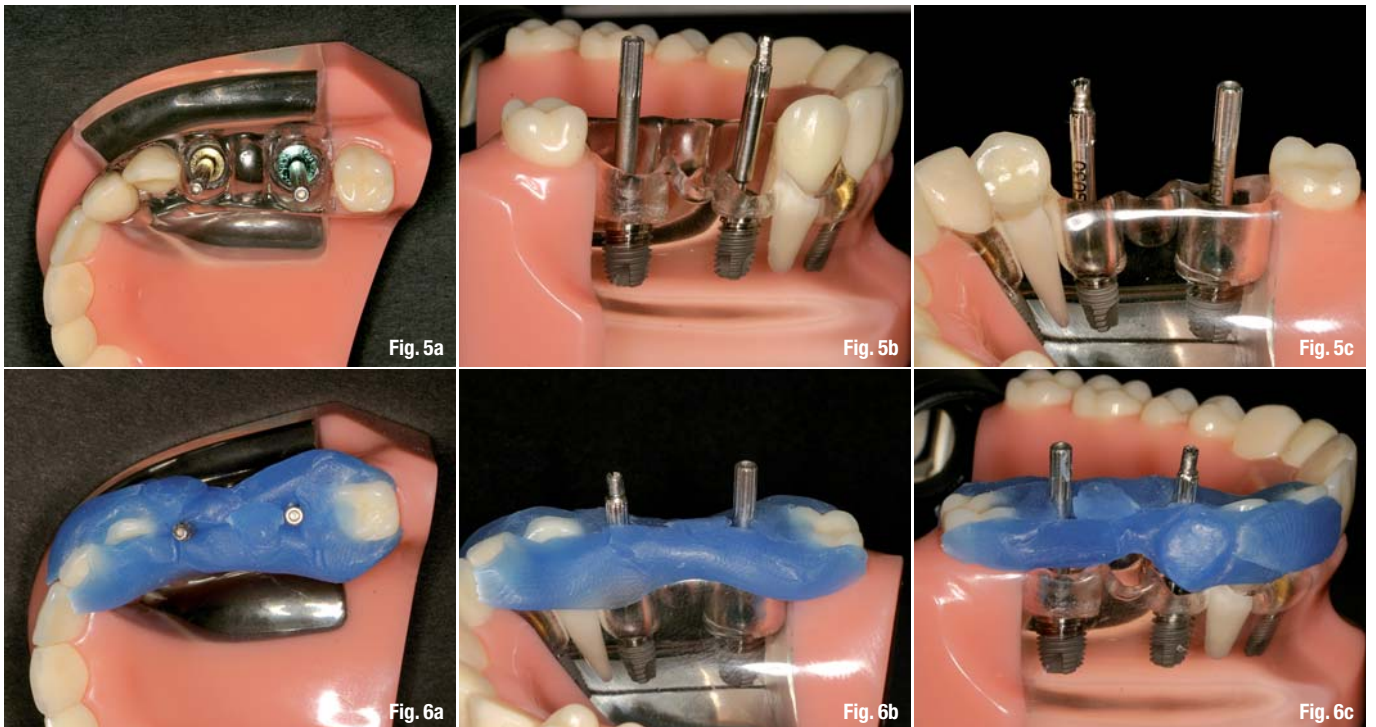
Fig. 4

_There are times when it becomes necessary to remove the cemented prosthetic restoration from one or more implants and the prosthesis is not amenable to conventional crown and bridge removal devices. In order to remove these prostheses, we need to gain access to the abutment screws by drilling through the crown or bridge. The challenge is to create the smallest possible access holes and to do this with a minimum of clinical time and effort. This article will describe a simple method for constructing and using a device to guide the development of appropriate access holes in the implant prosthesis.

I was lucky enough not to have a patient with a loose or damaged bridge to use for this presentation, so I used a patient education model to provide the images to facilitate the description of the technique (Figs. 1a & b). Figure 2 shows the location of the implants.

_Constructing the device

The master cast that was used for the construction of the implant prosthesis is the central element for this technique (Fig. 3). Long screws from impression copings (Fig. 4) or long labora-



tory screws are inserted into the implant analogues (Figs. 5a & b). The cast is blocked out with periphery wax to act as formwork for the construction of the device (Figs. 6a–c). The wax should extend for at least one tooth on either side of the prosthesis.

If no tooth is present distal to the prosthesis, then additional teeth are covered anteriorly to maximise stability of the device. The wax should also block out the full dimensions of the prosthesis. I like to construct the mesial aspect of the device to be sufficiently wide and robust for a finger or thumb to be readily placed on this area for stabilising the device during preparation of the access holes.

The model and the screws are lubricated with either petrolatum or a water-based lubri-

cant. Auto-polymerising or light-curing resin is adapted to the cast to cover the adjacent occlusal surfaces and encompass the screws in the implant analogues (Figs. 7a & b).

I prefer to use GC pattern resin and in the later stage of polymerisation, I remove the screws before they potentially become locked in the resin. Once the material sets, it is trimmed and polished (Figs. 8a & b) then checked for stability on the model. Additional material can be added if required.

If a stone model of the prosthesis is available, it is convenient to confirm the stability of the device and to assess that there is no contact between the prosthesis and the device (Fig. 9). The intaglio surface is adjusted as required to ensure appropriate adaptation.

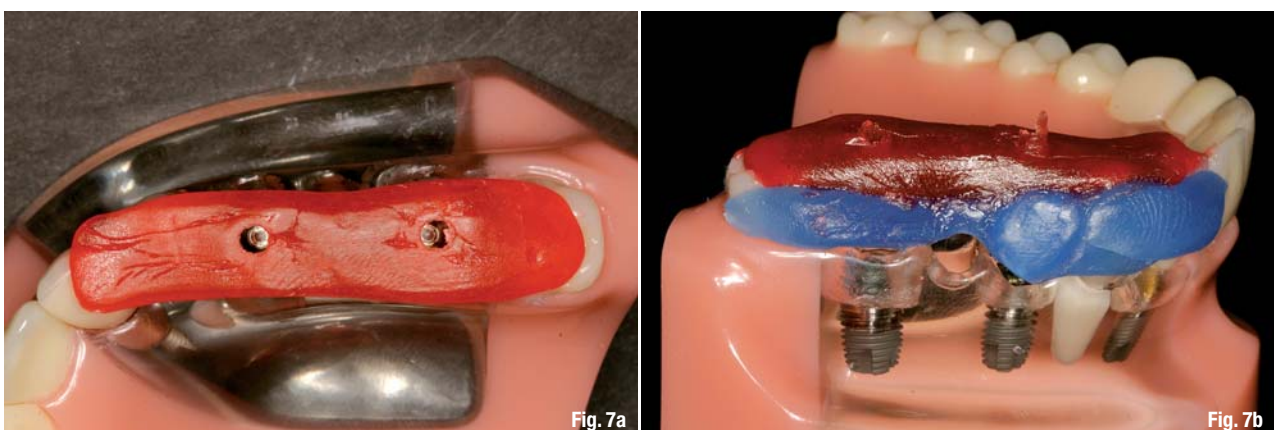

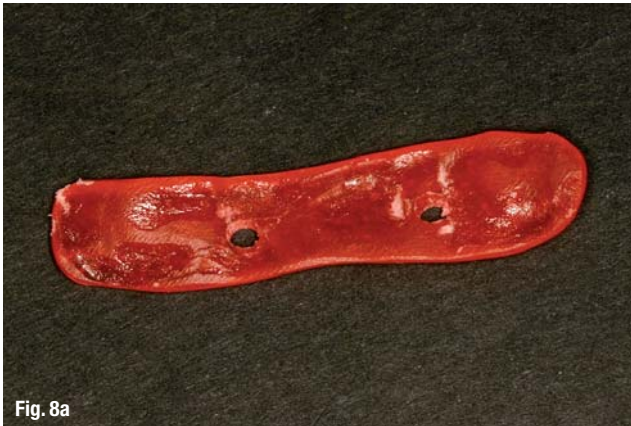


Fig. 8a

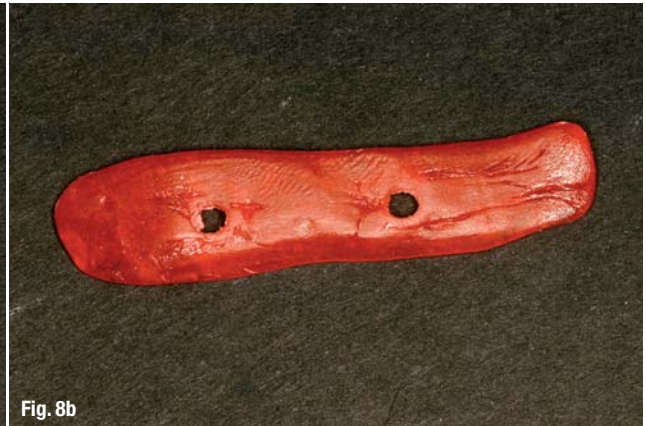

Fig. 8b

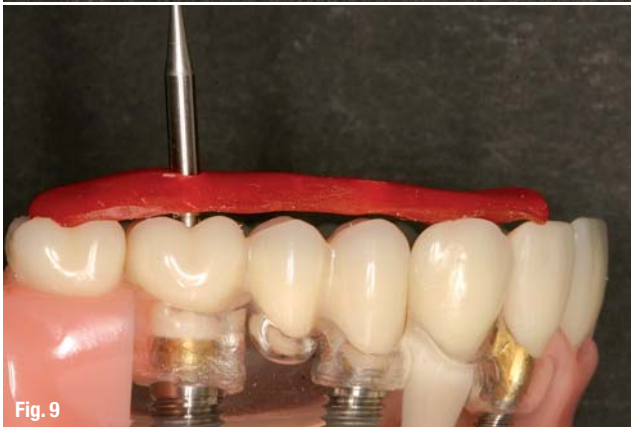

Fig. 9

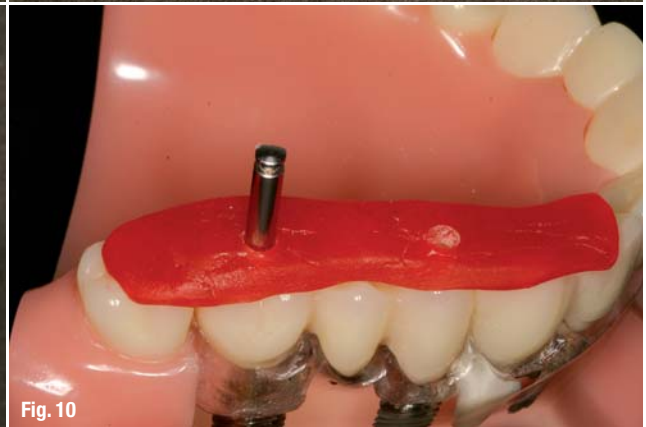

Fig. 10

In the clinic

The chairside process is simplified by the use of this acrylic resin guiding device that provides a visual aid for the appropriate position for drilling the access holes. Ideally, porcelain should be removed using a diamond high-speed bur with copious irrigation. I prefer to use a round diamond bur for this purpose, as it is less likely to cause porcelain chipping. If the prosthesis is metal ceramic, the metal substructure is first penetrated with a small round carbide bur. Subsequently, a metal-cutting tungsten carbide bur is used to widen the access as required. Figure 10 shows a screwdriver passing through the guide

into the abutment screw. Figures 11a and b show the precision of the preparation without over-preparation.

Once the access hole has been deburred of obturating materials, an appropriate screwdriver is inserted. In order to prevent ceramic delamination, it is important to ensure the driver is not contacting any porcelain before significant torque is applied. I initially insert the driver and inspect for lack of contact with the porcelain. Following, I apply light hand torque to the driver in order to determine that it is fully seated before a second inspection to ensure no porcelain contact. Finally, the screw and the prosthesis are removed.

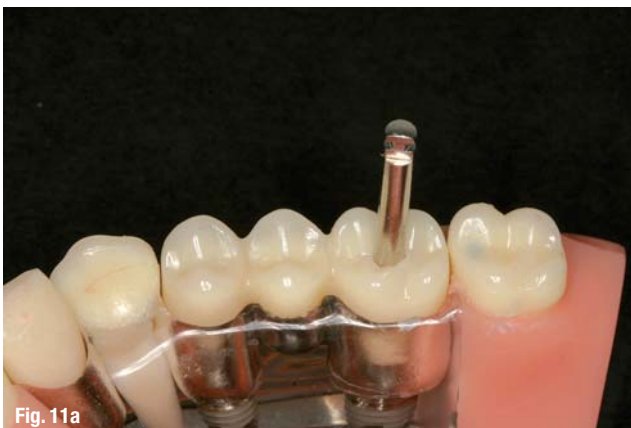

Fig. 11a

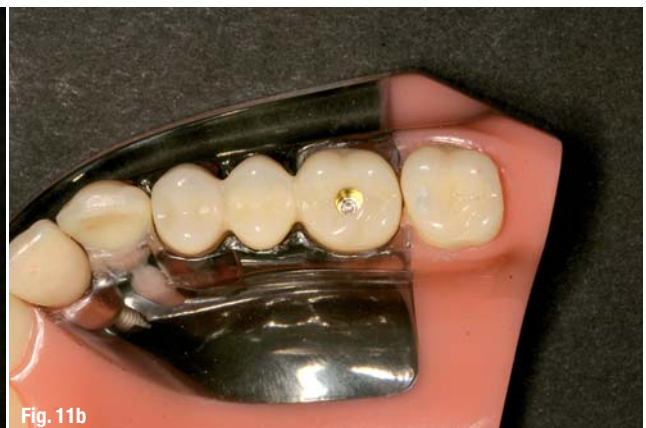

Fig. 11b

_Discussion

Drilling free hand into the prosthesis with no guide can result in oversized access holes and wasted chairside time. The primary goal of the method described here is to maximise laboratory procedures in order to reduce chairside time. We also minimise the size of the access holes, which reduces the damage to the prosthesis.

Delegation of the construction of the device to a technical assistant can further reduce cost, for both the patient and us. Thereby, a task to which we look forward with trepidation can be reduced to a minor inconvenience.

By minimising the diameter of the access holes, we increase the probability that the prosthesis can be returned to the patient after dealing with the reason for removal. Once the prosthesis has been removed from the mouth, there are two options. Firstly, we could consider the abutment/prosthesis as a single item. After inspection and cleaning, the prosthesis can be replaced. Had the abutment screw become loose, then the grain

structure of the screw may have become elongated and the screw should be replaced.

The second option is separating the abutment from the crown or bridge. When they cannot be separated by mechanical means, they can be separated by gentle heating in a furnace. Slowly heat to less than 200 °C for five minutes, then the abutment and prosthesis should separate very easily. Allow to cool to room temperature slowly, then inspect porcelain for defects before returning to the patient._

_about the author

cosmetic
dentistry

Dr Scott Davis graduated from the University of Sydney in 1984 with a Bachelor of Dental Science degree and completed his Master of Dental Science degree in Prosthodontics in 1993 at the University of Western Australia. He worked as a senior lecturer in Restorative Dentistry. Since 1997, he has worked in a private specialist practice. Dr Davis can be contacted at scott@davisdental.com.au.

AD

implants

international magazine of oral implantology



One issue free of charge!

You can also subscribe via
www.oemus.com/abo



Subscribe now!

*Prices include shipping and VAT

I hereby agree to receive a free trial subscription of **implants international magazine of oral implantology** (4 issues per year). I would like to subscribe to **implants** for € 44* for German customers, € 46* for customers outside of Germany, unless a written cancellation is sent within 14 days of the receipt of the trial subscription. The subscription will be renewed automatically every year until a written cancellation is sent to OEMUS MEDIA AG, Holbeinstr. 29, 04229 Leipzig, Germany, six weeks prior to the renewal date.

▶ Reply via Fax +49 341 48474-290 to OEMUS MEDIA AG or per E-mail to grasse@oemus-media.de

Last Name, First Name

Company

Street

ZIP/City/Country

E-mail

Signature

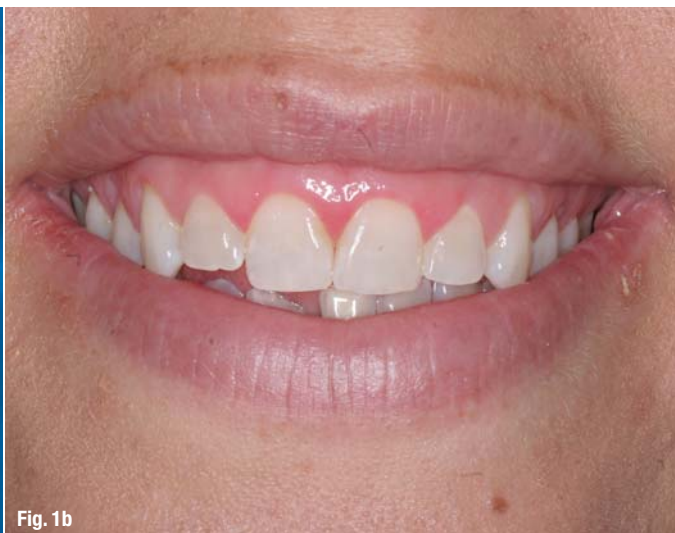Notice of revocation: I am able to revoke the subscription within 14 days after my order by sending a written cancellation to OEMUS MEDIA AG, Holbeinstr. 29, 04229 Leipzig, Germany.

Signature

CDE 2/10

Bite alteration for reducing gummy smiles: Two case reports

Author_ Dr David S. Frey, USA



The traditional method for correcting a gummy smile with too high a gum-to-teeth ratio is enormously invasive. It involves cutting and lifting the gum tissue back in order to remove bone, after which the gums have to be sewn back in place.

This process requires a six- to eight-week healing process, which is not only painful¹, but also aesthetically displeasing. Another method, which involves repositioning the lip after cutting into the vestibule, is equally invasive and requires an excessively long period of healing.²

Today, cosmetic dentists often perform a gingivectomy utilising a scalpel, electrosurge or diode laser in order to correct an overly gummy smile. However, these methods are contingent upon the amount of biological width available in the patient.³

Two to three millimetres of gum tissue must remain over the bone after the tissue has been

removed. This biological width limitation usually creates one of two options. Either the patient must be subjected to invasive surgical gum flaps accompanied by bone removal or the patient must be satisfied with very little change in the gum-to-teeth ratio. If the patient presents with a significantly short vertical index (VI; measured from the cemento-enamel junction [CEJ] of tooth #8 or 9 to the CEJ of tooth #24 or 25), the gummy smile condition may not be satisfactorily corrected when only a gingivectomy is performed.

Cosmetic dentists undertake regular training to adjust horizontal smile abnormalities such as overcrowding and large gaps. The idea of changing the vertical dimension of occlusion as part of improving dento-facial aesthetics is not new.⁴ While occlusal philosophies may differ, most will agree that the occlusion must be given careful consideration when changing its vertical dimension, both as part of the diagnostic process and to avoid possible iatrogenic results.

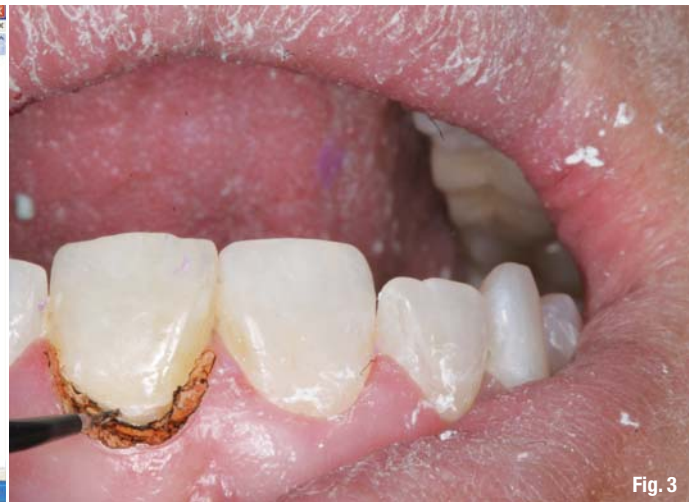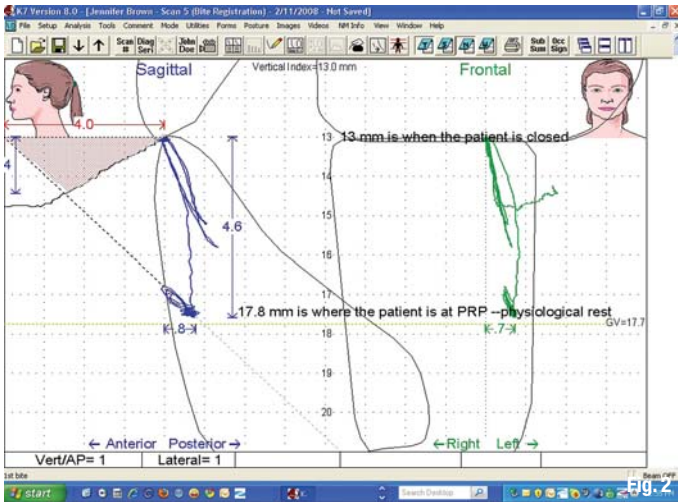


Fig. 3

When the patient presents with a significant difference between the mandibular position at habitual occlusion relative to an optimised occlusal position, increasing vertical dimension by increasing the crown-to-gum ratio and effectively decreasing the gummy smile can have a dramatic cosmetic effect on a patient. The cases presented here illustrate that vertical abnormalities such as gummy smiles may sometimes be further enhanced and the need for surgical intervention minimised if the vertical dimension of the bite is altered.

In adjusting the vertical dimension, care must be taken to ensure a functional occlusion in the finished case. Jankelson described the method for muscle relaxation in order to determine mandibular position at true physiological rest.⁵ Application of transcutaneous electrical nerve stimulation (J5 Myomonitor TENS, Myotronics) for a period of 30 to 40 minutes allows the muscles of mastication innervated by cranial nerves #5 and 7 to relax.

While there is no universal agreement amongst dentists on occlusal philosophy, I have found the Jankelson method of establishing a true mandibular physiological rest position (PRP) to be highly effective. Physiological rest position is objectively verified with surface electromyography and computerised jaw tracking (K7 Evaluation System, Myotronics).

The K7 System provides calculations that indicate when the patient is at physiological rest as compared with habitual rest. These calculations indicate the extent to which VI can be increased or the extent to which freeway space can be decreased without interrupting the patient's true PRP.

Concerns about changing the entire arch to effect anterior defects are unfounded for two reasons. Firstly, the newly diagnosed mandibular position is verified as correct by using an orthotic before anything is done to the natural teeth. Secondly, this technique of treating a

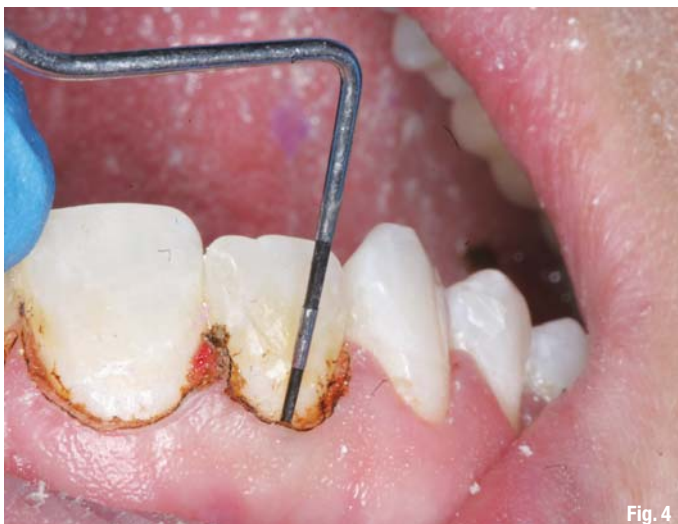

Fig. 4

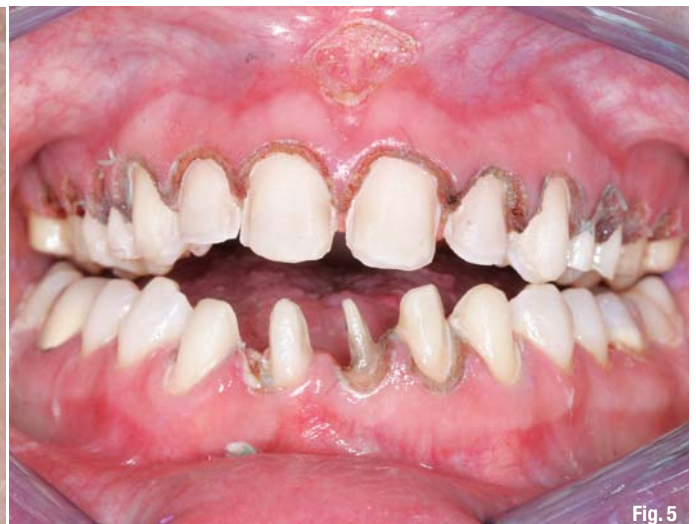

Fig. 5



Fig. 6

gummy smile is based upon opening the bite. Therefore, when porcelain is added to the full arch to increase vertical dimension, it involves little to no destruction of the natural dentition because the restorations are placed over the occlusal surface.

In my experience and as illustrated in these cases, once the PRP of the mandible has been established, the increased gum-to-teeth ratio is significant prior to the removal of any gum tissue. It is prudent to mention here that if the patient's PRP does not differ significantly from habitual rest after TENS relaxation, very little change in vertical dimension would be available for this procedure.

Use of the Golden Proportion to establish a pleasing aesthetic effect has been seen in art, architecture and various scientific fields for centuries and used in dentistry for at

least 25 years.⁶ Like occlusal philosophy, some question its validity.^{7,8} However, it is used by many today in plastic surgery, orthodontics and aesthetic dentistry as an aspect of treatment planning for facial aesthetics and, in my experience, patients are highly pleased with the outcome.

Calculations utilising the Golden Proportion equation can also be applied to tooth shape and will indicate whether the 'golden' VI can be reached through a combination of bite correction and gingivectomy. These simple calculations indicate whether the vertical length of the patient's smile will be more aesthetically pleasing after the corrections have been made:

$\text{Width of central incisor} \div 1.618 = \text{golden length of central incisor}$

$\text{Length of central incisor} \times 1.618 = \text{golden VI}$

Based on these two calculations, an orthotic in the optimal bite position for both aesthetics and function can be fitted for the patient's upper teeth. The orthotic is worn for approximately one month in order to be certain that no headaches, neck pain, grinding or chewing issues ensue. This period also provides the patient with time to become psychologically accustomed to the additional tooth length that shows prior to the gingivectomy and application of veneers. If the patient is dissatisfied with the length-to-width ratio of the teeth in the orthotic, adjustments can be made to the orthotic before beginning the procedure.

Correcting the bite before performing a gingivectomy can offer a greater aesthetic result, significantly reducing the amount of gum tissue that shows before a gingivectomy is performed.



Fig. 7a

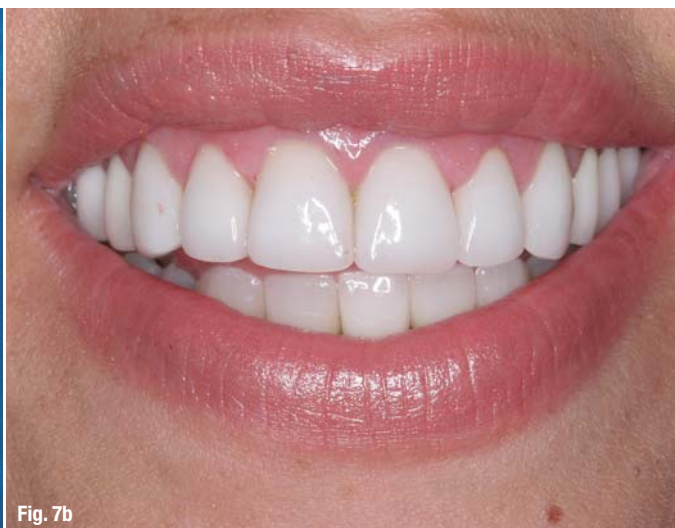

Fig. 7b

It should be noted that placement of porcelain on the molar teeth to increase vertical height is extremely conservative because the porcelain lies on top of the existing teeth.

Even if the available biological width is significant, correcting the bite allows the dentist to remove less gum tissue during the gingivectomy. A frenectomy can also be performed, when appropriate, to remove a small portion of the lip frenulum with a diode laser. This allows the lip to move down slightly over the previously exposed gums and can also reduce the amount of gum tissue that must be removed during the gingivectomy.

Case I

A 27-year-old female presented with 13 mm VI, requesting that her gummy smile be corrected or reduced. The average VI is 17 to 21 mm. Therefore, her VI would be aesthetically pleasing if increased by a minimum of 4 mm, reducing the gum-to-teeth ratio.

The patient's teeth were out of proportion, with the length-to-width ratio of the central incisors almost identical, rather than the aesthetically pleasing length-to-width ratio of 75 to 80 per cent. Her gums were inflamed and in poor condition. Therefore, she was first referred to a hygienist for cleaning, root planing, deep scaling and debriding (Figs. 1a & b).

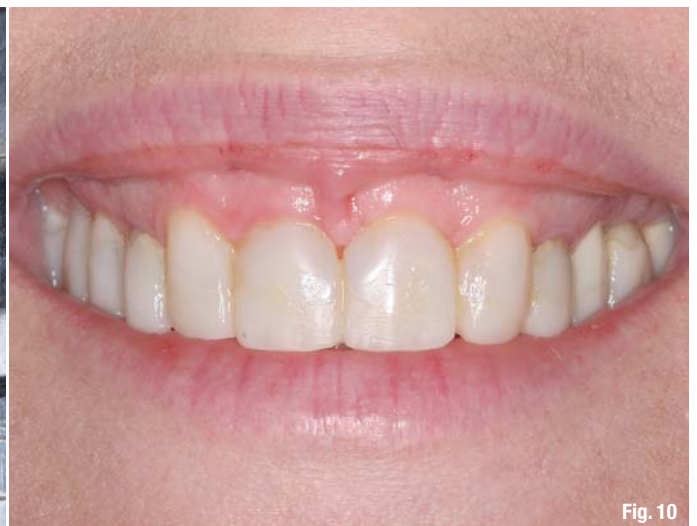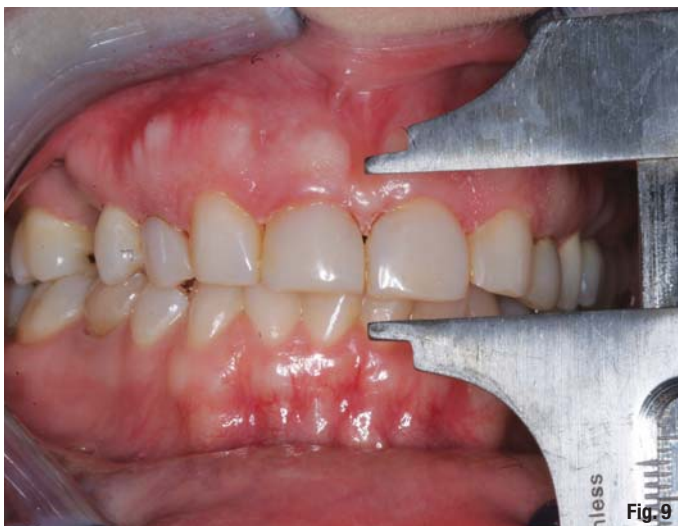At physiological rest, the K7 Evaluation System calculated that the patient's VI was increased to 17 mm before any gum tissue was removed. The gum-to-teeth ratio had already been increased significantly. The Golden Proportion equations were also utilised. The patient's



golden VI was calculated at 16.7 mm, and the orthotic gave her a VI of 17 mm (Fig. 2).

It was determined that the patient would have an even greater aesthetic result by further increasing the gum-to-teeth ratio. Sounding determined that 2 mm of gum tissue could be removed safely, so an additional 2 mm was burned away utilising a diode laser. The diode laser immediately cauterises the tissue and causes less bleeding and less post-operative stress for the patient than other gingivectomy methods. As demonstrated in Figure 3, gum tissue had been removed from three teeth, showing the additional vertical length compared to the remaining teeth. The healing process following the diode laser gingivectomy is approximately two weeks.

Sounding indicated that a gingivectomy alone would have allowed for the removal of no



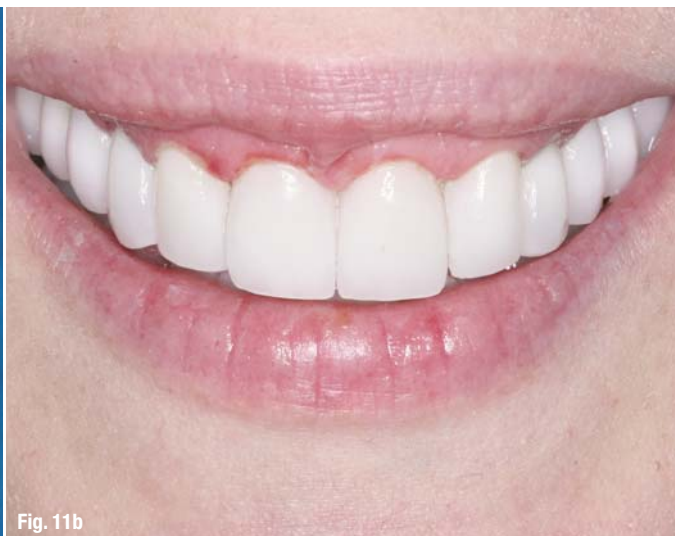

Fig. 11a

Fig. 11b

more than 2 mm of gum tissue. In this case, the patient's VI would have increased only to 15 mm, leaving her with a gummy smile even after the procedure was completed (Fig. 4).

After administering a local anaesthetic, a frenectomy was performed on the patient to further release the upper lip and reduce the gum-to-teeth ratio (Fig. 5).

The bite was checked again and the temporaries were applied. The final VI increase for the patient following the bite correction, frenectomy and gingivectomy was 6 mm, increasing the VI from 13 to 19 mm. While the increase could have remained at 17 mm, the additional 2 mm was an aesthetic improvement (Fig. 6).

After the veneers had been applied and the gums healed, the patient showed an exceptional reduction in her gummy smile, as well as increased gum health with proper stippling (Figs. 7a & b).

_Case II

A 37-year-old female patient presented with a 12 mm VI and complaints of an overly gummy smile (Fig. 8). Although her gums were healthy, she was referred to a hygienist for a thorough cleaning prior to treatment.

The patient's central incisors were 9 mm wide, while the Golden Proportion was 11.6 mm. The patient's golden VI, therefore, was 18.8 mm, which was an increase of 6.8 mm from her current VI. Measurements of the patient's teeth showed that the length-to-width ratio was almost identical (Fig. 9).

The Myomonitor and K7 Bite Evaluation System determined that the patient's bite could be opened to a VI of 17 mm, which was a significant increase of 5 mm from her original VI. The patient wore an orthotic for one month, after which her bite was re-checked and temporary teeth applied (Fig. 10).

Sounding determined that 2 mm of gum tissue could safely be removed. After a frenectomy and gingivectomy utilising the diode laser, 2 mm of tissue was removed, further increasing the patient's VI to 19 mm, allowing for an exceptional correction to the gummy smile condition of 7 mm from the original 12 mm VI (Figs. 11a & b).

Editorial note: A complete list of references is available from the publisher.

_about the author

cosmetic
dentistry



Dr David S. Frey has been in private practice in Beverly Hills for over 20 years. A graduate of the University of Pacific Dental School in 1989, Dr Frey's passion for learning and excellence has allowed him to establish a very high-end cosmetic and reconstructive practice. Furthermore, Dr Frey has pursued extensive training and education at the prestigious Las Vegas Institute allowing him to more comprehensively evaluate his patients. He has authored two books, *Revitalize Your Smile* and *Revitalize Your Mouth*, and written for top US dental journals. He has appeared in *People* magazine for his work on celebrity idol Elliott Yamin, and has made multiple appearances on the *Learning Channel's* programmes *Ten Years Younger* and *A Personal Story*.



2010

GREATER NEW YORK DENTAL MEETING

86th
Annual Session

FREE REGISTRATION*

MEETING DATES:
NOVEMBER 26 -
DECEMBER 1

EXHIBIT DATES:
NOVEMBER 28 -
DECEMBER 1

The
Largest
Dental
Convention/
Exhibition/
Congress
in the
United
States



**Free registration
before November 26*

Please send me more information about...

- Attending the Greater New York Dental Meeting
- Participating as a guest host and receiving free CE
- I speak _____ and am willing to assist international guests
enter language



Name _____

Address _____

City, State, Zip/Country Code _____

Telephone _____ E-mail _____

Fax or mail this to:
Greater New York Dental Meeting or
visit our website: www.gnydm.com for more information.



For More Information:
Greater New York Dental Meeting™
570 Seventh Avenue - Suite 800
New York, NY 10018 USA
Tel: +1 (212) 398-6922
Fax: +1 (212) 398-6934
E-mail: info@gnydm.com
Website: www.gnydm.com

Provisional restorations in complex restorative cases

Author_ Dr Christopher Ho, Australia

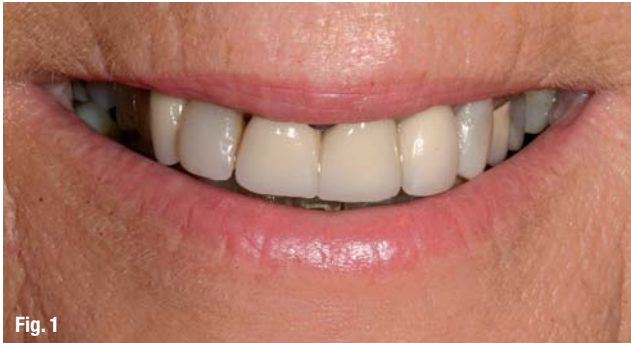

Fig. 1

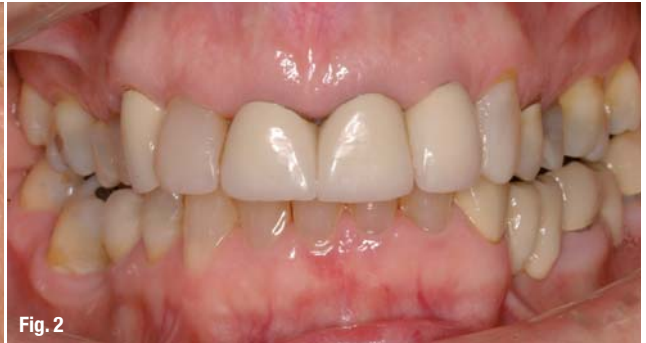

Fig. 2

Fig. 1 _Smile photograph, showing asymmetry in smile, maxillary cant, slanted midline, negative buccal corridor and poor axial inclination.

Fig. 2 _Retracted frontal photograph.

The aesthetic rehabilitation of patients with functionally compromised dentition frequently involves a multidisciplinary approach, incorporating several different treatment modalities. A correct aesthetic and functional diagnosis with an appropriate treatment plan, as well as careful material selection and application, are critical factors in the successful restoration.

The following case presentation demonstrates a multidisciplinary approach to recreating an aesthetic smile in a female patient with functionally and aesthetically compromised dentition.

Patients requiring prosthodontic rehabilitation often have multiple concerns (aesthetic, functional and health) and have avoided treatment for some time, owing to fear, cost and time constraints. It is the goal of treatment to provide aesthetic and functional dentition with minimal maintenance over the long term.

_Treatment planning and procedures

The primary objective was to recreate an aesthetic smile and to establish a functional occlusion. This involved orthodontic, periodontal and restorative modalities:

1. *Periodontal treatment:* The patient underwent preliminary treatment that included professional oral hygiene and reinforcement of oral hygiene practices.
2. *Orthodontic treatment:* The tipped and drifted mandibular teeth that were a consequence of the missing teeth were corrected.
3. *Diagnostic wax-up:* This allows the team to preview the desired aesthetic appearance. The diagnostic wax-up provides a guideline for the desired treatment and a blueprint for the final restorations. This wax-up also allows the manufacture of putty keys for provisionalisation and reduction guides for the preparation process.

Fig. 3 _Orthodontic treatment in order to upright tipped teeth and correct occlusal plane.

Fig. 4 _Gingival recontouring completed.

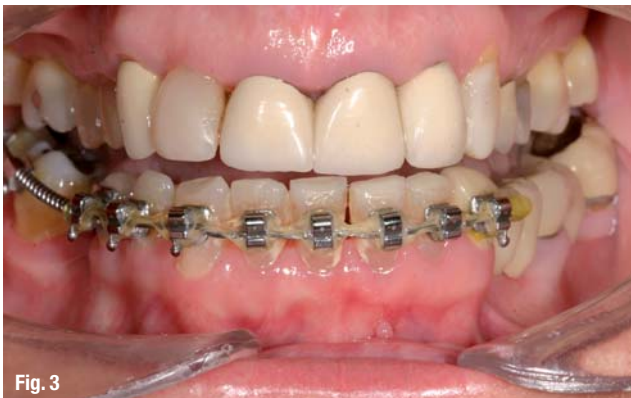

Fig. 3

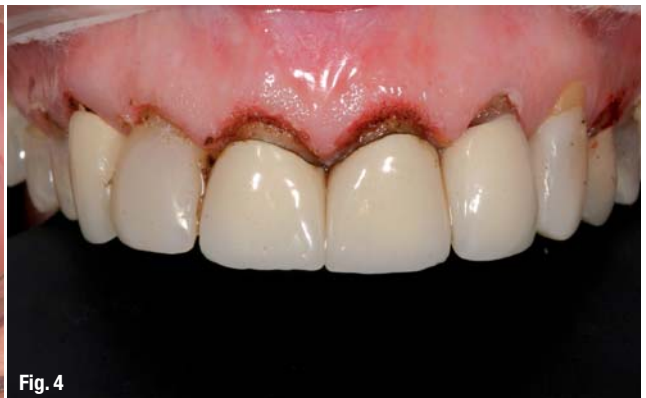

Fig. 4

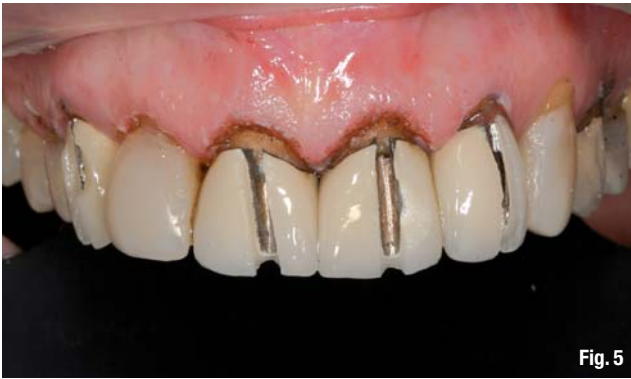

Fig. 5

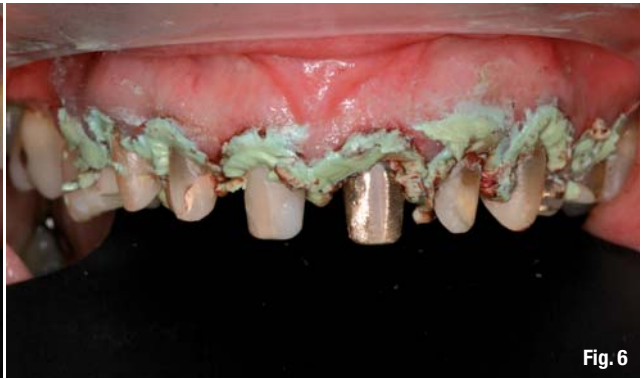

Fig. 6

4. *Gingival recontouring:* A 940 nm diode laser (EZlase, Biolase) was utilised to improve soft-tissue aesthetics. Periodontal bone sounding was performed to ensure that biologic width was not invaded. Gingival tissues were then lasered to improve the gingival contour, symmetry and gingival zeniths.

5. *Preparation:* It is recommended that an axial reduction of 0.8 to 1.0 mm and an occlusal reduction of 2.0 mm be made, as ceramic materials require a certain thickness to withstand masticatory and para-functional stresses. Chamfers or 90° rounded shoulders are recommended for finish lines in order to firstly provide sufficient bulk at the margins and secondly allow the transference of stresses around the margins. In order to minimise stress concentration within the restoration, all line angles should be rounded, all sharp edges smoothed and boxes, grooves and 'butt' type shoulders are contraindicated.

6. *Impression procedure:* A double zero retraction cord (Ultrapack #00, Ultradent) was placed into the gingival sulcus as a first cord. A retraction paste (Expasyl, Pierre Rolland) was then placed over the first cord. The correct use of this retraction paste should see blanching of the gingival tissues as the paste is extruded into the gingival sulcus. An impression was made with a polyvinyl siloxane material (Imprint 3, 3M ESPE).

7. *Maxillo-mandibular relations:* The Kois Dento-Facial Analyzer System registers and transfers the patient's occlusal plane and tilts in the occlusal plane in three planes of space to the articulator related to an average 100 mm axis-incisal distance. This allows orientation for aesthetic positioning of the anterior teeth in relation to the midline of the face and ensures correct orientation of the incisal plane.

9. *Provisionalisation:* The provisional restorations are duplicated from the diagnostic wax-up that incorporates the proposed changes. It allows patients a 'test run' of the final result by allowing them to see a preview of the planned result. This is an essential step in the planning process.

The aims of provisionalisation are:

- a. *Health:* pulpal protection and periodontal health and gingival stability;
- b. *Function:* the assessment and indication of any occlusal and phonetic problems with the proposed changes—the pronouncing of 'V' and 'F' sounds should create a light contact between the central incisor and the wet-dry line of the lower lip;
- c. *Aesthetics:* the assessment of the basic shade to be chosen, incisal edge display, form and shape of teeth, dental midline location, lip support, parallelism of incisal plane to inter-pupillary line as well

Fig. 5 Crowns sectioned in order to allow insertion of Christensen Crown Remover (Hu-Friedy) for removal.

Fig. 6 Use of Expasyl for haemostasis and retraction.

Fig. 7 Use of Kois Dento-Facial Analyzer to align midline and incisal plane.

Fig. 8 Two to three days after provisionalisation, for review of provisionals to ensure approval of shape, colour and other desired changes before final crowns are made.

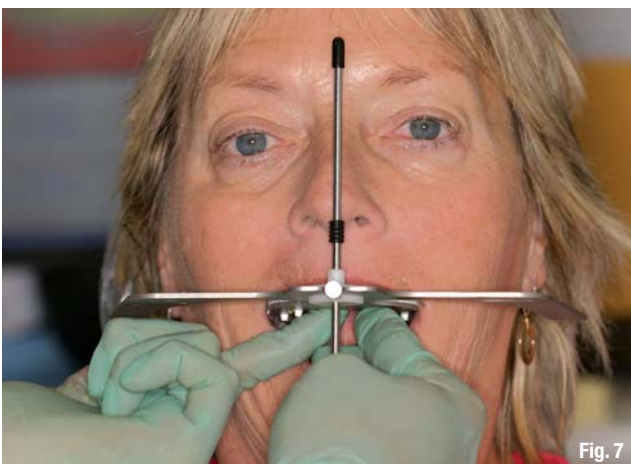


Fig. 7



Fig. 8

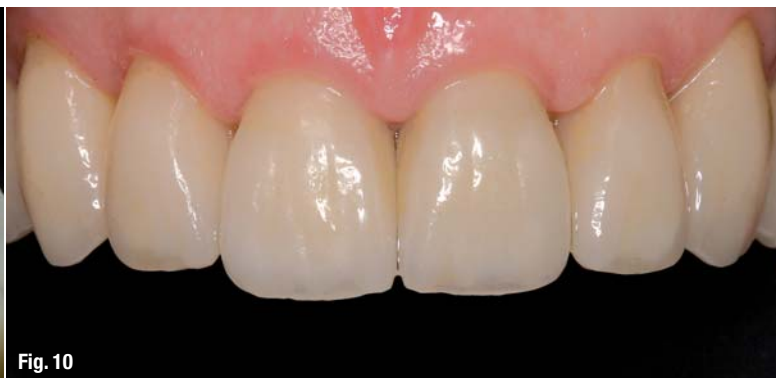
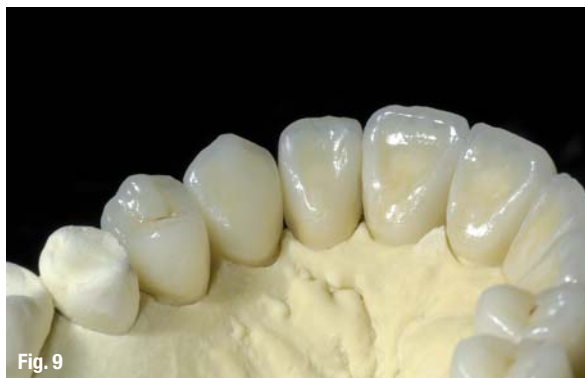
Fig. 9 Palatal view of all-ceramic crowns.
Fig. 10 Frontal view of completed all-ceramic crowns.

as the curvature of lower lip—evaluation of aesthetics provided by the provisionals at this stage is crucial in guiding the patient to the amount of display necessary for an aesthetic smile.

The provisional crowns were constructed with Protemp 4 (3M ESPE), a bis-acrylic resin composite. All contours were kept curvaceous and smooth with space made available for the patient to use interdental cleaning aids, owing to the provisionals being splinted together. The patient was given instructions on oral hygiene during the provisional phase and was asked to return in two to three day's time for final approval.

I recommend this delayed approach of assessing the provisionals, as patients are not pressured into deciding whether they like the provisionals on the day of preparation. Patients are often anaesthetised and suffer the associated facial palsy and cannot adequately assess aesthetics at this time. The patient will also often ask friends and family about the proposed changes and the extra time allows patients to accustom themselves to their new look.

If the provisional restoration requires modifications, it can be adjusted and an impression taken to communicate the changes to the ceramist.

10. *Cementation*: The crowns were received back from the laboratory and tried in the mouth. I prefer not to use local anaesthetic for the patient to approve the final aesthetics prior to cementation. However, if local anaesthesia is required, an alternative technique is to use the AMSA local anaesthetic block technique so that the injection achieves pulpal anaesthesia of the central incisors through the second premolar without collateral numbness of the face and facial muscles of expression. This is best achieved with a computer-controlled injection system (The Wand, Milestone Scientific) that delivers a virtually painless palatal injection.


Once the patient is happy and approves the final aesthetics, the restorations are prepared for cemen-

tation. The patient is asked to return to the office one week later in order to allow a final examination of the aesthetics, phonetics and occlusion.

Conclusion

The aesthetic rehabilitation of a patient with functionally compromised dentition frequently involves a multidisciplinary approach. Proper sequence and planning, involving periodontal, orthodontic, aesthetic and restorative treatment, is required with good communication amongst the whole team—the patient, ceramist, the treating clinicians.

Provisionalisation is a significant factor in achieving a successful aesthetic outcome for both the patient and the dental team. It permits the patient to preview their future teeth, allowing them to assess the aesthetic and functional changes. Invaluable information can be gained regarding aesthetic factors, including incisal display, buccolingual position of teeth, smile line and shade, and functional criteria can be assessed with phonetic and occlusal changes.

<u>about the author</u>		cosmetic dentistry
	<p>Dr Christopher Ho received his Bachelor of Dental Surgery with first-class honours from the University of Sydney, Australia. He received a Graduate Diploma in Clinical Dentistry (Oral Implants) and a Master's degree in Clinical Dentistry (Prosthodontics) with distinction from Kings College London. Dr Ho is a sought-after lecturer on aesthetic and implant dentistry internationally and within Australia. He lectures at several universities in Australia and the UK. He is a faculty member of the Global Institute for Dental Education.</p>	
<p>Dr Ho has a referral-based private practice in prosthodontic and implant dentistry in Sydney.</p>		




تحت رعاية
سمو الشيخ حمدان بن راشد آل مكتوم
نائب حاكم دبي، وزير المالية
رئيس هيئة الصحة بدبي



Under the patronage of
H. H. Sheikh Hamdan Bin Rashid Al Maktoum
Deputy Ruler of Dubai, Minister of Finance
President of the Dubai Health Authority

مؤتمر الإمارات الدولي لطب الأسنان و معرض طب الأسنان العربي
UAE International Dental Conference & Arab Dental Exhibition



Delivering Science & Technology

إيدك
AEDDC[®]
Dubai 2011

www.aeddc.com



Largest Dental Event
in the **Middle East & North Africa**

1 - 3 February, 2011

مركز دبي الدولي للمؤتمرات والمعارض
Dubai International Convention & Exhibition Centre

Organised by



Strategic Partner



Supported by



For more information, call or visit our website

INDEX[®] Conferences & Exhibitions Organisation Est.

P.O. Box: 13636, Dubai - United Arab Emirates | Dubai Healthcare City, Ibn Sina Bldg. #27 Block B, Office 203
Tel: +971 4 3624717 | Fax: +971 4 3624718 | E-mail: index@emirates.net.ae | Website: www.aeddc.ae

In vitro bleaching study with a 20 % hydrogen-peroxide system

Authors_ Dr Daniel C.N. Chan, Dr Albert Kwok-Hung Chung, Dr William D. Browning & Dr So-Ran Kwon, USA

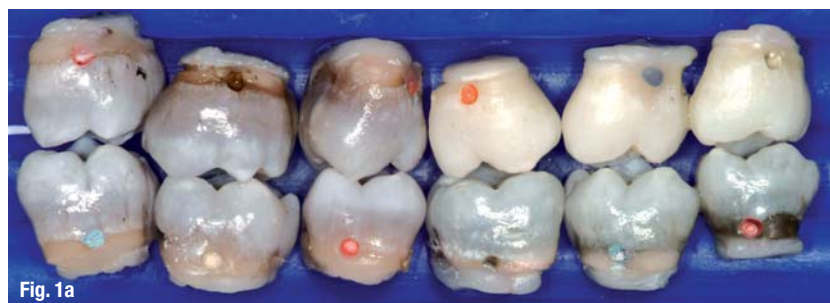


Fig. 1a

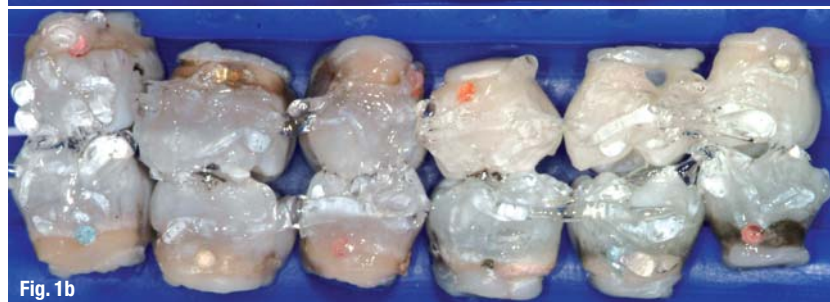

Fig. 1b

Figs. 1a & b Stained teeth before and after application of the 20 % whitening gel.

While nightguard vital bleaching is the most used treatment modality for whitening of discoloured teeth, in-office tooth whitening procedures that use a concentration of higher than 10 % carbamide peroxide have been advocated as acceptable alternatives. Patients often choose in-office bleaching when they desire more rapid whitening of their teeth and/or when they do not desire to wear bleaching trays for at-home techniques.¹ Although manufacturers indicate that most in-office bleaching agents can be used without light irradiation, studies have reported that light activation can enhance the results of the bleaching procedures.² The light energy increases the rate of

hydrogen peroxide degradation to form oxygen free radicals, leading to an enhancement of the bleaching process.²⁻⁵

Introduced in 1948, tetracyclines (TCN) are broad-spectrum antibiotics that may be used in the treatment of many common infections in children and adults. One of the negative side-effects of TCN is incorporation into tissues that are calcifying at the time of drug administration, such as teeth, cartilage and bone. A resulting permanent discolouration of both the primary and permanent dentitions can vary, such as yellow or grey or brown, depending on the dosage and the type of the drug received, as well as the duration of exposure to the drug.^{6,7}

In recent literature, it has been noted that Minocycline, a semi-synthetic member of the TCN family widely used in the treatment of acne, also causes abnormal pigmentation of collagenous tissues such as the skin, thyroid gland, nails, bone, sclera and conjunctiva in adults. The pigment is the product of an oxidation reaction, and laboratory studies have shown that the pigment formation can be induced by exposure to ultraviolet light in the presence of air.⁸ Similarly, Minocycline has been shown to cause a blue-grey to grey discolouration of the teeth of adults. This appears to be linked to the cycle of demineralisation and remineralisation of the enamel surface, and can produce staining that is clinically indistinguishable from staining during tooth development.⁹

As a continuation of what was reported by Harada¹⁰, we recently described an effective *in vitro* method to produce standardised discolouration of extracted human molar teeth using Chlortetracycline and its analogs.¹¹ Utilising this technique, a readily available source of discoloured teeth can be produced to evaluate the efficacy of various bleaching protocols.

The purpose of the present study was to evaluate the effects of one in-office tooth whitening procedure (Zoom 2, Discus Dental) on such standardised discoloured teeth to assess their usefulness as models for bleaching research. Our hypothesis was that the teeth discoloured by the *in vitro* technique

Fig. 2 Stained teeth demonstrating application of the mercury metal halide light. Note the way that all the stained teeth fit inside the scope of the light.




Fig. 2

would whiten in the same manner and to the same degree as non-experimental teeth.

Materials and methods

Twenty extracted human molar teeth were sectioned approximately 2 mm above their furcations to provide the clinical crowns for this experiment. Images of the buccal and lingual surfaces were recorded with a digital camera (Canon EOS-D30, Canon) using standardised settings throughout the experiment. Each tooth was then analysed with a dental spectrophotometer (VITA Easyshade, VITA) against a neutral grey background.

After baseline recordings, the pulp chambers were etched for 60 seconds with 37 % phosphoric acid gel and then thoroughly rinsed with distilled water. Saturated solutions of Chlortetracycline, Doxycycline and Minocycline were produced by mixing 100 to 250 mg of the five respective medications in 5 ml of distilled water. Only the resulting supernatant was recovered for use. Five pulp chambers were filled with 0.5 ml of each of the solutions. Distilled water was used as a control in the five remaining pulp chambers. Composite resin disks were used to seal the chambers of all teeth.

The teeth were then placed crown first into a centrifuge tube and subjected to centrifugation at 2,800 rpm for 20 minutes. After centrifugation, the teeth were stored in distilled water for one week before exposure to continuous light irradiation with two 60 W Xenon lamps for seven weeks. Digital images of the colour change of both the buccal (B) and lingual (L) surfaces were recorded against a neutral grey background. The chroma (C*), brightness (L*) and hue (H*) values were recorded with the spectrophotometer, and the colour differences (ΔE) between baseline and seven weeks were calculated from the spectral data. Colour differences were calculated using CIE ΔE*, using the following formula:

$$\Delta E^* = [(\Delta L^*)^2 + (\Delta C^*)^2 + (\Delta H^*)^2]^{1/2}$$

In-office whitening procedure

At the completion of the discolouration phase, three randomly selected samples from each group were subjected to Zoom 2 in-office tooth whitening procedures. The Zoom 2 system uses a hydrogen-peroxide-based tooth whitener, which comes pre-packaged as two individual components: a 25 % hydrogen peroxide gel and a proprietary activator. These two components are mixed at room temperature to form a working gel that has a 20 % concentration of hydrogen peroxide and a pH between 7.5 and 8.5 (Figs. 1a & b). Prior to the application of

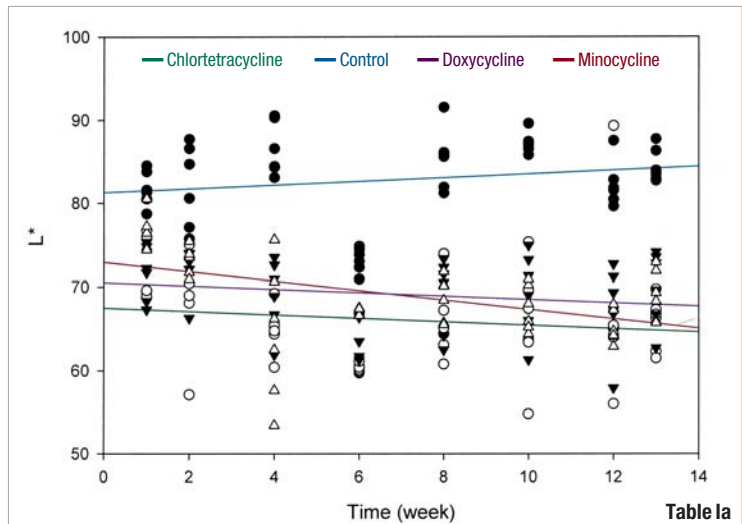


Table 1a

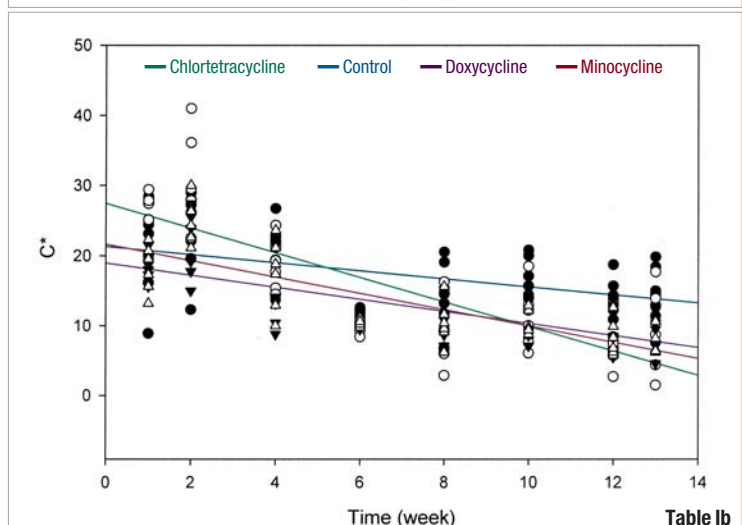


Table 1b

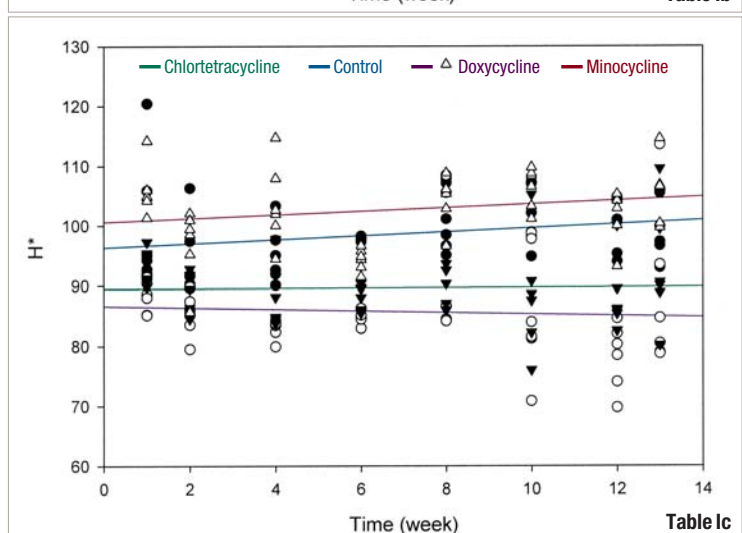


Table 1c

the gel to the sample teeth, the samples were coated with a solution supplied by the manufacturer in the form of pre-treatment starter swabs.

Tables 1a-c Regression plots of L*, C* and H*.

The treatment sessions were broken down into three 15-minute applications of the 20 % concentration hydrogen peroxide gel. Between each

Figs. 3a-d The stained teeth and control groups demonstrating progress from baseline through weeks 1, 3, 5 and 7.

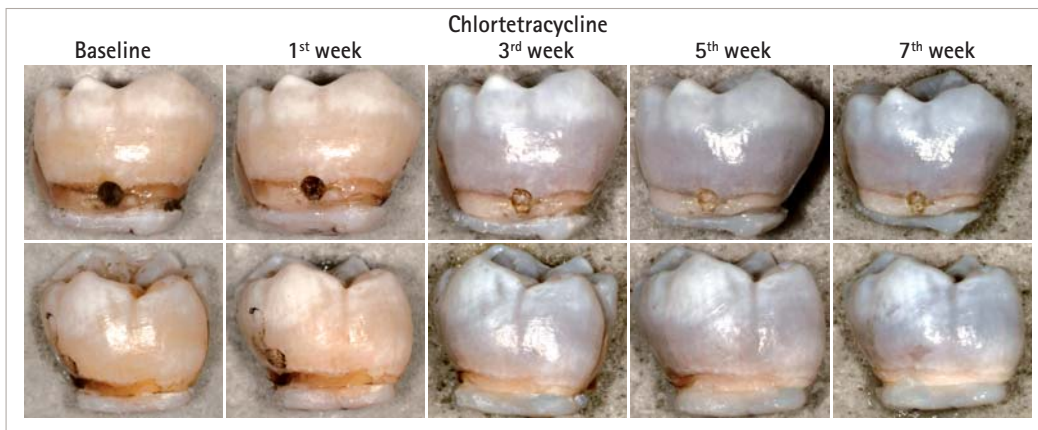


Fig. 3a

application, the gel was removed with high volume suction and the samples were wiped clean with cotton gauze saturated in distilled water. Therefore, the total exposure of the teeth to the bleaching agent was limited to 45 minutes per session. Sessions were performed once a week for seven weeks.

The gel applications were activated by the use of the Zoom 2 mercury metal halide light unit that, according to the manufacturer, emits violet coloured light with a wavelength in the range of 350 to 400 nm. When placed into position, the light unit is capable of illuminating all of the teeth simultaneously (Fig. 2). The use of this light unit implies that a specific wavelength of light activates some aspect of the whitener and enhances the whitening effect. An infrared filter helps to minimise the amount of heat generated at the surface of the teeth during the treatment session.

Immediately following the completion of each 45-minute session, digital images of both the buccal and lingual surfaces were recorded against a neutral grey background. The L*, C*, and H* values were also recorded with the spectrophotometer. The samples were stored in distilled water until the next session to prevent desiccation.

Results

The means of the L*, C* and H* values for each of the TCN derivatives and the control as recorded by the spectrophotometer at the specified weekly intervals are listed in Table II. Tables Ia to c show the regression plots of the L*, C* and H* values for the TCN and control groups. Statistical analysis of the changes in L*, C* and H* between baseline and the final evaluation was performed. There was a significant association amongst treatment group, evaluation and interaction term, treatment group x evaluation, and L* (two-way ANOVA; $p < 0.001$, $p = 0.002$ and $p < 0.001$, respectively). All groups except Doxycycline demonstrated statistically significant differences in brightness between the baseline and the final evaluation (Holm-Sidak Multiple Comparisons Test; all comparisons to baseline; $p < 0.05$). For the Chlortetracycline-, Doxycycline- and Minocycline-stained groups a decrease in brightness rather than an increase was observed. The control group demonstrated a significant increase in brightness (Table Ia).

The mean L* for the control group was significantly higher than the Chlortetracycline, Doxycycline and Minocycline groups at baseline. Since

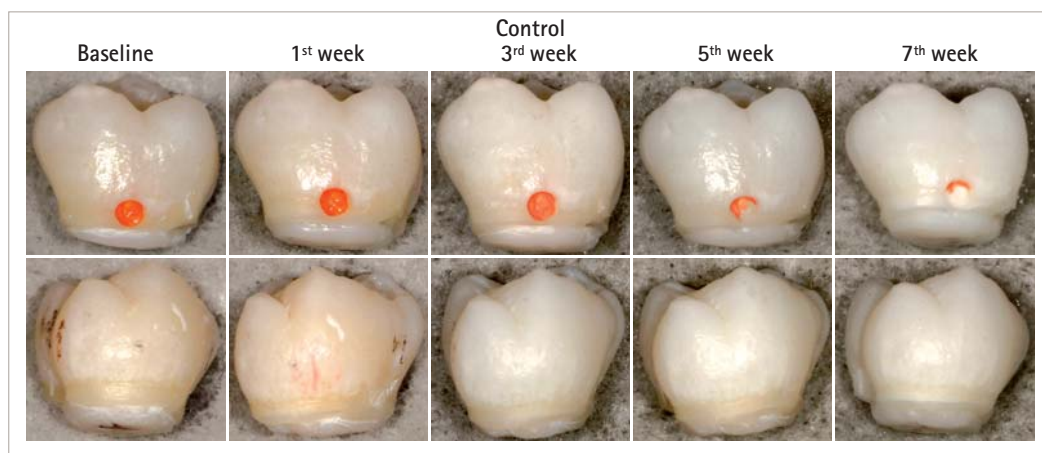


Fig. 3b

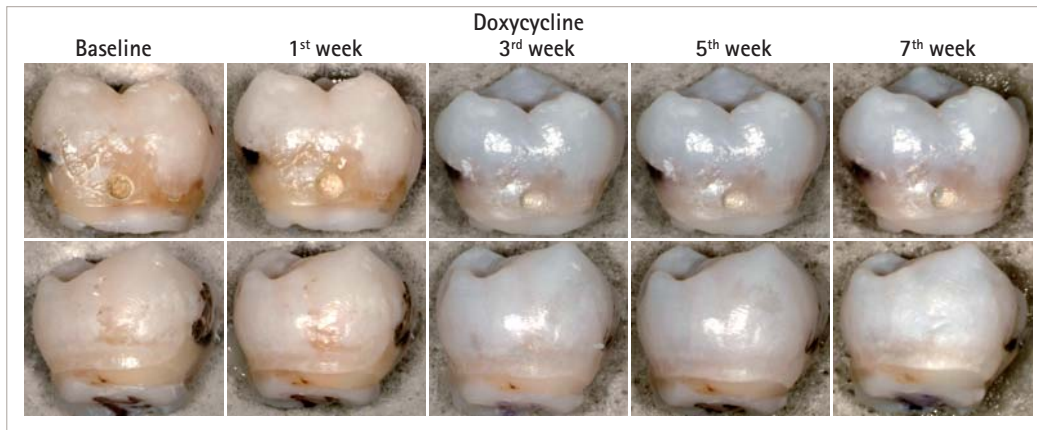


Fig. 3c

the mean L^* for the control group increased significantly between baseline and final measurements and the Chlortetracycline, Doxycycline and Minocycline groups' mean L^* decreased, these differences were even greater at the final evaluation period (Table Ia). While these changes explain the significant differences between the four groups, they do not indicate a positive whitening effect.

There was a significant association between C^* and treatment group, evaluation and the interaction term, treatment group x evaluation (two-way ANOVA; $p < 0.003$, $p < 0.001$ and $p = 0.002$, respectively). From the baseline to final evaluation, all four groups demonstrated a significant reduction in C^* (Holm-Sidak Multiple Comparisons Test; all comparisons to baseline; $p < 0.05$; Table Ib). With the C^* data, we once again see that there was a significant difference between the control group and the Chlortetracycline group at baseline, with the Chlortetracycline group significantly more chromatic.

At the final evaluation, the reduction in C^* for the Chlortetracycline, Minocycline and Doxycycline groups was so dramatic that the control group

was significantly more chromatic than these three groups (Holm-Sidak Multiple Comparisons Test; $p < 0.05$). There was no significant association between H^* data and the evaluation period (Table Ic). There was a significant association between treatment group and H^* . Comparing the means for the three experimental groups to the control, the hue value for Chlortetracycline was significantly lower (that is, more blue). The mean values for the four groups include data from both the baseline and final evaluations. It does not indicate there was a significant change in H^* , only that the Chlortetracycline teeth were more blue than the other three groups.

Discussion

Bleaching treatment is considered to be the most conservative procedure for treating discoloured and stained teeth when compared to laminate and crown restorations. Moreover, bleaching can be used to reduce the colour of dark teeth before preparation and placement of aesthetic indirect restorations. Therefore, depending on colour reduction, the tooth preparation can be more conservative and preserve more sound dental tissues.^{7,12-14}

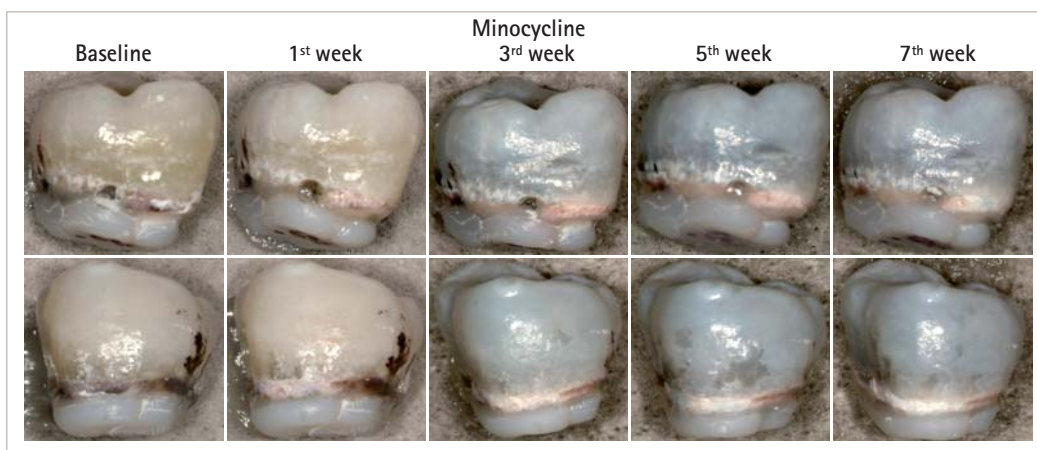


Fig. 3d

	Baseline			1 st week			3 rd week			5 th week			7 th week		
	L*	C*	H*	L*	C*	H*	L*	C*	H*	L*	C*	H*	L*	C*	H*
Chlortetracycline	71.58	27.13	88.12	68.10	30.50	85.23	60.28	9.63	84.65	65.70	11.23	85.63	65.40	8.97	88.25
Control	81.73	20.17	100.03	82.07	23.02	94.48	73.20	11.97	97.77	87.25	16.98	101.33	85.52	15.33	99.60
Doxycycline	71.60	18.37	93.23	72.22	21.47	88.42	64.32	10.25	88.12	69.28	12.10	88.37	69.90	8.53	93.05
Minocycline	77.32	18.10	105.9	73.20	25.17	96.95	67.15	10.48	94.30	67.43	10.28	106.25	69.00	8.12	105.67

Table II

Table II Means of colour difference at baseline and weeks 1, 3, 5 and 7.

Since its introduction to dentistry in 1989, night-guard vital bleaching has been proven to be a simple and safe procedure to lighten discoloured teeth. With extended treatment time, TCN-stained teeth can be expected to lighten in at least 86 % of cases. Side effects are usually mild and transient, disappearing within days of treatment completion with no long-term sequelae.¹⁵

Recent in-office tooth whitening procedures with 20 % hydrogen peroxide are gaining popularity as alternatives to at-home nightguard vital bleaching. The present study evaluated the efficacy of one such in-office whitening protocol on standardised *in vitro* stained human teeth.

One of the most significant observations is that visually the dark colour of the TCN-stained teeth appeared more intense as the treatment protocol progressed (Figs. 3a–d). The enamel appeared to be more translucent in all TCN groups, allowing the underlying darker dentine shade to be expressed. This is confirmed by the spectrophotometer readings in which the data shows a reduction in the L* values (Table II).

One explanation is that the superficial enamel layer was affected much faster by the higher concentration bleaching agent than the deeper dentine. Haywood hypothesised that dentine can be bleached in the case of Chlortetracycline-stained teeth.¹⁶ Success was achieved generally after two to six months of 10 % nightguard bleaching.^{17,18} In our case, the short treatment duration may not have resulted in sufficient contact time to effect dentine colour change. A slower process such as that suggested by Haywood may be indicated for teeth more intensely stained by tetracycline. Another explanation is that the colour of TCN-stained teeth became more intense in the artificial light owing to the photo-oxidation of this complex.¹⁹ However, there have been no studies on the efficacy or adverse effect of light in TCN-stained teeth.

The results support the conclusion that Zoom 2 provided a positive whitening effect, as one would

expect either a reduction in colour saturation and/or an increase in brightness. All four treatment groups demonstrated a reduction in C* from the baseline to final evaluations. Compared to the control group, the reduction in C* for the TCN groups was much more prominent. It is interesting to note that only the control group demonstrated an increase in brightness; all of the TCN groups decreased in brightness.

Conclusions

Subjecting the standardised TCN-stained teeth to the Zoom 2 in-office bleaching system yielded results consistent with a whitening effect when considering changes in chroma. However, a reduction in brightness was noted for all of the experimental groups, which is not consistent with the increase in brightness of the control group. Additionally, at the conclusion of the experimental period, the experimental groups attained a bluer hue when compared to their hue at the beginning of the experiment. No significant change in the hue of the control group was noted. Bleaching studies of teeth stained in the manner described in the present study may yield significantly different results to studies of teeth stained by TCN while they are developing.

Editorial note: A complete list of references is available from the publisher.


_contact
cosmetic
dentistry



Dr Daniel C.N. Chan
 University of Washington
 School of Dentistry
 Office of Clinical Services
 Health Sciences Center, D322
 P.O. Box 356365
 Seattle, WA 98195, USA

E-mail: dcnchan@u.washington.edu

THE AACD IS COMING TO EUROPE!
THURSDAY, SEPTEMBER 23 – SATURDAY, SEPTEMBER 25, 2010



AACD

comes to

EUROPE

London, England

Surround yourself with progressive, world-class dental professionals, educators, and exhibiting partners at this first-of-its-kind event. Experience the camaraderie and values for which AACD is known. Gain confidence in your clinical skills through hands-on workshops and in-depth lectures. Strengthen your team dynamic while fostering your passion for cosmetic dentistry. Register with the AACD today!

This special event is brought to you by the AACD, the British Academy of Cosmetic Dentistry, the Dental University of Paris Study Group, the European Society of Cosmetic Dentistry, the German Society of Cosmetic Dentistry, and the Swedish Academy of Cosmetic Dentistry.



www.aacd.com • info@aacd.com • 608.222.8583

 AMERICAN ACADEMY
OF COSMETIC DENTISTRY

The gold standard

Author_Dr Michael B. Miller, USA



Dr Michael B. Miller

We've all heard the term "gold standard" applied to many items in our everyday lives as well as those used in our practices. For the sake of discussion, we'll define "gold standard" as the product in a specific category that reaches the highest level of achievement sought after by all competitors. But is this nebulous concept static or dynamic? In my view, it has to be dynamic in our fast-changing world. Here are some gold standards in general dentistry and my view on whether they need to be updated.

Cast gold restorations

It seems appropriate to start here when discussing gold standards. According to several widely quoted surveys¹, dentists would prefer to have their own teeth restored with gold, even as they recommend tooth-colored alternatives for their patients. Although this may have been true in the past and still may be applicable to the "senior" members of our profession, I doubt it applies any longer to most mainstream practitioners.

Traditionalists also will argue that no matter how well-made a ceramic restoration is, it will never match the amazing longevity of gold, which will not cause accelerated wear to the teeth against which it occludes. But with the advancement of ceramic technology, specifically in relation to zirconia-supported crowns and bridges, excellent-fitting and durable restorations are no longer the exception. Nevertheless, if a patient desires the ultimate in strength and

esthetics are not an issue, then cast gold is still the standard.

Bonding agents

With self-etch products being introduced on almost a weekly basis, you would think that the gold standard had shifted away from total-etch. But even the owner of one of the most prolific manufacturers of both types of adhesives was quoted recently as stating that he still considers "fourth generation, total-etch adhesives" as the pinnacle.² In addition, the only bonding agent to receive a five-star rating (the highest possible rating based on clinical and laboratory testing) in the 2009 Annual Edition of REALITY happens to be a fourth generation, total-etch product. Furthermore, the bonding agent that created the so-called seventh generation (that is, an all-in-one self-etch material) has recently undergone brand extension with the introduction of a total-etch sibling.

Even though there are several very good self-etch adhesives, I believe that the gold standard still belongs to total-etch. This is due to the virtually universal application of total-etch products, including their utility on unprepared enamel. Granted, you need to be somewhat more conscientious when applying total-etch adhesives than you would be with self-etch adhesives, to prevent postoperative sensitivity. Rinsing off the etchant is an extra step and an unpleasant one at that, especially when you are not using a rubber dam. In addition, self-etch adhesives usually are more than adequate for certain restorations, such as full crowns. Having said that, if you could have only one bonding agent in your office, it should still be a total-etch version.

Curing lights

Halogen lights were first introduced approximately 30 years ago and ruled the roost for most of this time despite the brief and rather tepid challenges of argon lasers and plasma arcs. During this time, these lights have reliably cured all photo-activated materials with reasonable efficiency and economy, due to the wide bandwidth of halogen bulbs. However, light-emitting diode (LED) units have stolen the thunder of halogen lights, due to their relatively small size, mostly cordless design, and more efficient energy management.

The problem, of course, is that most LEDs still won't cure some materials that utilize photoinitiators, which are activated at wavelengths lower than the usual coverage of LEDs. Therefore, even with the market domination of LEDs, the halogen light remains the gold standard. This is evidenced by the fact that a halogen light remains REALITY's highest-rated curing light.

__Radiography

The digital revolution has definitely changed radiography, leaving film in its wake. Digital radiographic images can be organized, stored, and recalled electronically for instant retrieval and presentation with special software. This software allows for a wide array of patient-pleasing devices (such as zoom, image reversal, image coloration, annotations, and so forth), which also are very valuable when sending pre-determinations. This software also provides dentists with the capability to e-mail images to colleagues or insurance companies.

Patients also respond very favorably to digital images, because the image is much larger on the computer screen and they can see what you are talking about more clearly when you point to a shadowy area of a radiograph. Viewing an image on a computer monitor is also much more comfortable for patients, since they are more used to viewing images this way than viewing a film-based image on a viewbox, with its glare and unfamiliar feel. Options such as coloration, image enhancement, and image reversal allow for better contrast and improved views of carious lesions, open margins, bone loss, and furcations.

While some clinicians still believe that film-based radiography is more diagnostic, this is one category where the gold standard has surely shifted to digital.

__Cements

Materials designed for luting restorations have undergone such significant changes over the years that designating any gold standard would be difficult, if not impossible, in part because no single type of cement can be used across the board. Therefore, to establish any sanity in this area, you have to identify a type of restoration and then establish a gold standard for it.

For example, cements for metal-based crowns and bridges have morphed from zinc phosphate to zinc polycarboxylate to glass ionomer to resin ionomer to resin. There are several permutations in the resin category alone, ranging from the early self-cured materials paired with self-etching primers to the current crop of dual-cured, self-adhesive

versions. While most of the recent buzz in the market has surrounded the self-adhesive resin products, resin ionomer still has to be the gold standard in this arena; two such products achieved a rating of five stars in REALITY. On the other hand, no self-adhesive resin cements even came close to this lofty status.

To lute metal-free restorations, the choices are even more convoluted and beyond the scope of this column. Suffice it to say that you need to identify your needs carefully and match them to a specific type of cement.

Gold standard status remains a useful parameter to judge new entries in specific product categories. However, with the rapidly changing marketplace, the gold standards of yesterday may not be applicable today or tomorrow.

Editorial note: This article originally appeared in the November/December 2009 issue of General Dentistry. It is published with permission by the Academy of General Dentistry. © 2009 by the Academy of General Dentistry. All rights reserved.

__References

1. Christensen G. Longevity versus esthetics: The great restorative debate. *J Am Dent Assoc* 2007;138(7): 1013-1015.
2. Q&A: Dr. Byoung Suh. *Dental Products Report* 2009; July:8.

__about the author

cosmetic
dentistry

Dr Michael B. Miller is a Fellow of the Academy of General Dentistry, a Founding and Accredited Member and Fellow of the American Academy of Cosmetic Dentistry and has memberships in the International Association of Dental Research, Academy of Dental Materials and Academy of Operative Dentistry. He is also a founding board member of the National Children's Oral Health Foundation, which is dedicated to fostering the development of local dental health and education facilities for underserved children. In addition, Dr Miller is the Co-Founder, President and Editor-in-Chief of REALITY and maintains a dental practice in Houston, Texas.

Reality Publishing Company

11757 Katy Frwy, Suite 210
Houston, TX 77079
USA

Tel.: +1 800 544 4999 | +1 281 558 9101

E-mail: mm@realityesthetics.com
Website: www.realityesthetics.com

You can't always get what you want (unless you ask clearly!)

Author_ Laura Kelly, USA

Images_ Dr Jeff Morley & LK Dental Studio, USA

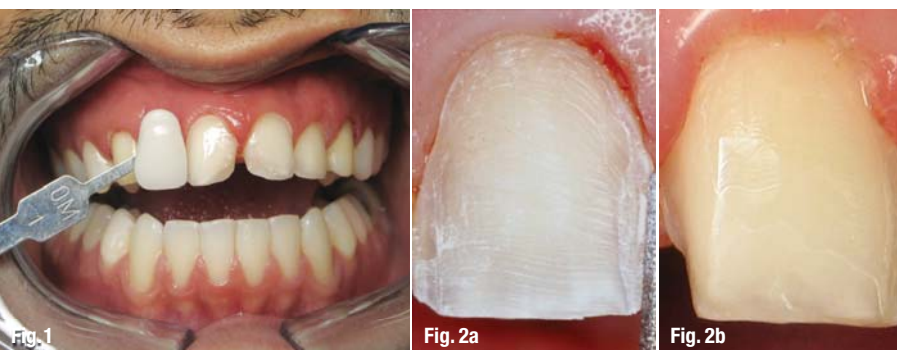

Fig. 1_ Shade tab placed in the same plane as teeth, ensuring the tab and corresponding shade number is in the photograph.

Figs. 2a & b_ Smooth preparations allow for impressions to be extremely clear.

_Let's be honest: There are times when your laboratory technician simply doesn't deliver what you envisioned so clearly in your mind—a bit more translucency or a specific gingival colour, a minor mesial rotation on that bicuspid, or an occlusal table that's just a little too wide.

Twenty years ago, when I began my career as a laboratory technician, we had only a few tools at our disposal. Hastily made sketches on the back of prescription pads, a few coloured pencils to indicate body shade, incisal level or some other specific instruction; and sometimes pre-op models were sent.

Figs. 3a & b_ It is important to verify the quality of the impression before it is sent to the lab. Voids on the margins require another impression for marginal accuracy.

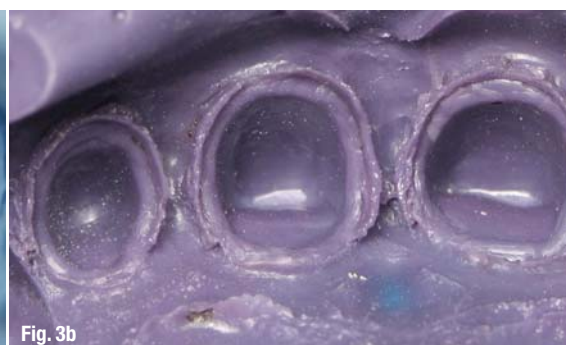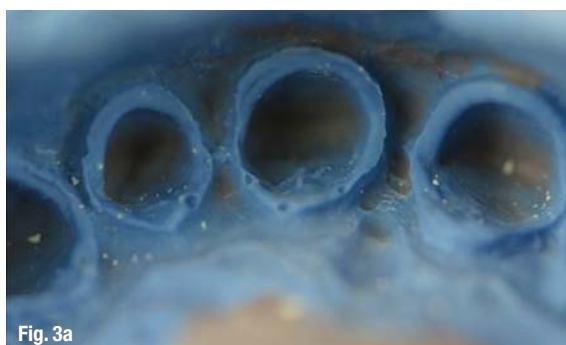Looking back, I am amazed at what we pieced together given such limited communication tools.

Yet that was the best the dentists could provide to the technician, and we had to work from what we had. It was challenging to create the specific results for, say, a single unit anterior crown. Often there were trips between the laboratory and the practice or extra meetings—not to mention costly remakes for everyone. As we improved, we pulled it off, but it wasn't easy.

Fast-forward two decades to the era of the digital camera, e-mail and Skype, and the way we work together is instantly and forever transformed. No longer must we guess, imagine or try to convey with facsimiles or mere words. These tools have totally changed the way the dentist and laboratory technician collaborate on their work, and everyone—the patient included—has been the beneficiary of this technology.

Imagine if you had to work without a digital camera today: Film. Developing. Printing. Waiting. Time. Out of focus. Do it again. Wait some more. With today's digital technology, the clinician can instantly determine whether the information in the photograph will adequately convey everything necessary to the technician.

Many cases require more than a shade tab number written in the shade box on the prescription,



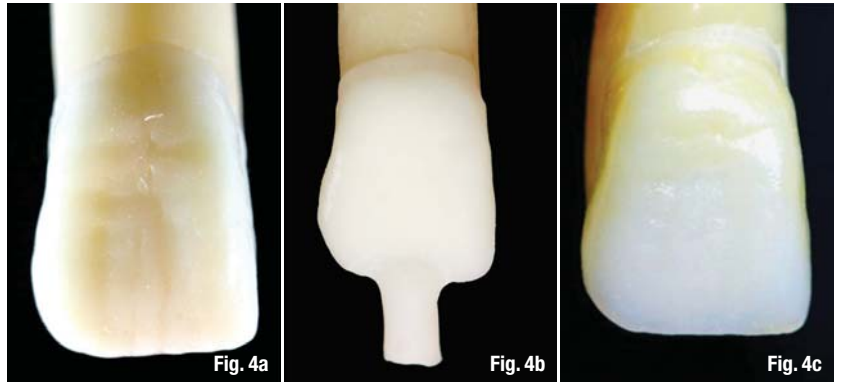
and taking full-face, retracted and lateral views makes all the difference to the technician working on your cases.

Once the image is captured, e-mail can transfer the information virtually instantaneously, permitting the dentist to choose a technician anywhere in the country. This allows the dentist to select a technician with whom he or she can work best, regardless of geography. The technician, in return, can send preliminary images of his or her wax-up and bisque bake along with the final-stage images for the dentist's approval. Both parties can then have confidence that the case has been fabricated exactly as envisioned by the dentist and the patient.

This process of instruction, feedback and adjustment has allowed more dentists to deliver an increasingly sophisticated product created by more clinically astute and in-tune technicians—usually in less time and with greater precision from the beginning.

A laboratory technician would always prefer to work with a photograph and would prefer this level of information; thus, these tools have become the new standard of care. It must be said that in addition to increasing the predictable results, using these communication tools increases profitability for both the laboratory technician and the dentist. When you consider the cost of remakes and adjustments, as well as sending cases back and forth multiple times—not to mention patient dissatisfaction with these frustrations—the savings are real and the profits equally so. When professionals spend more time at the beginning and avoid costly mistakes, the benefits are tangible.

Even with these improved technologies, the most important tool we have is the time the dentist and laboratory technician invest in one another. By taking the time to meet and discuss cases, being clear about mutual expectations and giving immediate feedback to one another, the dentist



and technician can build a strong working relationship that can last for years and even decades.

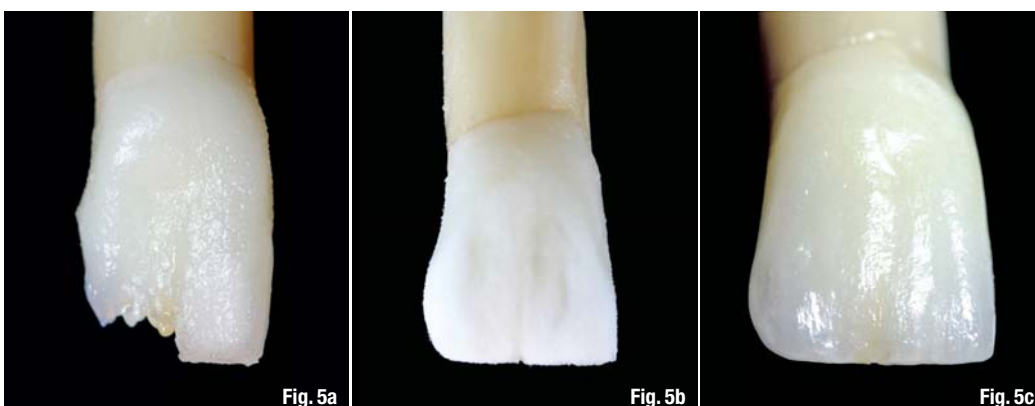
—Labs evaluate you too

We all know that dentists are constantly evaluating their laboratory technicians and relationships, and the same is true for the technicians. When we receive a case from a client who communicates well, makes expectations clear, works in a collaborative partnership and gives candid and timely feedback, we know we have to be on our toes and it challenges us to do our very best.

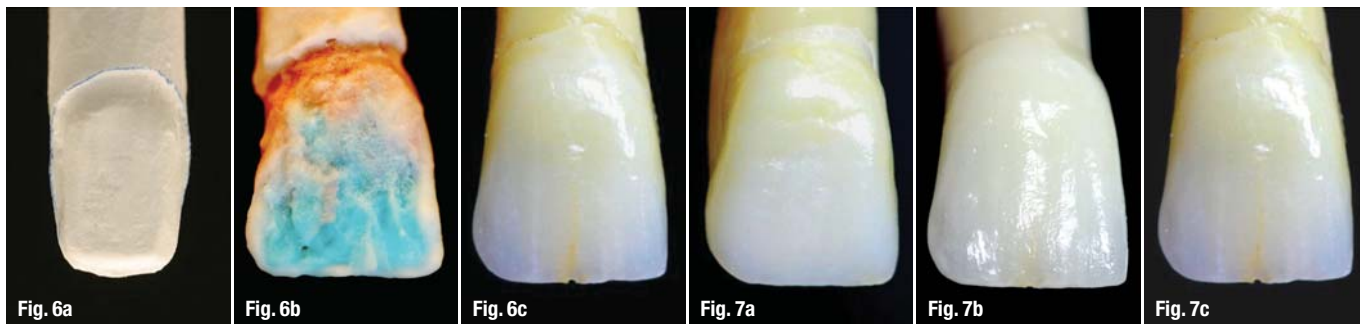
When we work with a dentist who sends clear impressions and focused photographs, and who alerts us to the arrival of the case, we know that dentist is serious and that his or her expectations are high. However, when impressions are distorted, margins are unreadable or prescriptions are incomplete, it sends a very different message indeed. Perhaps it doesn't matter much to such a dentist? Perhaps, just about anything will do? Perhaps your case can wait?

In many larger laboratory environments, the most highly trained technicians are assigned the cases of the first type of dentist—the one who sent clear impressions that is—because their time is too valuable to work with poor material and information. Here's a little secret: technicians are natural

Figs. 4a–c Waxed to full contour (a). Pressed in IPS Empress (Ivoclar Vivadent) ingot with sprue on the incisal edge which will be removed (b). Veneer with surface staining only (c).



Figs. 5a–c IPS Empress (Ivoclar Vivadent) pressed and cut-back technique, allowing for characterisations to be placed internally—layered with IPS Empress porcelain for optimal aesthetics.



Figs. 6a-c Refractory technique: porcelain (Noritake) layered directly on refractory material. After firing porcelain directly on the refractory die and final contouring and glazing, the veneer is removed and seated onto die stone model.

Figs. 7a-c The pressed and stain technique is the most simplified technique, yet all surface staining creates an unnatural appearance, and surface stain can be removed leaving 'bald spots' if adjustments are necessary (a). The pressed and cut-back/layered technique maintains excellent marginal adaptation due to the lost wax technique. It also provides a more natural appearance on account of the internal placement of colour (b). Very natural appearance due to complete layering of porcelains (c). Can be technique- and labour-intensive, requiring technical expertise to provide excellent, lifelike results.

pleasers and we want to impress you, make you happy and meet your needs. If you want the best technicians working on your cases, make it your business to send them the best, communicate with them until you work together like a well-oiled machine and demand excellence in return. The way you communicate will affect all of this.

In modern dentistry, it is easy to do the right thing. We have the tools. We have the standards. We have the desire. We can work better together. Just tell us what you want and we can deliver.

When looking for a new lab...

- Call and introduce yourself, communicate what it is you are looking for and what is missing from your current lab relationship. (We need to know what you don't like so it's not repeated!)
- Ask to see photographs of their work, and find out who receives the photographs that you will be attaching to your e-mails of cases.

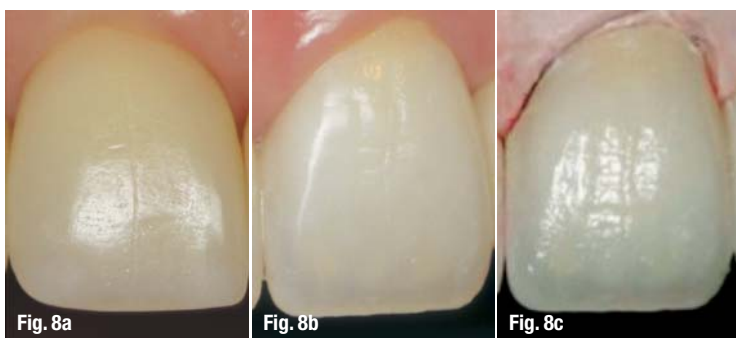
- Ask other dentists what their experience has been with the laboratory you are considering.
- The outsourcing of cases overseas has increased in the laboratory profession. If this is important to you, you may want to enquire as to where your restorations are being made.

What to include:

- clear, full-arch impressions
- bite
- photographs
- face bow or stick bite
- pre-op models
- model of temps or diagnostic wax-up to follow
- concise instructions

Labs evaluate you by:

- quality of impression, free of pulls, distortions or voids on the margins
- photographs sent with shade tab desired, as well as prep or 'stump' shade for all ceramic restorations
- detailed prescriptions and 'call to discuss' written on cases that require more communication
- your willingness to be open to feedback—ask your technician what you can do to make his or her job easier and he or she will be pleasantly surprised
- your direct and honest feedback; technicians need to know what you like and what you don't in order to improve and meet your expectations.



Figs. 8a-c Communicating surface texture, degree of sheen to the technician can provide a better match to adjacent teeth, creating a more natural appearance to ceramic restorations.

- Ask how the lab assigns your cases to a technician(s) and request to speak directly with the technician you will be working with.
- Visit the lab if possible, or use Skype for instant communications online.
- Ask for a bisque-bake photograph to be e-mailed to you for approval before sending the case out. This saves time and the dentist can give useful feedback at a time when modifications are easily made.
- Schedule quarterly phone or in-person meetings to discuss progress; so engage in regular meetings.

_contact		cosmetic dentistry
	Laura Kelly	
	3420 Fostoria Way, Suite G202 San Ramon, CA 94583 USA	
	E-mail: laura@lkdentalstudio.com	
	Website: www.lkdentalstudio.com	



ANNUAL DENTAL TRIBUNE STUDY CLUB

SYMPOSIA AT THE GNYDM

NOVEMBER 28 – DECEMBER 1, 2010, 10:00 AM DAILY



For the third year in a row, the DTSC hosts its annual CE Symposia at the GNYDM, offering four days of focused lectures in various areas of dentistry. Find us on the Exhibition Floor in Aisle 6000, Room # 3.

Each day will feature a variety of presentations on topics, which will be led by experts in that field. Participants will earn ADA CERP CE credits for each lecture they attend. DTSC is the official online education partner of GNYDM.



PLEASE SEE PROGRAM DETAILS UNDER WWW.DTSTUDYCLUB.COM/GNYDM

REGISTER NOW: WWW.GNYDM.COM

FREE FOR REGISTERED GNYDM ATTENDEES, BUT PRE-REGISTRATION IS RECOMMENDED.

For more information, please contact Julia E. Wehkamp, C.E. Director, Dental Tribune Study Club
Phone: (416) 907-9836, Fax: (212) 244-7185, E-mail: j.wehkamp@DTStudyClub.com

SUNDAY, NOVEMBER 28

10:00 - 11:00 Howard Glazer, DDS, FAGD
BEAUTIFIL: GO WITH THE FLOW - COURSE: 3020

11:20 - 12:20 John Flucke, DDS
LIGHT CURED ADHESIVE DENTISTRY - SCIENCE AND SUBSTANCE - COURSE: 3030

1:20 - 2:20 Martin Goldstein, DMD
A SIMPLIFIED APPROACH TO MULTI-LAYER DIRECT COMPOSITE BONDING - COURSE: 3040

2:40 - 3:40 Jay Reznick, DMD, MD
3D IMAGING AND CT-GUIDED DENTAL IMPLANT SURGERY - 3050

4:00 - 5:00 Louis Malcmacher, DDS, MAGD
TOTAL FACIAL ESTHETICS FOR EVERY DENTAL PRACTICE - COURSE: 3060

MONDAY, NOVEMBER 29

10:00 - 11:00 Mrs. Noel Brandon-Kelsch
ECO-FRIENDLY INFECTION CONTROL-UNDERSTANDING THE BALANCE - COURSE: 4120

11:20 - 12:20 Gregori Kurtzman, DDS
INCORPORATING NEW ADVANCES IN DENTAL MATERIALS AND TECHNIQUES INTO YOUR RESTORATIVE PRACTICE - COURSE: 4130

1:20 - 2:20 Various Speakers
OPTIMIZING YOUR PRACTICE WITH 3D CONE-BEAM TECHNOLOGY - COURSE: 4140

2:40 - 3:40 Daniel McEowen, DDS
HIGH RESOLUTION CONE BEAM WITH PREXION 3D - COURSE: 4150

4:00 - 5:00 Maria Ryan, DDS, PhD
DETECTING CORONARY HEART DISEASE THROUGH PERIODONTITIS AND PERIIMPLANTITIS - COURSE: 4160

TUESDAY, NOVEMBER 30

10:00 - 11:00 Fotinos Panagakos, DMD, PhD
DENTIN HYPERSENSITIVITY - NEW MANAGEMENT APPROACHES - COURSE: 5110

11:20 - 12:20 Greg Diamond, DDS
LASERS IN PERIODONTAL THERAPY - COURSE: 5120

1:20 - 2:20 Dov Almog, DMD
INTRODUCTION TO CONE BEAM CT (CBCT), ESPECIALLY AS IT PERTAINS TO PREVENTION OF FAILURES IN ORAL IMPLANTOLOGY - COURSE: 5130

2:30 - 3:30 Maria Ryan, DDS, PhD
DETECTING CORONARY HEART THROUGH PERIODONTITIS AND PERIIMPLANTITIS - COURSE: 5140

4:00 - 5:00 Dwayne Karateew, DDS
CONTEMPORARY CONCEPTS IN TOOTH RELACEMENT: PARADIGM SHIFT - COURSE: 5150

WEDNESDAY, DECEMBER 1

10:00 - 11:00 Mr. Al Dube
BEST MANAGEMENT PRACTICE, WASTE MANAGEMENT FOR THE DENTAL OFFICE, AND OSHA COMPLIANCE - COURSE: 6060

11:20 - 12:20 Glenn van As, DMD
HARD AND SOFT TISSUE LASERS - COURSE: 6070

12:45 - 4:45 Drs. David Hoexter, Jeffrey Hoos, Dwayne Karateew, Enrique Merino, Kenneth Serota, Marius Steigmann
REVOLUTIONARY IMPLANT DESIGN UNVEILED: A COLLECTION FROM THE MASTERS - COURSE: 6080



Does CAD/CAM pay off?

An interview with Prof Albert Mehl, University of Zürich, Switzerland



Prof Dr Dr Albert Mehl

_IDS 2009 showcased the impressive advancements in CAD/CAM dentistry. For private dentists, however, there is much uncertainty regarding response to these developments. **cosmetic dentistry** spoke with Prof Albert Mehl, currently Guest Professor at the Centre for Dentistry and Oral Medicine at the University of Zürich, about whether investing in CAD/CAM pays off and for whom.

_cosmetic dentistry: *Most failures with conventional technology occur during impression preparation (insufficient illustration of the preparation margins, insufficient drainage). What advantages do CAD/CAM systems offer for the dental practice?*

Prof Mehl: Most importantly, treatment times are reduced because the dental restoration can be manufactured in the same session as the preparation (chairside method). Temporaries become obsolete, thus making uncomfortable and unaesthetic transition times a thing of the past. Owing to adhesive technology, sufficient retention for a temporary is in some cases not available because of the minimally invasive preparation. Furthermore, the latest studies demonstrate improved bonding to teeth with freshly cut dentine and enamel. Computer-aided milling and polishing allows the use of high-quality materials, which are manufactured industrially under optimal conditions, resulting in longer-lasting restorations compared to conventionally manufactured restorations. This has already been documented in numerous scientific studies. Through the combination of time saving, cost reduction and increased quality, the chairside method offers an interesting perspective for modern dentistry. This pertains mainly to single-tooth restorations but we can expect new possibilities in the production of fixed partial dentures with small span widths in the near future.

_How does the significant investment in digital impression technology pay off?

When considering concepts that entail the sending of data of a digital impression to a decentralised production site via the Internet, one can say that the time-frame equals that of conventional impression techniques. The extent to which the accuracy of digital technology is comparable to conventional impression techniques (including preparation of models) has not yet been determined, particularly in larger span widths. Comparative studies are now being conducted, and it is upon this issue that the further expansion of these concepts is dependent. However, first experiences suggest that this is indeed possible. Digitalisation would then enable the same advantages in other areas. The virtual 3-D model is important not only for the computer-aided fabrication of dental restora-

tions, but also for every other kind of diagnostic, such as the exact 3-D determination of tooth movements, archiving of virtual models and the documentation of 3-D changes to the tooth and surrounding soft tissue. According to the industry, amortisation could be achieved through the cost savings of computer-aided production in production centres, software updates and systems for the chairside production of single-tooth restoration, and extension to diagnosis and treatment planning software. The enormous potential of digital scanning has been recognised by the industry and thus is currently in heavy development. As soon as quality and practicability have been demonstrated within clinical environments, amortisation will no longer be an issue.

_How can the aesthetic disadvantages of the single-session treatment (CEREC/E4D) be solved in the future?

Sophisticated, aesthetic single-session treatments in the anterior region are difficult and achievable only with much experience. Hence, most dentists will probably prefer the conventional veneer layered crowns. However, aesthetically pleasing results can be obtained using multi-coloured blocks. It is expected that these blocks will be improved by optimising the form and position of the layers and that the software will position the restoration within the block for optimum colour effects. In order to standardise this process, the use of tooth colour measurement systems may also be relevant.

_Are you referring to integrating digital colour measurement systems with CAD/CAM?

This is an interesting aspect. This kind of integration is likely to be available soon. In my opinion, this is another major advantage of CAD/CAM technology. Through the means of standardised calculation processes, the ideal layer thickness of frames and veneers for every required shade can be obtained individually for each combination of materials and type of restoration. A systematic analysis of these combinations and the resulting colour effects through large test series are essential though. Such tests have not been available thus far.

_Does the extended workflow—from practice to centre to laboratory and back to the practice—offset the time-saving factor?

This is the case and certainly a disadvantage of a centralised production process. The advantage, however, is that such centres can invest in high-quality and highly precise production technologies. These machines are maintained by specialists and ensure high capacity. The storage of many different materials including a variety

of shades and implant systems is easier and more economical as well. Overall, production costs are very low and theoretically offer superior quality at the same time, which is something that needs to be considered when we speak of the time disadvantage. I anticipate that decentralised production will play a vital role in dentistry for larger restorations such as fixed partial crowns and implants.

The first IT systems that were available to dentists at the end of the 1970s/beginning 1980s were expensive mini-computers (VAX) that were never actually amortised. Will it be the same with CAD/CAM? What do you foresee price development to be?

An amortisation of CAD/CAM systems depends not only on the possibilities and range of indications, but also on clinical concepts and the patient base (for example, the number of ceramic restorations produced and the extent of the potential for this kind of treatment). This needs to be analysed case by case. Generally speaking, we have already undergone the introduction phase and many CAD/CAM practices now demonstrate impressively that the system can actually be amortised quite well. Many companies have found CAD/CAM technology to be one of the key technologies in dentistry today, and large sums are invested in research and development, which will boost development processes. Many of these improvements can be incorporated into the systems later, as a large part of the expertise is incorporated into software. There are likely to be changes in the hardware as well, but those will take much longer. Dentists thinking about investing in a CAD/CAM system should make their decision regardless of such considerations. After all factors—range of indication, user friendliness, testimonies of fellow colleagues, economic efficiency, and scientific approval—have been analysed, entry into the CAD/CAM world clearly does make sense. In the short and intermediate term, we do not expect a significant decrease in price. But as a scientist, I always look far into the future and am convinced that after the high development costs have been amortised, prices will have the potential to decrease in the long term. The vision is that someday every dental practice will own such a system. IT technology is a good example and CAD/CAM technology, which is based on this IT technology, will follow suit.

iTero, 3M ESPE Lava COS, CEREC, E4D—How many points of laser light are technically required?

For dental restorations, an accuracy of 50 µm is demanded. Surprisingly, little is known about how critical this level really is, but we apply this standard, and surfaces should be scanned with a grid of at least comparable size. Double resolution (25 µm) would be even better. An average molar surface of 2 cm², for example, would yield 320,000 measuring points. The ideal number then depends on the data processing. By combining several scans, these numbers can be increased significantly. The software can then calculate the optimum

distribution of measuring points, thereby improving the results even more.

LED (CEREC) versus laser (3M ESPE, iTero, E4D), parallel confocal imaging (iTero) versus triangulation (CEREC, 3M ESPE, E4D)—what are the advantages and disadvantages? How much interpolation is acceptable?

These technical details principally influence accuracy and clinical adaptability. However, we cannot fully evaluate the quality of intra-oral scanners based on these details because they only constitute a small percentage of the overall complex measurement systems. In addition, there is the decisive factor of software interplay. Clinical and scientific experiences of each measuring system are far more important.

What are the advantages and disadvantages of digital bite registration versus traditional bite registration with subsequent manual adjustment?

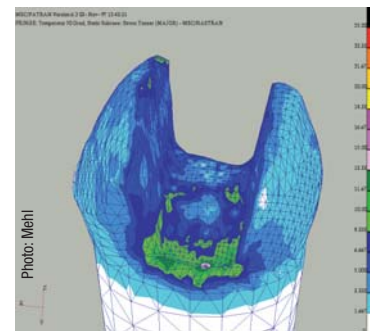
The software allows a more precise positioning of the jaw and a superior analysis of the occlusion compared to the conventional, manual procedure on the plaster model, on condition that the digital impression ensures a high degree of measurement accuracy for the jaw impression. In addition to the controlling of the restoration material thickness, contact patterns can be analysed, 2-D slices can be adjusted for visualisation in different areas, and articulation movements can be measured. Using software, the resilience of teeth can be simulated, enabling new possibilities for diagnosis of the contact situation.

iTero and E4D do not require powder coating. Why isn't this possible with CEREC and 3MESPE?

Powder-free impressions are the preferred option. However, they still are a significant challenge in intra-oral scanning technology. Based on my experience, I am not able to evaluate whether this is possible with sufficient accuracy at the present stage. There are many different approaches to analysing the light reflected from tooth surfaces without using powder; however, the accuracy of the measurement is dramatically reduced. At the end of the day, it is the results that count and it is up to us to analyse these closely.

Do you believe that prostheses manufactured via rapid prototyping can be done in practice with better aesthetic quality and without the assistance of a dental technician?

There is debate about whether this is possible. While this procedure has become common in some milling centres with regard to metal and acrylic resins, restorations with aesthetic materials such as dental ceramics and composites have shown some principal and unresolved issues. Basic research is needed in this field. As a second step, production devices should be made compact so they become more cost-efficient for dental practices. In conclusion, this technology is unlikely to experience a major breakthrough in the medium term.



Minimally invasive anterior restorations with non-prep veneers

Authors_ Dr Harald Streit & Bernhard Hellmuth, Germany



Fig. 1

Fig. 1_ The patient disliked the gaps in her dentition and wished for the appearance of her teeth to be improved.

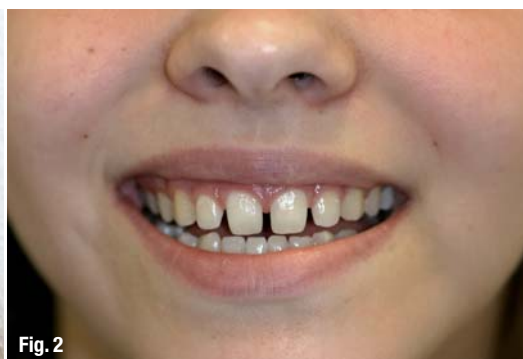

Fig. 2

_How many people would like their teeth to look more beautiful? And how many of them avoid dental treatment merely because they fear that they have to sacrifice healthy tooth structure to achieve an aesthetic improvement?

These questions cannot be answered, of course. However, dentists who have found it difficult to convince their patients of the advantages of corrective dental treatment because they are scared of having their teeth cut can now offer a conservative alternative in the form of minimally invasive restorations.

Misaligned teeth and gaps between teeth are unpleasant. Nobody likes to see large gaps between their teeth, particularly not in the anterior region. These were exactly the concerns of this 17-year-old female

patient, who presented to our practice with a wish to improve the aesthetics of her anterior teeth (Fig. 1). At the same time, she insisted on preserving the healthy tooth structure of her anterior teeth, and required relatively inexpensive treatment. Mandibular teeth #35 and 44 were congenitally absent. In addition, the patient lost tooth #36 due to endodontic complications.

First, the patient underwent long-term orthodontic treatment to close the existing gaps. The missing teeth #35 and 36 were replaced with implants, onto which temporary restorations were placed. In order to increase their stability, brackets were bonded to these restorations and to the entire natural dentition.

_Precise planning, accurate outcome

The patient's aesthetic appearance was also impaired by an excessive display of gum tissue (gummy smile). When she smiled, the asymmetrical contours of her gingival tissues became visible. The high dynamics and slanted contour of her lips could not be influenced therapeutically (Fig. 2). Moreover, the teeth appeared barrel-shaped.

Correcting such a situation is unforgiving of mistakes. The treatment has to be planned and performed with absolute accuracy. For this purpose, gum contouring was carried out upon completion of the

Fig. 3_ The gingival contour was corrected in the area between teeth #11 and 21 with a soft-tissue laser.

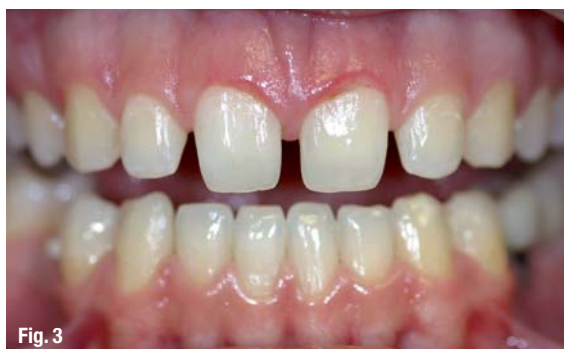

Fig. 3

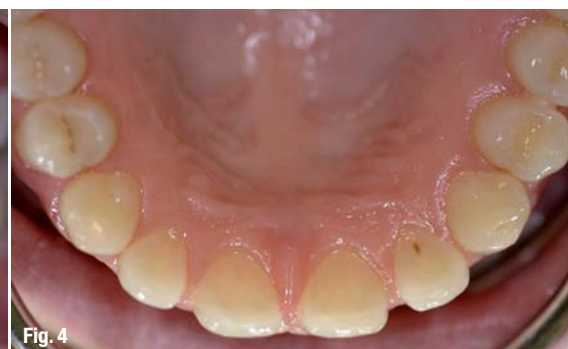

Fig. 4

Fig. 4_ The mirror image shows the healed tissue one week after the treatment.



Fig. 5

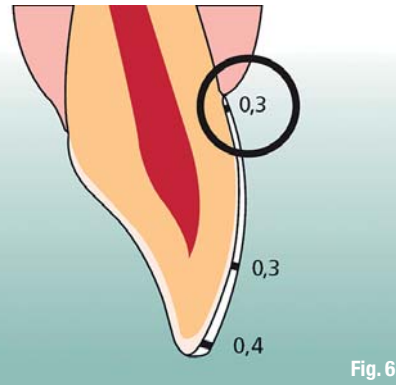


Fig. 6

orthodontic treatment and successful stabilisation of the dentition. Excess gum was trimmed away with a soft-tissue laser and the gingival contours of the two central incisors were harmonised with each other (Fig. 3). The advantage of laser contouring is that the laser naturally seals the wounds and treatment can be continued soon after contouring. The mirror image shows the situation after one week with a palatal view of the anterior teeth (Fig. 4).

Thin and yet stable

At the next stage, the dental technician in charge determined the final tooth shade with the help of a shade guide and shade samples, taking into account the initial tooth shade, which plays a major role particularly in very thin translucent restorations. An impression was taken to create a model with detachable segments. A wax-up was designed on the model to plan and determine the position of the incisal edges. In the process, particular care was taken to extend the incisal edges only minimally. Otherwise, the completed restoration *in situ* would have given an optical impression of being too long.

Please note that the dental technician should apply no more than two thin coatings of die spacer to the dies. The spacer should be applied only up to 1 mm from the preparation margin in order to avoid hollow restoration margins in the oral cavity.

Thin veneers, as presented in this case, are fabricated by creating a fully anatomical wax-up, which is pressed and then characterised with stains. IPS e.max Press (Ivoclar Vivadent) is ideally suited for this purpose. This material is composed of lithium disilicate glass-ceramic and is 2.5 to 3 times stronger than other glass-ceramic materials. Having a flexural strength of almost 400 MPa, IPS e.max Press offers exceptional stability (Fig. 5). These characteristics convey sufficient strength to veneers, inlays, crowns and similar restorations to withstand comparatively high loads. Furthermore, restorations made of IPS e.max Press look impressively beautiful. The product range includes special press ingots, which offer an increased

level of opacity for cases in which the underlying tooth structure is discoloured. These ingots effectively mask dark areas and provide a natural-looking aesthetic result, even if the teeth are discoloured.

Precisely to prescription

In the case presented here, teeth #13 to 23 were restored with non-prep veneers. The highly translucent IPS e.max Press HT ingots are particularly suited for this type of minimally invasive thin restoration. First, the dental technician creates an anatomical wax-up of the veneer using organic wax that burns out without leaving residue. In this respect, the final occlusal relief must be taken into consideration as early as during the wax-up. The subsequent application of stain and glaze materials results in a slight increase in the vertical dimensions of the restorations.

The technician should strictly adhere to the minimum thicknesses stipulated for the relevant lithium disilicate glass-ceramic. According to the manufacturer's directions, the minimum thickness of IPS e.max Press is 0.3 mm in the cervical and labial area, and 0.4 mm at the incisal edge (Fig. 6).

The wax margins are tapered towards the end. The transitions between restoration and tooth structure should be contoured particularly carefully. In this way, the need for later corrections can be pre-empted. It is well known that inexperienced technicians often find it difficult to create such a thin wax-up and thus tend to create thicker wax-ups. However, it is unnecessary to over-contour the margins as a precaution, as the technician may then have to rework the restorations after they have been pressed and divested. This takes time. Thus, it is best to contour as suggested by the manufacturer right from the start.

Everything under control

The veneers are pressed in a Programat EP 5000 ceramic press furnace at 920 °C. Upon completion of the press cycle, they are carefully divested—adjustments are kept to a minimum. The sprues are separated with

Fig. 5 Veneers are best contoured in a fully anatomical shape and pressed.

Fig. 6 Thin veneers should have a thickness of at least 0.3 mm in the cervical area and 0.4 mm in the incisal.

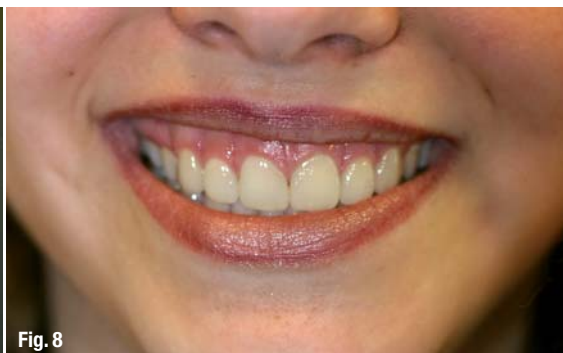
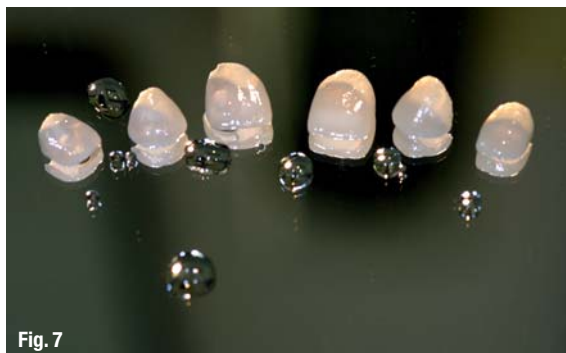
Fig. 7_ The pressed veneers are individualised with IPS e.max Ceram Shades.
Fig. 8_ The smile of the patient at the try-in demonstrated her satisfaction with the result.

thin diamond disks, whilst the objects are kept moist and cool. The attachment points are smoothed out using light pressure and low speed. Next, the restorations are tried in on the dies of the model, and the contact points, occlusion and articulation are checked. If necessary, the surface texture may be adjusted.

After these steps have been completed, the veneers are carefully blasted using aluminium oxide at minimum pressure and cleaned with steam before they are matched to the tooth shade with IPS e.max Ceram Glaze and Stains and IPS e.max Ceram Shades, individualised and glazed (Fig. 7). They are best tried in with Variolink Veneer Try-In pastes. The translucency and shade of these glycerine pastes are identical to those of the polymerised Variolink Veneer luting composite and therefore the composite shade, which provides the least perceptible final result, can already be determined and tested before the veneers are cemented in place. This try-in is performed to check the aesthetics of the veneers only; the occlusion is not checked at this point. After the try-in, the water-soluble paste is removed from the veneers in an ultrasonic bath and then the veneers are thoroughly dried.

Incorporation

The patient was impressed with the veneers already at the first try-in. Her smile, as seen in Figure 8, was an expression of her happiness and the practice team was pleased. The veneers fitted at the first go. The proximal contact points did not require any adjustments. Consequently, the restorations were incorporated immediately.

As a basic principle, ceramic veneers are inserted using an adhesive technique. In preparing them, the inner surfaces were cleaned with water, dried and etched with 5% hydrofluoric acid (for example IPS Ceramic Etching Gel) for 20 seconds and then carefully rinsed and dried. Next, Monobond Plus was applied and allowed to react for 60 seconds in order to achieve the necessary silanisation of the lithium-disilicate veneers.

The patient's enamel was etched with 37 % phosphoric acid for 30 seconds, rinsed with water and then

lightly dried. Next, the oral cavity was isolated with a rubber dam.

The veneers were cemented in place using light-curing Variolink Veneer. This translucent luting composite is suited for anterior restorations with a thickness of less than 2 mm. The restorations have to be sufficiently translucent for the luting composite to be effectively light-cured through them. Variolink Veneer is available in a range of value shades, which cause the restoration *in situ* to appear brighter or darker. This luting composite ensures a strong bond and high resistance to wear.

We selected Variolink Veneer in the shade Medium Value 0 for the present case. This shade is neutral and does not have any effect on the brightness of the restoration. An appropriate amount of luting composite was applied to the bonding surfaces of the restoration and the restoration was placed *in situ* using light pressure. After the surplus material had been removed, each veneer was light-cured for five seconds using a bluephase 20i curing light.

Offering a reliable, high light intensity of 2,000 to 2,200 mW/cm², the Turbo programme eliminates the risk of insufficient polymerisation. The built-in fan ensures a consistently high light intensity. Excess composite material was removed from the margins of the restorations and then the cement joint was polished with a soft silicone polisher.

Without a doubt, the thinner and more delicate the veneers are, the more difficult it is for the clinician to place them. As delicate and fragile the non-prep veneers presented in this report may appear when they are first delivered, they are highly stable and durable once they have been inserted. The adhesive bond with the enamel ensures a long-lasting high stability and optimal adhesive bond of the restoration *in situ*.

Looking beautiful

In terms of aesthetics, the treatment of this patient is a complete success. The margins of the restorations are tapered very thinly and are not discernible from the

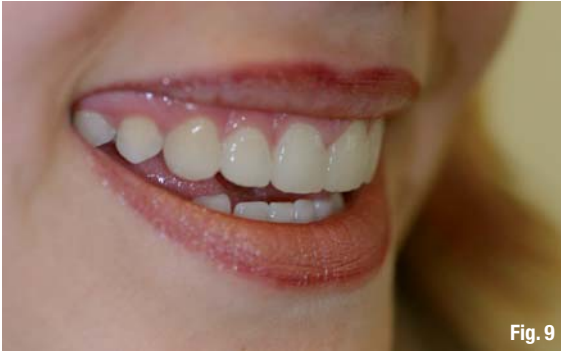

Fig. 9

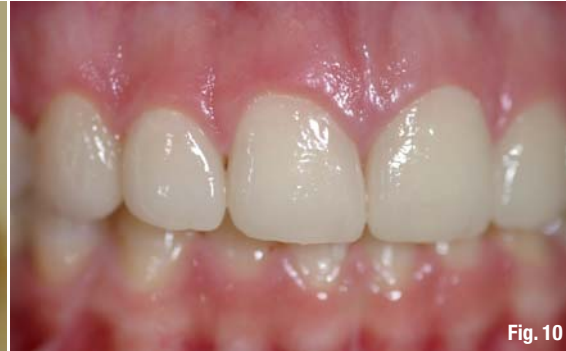

Fig. 10

tooth structure even when examined from different angles (Fig. 9). The lower dental arch has been reshaped as a result of the orthodontic treatment and no longer contains gaps. The upper marginal gingival contour has been corrected to follow a 'high-low-high' pattern, which has a decisive effect on the pink-white aesthetics. According to this pattern, the gingival margins are located higher on the upper central incisors than on the adjacent lateral ones, while the margins on the lateral incisors are located lower than on the canines. If details such as this pattern are not observed, the aesthetic result looks only half as good as it should even if an otherwise excellent restoration is placed.

The restorations reflect the typical characteristics of the natural teeth. Figure 10 shows the beautiful design of the surface texture of the veneers, including their shiny marginal contours. The light is optimally transmitted through the veneers and scattered. The resulting reflections and optical effects impart a natural-looking vibrant appearance to the ceramic veneers. The translucent effect of the lithium disilicate glass-ceramic creates a pleasant chameleon effect; the contact points correlate to one another and the incisal triangles are shaped in a slightly open curve. The gingiva does not show any signs of irritation and it features a healthy stippled surface texture.

These veneers offer a decisive advantage when placing restorations with margins in the visible area. In younger patients in particular, the gum line may recede with increasing age. However, receding gum lines do not present a disadvantage in terms of quality or aesthetics with these restorations, as their margins are invisible.

_ Conclusion

In the present case, the patient's expectations in terms of shape, size and shade were optimally met. Her appearance was favourably altered without sacrificing any dental hard tissue. From the current vantage point, non-prep veneers are thus indicated in cases in which misaligned teeth or differences in tooth length negatively affect the appearance of anterior teeth, and preparation is not a necessity.

Compared with conventional veneers or crowns, non-prep veneers represent not only a highly aesthetic, but also a minimally invasive treatment option.

Non-prep veneers expand the range of dental treatment options and provide a viable route to meet the patient's desire for aesthetic improvement, which previously could not be carried out because the resulting loss of tooth structure would have been unacceptable to both the patient and clinician. Hence, this treatment option, which has been used in North America successfully for quite some time and is becoming increasingly popular, is also of interest to young and young-at-heart patients in Europe.

Although the dentist does not need to grind the teeth to place non-prep veneers, the desired result has to be accurately planned and the procedure perfectly prepared. Insertion without guide grooves in particular requires a maximum measure of concentration and sure instinct. Selecting an appropriate material is equally essential. With its exceptional strength, the IPS e.max Press lithium disilicate glass-ceramic is a material suited for this purpose. Once the delicate and fragile-looking ceramic veneers have been adhesively placed *in situ*, they are durable and stable.

Fig. 9 A beautiful result: the margin of the restoration tapers to invisible and there are no gaps in the dental arch.

Fig. 10 The surface texture scatters the light. The reflections impart a natural vibrancy.

_ contact

cosmetic
dentistry



Dr Harald Streit

Gartenstraße 11
97616 Bad Neustadt a. d. Saale
Germany

E-mail:
harald.streit@honestam.de



MDT Bernhard Hellmuth

Unikat Dental Labor
Gartenstraße 11
97616 Bad Neustadt a. d. Saale
Germany

E-mail: bh@unikat.dental.de

Compatibility of products offers flexibility

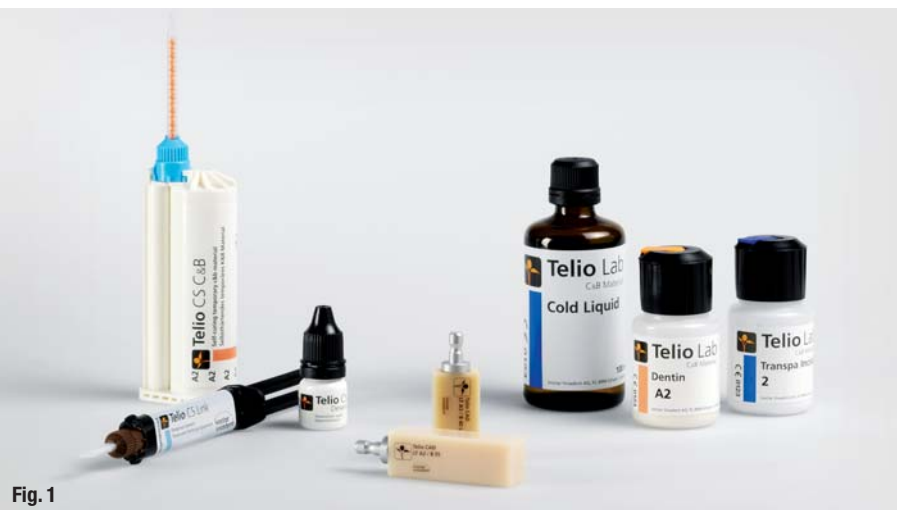

Fig. 1

Fig. 1 The coordinated products of the Telio system at a glance.

Thus far, dentists and dental technicians have used a wide range of products for the fabrication of temporary restorations. Now, Ivoclar Vivadent has developed the Telio system, a product solution for temporary restorations that offers users coordinated products and meets the requirements of dentists, CAD/CAM users and dental technicians alike.

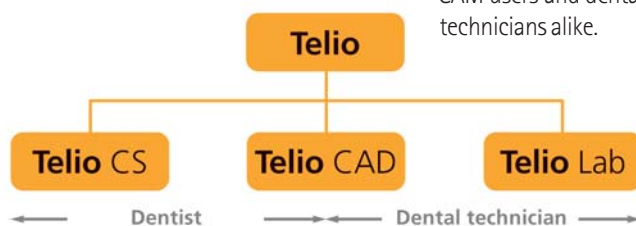


Fig. 2 Telio from Ivoclar Vivadent: a system of compatible materials for temporary restorations.

Telio is currently the most comprehensive product system for temporary restorations. All Telio products are compatible with one another in terms of material and shade. This compatibility of all individual products for temporisation improves cooperation between dentist and dental technician for all treatment steps. Furthermore, labside products can be combined with chairside products, thus allowing for a great degree of flexibility.

Telio CS for dentists

The Telio product range for chairside applications consists of a self-curing temporary crown and bridge material (Telio CS C&B), a dual-curing eugenol-free luting material (Telio CS Link) and a desensitiser (Telio CS Desensitizer). In addition to crowns and bridges,

Telio CS C&B also allows easy fabrication of inlays, onlays and veneers. Furthermore, Telio CS C&B can be utilised to relines temporary restorations, made of, for instance, Telio CAD or Telio Lab material.

Telio CAD for CAD/CAM users

The Telio CAD acrylate polymer blocks are used to fabricate temporary crowns and bridges on natural dentition or implants. The restorations are milled either chairside (e.g. in the Sirona CEREC unit) or labside (e.g. in the Sirona inLab unit). Alternatively, Telio CAD restorations can also be ordered from NobelProcera, who will mill the restoration in one of their milling centres. The restorations are subsequently either directly seated or first characterised with stains and layering materials.

Telio Lab for dental technicians

For the fabrication of temporaries in the dental laboratory, Telio offers a powder/liquid resin processed in the cold technique and adjusted to the A to D shades. Telio Lab is suitable for the creation of temporary crowns and bridges, which can be easily cemented to prepared natural teeth or implant abutments. In addition, the Telio Lab LC components can be used to individualise or complement restorations. In addition to using these materials for the cut-back technique, users can design the occlusion and the emergence profile with these materials.

Telio offers options for temporisation, ranging from standard to highly aesthetic restorations, such as implant-borne, long-term temporaries. Ivoclar Vivadent has thus expanded its product portfolio in the area of implant aesthetics and thereby strengthened its leading position in this field.

_contact	cosmetic dentistry
<p>Ivoclar Vivadent AG Bendererstrasse 2 9494 Schaan Principality of Liechtenstein</p> <p>E-mail: info@ivoclarvivadent.com Website: www.ivoclarvivadent.com</p>	

FORUM DENTAL MEDITERRANEO FDM

BARCELONA • 7-9 ABRIL 2011

Palacio de Congresos • Fira de Barcelona

2011

**Encuentros Profesionales
y Exposición Industrial**

***Professional Meeting and
Dental Trade Show***



PUNTEX
Eventos

organiza:

www.puntex.es

International Events

2010

AAED 35th Annual Meeting

Where: Kapalua, HI, USA
Date: 3–6 August 2010
E-mail: meetings@estheticacademy.org
Website: www.estheticacademy.org

FDI Annual World Dental Congress

Where: Salvador da Bahia, Brazil
Date: 2–5 September 2010
E-mail: congress@fdiworldental.org
Website: www.fdiworldental.org

AACD & ESCD Joint Meeting

Where: London, UK
Date: 23–25 September 2010
E-mail: info@aacd.com
Website: www.aacd.com

ACE 2010 Annual Symposium

Where: Bonita Springs, FL, USA
Date: 23–25 September 2010
E-mail: contact@acesthetics.com
Website: www.acesthetics.com

Veneersymposium

Where: Leipzig, Germany
Date: 5 & 6 November 2010
E-mail: event@oemus-media.de
Website: www.oemus.com

2nd Dental–Facial Cosmetic International Conference

Where: Dubai, UAE
Date: 5 & 6 November 2010
E-mail: info@cappmea.com
Website: www.cappmea.com

7th Annual DGÄZ Meeting

Where: Rottach-Egern, Germany
Date: 19 & 20 November 2010
E-mail: info@dgaez.de
Website: www.dgaez.de

Greater New York Dental Meeting

Where: New York, NY, USA
Date: 26 November–1 December 2010
Website: www.gnydm.org

2011

34th International Dental Show

Where: Cologne, Germany
Date: 22–26 March 2011
E-mail: ids@koelnmesse.de
Website: www.ids-cologne.de

AACD Boston 2011

Where: Boston, MA, USA
Date: 18–21 May 2011
E-mail: pr@aacd.com
Website: www.aacd.com

EAED Spring Meeting

Where: Istanbul, Turkey
Date: 2–4 June 2011
E-mail: info@eaed.org
Website: www.eaed.org

7th IFED World Congress

Where: Rio de Janeiro, Brazil
Date: 21–24 September 2011
Website: www.ifed.org



submission guidelines:

Please note that all the textual components of your submission must be combined into one MS Word document. Please do not submit multiple files for each of these items:

- _ the complete article;
- _ all the image (tables, charts, photographs, etc.) captions;
- _ the complete list of sources consulted; and
- _ the author or contact information (biographical sketch, mailing address, e-mail address, etc.).

In addition, images must not be embedded into the MS Word document. All images must be submitted separately, and details about such submission follow below under image requirements.

Text length

Article lengths can vary greatly—from 1,500 to 5,500 words—depending on the subject matter. Our approach is that if you need more or less words to do the topic justice, then please make the article as long or as short as necessary.

We can run an unusually long article in multiple parts, but this usually entails a topic for which each part can stand alone because it contains so much information.

In short, we do not want to limit you in terms of article length, so please use the word count above as a general guideline and if you have specific questions, please do not hesitate to contact us.

Text formatting

We also ask that you forego any special formatting beyond the use of italics and boldface. If you would like to emphasise certain words within the text, please only use italics (do not use underlining or a larger font size). Boldface is reserved for article headers. Please do not use underlining.

Please use single spacing and make sure that the text is left justified. Please do not centre text on the page. Do not indent paragraphs, rather place a blank line between paragraphs. Please do not add tab stops.

Should you require a special layout, please let the word processing programme you are using help you do this formatting automatically. Similarly, should you need to make a list, or add footnotes or endnotes, please let the word processing programme do it for you automatically. There are menus in every programme that will enable you to do so. The fact is that no matter how carefully done, errors can creep in when you try to number footnotes yourself.

Any formatting contrary to stated above will require us to remove such formatting before layout, which is very time-consuming. Please consider this when formatting your document.

Image requirements

Please number images consecutively throughout the article by using a new number for each image. If it is imperative that certain images are grouped together, then use lowercase letters to designate these in a group (for example, 2a, 2b, 2c).

Please place image references in your article wherever they are appropriate, whether in the middle or at the end of a sentence. If you do not directly refer to the image, place the reference at the end of the sentence to which it relates enclosed within brackets and before the period.

In addition, please note:

- _ We require images in TIF or JPEG format.
- _ These images must be no smaller than 6x6 cm in size at 300 DPI.
- _ These image files must be no smaller than 80 KB in size (or they will print the size of a postage stamp!).

Larger image files are always better, and those approximately the size of 1 MB are best. Thus, do not size large image files down to meet our requirements but send us the largest files available. (The larger the starting image is in terms of bytes, the more leeway the designer has for resizing the image in order to fill up more space should there be room available.)

Also, please remember that images must not be embedded into the body of the article submitted. Images must be submitted separately to the textual submission.

You may submit images via e-mail, via our FTP server or post a CD containing your images directly to us (please contact us for the mailing address, as this will depend upon the country from which you will be mailing).

Please also send us a head shot of yourself that is in accordance with the requirements stated above so that it can be printed with your article.

Abstracts

An abstract of your article is not required.

Author or contact information

The author's contact information and a head shot of the author are included at the end of every article. Please note the exact information you would like to appear in this section and format it according to the requirements stated above. A short biographical sketch may precede the contact information if you provide us with the necessary information (60 words or less).

Questions?

Claudia Salwiczek (Managing Editor)
c.salwiczek@oemus-media.de

cosmetic dentistry _ beauty & science

Publisher

Torsten R. Oemus
oemus@oemus-media.de

CEO

Ingolf Döbbecke
doebbecke@oemus-media.de

Members of the Board

Jürgen Isbaner
isbaner@oemus-media.de

Lutz V. Hiller
hiller@oemus-media.de

Editor-in-Chief

Dr Sushil Koirala
skoirala@wlink.com.np

Co-Editor-in-Chief

Dr So-Ran Kwon
smileksr@hotmail.com

Managing Editor

Claudia Salwiczek
c.salwiczek@oemus-media.de

Executive Producer

Gernot Meyer
meyer@oemus-media.de

Designer

Franziska Dachsel
f.dachsel@oemus-media.de

Copy Editors

Sabrina Raaff
Hans Motschmann

Published by

Oemus Media AG
Holbeinstraße 29
04229 Leipzig, Germany
Tel.: +49-341/4 84 74-0
Fax: +49-341/4 84 74-2 90
kontakt@oemus-media.de
www.oemus.com

Printed by

Messedruck Leipzig GmbH
An der Hebemärchte 6
04316 Leipzig, Germany

Advisory Board

Dr Michael Miller, USA
Dr Seok-Hoon Ko, Korea

Editorial Board

Dr Anthony Au, Australia
Dr Bao Baicheng, China
Dr Helena Lee, Singapore
Dr Hisashi Hisamitsu, Japan
Dr Jiraporn Charudilaka, Thailand
Dr Mostaque H. Sattar, Bangladesh
Dr Ratnadeep Patil, India
Dr Sim Tang Eng, Malaysia
Dr Suhit Raj Adhikari, Nepal
Dr Takashi Nakamura, Japan
Dr Vijayaratnam Vijayakumaran, Sri Lanka



Claudia Salwiczek, Managing Editor

cosmetic
dentistry _ beauty & science
is the official publication of:



Copyright Regulations

_cosmetic dentistry_beauty & science is published by Oemus Media AG and will appear in 2010 with one issue every quarter. The magazine and all articles and illustrations therein are protected by copyright. Any utilisation without the prior consent of editor and publisher is inadmissible and liable to prosecution. This applies in particular to duplicate copies, translations, microfilms, and storage and processing in electronic systems.

Reproductions, including extracts, may only be made with the permission of the publisher. Given no statement to the contrary, any submissions to the editorial department are understood to be in agreement with a full or partial publishing of said submission. The editorial department reserves the right to check all submitted articles for formal errors and factual authority, and to make amendments if necessary. No responsibility shall be taken for unsolicited books and manuscripts. Articles bearing symbols other than that of the editorial department, or which are distinguished by the name of the author, represent the opinion of the afore-mentioned, and do not have to comply with the views of Oemus Media AG. Responsibility for such articles shall be borne by the author. Responsibility for advertisements and other specially labeled items shall not be borne by the editorial department. Likewise, no responsibility shall be assumed for information published about associations, companies and commercial markets. All cases of consequential liability arising from inaccurate or faulty representation are excluded. General terms and conditions apply, legal venue is Leipzig, Germany.

cosmetic dentistry _ beauty & science



You can also subscribe via
www.oemus.com/abo

One issue free of charge!

 **Subscribe now!**

I hereby agree to receive a free trial subscription of **cosmetic dentistry** _ beauty & science (4 issues per year).

I would like to subscribe to **cosmetic dentistry** (€ 44* for German customers; € 46* for customers outside of Germany) unless a written cancellation is sent within 14 days of the receipt of the trial subscription. The subscription will be renewed automatically every year until a written cancellation is sent to OEMUS MEDIA AG, Holbeinstr. 29, 04229 Leipzig, Germany, six weeks prior to the renewal date.

▶ **Reply** via Fax +49 341 48474-290
or via E-mail to grasse@oemus-media.de

Last Name, First Name

Company

Street

ZIP/City/County

E-mail

Signature

Notice of revocation: I am able to revoke the subscription within 14 days after my order by sending a written cancellation to OEMUS MEDIA AG, Holbeinstr. 29, 04229 Leipzig, Germany.

Signature



PERFECT BLEACH – NATURALLY WHITE

The effective and gentle whitening gel for discoloured teeth

- Carbamide peroxide-based home whitening system
- Concentration available in 10 % and 17 %
- Gentle to the tooth substance
- Visible whitening after only a short time
- User-friendly, simple handling



NEW
Special Patient Kit
available

Perfect Bleach

